Published by the American Medical Association

January 1978
Volume 114, Number 1

archives of Dermatology

LUK-H04757-9-P024904

Crude Coal Tar Plus Near Ultraviolet Light Suppresses DNA Synthesis in Epidermis ..... R. B. Stoughton, P. DeQuoy, J. F. Walter 43

Sunburn Protection by Longwave Ultraviolet Radiation-Induced Pigmentation ..... K. H. Kaidbey, A. M. Kligman 46

Large Cell Acanthoma ..... H. Rahbari, H. Pinkus 49

Thyroid Neoplasms After Radiation Therapy for Adolescent Acne Vulgaris ..... E. Paloyan, A. M. Lawrence 53

The Role of Microorganisms in Diaper Dermatitis ..... J. J. Leyden, A. M. Kligman 56

Topical Use of Caffeine With Hydrocortisone in the Treatment of Atopic Dermatitis ..... R. J. Kaplan, L. Daman, E. W. Rosenberg, S. Feigenbaum 60

Radiation Dermatitis Following Electron Beam Therapy ..... N. M. Price 63

Epidermotropically Metastatic Malignant Melanoma ..... R. Kornberg, M. Harris, A. B. Ackerman 67

Cutaneous Ciliated Cysts ..... E. R. Farmer, E. B. Helwig 70

Clinical Syndrome of Chemotaxis Defect, Infections, and Hyperimmunoglobulinemia E ..... H. W. Wyre, Jr, W. T. Johnson 74

Primary Cutaneous Aspergillosis in a Leukemic Child ..... J. R. Carlile, R. E. Millet, C. T. Cho, T. S. Vats 78

A Mechanobullous Disease of the Newborn ..... S. Z. Smith, D. L. Cram 81

Hand-Schüller-Christian Disease in a Septuagenarian ..... J. F. Dolezal, S. T. Thomson 85

Dermatofibrosarcoma Protuberans With Lymph Node Involvement ..... R. J. Hausner, F. Vargas-Cortes, R. W. Alexander 88

Angioimmunoblastic Lymphadenopathy ..... R. B. Matloff, R. S. Neiman 92

Linear Unilateral Basal Cell Nevus With Comedo-like Lesions ..... T. Horio, J. Komura 95

Progressive Cribriform and Zosteriform Hyperpigmentation ..... J. M. Rower, R. D. Carr, E. D. Lowney 98

Ichthyosiform Sarcoidosis ..... Y. C. Kauh, H. E. Goody, H. A. Luscombe 100

Dystrophic Xanthomatosis in Mycosis Fungoides ..... T. Rosen 102

Smooth Muscle Hamartoma Associated With Becker's Nevus ..... R. W. Urbanek, W. C. Johnson 104

Subcutaneous Cysticercosis ..... S. Raimer, J. E. Wolf, Jr 107

Balloon Cell Nevus ..... D. K. Goette, R. D. Doty 109

Pathogenesis of Erythromelalgia ..... H. P. Jørgensen, J. Søndergaard 112

Contact Dermatitis Due to Multiple Corticosteroid Creams ..... R. J. Coskey 115

Trichophyton simii Infection in the United States Not Traceable to India ..... S. Barsky, D. Knapp, S. McMillen 118

AMA AMERICAN MEDICAL ASSOCIATION

LIBRARY

wash it. dry it. peel it.

Fostex,® the flexible therapeutic acne wash that degreases, dries, and peels. Easily integrated with all topical or systemic therapy for acne Grades I, II, and III. Convenient and economical Fostex Liquid and Cream are also effective anti-seborrheic shampoos for oily scalps associated with acne. Available as Fostex Cream in 4½ oz. jars, Fostex Cake in 3¾ oz. bars, and Fostex Liquid in 5 oz. plastic bottles.

Fostril,® the flesh-tinted drying and peeling lotion that conceals as it heals. Adaptable to Grades I, II, or III acne, Fostril is available in 1 oz. plastic tubes.

Transact,® the transparent medicated acne gel. A thin film of Transact will dry the oiliest of skin and is ideal for acne on chest, shoulders, and back. Greaseless, nonstaining, with a fresh clean fragrance. In 1 oz. plastic tubes.

WESTWOOD
PHARMACEUTICALS INC.
Buffalo, New York 14213
In Canada, Belleville, Ontario K8N 1E2

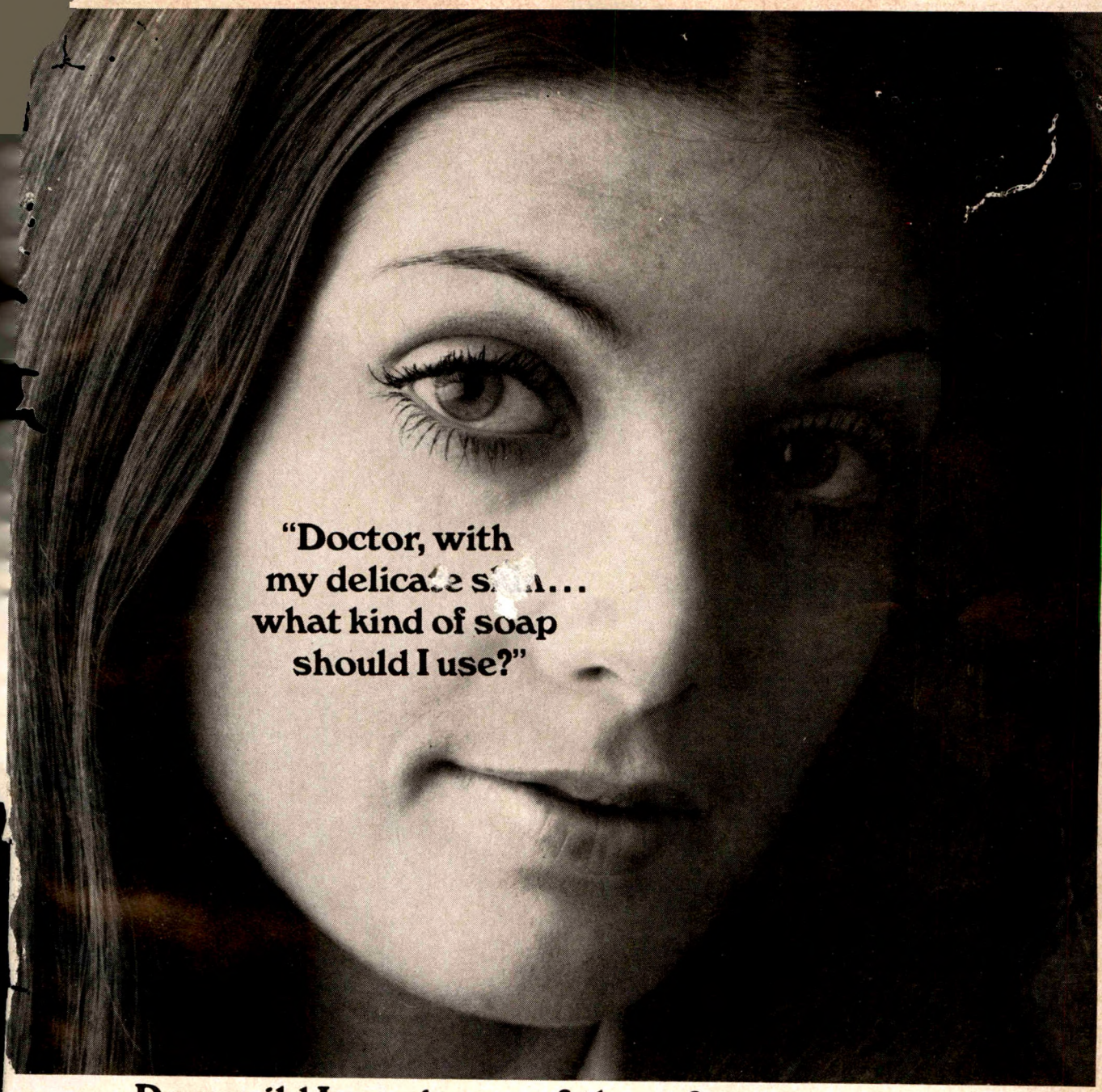

Pure mild Ivory is one of the safest possible soaps you can recommend for delicate skin. More doctors recommend Ivory than any other soap.

P 24 904

It makes sense. Ivory's absence of many extra ingredients helps minimize chances of irritation.

Thirty-eight years of laboratory testing—including patch tests and arm immersion experiments—confirm that Ivory is one of the mildest least irritating soaps you can recommend.

And 89 years of safe consumer use support this clinical experience.

Ivory may safely be used as an adjunct to treatment of scabies, seborrhea and impetigo.



Archives of DERMATOLOGY

Copyright © 1978 by the AMERICAN MEDICAL ASSOCIATION

VOL 114, NO. 1 JANUARY 1978

ORIGINAL CONTRIBUTIONS

Crude Coal Tar Plus Near Ultraviolet Light Suppresses DNA Synthesis in Epidermis
Richard B. Stoughton, MD; Peter DeQuoy, BA, La Jolla, Calif; Joseph F. Walter, MD, San Diego 43

Sunburn Protection by Longwave Ultraviolet Radiation-Induced Pigmentation
Kays H. Kaidbey, MD, Albert M. Kligman, MD, PhD, Philadelphia 46

Large Cell Acanthoma
Homayoon Rahbari, MD, Hermann Pinkus, MD, Detroit 49

Thyroid Neoplasms After Radiation Therapy for Adolescent Acne Vulgaris
Edward Paloyan, MD, A. M. Lawrence, MD, PhD, Hines, Ill 53

The Role of Microorganisms in Diaper Dermatitis
James J. Leyden, MD, Albert M. Kligman, MD, PhD, Philadelphia 56

Topical Use of Caffeine With Hydrocortisone in the Treatment of Atopic Dermatitis
Robert J. Kaplan, MD; Lauren Daman, MD; E. William Rosenberg, MD; Seth Feigenbaum, MA, Memphis 60

Radiation Dermatitis Following Electron Beam Therapy
Norman M. Price, MB, ChB, Palo Alto, Calif 63

Epidermotropically Metastatic Malignant Melanoma
Richard Kornberg, MD, San Diego; Matthew Harris, MD; A. Bernard Ackerman, MD, New York 67

Cutaneous Ciliated Cysts
Evan R. Farmer, MD, Elson B. Helwig, MD, Washington, DC 70

CASE REPORTS

Clinical Syndrome of Chemotaxis Defect, Infections, and Hyperimmunoglobulinemia E
Lt Comdr Harry W. Wyre, Jr, MC, USNR, Capt W. Taylor Johnson, MC, USN, Bethesda, Md 74

Primary Cutaneous Aspergillosis in a Leukemic Child
John R. Carlile, MD; Ruth E. Millet, MD; Cheng T. Cho, MD, PhD; Tribhawan S. Vats, MD, Kansas City, Kan 78

A Mechanobullous Disease of the Newborn
Stephen Z. Smith, MD, David L. Cram, MD, San Francisco 81

Hand-Schüller-Christian Disease in a Septuagenarian
James F. Dolezal, MD, Stephen T. Thomson, MD, Iowa City 85

Dermatofibrosarcoma Protuberans With Lymph Node Involvement
Richard J. Hausner, MD; Fernando Vargas-Cortes, MD; Ronald W. Alexander, MD, Gainesville, Fla 88

Angioimmunoblastic Lymphadenopathy
Ronald B. Matloff, MD, Richard S. Neiman, MD, Boston 92

Linear Unilateral Basal Cell Nevus With Comedo-like Lesions
Takeshi Horio, MD, Jinro Komura, MD, Kyoto, Japan 95

Progressive Cribriform and Zosteriform Hyperpigmentation
J. Marvin Rower, MD; Richard D. Carr, MD; Edmund D. Lowney, MD, Columbus, Ohio 98

Ichthyosiform Sarcoidosis
Young C. Kauh, MD; Howard E. Goody, MD, PhD; Herbert A. Luscombe, MD, Philadelphia 100

(Continued on page 4)

EDITORIAL BOARD

Chief Editor
John H. Epstein, MD
450 Sutter Street
San Francisco 94108

Assistant Chief Editor
Kimie Fukuyama, MD
San Francisco

Assistant Chief Editor
Denny L. Tuffanelli, MD
San Francisco

Donald C. Abele, MD
Augusta, Ga.

Harry L. Arnold, Jr, MD
Honolulu

Walter C. Lobitz, Jr, MD
Portland, Ore

Frederick D. Malkinson, MD
Chicago

Sigfrid A. Muller, MD
Rochester, Minn

W. Mitchell Sams, Jr, MD
Chapel Hill, NC

John S. Strauss, MD
Boston

Morris Waisman, MD
Tampa, Fla

Gerald D. Weinstein, MD
Miami

Give rough, dry skin the soft touch.

Nutraplus® restores softness to excessively rough, dry skin through enhanced absorption and moisture retention.

Nutraplus® cream or lotion with 10% urea ... stable, efficacious, economical, patient-preferred.

Owen
Owen Laboratories, Dallas, Texas 75234
Division of Alcon Laboratories, Inc.

Printed in U.S.A. ©1977

CONTENTS—Continued

Dystrophic Xanthomatosis in Mycosis Fungoides
Theodore Rosen, MD, Houston 102

Smooth Muscle Hamartoma Associated With Becker's Nevus
R. Walter Urbanek, MD, Waine C. Johnson, MD, Philadelphia 104

Subcutaneous Cysticercosis
Sharon Raimer, MD, John E. Wolf, Jr, MD, Houston 107

Balloon Cell Nevus
Lt Col Detlef K. Goette, MC, USA,
Maj Richard D. Doty, MC, USA, Presidio of San Francisco, Calif 109

Pathogenesis of Erythromelalgia
Hans Paulli Jørgensen, MD, Jørgen Søndergaard, MD, Copenhagen 112

Contact Dermatitis Due to Multiple Corticosteroid Creams
Ralph J. Coskey, MD, Detroit 115

***Trichophyton simii* Infection in the United States Not Traceable to India**
Sidney Barsky, MD; David Knapp, MD; Shirley McMillen, MA, Chicago 118

REGULAR DEPARTMENTS

Letters to the Editor 125

Man Eating Tiger? Stanley A. Spatz, MD, Hallandale, Fla, Edward Shmunes, MD, Columbia, SC . . . **More on Skin Closures** P. Haines Ely, MD, Roseville, Calif . . . **Should Therapeutic Coal-Tar Preparations Be Available Over-the-Counter?** Herschel S. Zackheim, MD, Redwood City, Calif . . . **Lessons in Grammar** Stanley A. Spatz, MD, Hallandale, Fla . . . **Lupus Band Test** Thomas G. Olsen, MD, Bethesda, Md, Eugene W. Monroe, MD, Milwaukee . . . **Relapsing Polychondritis With Positive Direct Immunofluorescence** Wilma F. Bergfeld, MD, Cleveland . . . **Swimmer's Green Hair** Lt Col Detlef K. Goette, MD, USA, Presidio, San Francisco . . . **Lupus Band Test** Eugene W. Monroe, MD, Milwaukee . . . **Contact Dermatitis Owing to Tincture of Benzoin** Ralph J. Coskey, MD, Detroit . . . **Treatment of Hallopeau's Acrodermatitis With Topical Mechlorethamine** Alfred Notowicz, MD; Ernst Stolz, MD; Nellie v. d. Heuvel, MD, Rotterdam, Netherlands . . . **Causes and Genetic Predisposition in Porphyria Cutanea Tarda** Tiong Ho Tio, MD, Rotterdam, Netherlands . . . **Leukoderma as a Sequela of Lichen Planus** Amrinder J. Kanwar, MD, Om P. Singh, MD, DVD, New Delhi . . . **Lesions Caused by Canine Ear Mites** Robert P. Herwick, MD, San Francisco

Short Report 136

Chronic Benign Familial Pemphigus Jonathan K. Wilkin, MD, Memphis

Books 140

News and Notes 144

Index to Advertisers 146

Instructions for Authors 8

SUBSCRIPTION RATES: The yearly rate of the ARCHIVES OF DERMATOLOGY is as follows: United States and US Possessions, one year, $18; two years, $28; all other countries, one year, $28; two years, $38. Special yearly price to residents, interns and medical students in the United States and US Possessions, $9.

THE ARCHIVES OF DERMATOLOGY is published monthly by the American Medical Association, 535 N Dearborn St, Chicago, IL 60610, and is an official publication of the Association. Second-class postage paid at Chicago and at additional mailing office.

Selsun®
(SELENIUM SULFIDE LOTION, U.S.P.) ℞

Brief Summary

Contains:
Selenium sulfide, 2½%, w/v; bentonite; lauric diethanolamide; ethylene glycol monostearate; titanium dioxide; amphoteric—2; sodium lauryl sulfate; sodium phosphate (monobasic); glyceryl monoricinoleate; citric acid; captan; perfume; and water.

Indications:
For the treatment of dandruff and seborrheic dermatitis of the scalp.

Contraindications:
Should not be used by patients allergic to any of its components.

Warnings:
Safety for use on infants has not been established.

Precautions:
Cutaneous sensitization of the scalp or adjacent areas has been reported; if sensitivity reactions should occur, discontinue use. Chemical conjunctivitis may result if product enters the eyes. Do not use when acute inflammation or exudation is present as an increase in absorption may occur.

Adverse Reactions:
As with other shampoos, oiliness or dryness of the hair and scalp may occur following use; there have been occasional reports of an increase in the amount of normal hair loss. Hair discoloration may occur; can be avoided or minimized by thorough rinsing.

ABBOTT
7093197

For the benefit of your patients

TRADITIONAL THERAPY

FOR DANDRUFF AND SEBORRHEIC DERMATITIS OF THE SCALP

HAS BEEN IMPROVED

NEW FRAGRANCE
(much milder)

NEW COLOR
(*much lighter*)

NEW SUDSING
(much better)

SAME EFFICACY AND SAFETY

IMPROVED

Selsun® ℞

SELENIUM SULFIDE, LOTION, U.S.P.

Please see opposite page for Brief Summary.

Archives of Dermatology

James H. Sammons, MD
Executive Vice-President

Thomas F. Hannon
Group Vice-President,
Publishing Operations

William R. Barclay, MD
Group Vice-President,
Scientific Publications

Norman D. Richey
Director, Publication
Production Division

John T. Baker
Director, Marketing Division

Helen R. Mazur
Acting Fulfillment Manager

John T. Baker, General Sales Manager; **Robert Corcoran,** Eastern Sales Manager; **Fred Bauman, Richard M. Johnson,** Eastern Sales Representatives; **Alice Harvey, William J. Healy,** Midwest Sales Representatives; **Thomas J. Carroll,** West Coast/Northern Sales Representative

PUBLICATION STAFF

Offices: 535 N Dearborn St
Chicago, IL 60610

Robert W. Mayo
Executive Editor and Director,
Scientific Publications Division

Sandra Williamson
Administrative Assistant

Marlene M. Hinsch, Production Manager

Editorial Processing Manager: Diana A. Morgan

Copy Editing: Rosanne Schulenberg (Supervisor), Patti Narret, Kathy Swartz

Proofreading: Lorraine L. Kruse (Supervisor), Verna Coffman, Patricia Coyne, Elizabeth Petrikenas, Patricia Poznanski, Mary Kay Tinerella, Dorothy Troy

Production Supervisors: Julia Bero (Layout), Thomas J. Handrigan (Illustrations), Marlene M. Hinsch (Editorial), James P. Bagniewski (Advertising)

Art and Senior Production Assistants: Betty Frigerio, Floriana Hayes, Shirley Latronica, Donna Pender, Nancy Keyes, Marilyn Moroney, Susan Routhier, JoAnne Weiskopf

Production Assistants: Karen Branham, E. Linda Eisenberg, Anna Goins, Lucille Kuznicki, Elaine Starks

Manuscript Records: Denise Henderson

Indexing: Phyllis H. McLaren (Supervisor), Jane P. Mauldin, Helen F. Topel

Please address communications concerning accepted or published communications to: AMA Specialty Journals, 535 N Dearborn St, Chicago, IL 60610.

Conditions for Acceptance of Color Illustrations

Illustrations in full color are accepted for publication in ARCHIVES OF DERMATOLOGY if the editor believes that color will add significantly to the published manuscript.

When color illustrations are accepted, the American Medical Association will pay part of the expense of reproduction and printing, the remainder to be borne by the author or the institution with which he is affiliated. After deducting AMA's contribution, the author's share is $275 for up to six square finished illustrations. Additional illustrations and special effects, such as outlining, opaquing, or surprinting, will be billed to the author at cost.

Color transparencies must be submitted for evaluation. Do not send color prints unless accompanied by original transparencies. If transparencies are mounted in frames or glass, the material should be carefully packed in gauze and sent with the manuscript in a separate container or between two pieces of pressboard.

Advertising and Subscription Information

ADVERTISING OFFICES: 535 N Dearborn St, Chicago, IL 60610, Area Code 312, 751-6000; and 600 Third Ave, New York, NY 10016, Area Code 212-867-6640.

ADVERTISING PRINCIPLES: Each advertisement in this issue has been reviewed and complies with the principles governing advertising in AMA scientific publications. A copy of these principles is available on request.

CHANGE OF ADDRESS: Please notify the publisher at least six weeks in advance, including both old and new address, and a mailing label taken from the most recent copy. Include your new zip code number.

Dome

NOW...
the only stable nystatin lotion available.

New Candex® (nystatin) Lotion

- ☐ for a dermatologic need
- ☐ for control of candidal infections
- ☐ for cosmetic elegance

New CANDEX Lotion offers excellent penetration around fingernails, into hairy areas and into infected tissue. It soothes inflammation and chafed or macerated skin. And it is paraben-free for the patient with that special sensitivity.

Also Available: CANDEX Creme (nystatin)

Indications: Candex (nystatin) Lotion and Creme are indicated for the treatment of cutaneous or mucocutaneous mycotic infections caused by Candida species (Monilia). A lotion is preferred on oozing intertriginous areas. **Contraindications:** Lesions caused by pathogens not susceptible to nystatin, and hypersensitivity to any of the components. **Precautions:** If irritation or sensitivity occurs and/or infection persists, discontinue use. If new infections appear, appropriate therapy should be instituted. **Caution:** Federal (USA) law prohibits dispensing without prescription. For external use only. Not for ophthalmic use. Store Candex (nystatin) Lotion below 86 F (30 C); avoid freezing; shake well. **Dosage and Administration:** Apply two or three times daily. Continue use for one week after clinical cure. **How Supplied:** Candex (nystatin) Lotion in 30 ml plastic bottles; Candex (nystatin) Creme in 15 g tubes.

Dome Laboratories

MILES Division Miles Laboratories Inc
West Haven Connecticut 06516 USA

© 1977 DOME LABORATORIES, DIVISION MILES LABORATORIES, INC. ALL RIGHTS RESERVED.

Instructions for Authors

Send manuscripts by first-class mail to the Chief Editor, John H. Epstein, MD, 450 Sutter St, San Francisco, CA 94108. Manuscripts are received with the understanding that they are not under simultaneous consideration by another publication. Accepted manuscripts become the permanent property of the ARCHIVES and may not be published elsewhere without permission from the publisher (AMA).

In addition, in view of *The Copyright Revision Act of 1976*, effective Jan 1, 1978, transmittal letters to the editor should contain the following language: "In consideration of the American Medical Association taking action in reviewing and editing my submission, the author(s) undersigned hereby transfers, assigns, or otherwise conveys all copyright ownership to the AMA in the event that such work is published by the AMA." We regret that transmittal letters not containing the foregoing language signed by all authors of the submission will necessitate delay in review of the manuscript.

Author Responsibility.—All accepted manuscripts are subject to copy editing. The author will receive an edited typescript rather than galley proofs for approval. The author is responsible for all statements in his work, including changes made by the copy editor.

Designate one author as correspondent and provide his address and telephone number. Order reprints at the time the typescript is returned after editorial processing. Specify address to which requests for reprints should be sent.

Manuscript Preparation.—Submit an original typescript and two high-quality copies of the entire manuscript. All copy (including references, legends, and tables) must be typed double-spaced on 22 × 28-cm (8½ × 11-inch), heavy-duty white bond paper. Ample margins should be provided.

Refer to patients by number (or, in anecdotal reports, by fictitious given names). Real names or initials should not be used in the text, tables, or illustrations.

Titles.—Titles should be short, specific, and clear. They should not exceed 42 characters per line, including punctuation and spaces, and be limited to two lines, if possible. The title page should include the full names and academic affiliations of all authors, the address to which requests for reprints should be sent, and, if the manuscript was presented at a meeting, the name of the organization, place, and date on which it was read.

Style of Writing.—The style of writing should conform to acceptable English usage and syntax. Slang, medical jargon, obscure abbreviations, and abbreviated phrasing are to be avoided.

Informed Consent.—Manuscripts reporting the results of experimental investigations of human subjects must include a statement to the effect that informed consent was obtained after the nature of the procedure(s) had been fully explained.

Abstract.—Provide an abstract (135-word maximum) of the article, including statements of the problem, method of study, results, and conclusions. The abstract replaces the summary.

References.—List references in consecutive numerical order (not alphabetically). Once a reference is cited, all subsequent citations should be to the original number. All references must be cited in the text or tables. Unpublished data and personal communications should not be listed as references. References to journal articles should include (1) author(s), (2) title, (3) journal name (as abbreviated in *Index Medicus*), (4) volume number, (5) inclusive page numbers, and (6) year, in that order. References to books should include (1) author(s), (2) chapter title (if any), (3) editor (if any), (4) title of book, (5) city of publication, (6) publisher, and (7) year. Volume and edition numbers, specific pages, and name of translator should be included when appropriate. The author is responsible for the accuracy and completeness of the references and for their correct text citation.

Metrication.—All measurements must be in metric units. English units may also be given parenthetically if the measurements were originally done in English units.

Illustrations.—Use only those illustrations that clarify and augment the text. Submit illustrations in duplicate, unmounted and untrimmed. Do not send original artwork. Send high-contrast glossy prints (not photocopies). Figure number, name of senior author, and arrow indicating "top" should be typed on a gummed label and affixed to the back of each illustration. All lettering must be legible after reduction to column size. Artwork submitted for publication may be relettered to achieve uniformity of lettering style throughout the journal. Magnification and stain should be provided when pertinent. Illustrations should preferably be in a proportion of 12.5 × 18 cm (5 × 7 inches).

An experienced medical illustrator should be employed whenever possible for the preparation of all artwork. Template lettering or preset type is preferred to hand-lettered labels. If halftone artwork with labels is submitted, affix type and leaders to a clear acetate overlay registered to the base drawing. Labels and leaders should be applied directly to the drawing board surface if the artwork consists only of line ink technique.

Illustrations in full color are accepted for publication if the editors believe that color will add significantly to the published manuscript. The ARCHIVES will pay part of the expense of reproduction and printing color illustrations, the remainder to be borne by the author or his sponsor. After deducting the ARCHIVES contribution, the author's share is $275.00 for up to six square-finished illustrations that can be arranged on a one-page layout. Any additional illustrations or special effects will be billed to the author at cost. Positive color transparencies (35 mm preferred) must be submitted for an evaluation. Do not send color prints unless accompanied by original transparencies. All transparencies should be carefully packed and sent with the manuscript.

Legends.—Legends should be typed double-spaced, beginning on a separate sheet of paper. Length should be limited to a maximum of 40 words.

Photographic Consents.—A letter of consent must accompany all photographs of patients in which a possibility of identification exists. It is not sufficient to cover the eyes to mask identity.

Acknowledgments.—Illustrations from other publications must be acknowledged. Include the following when applicable: author(s), title of article, title of journal or book, volume number, page(s), month, and year. The publisher's permission to reprint should be submitted to the ARCHIVES after the manuscript has been formally accepted.

Statistical Review.—Manuscripts containing statistical evaluations should include the name and affiliation of the statistical reviewer.

Tables.—Each table should be typed double-spaced, including all headings, on a separate sheet of 22 × 28-cm (8½ × 11-inch) paper. Do not use larger size paper. If a table must be continued, use a second sheet and repeat all heads and stubs. Each table must have a title.

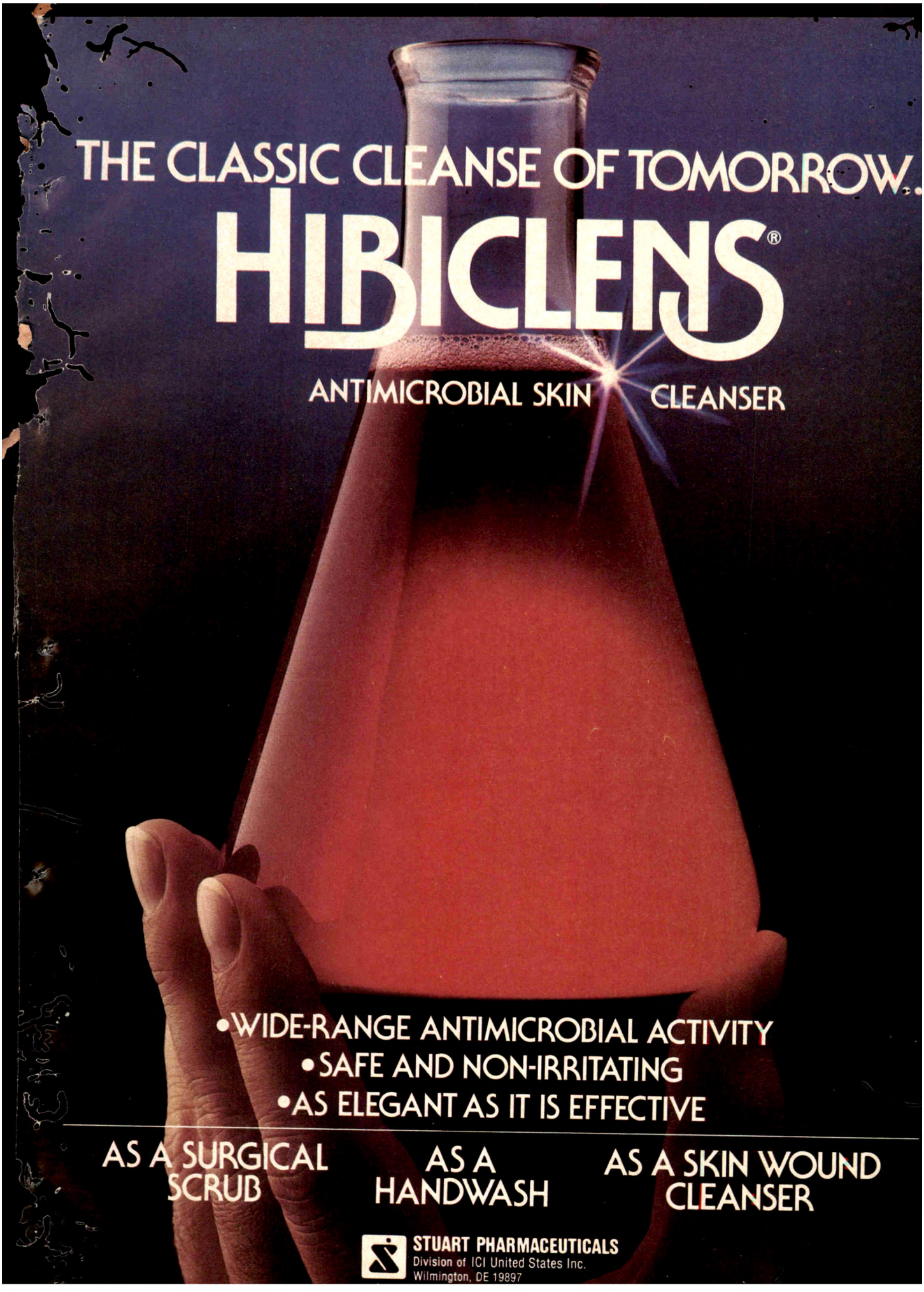
THE CLASSIC CLEANSE OF TOMORROW.
HIBICLENS®
ANTIMICROBIAL SKIN CLEANSER
•WIDE-RANGE ANTIMICROBIAL ACTIVITY
•SAFE AND NON-IRRITATING
•AS ELEGANT AS IT IS EFFECTIVE
AS A SURGICAL SCRUB
AS A HANDWASH
AS A SKIN WOUND CLEANSER
STUART PHARMACEUTICALS
Division of ICI United States Inc.
Wilmington, DE 19897



Acne illustrated by artist.

VECTRIN Capsules, 100 mg
(minocycline HCl capsules, USP)
Brief Summary of Prescribing Information

Indicated in severe acne as adjunctive therapy. Consult package insert for complete prescribing information.

Contraindication: Hypersensitivity to any tetracycline.

Warnings: When need for intensive treatment outweighs potential dangers, perform renal and liver function tests before and during therapy; also follow serum concentrations. In renal impairment, usual doses may lead to excessive accumulation and liver toxicity. Under such conditions, use lower total doses, and, in prolonged therapy, determine serum levels. The use of tetracyclines during tooth development (last half of pregnancy, infancy, and childhood to the age of 8 years) may cause permanent discoloration of the teeth (yellow-gray-brown). This is more common during long-term use but has been observed following repeated short-term courses. Enamel hypoplasia has also been reported. Tetracyclines, therefore, should not be used in this age group unless other drugs are not likely to be effective or are contraindicated. Photosensitivity manifested by an exaggerated sunburn reaction has been observed in some individuals taking tetracyclines. Advise patients apt to be exposed to direct sunlight or ultraviolet light that such reaction can occur, and discontinue treatment at first evidence of skin erythema. Studies with minocycline HCl indicated that photosensitivity did not occur. However, reports have been received. In patients with significantly impaired renal function, the antianabolic action of tetracycline may cause an increase in BUN leading to azotemia, hyperphosphatemia, and acidosis. **CNS side effects:** (light-headedness, dizziness, vertigo) have been reported, may disappear during therapy, and always disappear rapidly when drug is discontinued. Caution patients who experience these symptoms about driving vehicles or using hazardous machinery while taking this drug. **Pregnancy:** In animal studies, tetracyclines cross the placenta, are found in fetal tissues, and can have toxic effects on the developing fetus (often related to retardation of skeletal development). Embryotoxicity has been noted in animals treated early in pregnancy. The safety of minocycline HCl for use during pregnancy has not been established. **Newborns, infants, and children:** All tetracyclines form a stable calcium complex in any bone-forming tissue. Prematures, given oral doses of 25 mg/kg every six hours, demonstrated a decrease in fibula growth rate reversible when drug was discontinued. Tetracyclines

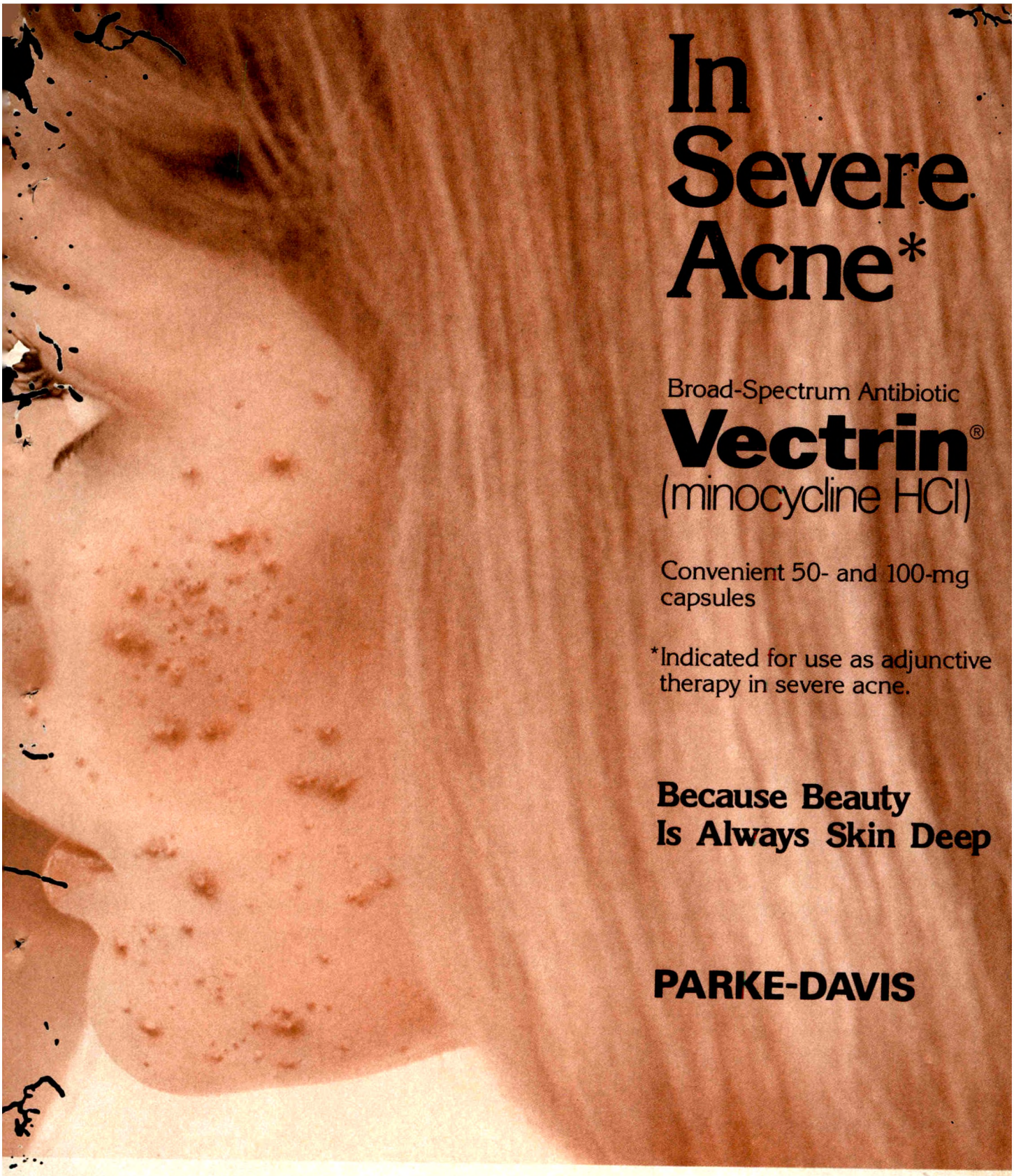

In Severe Acne*

Broad-Spectrum Antibiotic

Vectrin®
(minocycline HCl)

Convenient 50- and 100-mg capsules

*Indicated for use as adjunctive therapy in severe acne.

Because Beauty Is Always Skin Deep

PARKE-DAVIS

e present in the milk of lactating women who e taking a drug in this class.

Precautions: Use may result in overgrowth of non-susceptible organisms, including fungi. If superinfection occurs, antibiotics should be discontinued and appropriate therapy instituted. In venereal diseases when coexistent syphilis is suspected, darkfield examination should be done before treatment is started and blood serology repeated monthly for at least four months. Patients on anticoagulant therapy may require downward adjustment of such dosage. Test for organ system dysfunction (eg, renal, hepatic, and hemopoietic) in long-term use. Treat all group A beta-hemolytic streptococcal infections for at least 10 days. Avoid giving tetracycline in conjunction with penicillin.

Adverse Reactions: GI: Anorexia, nausea, vomiting, diarrhea, glossitis, dysphagia, enterocolitis, inflammatory lesions (with monilial overgrowth) in anogenital region. **Skin:** Maculopapular and erythematous rashes. Exfoliative dermatitis (uncommon). Photosensitivity is discussed above. (See Warnings.) **Renal toxicity:** Rise in BUN, dose-related. (See Warnings.) **Hypersensitivity reactions:** Urticaria, angioneurotic edema, anaphylaxis, anaphylactoid purpura, pericarditis, exacerbation of systemic lupus erythematosus. In young infants, bulging fontanels have been reported following full therapeutic dosage, disappearing rapidly when drug was discontinued. **Blood:** Hemolytic anemia, thrombocytopenia, neutropenia, eosinophilia. **CNS:** (See Warnings.) When given over prolonged periods, tetracyclines may produce brown-black microscopic discoloration of thyroid glands; no abnormalities of thyroid function studies are known to occur.

NOTE: Concomitant therapy: Antacids containing aluminum, calcium, or magnesium impair absorption; do not give to patients taking oral tetracycline. Studies to date indicate that absorption of VECTRIN (minocycline hydrochloride) is not notably influenced by foods and dairy products.

Full prescribing information available upon request.

PARKE, DAVIS & COMPANY
Detroit, Michigan 48232

WHEN DERMATOSES TAKE SHAPE

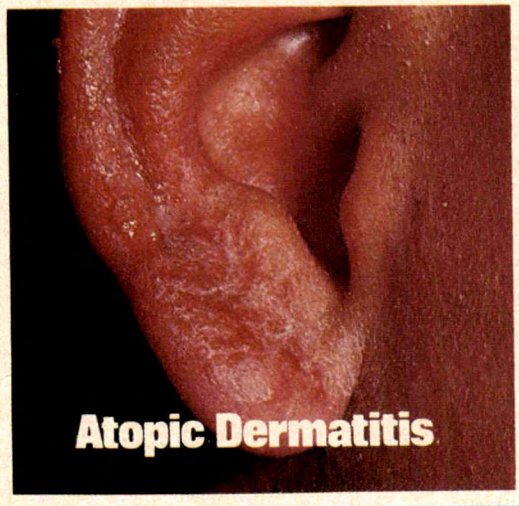

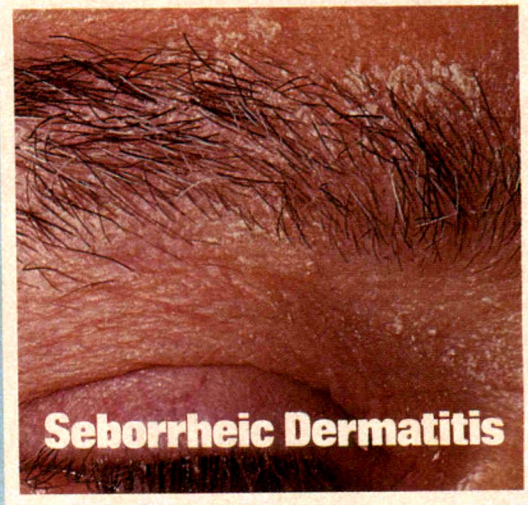

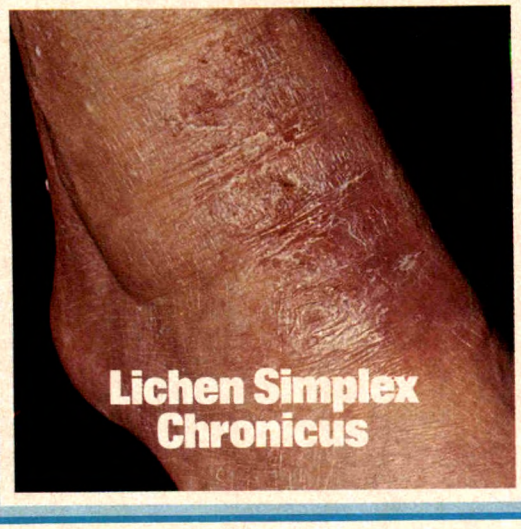

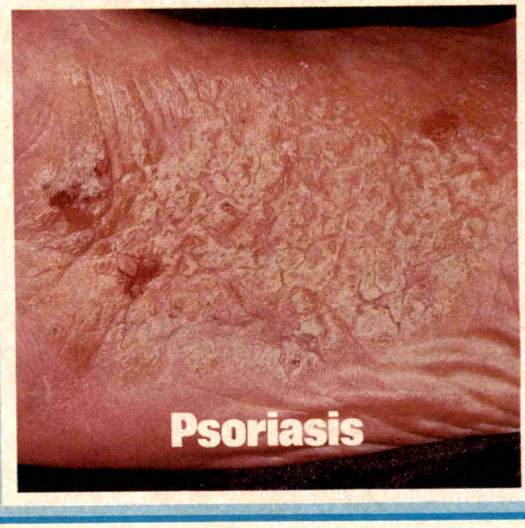

COPYRIGHT © 1977, SCHERING CORPORATION. ALL RIGHTS RESERVED. SLS-866

Schering

DIPROSONE® TAKES CHARGE!

BRAND OF
BETAMETHASONE
DIPROPIONATE

Prompt and Effective Topical Action for Everyday Steroid-Responsive Dermatoses

- Rapid onset of response
- Economy and convenience of b.i.d. dosage
- Occlusive dressings rarely needed
- Sensitivity is unusual



Available for prescribing flexibility in cream, ointment, and lotion. Also available in aerosol, which is indicated for contact dermatitis only.

Please see Clinical Considerations section which follows...

DIPROSONE®
brand of betamethasone dipropionate
Cream 0.05%, Ointment 0.05%, Lotion 0.05% w/w, Aerosol 0.1% w/w
(Potency expressed as betamethasone)
For Dermatologic Use Only

ACTIONS: DIPROSONE **Cream, Ointment, Lotion,** and **Aerosol** are primarily effective because of their anti-inflammatory, antipruritic, and vasoconstrictive actions.

INDICATIONS: DIPROSONE **Cream, Ointment,** and **Lotion** are indicated for the relief of the inflammatory manifestations of corticosteroid-responsive dermatoses.

DIPROSONE **Aerosol** is indicated solely for the adjunctive topical management for the relief of inflammatory manifestations of acute contact dermatitis.

DIPROSONE **Aerosol** has not been shown to be effective in any steroid-responsive dermatosis other than contact dermatitis.

CONTRAINDICATIONS: DIPROSONE **Cream, Ointment, Lotion,** and **Aerosol** are contraindicated in vaccinia and varicella. Topical steroids are contraindicated in those patients with a history of hypersensitivity to any of the components of such preparations.

DIPROSONE **Aerosol** is also contraindicated for use under occlusive dressings.

WARNINGS FOR DIPROSONE AEROSOL: Keep DIPROSONE **Aerosol** away from eyes or other mucous membranes. Use only as directed; intentional misuse by deliberately concentrating or inhaling the contents can be harmful or fatal. Avoid freezing of the tissue by not spraying for more than three seconds, at a distance of not less than six inches. Contents under pressure. Do not puncture. Do not use or store near heat or open flame. Exposure to temperatures above 120° Farenheit may cause bursting. Never throw container into fire or incinerator. Keep DIPROSONE **Aerosol** out of reach of children.

PRECAUTIONS: If irritation develops with the use of DIPROSONE products, treatment should be discontinued and appropriate therapy instituted. In the presence of an infection, the use of an appropriate antifungal or antibacterial agent should be instituted. If a favorable response does not occur promptly, the corticosteroid should be discontinued until the infection has been adequately controlled.

If extensive areas are treated or if the occlusive technique is used, the possibility exists of increased systemic absorption of the corticosteroid and suitable precautions should be taken. Although topical steroids have not been reported to have an adverse effect on pregnancy, the safety of their use in pregnant females has not been absolutely established. Therefore, they should not be used extensively in pregnant patients, in large amounts or for prolonged periods of time. DIPROSONE products are not for ophthalmic use.

ADVERSE REACTIONS: The following local adverse reactions have been reported with topical corticosteroids: burning; itching; irritation; dryness; folliculitis; hypertrichosis; acneiform eruptions; hypopigmentation. Additionally, the following may occur with DIPROSONE **Aerosol** and also may occur more frequently with occlusive dressings than without such therapy: maceration of the skin; secondary infection; skin atrophy; striae; miliaria.

DOSAGE AND ADMINISTRATION: DIPROSONE **Cream** and **Ointment** are applied as a thin film over the affected skin areas twice daily, in the morning and at night. Clinical studies of DIPROSONE have indicated that applications twice a day are generally adequate.

Apply a few drops of DIPROSONE **Lotion** to the affected areas and massage lightly until it disappears. Apply twice daily, in the morning and at night. For the most effective and economical use, apply nozzle to affected area and gently squeeze bottle.

DIPROSONE **Aerosol** may be held upright or inverted during use. The spray should be directed onto the affected area from a distance of not less than six inches and applied for only three seconds. Apply DIPROSONE **Aerosol** sparingly to the affected skin area three times a day.

Aerosol packaged by Aerosol Techniques, Inc., Armstrong Laboratories Division, West Roxbury, MA. 02132.

For more complete details, consult package insert or Schering literature available from your Schering Representative or Professional Services Department, Schering Corporation, Kenilworth, New Jersey 07033.

DECEMBER 1977



A safe, economical method of permanent hair removal– from face, legs, body

To save valuable office time, you can confidently recommend Perma Tweez to your patients for their home use.

- Battery-operated instrument self-sterilizes when current flows.
- Patented self-correcting needle.
- No-puncture safety feature helps prevent infection.
- Proved clinically safe (report on request).

FOR PHYSICIAN ORDERING

GENERAL MEDICAL CO., Dept D-93
1935 Armacost Ave.
West Los Angeles, CA 90025
30 DAY FREE TRIAL EXAMINATION.
(May be returned with no obligation.)

☐ PERMA TWEEZ $19.95
☐ ATTACHMENT $3.00
(for treating others)
☐ INVOICE AFTER 30 DAYS
☐ CHECK ENCLOSED

DR_____

STREET_____

C/S_____ ZIP_____

The Corneocyte Count Down.

A high corneocyte count means scaling, flaking and an itchy scalp. Unsightly and unwanted by your dandruff patients.

Chances are they have tried the TV-promoted brands before consulting you about their problem.

Prescribe Exsel® (selenium sulfide) 2.5%. Clinically proven the most potent dandruff shampoo available. It gets rid of the unwanted corneocyte scales and retards their redevelopment for days.*

And Exsel offers one distinct advantage over other Rx anti-dandruff preparations: cosmetic elegance. Pleasing, fragrant lime-scented Exsel shampoo lathers richly, therefore assuring greater patient acceptability and better compliance with your instructions.

Exsel® (selenium sulfide) 2.5% Lotion- CONTAINS: selenium sulfide...2.5% with: edetate disodium; bentonite; sodium linear alkylate sulfonate; alphaolefin sulfonate; glyceryl monoricinoleate; silicone; titanium dioxide; citric acid monohydrate; sodium phosphate monobasic, monohydrate; perfume and purified water. ACTIONS: The mechanism of action of selenium sulfide in seborrheic dermatitis is unknown. INDICATIONS: Selenium sulfide is indicated in the treatment of seborrheic dermatitis of the scalp, including dandruff. CONTRAINDICATIONS: The product should not be used by patients allergic to any of its components. WARNINGS: Safety for use in infants has not been established. PRECAUTIONS: 1. Chemical conjunctivitis may result if this preparation enters the eyes. 2. The product should be used with caution when acute inflammation or exudation is present as an increase in absorption may occur. ADVERSE REACTIONS: 1. Hair loss has been reported with the use of the product. 2. Discoloration of the hair may follow the use of selenium sulfide. This can be minimized by careful rinsing of the hair after treatment. 3. Oiliness of the hair and scalp may increase following the use of this product.

*Kligman, A.M. et al. Dandruff: It's nature and treatment, University of Pennsylvania, Department of Dermatology, Duhring Laboratories. Paper presented at American Academy of Dermatology, San Francisco, 1975.

Herbert Laboratories
Dermatology Division of
Allergan Pharmaceuticals, Inc.
Irvine, California 92713, U.S.A.

Count on Exsel.
(selenium sulfide) 2.5%

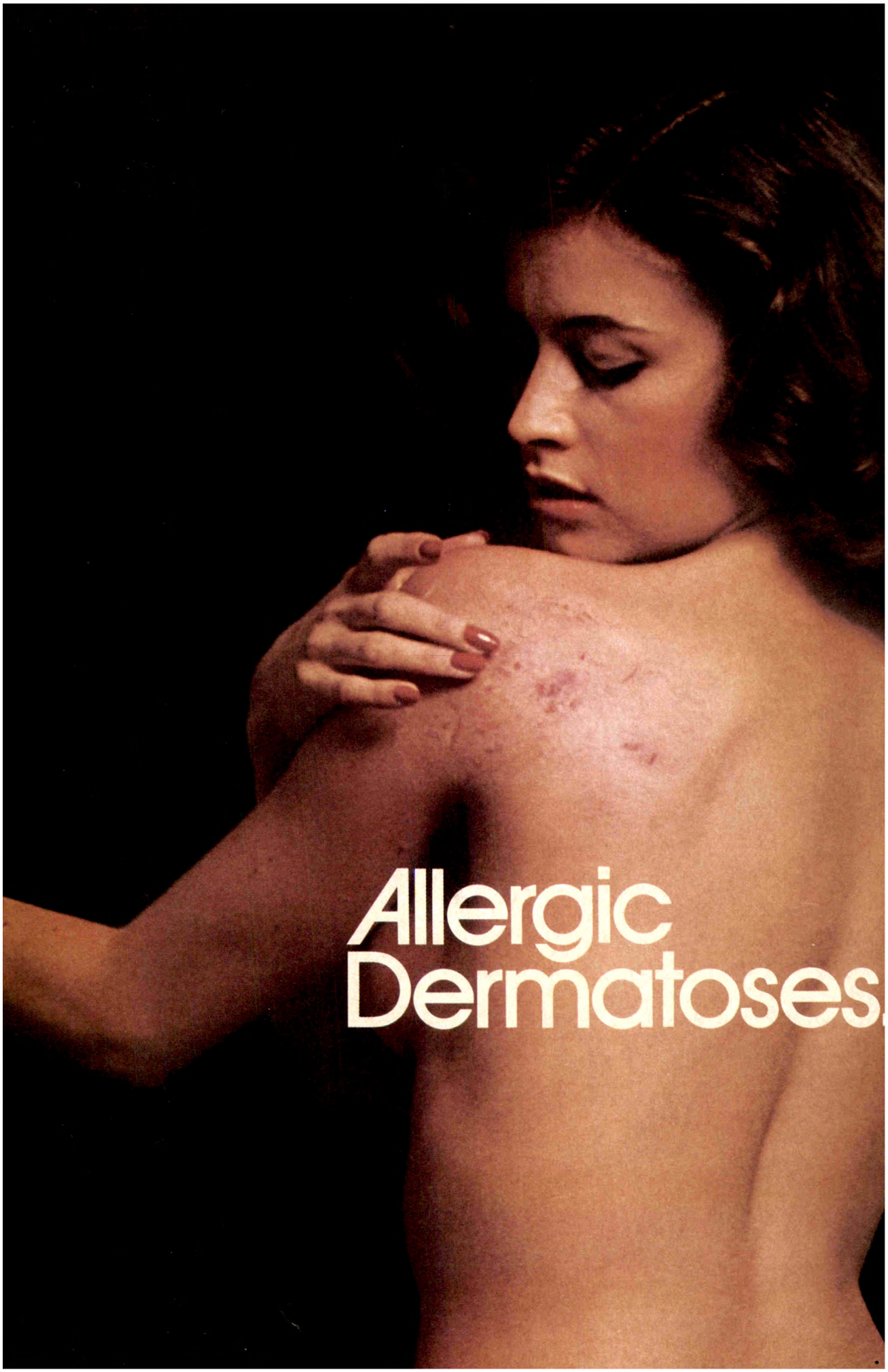

Allergic Dermatoses

with strong emotional overlay

the cause can be obscure

Factors precipitating allergic dermatoses with strong emotional overlay, which can range from allergens to anxiety, can be difficult to identify.

successful treatment often includes

Atarax®
(hydroxyzine HCl)

TABLETS: 10 mg, 25 mg, 50 mg, and 100 mg

- rapid antianxiety action
- demonstrated antihistaminic activity

ROERIG Pfizer
A division of Pfizer Pharmaceuticals
New York, New York 10017

pplehead art, hand-
arved from an apple
nd dehydrated in stages. Apple
arving is a 250 year old art in
his country.

©1977, W.P. Inc.

Recommend our therapeutic moisture system.

"A drier than normal stratum corneum has less surface area than the tissues below and the skin surface first becomes taut and then cracks to form scales, or fissures, where the stratum corneum is very thick... any physiologic condition which decreases the water content of the stratum corneum may lead to tautness and scale formation.

"Conversely, hydration of the stratum corneum makes it more pliable... warmer climates and all conditions increasing the water content of the stratum corneum will be helpful in treating dry skin and scaling dermatoses.

"The application of emollient films to skin still moist from bathing will trap a certain amount of water, increase the volume and surface area of the horny layer, and permit the stratum corneum to cover the body surface more completely and thereby diminish the tautness of skin and scale formation."*

The Alpha Keri® moisture system is a time tested, efficient way to hydrate the stratum corneum. Alpha Keri bath oil's emollient film helps the skin retain moisture with the first bath. And Keri® Lotion can be applied between baths as often as needed. Dryness, scaling and itching are relieved in minutes.

Alpha Keri and Keri Lotion are indicated for adjunctive treatment of the entire range of dry, scaling, pruritic dermatoses. Alpha Keri is available in 4, 8, and 16 oz. plastic bottles, and 5 oz. aerosol shower spray. Keri Lotion, scented and unscented, is available in 6½, 13, and 20 fl. oz. dispenser bottles.

*Moschella SL, Pillsbury DM, Hurley HJ: *Dermatology*, Vol. 2. W. B. Saunders Co., Philadelphia, 1975. p. 1059-60.

WESTWOOD
PHARMACEUTICALS INC.
Buffalo, New York 14213

Efudex 5% Cream offers the dermatologist:

- An effective topical alternative to surgery for multiple lesions and difficult treatment sites.
- Cosmetically gratifying results, with minimal or no scarring. No systemic toxicity.
- Convenient, economical b.i.d. application. Apply with care near eyes, nose and mouth; wash hands immediately afterward if applied with fingers.

p 24 904

Efudex® 5% Cream fluorouracil/Roche

An exclusive Roche formulation Also available as 5% Efudex Solution

Before prescribing, please consult complete product information, a summary of which follows:

Indications: Multiple actinic or solar keratoses. In 5% strength, superficial basal cell carcinoma when conventional methods are impractical, such as with multiple lesions or difficult treatment sites. Establish diagnosis before treating, as this method has not been proven effective in other types of basal cell carcinomas. Conventional techniques preferred for isolated, easily accessible lesions, as success rate is nearly 100%. Success rate with Efudex is about 93%.

Contraindications: Patients with known hypersensitivity to any of its components.

Warnings: If occlusive dressing is used, may increase inflammatory reactions in adjacent normal skin. Avoid prolonged exposure to ultraviolet rays. Safe use in pregnancy not established.

Precautions: If applied with fingers, wash hands immediately. Apply with care near eyes, nose and mouth. Solar keratoses failing to respond should be biopsied. Warn patients that treated area may be unsightly during therapy and sometimes for several weeks after. Perform follow-up biopsies in superficial basal cell carcinoma.

Adverse Reactions: Local—pain, pruritus, hyperpigmentation and burning at application site most frequent; also dermatitis, scarring, soreness, tenderness, suppuration, scaling and swelling. Also reported—insomnia, stomatitis, irritability, medicinal taste, photosensitivity, lacrimation, telangiectasia, leukocytosis, thrombocytopenia, toxic granulation and eosinophilia.

Dosage and Administration: When Efudex is applied erythema occurs, then vesiculation, erosion, ulceration, necrosis, epithelization. *Actinic or solar keratosis*—apply sufficient quantity to cover lesions, twice daily. Usual length of therapy is 2 to 4 weeks. *Superficial basal cell carcinomas*—apply sufficient quantity **(only 5% strength recommended)** to cover lesions, twice daily. Continue treatment for at least 3 to 6 weeks, but possibly as long as 10 to 12.

How Supplied: Solution, 10-ml drop dispensers containing 2% or 5% fluorouracil on a weight/weight basis. Cream, 25-Gm tubes containing 5% fluorouracil in a vanishing cream base.

ROCHE

Roche Laboratories
Division of Hoffmann-La Roche Inc.
Nutley, New Jersey 07110

An excellent blend of clinical efficacy and cosmetic acceptance. Now indicated for seborrheic dermatitis.

Obviously, efficacy is foremost in your mind when you recommend a therapeutic shampoo. And efficacy, coupled with cosmetic acceptability, usually guarantees a successful therapeutic course.

That's why Head & Shoulders is so highly regarded in the treatment of dandruff.

Clinically effective

For years, Head & Shoulders has proved effective in the treatment of dandruff—whether for initial therapy or long-term control. And now, research shows that Head & Shoulders is effective in the treatment of seborrheic dermatitis.*

Cosmetically pleasing

Head & Shoulders lathers well, has a pleasant odor and appearance, and need not be left on the scalp for an extended period of time. Also, it leaves hair clean, manageable, and attractive.

Head & Shoulders®

You'll like it for its therapeutic benefits. Your patients will like it for its cosmetic appeal.

*Orentreich, N.: A clinical evaluation of two shampoos in the treatment of seborrheic dermatitis, J. Soc. Cosmet. Chem. 23:189 (March 3) 1972.

© 1974 Procter & Gamble 1195-058

QUICK RELIEF

for Insurance Headaches

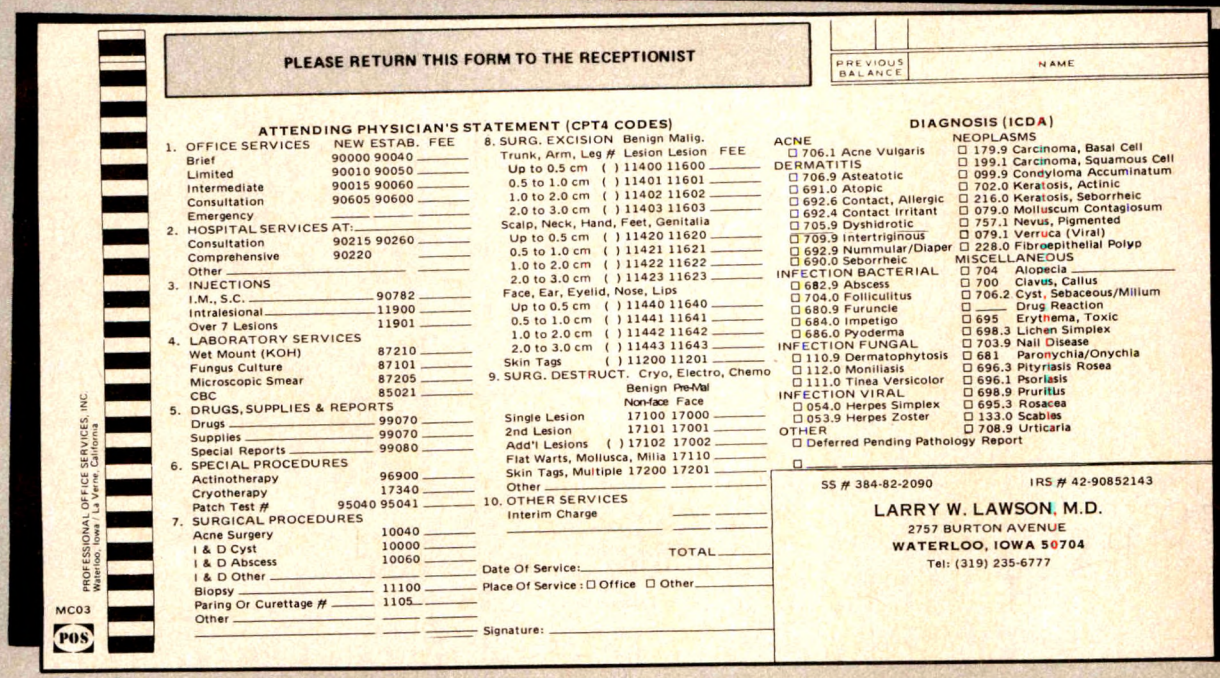

PLEASE RETURN THIS FORM TO THE RECEPTIONIST

PREVIOUS BALANCE | NAME

ATTENDING PHYSICIAN'S STATEMENT (CPT4 CODES)

	NEW	ESTAB.	FEE
1. OFFICE SERVICES			
Brief	90000	90040	
Limited	90010	90050	
Intermediate	90015	90060	
Consultation	90605	90600	
Emergency			
2. HOSPITAL SERVICES AT:			
Consultation	90215	90260	
Comprehensive	90220		
Other			
3. INJECTIONS			
I.M., S.C.		90782	
Intralesional		11900	
Over 7 Lesions		11901	
4. LABORATORY SERVICES			
Wet Mount (KOH)		87210	
Fungus Culture		87101	
Microscopic Smear		87205	
CBC		85021	
5. DRUGS, SUPPLIES & REPORTS			
Drugs		99070	
Supplies		99070	
Special Reports		99080	
6. SPECIAL PROCEDURES			
Actinotherapy		96900	
Cryotherapy		17340	
Patch Test #	95040	95041	
7. SURGICAL PROCEDURES			
Acne Surgery		10040	
I & D Cyst		10000	
I & D Abscess		10060	
I & D Other			
Biopsy		11100	
Paring Or Curettage #		1105	
Other			

8. SURG. EXCISION	Benign Lesion	Malig. Lesion	FEE
Trunk, Arm, Leg #			
Up to 0.5 cm	( ) 11400	11600	
0.5 to 1.0 cm	( ) 11401	11601	
1.0 to 2.0 cm	( ) 11402	11602	
2.0 to 3.0 cm	( ) 11403	11603	
Scalp, Neck, Hand, Feet, Genitalia			
Up to 0.5 cm	( ) 11420	11620	
0.5 to 1.0 cm	( ) 11421	11621	
1.0 to 2.0 cm	( ) 11422	11622	
2.0 to 3.0 cm	( ) 11423	11623	
Face, Ear, Eyelid, Nose, Lips			
Up to 0.5 cm	( ) 11440	11640	
0.5 to 1.0 cm	( ) 11441	11641	
1.0 to 2.0 cm	( ) 11442	11642	
2.0 to 3.0 cm	( ) 11443	11643	
Skin Tags	( ) 11200	11201	

9. SURG. DESTRUCT. Cryo, Electro, Chemo	Benign Non-face	Pre-Mal Face	
Single Lesion	17100	17000	
2nd Lesion	17101	17001	
Add'l Lesions	( ) 17102	17002	
Flat Warts, Mollusca, Milia		17110	
Skin Tags, Multiple	17200	17201	
Other			
10. OTHER SERVICES			
Interim Charge			
TOTAL			

Date Of Service:

Place Of Service: ☐ Office ☐ Other

Signature:

DIAGNOSIS (ICDA)

ACNE
- ☐ 706.1 Acne Vulgaris

DERMATITIS
- ☐ 706.9 Asteatotic
- ☐ 691.0 Atopic
- ☐ 692.6 Contact, Allergic
- ☐ 692.4 Contact Irritant
- ☐ 705.9 Dyshidrotic
- ☐ 709.9 Intertriginous
- ☐ 692.9 Nummular/Diaper
- ☐ 690.0 Seborrheic

INFECTION BACTERIAL
- ☐ 682.9 Abscess
- ☐ 704.0 Folliculitus
- ☐ 680.9 Furuncle
- ☐ 684.0 Impetigo
- ☐ 686.0 Pyoderma

INFECTION FUNGAL
- ☐ 110.9 Dermatophytosis
- ☐ 112.0 Moniliasis
- ☐ 111.0 Tinea Versicolor

INFECTION VIRAL
- ☐ 054.0 Herpes Simplex
- ☐ 053.9 Herpes Zoster

OTHER
- ☐ Deferred Pending Pathology Report
- ☐

NEOPLASMS
- ☐ 179.9 Carcinoma, Basal Cell
- ☐ 199.1 Carcinoma, Squamous Cell
- ☐ 099.9 Condyloma Accuminatum
- ☐ 702.0 Keratosis, Actinic
- ☐ 216.0 Keratosis, Seborrheic
- ☐ 079.0 Molluscum Contagiosum
- ☐ 757.1 Nevus, Pigmented
- ☐ 079.1 Verruca (Viral)
- ☐ 228.0 Fibroepithelial Polyp

MISCELLANEOUS
- ☐ 704 Alopecia
- ☐ 700 Clavus, Callus
- ☐ 706.2 Cyst, Sebaceous/Milium
- ☐ ____ Drug Reaction
- ☐ 695 Erythema, Toxic
- ☐ 698.3 Lichen Simplex
- ☐ 703.9 Nail Disease
- ☐ 681 Paronychia/Onychia
- ☐ 696.3 Pityriasis Rosea
- ☐ 696.1 Psoriasis
- ☐ 698.9 Pruritus
- ☐ 695.3 Rosacea
- ☐ 133.0 Scabies
- ☐ 708.9 Urticaria

SS # 384-82-2090 IRS # 42-90852143

LARRY W. LAWSON, M.D.
2757 BURTON AVENUE
WATERLOO, IOWA 50704
Tel: (319) 235-6777

PROFESSIONAL OFFICE SERVICES, INC.
Waterloo, Iowa / La Verne, California

MC03

POS

Laboratory tests prove: You can speed up insurance claim handling with MED-I-CLAIM From Professional Office Services

Your insurance claim handling paperwork is complete with this one Attending Physician's Statement.

These 2 and 3 part forms are painless because you complete all paperwork in one writing.

MED-I-CLAIM works with all popular pegboard systems

MED-I-CLAIM is personalized and tailored to the needs of your practice with AMA or state procedural codes.

SIDE EFFECT!

You improve Cash Flow because every client's billing is ready for collection immediately.

POS®

Professional Office Services Inc.

2757 Burton Avenue
P.O. Box 450
Waterloo, Iowa 50704

Mail this coupon today for a sample and complete information on MED-I-CLAIM.

Name _____

Address _____

City _____ State _____ Zip _____

Superior to the most widely used brand of topical steroid in psoriasis and atopic dermatitis.

Based on the evidence.

In double-blind, parallel studies,* Topicort® (desoximetasone) Emollient Cream 0.25% demonstrated greater efficacy than betamethasone valerate cream 0.1% in the two most common corticosteroid-responsive dermatoses.

		NO. OF PATIENTS	Overall Evaluation: EXCELLENT & GOOD	Overall Evaluation: EXCELLENT (CLEARANCE OF DISEASE)
ATOPIC DERMATITIS	TOPICORT	39	100%	77%
	BETAMETHASONE VALERATE	41	90%	54%
PSORIASIS	TOPICORT	61	84%	43%
	BETAMETHASONE VALERATE	56	63%	21%

These recently conducted U.S. studies confirm the outstanding worldwide acceptance of Topicort in more than 30 countries for up to 4 years.

*Data on file and available upon request from Hoechst-Roussel Pharmaceuticals Inc., Somerville, New Jersey 08876.

Less than 1% incidence of side effects.
Of 488 patients in the clinical trials, side effects were seen in only 4 (0.8%).* And in 2 of the 4 patients, the relationship of side effects to the drug was uncertain.

The convenience of b.i.d. dosage. And the uniqueness of a preservative-free, emollient cream base.
The specially developed, preservative-free Topicort base combines the emollience of an ointment with the cosmetic acceptability of a cream in a water-in-oil emulsion. This makes Topicort (desoximetasone) especially useful in psoriatic and other dry, scaly dermatoses.

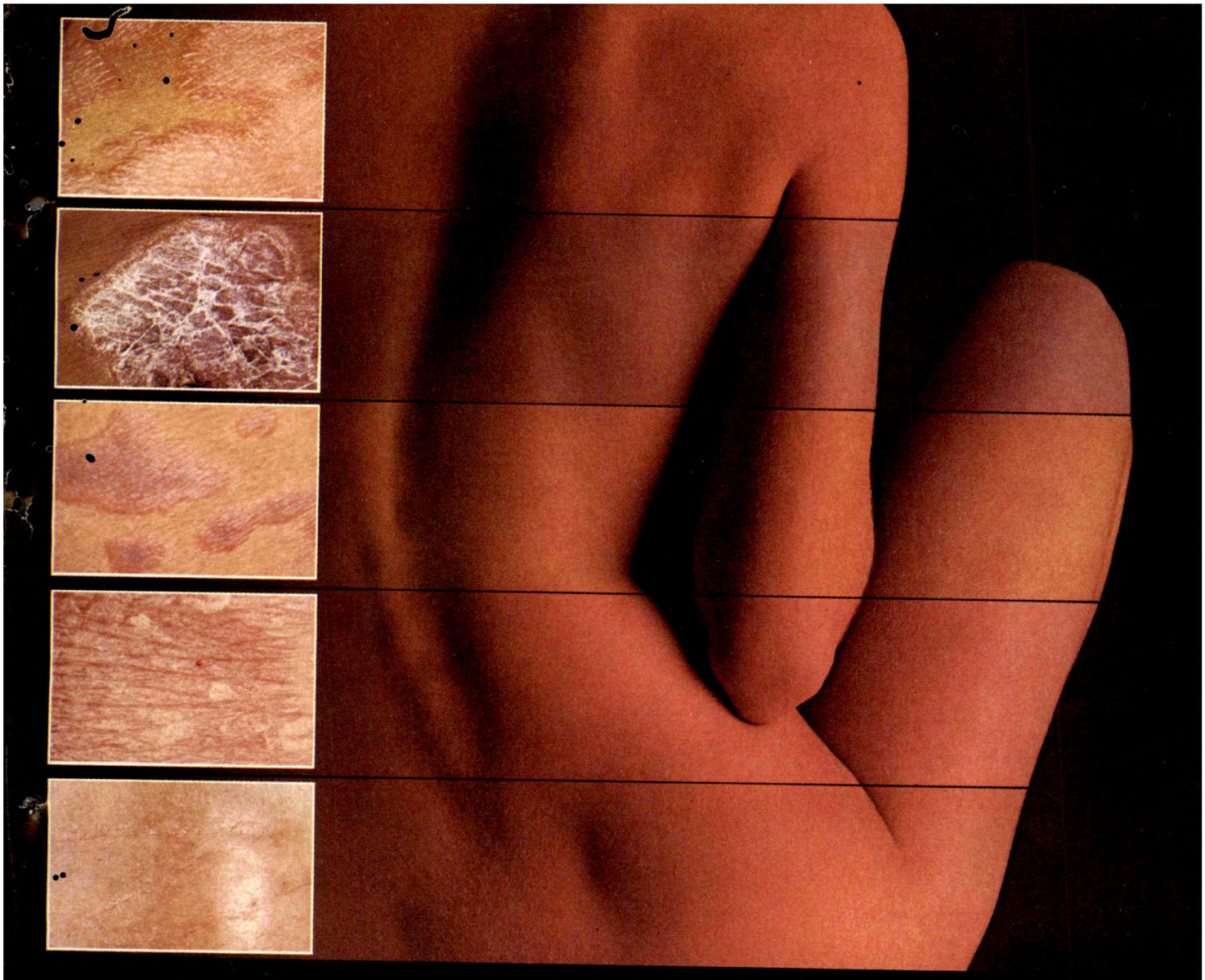

TOPICORT®
(DESOXIMETASONE)
EMOLLIENT CREAM 0.25%

An important innovation from the research laboratories of
Hoechst-Roussel Pharmaceuticals Inc.

Please consult full prescribing information on following page.

EDITION 9/77

TOPICORT®(desoximetasone) EMOLLIENT CREAM 0.25%

Description: Topicort® (desoximetasone) Emollient Cream 0.25% contains the active synthetic corticosteroid desoximetasone. The chemical name of desoximetasone is 9α - fluoro - 11β,21 - dihydroxy - 16α - methylpregna - 1,4 - diene-3,20-dione. The chemical structure is:

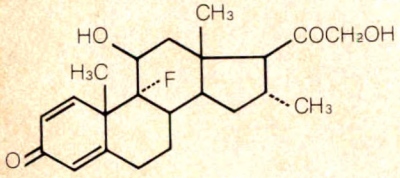

Each gram of Topicort® (desoximetasone) Emollient Cream 0.25% contains 2.5 mg desoximetasone in an emollient cream consisting of isopropyl myristate, cetylstearyl alcohol, white petrolatum, mineral oil, lanolin alcohol and purified water.

Actions: Topicort® (desoximetasone) Emollient Cream is primarily effective because of its anti-inflammatory, antipruritic and vasoconstrictive actions.

Indications: Topicort® (desoximetasone) Emollient Cream is indicated for the relief of inflammatory manifestations of corticosteroid-responsive dermatoses.

Contraindications: Topical steroids are contraindicated in vaccinia, varicella and in those patients with a history of hypersensitivity to any of the components of the preparation. This preparation is not for ophthalmic use.

Precautions: If local infection exists, suitable concomitant antimicrobial or antifungal therapy should be administered. If a favorable response does not occur promptly, application of the corticosteroid should be discontinued until the infection is adequately controlled.

Although systemic side effects associated with absorption of topical corticosteroid preparations are rare, their possible occurrence must be kept in mind when these preparations are used over large areas or for an extended period of time, or if occlusive technique is used.

If irritation or sensitization develops, the preparation should be discontinued and appropriate therapy instituted.

Although topical steroids have not been reported to have an adverse effect on pregnancy, the safety of their use during pregnancy has not been absolutely established; therefore, they should not be used extensively on pregnant patients, in large amounts, or for prolonged periods of time.

Adverse Reactions: The following local adverse reactions have been reported with topical corticosteroids: burning, itching, irritation, striae, skin atrophy, secondary infection, dryness, folliculitis, hypertrichosis, acneform eruptions and hypopigmentation. The following may occur more frequently with occlusive dressings: maceration of the skin, secondary infection, skin atrophy, striae, and miliaria.

Dosage and Administration: Apply a thin film of Topicort® (desoximetasone) Emollient Cream 0.25% to the affected skin areas twice daily. Rub in gently.

How Supplied: Topicort® (desoximetasone) Emollient Cream 0.25% is supplied in 15-gram tubes.

HOECHST-ROUSSEL
PHARMACEUTICALS INCORPORATED
SOMERVILLE, NEW JERSEY 08876

Expand Your Horizons And Those of Your Nursing Home Patients

This compilation of articles and memoranda is geared to further your understanding of your role in regard to: your nursing home patients; their families; and the nursing home staff. Published by the American Medical Association, **The Medical Director in the Long-Term Care Facility** is the only book of its kind.

The Table of Contents includes:

- Doctor's Role in the Nursing Home
- Medical Direction in Long-Term Care Facilities
- Role Relationships of the Medical Director
- The Role of the Physician in Long-Term Care Facilities—The Administrator's Viewpoint
- Federal Regulations and Proposed Duties for the Medical Director in the Skilled Nursing Facility
- The Nursing Home's Medical Director—A New Breed of Mentor

The Medical Director in the Long-Term Care Facility should help you to meet the nursing home problems which you encounter. Use the coupon to order this valuable compendium today.

$3.50

S/J

Order Dept./OP-22
American Medical Association
535 N. Dearborn/Chicago, IL 60610

Please send _____ copy(ies) of THE MEDICAL DIRECTOR IN THE LONG-TERM CARE FACILITY, OP-22, at $3.50 each. Enclosed is $_____, payable to the AMA.

Name _____

Address _____

City/State/Zip _____

Wind up... to improve venous return

Dome

Dome-Paste® Bandage

Modified Unna's Boot

Encourages healing of skin lesions... contributes to patient's comfort

Now a new 3-inch width... easy application for smaller limbs, fewer wrinkling problems than with fraying bandages, greater economy.

- ☐ Also in standard 4-inch width with nonraveling, thread-locked edges.
- ☐ Both sizes in 10-yard rolls; neutral-colored, rayon-reinforced for strength.
- ☐ Uniformly impregnated with zinc oxide, gelatin, calamine.
- ☐ Each roll sealed in a polyethylene bag to preserve freshness.
- ☐ Always ready for immediate use.

DOM-1306R2

Dome Laboratories

Division Miles Laboratories Inc MILES
West Haven Connecticut 06516 USA

Atopic dermatitis o
hand and wrist
36 year old male

Added versatility in dermatology

new Lidex®-E (fluocinonide) 0.05%

The established potency of fluocinonide, in a soothing emollient base.

Less drying than a cream, with the lubricating qualities of an ointment–cosmetically acceptable to patients.

Especially useful wherever a soothing topical steroid is indicated, as in atopic dermatitis.

Available in 15g and 60g tubes.

SYNTEX

Please see following page for summary of prescribing information

new Lidex® E (fluocinonide) Cream 0.05%

Prescribing Information

Description LIDEX-E cream 0.05% contains the active compound fluocinonide. Fluocinonide, which is the 21-acetate ester of fluocinolone acetonide, has the chemical formula 6α, 9-difluoro-11β, 16α, 17, 21-tetrahydroxypregna-1, 4-diene-3, 20-dione, cyclic 16, 17-acetal with acetone, 21-acetate.

The cream contains fluocinonide 0.5 mg./g. in a water-washable aqueous emollient base of stearyl alcohol, cetyl alcohol, mineral oil, propylene glycol, sorbitan monostearate, polysorbate 60, citric acid and purified water.

Actions Topical steroids are primarily effective because of their anti-inflammatory, antipruritic and vasoconstrictive actions.

Indications For relief of the inflammatory manifestations of corticosteroid-responsive dermatoses.

Contraindications Topical steroids are contraindicated in vaccinia and varicella.

Topical steroids are contraindicated in those patients with a history of hypersensitivity to any of the components of the preparation.

Precautions If irritation develops, the cream should be discontinued and appropriate therapy instituted.

In the presence of an infection, the use of an appropriate antifungal or antibacterial agent should be instituted. If a favorable response does not occur promptly, the corticosteroid cream should be discontinued until the infection has been adequately controlled.

If extensive areas are treated, the possibility exists of increased systemic absorption and suitable precautions should be taken.

Although topical steroids have not been reported to have an adverse effect on pregnancy, the safety of their use in pregnant females has not absolutely been established. Therefore, they should not be used extensively on pregnant patients, in large amounts or for prolonged periods of time.

This product is not for ophthalmic use.

Adverse reactions The following local adverse reactions have been reported with topical corticosteroids: burning sensations, itching, irritation, dryness, secondary infection, folliculitis, acneform eruptions, hypopigmentation, striae, skin atrophy.

Dosage and Administration A small amount should be gently massaged into the affected area three or four times daily, as needed.

How Supplied LIDEX®-E (fluocinonide) cream 0.05% — 15g. and 60g. tubes.

SYNTEX

SYNTEX LABORATORIES, INC.
PALO ALTO, CALIFORNIA 94304

Announcement of
FOURTH ANNUAL
DERMATOCRYOSURGICAL SEMINAR

(To be followed by the First Annual American College of Cryosurgery Program, March 13, 1978)

Sponsored by
RUDOLPH ELLENDER MEDICAL FOUNDATION
Co-sponsored by
American Society of Contemporary Medicine and Surgery
A.M.A. and A.A.D.—Approved

This continuing Medical Education Activity meets with criteria for 8 hours credit in Category 1 for the Physician's Recognition Award

Endorsement—American Society for Dermatologic Surgery
Saturday, March 11, 1978 and
Sunday, March 12, 1978

PLACE: Fairmont Hotel—New Orleans

TOPICS: Cryobiology, Cryosurgical Therapy of Benign and Malignant Lesions, Deep Malignancies of the Head and Neck, Cryotherapy of Acne and Instrumentation

DIRECTOR: Ronald R. Lubritz, M.D., Hattiesburg, Mississippi

FACULTY: Andrew A. Gage, M.D., Buffalo, New York—Gloria F. Graham, M.D., Wilson, North Carolina—Douglas R. Torre, M.D., New York, New York—Setrag A. Zacarian, M.D., Springfield, Massachusetts

CLINICAL DEMONSTRATIONS—Cryosurgical Techniques on patients via closed circuit TV

TUITION: $195.00

For further information contact:
A. V. Ravagni, Business Secretary
Roof, Delta Towers, 1732 Canal Street
New Orleans 70112 USA
Ph: (504) 524-9729

LADIES DAY ACTIVITIES:
Usually tours of the French Quarter and Garden District

The Fairmont Hotel offers course participants a pleasant blend of extracurricular activities; ranging from Bailey's Pub (which never closes), to the Blue Room with name entertainment nightly, to the renowned Sazarac Restaurant, to a new addition featuring swimming pool and tennis courts. For Toll Free Reservations, call 800—527-4727 (in Texas Call 800—492-6622).

When Griseofulvin is indicated...

TINEA PEDIS*

TINEA UNGUIUM*



TINEA CRURIS*

TINEA CAPITIS*

*Also *Tinea barbae* and *Tinea corporis* when caused by fungi from genera known to be sensitive to griseofulvin.

Gris-PEG®

(griseofulvin ultramicrosize) Tablets 125 mg

offers effective therapy with 1/2 the dose.†

- Can be taken on an empty stomach
- Absorption nearly complete without fatty meals
- Reduced cost for patients
- Once-a-day or b.i.d. dosage

†250 mg of Gris-PEG® provides plasma levels equivalent to those obtained with 500 mg microsize griseofulvin. This improved absorption permits the oral intake of half as much griseofulvin but there is no evidence, at this time, that this confers any significant clinical difference in regard to safety or efficacy.



Dorsey LABORATORIES
Division of Sandoz, Inc.
LINCOLN, NEBRASKA 68501

Please see other side for full prescribing information.

Gris-PEG®

(griseofulvin ultramicrosize) Tablets 125 mg

The ½ dose griseofulvin.

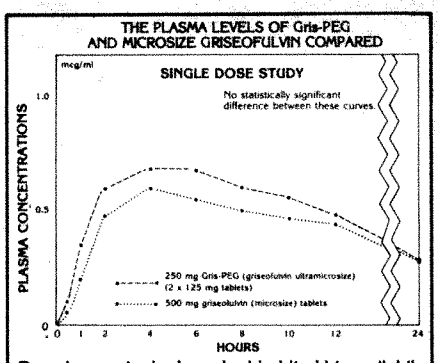

Based on a single dose double-blind bioavailability study conducted in 24 human volunteers comparing the average griseofulvin (microsize) and Gris-PEG plasma levels. There is no significant difference between peak plasma levels, times to peak, and areas under the curve. Gas chromatographic assay.

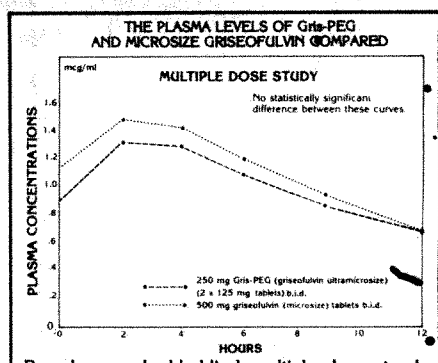

Based on a double-blind multiple dose steady state crossover bioavailability study conducted in 17 human volunteers comparing the average griseofulvin (microsize) and Gris-PEG plasma levels obtained on days 9, 11 and 13. There is no significant difference between times to peak, peak plasma levels, and areas under the curve. Gas chromatographic assay.

DESCRIPTION

Griseofulvin is an antibiotic derived from a species of *Penicillium*.

Gris-PEG is an ultramicrocrystalline solid-state dispersion of griseofulvin in polyethylene glycol 6000.

Gris-PEG Tablets differ from griseofulvin (microsize) tablets USP in that each tablet contains 125 mg of ultramicrosize griseofulvin biologically equivalent to 250 mg of microsize griseofulvin.

ACTION

Microbiology: Griseofulvin is fungistatic with *in vitro* activity against various species of *Microsporum*, *Epidermophyton* and *Trichophyton*. It has no effect on bacteria or other genera of fungi.

Human Pharmacology: The peak plasma level found in fasting adults given 0.25 g of Gris-PEG occurs at about four hours and ranges between 0.37 to 1.6 mcg/ml.

Comparable studies with microsize griseofulvin indicated that the peak plasma level found in fasting adults given 0.5 g occurs at about four hours and ranges between 0.44 to 1.2 mcg/ml.

Thus, the efficiency of gastrointestinal absorption of the ultramicrocrystalline formulation of Gris-PEG is approximately twice that of conventional microsized griseofulvin. This factor permits the oral intake of half as much griseofulvin per tablet but there is no evidence, at this time, that this confers any significant clinical differences in regard to safety and efficacy.

Griseofulvin is deposited in the keratin precursor cells and has a greater affinity for diseased tissue. The drug is tightly bound to the new keratin which becomes highly resistant to fungal invasions.

INDICATIONS

Gris-PEG (griseofulvin ultramicrosize) is indicated for the treatment of the following ringworm infections:

Tinea corporis (ringworm of the body)
Tinea pedis (athlete's foot)
Tinea cruris (ringworm of the thigh)
Tinea barbae (barber's itch)
Tinea capitis (ringworm of the scalp)
Tinea unguium (onychomycosis, ringworm of the nails)

when caused by one or more of the following genera of fungi:

Trichophyton rubrum
Trichophyton tonsurans
Trichophyton mentagrophytes
Trichophyton interdigitalis
Trichophyton verrucosum
Trichophyton megnini
Trichophyton gallinae
Trichophyton crateriform
Trichophyton sulphureum
Trichophyton schoenleini
Microsporum audouini
Microsporum canis
Microsporum gypseum
Epidermophyton floccosum

NOTE: Prior to therapy, the type of fungi responsible for the infection should be identified.

The use of the drug is not justified in minor or trivial infections which will respond to topical agents alone.

Griseofulvin is *NOT* effective in the following:

Bacterial infections
Candidiasis (Moniliasis)
Histoplasmosis
Actinomycosis
Sporotrichosis
Chromoblastomycosis
Coccidioidomycosis
North American Blastomycosis
Cryptococcosis (Torulosis)
Tinea versicolor
Nocardiosis

CONTRAINDICATIONS

This drug is contraindicated in patients with porphyria, hepatocellular failure, and in individuals with a history of sensitivity to griseofulvin.

WARNINGS

Prophylactic Usage: Safety and Efficacy of Griseofulvin for Prophylaxis of Fungal Infections Has Not Been Established.

Animal Toxicology: Chronic feeding of griseofulvin, at levels ranging from 0.5 to 2.5% of the diet, resulted in the development of liver tumors in several strains of mice, particularly in males. Smaller particle sizes result in an enhanced effect. Lower oral dosage levels have not been tested. Subcutaneous administration of relatively small doses of griseofulvin, once a week, during the first three weeks of life has also been reported to induce hepatomata in mice. Although studies in other animal species have not yielded evidence of tumorigenicity, these studies were not of adequate design to form a basis for conclusions in this regard.

In subacute toxicity studies, orally administered griseofulvin produced hepatocellular necrosis in mice, but this has not been seen in other species. Disturbances in porphyrin metabolism have been reported in griseofulvin treated laboratory animals. Griseofulvin has been reported to have a colchicine-like effect on mitosis and cocarcinogenicity with methylcholanthrene in cutaneous tumor induction in laboratory animals.

Usage in Pregnancy: The safety of this drug during pregnancy has not been established.

Animal Reproduction Studies: It has been reported in the literature that griseofulvin was found to be embryotoxic and teratogenic on oral administration to pregnant rats. Pups with abnormalities have been reported in the litters of a few bitches treated with griseofulvin. Additional animal reproduction studies are in progress. Suppression of spermatogenesis has been reported to occur in rats, but investigation in man failed to confirm this.

PRECAUTIONS

Patients on prolonged therapy with any potent medication should be under close observation. Periodic monitoring of organ system function, including renal, hepatic and hematopoietic, should be done.

Since griseofulvin is derived from species of *Penicillium*, the possibility of cross sensitivity with penicillin exists; however, known penicillin-sensitive patients have been treated without difficulty.

Since a photosensitivity reaction is occasionally associated with griseofulvin therapy, patients should be warned to avoid exposure to intense natural or artificial sunlight. Should a photosensitivity reaction occur, lupus erythematosus may be aggravated.

Griseofulvin decreases the activity of warfarin-type anticoagulants so that patients receiving these drugs concomitantly may require dosage adjustment of the anticoagulant during and after griseofulvin therapy.

Barbiturates usually depress griseofulvin activity and concomitant administration may require a dosage adjustment of the antifungal agent.

ADVERSE REACTIONS

When adverse reactions occur, they are most commonly of the hypersensitivity type such as skin rashes, urticaria, and rarely, angioneurotic edema, and may necessitate withdrawal of therapy and appropriate countermeasures. Paresthesias of the hands and feet have been reported rarely after extended therapy. Other side effects reported occasionally are oral thrush, nausea, vomiting, epigastric distress, diarrhea, headache, fatigue, dizziness, insomnia, mental confusion, and impairment of performance of routine activities.

Proteinuria and leukopenia have been reported rarely. Administration of the drug should be discontinued if granulocytopenia occurs.

When rare, serious reactions occur with griseofulvin, they are usually associated with high dosages, long periods of therapy, or both.

DOSAGE AND ADMINISTRATION

Accurate diagnosis of the infecting organism is essential. Identification should be made either by direct microscopic examination of a mounting of infected tissue in a solution of potassium hydroxide or by a culture on an appropriate medium.

Medication must be continued until the infecting organism is completely eradicated as indicated by appropriate clinical or laboratory examination. Representative treatment periods are—*tinea capitis*, 4 to 6 weeks; *tinea corporis*, 2 to 4 weeks; *tinea pedis*, 4 to 8 weeks; *tinea unguium*—depending on rate of growth—fingernails, at least 4 months; toenails, at least 6 months.

General measures in regard to hygiene should be observed to control sources of infection or reinfection. Concomitant use of appropriate topical agents is usually required particularly in treatment of *tinea pedis*. In some forms of athlete's foot, yeasts and bacteria may be involved as well as fungi. Griseofulvin will not eradicate the bacterial or monilial infection.

An oral dose of 250 mg of Gris-PEG (griseofulvin ultramicrosize) is biologically equivalent to 500 mg of griseofulvin (microsized) USP (see ACTION Human Pharmacology).

Adults: A daily dose of 250 mg will give a satisfactory response in most patients with *tinea corporis*, *tinea cruris* and *tinea capitis*. One 125 mg tablet twice per day or two 125 mg tablets once per day is the usual dosage. For those fungal infections more difficult to eradicate such as *tinea pedis* and *tinea unguium*, a divided daily dose of 500 mg is recommended. In all cases, the dosage should be individualized.

Children: Approximately 5 mg per kilogram (2.5 mg per pound) of body weight per day is an effective dose for most children. On this basis the following dosage schedule for children is suggested: Children weighing over 25 kilograms (approximately 50 pounds) 125 mg to 250 mg daily; children weighing 15-25 kilograms (approximately 30 to 50 pounds) 62.5 mg to 125 mg daily; children 2 years of age and younger, dosage has not been established.

Dosage should be individualized, as is done for adults. Clinical experience with griseofulvin in children with *tinea capitis* indicates that a single daily dose is effective. Clinical relapse will occur if the medication is not continued until the infecting organism is eradicated.

HOW SUPPLIED

Gris-PEG (griseofulvin ultramicrosize) Tablets (white) differ from griseofulvin microsized tablets (USP) in that each tablet contains 125 mg of ultramicrosize griseofulvin, biologically equivalent to 250 mg of microsized griseofulvin. Two 125 mg tablets of Gris-PEG are biologically equivalent to 500 mg of microsized griseofulvin. In bottles of 100 and 500 scored, film-coated tablets.

Dorsey
LABORATORIES
Division of Sandoz, Inc. • LINCOLN, NEBRASKA 68501

OY-YB



All soaps for dry skin are not alike... especially Oilatum®

Oilatum Soap is an old dry skin cleanser with an exciting new concept!

While there are several newer cleansers now available, most contain hydrogenated oils, lanolin or mineral oil to provide *emolliency.*

New evidence[1], reported in the *British Journal of Dermatology,* suggests that a formula *rich in linoleic acid* "rapidly restored to normal the abnormally high rates of transepidermal water loss."

And, Oilatum Soap's pure vegetable oil is rich in this same linoleic acid!

Additionally, Oilatum Soap is available in two forms—*scented and unscented.* Most dry skin cleansers don't offer you this choice . . . one which assumes considerable importance when you have to consider the problem of patient sensitivity to perfumes.

STIEFEL
Logical Dermatologicals since 1847

Stiefel Laboratories, Inc.,
Oak Hill, N.Y. 12460
Stiefel Laboratories (Canada) Ltd.,
St. Laurent, Quebec, Canada H4R 1E1

1. Prottey, C.; Hartop, P. J.; Black, J. G. and McCormack, J. I.: The repair of impaired epidermal barrier function in rats by the cutaneous application of linoleic acid. *Brit. J. Derm.*, **94**, 13-21, 1976

Pure and Simple

ACNE-AID®

STIEFEL

Detergent Soap

Contains nothing that will interfere with or aggravate your acne regimen.

No sulfur, no salicylic acid, no medication, no perfume. Acne-Aid® Detergent Soap means gentle cleaning, *pure and simple.*

You can recommend it with even your most aggressive therapeutic measures, such as tretinoin or PanOxyl®... where many medicated soaps may be contraindicated.

STIEFEL
Logical Dermatologicals since 1847

Stiefel Laboratories, Inc.,
Oak Hill, N.Y. 12460
Stiefel Laboratories (Canada) Ltd.,
St. Laurent, Quebec, Canada H4R 1E1

what's best for the care of dry, or premature aging or wrinkled skin... DUE TO EPIDERMAL DEHYDRATION?

SUPPLIED: 2 OZ. TUBES

WRITE FOR SAMPLES

DOAK PHARMACAL CO., INC. WESTBURY, N.Y. 1159

DISTRIBUTOR IN CANADA

Still the only oral antipruritic with q12h convenience

Before prescribing, see complete prescribing information in SK&F literature or *PDR*. The following is a brief summary.

Indications

Based on a review of this drug by the National Academy of Sciences—National Research Council and/or other information, FDA has classified the indications as follows:

Effective: For symptomatic relief of pruritic symptoms in urticaria.

Possibly effective: For relief of pruritic symptoms in neurodermatitis, allergic dermatitis, contact dermatitis, atopic dermatitis, chickenpox, pruritus ani and vulvae.

Final classification of the less-than-effective indications requires further investigation.

Contraindications: Comatose patients; presence of large amounts of C.N.S. depressants; bone marrow depression; idiosyncrasy or hypersensitivity to this drug or other phenothiazines; in newborn or premature children; in nursing mothers; in acutely ill and/or dehydrated children.

Warnings: May impair mental and/or physical ability required for potentially hazardous tasks (driving vehicles, operating machinery); may impair mental alertness in children. Concomitant use with alcohol or other C.N.S. depressants may have additive effect. Warn patients accordingly.

Use with extreme caution in patients with asthmatic attack, narrow-angle glaucoma, prostatic hypertrophy, stenosing peptic ulcer, pyloroduodenal obstruction, bladder neck obstruction, patients receiving MAO inhibitors.

Do not use in women of childbearing potential. There are reported instances of jaundice and prolonged extrapyramidal symptoms in infants whose mothers received phenothiazines during pregnancy.

Use with caution in children, as administration may result in excitation; overdosage may produce hallucinations, convulsions, sudden death.

Elderly patients (60 or older) are more prone to develop the following phenothiazine side effects: hypotension, syncope, toxic confusional states, extrapyramidal symptoms (especially parkinsonism), excessive sedation.

Precautions: May increase, prolong or intensify sedative action of C.N.S. depressants (when administered concomitantly, narcotic or barbiturate dosage should be reduced to ¼ or ½); lead to restlessness and motor hyperactivity in patient with pain being treated with narcotics; block or reverse the pressor effect of epinephrine. Use cautiously in persons (particularly children) with acute or chronic respiratory impairment, as it may suppress cough reflex; in persons with cardiovascular disease, liver function impairment, or history of ulcer disease. The drug's slight antiemetic action may obscure signs of intestinal obstruction, brain tumor, toxic drug overdose.

Adverse Reactions: (Note: May produce adverse reactions attributable to both phenothiazines and antihistamines, although not all the following have

Controls the itching* promptly ...while you treat the cause

Temaril® Spansule®

Each 'Spansule' capsule contains trimeprazine tartrate equivalent to 5 mg. of trimeprazine.

brand of sustained release capsules

been reported with 'Temaril'. There have been occasional reports of sudden death in patients receiving phenothiazine derivatives chronically.) Drowsiness, extrapyramidal reactions (opisthotonos, dystonia, akathisia, dyskinesia, parkinsonism), particularly with high doses, hyperreflexia in newborn (when used during pregnancy), dizziness, headache, lassitude, tinnitus, incoordination, fatigue, blurred vision, euphoria, diplopia, nervousness, insomnia, tremors and grand mal seizures, excitation, catatonic-like states, neuritis and hysteria, oculogyric crises, disturbing dreams/nightmares, pseudoschizophrenia, intensification and prolongation of action of C.N.S. depressants, atropine, heat, organophosphorus insecticides.

Also postural hypotension, reflex tachycardia, bradycardia, faintness, cardiac arrest, ECG changes, anorexia, nausea, vomiting, epigastric distress, diarrhea, constipation, dry mouth, increased appetite and weight gain, urinary frequency and dysuria, urinary retention, early menses, induced lactation, gynecomastia, decreased libido, inhibition of ejaculation, false positive pregnancy tests, thickening of bronchial secretions, tightness of chest, wheezing, nasal stuffiness, urticaria, dermatitis, asthma, laryngeal edema, angioneurotic edema, photosensitivity, lupus erythematosus-like syndrome, anaphylactoid reactions, leukopenia, agranulocytosis, pancytopenia, hemolytic anemia, elevation of plasma cholesterol levels, thrombocytopenic purpura, jaundice, erythema, peripheral edema, stomatitis, high or prolonged glucose tolerance curves, glycosuria, elevated spinal fluid proteins, reversed epinephrine effects.

After prolonged phenothiazine administration at high dosage, the following have occurred: skin pigmentation, ocular changes (the appearance of lenticular and corneal opacities, epithelial keratopathies, pigmentary retinopathy). Vision may be impaired.

Drug Interactions: MAO inhibitors and thiazide diuretics prolong and intensify anticholinergic effects. Combined use of MAO inhibitors and phenothiazines may result in hypertension and extrapyramidal reactions. Phenothiazines potentiate C.N.S. depressant and analgesic effects of narcotics. Phenothiazine effects may be potentiated by oral contraceptives, progesterone, reserpine, nylidrin HCl.

Supplied: 'Spansule' capsules — in bottles of 50. Syrup — Each 5 ml. teaspoonful contains trimeprazine tartrate equivalent to 2.5 mg. of trimeprazine and alcohol 5.7%, in 4 fl. oz. bottles. Tablets — Each tablet contains trimeprazine tartrate equivalent to 2.5 mg. of trimeprazine, in bottles of 100 and 1000. Tablets and 'Spansule' capsules also available in Single Unit Packages (SUP) of 100, intended for institutional use only.

Smith Kline &French Laboratories
Division of SmithKline Corporation
Philadelphia, Pa.

SK&F
a SmithKline company

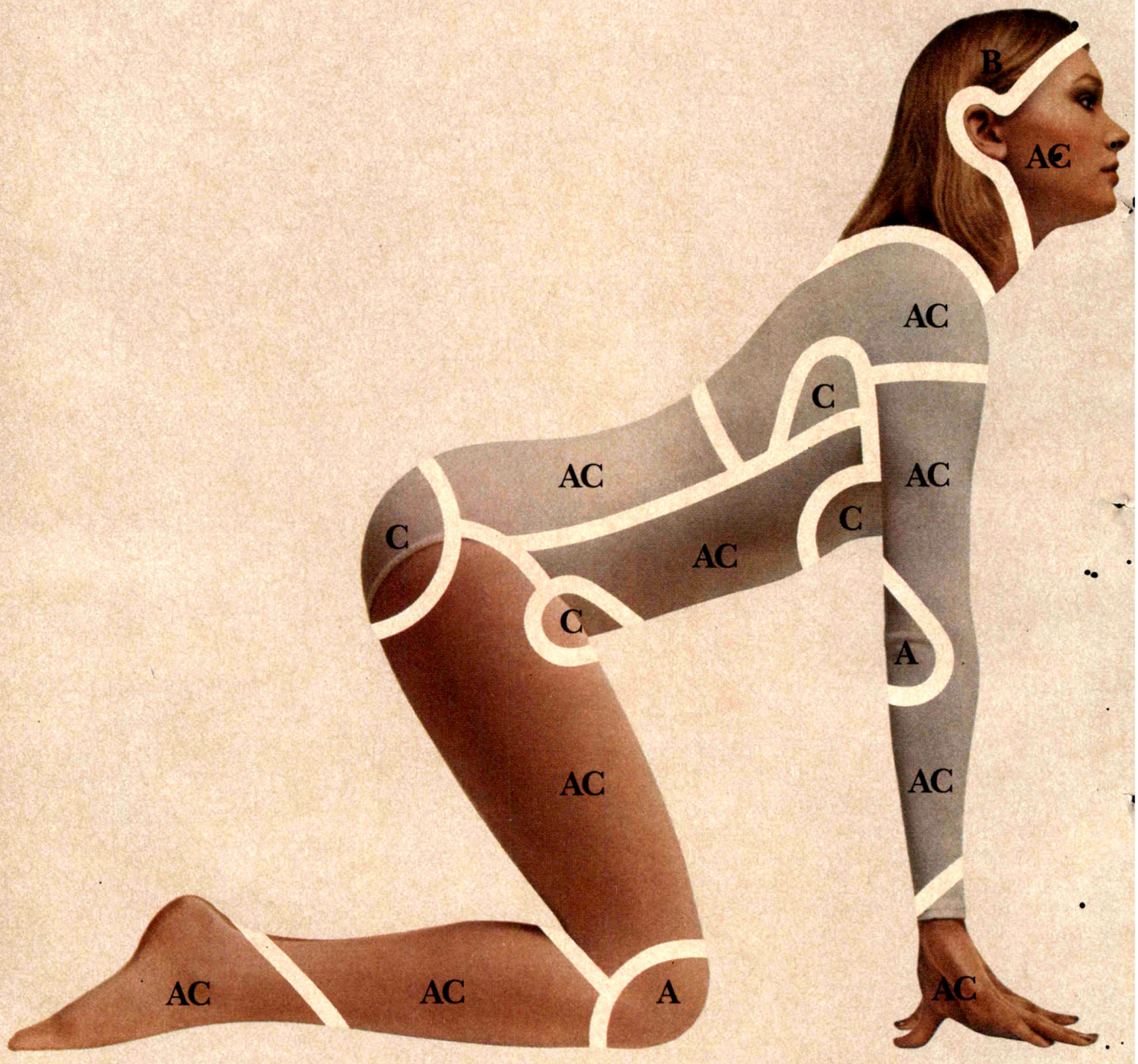

FOR THE

ZONES OF DERMATOSES

For dry areas/lesions

A New Halog® Ointment 0.1%

Halcinonide Ointment 0.1%

For scalp lesions

B New Halog® Solution 0.1%

Halcinonide Solution 0.1%

For moist areas/lesions

Full-strength

C Halog® Cream 0.1%

Halcinonide Cream 0.1%

'Maintenance formula'

Quarter-strength

New Halog® Cream 0.025%

Halcinonide Cream 0.025%

Clinical experience

A total of 984 psoriatic patients in US clinical studies were treated with either the Solution, the Creams, or the Ointment. After 2 weeks' therapy,* 151 (78%) of 194 patients improved with Halog Solution, 407 (92.5%) of 440 patients improved with full-strength (0.1%) Halog Cream, 132 (72%) of 184 patients improved with quarter-strength (0.025%) Halog Cream, and 145 (87%) of 166 patients improved with Halog Ointment.

In general, the preferred topical formulations for lesions in specific areas are: solutions for scalp lesions, creams for moist areas/lesions, and ointments for dry areas/lesions. The studies cited above, however, were not limited to lesions in these specific areas.

*Majority of patients evaluated after 2 weeks' therapy. Data on file at Squibb Institute for Medical Research.

See next page for brief summary.

© 1977 E.R. Squibb & Sons, Inc. 357-508

HALOG®

HALCINONIDE

SQUIBB®

HALOG® (Halcinonide)
Cream/Ointment/Solution
Halog Cream 0.025% (Halcinonide Cream 0.025%) and Halog Cream 0.1% (Halcinonide Cream 0.1%) contain 0.25 mg. and 1 mg. halcinonide per gram, respectively, in a specially formulated cream base. Halog Ointment (Halcinonide Ointment 0.1%) contains 1 mg. halcinonide (0.1%) per gram in Plastibase® (Plasticized Hydrocarbon Gel), a polyethylene and mineral oil gel base. Halog Solution (Halcinonide Solution 0.1%) contains 1 mg. halcinonide (0.1%) per ml.

CONTRAINDICATIONS: Topical steroids are contraindicated in vaccinia, varicella, and in those patients with a history of hypersensitivity to any of the components of the preparations. These preparations are not for ophthalmic use.

PRECAUTIONS: *General*—If local infection exists, suitable concomitant antimicrobial or antifungal therapy should be administered. If a favorable response does not occur promptly, application of the corticosteroid should be discontinued until the infection is adequately controlled. If extensive areas are treated or if the occlusive technique is used, the possibility exists of increased systemic absorption of the corticosteroid and suitable precautions should be taken. If irritation or sensitization develops, the preparation should be discontinued and appropriate therapy instituted. Although topical steroids have not been reported to have an adverse effect on pregnancy, the safety of their use during pregnancy has not been absolutely established; therefore, they should not be used extensively on pregnant patients, in large amounts, or for prolonged periods of time.

Occlusive Dressing Technique—The use of occlusive dressing increases the percutaneous absorption of corticosteroids; their extensive use increases the possibility of systemic effects. For patients with extensive lesions it may be preferable to use a sequential approach, occluding one portion of the body at a time. The patient should be kept under close observation if treated with the occlusive technique over large areas and over a considerable period of time. Occasionally, a patient who has been on prolonged therapy, especially occlusive therapy, may develop symptoms of steroid withdrawal when the medication is stopped. Thermal homeostasis may be impaired if large areas of the body are covered. Use of the occlusive dressing should be discontinued if elevation of the body temperature occurs. Occasionally, a patient may develop a sensitivity reaction to a particular occlusive dressing material or adhesive and a substitute material may be necessary. If infection develops, discontinue the use of the occlusive dressing and institute appropriate antimicrobial therapy.

ADVERSE REACTIONS: The following local adverse reactions have been reported with topical corticosteroids: burning, itching, irritation, striae, skin atrophy, secondary infection, dryness, folliculitis, hypertrichosis, acneform eruptions, and hypopigmentation. The following may occur more frequently with occlusive dressings: maceration of the skin, secondary infection, skin atrophy, striae, and miliaria. Contact sensitivity to a particular dressing material or adhesive may occur occasionally (see PRECAUTIONS).

For full prescribing information, consult package insert.

HOW SUPPLIED: The 0.025% and 0.1% Cream and the 0.1% Ointment are supplied in tubes of 15 g. and 60 g., and in jars of 240 g. (8 oz.). The 0.1% Solution is supplied in plastic squeeze bottles of 20 ml. and 60 ml.

SQUIBB®

Acne on back and shoulders—within easy reach

BUF™ BODY SCRUB

features BUF-PUF® Nonmedicated Cleansing Sponge on a contoured reusable handle

- **thoroughly cleanses the skin and removes excess oil**
- **helps loosen and remove comedones**
- **aids removal of hyperkeratotic skin**

Also helps manage psoriasis

Clinical investigation* revealed BUF-PUF debrided thick psoriatic scales. The adjunctive use of BUF-PUF to mechanically remove scale build-up may help topical anti-psoriatic agents to better penetrate the stratum corneum. No evidence of any Koebner reaction or other adverse effects was observed.

*Shellow, W. V.R., "The Use of a Polyester Fiber Sponge as an Adjunct in the Treatment of Psoriasis." Submitted for publication.

©1977 **Riker Laboratories, Inc.** NORTHRIDGE, CALIFORNIA 91324

"Adolescents especially, may suffer severe loss of self-esteem in our appearance-conscious society as a result of their acne. Some may be more seriously affected emotionally than others and withdraw from normal social interaction."[1]

Help Prevent Both Psychic...And Physical Scarring!

BENZAGEL®

(5% or 10% benzoyl peroxide, 6% polyoxyethylene lauryl ether)

and your counselling are BASIC to Successful Topical Therapy

"Results...Subjective and objective clinical results with this form of therapy were impressive. A rapid improvement could be seen within two weeks...Cysts, pustules and papules decreased in numbers, with a simultaneous reduction of accompanying inflammation. The distinct decline of oily conditions was dramatic."[2]

5 BENZAGEL® ACNE GEL & 10 BENZAGEL® ACNE GEL

Description: 5% or 10% benzoyl peroxide, 6% polyoxyethylene lauryl ether and 40% alcohol in an astringent gel containing colloidal magnesium aluminum silicate, hydroxypropyl methylcellulose, citric acid, fragrance and purified water.

Action: Provides drying, desquamative and antiseptic activity.

Indication: An aid in the treatment of acne.

Dosage and Administration: Wash affected areas prior to application. Apply once or more daily or as directed by physician.

Contraindications: Should not be used by patients having known sensitivity to either benzoyl peroxide or polyoxyethylene lauryl ether.

Precautions: For External Use Only. Not for ophthalmic use. Keep away from eyes and mucosae. Very fair individuals should begin with a single application at bedtime allowing overnight medication. May bleach colored fabrics. Keep this and all other medications out of the reach of children.

Caution: Federal law prohibits dispensing without prescription.

How Supplied: Plastic tubes, 1½ oz. and 3 oz.

REFERENCES:

1. Reisner, R.: The Rational Therapy of Acne, Cutis, Vol. 17, March, 1976, pg. 528.
2. Kuflik, E.: Benzoyl Peroxide Gel in Acne Therapy, Cutis, Vol. 17, January, 1976, pg. 175-177.

Dermik

Dermik Laboratories, Inc.
Fort Washington, Pa. U.S.A. 19034

Ideal for dry skin care.

For dry skin care on a day-to-day basis, consider the soothing, softening, nondetergent cleansing properties of Alpha Keri Soap.

- Excellent cleansing properties eliminate harshness and irritation
- Contains Alpha Keri® therapeutic bath oil to soothe and soften skin
- Rich lather and delicate scent create outstanding patient acceptance

Alpha Keri® soap

The soothing, smoothing detergent-free cleanser

WESTWOOD
PHARMACEUTICALS INC.
Buffalo, New York 14213

In Canada, Belleville, Ontario K8N5E9

©1976, W.P. Inc.

Crude Coal Tar Plus Near Ultraviolet Light Suppresses DNA Synthesis in Epidermis

Richard B. Stoughton, MD; Peter DeQuoy, BA; Joseph F. Walter, MD

• Crude coal tar and a refined product, when they are combined with near ultraviolet (UV) light (UVA, 320-400 nm), depress DNA synthesis in vivo in normal and proliferating skin of the hairless mouse. Near ultraviolet light alone does not interfere with DNA synthesis, but coal tar without UVA does have an inhibitory effect on DNA synthesis of normal skin. This effect of coal tar without UVA is not as great as the effect of the combination of UVA and coal tar.

Between 0.9 and 1.6 joules/sq cm of UVA are required for its biologic effect on DNA synthesis in coal-tar-treated skin.

(*Arch Dermatol* 114:43-45, 1978)

Crude coal tar and its various refined products have been used in dermatology for almost 100 years. In spite of glucocorticoids, antibiotics, antimetabolites, and all the rest of the modern sophisticated pharmacopoeia, these coal-tar products are still widely used by dermatologists, particularly in psoriasis and eczema. We are somewhat embarrassed by the fact that we do not know which of the many agents in coal tar are therapeutic, nor how it works at the cellular level to alter the disease process. Some recent work has indicated that photosensitivity may be related to therapeutic effectiveness[1] and that interstrand photoadducts of DNA may be associated with coal tar plus near ultraviolet (UV) light (UVA) exposure in vitro.[2]

We report a profound depression of DNA synthesis in hairless mouse skin that is exposed to crude coal tar or a refined crude coal-tar preparation plus UVA. Crude coal tar itself has some demonstrable effect on DNA synthesis of normal mouse epidermal cells, and UVA alone was found to have no effect on DNA synthesis. The combination of crude coal tar plus UVA results in a severe suppression of DNA synthesis that is far greater than that seen with tar alone.

MATERIALS AND METHODS

Healthy hairless mice 2- to 4-months-old were used for all experiments. These mice had been inbred for ten years in our institution. The age of the mice was kept within one month for each group of experiments and the animals were randomized within each group.

Light Source

A Blak-Ray B-100A lamp (Ultra-Violet Products, Inc) with maximum output in the 360-nm range was used throughout the calibrated regularly with a Blak-Ray UVA meter (Model J-221). The Blak-Ray B-100A lamp has more than 95% of its output in the 365-nm area. It also has spectral lines at 404, 407, and 334 but they are, in total, less than 2% of the total output. The model J-221 meter is calibrated with 365-nm light but it is capable of registering light in the 300- to 400-nm range. The animals were radiated at a distance of 10 inches, which delivered 6.7 joules/sq cm during a 45-minute exposure.

Tar Preparations

The agents applied were 0.5% crude coal tar (Estar gel) and the gel base for a control, along with crude coal tar (6% in petrolatum), and petrolatum for a control.

PROCEDURES

A thin layer of the tar preparation or control was applied to the upper portion of

Table 1.—Suppression of DNA Synthesis by 6% Crude Coal Tar*

Group/Treatment	Counts/μg of DNA	Standard Deviation
1/6% Crude coal tar + UVA†	0.6	±0.4
2/6% Crude coal tar	3.6	±1.6
3/Control, petrolatum	6.2	±4.2
4/UVA† only	6.1	±4.0

*Normal hairless mouse skin was used. There were ten animals per group. Statistically significant differences were as follows: $P < 0.01$ for group 1 vs 3 and 1 vs 4; $P < 0.05$ for 2 vs 3.
†UVA indicates ultraviolet A.

Accepted for publication Sept 14, 1977.
From the Division of Dermatology, Scripps Clinic and Research Foundation, La Jolla, Calif (Dr Stoughton and Mr DeQuoy), and the University of California School of Medicine, San Diego (Dr Walter).
Reprint requests to 10666 N Torrey Pines Rd, La Jolla, CA 92037 (Dr Stoughton).

the back with a cotton applicator. The mice were then immobilized for two hours in a restraining apparatus. Two hours after application, the treated area was washed gently with nonmedicated soap, rinsed with distilled water, and gently dried. Then the mice were placed 10 inches beneath the Blak-Ray lamp and radiated for 45 minutes. One hour following radiation, 25 μC: of H^3-thymidine containing 6 μg of thymidine was injected intraperitoneally and the animal was killed two hours after UV light exposure.

Preparation of Epidermis for DNA Isolation

The epidermis was separated from the dermis by placing the skin dermis down on a plate that was heated to 55 C for one minute. The epidermis could then easily be scraped away from the dermis with a scalpel blade. The epidermis was wrapped in aluminum foil, frozen in liquid nitrogen, and stored at −20 C until used.

Cell Lysis

Approximately 30 mg of epidermis was taken and the cells were lysed in a tissue grinder in 5 ml of a solution containing 8M urea, 1% sodium dodecyl sulphate, 10^{-3}M ethylenediamine-tetraacetic acid, and 0.24M sodium phosphate buffer, pH 6.8.

Hydroxyapatite Column Chromatography

A 20-cu cm glass syringe was used as a column. Tygon tubing with a clamp was attached to the nozzle. A filter (any colorless cotton material of suitable mesh) was placed at the bottom of the syringe on top of which was layered 1 cm of sand (Mallinckrodt 7062). The syringe was filled with 10 ml of a solution containing 8M urea and 0.24M sodium phosphate buffer (pH 6.8, starting buffer, at room temperature). Crystals of Bio-gel hydroxyapatite (Bio-Rad 13596) were added and allowed to settle to form a bed that was about 1.5 cm deep. The crude epidermal cell lysate was added and washed through the hydroxyapatite with 90 ml of the starting buffer in 15-ml washes. (After this volume, there was no UV-absorbing material present, which indicates that all the RNA has been eluted.) In order to achieve a flow rate of approximately 5 ml/min, the surface of the hydroxyapatite should be gently disturbed with a glass hand pipette on one occasion after the lysate has been added. The urea was removed in 15-ml washes with 90 ml of 0.14M sodium phosphate buffer (pH 6.8). The hydroxyapatite was then ready for the elution of DNA. Six milliliters of 0.48M sodium phosphate buffer (pH 6.8) were added and the first 1-ml sample and subsequent three 1.5-ml samples were collected. Experience shows that the middle two samples contain the DNA. After use, the hydroxyapatite was dissolved away by passing 5N hydrochloric acid through the syringe. The sand can be washed and used again. In addition, the hydroxyapatite may be reused if necessary. Any residual DNA was removed from the column by washing it through with the 0.48M phosphate buffer. This was checked by ascertaining that no UV-light-absorbing material was present by UV spectrophotometry and that no radioactivity was measurable. The 0.48M buffer was washed out with the 0.24M starting buffer and the column was ready for reuse. The sodium phosphate buffers were made up in equal parts of monobasic hydrous and dibasic anhydrous sodium phosphate.

Table 2.—Suppression of DNA Synthesis of Normal Skin by a Refined Coal-Tar Preparation*

Group/Treatment	Counts/μg of DNA	Standard Deviation
1/Estar gel + UVA†	0.6	±0.5
2/Control, gel base	6.8	±3.6
3/UVA† only	6.4	±3.5
4/Estar gel only	3.8	±1.8

*Normal hairless mouse skin was used. There were ten animals per group. Statistically significant differences were as follows: $P < 0.01$ for groups 1 vs 4, 1 vs 2, and 1 vs 3; $P < 0.05$ for 4 vs 2.
†UVA indicates ultraviolet A.

Table 3.—Suppression of DNA Synthesis in Proliferating Epidermis by a Refined Coal-Tar Preparation*

Group/Treatment	Counts/μg of DNA	Standard Deviation
1/Estar gel + UVA†	5.0	±2.5
2/Control, gel base	24.3	±7.3
3/UVA† only	25.4	±18.2
4/Estar gel only	27.0	±8.1

*Hairless mice were pretreated with ultraviolet C to stimulate epidermal DNA synthesis. There were ten animals per group. Statistically significant differences were as follows: $P < 0.01$ for groups 1 vs 2, 1 vs 3, and 1 vs 4.
†UVA indicates ultraviolet A.

Table 4.—Dose Response Showing Relation of Suppression of DNA Synthesis to Amount of UVA in Coal-Tar-Treated Normal Skin*

Time, min and Dosage of UVA Exposure	Counts/μg of DNA	Standard Deviation
48; 6.7 joules/sq cm	0.8	±0.5
24; 3.3 joules/sq cm	2.7	±0.6
12; 1.6 joules/sq cm	1.6	±2.0
6; 0.9 joules/sq cm	7.1	±3.3
3; 0.4 joules/sq cm	6.0	±2.3
0; 0.0 joules/sq cm	4.5	±2.0

*Estar gel was applied before exposure to ultraviolet A. Five hairless mice were used for each time exposure. This dose-response curve indicates a necessary exposure between 0.9 and 1.6 joules/sq cm to depress DNA synthesis in the presence of Estar gel. UVA indicates ultraviolet A.

Estimation of DNA Content

The absorbance of DNA was measured in a spectrophotometer in quartz cuvettes using an UV light source at 260 nm. If the $A_{260}:A_{280}$ is less than 1.8, the sample is contaminated with protein, which indicates inadequate washing of the hydroxyapatite prior to the elution of DNA. This ratio is important for obtaining consistent and accurate results. Assuming that one optical density is approximately equal to 50 μg of DNA per milliliter, the DNA content of the sample may be calculated.

Preparation for Liquid Scintillation Counting

One milliliter of 16M urea (to allow the Insta-gel to gel properly) and 4 ml of Insta-gel were added to a 1-ml sample that was briefly shaken and refrigerated for 30 minutes before counting. Results are expressed as counts per minute per 10 μg of DNA (the minimum yield of DNA was 10 μg/ml).

Mice that were exposed to UVA alone went through the same procedures as above except for the application of the tar preparation.

All experiments were performed with as little lighting as possible from windows and none from overhead lights.

Mice were exposed to UVC to stimulate epidermal proliferation.[3] A germicidal lamp (General Electric G8T5) was used. Maximal output is in the 265-nm range. Maximal stimulation of mitosis and DNA synthesis is 48 to 72 hours after radiation.[4] The tar preparations were applied at 48 hours, left on for two hours, exposed to

UVA, and then injected with H^3-thymidine one hour following radiation. The animals were killed one hour after H^3-thymidine injection and DNA was recovered from the epidermis, as stated above and as outlined in reference 3.

The dose response of DNA synthesis to coal tar plus UVA was determined using the above procedures. Animals were exposed to UVA two hours after the application of Estar gel. One hour following UVA exposure, 25 μCi of H^3-thymidine was injected intraperitoneally and the animal was killed one hour after injection of H^3-thymidine.

RESULTS

There is a profound suppression of DNA synthesis in epidermal cells of the hairless mouse when they are exposed to UVA plus crude coal tar or a refined crude coal-tar product. This suppression of DNA synthesis is induced in normal skin or abnormally proliferating skin, such as that present in UVC-stimulated epidermis. Table 1 shows considerable suppression of DNA synthesis in normal skin that is induced by 6% crude coal-tar ointment plus UVA (group 1). This is a statistically significant difference ($P < 0.01$). (All statistical results reported in this paper are based on Student's t-test.)

Table 2 indicates that a refined crude coal-tar product, Estar gel, plus UVA (group 1) profoundly suppresses DNA synthesis as compared with UVA only (group 3) and the control. This is statistically significant ($P < 0.01$). There is also a statistically significant depression of DNA synthesis by the Estar gel alone (group 4) as compared with UVA only and the control (gel base, group 2). This has a P value of less than 0.05.

Table 3 shows the results that were obtained when Estar gel was applied to the hairless mouse model that was previously stimulated with UVC. This UVC stimulation results in a rather large increase in DNA synthesis in the epidermis.[3] In this stimulated model, it is clear that Estar gel plus UVA (group 1) gave profound suppression of DNA synthesis as compared with the control (gel base, group 2), UVA alone (group 3), or the Estar gel (group 4) alone. The Estar gel alone did not suppress DNA synthesis in this UVC-stimulated model, which is different from the results obtained in normal hairless mouse skin where the Estar gel alone was capable of suppressing DNA synthesis. Table 4 gives a dose-response outline concerning Estar gel plus UVA on normal hairless mouse skin. It can be seen that the critical area for DNA synthesis suppression is between 0.9 and 1.6 joules/cu cm.

COMMENT

These results leave no doubt about the ability of tar plus UVA to severely depress DNA synthesis in epidermal cells when they are applied to the in vivo model. Previous work has shown a good correlation between suppression of DNA synthesis by topical drugs in this model and the ability of the drug to suppress psoriatic plaques.[3]

We intend to explore this area in greater detail to learn about the effects of crude coal tar alone and in conjunction with different types of ultraviolet light (UVC, UVB) on normal and proliferative models of skin in vivo.

We feel that this might be a useful screening technique to sort out the active therapeutic agents in crude coal tar. It might be possible to separate active therapeutic agents in tar from other agents that have been shown to have a carcinogenic effect in animals, and those agents that cause staining, unpleasant aroma, irritation, and folliculitis.

This investigation was supported by Public Health Service research grant AM 11649 from the National Institutes of Health.

References

1. Kaidbey KH, Kligman AM: Clinical and histological study of coal tar phototoxicity in humans. *Arch Dermatol* 113:592-595, 1977.
2. Pathak MA, Biswas RK: Skin photosensitization and DNA cross-linking ability of photochemotherapeutic agents. *J Invest Dermatol* 68:236, 1977.
3. Du Vivier A, Bible R, Mikuriya R, et al: An animal model for screening drugs for antipsoriatic properties using hydroxyapatite to rapidly isolate DNA from the epidermis. *Br J Dermatol* 94:1-6, 1976.
4. Epstein JH, Fukuyama K, Fye K: Effects of ultraviolet radiation on the mitotic cycle and DNA, RNA and protein synthesis in mammalian epidermis in vivo. *Photochem Photobiol* 12:57, 1970.

New Requirement for Authors

Congress recently passed *The Copyright Revision Act of 1976*, effective Jan 1, 1978, which affects the American Medical Association's procedure for reviewing manuscripts submitted for publication.

In view of this law, all transmittal letters accompanying manuscripts submitted for publication should contain the following language: "In consideration of the AMA taking action in reviewing and editing my submission, the author(s) undersigned hereby transfers, assigns, or otherwise conveys all copyright ownership to the AMA in the event that such work is published by the AMA."

Sunburn Protection by Longwave Ultraviolet Radiation-Induced Pigmentation

Kays H. Kaidbey, MD, Albert M. Kligman, MD, PhD

• The role of melanin pigment in sunburn protection was investigated. Deep tans were induced over the backs of volunteers with repeated exposures to longwave ultraviolet radiation (UV-A). Melanogenesis was stimulated without an appreciable thickening of the stratum corneum. Two to three times the minimal erythema dose was required to produce redness in UV-A-tanned skin. Transmission studies through isolated corneum sheets revealed that specimens from tanned skin were about twice as efficient in filtering sunburn rays as stratum corneum from untanned skin. Tanning with UV-A does not provide a substantial resistance against sunburn.

(*Arch Dermatol* 114:46-48, 1978)

The acquisition of a deep suntan is invariably accompanied by resistance to sunburning. Everyone is aware of the risk of becoming badly sunburned on the first summer exposure. After becoming tanned, most individuals can spend a good deal of time in the scorching summer sun with little discomfort. This protection is usually attributed to increased melanogenesis and thickening of the horny layer.[1,2] It is not known whether these two factors completely account for the degree of induced resistance.

All wave lengths of the ultraviolet spectrum and even visible light are capable of stimulating delayed melanogenesis in human skin.[3] However, sunburn rays (290 to 320 nm, UV-B) are the most efficient. These are also the most carcinogenic in laboratory animals[4-6] and are probably chiefly responsible for aging changes in exposed human skin. Accordingly, sunscreens are designed to filter out erythemic radiation. The most widely used ones contain *p*-aminobenzoic acid or its esters. These compounds are highly efficient in absorbing UV-B but transmit longwave ultraviolet radiation (UV-A) freely.

Long-lasting, esthetically pleasing tans can be induced by irradiation with UV-A alone. Histologic study of skin tanned by repeated exposure to UV-A has shown increased melanin pigment in the basal layer as well as an increase in the number of enzymatically active melanocytes. There were, however, insignificant structural changes.[7,8] In contrast to UV-B, the epidermis was not appreciably damaged and hence, acanthosis and thickening of the horny layer did not occur.

A rich tan in wintertime is highly prized by white people in our society. Indeed, many white persons foolishly use various "sunlamps" to acquire a tan, thereby accelerating aging changes. In contrast, fluorescent blacklights emitting UV-A provide a means of self-tanning without the hazard of sunburn. Several questions arise: How much protection is afforded by UV-A-induced tans? How important is melanin in absorbing and scattering erythemic radiation? What is the risk of a serious sunburn if a UV-A-tanned person spends his first winter vacation day in the tropical sun?

We shall show in this work that UV-A tans are not very effective in protecting skin from the harmful effects of erythemic radiation.

MATERIALS AND METHODS

Subjects

The subjects were eight healthy adult white male volunteers between the ages of

Accepted for publication April 27, 1977.

From the Department of Dermatology, University of Pennsylvania, the Duhring Laboratories, Philadelphia.

Reprints not available.

21 and 32 years. All were capable of acquiring deep natural suntans. Informed consent was obtained.

Induction of Tanning

A 15 × 15-cm square was outlined on the untanned back of each subject and exposed to UV-A twice weekly (Mondays and Thursdays) for eight weeks. All exposures were made after the radiation was passed through a 0.15-mm plastic film to eliminate sunburning waves. This film has a sharp cutoff at approximately 315 nm. UV-A was obtained from two sources. Four subjects were exposed to a specifically designed 400-W lamp (Westinghouse) that emitted a continuous spectrum from 300 nm to about 680 nm, with peak energies at 365 and 405 nm (total flux = 22.2 mW/sq cm; UV-A irradiance, 3.2 mW/sq cm; UV-B less than 315 nm = 2 mW/sq cm). The lamp-to-skin distance was 50 cm and each exposure was 15 minutes (total dose, 20 joules/sq cm; UV-A dose, 2.8 joules/sq cm). The other four subjects were exposed to four 20-W blacklight fluorescent tubes housed in a reflecting bank. These emit a continuous spectrum between 310 and 400 nm, with peak output at approximately 360 nm (total flux = 1.6 mW/sq cm; UV-A through plastic film = 1.35 mW/sq cm). Source-to-skin distance was 5 cm and each exposure was 25 minutes (UV-A dose, 2.0 joules/sq cm). The intensities were measured by means of a thermopile.

Protection Against Sunburn

Protection against sunburn was assessed one week after the last UV-A exposure. Sunburning radiation was obtained from a 150-W xenon solar simulator.[9] The minimal erythema dose (MErD) was individually determined on the untanned midback. Each of the subjects tanned by the fluorescent blacklight received 1, 2, and 3 MErDs to the tanned sites as well as to an adjacent untanned area.

Transmission of Erythemic Radiation Through Stratum Corneum Sheets

Cantharidin blisters were raised in tanned and untanned skin to provide sheets of stratum corneum. After cryostat sectioning, the number of cell layers was determined by the alkali swelling technique.[10] In addition, 1.5-cm squares of horny layer were taped along the edges to the untanned back of a light-complected white subject. One tenth milliliter of physiologic saline was pipetted under each square to wet the horny layer, thereby lessening scatter, and also to assure intimate contact. The MErD through each horny layer specimen was determined using a bank of five 20-W fluorescent sunlamp bulbs. The lamp-to-skin distance was 18 cm (intensity, 1.0 mW/sq cm). Graded increments of UV-B were administered until erythema appeared. The ratio of the MErDs through tanned and untanned stratum corneum was designated the transmission index. These measurements were made on specimens from the four subjects tanned with the fluorescent blacklights.

Table 1.—Number of Cell Layers of Back Stratum Corneum

Subject No.	Untanned	UV-A Tanned: 400-W source	UV-A Tanned: Blacklights
1	11	13	...
2	12	13	...
3	13	18	...
4	12	15	...
5	8	...	12
6	9	...	10
7	14	...	12
8	14	...	16

Light Microscopy

Elliptical biopsy specimens were secured from the tanned and untanned skin of the back of each subject. One portion was stained by the DOPA method to visualize melanocytes. The remainder was fixed in 10% formaldehyde solution and sections were stained with PAS, hematoxylin-eosin, and Fontana's ammoniated silver.

RESULTS

Tanning

All eight subjects had deep even pigmentation develop by the end of eight weeks that was comparable to sunlight tans in the estimation of the subjects. The tan produced by the 400-W bulb was slightly more pronounced than that produced with the fluorescent blacklights. Neither erythema nor desquamation was seen at any time.

Protection Against Sunburn

The protective indexes (ratio of MErDs on tanned and untanned skin) were two for two subjects and three for the other two; ie, the tanned areas could tolerate two to three times the amount of sunburning radiation before showing minimal redness. The reactions produced by 5 and 10 MErDs on tanned and untanned skin were indistinguishable in intensity and time course; thus, tanned skin afforded no protection against higher doses of erythemic radiation.

Cell Layers of the Stratum Corneum

There was a minimal increase or no change in the number of horny cell layers from tanned sites as determined by the alkali swelling technique (Table 1).

UV-B Transmission Through Stratum Corneum

In three of the four subjects, 2 MErDs through the untanned horny layer produced no erythema whereas 4 MErDs caused 1+ to 2+ reactions; thus, the threshold erythema dose through the untanned horny layer was approximately 3 MErDs (Table 2). Through tanned skin, 6 MErDs caused redness in every subject, whereas three of four showed no erythema with 4 MErDs. The approximate transmission index was therefore 6/3 or 2. Thus, the deeply tanned horny layer provided about twice as much protection as untanned specimens.

Table 2.—Erythemic Reactions Following UV-B Irradiation Through Sheets of Stratum Corneum*

Subject No.	Untanned MErDs 2	Untanned MErDs 4	Untanned MErDs 6	UV-A Tanned MErDs 2	UV-A Tanned MErDs 4	UV-A Tanned MErDs 6
1	0	1+	2+	0	0	1+
2	1+	1+	2+	0	1+	2+
3	0	2+	3+	0	0	1+
4	0	2+	3+	0	0	1+

*Key to scoring: 1+ indicates threshold erythema; 2+, moderate erythema; and 3+, intense erythema and edema.

LIGHT MICROSCOPY

Except for the considerable increase in pigment granules, specimens from UV-A-tanned sites were similar to the normal skin of the back. Both the epidermis and dermis were unchanged as judged by PAS, elastic, and HE stains. The Fontana stain revealed heavy and uniform deposition of fine melanin granules dispersed throughout the basal and parabasal zones and in the stratum corneum. Supranuclear capping of basal cells was not prominent. DOPA-stained specimens showed an increased number of intensely stained melanocytes. The latter were larger and possessed longer and more prominent dendritic processes.

COMMENT

No one doubts that melanin contributes to protection against sunburn. The high sunburn susceptibility of albinos and patients with vitiligo is

proof enough. Our studies were concerned with the magnitude of the role played by pigmentation. With sunlight or artificial UV-B sources, the horny layer thickens concomitantly and the proportion of protection afforded by melanin alone cannot be assessed. Our experimental tactic was to stimulate melanogenesis without affecting the epidermis or the horny layer. This was adequately accomplished by repeated exposures to high doses of artificially produced UV-A.

Skin tanned in this way possessed relatively little resistance to erythemic radiation. In two of four subjects, 2 MErDs caused redness whereas 3 MErDs broke through in the other two; the true values might actually be lower, taking into consideration the difficulty in visualizing erythema in pigmented skin. Thus, in summertime at our latitude, the UV-A-tanned white individual might on the average be able to stay in midday sunlight about twice as long before becoming red, ie, about 40 minutes.

Years ago Miescher's[11] observations suggested that melanin was of prime importance in photoprotection. He found that a heavily pigmented black subject was not reddened by an equivalent of 60 MErDs from a Bach or a Kromayer lamp. Even at larger doses, only darkening was observed but not erythema. However, these lamps are rich in short ultraviolet radiation (UV-C, 250 to 290 nm) which is not found in sunlight. Also, UV-C is almost totally absorbed by the epidermis and produces biologic responses that are qualitatively different from UV-B. Furthermore, we now know that factors other than the degree of pigmentation may be important in determining sunburn susceptibility. These include the size, distribution, and degree of melanization of melanosomes.[12] Melanin is differently distributed in blacks.[13,14] The melanosomes are large and are dispersed singly, in contrast to the fewer smaller and "packaged" melanosomes in whites. Delayed tanning after exposure to ultraviolet light does not alter the size or the racial packaging of melanosomes, although these become more heavily melanized and dispersed within the dendrites of melanocytes.[15] It has been established that in normal skin of blacks, the density and number of cell layers of the stratum corneum is greater.[16] Therefore, it is not quite appropriate to use the example of the black to illustrate the importance of melanin.

By studying the transmission of UV-B through tanned and untanned stratum corneum, we hoped to gain a rough measure of the capacity of this membrane to act as a filter. The sensor we used was not the spectrophotometer but an untanned white subject. With this method, twice the dose of light was necessary to produce redness through tanned corneum in comparison with untanned specimens. It is interesting that both studies yielded the same result, an approximate doubling of the threshold erythema dose through tanned skin. This modest degree of protection can be attributed to melanin since the horny layer was not appreciably thickened. It should be pointed out that the transmission measurements were through sheets of stratum corneum and not the whole epidermis. The latter would, of course, provide greater protection. Several investigators have measured the transmission of ultraviolet light through the horny layer and intact epidermis using spectrophotometric methods.[17] Unfortunately, the values varied considerably owing mainly to methodologic differences. There is, however, agreement that the epidermis absorbs sunburning rays more efficiently than longer UV-A rays.

Our findings lead to the conclusion that individuals who acquire esthetically satisfying tans by UV-A are at high risk of suffering severe sunburn reactions. The use of sunscreen preparations is therefore necessary when exposure to sunlight is anticipated.

References

1. Blum HF, Kirby-Smith JS: Natural protection against sunburn. *Science* 96:203-204, 1942.
2. Blum HF: The physiological effects of sunlight on man. *Physiol Rev* 25:483-530, 1945.
3. Pathak MA, Riley FC, Fitzpatrick TB: Melanogenesis in human skin following exposure to long ultraviolet and visible light. *J Invest Dermatol* 39:435-438, 1962.
4. Rusch HP, Kline BE, Baumann CA: Carcinogenesis by ultraviolet rays with reference to wavelength and energy. *Arch Pathol* 31:135-146, 1941.
5. Blum HF, Lippincott SW: Carcinogenic effectiveness of ultraviolet radiation of wavelength 2537A. *J Natl Cancer Inst* 3:211-216, 1942.
6. Urbach F, Epstein JH, Forbes PD: Ultraviolet carcinogenesis: Experimental, global and genetic aspects, in Fitzpatrick TB, Pathak MA, Harber LC, et al (eds): *Sunlight and Man*. Tokyo, University of Tokyo Press, 1974, pp 259-283.
7. Langner A, Kligman AM: Tanning without sunburn with aminobenzoic acid-type sunscreen. *Arch Dermatol* 106:338-343, 1972.
8. Kaidbey KH, Kligman AM: Photopigmentation with Trioxsalen. *Arch Dermatol* 109:674-677, 1974.
9. Berger DS: Specification and design of solar ultraviolet simulator. *J Invest Dermatol* 53:192-199, 1969.
10. Christophers E, Kligman AM: Visualization of the cell layers of the stratum corneum. *J Invest Dermatol* 42:407-409, 1964.
11. Miescher G: Untersuchungen über die Bedeutung des Pigments für den U.V. Lichtschutz der Haut. *Strahlentherapie* 45:201-216, 1932.
12. Olson RL, Gaylor J, Everett MA: Skin color, melanin and erythema. *Arch Dermatol* 108:541-544, 1973.
13. Szabo G, Gerald AB, Pathak MA, et al: Racial differences in human pigmentation on the ultrastructural level. *J Cell Biol* 39 (Special issue, pt 2): 132a-133a, 1968.
14. Szabo G, Gerald AB, Pathak MA, et al: Racial differences in the fate of melanosomes in human epidermis. *Nature* 222:1081-1082, 1969.
15. Jimbow K, Pathak MA, Szabo G, et al: Ultrastructural changes in human melanocytes after ultraviolet radiation, in: Fitzpatrick TB, Pathak MA, Harber LC, et al (eds): *Sunlight and Man*. Tokyo, University of Tokyo Press, 1974, pp 195-215.
16. Weigand DA, Haygood C, Gaylor JR: Cell layers and density of Negro and Caucasian stratum corneum. *J Invest Dermatol* 62:563-568, 1974.
17. Everett MA, Yeargers E, Sayre RM, et al: Penetration of epidermis by ultraviolet rays. *Photochem Photobiol* 5:533-542, 1966.

Large Cell Acanthoma

One of the Actinic Keratoses

Homayoon Rahbari, MD, Hermann Pinkus, MD

• Large cell acanthoma (LCA), which was first introduced to the dermatologic literature in 1970 and has had no major presentation since then, is not an uncommon lesion. The lesion is a circumscribed hyperkeratotic epidermal growth with the outstanding pathologic feature being large cells. Clinical diagnoses have included several benign and malignant skin conditions. Large cell acanthoma may be related to lichen planus-like keratosis and lentigo senilis. We diagnosed 38 instances of LCA among 34,000 specimens received in our dermatopathology laboratory.

(*Arch Dermatol* 114:49-52, 1978)

Actinic keratosis has been used as a shorthand title for solar keratosis on the sun-damaged skin of the elderly since it was introduced by committee action[1] as an etiologic designation to replace senile keratosis. It is now often used as a clinical and histologic diagnosis for the particular precancerous lesion first identified by Freudenthal[2] as keratoma senile and introduced to American literature by Pinkus[2] as keratosis senilis a year before the term "actinic

Accepted for publication Feb 18, 1977.

From the Department of Dermatology and Syphilology, Wayne State University School of Medicine and Detroit General Hospital.

Reprint requests to 415 S Monroe St, PO Box 360, Monroe, MI 48161 (Dr Rahbari).

Table 1.—The Group of Actinic Keratoses
Sunlight-induced keratoses seen on the sun-damaged skin, with the potential toward invasion and malignancy
Keratosis senilis (Freudenthal-Pinkus)
Bowenoid actinic keratosis
Acantholytic (Darier-like) actinic keratosis
Keratoses on the exposed skin consisting of presumably sunlight-induced clones of abnormal cells without tendency to malignancy
Disseminated superficial actinic porokeratosis
Lichen planus-like keratosis
Lentigo senilis
LCA

Fig 1.—Left, Poorly demarcated epithelial growth on an erythematous base, on the forehead. Right, Higher magnification of Fig 1, left.

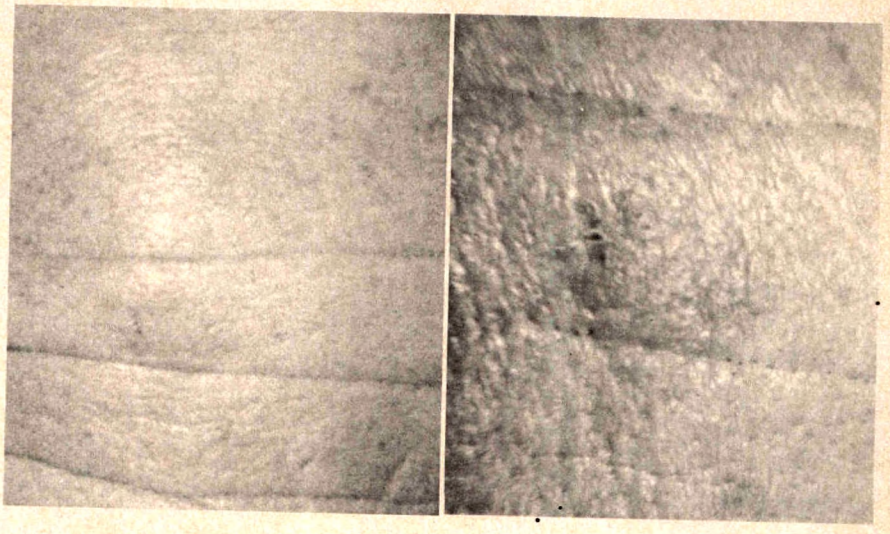



Fig 2.—Top left, Sharp line of demarcation (arrow) between the large cells and the uninvolved epidermis (hematoxylin-eosin, ×135). Top center, Lateral end of LCA showing the demarcation line (arrow) between the large cells and the normal epidermis (hematoxylin-eosin, ×135). Top right, Higher magnification of Fig 2, top center (hematoxylin-eosin, ×225). Bottom left, Lateral end of LCA showing the demarcation line (arrow) between the large cells and the normal epidermis (hematoxylin-eosin, ×135). Bottom center, Higher magnification of Fig 2, bottom left (hematoxylin-eosin, ×225). Bottom right, Higher magnification of Fig 2, bottom left. Arrow shows the separation line of LCA and the normal sweat duct cells (hematoxylin-eosin, ×225).

Fig 3.—Acanthotic and papillomatous involved epidermis. Note the wavy and orthokeratotic keratin layer (hematoxylin-eosin, ×135).

keratosis" was suggested on clinical-etiologic grounds. We believe actinic keratosis should be considered a group heading under which keratosis senilis of Freudenthal,[2] together with its histologic variants, could be listed (Table 1). As an etiologically based term, however, "actinic keratosis" encompasses other keratotic lesions recognized since 1959 and considered to be sunlight-induced clonal growths of abnormal epidermal cells. In this subdivision one can list disseminated superficial actinic porokeratosis, lichen planus-like keratosis, lentigo senilis, and an entity that we are describing here under the term large cell acanthoma (LCA).

In discussion of epidermal mosaicism in benign and precancerous neoplasia, one of us (H.P.) introduced the concept of LCA in 1970.[3] Since then, besides the work of Fand and Pinkus[4] and the short discussion of the subject by Pinkus and Mehregan,[5(p 494)] no further presentations have been put forth to make the clinician and the dermatopathologist aware of this lesion. Clinically, the lesion is lightly pigmented and slightly hyperkeratotic. It is a somewhat elevated and rather nondescript plaque usually over an erythematous base and measures about 5 to 10 mm in diameter (Fig 1). The growth has ordinarily been present for some time before the patient sees a need to bring it to the attention of a physician. The clinical picture of the lesion is rather confusing to the clinician as it does not correspond fully to the well-known entities.

We have diagnosed 38 instances of LCA among 34,000 specimens received in our dermatopathology laboratory, attesting to its relative prevalence. The specimens were all from white patients, ranging in age from 28 to 89 years (mean, 59.94 years). Large cell acanthoma is encountered more frequently in women (26 women vs 12 men). Its site of predilection is sun-exposed areas, especially the face (17 instances), with other sites as follows: upper extremities, 12; lower extremi-

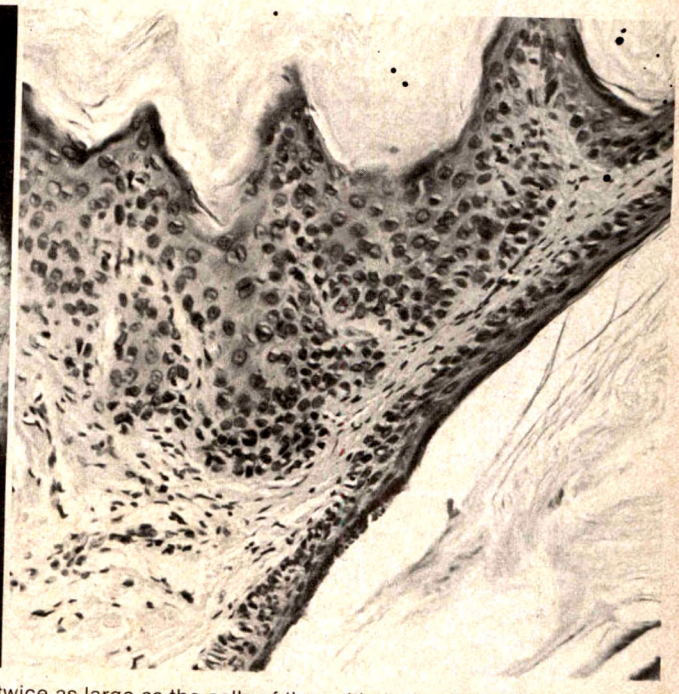

Fig 4.—Left, Large cells of the involved epidermis, which are about twice as large as the cells of the epithelial wall of the dilated follicle (hematoxylin-eosin, ×135). Right, Higher magnification of Fig 4, left. Note the cell sizes of the follicular wall and LCA.

ties, 4; back, 3; anterior part of the trunk, 2. The clinical diagnosis mentioned most frequently is seborrheic verruca (18 instances). Actinic keratosis is considered next in the order of frequency (11), and the basal cell epithelioma (5), lentigo (4), and one each for the following diagnoses: lichen planus, psoriasis, scar, squamous cell carcinoma, carcinoma, verruca vulgaris, Bowen's dermatosis, Dubreuilh's melanosis, intradermal nevus, macular atrophy, melanoma, and granuloma faciale.

MATERIALS AND METHODS

Following routine processing of the tissue specimens,[5(pp 62-66)] 10-μ sections were stained with hematoxylin-eosin, acid orcein and Giemsa, and in selected cases with Alcian blue-PAS-positive combination, Van Gieson's, Gomori's reticulum, and Feulgen stains.

Histopathology

The sections show a circumscribed lesion with a one-cell demarcation line between the large cells and the uninvolved epidermis (Fig 2). The epidermis is slightly to moderately acanthotic and in some sections somewhat papillomatous. The lesion consists of definitely large cells that have proportionally large nuclei (Fig 3). The overlying keratin is wavy and orthokeratotic. These cells appear almost twice as large as the cells of the uninvolved epidermis or the normal adnexal cells (Fig 4). The granular cell layer is especially prominent as to the size of the cells (Fig 5). The basal cell layer often is hyperpigmented but shows no increase in the

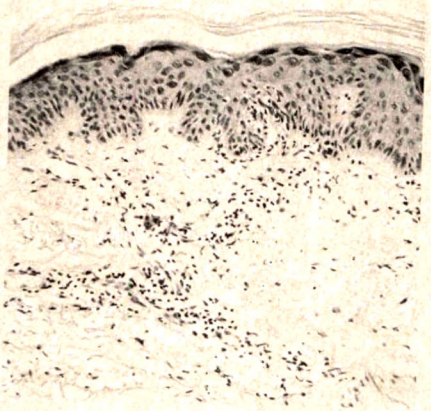

Fig 5.—Large cells of the granular cell layer are prominent (hematoxylin-eosin, ×90).

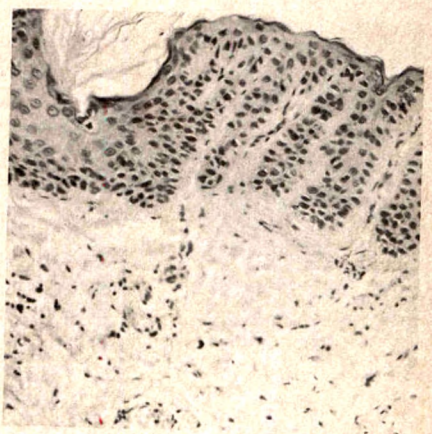

Fig 6.—The downward budding of the large celled rete ridges (hematoxylin-eosin, ×135).

Fig 7.—Intact PAS-positive basement membrane (PAS-Alcian blue, ×135).

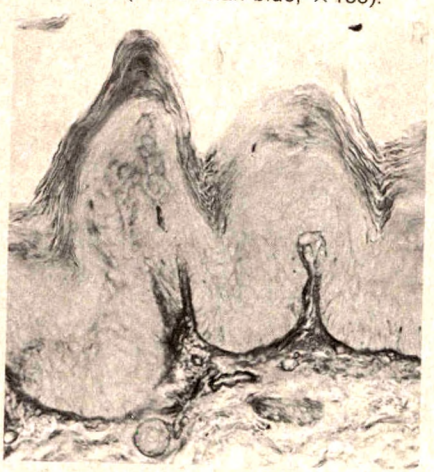

Fig 8.—Erosion of the lower involved epidermis (hematoxylin-eosin, ×135).

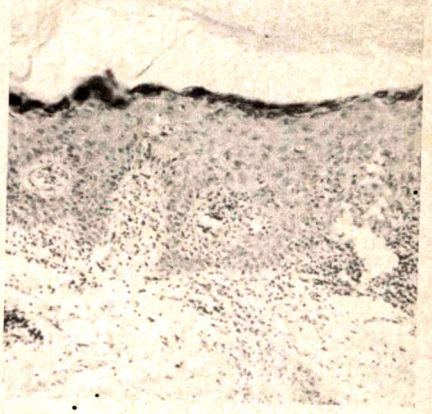

number of junctional melanocytes. Melanin granules form a cap over the basal cell nuclei. Mitotic activity is not a prominent feature but is present on occasions, and very rarely there are individually keratinized cells. Glycogen granules are seen in the upper half of the papillomatous Malpighian stratum. In several sections the rete ridges show downward budding or elongation (Fig 6). The PAS-positive basement membrane is intact and there is no indication of invasion (Fig 7). The dermis shows slightly Alcian blue-positive deposits in the zone of actinic elastosis. There are telangiectasia and foci of chronic inflammation in the upper corium reminiscent of lichen planus-like keratosis in some sections (Fig 8).

COMMENT

To our knowledge, LCA had gone unrecognized prior to Pinkus' discussion of this entity.[3] The lesion occurs over the sun-exposed parts of the skin of middle-aged or elderly individuals. It is clinically and histopathologically characterized by a circumscribed area that is evidently different from the surrounding skin. There are several features that differentiate LCA from actinic keratosis of the keratosis senilis (Freudenthal) type.[2] Large cell acanthoma shows hypergranulosis and wavy orthokeratotic hyperkeratosis, in contrast to the usual loss of granular layer and compact parakeratotic hyperkeratosis seen in keratosis senilis. Large cell acanthoma is frequently hyperpigmented and does not show downward budding of dysplastic cells or areas of acantholysis. Actinic keratosis of keratosis senilis type has the potentiality of progression into squamous cell carcinoma. We have not seen any suggestions of malignant transformation in our cases of LCA. Athough the large cells of LCA are not completely uniform, they definitely do not manifest the irregularity of size and shape that the cells of Bowen's dermatosis show. The orthokeratotic keratinous layer is another differentiating point between LCA and Bowen's disease. Again, the lack of progression into an invasive malignant neoplasm separates LCA from Bowen's dermatosis. The dermis usually reacts to dysplastic cells of Bowen's dermatosis with accumulation of inflammatory infiltrate, which is not seen with LCA in the absence of traumatization.

The large cells of LCA could reach their attained size either by hypertrophy or through hyperplasia. If these cells had hypertrophied, the nuclei might have reached the present size but in the process their chromatin would have "diluted out" and they would stain very faintly. As the cell size, including that of its nucleus, is almost twice as large as that of the uninvolved epidermal cell, the nucleus must have twice as much chromatin to continue to stain as deeply as the normal cells. Therefore, they are hyperplastic cells.

To prove the above contention one would have to count the chromosomes of the LCA cells. The clinician has to be aware of the possibility of LCA and provide the cytologist with appropriate material for chromosome count before clinically destroying the lesion in his quest to treat the patient. We have not been able to arrange for this sequence of events up to this time. In one case,[3] mitotic activity was increased experimentally by tape stripping, but we were not able to count the chromosomes. In another approach, Fand and Pinkus,[4] after staining thin LCA skin sections with Feulgen stain, studied the depth of color absorbed by the chromatin mass with the help of a microdensitometer. This method permits relative estimation of the amount of DNA present in normal and abnormal nuclei in the same section. It was concluded that LCA cells were a population of hyperchromatic or polyploid cells, although polyploidy was an unknown phenomenon in benign human epidermis prior to their work.

The relationship of lentigo senilis and lichen planus-like keratosis has been discussed by Mehregan.[6] The hyperpigmentation and acanthosis in LCA are reminiscent of seborrheic verruca and lentigo senilis. On the other hand, presence of chronic inflammation with occasional impingement of the rete ridges in LCA is similar to lichen planus-like keratosis. Could it be that LCA, lichen planus-like keratosis, and lentigo senilis are related to one another as the angles of a triangle? Lentigo senilis could eventuate at times into lichen planus-like keratosis, and on occasions into LCA? All three are lesions of exposed skin of the elderly and have many attributes in common. Or is it that these lesions are not related at all and their apparent similarities are due to the limited repertoire of the skin in its reaction to exogenous forces?

Considering all the attributes of the LCA, we feel it can be best considered a member of the group of actinic keratoses in the wider sense (Table 1). Although other noxious agents could be the causative elements for appearance of a hyperchromatic and large clone of cells in the epidermis, the logical agent to effect the change on sun-exposed areas would be the sun's rays.

There are two reasons for calling attention to LCA: (1) its clinical appearance misleads the observer to confuse it with various benign and malignant skin lesions, and (2) the histologic picture is pathognomonic and uniquely characterized by the presence of an island of benign hyperchromatic cells of overly large size.

This investigation was supported in part by Detroit General Hospital Research Corp.

Michael Mahon, DO, provided us with clinical photos of LCA.

References

1. Becker SW: Dermatological nomenclature. *Arch Dermatol* 80:778-784, 1959.

2. Pinkus H: Keratosis senilis. *Am J Clin Pathol* 29:193-207, 1958.

3. Pinkus H: Epidermal mosaic in benign and precancerous neoplasia (with special reference to large cell acanthoma). *Acta Dermatol* 64,65:53-59, 1969-70.

4. Fand SB, Pinkus H: Polyploidy in benign epidermal neoplasia, abstracted. *J Cell Biol* 47:59a, 1970.

5. Pinkus H, Mehregan AH: *A Guide to Dermatohistopathology*, ed 2. New York, Appleton-Century-Crofts Inc, 1976.

6. Mehregan AH: Lentigo senilis and its evolutions. *J Invest Dermatol* 65:429-433, 1975.

Thyroid Neoplasms After Radiation Therapy for Adolescent Acne Vulgaris

Edward Paloyan, MD, A. M. Lawrence, MD, PhD

• There is a potential hazard of thyroid cancer after exposure to external irradiation for the treatment of adolescent acne vulgaris. We noted a 60% incidence of thyroid carcinoma among 20 patients with such a history, who were operated on for thyroid nodules during a five-year period. Eighty-three percent of the patients with carcinoma had either a follicular or a mixed papillary-follicular carcinoma; 17% had a papillary carcinoma; 33% had regional node metastases; none had evidence of distant metastases. The interval between radiation exposure and thyroidectomy ranged from nine to 41 years. This association of thyroid neoplasms and a prior history of radiation for acne vulgaris may be coincidental and therefore remains to be proved by retrospective surveys of large numbers of treated patients with appropriate controls.

(*Arch Dermatol* 114:53-55, 1978)

X-rays have been administered in the treatment of severe cases of acne vulgaris for at least 80 years. The first communications on the subject were by Gautier and Pakhetonow, both of Paris, who read their reports before the 12th International Congress of Medicine, which was held at Moscow in 1897.[1] The first reports of such treatment in the United States appeared in 1901.[2]

Radiation therapy for acne is usually administered within a range of 50 to 80 kV and has been regarded as an effective, safe, and justifiable treatment in selected cases of benign dermatoses, such as in potentially disfiguring and emotionally disabling severe cases of acne vulgaris among adolescents and young adults, provided they are administered in selected patients according to recognized standards and by fully qualified dermatologists.[3]

Unfortunately, many patients were treated in "institutes" and not under the supervision of qualified dermatologists.[3] As a result, there is no information in many instances regarding the administered dose, the energy and penetrance of the x-rays, the calibration of the equipment, and the shielding of other parts of the body.

Accepted for publication July 6, 1977.

From the Departments of Surgery (Dr Paloyan) and Medicine (Dr Lawrence), Loyola University Stritch School of Medicine and Veterans Administration Hospital, Hines, Ill.

Reprint requests to PO Box 5, Hines, IL 60141 (Dr Paloyan).

The association between thyroid neoplasia and a prior history of exposure to head and neck irradiation for benign conditions was first suggested by Duffy and Fitzgerald[4] and well documented by subsequent reports.

Albright and Allday, in 1967, called attention to the association of thyroid carcinoma and radiation therapy for adolescent acne vulgaris in five patients.[5] They found that the interval between irradiation and diagnosis ranged between five and 40 years.

As a general statement in regard to radiation-associated thyroid neoplasms, the younger the patient at the time of exposure, the greater the susceptibility and the shorter the period of latency before the overt development of thyroid disease.[6] Whereas infants irradiated during the first few weeks of life may develop thyroid tumors within 10 to 15 years,[7] the interval extends to approximately 25 years in children irradiated for tonsillitis[8] and may be as long as 35 to 40 years in patients treated for acne vulgaris in their late teens or young adulthood.[5]

The purpose of this report is to describe the possible hazard of thyroid cancer after radiation therapy for acne vulgaris and to describe the findings in 12 new cases.

CLINICAL POPULATION AND METHODS

Among 224 patients referred for thyroidectomy for white on scan solitary nodules from 1971 to 1976, 20 were found to

have a history of radiation exposure to the head and neck for the treatment of acne vulgaris. Fifteen of these were women and five were men. The age at which radiation was administered ranged between 12 and 34 years. This range was 12 to 32 years for the 12 patients who were found to harbor a carcinoma (Table 1). Treatment records could be obtained in only three patients: the total administered dose was 680, 900, and 950 rads in air, respectively.

The first of these three patients was a 36-year-old woman who had a 3-cm nodule at the inferior pole of the right lobe. Beginning at the age of 14 she was treated for acne with diet, topical therapy, and vitamin A, in addition to "superficial x-ray therapy for a total dose of 680 roentgens over a period of two years." The factors for the radiation were 80 kV and 5 mamp with a half-value of 0.3 mm of aluminum. There was no mention of shielding in the letter forwarded by the physician who had treated this patient. The patient did not recall any shielding, except for the eyes. The tumor proved to be a mixed papillary-follicular carcinoma with metastases to two lymph nodes immediately adjacent to the neoplasm. A total thyroidectomy, with autotransplantation of three parathyroid glands, was performed.

The second patient was a 47-year-old woman who had noted a nodule in the right lobe of the thyroid 1½ years previously; it had grown to the size of 4 × 5 cm before she sought medical attention. This patient was treated for six months at the age of 20 years for extensive papular acne of the cheeks. She received 900 roentgens through three ports: left cheek, right cheek, and center of the face. Radiation was unfiltered; the intrinsic filtration of the machine was 1 mm of aluminum. According to the physician who administered this treatment, 75% of the radiation was absorbed in the first 0.3 mm of the skin. The patient was covered with lead shielding over the head, the thoracic region, and pelvis. The nodule proved to be a follicular carcinoma, with metastases in three of six lymph nodes immediately adjacent to the right lobe of the thyroid. A total thyroidectomy was performed with autotransplantation of two parathyroid glands.

The third patient was a 33-year-old woman who was referred for the operative treatment of Graves' disease with a concomitant 4- × 3-cm nodule occupying most of the left lobe of the gland. This nodule contained both cold and hot areas in a "patchy" distribution on a scan done prior to institution of therapy with thyroid blockers and, subsequently, thyroxine. At the age of 14 she was treated for four months with a total of 950 roentgens of unfiltered x-ray at 66 kV. The treatment was given in divided doses of 50 or 75 roentgens and the only areas treated were the forehead and the cheeks. A lead shield, with a cutout for the cheeks or the forehead, was used to avoid exposure to the nose, eyes, and lips. The nodule proved to be a follicular adenoma. The remainder of the thyroid showed the classic changes of treated Graves' disease. Eight lymph nodes showed only hyperplastic changes. All four parathyroid glands were preserved in situ.

In spite of repeated inquiries, treatment records could not be obtained for the other 17 patients. Two of the 17 were treated in Chicago-area hospitals; 5 were treated in the office of two well-known, highly reputed Chicago dermatologists who are deceased, and the remaining 12 received their treatment in the offices of other dermatologists in Chicago and other parts of this country. Among the remaining 204 patients in this series, 44 (22%) had carcinomas.

RESULTS

The interval between exposure to radiation and thyroidectomy ranged between 7 and 41 years for the entire population; it extended from 9 to 41 years in the 12 patients with carcinoma (Table 1).

Twelve of the 20 patients (60%) had a carcinoma (Table 2); among the remaining eight the principal pathologic changes consisted of a follicular adenoma in 3 patients, colloid nodules in another 3, and chronic Hashimoto's thyroiditis in the last 2.

Two of the patients with carcinoma were men (40% of the men in the series) and ten were women (67%). The carcinoma was of the papillary variety in 2 patients, follicular in 2, and of the mixed papillary-follicular pattern in 8; therefore, ten of the 12 patients (83%) had a follicular component in their tumor. The carcinoma occurred in both thyroid lobes in six of the 12 patients (50%). Four patients (33%) had regional lymph node metastases. One required a modified radical neck resection: 21 of 27 nodes resected contained metastases. None of the patients had evidence of distant metastases.

COMMENT

The association of thyroid neoplasia and a previous history of radiation exposure for the treatment of acne vulgaris may be purely coincidental, especially in patients treated by qualified physicians who utilize appropriate techniques and shielding. Furthermore, these patients may have been exposed to other sources of ionizing irradiation for the treatment of thymic enlargement in infancy or tonsillitis in childhood, or for diagnostic studies such as multiple dental x-rays, cardiopulmonary fluoroscopy, and multiple chest x-rays. Even though such a history could not be elicited in spite of careful and repeated questioning of the patients, and in most instances their parents, a negative history is often unreliable and parents will occasionally deny such a history to assuage perceived guilt feelings.

Nevertheless, the 60% incidence of carcinoma in this group of patients is

Table 1.—Interval Between X-ray Exposure and Thyroidectomy in 12 Patients With Carcinoma

Age at Thyroidectomy, yr	Sex	Age X-ray Exposure, yr	Interval, yr
66	F	25	41
54	F	32	22
51	F	20	31
47	F	20	27
46	F	16	30
44	F	13	31
41	F	15	26
40	F	19	21
36	F	14	22
35	F	16	19
33	M	12	21
26	M	17	9

Table 2.—Incidence of Carcinoma in 20 Patients With Thyroid Nodules*

Sex	No. of Patients	Patients With Carcinoma	Incidence, %
F	15	10	67
M	5	2	40
Total	20	12	60

*All patients had a history of radiation exposure for treatment of acne vulgaris.

commensurate with the incidence reported in patients who received radiation for the treatment of tonsillitis. The incidence of follicular carcinoma is also similar.[8] There is reason to assume that when soft x-rays are administered for the treatment of acne with appropriate shielding by fully qualified dermatologists, exposure to the thyroid gland is minimal or negligible. However so many patients were treated in "institutes"[3] without the direct supervision of qualified dermatologists and possibly with defective or poorly calibrated equipment that thyroidectomy should be considered in patients with a history of radiation exposure for the treatment of acne vulgaris when thyroid nodules appear. The treatment of such patients should be guided by the principles developed for the thymic and tonsillar irradiation groups.[4,6-9]

The prognosis of thyroid carcinoma, especially in the papillary variety, is excellent, even in the presence of regional metastases,[10,11] with one exception: follicular cancers after the age of 50 have a less favorable prognosis, particularly in men, in whom the ten-year mortality has been reported near 80% in two large series.[10,11] There is no reason to believe that radiation-associated thyroid cancers have pathologic and biologic characteristics different from the spontaneous variety, even though two thirds of them (as in this series) may be follicular or may have a follicular component.[8,12]

The number of adolescents who have been exposed to radiation for the treatment of acne is substantial and may be more than a million according to unofficial estimates. In view of the established association of thyroid neoplasms and a history of prior head and neck irradiation in other settings, the observations reported here point to the need for controlled retrospective studies on a large scale in irradiated and nonirradiated acne patients to clarify the potential carcinogenicity of proper radiation therapy techniques for acne.

This investigation was supported in part by the John A. Hartford Foundation, Inc, and the Illinois Division of the American Cancer Society.

References

1. Kline PR, Gahan E: Unilateral roentgen irradiation in the treatment of acne vulgaris. *Arch Dermatol Syphilol* 46:207-208, 1942.
2. Pusey WA: Acne and sycosis treated by exposures to roentgen rays. *Cutan Genito-Urin Dis* 20:204-210, 1902.
3. Sulzberger MB, Baer RL, Borota A: Do roentgen-ray treatments as given by skin specialists produce cancers or other sequelae? *Arch Dermatol Syphilol* 65:639-655, 1952.
4. Duffy BJ Jr, Fitzgerald PJ: Cancer of the thyroid in children: A report of 28 cases. *J Clin Endocrinol Metab* 10:1296-1308, 1950.
5. Albright EC, Allday RW: Thyroid carcinoma after radiation therapy for adolescent acne vulgaris. *JAMA* 199:128-129, 1967.
6. Winship T, Rosvoll RV: Childhood thyroid carcinoma. *Cancer* 14:734-743, 1961.
7. Clark DE: Association of irradiation with cancer of the thyroid in children and adolescents. *JAMA* 159:1007-1009, 1955.
8. Paloyan E, Lawrence AM, Brooks MH, et al: Total thyroidectomy and parathyroid autotransplantation for radiation-associated thyroid cancer. *Surgery* 80:70-76, 1976.
9. Guansing AR, Engbring N, Cerletty J, et al: Thyroid neoplasia: A delayed complication of low-dose head and neck irradiation. *Excerpta Medica International* 378:561-564, 1975.
10. Eisenberg H: Survival experience of cancer of the thyroid by various treatments as experienced in a total population group, in Hedinger CE (ed): *Thyroid Cancer*. Heidelberg, Germany, Springer-Verlag, 1975, pp 305-309.
11. Franssila KO: Prognosis in thyroid carcinoma. *Cancer* 36:1138-1146, 1975.
12. Becker FO, Economou SG, Southwick HW, et al: Adult thyroid cancer after head and neck irradiation in infancy and childhood. *Ann Intern Med* 83:347-351, 1975.

CORRECTION

Acknowledgment Omission.—In the article titled "Induction of Drug Photosensitization in Man After Parenteral Exposure to Hematoporphyrin," published in the October ARCHIVES (113:1392-1397, 1977), acknowledgment of research grant No. AM 18549 from the National Institutes of Health was omitted.

The Role of Microorganisms in Diaper Dermatitis

James J. Leyden, MD, Albert M. Kligman, MD, PhD

• A quantitative microbiological survey of multiple sites in the diaper area in 40 normal infants and 100 infants with various forms of diaper dermatitis showed (1) no significant differences between normal infants and those with the common chafing form of diaper dermatitis except for a low number of *Staphylococcus aureus* organisms in 50% of those with chafing dermatitis compared to no *S aureus* in normals; (2) *S aureus* occurred in high numbers in every case of atopic dermatitis and was frequently found at much lower levels in psoriasis, seborrheic dermatitis, and chafing dermatitis; (3) *Candida albicans* occurred in 80% of cases clinically diagnosed as moniliasis localized to the diaper area and in 33% of those suspected of *Candida* infection with dissemination beyond the diaper area, while *C albicans* was found in only five of 145 culture sites in 40 normal infants.

(*Arch Dermatol* 114:56-59, 1978)

The belief that microorganisms play a central role in the pathogenesis of diaper dermatitis is ancient. The history of microbial etiology starts with the last century, when clinicians had to contend with the possibility of congenital syphilis. In fact, it was not until the turn of the century that Jacquet[1] described a nonsyphilitic form of diaper dermatitis with convincing details. In the early 1900s, dermatologists came to view urinary ammonia as an important etiological factor.[2] When Cooke[3] demonstrated in 1921 that an aerobic Gram-positive rod, *Brevibacterium ammonia genes*, was capable of liberating ammonia from urea, this organism came to be viewed as the etiologic agent. Indeed, in pediatric circles diaper dermatoses are virtually synonymous with "ammoniacal dermatitis."

The more recent literature has centered on *Candida albicans*. There is no question that this organism can frequently be recovered. Dixon et al[4] found an overall prevalence of 41% in 117 patients; Montes and colleagues'[5] recovery rate was 77%. In two series dealing with severe diaper eruptions followed by a generalized "psoriasiform id," Jefferson[6] demonstrated *C albicans* in 20 of 32 patients; Fergusson et al[7] reported almost a 50% incidence in 29 similar patients. That the situation is far from simple is shown by dissimilar findings. Of a total of 28 cases, Warin and Faulkner[8] found *Candida* in only four of 17 cultured cases. These investigators believe that *C albicans* is a secondary colonizer that aggravates rather than instigates the rash.

A variety of other organisms including *Staphylococcus aureus* and Gram-negatives (*Escherichia coli* and *Proteus*) have been found, but these have not been considered to be causative. While it is clear that there is no characteristic uniform microflora in diaper rash, the issue of whether some forms are precipitated by microorganisms is contradicted by findings such as those of Brookes and colleagues.[9] In 35 normal infants and 25 with diaper dermatitis, they found no differences in the microflora.

One might sum up the problem in the following way. Despite many studies, no consensus has been reached regarding which organisms, *if any*, play a central role in the pathogenesis of diaper rash. With the exception of the work of Montes and Brookes and their co-workers, all these investigations have a serious deficiency in that quantitative methods were not used. The data merely indicate whether or not a given organism was present. We cannot determine whether a given organism was numerous or sparse, whether a chance contaminant or truly proliferating. Prevalance rates do not take into consideration the possibility that microorganisms of comparatively high virulence might be present at low densities without harming the skin while high numbers of less dangerous species could be injurious. Another handicap of previous studies is that clinical descriptions were often lacking. Diaper rash is a melange of conditions and manifests itself with variable signs and intensity. Important information can be missed if the microflora is not correlated with the clinical picture.

We report here in a quantitative fashion the microbiology of the diaper area of infants with and without diaper dermatitis and correlate these findings with the clinical findings.

Submitted for publication May 17, 1977; accepted July 27.

From the Department of Dermatology, Duhring Laboratories, Hospital of the University of Pennsylvania, Philadelphia.

Reprint requests to Department of Dermatology, Duhring Laboratories, Suite 203, 3500 Market St, Philadelphia, PA 19104 (Dr Leyden).

SUBJECTS AND METHODS

Subjects

Forty normal infants, aged 1 to 14 months, with no history of previous diaper dermatitis, and 100 infants, 1 week to 15 months of age, with diaper dermatitis were studied. All attended the Dermatology Clinic at the Children's Hospital of Philadelphia.

The 100 infants with diaper rash were classified clinically into the following categories: chafing dermatitis (20%), atopic dermatitis (24%), moniliasis (25%), moniliasis with disseminated "id" (15%), seborrheic dermatitis (10%), psoriasis (2%), and undecided (4%). The criteria for these diagnoses were as follows: (1) Chafing dermatitis. The eruption was present only in the diaper area, mainly where friction was greatest—the inner surfaces of the thighs, the genitals, buttocks and the abdomen. This form tends to wax and wane quickly, consisting of a mild erythema with a shiny glazed surface and occasional papules. (2) Atopic dermatitis. A variable inflammatory rash not diagnostic in itself, but with typical lesions of atopic dermatitis on the cheeks, neck, antecubital fossa, or extremities along with a family history of atopic dermatitis, allergic rhinitis, or asthma. (3) Moniliasis. The diaper area showed a confluent intense erythema with a sharp border beyond which were satellite papules and pustules. Patients with this form of diaper dermatitis who subsequently developed a disseminated eruption consisting of discrete plaques of erythema and scaling on the trunk, extremities, neck, and scalp were classified as moniliasis with "id" reaction. (4) Seborrheic dermatitis. The diaper area showed erythema and scaling, most pronounced in the groin and buttocks creases, along with similar lesions in the retroauricular neck, axillary, and limb creases as well as the scalp. (5) Psoriasis Well-marginated plaques of erythema with a heavy scale in the diaper area as well as the trunk and scalp, in addition to a family history of psoriasis.

No patient had received any therapy for at least one week prior to this study.

Culture Sites and Technique

Cultures were obtained from as many as the following areas as possible: the inguinal fold, the anterior thigh (within the area covered by the diaper), the labia major, the perianal area, and the buttocks. Samples for quantitative microbiological analysis were obtained by the detergent scrub technique of Williamson and Kligman.[10] In brief, this technique employs two one-minute scrubbings with 0.1% octoxynol-9 (Triton X-100) in a 3.8 sq cm area of skin outlined by a sterile glass cylinder. Samples are pooled, serially diluted in half-strength, buffered Octoxynol-9, and then drop-plated onto trypticase soy agar (TSA) with lecithin and polysorbate 80, MacConkey's selective agar for Gram-negatives, and Sabouraud's agar. Organisms were identified by standard techniques. The *Micrococcaceae* were identified only to the point of separating coagulase-positive *S aureus*. Diphtheroids were sorted out into two groups: lipophilic diphtheroids whose growth is stimulated by lipids, and large-colony diphtheroids with large colonies that are not enhanced by lipids. Cooke's strain, *Brevibacterium ammoniagenes* (an aerobic, short, Gram-positive, nonmotile, non-spore-forming organism), was obtained from the American Type Culture Center (ATCC). On TSA it displays a large, wrinkled yellow colony; it is nonfluorescent, strongly urease-positive, and its growth is not enhanced by lipids. These characteristics would classify it as a large-colony diphtheroid. We considered an organism to be *B ammoniagenes* if it had similar morphology to the ATCC strain and the urea-splitting test was strongly positive. *Candida albicans* was identified on the basis of germ tube formation in serum incubated at 37 C for two hours.

RESULTS

Table 1 summarizes the results. The geometric mean aerobic count was 240,000/sq cm for the inguinal fold, 92,400/sq cm for the thigh, 75,000/sq cm for the labia, 892,300/sq cm for the perineum, and 610,000/sq cm for the perianal area. Coagulase-negative cocci were present in nearly every site sampled and constituted the bulk of the total aerobic flora (50% to 73%). Lipophilic diphtheroids were the next most frequently isolated organism, being present in about 50% of sites and constituting 25% to 36% of the total flora. Large-colony diphtheroids were also frequently present and often constituted a high percentage of the total flora (16% to 55%). *Bacillus ammoniagenes (Brevibacterium ammoniagenes)* was present in only two cultures. Gram-negatives were frequently recovered, but accounted for only a small fraction of the total flora except for the perineum where it represented 70%. *Candida albicans* was recovered in low numbers in only five samples (three perineal and two perianal). *Staphylococcus aureus* was not recovered from any site.

In those with diaper dermatitis, the geometric mean aerobic density was in the range of 10^5 organisms per square centimeter for all cases for all sites (Table 2). Thus, the density was approximately the same as in normals for the perineum, perianal, and inguinal fold areas but was higher for the thigh and labia. As in the latter, coagulase-negative cocci were present in nearly every case; similarly, lipophilic and large-colony diphtheroids were also frequently present in high numbers. Gram-negatives were very common, usually in low numbers. *Candida albicans* was present in 80% of those cases considered to be local moniliasis and in a third of those diagnosed as moniliasis with disseminated id. In seborrheic dermatitis *C albicans* was recovered in 20%. In all these instances, it made up only 1% to 4% of the microflora. *Staphylococcus aureus* was also frequently isolated, approximately 50% of the cases. Unlike *C albicans* it comprised a goodly portion of the population, from 10% to 80%. Atopic dermatitis had the highest prevalence of *S aureus* (100%), and its abundance was great, comprising on the average 80% of the microflora. Frequently it was the sole organism. Among the large-colony diphtheroids, *Brevibacterium ammoniagenes* was recovered only six times.

COMMENT

Diaper dermatitis is not a specific diagnosis and is best viewed as a family of disorders. In this respect, it is a regional diagnosis like "hand dermatitis" that has many different causes. Previous surveys have usually not correlated the clinical and microbiology. The result has been confusion and disagreement. Thus, some discount bacteria altogether, others see *C albicans* as the culprit, while perhaps the view with greatest currency is that ammonia liberated from urea irritates the skin.

The most prevalent form of diaper dermatitis is the least serious, the shiny erythema on friction surfaces that produces an irritated or chafed look. This form comes and goes, affects most infants at some time, and responds quickly to simple drying measures and frequent diaper changes. Chafing rash is mild, and mothers generally do not seek medical help though pediatricians not infrequently see this type as part of infant care. Chafing dermatitis is usually not included in microbiological surveys, Brookes and colleagues'[9] study being an exception since their sample was derived from a well-baby clinic. Like them, we could find no qualitative differences in those with and without chafing dermatitis, except for low numbers of *S aureus*, which were found in 50% of such cases. The level of *S aureus* was far below the 10^6 per square centimeter we have established as the level at which an underlying dermatitis is truly secondarily infected.[11] In a separate report, we will present data showing that there is no significant difference between ammonia levels in the diapers of infants with and without diaper dermatitis nor in the prevalence of urea-splitting organisms. Moreover, the maximal amount of

Table 1.—Normal Microflora in Diaper Area

	No. of Positive Samples (% of Total Flora in Positive Cases)				
	Inguinal Fold (N = 40)	Thigh (N = 32)	Labia (N = 13)	Perineum (N = 30)	Perianal Area (N = 30)
Geometric mean, aerobic density/sq cm	240,000	92,400	75,500	892,300	610,000
Coagulase-negative cocci	38 (70)	31 (65)	13 (71)	30 (73)	29 (50)
Lipophilic diphtheroids	20 (25)	16 (32)	11 (30)	10 (27)	11 (36)
Large-colony diphtheroids	10 (16)	6 (55)	2 (6)	12 (35)	3 (55)
Staphylococcus aureus	0 (0)	0 (0)	0 (0)	0 (0)	0 (0)
Gram-negative bacilli	33 (2)	28 (2)	13 (2)	29 (1.5)	27 (23.5)
Candida albicans	0 (0)	0 (0)	0 (0)	3 (0.01)	2 (0.01)
Pityrosporum	3 (1)	4 (1)	0 (0)	0 (0)	0 (0)
Brevibacterium ammoniagenes	0 (0)	0 (0)	0 (0)	2	0 (0)

Table 2.—Prevalence of Microorganisms in Relationship to Clinical Diagnosis

			% of Positive Samples (% of Total Flora When Present)						
Clinical Diagnosis	N	Aerobic density/ sq cm*	*C albicans*	*S aureus*	Gram-Negative Rods	Large-Colony Diphtheroids	Lipophilic Diphtheroids	Coagulase Negative Micrococci	*B ammoniagenes*
Moniliasis (satellite pustules)	25	764,500	80 (4)	30 (25)	60 (11)	20 (10)	40 (20)	100 (30)	0 (0)
Moniliasis (disseminated "id")	15	932,000	33 (2)	60 (40)	50 (20)	18 (15)	22 (10)	100 (13)	0 (0)
Atopic dermatitis	24	980,000	0 (0)	100 (80)	20 (1)	5 (2)	20 (1)	100 (16)	3 (1)
Seborrheic dermatitis	10	732,000	20 (1.5)	80 (30)	40 (3)	20 (30)	10 (10)	100 (25)	0 (0)
Psoriasis	2	487,000	0 (0)	50 (10)	100 (1)	50 (6)	50 (11)	100 (70)	1 (2)
Chafing dermatitis	20	643,000	0 (0)	50 (20)	25 (10)	20 (3)	40 (6)	100 (60)	2 (1)

*Geometric mean count.

ammonia that could be liberated from urine does not cause a rash when applied occlusively to normal skin. It is our opinion that the irritant or chafing form of diaper dermatitis is the result of friction and maceration in constantly wet skin. Water itself is highly damaging to the horny layer. Microbes appear to play no role in chafing dermatitis.

In those cases diagnosed as atopic dermatitis on the basis of typical lesions elsewhere and the presence of a family history of atopic disease, *S aureus* was found in all 24 cases and was the predominant organism, constituting 80% of the flora. These results are identical with our earlier findings in atopic dermatitis of other body areas of children.[11,12] We consider that *S aureus* is a secondary invader in atopic dermatitis and contributes to morbidity when the density exceeds 10^6 organisms per square centimeter.[11] This figure probably holds for atopic dermatitis in the diaper area.

Likewise, the microflora in psoriatic diaper rash corresponded to our findings in psoriasis of adults.[13] *Staphylococcus aureus* occurred in 50% of the cases but in low numbers (10% of the total flora). At this low density *S aureus* is unlikely to be playing a significant role.

The findings in seborrheic dermatitis were mixed. In two of ten cases, *C albicans* was isolated. Both of these cases and six others also contained *S aureus* at moderately high levels (30% of the total aerobic flora). *Candida albicans* has been recovered in other series of seborrheic dermatitis and has been viewed as a secondary aggravating factor.[14] Our cases are too few to come to a firm conclusion. Our experimental experiences with *C albicans* lead us to believe that its virulence is high and that is often an instigating factor rather than a secondary invader.[15,16]

In cases diagnosed as moniliasis, recovery of the organism depends strongly on the clinical type. The recovery rate was 80% in typical local moniliasis. In more severe varieties with disseminated lesions, the recovery was much lower (33%). In both types *Candida* represented only a minor proportion of the total flora (2% to 4%). We recovered *C albicans* in only five of 145 cultures from normal infant skin. When present, it represented less than 0.01% of the total flora. Dixon et al[4] also found *C albicans* to be extremely infrequent on normal skin (one of 68 cases); Brookes et al[9] found no *C albicans* in 35 normal infants. In contrast to these reports is

the recovery rate of 12% from normal skin by Montes et al.[5] Quantitative data for *C albicans* were not given by Montes et al or Brookes et al; hence, it is not known whether the density was as low as in our five cases. Failure to find *Candida* in clinically typical moniliasis and its recovery from other cases not suspected to be moniliasis helps sustain the prevailing view that *C albicans* acts as a secondary aggravating factor but does not instigate the rash. Dixon et al[4] found *C albicans* in 63% of suspected cases and in 25% of those labeled "*Candida* unlikely." The recovery of *C albicans* from severe diaper dermatitis with a desiminated id has been quite variable. Jefferson[6] found *C albicans* in 20 of 32 patients, and Ferguson et al[7] reported almost a 50% incidence in 29 patients. On the other hand, Warin and Faulkner[8] found *Candida* in only four of 17 similar cases. Again, our quantitative data in this study do not settle this question either. When present, *C albicans* made up only a small fraction of the flora. One should not be tempted to dismiss *C albicans* on this account. Previous studies from our laboratory have shown that in experimental induction of *Candida* infections, *C albicans* represents only a minor percentage of the total flora (usually around 1%);[15,16] in contrast to *S aureus* in atopic dermatitis, where levels of 10^6/sq cm are required to aggravate preexisting dermatitis,[11] 10^4/sq cm levels of *C albicans* will promptly induce a primary dermatitis.[15] Furthermore, in experimentally induced erosio interdigitalis blastomycetia, after initial breakdown of the skin, *C albicans* becomes less and less frequently recovered and may disappear altogether even though the clinical reaction is progressive.[16] The lower recovery rate from the most severe clinical cases and the low percentage of the total flora when present are in accord with the data from serial analysis of experimental *C albicans* infections. These observations have led us to conclude that *C albicans* plays a primary instigating role in certain severe forms of diaper rash. When recovered, it represents a significant finding and treatment directed against *Candida* is indicated.

References

1. Jacquet L: Dermites infantiles simples. *Traite Mal Enf Paris*, 1905.
2. Zahorsky J: The ammoniacal diaper in infants and young children. *Am J Dis Child* 10:436-440, 1915.
3. Cooke JV: Dermatitis of the diaper region in infants (Jacquet dermatitis). *Arch Dermatol Syph* 14:539-546, 1921.
4. Dixon PN, Warin RP, English MP: Role of *Candida albicans* infection in napkin rashes. *Br Med J* 2:23-27, 1969.
5. Montes LF, Pittillo RF, Hunt D, et al: Microbial flora in infants' skin: Comparison of types of micro-organisms between normal skin and diaper dermatitis. *Arch Dermatol* 103:640-645, 1971.
6. Jefferson, J: Napkin psoriasis. *Br J Dermatol* 78:614-615, 1966.
7. Fergusson AG, Fraser NG, Grant PW: Napkin dermatitis with psoriasiform ide: A review of 52 cases. *Br J Dermatol* 78:289-296, 1966.
8. Warin RP, Faulkner KE: Napkin psoriasis. *Br J Dermatol* 73:445-447, 1961.
9. Brookes DB, Hubbert RM, Sarkany I: Skin flora of infants with napkin rash. *Br J Dermatol* 85:250-254, 1971.
10. Williamson P, Kligman AM: A new method for the quantitative investigation of cutaneous bacteria. *J Infect Dis* 45:498, 1965.
11. Leyden JJ, Marples RR, Kligman AM: *Staphylococcus aureus* in lesions of atopic dermatitis. *Br J Dermatol* 90:525-530, 1974.
12. Leyden JJ: Antibiotic usage in dermatological practice. *Int J Dermatol* 13:342-352, 1974.
13. Marples RR, Heaton CL, Kligman AM: *Staphylococcus aureus* in psoriasis. *Arch Dermatol* 107:568-570, 1973.
14. Beare JM, Cheesman EA, MacKenzie WF: The association between *Candida albicans* and lesions of seborrheic dermatitis. *Br J Dermatol* 80:675-681, 1968.
15. Rebora A, Marples RR, Kligman AM: Experimental *Candida albicans* infection. *Arch Dermatol* 108:69-73, 1973.
16. Rebora A, Marples RR, Kligman AM: Erosio interdigitalis blastomycetica. *Arch Dermatol* 108:66-68, 1973.

Topical Use of Caffeine With Hydrocortisone in the Treatment of Atopic Dermatitis

Robert J. Kaplan, MD; Lauren Daman, MD; E. William Rosenberg, MD; Seth Feigenbaum, MA

• In a double-blind study, topically applied caffeine 30%-hydrocortisone 0.5% in hydrophilic ointment was compared to betamethasone valerate 0.1% cream and to hydrocortisone 0.5% in hydrophilic ointment. Eighty-three patients were evaluated over a three-week period for pruritus, erythema, scaling, lichenification, excoriation, oozing, and global impression. The betamethasone and caffeine-hydrocortisone groups performed significantly better than the hydrocortisone group on three of the seven scales: lichenification, excoriation, and global impression. Also, the betamethasone group differed significantly from the hydrocortisone group on six of the seven scales, but did not differ significantly from the caffeine-hydrocortisone group on any scale. It is suggested that caffeine is effective because it elevates local levels of cyclic adenosine-3′, 5′-monophosphate by inhibiting phosphodiesterase.

(*Arch Dermatol* 114:60-62, 1978)

It has been demonstrated that locally applied β-adrenergic agents can suppress the immediate hypersensitivity skin test reaction in atopic patients, presumably by increasing skin levels of cyclic adenosine-3′, 5′,-monophosphate (cAMP).[1] Caffeine, a methylxanthine, inhibits phosphodiesterase, thus increasing levels of cAMP. Increasing skin levels of cAMP might be expected to ease the symptoms of atopic dermatitis. Two double-blind clinical studies conducted at this institution,[2,3] using a 10% and a 30% caffeine cream in hydrophilic ointment vs hydrophilic ointment as placebo, demonstrated the superiority of the caffeine creams compared to placebo in treating chronic atopic dermatitis. In an effort to ascertain the relative efficacy of the caffeine compared with proved steroidal preparations, a clinical study was undertaken to compare caffeine 30%-hydrocortisone 0.5% in hydrophilic ointment to betamethasone valerate 0.1% (Valisone) cream and to hydrocortisone 0.5% in hydrophilic ointment.

SUBJECTS AND METHODS

Ninety patients who were consecutively seen in the university dermatology outpatient clinic with typical manifestations of chronic atopic dermatitis and who had not used topical medication for two weeks prior to study were selected. All patients consented to participate in the study. To minimize selection bias, entering patients were randomly assigned to one of three treatment groups: (1) hydrocortisone-free alcohol 0.5% in hydrophilic ointment, (2) caffeine anhydrous powder 30%-hydrocortisone 0.5% in hydrophilic ointment, and (3) betamethasone valerate 0.1% cream. All medications were presented in identically coded containers and each patient was

Accepted for publication Aug 14, 1977.

From the Division of Dermatology, University of Tennessee Center for the Health Sciences, Memphis.

Reprint requests to Department of Dermatology, University of Tennessee, College of Medicine, Memphis, TN 38163 (Dr Kaplan).

given identical application specifications, which also appeared on each container. Identities of the creams were unknown to both the patients and the physicians. The creams were distributed in divided doses, initially and at the second weekly evaluation. The patients were evaluated initially and at weekly intervals for three successive weeks. Each patient was evaluated for pruritus, erythema, scaling, lichenification, oozing, excoriation, and overall global impression on a six-point rating scale (0, none; 1, mild; 3, moderate; 5, severe). Three dermatologist investigators established grading criteria; reliability testing was performed prior to beginning the study. The correlation coefficient for this testing was not less than 0.8 for any scale.

A one-way analysis of variance with repeated measures and unweighted means was employed to test for significance of group and time effects. If a significant F ratio was found in the analysis of variance, the Newman-Keuls a posteriori test[4] was used to make all comparisons among means. A single-factor analysis of variance was used to test age values among groups and χ^2 was used to test race and sex distributions. All data stated to be significant had a P value of less than .05.

RESULTS

The demographic characteristics of the study sample are given in Table 1. Although there was a preponderance of blacks in all treatment groups, representing the typical percentage of this racial group seen in our clinic, no significant differences were found in the race, age, or sex distributions of the treatment groups.

At the completion of the evaluation period there were 83 valid studies. Two patients did not appear for follow-up evaluation (one in the hydrocortisone group and one in the caffeine-hydrocortisone group) and could not be located. Five patients, for reasons described in Table 2, discontinued usage of the cream and were not included in the analyses.

Table 3 gives the initial evaluation and last visit severity scores for the three treatment groups. There were no significant differences between treatment groups by analysis of variance on any of the clinical scales at the initial evaluation. There was, however, a significant groups-by-time interaction effect for each of the scales, indicating that the groups were differentially affected by the various treatments. Testing of the last visit scores indicated that while all treatment groups improved, the betamethasone and the caffeine-hydrocortisone groups performed significantly better than the hydrocortisone group on three of the seven scales: lichenification, excoriation, and global impression. Also, the betamethasone group differed significantly from the hydrocortisone group on six of the seven scales, but did not differ significantly from the caffeine-hydrocortisone group on any scale.

This study was an extension of our attempts to determine whether Szentivanyi's[5] theory of β-adrenergic impairment as a cause of atopic disease could lead to improved therapeutic techniques. It has been suggested that atopics react to various stimuli as if they had a generalized β-adrenergic blockade.[5-7] The choice of a phosphodiesterase inhibitor such as caffeine followed logically from the β-adrenergic impairment theory because phosphodiesterase inhibitors tend to raise levels of intracellular cAMP. It has been known for some time that β-adrenergic stimuli affect cell function via the mechanisms of increasing cAMP. It has been shown in vitro that histamine release induced by antigenic challenge can be blocked by prior exposure to β-adrenergic agents, methylxanthines, or by directly increasing the levels of cAMP.[8] By the presumable increase of skin levels of cAMP, it was demonstrated in vivo that locally applied β-adrenergic agents can suppress immediate hypersensitivity skin test reaction in man.[1] Also, acute inflammatory skin reactions induced by intradermal injections of inorganic pyrophosphate or adenosine triphosphate (ATP) or both, thus not involving antigenic stimuli, are similarly blocked by cAMP.[9] In addition, Bourne et al[10] reviewed the evidence showing that elevating intracellular levels of cAMP reduced inflammatory reactions by a "general inhibitory action . . . on immunologic

Table 1.—Demographic Distribution of 90 Patients With Atopic Dermatitis

Demographic Variables	Treatment Groups: Hydrocortisone (N = 30)	Caffeine and Hydrocortisone (N = 30)	Betamethasone Valerate (N = 30)	Total (N = 90)
Age, yrs (mean)	21.2	14.7	19.7	18.5
Race, % black	76	90	87	84
Sex, % male	31	52	27	36

Table 2.—Demographic and Clinical Features of Five Patients Who Discontinued Experimental Medication

Age/Race/Sex	Treatment Group	Side Effects
24/B/F	Hydrocortisone	Immediate burning with subsequent drying of skin
41/B/F	Caffeine and hydrocortisone	Immediate increase in pruritus
25/B/M	Caffeine and hydrocortisone	Immediate increase in pruritus
2/B/F	Caffeine and hydrocortisone	Impetigo, requiring systemic antibiotic
11/W/F	Caffeine and hydrocortisone	Immediate increase in pruritus

Table 3.—Mean Initial and Last Visit Severity Scores* of 83 Patients With Atopic Dermatitis on Seven Clinical Scales

Clinical Scale	Hydrocortisone (N = 28) First	Hydrocortisone (N = 28) Last	Caffeine and Hydrocortisone (N = 25) First	Caffeine and Hydrocortisone (N = 25) Last	Betamethasone Valerate (N = 30) First	Betamethasone Valerate (N = 30) Last	P
Pruritus	3.6	1.7	3.5	1.1	3.7	0.7	< .05†
Erythema	2.7	1.6	2.6	1.4	2.7	0.9	< .05†
Scaling	2.4	1.5	2.4	1.2	2.5	0.9	< .05†
Lichenification	3.4	2.2	3.0	1.6	3.4	1.4	< .05†‡
Oozing	1.8	1.0	1.8	0.6	2.1	0.5	NS
Excoriation	2.6	1.6	2.1	0.8	2.7	0.6	< .05†‡
Global impression	3.5	2.4	3.2	1.6	3.4	1.5	< .05†‡

*0, none; 1, mild; 2, mild to moderate; 3, moderate; 4, moderate to severe; 5, severe.
†Betamethasone valerate 0.1% vs hydrocortisone 0.5%.
‡Betamethasone valerate 0.1% and caffeine 30%-hydrocortisone 0.5% vs hydrocortisone 0.5%.

and inflammatory functions of leukocytes." Methylxanthines act by inhibiting phosphodiesterase, thus increasing intracellular cAMP levels by inhibiting the degradation of cAMP to adenosine-5′-monophosphate. It was our belief that manipulating phosphodiesterase in atopics might be a useful mechanism for aiding the disease even though it has been shown by Holla et al[11] that atopic skin does not have an abnormal phosphodiesterase level. Phosphodiesterases are present in atopic skin.[12] Even if the β-adrenergic failure were somewhere else in the system other than in the phosphodiesterase, manipulating phosphodiesterase levels would tend to raise intracellular cAMP levels.

The fact that caffeine seemed useful in atopic dermatitis does not prove, however, the validity of Szentivayi's theory. As reviewed by Bourne et al.[10] increasing the intracellular cAMP level tends to diminish a variety of leukocyte-induced inflammatory responses. Furthermore, methylxanthines may have lesser effects on calcium fluxes, ATP content, and other phenomena[13] quite apart from the effect as phosphodiesterase inhibitors. In any event, no matter what the mechanism, we interpret our results as indicating a practical usefulness for caffeine-hydrocortisone combinations in the treatment of atopic dermatitis. The caffeine-hydrocortisone creams were statically significantly better than plain hydrocortisone in improving lichenification, excoriation, and the overall global impression of atopic patients. Although not statically significant, similar trends were found for the phenomena of pruritus, erythema, oozing, and scaling. More importantly, there were no significant differences between the 0.1% betamethasone valerate and the 0.5% hydrocortisone-30% caffeine hydrocortisone groups on any scale. Long-term use of topically applied fluorinated corticosteroids may be associated with cutaneous atrophy, pigmentary disturbances, telangiectasias, and hypothalamic pituitary adrenal suppression.[14] Use of a methylxanthine-hydrocortisone product might help such complications by reducing the necessary effective dose of corticosteroids.

Since most of the problems encountered in our study involved the caffeine product, we recognized the possibility that topically applied caffeine might irritate some atopic individuals. An examination of the products, after the codes were broken, disclosed some granularity in the creams containing the caffeine but not in the other two compounds. We do not know whether the irritation induced in some patients by the caffeine-hydrocortisone combinations was due to the grittiness of the product or to some pharmacologic effect of the caffeine. We have been advised that the grittiness of the product could be eliminated by the use of commercial-grade mixing equipment.

Sam Burson, RPh, helped compound the medications. Margaret Tate assisted with manuscript preparation.

References

1. Shereff RH, Harwell W, Lieberman P, et al: Effect of β-adrenergic stimulation and blockade on immediate hypersensitivity skin test reactions. *J Allergy Clin Immunol* 52:328-333, 1973.

2. Kaplan RJ, Daman LA, Shereff RH, et al: Treatment of atopic dermatitis with topically applied caffeine. *Arch Dermatol* 112:880-881, 1976.

3. Kaplan RJ, Daman L, Rosenberg EW, et al: Treatment of atopic dermatitis with topically applied caffeine: A follow-up report. *Arch Dermatol* 113:107, 1977.

4. Winer BJ: *Statistical Principles in Experimental Design*, ed 2. New York, McGraw-Hill Book Co Inc, 1971, pp 216-218.

5. Szentivanyi A: The β-adrenergic theory of the atopic abnormality in bronchial asthma. *J Allerg* 42:203-232, 1968.

6. Calnan CD: An atopic theorem. *Trans St Johns Hosp Dermatol Soc* 55:106-108, 1969.

7. Hemels HGWM: Effect of propranolol on the acetylcholine-induced sweat gland response in atopic and non-atopic subjects. *Br J Dermatol* 83:312-314, 1970.

8. Ishizaka T, Ishizaka K, Orange RP, et al: Pharmacologic inhibition of the antigen-induced release of histamine and slow reacting substance of anaphylaxis (SRS-A) from monkey lung tissues mediated by human IgE. *J Immunol* 106:1267-1273, 1971.

9. Ichikawa A, Hayashi H, Minami M, et al: An acute inflammation induced by inorganic pyrophosphate and adenosine triphosphate, and its inhibition by cyclic 3′,5′-adenosine monophosphate. *Biochem Pharmacol* 21:317-331, 1972.

10. Bourne HR, Lichtenstein LM, Melmon KL, et al: Modulation of inflammation and immunity by cyclic AMP. *Science* 184:19-28, 1974.

11. Holla SWJ, Hollman EPMJ, Mier PD, et al: Adenosine 3′:5′-cyclic monophosphate phosphodiesterase in skin. *Br J Dermatol* 86:147-149, 1972.

12. King LE Jr, Solomon SS, Hashimoto K: Cyclic nucleotide phosphodiesterase in normal and cancerous human skin. *Clin Res* 22:329A, 1974.

13. Appelman MM, Thompson WJ, Russell TR: Cyclic nucleotide phosphodiesterases, in Greengard P, Robinson G (eds): *Advances in Cyclic Nucleotide Research*. New York, Raven Press, 1973, vol 3, pp 65-98.

14. Carr RD, Belcher RW: Adrenocortical suppression with small doses of topical corticosteroids. *Acta Derm Venereol* 49:508-513, 1969.

Radiation Dermatitis Following Electron Beam Therapy

An Evaluation of Patients Ten Years After Total Skin Irradiation for Mycosis Fungoides

Norman M. Price, MB, ChB

• Ten patients, who had been treated for mycosis fungoides with electron beam radiation ten or more years previously, were examined for signs of radiation dermatitis. Although most patients had had acute radiation dermatitis, only a few manifested signs of mild chronic changes after having received between 1,000 and 2,800 rads.

(*Arch Dermatol* 114:63-66, 1978)

Therapeutic radiation of the skin by various modalities has resulted in the occurrence of radiation dermatitis.[1-5] Patients with mycosis fungoides have been treated with grenz rays,[6] x-rays,[7] and telorentgen.[8] The electron beam was originally used for the treatment of mycosis fungoides in 1951.[9] The electron beam at Stanford University Medical Center has been used for the treatment of mycosis fungoides since 1958.[10,11]

No detailed follow-up study has been undertaken to determine the extent of radiation dermatitis occurring in mycosis fungoides patients treated with the electron beam. This study was performed in order to evaluate patients' conditions ten or more years after they had received their radiation.

Accepted for publication Aug 16, 1977.

From the Dermatology Service, Veterans Administration Hospital, Palo Alto, Calif; and the Department of Dermatology, Stanford (Calif) University Medical Center.

Reprint requests to Dermatology Service (151D), VA Hospital, 3801 Miranda Ave, Palo Alto, CA 94304 (Dr Price).

PATIENTS AND METHODS

The patients who participated in this study were selected from the files of the Mycosis Fungoides Clinic at the Stanford University Medical Center. All these patients had received their electron beam therapy ten or more years prior to the beginning of the study in 1976. All the patients who had received therapy and who were still alive were sent a letter informing them of the purpose of the study and were invited to participate. Ten of 26 patients were able to participate.

The diagnosis of mycosis fungoides had been made on the basis of the clinical findings and diagnostic skin biopsy prior to the initiation of the electron beam therapy.[12] A summary of the patients and their treatment is given in Table 1. The conditions of seven of the patients were originally diagnosed in the generalized plaque phase, and those of the other three in the limited plaque phase of the disease. None were in an erythematous or tumor phase, and none were observed to have evidence of systemic involvement. A linear accelerator that produced a 2.5-meV electron beam at the skin surface of the patient had been used in such a manner as to avoid x-ray contamination of the field.[10]

The study was performed by evaluating the patients and their charts for clinical signs of radiation dermatitis, and for documentation of earlier (acute) radiation dermatitis changes. A 4-mm punch biopsy specimen was taken from the skin of a normally covered part of the body (buttocks or hips) in order to study the specimen for histologic changes of radiation dermatitis (Table 2). The areas selected for biopsy had not been sites of previous lesions, according to the patients' records and to the patients themselves. Two patients had been receiving topical mechlorethamine hydrochloride, both within a five-year period prior to biopsy. The others had received no additional therapy. The data from patients and their biopsies were tabulated and summarized in order to determine the incidence of various features of radiation dermatitis, both clinically and histologically.

RESULTS

Clinical Changes

Acute Radiation Dermatitis.—All the patients had evidence of having had early acute radiation dermatitis during or immediately following the electron beam therapy: erythema, six; edema, five; burning or tingling, four; pruritus, two; pigmentation, four; desquamation, seven; epilation, seven; shedding of nails, three; vesiculation or bulla formation, three; and erosion or ulceration, three. Arthritis was also observed in one patient.

Late Chronic Radiation Changes.—The following changes were noted from the clinical examinations of the patients during the study: excessive wrinkling or atrophy of the skin, five; telangiectasias, four; hypopigmentation, one; hyperpigmentation, three; permanent loss of scalp hair, 0; permanent loss of body hair, one; excessively

Table 1.—Patient Treatment Data

Patient No./Sex	Stage*	Other Treatments	Age When Treated, yr	Year of Treatment	Total Rads Received	Fractionation Period, Days
1/F	LP	...	20	1962	1,200	19
2/F	LP	...	48	1962	1,400	11
3/M	GP	...	30	1963	2,000	32
4/M	GP	...	54	1963, 1964†	2,800 (1,400 + 1,400)	21, 21
5/M	LP	...	63	1964	1,100	12
6/M	GP	...	41	1964	1,000	16
7/M	GP	...	62	1964, 1965†	2,700 (1,350 + 1,350)	22, 29
8/M	GP	...	61	1964, 1966†	2,700 (1,350 + 1,350)	39, 26
9/M	GP	NH2‡	48	1964, 1966†	2,750 (1,350 + 1,350)	45, 45
10/M	GP	NH2	59	1966	2,100	53

*Limited plaque, LP; generalized plaque, GP.
†Patients treated a second time for extensive recurrent disease.
‡NH2 signifies mechlorethamine.

Table 2.—Histologic Changes of Radiation Dermatitis*

Structure	Changes
Epidermis	
Stratum corneum	Hyperkeratosis, parakeratosis (1), ulceration, erosion
Granular and basal cell layers	Intercellular and intracellular edema, large nuclei, acanthosis or atrophy (4), pyknosis, atypia (1), increased melanin, homogenization
Other changes	Premature keratinization of cells (1), irregular downgrowth of epidermis, enclosure by downgrowth of superficial vessels, adenexal absence, degenerative changes, neoplastic changes
Dermis	
Collagen	Edema (9), fragmentation, thickening of entire dermis, basophilic degeneration, regeneration of new collagen, hyalinization
Elastic tissue elastosis	Fragmentation, decrease of elastotic material
Blood vessels	Dilation (8), fibrinoid necrosis of walls, thrombosis, obliterative arteritis, recanalization
Nerves	Inflammation, edema, fibrosis
Fibrous tissue	Radiation fibroblasts (large, hypochromatic, actively dividing nuclei), fibrosis
Pigmentation	Melanophages (6)
Edema	Superficial vesiculation formed by cleavage of epidermal-dermal junction
Other	Inflammatory infiltrate in dermis (1) and/or permeation into epidermis, neoplastic change in dermis

*Number of patients affected is shown in parentheses.

Fig 1.—Skin of patient, illustrating wrinkling and mild pigmentary changes.

dry skin, three; excessive longitudinal ridging of nails, six; keratoses, one; and basal cell epithelioma, one (Fig 1).

Histologic Changes

Epidermis.—Changes in the epidermis were as follows: parakeratosis, one; premature keratinization, one; atrophy, four; and atypia, one.

Dermis.—The following changes were noted in the dermis: collagen changes: papillary dermal edema, nine; blood vessel changes: dilation dermal capillaries, eight; pigmentary changes: melanophanges in upper dermis, six; and inflammatory infiltrate present, one (Fig 2 and 3).

COMMENT

The early (acute) features of radiodermatitis subsequent to large doses of x-ray or gamma radiation are erythema, desquamation, pigmentation, painful bulla formation, and ulceration. Their sequels may be telangiectasia, irregular hyperpigmentation, dermal atrophy with or without scarring, and presistent ulceration. The late (chronic) features of radiation dermatitis may occur many years after the administration of fractionated doses of radiation. The skin shows telangiectasia, irregular hyperpigmentation, dermal atrophy, and ulcerations together with focal areas of hyperkeratoses and the occasional presence of neoplasms.[1,4,5] The features of both acute and chronic radiation dermatitis may be seen as sequels to any form of radiation, whether it be superficial x-ray, deep x-ray, radium, atomic blast radiation, or even grenz ray radiation. The severity of the radiation dermatitis is dependent on the amount of rads and the penetrative depth of the radiation that the patient was given. Other important aspects are the duration of time over which the radiation was given and the location on the body to which the radiation was directed.[3]

The corresponding histologic features of acute and chronic radiation dermatitis can be categorized into those seen within the epidermis and the dermis. The various histopathologic features that can be observed are listed in Table 2. The degree to which these features are present is similarly dependent on the amount of rads and the penetrative depth of the radiation that the patient was given, as well as the extent of fractionation and the location of the treatment sites on the skin.

Reports of radiation dermatitis following treatment with the electron beam are few. A study done on the normal skin of patients who were treated for cancer of underlying organs with the electron beam shows

Fig 2.—Histologic section illustrating papillary dermal edema, dilated vessels, and epidermal atrophy (hematoxylin-eosin, ×25).

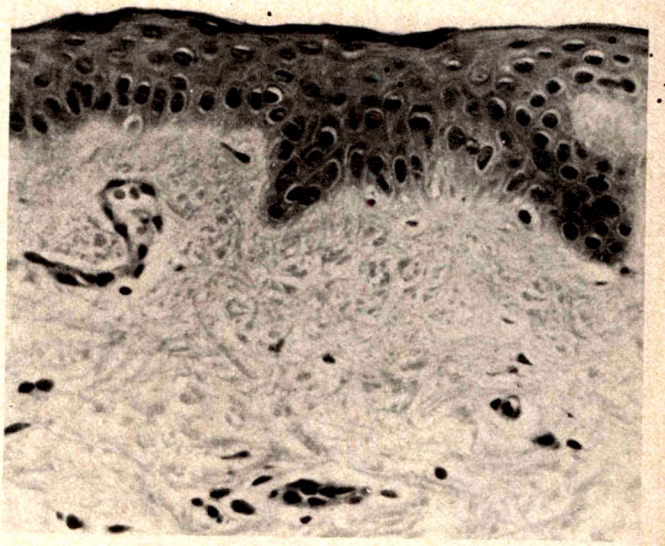

Fig 3.—Histologic section illustrating papillary dermal edema and occasional melanophage (hematoxylin-eosin, ×160).

that certain acute changes of radiation dermatitis will occur if more than 5,000 rads are given. The changes seen were erythema and desquamation. If higher doses were given, bulla formation and ulceration occurred. These findings were reported with usage of an electron beam producing 7 to 11 meV with a depth dose sufficient to treat underlying malignancies, in localized fields of irradiation. No chronic changes were described.[13] Grollman et al[14] reported radiation dermatitis changes in patients with mycosis fungoides and generalized psoriasis whose entire skin surface was treated with the electron beam. These changes were not divided into acute and chronic phases but were listed together. Changes described were telangiectasias, poikiloderma, hyperpigmentation, xerosis, folliculitis, and epilation. Dermal alteration, squamous cell carcinoma, and extensive subcutaneous fibrosis were described in a small number of patients. The patients were treated with radiation varying between 800 and 6,000 rads, depending on the severity of disease and their immediate response to therapy.

The above data differ significantly from our results. While all our patients had evidence of having acute radiation dermatitis changes during or immediately following the electron beam, the late changes are mild and were mainly of wrinkling or atrophy, telangiectasia, or hyperpigmentation of the skin. Similar findings have been reported by Chu et al.[15] The histologic changes in our patients were mainly of epidermal atrophy, upper dermal edema, capillary dilation, and melanophage deposition in the upper dermis.

These changes are explainable if one analyzes the amount of radiation given and the techniques used. In our group of patients, 1,000 to 1,400 rads was given to any individual patient, with a maximum of 2,800 rads to those who were treated twice. In the patients who were given two courses of treatment, an interval of a year or more occurred between courses of treatment. In the above-mentioned studies of Grollman et al, the radiation given varied between 800 and 8,000 rads, with the main complications occurring at the higher level. Another differing aspect of the treatments was the technique in which the linear accelerator was used: in the study reported by Grollman et al, the linear accelerator was aimed directly at the midline of the patient, thus providing a high level of x-ray contamination along with the electron beam. The percentage of x-ray contamination was reported to vary between 0.6% and 6.2% of the total electron dose given. This was later reduced to 0.3% by an adjustment of the machine. The technique used in our group of patients differed in that the center line of the linear accelerator was directed away from the patients at an angle of 20° from the horizontal plane so that the x-ray contamination of the electron beam was reduced to a negligible amount.[16] The x-ray contamination of the electron beam used in our group of patients was about 1.5% (oral communication, Richard T. Hoppe, MD, March 1977). The occurrence of the more severe forms of radiation dermatitis reported by Grollman et al may have been due to the amount and penetration of x-ray contamination, as well as to the higher levels of electron beam radiation given to that group of patients.

The most important factor in the causation of radiation dermatitis is the amount of rads given. This factor, independent of any of the other factors of the machine from which it is delivered, is the most important factor in determining whether a treated area will eventually show the features of radiation dermatitis. The higher the amount of radiation given to a particular area of the skin, the more likely it is to show the effects of radiation dermatitis. Therefore, the amount of 1,000 rads, which is used as a "guideline" by Domonkos[2] for the maximum amount of radiation that can be given to benign lesions treated with radiation, is unlikely to show any of the effects of radiation dermatitis, while amounts above 3,000 to 4,000 rads, as used in the treatment of malignant skin lesions, are likely to show some of the effects of radiation dermatitis. In our study of patients treated with the electron beam up to a maximum of 2,800 rads, there were only a few manifestations of clinical or histologic evidence of radiation dermatitis after a ten-year follow-up.

The degree of penetration of radiation is dependent on the voltage and the filtration of the machine being used to deliver the radiation, as well as on the density of the irradiated tissue. The depth to which radiation dermatitis can be determined histologically is a function of these factors. Differ-

UNIVERSITY OF MEDICINE LIBRARY

ent radiation modalities will therefore result in radiation dermatitis being found at different levels within the dermis. The more penetrating radiation results in the deeper forms of radiation damage. The electron beam has a 50% depth dose at approximately 9 mm at 2.5 meV, with a very rapid falloff of penetration below this depth.[16] It should be observed that the electron beam, delivered in higher energy values (at 10 meV or above), will have a skin-sparing effect, that is, the beam will only "build up" to its maximum dose after having passed through the skin. These extra-high-energy beams, which are now used for the treatment of internal malignancies, therefore have a skin-sparing effect and would not be expected to result in the chronic radiation dermatitis effects that are seen with orthovoltage radiation.[17]

The method of treatment with the electron beam in our group of patients was to use a multiple field technique in order to overcome the problems of variation in the shape, orientation, and size of the patients' skin surfaces. Initially, the technique was to incorporate four body orientations (anterior, posterior, and two lateral); this subsequently was changed to six body orientations (anterior, posterior, and four oblique fields). This resulted in an optimum dose uniformity to the entire patient, ensuring that no individual area was given more radiation than another.[16] Therefore, we are relatively confident that the sites on which we performed biopsies in order to carry out our study are representative of the remainder of the skin surface. In addition, there was no variation detectable in different areas of the skin when the patients were studied for clinical features of radiation dermatitis.

The degree to which mycosis fungoides of the skin can be controlled has been shown to be a function of the amount of radiation given.[18] Only 18% of the patients treated with doses lower than 1,000 rads obtained complete remission, compared to 94% observed in patients who received a total dose of 3,000 to 3,600 rads. In our study the patients were observed to have mild or no changes of radiation dermatitis. This may be a result of the fact that they had, in most cases, 2,000 rads of treatment or less. Patients who were treated with 3,000 or more rads may be observed to have more extensive radiation dermatitis. However, since this higher dosage of radiation had only been implemented within the last five years, there will have to be a sufficient lag-time before any evaluation of radiation dermatitis effects can be determined in patients who received the higher dosages.

The question arises as to whether sufficient time has passed to allow an adequate study for the chronic radiation dermatitis to have occurred in our group of patients. We arbitrarily decided to do the study after ten years and we would presume that this would be an adequate, if not an optimum, time to have carried out this study. To have done this study within a shorter time may possibly have resulted in some forms of radiation dermatitis being undetected, while a longer period would possibly have resulted in fewer patients being available for this study due to the advanced age of most of our patients.

Another problem is whether the ten patients who participated in our study were representative of all the patients who had been treated at our institution, but were unable to be included in the study. Some of these patients may have been observed to have more severe manifestations of radiation dermatitis than are reported in this study. Also, the problem of whether the poikiloderma that is often associated with the disease process of mycosis fungoides itself may be a confusing factor in the evaluation of the degree of radiation dermatitis in this latter category of patients.

We conclude that radiation from the electron beam has the same properties as other modalities of radiation in being able to cause radiation dermatitis. The fact that it was only present in the mildest of forms in our group of patients is probably a result of the low dosage given, the extent of fractionation, and the careful technique by which it was applied.

Alvin J. Cox, Jr, MD, assisted in the interpretation of the histopathologic findings.

References

1. Cipollaro AC, Crossland PM: *X-rays and Radium in the Treatment of Diseases of the Skin*, ed 5. Philadelphia, Lea & Febiger, 1967.
2. Domonkos AN: *Andrews Diseases of the Skin*. Philadelphia, WB Saunders Co, 1971.
3. Wansker BA: *X-ray and Radium in Dermatology*. Springfield, Ill, Charles C Thomas Publisher, 1954.
4. Epstein E: *Radiodermatitis*. Springfield, Ill, Charles C Thomas Publisher, 1962.
5. Rubin P, Casarett GW: Skin and adnexa, in *Clinical Radiation Pathology*. Philadelphia, WB Saunders Co, 1968.
6. Scholtz W: Ueber den Einfluss der Röntgenstrahlen auf die Haut in gesundem and krankem Zustande. *Arch Dermatol Syph* 59:421-446, 1902.
7. Sommerville J: Mycosis fungoides treated with general x-ray bath. *Br J Dermatol* 51:323-324, 1939.
8. Petratos MA: Current practice of telorentgen therapy. *Cutis* 4, 6:16-17, 1968.
9. Trump JG, Wright KA, Evans WW, et al: High energy electrons for the treatment of extensive superficial malignant lesions. *Am J Roentgenol Radium Ther Nucl Med* 69:623-629, 1953.
10. Bagshaw MA, Schneidman HM, Farber EM, et al: Electron beam therapy of mycosis fungoides. *Calif Med* 95:292-297, 1961.
11. Fuks Z, Bagshaw MA: Total-skin electron treatment of mycosis fungoides. *Radiology* 100:145-150, 1971.
12. Fuks ZY, Bagshaw MA, Farber EM: Prognostic signs and the management of the mycosis fungoides. *Cancer* 32:1385-1395, 1973.
13. Tapley N duV: *Clinical Applications of the Electron Beam*. New York, John Wiley & Sons, 1976.
14. Grollman JH, Bierman SM, Ottoman RE, et al: Total-skin electron-beam therapy of lymphoma cutis and generalized psoriasis: Clinical experiences and adverse reactions. *Radiology* 87:908-915, 1966.
15. Chu FCH, Glicksman AS, Nickson JJ: Late consequences of early skin reactions. *Radiology* 94:669-672, 1970.
16. Page V, Gardner A, Karzmark CJ: Patient dosimetry in the electron treatment of large superficial lesions. *Radiology* 94:635-641, 1970.
17. Tapley N duV: Electron beam, in Fletcher GH (ed): *Textbook of Radiotherapy*, ed 2. Philadelphia, Lea & Febiger, 1973.
18. Fuks Z, Hoppe RT, Bagshaw MA: The role of total skin irradiation with electrons in the management of mycosis fungoides. *Bull Cancer*, to be published.

Epidermotropically Metastatic Malignant Melanoma

Differentiating Malignant Melanoma Metastatic to the Epidermis From Malignant Melanoma Primary in the Epidermis

Richard Kornberg, MD; Matthew Harris, MD; A. Bernard Ackerman, MD

• In four instances, metastases to epidermis from primary cutaneous malignant melanomas at different sites showed histological features similar to those of cutaneous malignant melanoma primary in the epidermis. In these metastases, atypical melanocytes were present within the epidermis and in the upper part of the dermis much as in primary cutaneous malignant melanoma. Therefore, the presence of atypical melanocytes within the epidermis is not in itself an absolute criterion of malignant melanoma primary in skin. Nor does that finding absolutely deny malignant melanoma metastastic to the skin. Features that may enable histologic differentiation of epidermotropically metastatic malignant melanoma from primary cutaneous malignant melanoma are emphasized.

(*Arch Dermatol* 114:67-69, 1978)

Accepted for publication July 6, 1977.

From the Department of Dermatology, University of California at San Diego (Dr Kornberg), and the Departments of Surgery (Dr Harris) and Dermatology and Pathology (Dr Ackerman), New York University.

Reprints not available.

The presence of atypical melanocytes within the epidermis, no matter how many within the dermis or subcutis, is usually considered to be a critical feature for the histologic diagnosis of malignant melanoma primary in the skin.[1-3] In reverse, the absence of atypical melanocytes within the epidermis and presence only in the dermis or the subcutis is taken to be characteristic of malignant melanoma metastatic to skin. The validity of these criteria for differentiating primary from metastatic malignant melanoma is challenged by findings in the following four cases.

REPORT OF CASES

CASE 1.—A 37-year-old woman had a pigmented spot on the palm of her right hand for as long as she could remember. Eight months prior to consultation, she had noted changes in the lesion. It had enlarged, turned in part from uniformly dark brown to gray, black, and red, developed a scab, and bled easily when traumatized.

The lesion was 1.4 × 1 cm in diameter, raised, mainly black with spots of gray and red, and peripherally brown on the right palm over the distal end of the second metacarpal. Enlarged lymph nodes were palpable in the right axilla. The cutaneous lesion was excised in toto and microscopic examination disclosed a malignant melanoma, superficial spreading type, level IV. Transmetacarpal amputation of the right index finger and radical dissection of the ipsolateral axillary lymph node were performed. Two of 29 lymph nodes showed metastatic malignant melanoma.

Fourteen months after the surgical procedure, several dark brown to black nodules appeared in the skin of the right breast (Fig 1 and 2). Histologic examination of three of these nodules revealed numerous atypical melanocytes within the epidermis and throughout the thickened papillary dermis (Fig 3 and 4). Those within the epidermis were individually scattered or gathered into nests, whereas those within the papillary dermis were grouped in nests that in some areas became confluent to form sheets of cells. Some atypical melanocytes were situated within the adnexal epithelium, acrosyringia of sweat ducts, and infundibula of hair follicles. The epidermal and dermal melanocytic nests varied considerably in size and shape. The nuclei of the neoplastic cells were large, hyperchromatic, and pleomorphic and the cytoplasm was abundant, pale-staining, and contained "dusty" granules of melanin. Occasional mitotic figures, some atypical, were present in both the epidermal and dermal melanocytes. Within the epidermis, atypical melanocytes were dispersed from the basal to the cornified layer, but they did not extend laterally beyond the region of their greatest aggregation within the dermis. The nests of atypical melanocytes in the uppermost dermis appeared to compress the overlying epidermis, thereby thinning the suprapapillary plates and widening the dermal papillae. The epidermal rete ridges to the sides of the neoplasm were elongated and turned toward each other. A large vascular space lined by endothelial cells was seen to be occluded by atypical melanocytes (Fig 5 and 6). Around the blood vessels of the superficial plexus, there was a moderately

Fig 1.—Papules and nodules of metastatic malignant melanoma. Primary malignant melanoma was on palm.

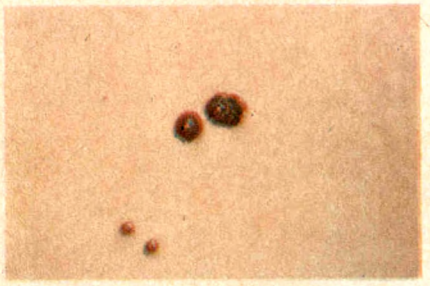

Fig 2.—Closer view of papules and nodules pictured in Fig 1.

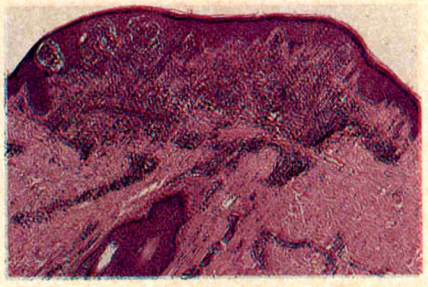

Fig 3.—Irregularly shaped nests of atypical melanocytes within epidermis and throughout upper part of dermis. Note slight inward turning of peripheral rete ridges, and superficial perivascular lymphohistiocytic infiltrate. Under scanning power, this lesion resembles primary malignant melanoma (hematoxylin-eosin, ×25).

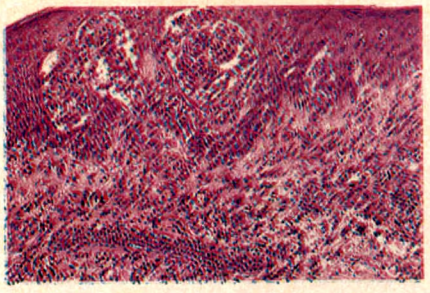

Fig 4.—In this higher-power view of Fig 3, atypical melanocytes can be seen not only within epidermis and papillary dermis, but in large, dilated lymphatic oriented almost parallel to the skin surface (hematoxylin-eosin, ×88).

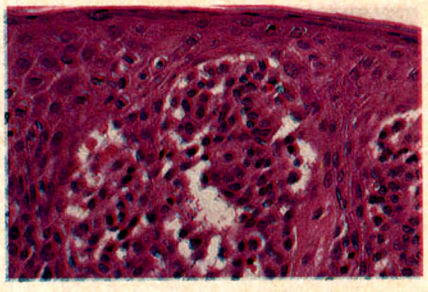

Fig 5.—Atypical melanocytes in irregularly shaped nests within epidermis very much resemble those usually associated with primary cutaneous malignant melanoma (hematoxylin-eosin, ×142).

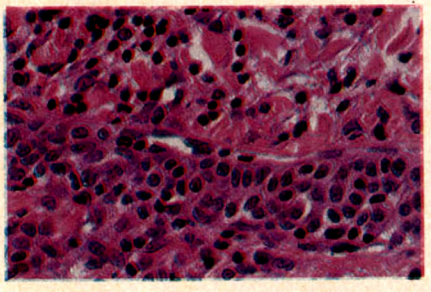

Fig 6.—Higher-power view of atypical melanocytes within dermal lymphatic (hematoxylin-eosin, ×160).

Case Summaries

Case/Age, yr/Sex	Site of Primary Melanoma	Type of Primary Melanoma*	Level of Primary Melanoma	Interval Between Histologic Diagnosis and Appearance of Metastases, mo
1/37/F	Hand	SSM	IV	14
2/23/M	Thigh	NM	IV	18
3/30/M	Suprapubic	SSM	III	9
4/69/M	Ankle	SSM	IV	Concurrent

*SSM indicates superficial spreading melanoma; NM, nodular melanoma.

dense predominantly lymphocytic infiltrate.

The data on patients 2, 3, and 4 are presented in the Table.

COMMENT

The junctional or compound melanocytic nevi contain collections of melanocytes within the epidermis that are relatively uniform in size and shape. In contrast, primary cutaneous malignant melanoma is characterized by nests of atypical melanocytes within the epidermis that vary significantly in size and shape, as well as by solitary atypical melanocytes scattered irregularly above the basal-cell zone. Allen and Spitz[1] stated that the presence of "junctional activity," ie, atypical melanocytes at the dermoepidermal junction, is the decisive histologic feature for the diagnosis of primary cutaneous malignant melanoma. Of equal importance to them is the absence of this feature in the lesions of malignant melanoma metastatic to skin. This view is shared by most general pathologists and dermatopathologists. We are familiar with only one allusion to epidermotropically metastatic malignant melanoma (EMMM), that by McGovern[4] in an illustration.

Each of the four cases of metastatic malignant melanoma to skin herein presented had nests of atypical melanocytes within the epidermis as well as within the dermis. At first glance, it would seem difficult to discern histologic differences between EMMM and primary cutaneous malignant melanoma of the nodular or superficial spreading types. Careful study of specimens from our four cases of EMMM enabled us to formulate criteria for differentiation of primary cutaneous malignant melanoma from metastases to the skin that appear similar.

All primary malignant melanomas in skin are characterized, in part, by the extension of atypical melanocytes within the epidermis beyond the region of main concentration of atypical melanocytes within the dermis. This is especially true of the superficial spreading and lentigo maligna types, but also of the nodular type, even if less prominently. One of the important histologic features differentiating EMMM from superficial spreading malignant melanoma is the absence of atypical melanocytes extending horizontally within the epidermis beyond the principal concentration of the metastasis in the dermis. Unlike nodular malignant melanoma, which is also characterized by little lateral spread of intraepidermal atypical melanocytes, EMMM in our cases was confined to the papillary dermis, whereas malignant melanoma that is considered to be nodular either completely fills the papillary dermis or extends into the reticular dermis. Furthermore, malignant melanoma generally lacks a collarette of epidermis so often found in EMMM. Lastly, neither superficial spreading malignant melanoma nor nodular melanoma have collections of atypical melanocytes within vascular lumina in the upper part of the dermis as may on occasion be seen in EMMM.

Thus, the microscopic features that favor the diagnosis of EMMM, rather than primary cutaneous malignant melanoma, are (1) thinning of the epidermis by aggregates of atypical melanocytes within the dermis, often associated with widening of dermal papillae and elongation of inward turning rete ridges at the periphery of the specimen; (2) atypical melanocytes within intradermal endothelial-lined spaces, and (3) a zone of atypical melanocytes within the dermis equal to or broader than that within the epidermis.

There are analogies to EMMM in other malignant neoplasms in the skin such as epidermotropic carcinoma,[5] pagetoid reticulosis (a variant of mycosis fungoides),[6,7] and Paget's disease. Why and how some malignant cells foreign to the epidermis are attracted to it and replicate within it is unknown.

Metastatic malignant melanoma to skin usually spares the epidermis, involving either the dermis, the subcutis, or both. Rarely, malignant melanoma metastasizes to the epidermis, and then the condition must be differentiated from primary cutaneous malignant melanoma of either the superficial spreading or nodular types, which may be done by observing the features just enumerated above.

The criteria for histologic differentiation of EMMM and primary cutaneous malignant melanoma are especially important vis-à-vis the problem of multiple primary malignant melanomas. Surely the therapeutic problem is not academic; new lesions, primary or metastatic, require very different oncologic management.

References

1. Allen AC, Spitz S: Malignant melanoma: A clinicopathological analysis of the criteria for diagnosis and prognosis. *Cancer* 6:1-45, 1953.
2. McGovern VJ, Mihm MD, Baily C, et al: The classification of malignant melanoma and its histological reporting. *Cancer* 32:1446-1457, 1973.
3. Price N, Rywlin A, Ackerman AB: Criteria for histologic diagnosis of primary cutaneous superficial spreading melanoma: Formulated on the basis of metastatically proven lesions. *Cancer* 38:2434-2441, 1976.
4. McGovern VJ: *Malignant Melanoma: Clinical and Histological Diagnosis.* New York, John Wiley & Sons Inc, 1976.
5. Pinkus H, Mehrigan A: Epidermotropic eccrine carcinoma. *Arch Dermatol* 88:597-604, 1963.
6. Braun-Falco O, Marghescu S, Wolff UH: Pagetoide reticulosis Morbus Woringer-Kolopp. *Der Hautargt* 24:11-21, 1973.
7. Woringer MMF, Kolopp P: Lesion erythematosquameuse polycyclique de l'avant-bras evolvant depuis six ans chez un garconnet de 13 ans: Histologiquement infiltrat intraepidermique d'apparance tumorale. *Ann Dermatol* 10:945-958, 1939-1940.

Cutaneous Ciliated Cysts

Evan R. Farmer, MD, Elson B. Helwig, MD

• We studied 11 patients with a cutaneous cyst lined by a simple columnar ciliated epithelium. All of the patients were women in the second or third decade of life. Each had only a single lesion, located on the lower extremity. Clinical examination showed a cyst without specific identifying characteristics.

The cyst is considered benign, because of the high degree of differentiation and lack of cellular atypia. The origin of the cyst is unknown. We favor the theory of sequestration and migration over that of transplantation or metaplasia.

(*Arch Dermatol* 114:70-73, 1978)

Cysts occurring in the skin are a common finding. They usually fall into several easily recognizable and well-defined categories.[1] Occasional lesions, however, present unusual features that do not fit these previously established criteria. Columnar ciliated epithelium lining the cyst cavity is one such feature. In this article, we present the clinical and pathologic findings in 11 patients with this unique epithelium lining their cutaneous cysts.

MATERIALS AND METHODS

A total of 11 cases of cutaneous cystic lesions lined by ciliated epithelium were available for study from the files of the Armed Forces Institute of Pathology (AFIP). The cases were submitted from civilian and military sources. The geographic distribution included the continental United States, Canada, and Australia. A brief history was available with each case.

All sections were stained with hematoxylin-eosin. Four cases were further studied with the following special stains: Fontana-Masson, Warthin-Starry at pH 3.3, Perls stain for iron, Mayer mucicarmine, PAS with and without diastase digestion, Rinehart and Abul-Haj's modification of Hale's colloidal iron technique with and without testicular hyaluronidase digestion, aldehyde-fuchsin at pH 1.7 and 1.0, alcian blue at pH 2.5 and 0.4, Movat pentachrome, Giemsa, and Mallory phosphotungstic acid-hematoxylin.[2]

RESULTS

Clinical Data

All 11 of our patients were women. Race was specified in four cases. Three were white, and one was black. The age of the patient at the time of excision was stated in ten cases. It ranged from 15 to 30 years, with an average of 22 years.

Each patient had only a single lesion, generally located on the lower extremity. The specific sites involved were the buttock (one case), thigh (four), calf (four), and foot (two). Neither the right nor the left side of the body seemed to predominate. Duration was recorded in five cases and varied from several weeks to five years. Preceding trauma was noted in two patients. This association even in these two patients was tenuous at best.

The lesion was measured prior to excision in only one case and was 7 × 5.8 × 3 cm. Otherwise, the size was stated to be small. Clinically, it was diagnosed as a cyst (eight cases), ganglion (one), or lipoma (one). The surface overlying the lesion was described in one case and noted to be dome-shaped. No mention of color was made.

The patients reported an array of symptoms. These included pain (one case), painless (one), enlargement (three), pulling sensation (one), spontaneous drainage (two), and infection (one). In five cases no symptoms were given.

All patients were stated to be in good health, and no associated diseases or tumors were noted. One patient became pregnant before her lesion was excised. There was no clinical change in the lesion during or after pregnancy. Each lesion was treated by excision.

Pathologic Findings

Gross Findings.—Size of the gross specimen was given in eight cases, but the actual diameter of the cyst was noted in only three: 2, 1.6, and 2 cm, respectively. The cyst was described as firm to rubbery and gray or grayish-white. The contents were amber to clear and watery.

Histopathologic Findings.—The cyst was located in the subcutaneous tissue in seven cases and in the deep dermis in four. In the latter situation it usually extended into the underlying fat.

No definite capsule surrounded the lesion. The surrounding collagen appeared dense in four cases, as if compressed by an expanding process. The configuration was unilocular in two and multilocular in nine cases (Fig 1). Papillary projections into the lumen as shown by multiple sections were common (Fig 2). The cavity was uniformly empty except for an occasional normal-appearing erythrocyte.

The lumen was lined by a simple cuboidal to columnar ciliated epithelium (Fig 3 and 4). Focal areas of pseudostratified ciliated epithelium were found in ten cases. Three cysts also contained foci of squamous meta-

Accepted for publication Sept 8, 1977.

From the Department of Skin and Gastrointestinal Pathology, Armed Forces Institute of Pathology, Washington, DC.

The opinions and assertions contained herein are the private views of the authors and are not to be construed as official or as reflecting the views of the Department of the Army or the Department of Defense.

Reprint requests to Armed Forces Institute of Pathology, Washington, DC 20306 (Dr Helwig).

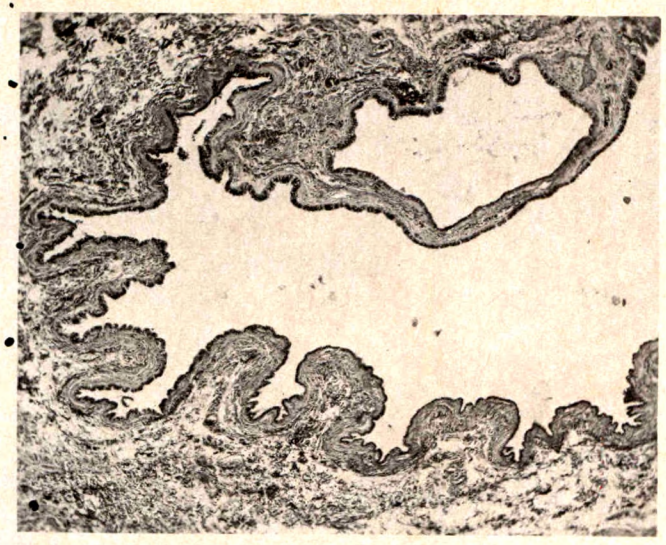

Fig 1.—Multilocular configuration of the cyst and papillary projections into the lumen (AFIP Neg 77-4165; hematoxylin-eosin, ×50).

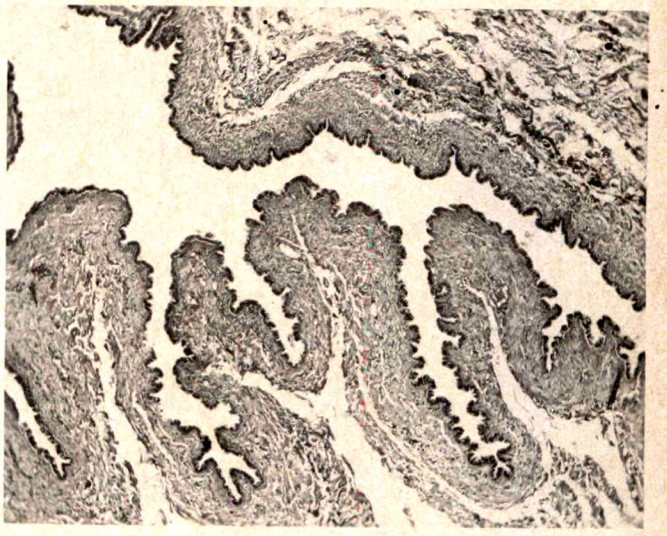

Fig 2.—Well-developed papillary projections into the lumen of the cyst (AFIP Neg 77-4164; hematoxylin-eosin, ×55).

plasia (Fig 5). The individual ciliated cell had an oval or round nucleus located in the center or toward the base. Nuclear chromatin was homogeneous, and an occasional small nucleolus was present. Perinuclear halos or clear spaces were frequently observed. No atypia or mitotic figures were seen.

The tissue surrounding each cyst was free of skin appendages, glandular elements, and smooth or striated muscle. A focal structure resembling a milium was observed in the connective tissue within one papillary projection. No connection with the lumen was noted.

The overlying epidermis, when included with the specimen, was essentially normal. The dermis in three cases was normal. In one case the dermis was sclerotic and had thick bundles of collagen. An inflammatory infiltrate consisting of lymphocytes and histiocytes was sparse and focal in distribution and occurred in only two cases. One case, however, did show partial replacement of the cyst wall by granulation tissue. This particular lesion had been traumatized several months before excision, according to the history.

The contributing pathologists specifically noted the presence of cilia in 9 of the 11 cases.

Histochemical Findings.—There was minimal variance in the histochemical reactions among the four cases receiving special staining. The region of the basal body beneath the cilia stained positively with the following stains: mucicarmine, colloidal iron with and without hyaluronidase digestion, aldehydefuchsin at pH 1.7 and 1.0, and alcian blue at pH 2.5 and 0.4. These reactions are consistent with the presence of a sulfated acid mucosaccharide. None of this material was noted elsewhere in the cytoplasm or in the lumen. PAS with diastase was negative in the region of the basal body. Occasional glycogen granules were present in the cells, as shown by the PAS reaction. A PAS-positive diastase-resistant basement membrane was present below the epithelial cells. No melanin or iron was demonstrated.

COMMENT

Reports of similar cases in the literature are sparse. Hess, in 1890,[3] presented the case of a 15-year-old girl with a walnut-sized cyst of recent onset. It was located on her back in the vicinity of the fourth or fifth thoracic vertebra. Prior to excision, the lesion was traumatized with knitting needles. Microscopically, it was described as a subcutaneous unilocular cyst not connected to the underlying structures. A capsule surrounded the lesion. No muscle bundles were noted in the wall. The lumen was lined by a simple columnar ciliated epithelium with 3 to 12 cilia per cell. The cavity contained erythrocytes and WBCs. The latter finding was interpreted to be secondary to the prior trauma.

Clark, in 1969,[4] reported a case of a 39-year-old woman with at least a ten-year history of a cystic lesion involving the left thigh. He described it grossly as a multilocular cyst containing clear, watery fluid. The lumen was lined by a simple columnar ciliated epithelium. No mucin-secreting cells or muscle bundles were observed. With electron microscopy, he was able to document the characteristic pattern of cilia: two central filaments encircled by nine pairs of filaments.

Our cases were similar to those previously reported. All of our patients were women. First awareness of the lesion was in the second or third decade of life. It is most likely that each patient was postmenarcheal, although this was not specifically stated in the available histories. The lesion was single and located on the lower extremity. Generally, it was multilocular, although a unilocular configuration was occasionally observed. The contents were clear and watery. Microscopically, the characteristic feature was the simple columnar ciliated epithelial lining. Focal areas of squamous metaplasia and pseudostratified columnar epithelium were also seen. Papillary projections into the lumen were quite frequent. No evidence of mucin-secreting cells was observed. No muscle bundles or other structures were noted in the cyst wall. The lesion is considered to be benign on the basis of differentiation and lack of atypia.

There were no distinguishing clinical features to allow the diagnosis to be made prior to excision. Pregnancy had no effect on the cyst. No associated diseases or tumors were observed.

The epithelial lining of the cysts resembles that seen in the Fallopian tube. Ciliated columnar epithelium without mucin-secreting cells is the linking element. Simple columnar cil-

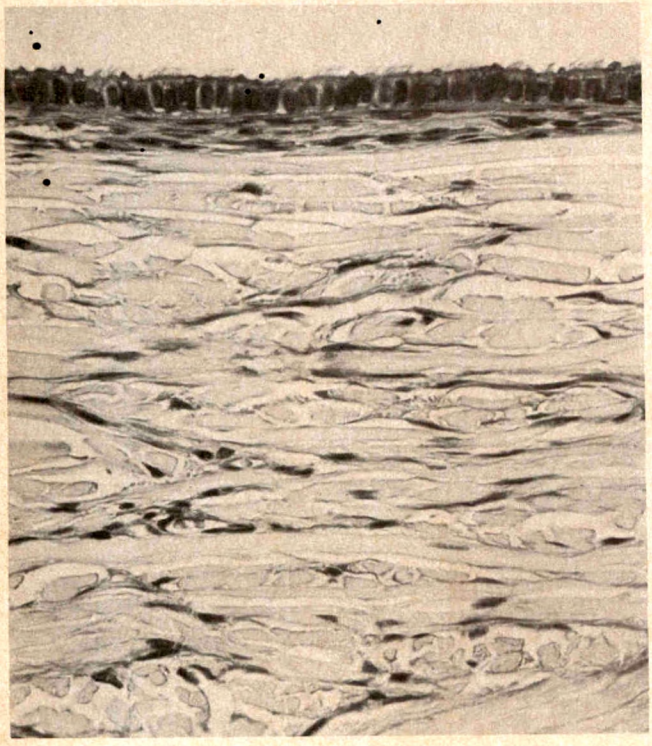

Fig 3.—Simple columnar ciliated epithelium lines the wall of the cyst. Appendageal structures and muscle bundles are not seen in the adjacent connective tissue (AFIP Neg 77-4166; mucicarmine, ×300).

Fig 4.—High-power magnification of the epithelium confirms the presence of the cilia (AFIP Neg 77-4767; mucicarmine, ×1,550).

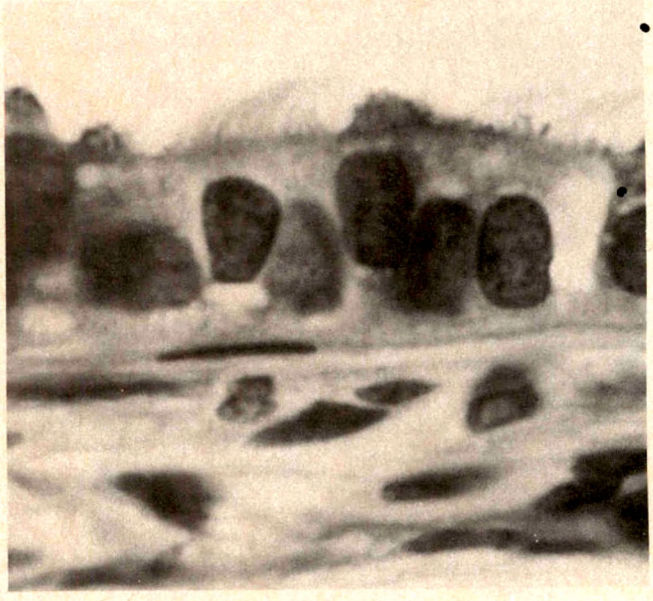

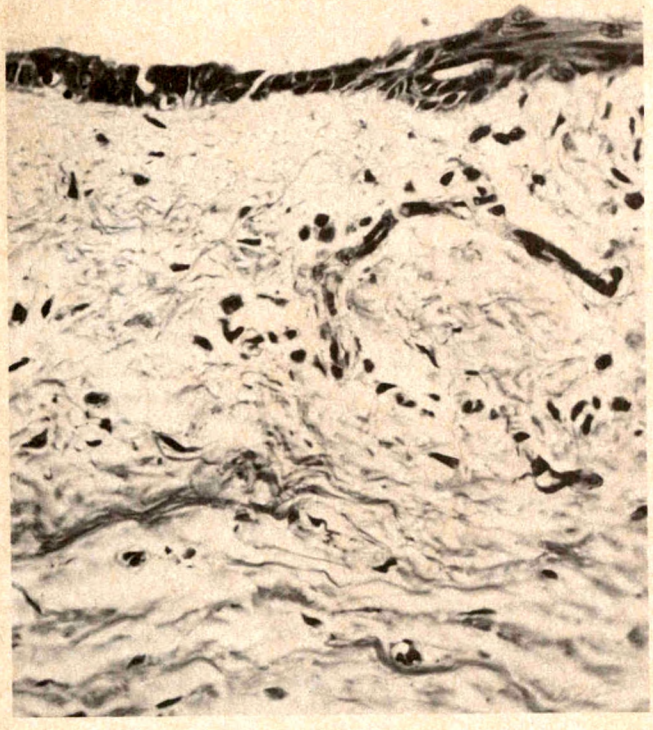

Fig 5.—This region of the wall shows squamous metaplasia adjacent to columnar ciliated epithelium (AFIP Neg 77-4161; hematoxylin-eosin, ×300).

iated epithelium is also found in the uterus, small bronchi, paranasal sinuses, and central canal of the spinal cord. The digestive tract and excretory ducts of glands contain a simple columnar epithelium without cilia.[5] Ciliated cysts have been reported to occur elsewhere in the body, including the esophagus,[6] stomach,[7] heart,[8] tail-gut,[9] and periureteral lymph node.[10] Each example, with the possible exception of the lymph node, was considered to be on the basis of a developmental defect.

Electron microscopic studies have shown occasional cilia in human embryonic sweat duct cells[11] and isolated flagella in normal basal cells of human epidermis.[12] Organization of the cells toward a simple columnar ciliated epithelium was not observed. In addition, the filament pattern in one study[11] was shown to be of the nine plus zero type, in contrast to Clark's findings in his case.[4]

Other cutaneous cysts are readily separated from this lesion on the basis

of the epithelial lining and other structures included in the cyst wall. Epidermal inclusion cysts show a stratified squamous epithelium with maturation through a granular cell layer. Pilar or tricholemmal cysts show a similar stratified squamous epithelium, but the keratin is formed by abrupt transition without an interposing granular cell layer. The cyst in steatocystoma multiplex has a stratified squamous epithelial lining and sebaceous glands within or adjacent to the cyst wall. Dermoid cysts are lined by a normally maturing stratified squamous epithelium and contain various well-developed epidermal appendages in the wall.[1] In tailgut cysts, the finding of mucin-secreting cells in the lining and smooth muscle bundles in the wall are helpful differentiating features.[9]

We propose the term "cutaneous ciliated cyst" for this entity. The cutaneous designation was chosen because the cyst could be located in either the dermis or the subcutaneous tissue. "Cilia" should be in the name, since this is the principal differentiating feature. We did not feel that the term chosen should limit the cyst to a particular location, even though all of our cases were on the lower extremity. Hess's case was located on the upper part of the back.[3]

The origin of this cyst is open to speculation. We have considered errors of embryonic development, transplantation, and metaplasia as possibilities. Sequestration of tissue or parts of organs from their normal location, that is, heterotopia, can occur during embryogenesis. Cysts found in the heart[8] or within the wall of the stomach[7] with an epithelial lining identical to the gastrointestinal tract are probable examples of this phenomenon. The epithelium of our cyst is quite similar to that of Müllerian duct structures, but it is difficult to explain how it would be able to occur on the extremities by sequestration during embryonic life in an otherwise normal person. Fraga et al,[13] in their study on bronchogenic cysts in the skin and subcutaneous tissue, observed four cases of typical bronchogenic cysts occurring on the shoulder some distance from their usual location. They postulated the mechanism of sequestration followed by migration to explain this phenomenon. Many structures form early in embryonic life, only to regress or be transformed with later development. An example is the caudal end of the gut, known as the tailgut.[9] Failure of regression at this location can result in cyst formation. Organs or structures with columnar ciliated epithelium are not known to occur on the extremities during embryonic life, thus making failure of regression or transformation unlikely as an explanation.

Transplantation of tissue may occur by the hematogenous route, the lymphatic route, or external manipulation. We cannot rule out the first two modes by our observations. If transplantation by the lymphatic route had occurred, we would have expected to find some of the lesions within a lymph node. This was not the situation. Two of our patients recalled preceding trauma to the site of the lesion. In each case, the direct association between the trauma and the appearance of the lesion was tenuous. The lack of a history of trauma in the remaining nine patients makes this possibility less likely. Endometriosis should be considered as a possible model, since all of our patients were postmenarcheal, and the epithelial lining of the cyst resembles the Fallopian tube. Steck and Helwig,[14] in their study of cutaneous endometriosis, noted the frequent occurrence of lesions in physiologic scars such as the umbilicus and in surgical scars. They questioned transplantation as the sole determinant and raised the possibility of local factors in scar tissue allowing or enhancing growth of heterotopic tissue. The site of all of the lesions they reported was confined to the abdomen or pelvic region, in contrast to that of our cases. The lack of surgical or other trauma and the location of the lesion decrease the applicability of the comparison between cutaneous ciliated cysts and cutaneous endometriosis.

Metaplasia of a previously existing lesion is difficult to prove or disprove. Part of the normal structure or organ from which the lesion derives would have to be found contiguous to the cyst. Otherwise, there is no conclusive evidence. We did not see any appendageal organs in direct apposition with the ciliated cysts. Three of our patients did show foci of squamous epithelium, raising the question of a preexisting epidermal inclusion cyst, but we are interpreting this finding as a metaplasia of the ciliated epithelium and not a metaplasia in the other direction.

Having exhausted the various hypotheses, we still do not know the cause of these cutaneous ciliated cysts. We favor the theory of sequestration and migration over the other possibilities discussed. Perhaps recognition of this lesion in other patients will provide the needed clues.

References

1. Hackney VC: Epithelial cysts of the skin, in Graham JH, Johnson WC, Helwig EB (eds): *Dermal Pathology*. Hagerstown, Md, Harper & Row Publishers Inc, 1972, pp 497-502.
2. Luna LG (ed): *Manual of Histological and Special Staining Methods of the Armed Forces Institute of Pathology*, ed 3. New York, McGraw-Hill Book Co Inc, 1968.
3. Hess K: Ueber cine subcutane flimmercyste. *Beitr Pathol* 8:98-109, 1890.
4. Clark JV: Ciliated epithelium in a cyst of the lower limb. *J Pathol* 98:289-291, 1969.
5. Bloom W, Fawcett DW (eds): *A Textbook of Histology*. Philadelphia, WB Saunders Co, 1975, pp 83-107.
6. Bjork VO, Fors B, Lodin H: Ciliated epithelial cyst of the oesophagus. *Acta Chir Scand* 245(suppl):151-156, 1959.
7. Gensler S, Seidenberg B, Rifkin H, et al: Ciliated lined intramural cyst of the stomach. *Ann Surg* 163:954-956, 1966.
8. De Lacroix WF, Hubner G: Ciliated epithelial inclusion cyst of the heart. *Beitr Pathol* 151:103-110, 1974.
9. Gius JA, Stout AP: Perianal cysts of vestigial origin. *Arch Surg* 37:268-287, 1938.
10. Ferguson BR, Bennington JL, Haber SL: Histochemistry of mucosubstances and histology of mixed Mullerian pelvic lymph node glandular inclusions. *Obstet Gynecol* 33:617-625, 1969.
11. Hashimoto K, Gross BG, Lever WF: The ultrastructure of the skin of human embryos. *J Invest Dermatol* 46:513-529, 1966.
12. Wilson RB, McWhorter CA: Isolated flagella in human skin. *Lab Invest* 12:242-249, 1963.
13. Fraga S, Helwig EB, Rosen SH: Bronchogenic cysts in the skin and subcutaneous tissue. *Am J Clin Pathol* 56:230-238, 1971.
14. Steck WD, Helwig EB: Cutaneous endometriosis. *JAMA* 191:167-170, 1965.

Clinical Syndrome of Chemotaxis Defect, Infections, and Hyperimmunoglobulinemia E

A Case Report

Lt Comdr Harry W. Wyre, Jr, MC, USNR, Capt W. Taylor Johnson, MC, USN

• A 17-year-old black girl had a clinical syndrome that consisted of neutrophil chemotaxis defect, recurrent bacterial infections, and hyperimmunoglobulinemia E. Neutrophil chemotaxis was quantitated by a radioassay technique that used ^{51}Cr-labeled neutrophils and a double micropore filter chemotaxis chamber. A table of the features of other cases of this syndrome is presented. Since ten of the 13 patients who are described had a chronic eczematoid dermatitis, we suggest that this may be a fourth feature of this syndrome. Red hair and fair skin were not consistent findings in these patients. In the evaluation of patients with chronic, recurrent bacterial infections of the skin of undetermined origin, we recommend determination of serum IgE levels. If IgE is found to be elevated, one should consider the presence of this syndrome, and neutrophil chemotaxis should then be examined.

(*Arch Dermatol* 114:74-77, 1978)

During the past few years, the interest in a group of children and young adults with chronic and recurrent pyodermatous lesions who have had a defect in the chemotaxis of the neutrophilic granulocytes and who also have had an associated dramatic elevation of the serum immunoglobulin E has increased.

Prior to 1975, no report of this triad of findings appeared in the dermatologic literature to our knowledge. In December 1975, Dahl et al[1] reported the case of a 7-year-old girl with recurrent infections of the skin, defective neutrophil chemotaxis, and hyperimmunoglobulinemia E. In this case there were the associated findings of incontinentia pigmenti and erythema multiforme.

We describe another patient with this unusual triad of findings and call the attention of the dermatologist to this syndrome in patients with chronic or recurrent infections of the skin.

REPORT OF A CASE

A 17-year-old black girl was admitted to the National Naval Medical Center, Bethesda, Md, in September 1974 at the age of 15 years. She was hospitalized for evaluation of chronic skin and eye infections that had occurred since the age of 3 years. These bacterial infections had been superficial, except for pneumonia in 1966, which was complicated by an empyema and required a thoracotomy for drainage. The bacterial infections had been generalized, but appeared to the worse extent on the face. There was no history of any other chronic mucocutaneous problems, and neither was there a family history of similar symptoms. The patient's parents and three sisters were in good health and had no susceptibility to infections. Notable past history included anemia that was a result of chronic infection.

Results of physical examination revealed the following findings: a sharp decrease in visual acuity that was secondary to bilateral corneal opacifications, and moderate photophobia; a scar over the right lateral thorax; numerous inflammatory pustules and papules, which were present primarily on the face but also on the thorax and on all extremities (Fig 1); and firm papules and nodules with hyperpigmentation, which were present primarily over the extremities, the largest being 2 × 3 cm. Results of the remainder of the physical examination were normal.

Results of laboratory examination revealed the following values: hemoglobin, 9.2 gm/100 ml (normal, 12 to 16 gm/100 ml); hematocrit, 28.3% (normal, 37% to 47%); WBC count, 8,200/cu mm, with 57% neutrophils, 32% lymphocytes, 8% monocytes, 1% basophils, and 2% eosinophils; platelets, 400,000/cu mm (normal, 150,000 to 450,000/cu mm); reticulocyte count, 0.9% (normal, 0.5% to 1.5%); and the ESR was 78 mm/hr (normal, 0 to 20 mm/hr). On peripheral smear, the erythrocytes were microcytic and hypochromic, and the leukocytes were normal, with no giant lysosomal inclusions noted. The level of serum iron was 25 mg/100 ml (normal, 40 to 130 mg/100 ml); the serum transferrin level was 250 mg/100 ml (normal, 200 to 400 mg/100 ml); glucose-6-phosphate dehydrogenase value, normal; sickle cell preparation, negative; direct and indirect Coombs' tests, negative. Bone marrow aspiration revealed stainable iron in adequate amounts. Serum electrolytes and renal and hepatic functions were all within normal limits. Serum protein electrophoresis showed hypergammaglobulinemia with the following values: total proteins, 9.2 gm/100 ml; albumin, 4.01 gm/100 ml; α_1-globulin, 0.25 gm/100 ml; α_2-globulin, 0.87 mg/100 ml; β-globulin, 1.43 gm/100 ml; and γ-globulin, 2.64 gm/100 ml. Immunoglobulin electrophoresis revealed

Accepted for publication Dec 27, 1976.

From the Department of Dermatology, National Naval Medical Center, Bethesda, Md.

The opinions expressed are those of the authors and are not necessarily those of the Department of the Navy or the Department of Defense.

Reprints not available.

the following values: IgG, 3,400 mg/100 ml (normal, 825 to 1,075 mg/100 ml); IgA, 1,700 mg/100 ml (normal, 80 to 210 mg/100 ml); IgM, 90 mg/100 ml (normal, 59 to 150 mg/100 ml); and IgE, 2,400 ng/ml (normal, 50 to 500 ng/ml).

Isohemagglutinin anti-A and anti-B titers were both 1:16. The antistreptolysin O (ASO) titer was less than 200 Todd units. The results of the test for antinuclear antibody (ANA) were negative. The mumps skin test (0.1 ml injected intradermally) was positive at 48 hours (14 mm of induration); however, the intermediate purified protein derivative (0.1 ml injected intradermally), *Candida* (0.1 ml injected intradermally), *Trichophyton* (0.1 ml injected intradermally), and streptokinase-streptodornase (SK-SD) (Varidase, 0.1 ml of 1:500 injected intradermally) skin tests were negative. Lymphoblast transformation[2] revealed that the patient's response to nonspecific mitogens as well as to the antigens tested (tetanus toxoid, SK-SD, and *Candida*) was normal. The percentage of T-lymphocytes, tested by E rosettes (sheep erythrocytes)[2], was below normal (39%, with normal control of 57%), and the percentage of B-lymphocytes, tested by EAC rosettes (sheep erythrocyte-antibody-complement)[2], was normal (23%, with normal control of 26%). Bacterial cultures from various cutaneous lesions at different times were positive for *Staphylococcus aureus*, *S epidermis*, *Escherichia coli*, and γ streptococcus. Chest roentgenograms showed blunting of the right costophrenic angle with pleural thickening at the right lung base, but no active pulmonary disease was present. The nitroblue tetrazolium test was normal. Evaluation of phagocytosis and killing of *S aureus* by neutrophils, using the method of Root et al,[3] revealed no abnormalities.

CHEMOTAXIS EVALUATION

Neutrophil chemotaxis was quantitated using a previously described radioassay that used ^{51}Cr-labeled neutrophils and a double micropore filter chemotaxis chamber.[4] The leukocytes were separated from heparinized blood by dextran sedimentation. These leukocytes were then labeled with ^{51}Cr, and they were suspended at a concentration of 2.3×10^6 neutrophils per milliliter in Gey's medium. The labeled leukocytes were placed in the upper compartment of a modified Boyden's chamber that was separated from the lower compartment by two 3-mμ micropore filters. The chemotactic stimulus was added to the lower compartment, and the amount of radioactivity that was incorporated into the lower filter was evaluated at the end of 1, 2, and 3 hours. The number of migrating neutrophils was proportional to the measured radioactivity and this was quantitated as corrected counts per minute lower filter (cor cpm LF). The results were the means of multiple determinations. There was no abnormality in the ability of the patient's serum to generate chemotactic factors when activated with *E Coli* endotoxin, and there was no inhibition of normal leukocyte migration by the patient's serum. Cell adherence to nylon wool and migration in response to buffer (random migration) were normal. However, a prominent defect of directed migration (chemotaxis) of the patient's neutrophils was noted throughout three hours of in vitro study. The patient's neutrophil chemotaxis was 18% of normal after one hour (80 ± 12 cor cpm LF, control was 434 ± 75 cor cpm LF), 16% of

Fig 1.—Left, Frontal facial view showing inflammatory papules and pustules. Right, Lateral facial view showing inflammatory papules and pustules.

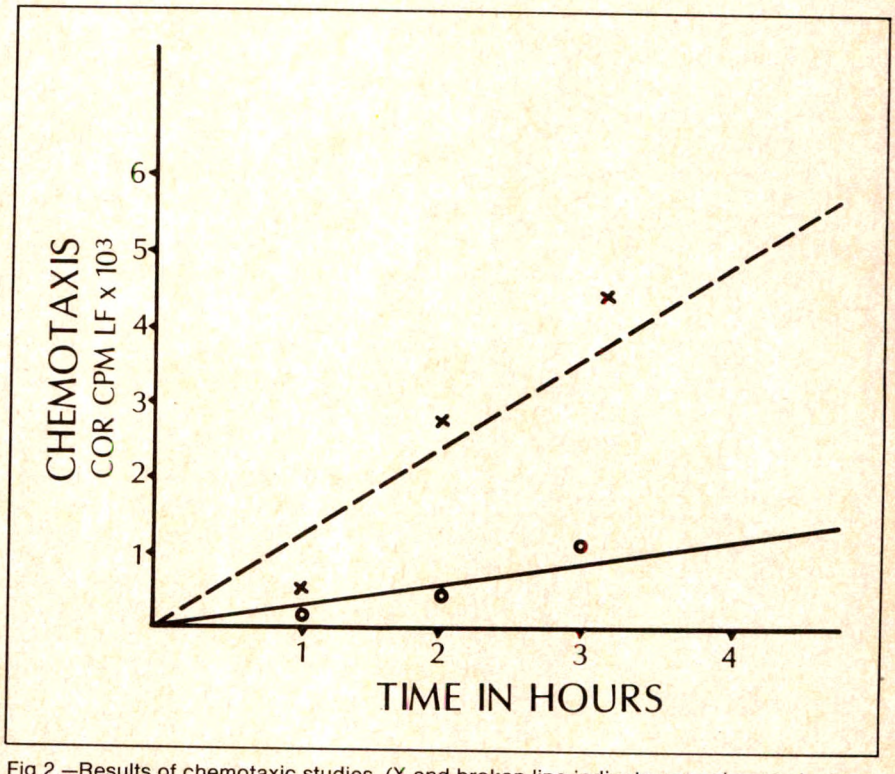

Fig 2.—Results of chemotaxic studies. (X and broken line indicate normal control; circle and solid line indicate patient; cor cpm LF indicates corrected counts per minute lower filter.)

Cases With Neutrophil Chemotactic Defect, Bacterial Infections, and Hyperimmunoglobulinemia E

Source	Case/Age, yr/Sex/Race*	IgE Levels	Cutaneous Manifestations: Bacterial Infections	Cutaneous Manifestations: Hair Color	Cutaneous Manifestations: Other	Systemic Manifestations
Clark et al[22]	1/11/F/W	19,000-44,000 ng/ml (normal, 5-2,045 ng/ml)	Yes	...	"Chronic papular dermatitis," chronic mucocutaneous candidiasis	Otitis media, bronchitis, pneumonia, lymph node abscesses
Hill and Quie[13]	2/2/F/W	10,000 IU/100 ml (normal, 30-99 IU/100 ml)	Yes	...	Atopic dermatitis	None
	3/2/M/W	2,500 IU/100 ml	Yes	...	Eczema (probable atopic dermatitis)	None
	4/1½/M/I	5,780 IU/100 ml	Yes	...	Eczema	Pneumonia
Hill et al[23]	5/17/F/...	7,300 IU/ml (normal, 0-440 IU/ml)	Yes	Red	Chronic eczema	Otitis media, pneumonia
	6/14/F/...	19,500 IU/ml	Yes	Red	Chronic eczema	Otitis media, pneumonia
	7/15/F/...	15,000 IU/ml	Yes	Red	Chronic eczema	Otitis media, pneumonia
	8/4/F/...	6,020 IU/ml	Yes	Light brown	Chronic eczema	Otitis media, pneumonia
Van Scoy et al[24]	9/20/F/W	38,667 ng/ml (normal, 6-780 ng/ml)	Yes	Brown	Atopic dermatitis	Otitis media, bronchitis, pneumonia, retropharyngeal abscess
	10/1/F/W	40,009 ng/ml	Yes	Red	Chronic "rash"	Adenitis
Pincus et al[25]	11/4½/M/O	3,500 and 6,980 IU/ml (normal, 100 IU/ml)	Yes	...	Alopecia, diffuse hyperkeratosis (variant ichthyosis)	Otitis media, with externa, bacterial ophthalmitis, dental abcesses
Dahl et al[1]	12/7/F/W	10,500 IU (normal, 300-700 IU)	Yes	Dark (from photo)	Incontinenti pigmenti, chronic erythema	Bronchitis, otitis media, upper respiratory tract infections, pneumonia
Present case	13/17/F/B	2,400 ng/ml (normal, 50-500 ng/ml)	Yes	Black	None	Pneumonia with empyema

*W indicates white; I, Indian; O, Oriental; B, black.

normal after two hours (450 ± 52 cor cpm LF, control was 2,758 ± 394 cor cpm LF), and 27% of normal after three hours (1,181 ± 187 cor cpm LF, control was 4,419 ± 158 cor cpm LF). The results of these studies are presented in Fig 2. This neutrophil chemotaxis defect had been consistently abnormal during numerous studies since the patient's initial evaluation.

COMMENT

Movement of leukocytes has been divided into two phases: (1) random migration, which is inherent cell movement, requires no stimuli, and has no specific direction, and (2) chemotaxis. Chemotaxis has been defined as directional cell movement in response to various humoral stimuli that are termed chemotactic factors. Directional movement of leukocytes must depend not only on the presence of these chemotactic factors, but also on cellular recognition of these stimuli and reaction to them. A deficiency in either of these conditions may result in defective chemotaxis.[5]

The movement of leukocytes has been estimated by Rebuck's skin window technique and, quantitatively, by Boyden's chamber technique.[6,7] Substances such as endotoxin (lipid A), antigen-antibody complexes, neutrophil and macrophage enzymes, and products of virus-infected tissue have been reported to activate the chemotactic factors.[8,9] These chemotactic factors are derived from the complement system (both classical and alternative pathways), the fibrinolytic system, and the kinin-generating system. Of these systems, the complement system has been most studied, and C3a, C5a, and the trimolecular complex C567 have been identified as the chemotactic factors in this system. The fifth component of complement (C5a) is the major neutrophil chemotactic factor of the complement system.[10,11] The precise molecular structure of the chemotactic factors and their mechanism of action is still under study.

With the development of suitable tests for study of leukocyte chemotaxis has come the identification of a number of diseases in which abnormal chemotaxis and an increased incidence of bacterial infections are seen.[12] The recurrent bacterial infections that are seen in these patients may well be related to an abnormality in chemotaxis, but this has not been definitely proved.[13] Most of the reports in the literature indicate that chemotactic defects are restricted to abnormalities of a single cell line, but this may just represent the lack of study of both the granulocyte and the mononuclear cell types.[12]

The coexistence of defective chemotaxis and elevated levels of serum IgE has led to investigations that attempt

to relate the chemotactic defect to this immunoglobulin. The serum or plasma of patients with hyperimmunoglobulinemia E did not alter the chemotaxis of normal control leukocytes. The washing of the patient's leukocytes and the resuspension of the leukocytes in normal serum did not restore normal chemotaxis.[14] Based on these observations, we believe that the decreased chemotactic response was not related to a direct effect of the increased concentration of IgE in the plasma. Furthermore, increased levels of IgE have been found in various clinical conditions, such as atopic dermatitis,[15-17] parasitic infections,[18,19] and chronic acral dermatitis,[20] in which no demonstrable chemotaxis defect has been reported and in which recurrent pyodermas are not necessarily present. At this point the interrelationship of serum IgE, defective neutrophil chemotaxis, and recurrent infections is unresolved.

In 1966, Davis et al[21] described two patients with recurrent "cold" staphylococcal abscesses and eczema, but could find no obvious explanation for the recurrent infections. These two patients were girls who had red hair and fair skin. Because of the pitiful appearance of these patients, with the recurrent abscesses and skin infections, the author suggested the name "Job's syndrome" because of the description of Job in the biblical book of Job. Chemotactic studies were not performed, and specific IgE values were not presented.

The original report in the literature that documented the triad of neutrophil chemotactic defect, recurrent bacterial infections, and hyperimmunoglobulinemia E was presented in 1973 by Clark et al.[22] The Table presents a summary (in chronological order of appearance in the literature) of the cases of patients with the triad of neutrophil chemotaxis defect, recurrent bacterial infections, and hyperimmunoglobulinemia E. Cases 5 and 6 are the two original cases of Job's syndrome that were described by Davis et al. The Table indicates that a majority of the reported cases have been in female patients (ten of 13). The majority of patients have been white, but this condition can occur in all races. The patient in case 11 was Oriental, and our patient, case 13, was black. This is the second case reported in a black patient; the first case has yet to be published.[26]

Ten of 13 patients had a chronic eczematoid dermatitis, which was considered to be atopic dermatitis in some of the cases. This is the only other consistent finding, and therefore the syndrome may well include this as a fourth feature. Of the eight patients who had their hair color mentioned or shown in photographs, four had red hair. From these data, we conclude that red hair as well as fair skin are not consistent components of this syndrome. We suggest the term "pyoderma-chemotaxis-IgE" syndrome as a general descriptive term, since it includes the essential features found in this syndrome. If one uses the term "Job's syndrome," it should be reserved for that subgroup of patients who have red hair and fair skin, as well as the general features of neutrophil chemotaxis defect, recurrent bacterial infections, hyperimmunoglobulinemia E, and probably chronic eczema.

Unfortunately, there are no specific therapies for the clinical disorders of chemotaxis. At this writing, we are treating our patient with systemic antibiotics (erythromycin stearate, 250 mg orally, four times daily) and topical antibiotics (0.1% gentamicin sulfate cream, three times daily, and erythromycin ophthalmic ointment at night). During our period of observation, there has been a decrease in cutaneous and eye lesions, but no complete resolution. There has been no evidence of systemic bacterial infections.

In the evaluation of patients with chronic, recurrent, bacterial infections of the skin of undetermined origin, we recommend determination of the serum level of IgE. If the serum IgE level is found to be elevated, the physician should consider the diagnosis of this clinical syndrome, and neutrophil chemotaxis should then be examined.

John Gallin, MD, and Daniel Wright, MD, from the National Institute of Allergy and Infectious Diseases, National Institutes of Health, Bethesda, Md, assisted in the clinical and laboratory evaluation of this patient.

Westwood Pharmaceuticals, Inc, Buffalo, provided assistance in the reproduction of the color illustrations.

Nonproprietary Name and Trademark of Drug

Gentamicin sulfate—*Garamycin.*

References

1. Dahl MV, Matula G, Leonards R, et al: Incontinenti pigmenti and defective neutrophil chemotaxis. *Arch Dermatol* 111:1603-1605, 1975.

2. Strong DM, Woody JN, Factor MA, et al: Immunological responsiveness of frozen-thawed human lymphocytes. *Clin Exp Immunol* 21:442-455, 1975.

3. Root, RK, Rosenthal AS, Balestra DJ: Abnormal bactericidal, metabolic, and lysosomal functions of Chédiak-Higashi syndrome leukocytes. *J Clin Invest* 51:649-665, 1972.

4. Gallin JI, Clark RA, Kimball HR: Granulocyte chemotaxis: An improved in vitro assay employing ^{51}Cr-labeled granulocytes. *J Immunol* 110:233-240, 1973.

5. Miller ME: Cell movement and host defenses. *Ann Intern Med* 78:601-603, 1973.

6. Disorders of neutrophil function, editorial. *Lancet* 1:438-440, 1974.

7. Boyden S: The chemotactic effect of mixtures of antibody and antigen on polymorphonuclear leucocytes. *J Exp Med* 115:453-466, 1962.

8. Gallin, JI: Abnormal chemotaxis: Cellular and humoral components, in Bellanti JA, Dayton DH (eds): *The Phagocytic Cell in Host Resistance.* New York, Raven Press, 1975, pp 227-249.

9. Ward PA: Leukotaxis and leukotactic disorders. *Am J Pathol* 77:520-538, 1974.

10. Snyderman R, Phillips J, Mergenhagen SE: Polymorphonuclear leukocyte chemotactic activity in rabbit serum and guinea pig serum treated with immune complexes: Evidence for C5a as the major chemotactic factor. *Infect Immun* 1:521-525, 1970.

11. Ward PA: Chemotaxis of polymorphonuclear leukocytes. *Biochem Pharmacol* 17(suppl): 99-105, 1968.

12. Gallin JI, Wolff SM: Leucocyte chemotaxis: Physiological considerations and abnormalities. *Clin Haematol* 4:567-607, 1975.

13. Hill HR, Quie PG: Raised serum-IgE levels and defective neutrophil chemotaxis in three children with eczema and recurrent bacterial infections. *Lancet* 1:183-187, 1974.

14. Hill HR, Quie PG: Defective neutrophil chemotaxis associated with hyperimmunoglobulinemia E, in Bellanti JA, Dayton DH (eds): *The Phagocytic Cell in Host Resistance.* New York, Raven Press, 1975, pp 249-266.

15. Ogawa M, Berger PA, McIntyre OR, et al: IgE in atopic dermatitis. *Arch Dermatol* 103:575-580, 1971.

16. Gurevitch AW, Heiner DC, Reisner RM: IgE in atopic dermatitis and other common dermatoses. *Arch Dermatol* 107:712-715, 1973.

17. Stone SP, Muller SA, Gleich GJ: IgE levels in atopic dermatitis. *Arch Dermatol* 108:806-811, 1973.

18. Hogarth-Scott RS, Johansson SGO, Bennich H: Antibodies to *Toxocara* in the sera of visceral larva migrans patients: The significance of raised levels of IgE. *Clin Exp Immunol* 5:619-625, 1969.

19. Rosenberg, EB, Whalen GE, Bennich H, et al: Increased circulating IgE in a new parasitic disease-human intestinal capillariasis. *N Engl J Med* 283:1148-1149, 1970.

20. Winkelmann RK, Gleich GJ: Chronic acral dermatitis: Association with extreme elevations of IgE. *JAMA* 225:378-381, 1973.

21. Davis SD, Schaller J, Wedgwood RJ: Job's syndrome: Recurrent, "cold" staphylococcal abscesses. *Lancet* 1:1013-1015, 1966.

22. Clark RA, Root RK, Kimball HR, et al: Defective neutrophil chematoxis and cellular immunity in a child with recurrent infections. *Ann Intern Med* 78:515-519, 1973.

23. Hill HR, Ochs HD, Quie PG, et al: Defect in neutrophil granulocyte chemotaxis in Job's syndrome of recurrent "cold" staphylococcal abscesses. *Lancet* 2:617-619, 1974.

24. Van Scoy RE, Hill HR, Ritts RE, et al: Familial neutrophil chemotaxis defect, recurrent bacterial infections, mucutaneous candidiasis, and hyperimmunoglobulinemia E. *Ann Intern Med* 82:766-771, 1975.

25. Pincus SH, Thomas IT, Clark RA, et al: Defective neutrophil chemotaxis with variant ichthyosis, hyperimmunoglobulinemia E, and recurrent infections. *J Pediatr* 87:908-911, 1975.

26. Church, JA, Frankel LD, Wright DG, et al: T-lymphocyte dysfunction, hyperimmunoglobulin E, recurrent bacterial infections and defective neutrophil chemotaxis in a Negro child. *J Pediatr*, to be published.

Primary Cutaneous Aspergillosis in a Leukemic Child

John R. Carlile, MD; Ruth E. Millet, MD; Cheng T. Cho, MD, PhD; Tribhawan S. Vats, MD

• Primary cutaneous aspergillosis is rare. In this report we describe a primary skin infection by *Aspergillus flavus* in a child with leukemia. The lesions were characterized by erythematous macules and papules associated with pain and itching, followed by a rapid progression to ulcers and central black eschars with a raised erythematous border. A favorable response to topical nystatin therapy was observed. The multiple cutaneous lesions seen in our patient were most likely due to primary inoculation near the site of intravenous infusion with subsequent local lymphatic spread.

(*Arch Dermatol* 114:78-80, 1978)

Skin lesions caused by *Aspergillus* species are uncommon. Cutaneous aspergillosis is usually observed as part of a fatal or systemic infection due to *Aspergillus* sp in patients with altered host defenses,[1-5] although it may be seen in normal hosts.[6] The cutaneous lesions may be seen as subcutaneous abscesses,[7,8] pustules,[9] cellulitis and ulceration,[1] purpura,[10] and toxic epidermal necrolysis.[11] Primary cutaneous aspergillosis is rare and may be manifest as nodules[6] or as an erythematous to violaceous, edematous, indurated plaque that progresses to a central black eschar.[12]

Accepted for publication Oct 21, 1976.

From the Departments of Pediatrics (Drs Carlile, Cho, and Vats) and Pathology (Dr Millet), University of Kansas Medical Center, College of Health Sciences and Hospital, Kansas City.

Reprint requests to Department of Pediatrics, University of Kansas Medical Center, Kansas City, KS 66103 (Dr Cho).

In this report we describe a primary infection of the skin by *A flavus* in a child with leukemia in relapse. The skin lesions were somewhat similar to those described by Prystowsky et al,[12] except that their patient had a single lesion whereas our patient had multiple lesions.

REPORT OF A CASE

A 5-year-old girl who had acute lymphocytic leukemia of two years' duration was admitted to the hospital because of fever and general malaise. The initial diagnosis of acute lymphocytic leukemia was made in August 1973. At the time of this admission the child was in the fourth month of her second bone marrow relapse. She had received no chemotherapy or radiation for 28 days prior to admission. On examination the child appeared pale and acutely ill. Substantial findings included a bloody exudate on the posterior pharynx, scattered bruises over the extremities, enlarged liver (3 cm below the right costal margin), and a large spleen (5 cm below the left costal margin). Peripheral blood examinations disclosed a hemoglobin level of 5.8 gm/100 ml and a hematocrit reading of 17.6 gm/100 ml. The total WBC count was 5,800/cu mm, with 17% lymphocytes, 1% monocytes, and 82% lymphoblasts. The platelet count was 16,000/cu mm.

Bacterial sepsis was suspected and the child was given intravenous fluid with antibiotics (a combination of nafcillin sodium, 100 mg/kg/day; carbenicillin, 500 mg/kg/day, and gentamicin, 5 mg/kg/day). No bacteria were isolated from the blood and urine cultures.

On the 14th hospital day the patient began complaining of pain and itching in the right forearm near the site of an intravenous infusion. There were numerous erythematous macules and papules on the extensor surface of the right forearm where a paper-covered board and adhesive tapes were used in securing the intravenous infusion set. Within two days ulcers developed in the center of the larger lesions and several macules and papules spread to the upper arm. Clear fluid was oozing from these ulcers, and a swab culture of this fluid yielded a heavy growth of an *Aspergillus* species, which was later identified as *A flavus*. Cultures of blood, sputum, and urine were negative for fungal or bacterial pathogens. There was no clinical or roentgenographic evidence of pulmonary infection at that time.

By the fourth day the ulcerating lesions measured 0.8 to 2.0 cm in diameter and began to form darkish brown to black eschars in the center with slightly raised erythematous borders (Fig 1). On the sixth day aspirations of the two largest lesions for cultures were negative for fungi and bacteria. Nystatin ointment was applied twice daily. The lesions progressively diminished in size and lost the intense erythema. On the 16th day erythema resolved and crust formed (Fig 2). There was no roentgenographic evidence of underlying bone or joint involvement. Serological test for aspergillosis was not done.

On the 29th day the patient experienced an acute onset of fever and respiratory difficulty. Chest roentgenograms showed consolidation of the left upper lobe of the lung. Despite antibiotic and supportive therapy, the patient suffered progressive respiratory failure with terminal hemorrhage and died on the 31st hospital day.

POSTMORTEM EXAMINATION

Postmortem sections of one of the ulcers showed a surface covered with fibrin and necrotic debris (Fig 3). There was slight hyperkeratosis of the surrounding epidermis. The underlying dermis was edematous and contained a granulomatous reaction composed of histiocytes and lymphocytes

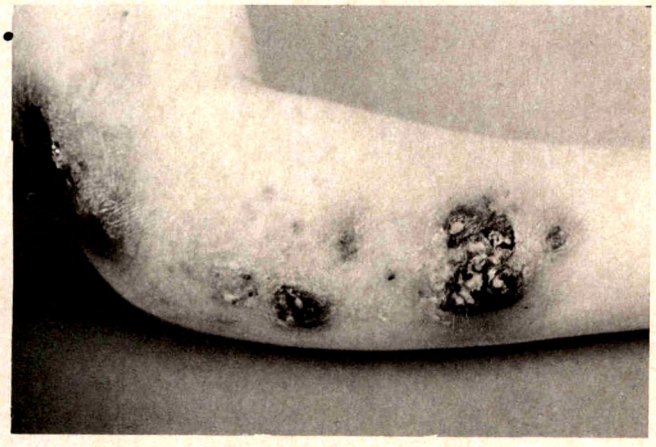

Fig 1.—Cutaneous lesions on fourth day after onset.

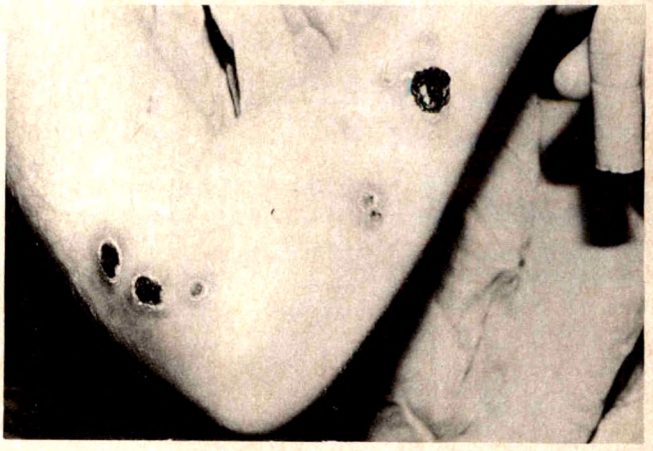

Fig 2.—Cutaneous lesions on 16th day after onset (12 days after commencement of topical nystatin therapy).

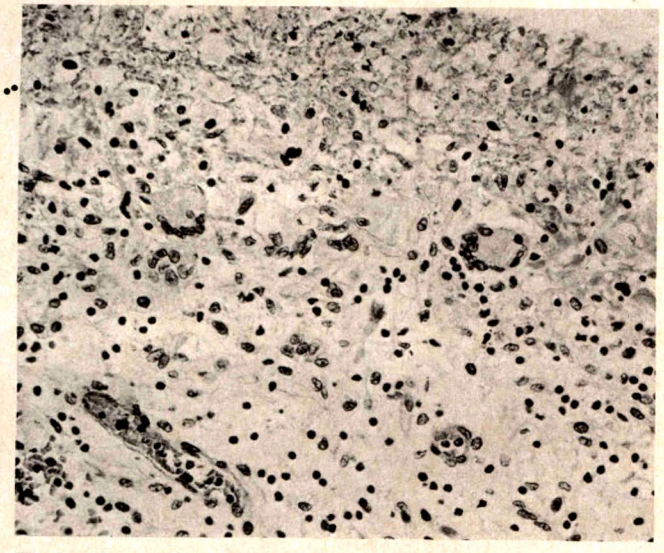

Fig 3.—Ulcer with necrotic debris and underlying cellular infiltrates and giant cell formation (hematoxylin-eosin, original magnification ×250).

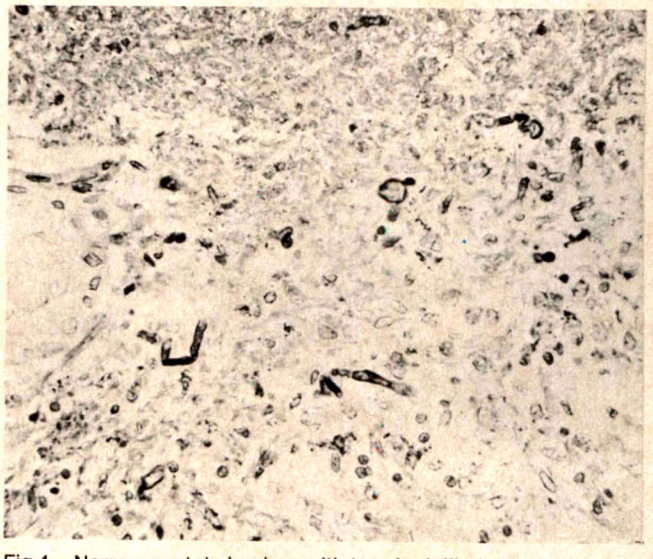

Fig 4.—Narrow septate hyphae with terminal dilations and branching (Grocott's silver methenamine, original magnification ×400).

with occasional plasma cells and multinucleated giant cells. Within the deeper dermis were several early abscesses that contained neutrophils, debris, and a few giant cells. There were scattered focal hemorrhages throughout the dermis and subcutaneous tissue, and the hemosiderin-laden macrophages were abundant. Around vessels and skin appendages in areas away from the histiocytic reaction were focal infiltrates of lymphoblasts and prolymphocytes intermixed with plasma cells and small lymphocytes. Lymphoblasts extended into the subcutaneous fat in some areas.

Tissue stained with Grocott's silver methenamine disclosed small numbers of septate hyphae within the superficial necrotic debris and extending into the underlying dermis (Fig 4). The hyphae were narrow, measuring 2 to 4 μm in diameter, and could sometimes be seen to branch at an acute angle or to have terminal bulbous dilations. In some areas hyphae were poorly stained, irregular, and fragmented. No hyphae were identified within vessels. Giemsa stains for bacteria were negative. General autopsy findings showed extensive pneumonic infiltrates of the left upper lobe of the lung, extensive mediastinal and retroperitoneal hemorrhage, and leukemic infiltration of many organs. A *Phycomycete (Cunninghamella)* was isolated from the involved lung tissues and hyphae of *Phycomycete* were identified in the sections of lung tissues. No other focus of mycotic infection was identified.

COMMENT

The organisms identified on postmortem sections of the skin are consistent with the *A flavus* cultured from the lesions before death, and the histopathologic features of the response are similar to those described in other cases of aspergillosis.[1,2,6,9,12,13] *Aspergillus* was not cultured from the lung. Careful examination of numerous sections of the involved lung disclosed no organisms like those found in the skin. Although a *Phycomycete* was isolated from the postmortem lung tissues, morphologically this organism is different from *Aspergillus* seen in the skin lesions. Furthermore, the vascular involvement characteristic of phycomycosis was not found in the skin lesions.

The clinical course and laboratory findings strongly suggested that our patient had a primary cutaneous aspergillosis. The cutaneous lesions observed in our patient were characterized by erythematous macules and papules associated with pain and itching, followed by a rapid progression of the lesions to ulceration and eschar formation. This is somewhat similar to the cases reported by Young et al[1] and Prystowsky et al,[12] whose patients had only a single skin lesion. Four of the five patients developed skin lesions at the site of an intravenous infusion where paper-covered boards or adhesive tapes were used to secure the infusion sets.[1,12] These findings suggest the possibility of direct cutaneous inoculation of *Aspergillus*.[1,12,14] Patients with systemic aspergillosis may have multiple scattered cutaneous lesions suggesting an embolic hematogenous spread from a primary pulmonary focus.[1,7,13,14] In our patient, however, the multiple cutaneous lesions were most likely due to primary inoculation with subsequent local lymphatic spread.

The occurrence of varying clinical manifestations of fungal diseases in patients with altered host defenses have been demonstrated.[1,15,16] However, information about the rare cutaneous manifestations associated with fungal infections is incomplete and requires additional documentation.

The favorable response of the skin lesions, the sparsity of the organisms, and their restriction to the most superficial dermis suggested the beneficial effect of topically applied antifungal therapy. Nystatin was previously reported as being effective in treating a primary cutaneous *A niger* infection in a 42-year-old man.[6] Undoubtedly, the usefulness of nystatin therapy in this disease needs further evaluation.

References

1. Young RC, Bennett JE, Vogel CL, et al: Aspergillosis. *Medicine* 49:147-193, 1970.
2. Landau JW, Newcomer VD, Schultz J: *Aspergillus:* Report of two instances in children associated with acute leukemia and review of the pertinent literature. *Mycopathol Mycobiol Appl* 20:177-244, 1963.
3. Zimmerman LE: Fatal fungal infections complicating other diseases. *Am J Clin Pathol* 25:46-65, 1955.
4. Symmers WS: Histopathologic aspects of the pathogenesis of some opportunistic fungal infections, as exemplified in the pathology of *Aspergillus* and the *Phycourycetosis*. *Lab Invest* 11:1073-1090, 1962.
5. Baker RD: Leukopenia and therapy in leukemia as factors predisposing of fatal mycoses. *Am J Clin Pathol* 37:358-373, 1962.
6. Cahill K, Mofty A, Kawaguchi T: Primary cutaneous aspergillosis. *Arch Dermatol* 96:545-547, 1967.
7. Utz JP, Emmons CW: Chemotherapeutic activity of X-50796 in systemic mycosis in man. *Am Rev Respir Dis* 84:514-528, 1961.
8. Cawley EP: Aspergillosis and the aspergilli. *Arch Intern Med* 80:423-434, 1947.
9. Allan G, Anderson D: Generalized aspergillosis in an infant 18 days of age. *Pediatrics* 26:432-440, 1960.
10. Mann B, Pasha M: Allergic primary pulmonary aspergillosis and Schonlein-Henoch purpura. *Br Med J* 1:282-283, 1959.
11. Rowell N, Thompson H: Toxic epidermal necrolysis in a patient with pulmonary aspergillosis. *Br J Dermatol* 73:278-282, 1961.
12. Prystowsky BV, Vogelstein B, Ettinger DS, et al: Invasive aspergillosis. *N Engl J Med* 295:655-658, 1976.
13. Vedder J, Schorr W: Primary disseminated pulmonary aspergillosis with metastatic skin nodules. *JAMA* 209:1191-1195, 1969.
14. Findlay GH, Roux HF, Simson IW: Skin manifestations in disseminated aspergillosis. *Br J Dermatol* 85(suppl 7):95-97, 1971.
15. Cho CT, Vats TS, Lowman JT, et al: *Fusarium solani* infection during treatment for acute leukemia. *J Pediatr* 83:1028-1031, 1973.
16. Meyer RD, Young LS, Armstrong D, et al: Aspergillosis complicating neoplastic disease. *Am J Med* 54:6-15, 1973.

A Mechanobullous Disease of the Newborn

Bart's Syndrome

Stephen Z. Smith, MD, David L. Cram, MD

• A patient had a unique mechanobullous disease (Bart's syndrome). The characteristic congenital localized skin defects, trauma-induced erosions, and nail deformities are present. The inheritance pattern appears to be autosomal dominant but, as in this report, isolated cases have been recognized.

In a review of the other mechanobullous diseases, Bart's syndrome appears to present a distinctive clinical picture and course and has a favorable prognosis. The progressive spontaneous improvement emphasizes the importance of early recognition and conservative treatment.

(*Arch Dermatol* 114:81-84, 1978)

Mechanobullous diseases comprise a spectrum of clinical presentations, inheritance, and course.[1] Classification remains difficult and new variants continue to be described.

Bart and associates[2] recognized a new mechanobullous syndrome consisting of skin defects that affected the lower extremities including a blistering of the skin and mucous membranes and a deformity of the nails. This is a report of another child with this syndrome and a review of the literature. The relationship of this syndrome to the other mechanobullous diseases and its possible pathogenetic mechanism will be discussed.

REPORT OF A CASE

A female infant was the product of a normal pregnancy and uneventful delivery. Her parents were of Mexican descent and there was no known consanguinity. Four siblings were normal.

Birth weight was 3,136 gm. Mild meconium aspiration occurred but otherwise the neonatal period was uneventful. The skin at birth was absent from the dorsa of the right hand and thumb (Fig 1) and bilaterally and symmetrically absent in the following areas: anterior lower legs (including the knees), the dorsa of the feet, and several toes (Fig 2 and 3). These sharply marginated areas on the legs and feet were covered with a glistening brownish-red, moist membrane, beneath which the vasculature was easily seen. The skin adjacent to these defects appeared normal. There were also skin erosions over the buttocks (Fig 4).

Results of a biopsy from an affected area of the lower leg, stained with hematoxylin-eosin, showed loss of the epidermis with dermal-epidermal separation and normal adnexa present in the dermis (Fig 5). The PAS staining of this specimen disclosed the basement membrane to be on the dermal side of the split. Electron microscopy was not performed.

While in the hospital the skin erosions or

Accepted for publication Oct 13, 1976.

From the Department of Dermatology, University of California School of Medicine, San Francisco. Dr Smith is now in private practice in Louisville.

Reprint requests to Department of Dermatology, University of California School of Medicine, 400 Parnassus Ave, San Francisco, CA 94143 (Dr Cram).

Fig 1.—Extensive superficial erosion involving dorsal hand and thumb.

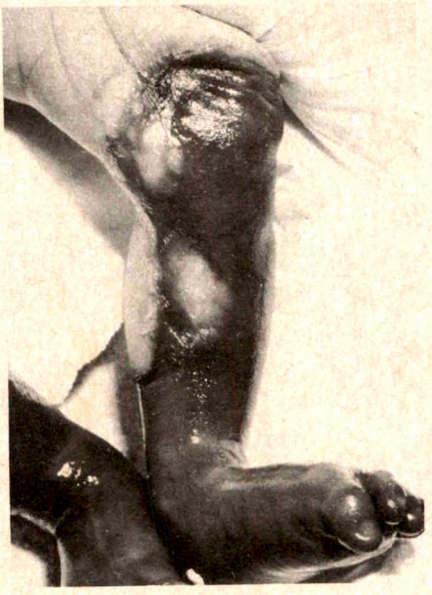

Fig 2 and 3.—Sharply marginated skin defects of the legs and feet with glossy membrane covering

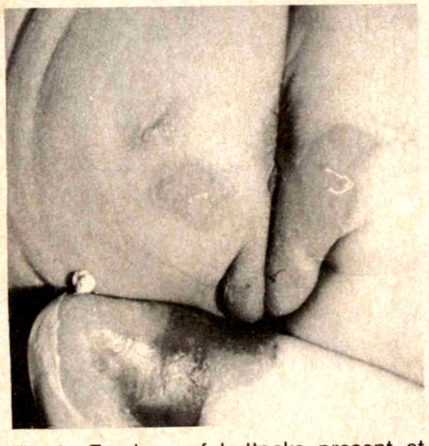

Fig 4.—Erosions of buttocks present at birth.

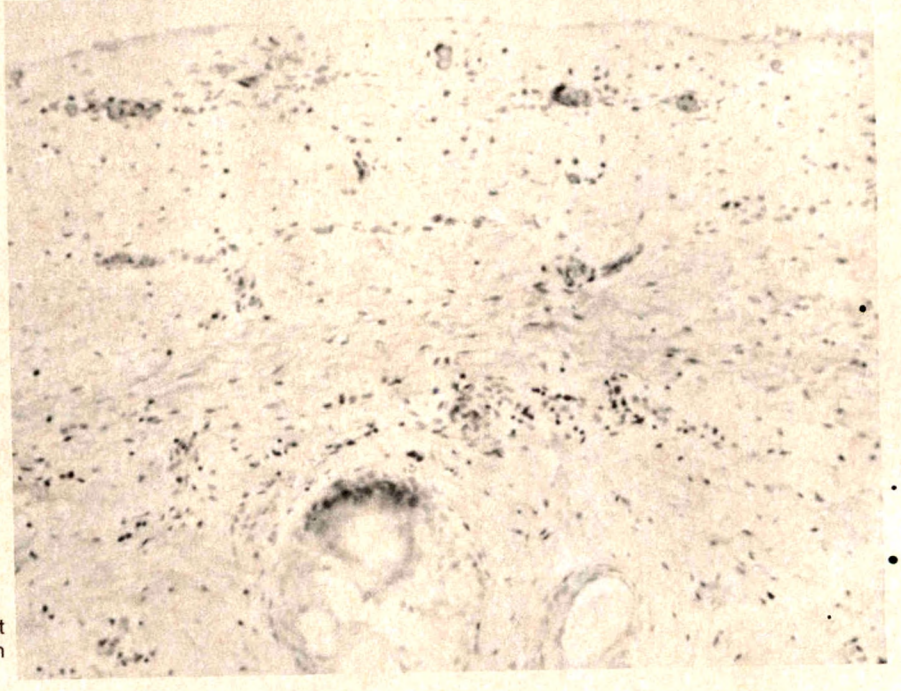

Fig 5.—Epidermal loss with adnexae present (hematoxylin-eosin, original magnification ×125).

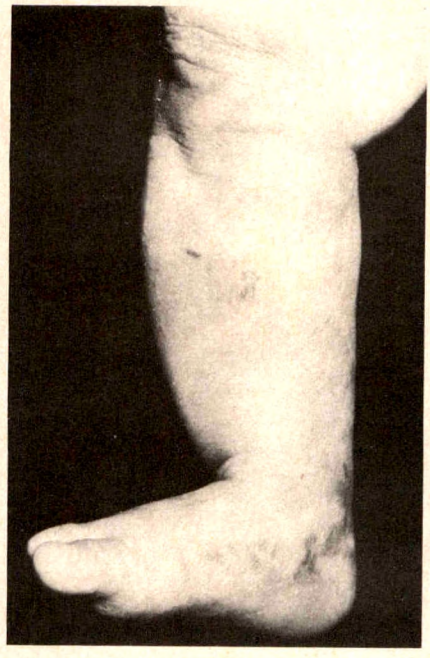

Fig 6 and 7.—Healed skin defects of legs at age 4½ months.

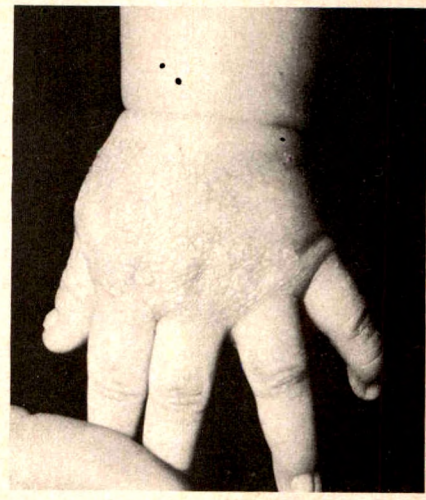

Fig 8.—Milia and minimal scarring dorsum of right hand at 4½ months of age.

Fig 9.—Short nails and thickened thumb nail seen at 4½ months of age.

the buttocks and extremities tended to heal in two or three days but new erosions continued to appear secondary to mild trauma. These erosions were not preceded by apparent blisters but occasionally were heralded by erythema. Feeding with plastic nipples caused erosions on the tongue and hard palate. The nails were initially noted to be small but otherwise not deformed. No other birth defects were found.

Within days, inward growth from the borders of the extremity defects began. The attending physicians in the nursery wrapped the legs, feet, and right hand with sterile gauze, which was removed in two days, revealing an eroded skin. Crusting, particularly of the left foot, developed, and it became progressively more difficult to keep the toes separated.

Healing of the skin defects with fine wrinkled scarring occurred during the next month in the nursery without further wrapping. The left foot healed with syndactyly, anonychia, and moderate scarring. When discharged from the hospital at 31 days of age, a few erosions on the buttocks and arms were still present.

At 4½ months of age the skin defects on the legs were completely healed (Fig 6 and 7), except for a small superficial erosion on the medial malleolus. Fine vellus hairs were present. The dorsum of the right hand healed with numerous milia and fine wrinkled scarring (Fig 8). The oral mucosa was free of erosions after the second week of life but occasional erosions on the trunk continued to appear where the skin was traumatized. The thumb nails at 4 months of age appeared heaped up, and all nails were short (Fig 9). Development was otherwise normal.

COMMENT

Congenital localized defects of the skin, mechanoblisters, and nail deformities with autosomal-dominant inheritance in a large kinship were described by Bart and associates in 1966.[2] Complete penetrance with variable expressivity resulted in a spectrum of involvement in the kinship. Some patients in the kindred only had mouth erosions, some only deformed nails, others recurrent blistering, and some the complete syndrome with the characteristic localized skin defect on the legs. The other skin erosions appeared to be a form of mechanobullous disease. They occurred mainly on the extensor extremities, intertriginous areas, neck, buttocks, and resulted from shearing trauma. Oral lesions were not noted to be present at birth but initial feeding with plastic nipple bottles rapidly induced erosions. All skin and mucous membrane erosions healed without scarring but with occasional hypopigmentation. In our review of the literature 21 other cases of this syndrome have been recognized.[2-5] The inheritance pattern was not always clear and some cases appeared to be spontaneous mutations.

The clinical and histologic picture of this syndrome is one of a mildly scarring mechanobullous dermatosis that defies classification in Pearson's terminology.[1,6] A review of the other mechanobullous diseases emphasizes the differences.

Epidermolysis bullosa simplex consists of major involvement of the feet, hands, and remainder of the extremities; nails are normal and the oral mucosa is rarely affected. Lesions are present at birth and recur with increasing physical activity. The blisters may be hemorrhagic. Electron microscopy of a skin biopsy specimen usually shows basal layer degeneration with cytolysis.

Predilection for palmar and plantar surfaces, later onset, and direct relationship to physical activity characterize recurrent bullous eruption of the hands and feet or Weber-Cockayne's disease. Electron microscopy of

a skin biopsy specimen shows suprabasal to lower granular layer cytolysis with midsquamous cleavage; dyskeratosis precedes the cytolysis.

Junctional bullous epidermotosis[7] or Herlitz disease is present at birth. In this disease large erosions commonly appear on the legs. Palms and soles are spared. Oral erosions appear after initial feeding. Chronic perioral involvement, dental dysplasia, and failure to thrive are common sequelae. Cleavage at the junction of the basal cell plasma membrane and basement membrane are characteristic of the histology of this epidermotosis on electron microscopy. Pearson[1] categorized the bullous component of Bart's case as junctional bullous epidermotosis. Pearson's classification is, however, based on electron microscopic findings and these studies have not been performed on any patients with Bart's syndrome. The clinical course of our case and those described by Bart are unique. Most patients with this epidermotosis die in infancy or early childhood despite the use of antibiotics, steroids, and topical measures. Retarded growth and development are apparent at an early stage of life. Two of the five patients with junctional bullous epidermotosis described by Pearson et al[7] did survive childhood, but continued to have severe erosions of their skin and of mucous membranes. All cases of this disease have a guarded prognosis. Our patient has grown and developed normally without other abnormalities.

The congenital skin defects, as seen on the legs and feet of our patient, do not conform to aplasia cutis congenita. Abt[8] reviewed 37 cases of aplasia cutis congenita and pointed out that the large majority had scalp involvement, usually at the vertex. Subsequent reports of approximately 270 patients[2,4,9-25] confirm that the posterior fontanel of the scalp, at or near the midline, is the most frequently involved area. The oval or circular skin defects with sharp edges tend to heal rapidly with a depressed scar devoid of hair. Other sites reportedly have been the distal limbs, trunk, and face. Like the scalp, all sites heal with scarring and are devoid of adnexae on histology.

The histology from the characteristic leg defect in our case confirms that the dermis and adnexal structures as well as the subcutaneous tissue are intact, with only the epidermis absent. There are several possible explanations for this defect.

The defects might be the result of tears from Sinomart's bands, which are adhesions of the amnion to the skin.[8,9] The accumulation of amniotic fluid usually cleanly separates the amnion from the fetal skin. However, any adherent amniotic tissue might pull the delicate fetal epidermis from the rest of the skin. After delivery, the otherwise normal skin would reepithelialize. The rapid healing of the skin defects on the legs in our patient could be explained by this mechanism. Another explanation for the defects would be that they are the result of mechanobullous disease in utero. Dermal-epidermal separation in utero would result in loss of the epidermis, while preserving the underlying dermis and adnexal structures. Perhaps this particular form of mechanobullous disease affects the fetus in genetically predetermined areas, specifically the legs. This would account for the similarity of the defects in all the reported cases. The physically active fetus is in this instance susceptible to intrauterine trauma, which would precipitate epidermal separation in a fashion similar to what occurs in children with mechanobullus diseases when they become physically active. Thus the skin defects on the legs and hand present at birth and the recurrent erosions on the buttocks and extremities in our patient would be the result of mechanobullous disease starting in utero and continuing after birth. Further theories must await a better understanding of the pathomechanism of all the mechanobullous diseases.

Our case appears to be identical to the syndrome described by Bart and merits separate classification among the mechanobullous diseases. Early recognition of the syndrome with its more favorable prognosis is important to avoid unnecessary topical and systemic therapy. Topical gauze in our patient was believed to lead to scarring of one foot, which may have been prevented. Surgical intervention, such as grafting, is unnecessary and would be detrimental to cosmetic improvement. The blistering of mucous membranes and skin also improves with time and requires only avoidance of trauma. The child described here is developing normally and will require only minimal surgical correction of her toe webbing at some future time.

References

1. Pearson RW: The mechanobullous diseases (Epidermolysis bullosa), in Fitzpatrick TB, Arndt KA, Clark WH, et al (eds): *Dermatology in General Medicine*. New York, McGraw-Hill Book Co Inc, 1971, pp 621-643.
2. Bart BJ, Gorlin RJ, Anderson VE, et al: Congenital localized absence of skin and associated abnormalities resembling epidermolysis bullosa. *Arch Dermatol* 93:296-304, 1966.
3. Bart BJ: Epidermolysis bullosa and congenital localized absence of skin. *Arch Dermatol* 101:78-81, 1970.
4. Scott FP: Congenital skin defects. *Dermatologica* 135:84-89, 1967.
5. Joensen HD: Epidermolysis bullose dystrophica dominans in two families in the Faroe Islands. *Acta Dermatovener* 53:53-60, 1973.
6. Pearson RW: Studies on the pathogenesis of epidermolysis bullosa. *J Invest Dermatol* 39:551-575, 1962.
7. Pearson RW, Potter B, Strauss F: Epidermolysis bullosa hereditaria letalis. *Arch Dermatol* 109:349-355, 1974.
8. Abt IA: Congenital skin defects. *Am J Dis Child* 14:113-121, 1917.
9. Pers M: Congenital absence of skin: Pathogenesis and relation to ring constriction. *Acta Chir Scand* 126:388-396, 1963.
10. Ingalls NW: Congenital defects of the scalp. *Am J Obstet Gynecol* 25:861-873, 1933.
11. Freud P, Rhodes AW, Weisz A: Hereditary skin defect in the newborn infant. *J Pediatr* 27:591-594, 1945.
12. Kahn EA, Olmedo L: Congenital defect of the scalp. *Plast Reconstr Surg* 6:435-440, 1950.
13. Savage D: Localized congenital defects of the scalp. *J Obstet Gynaecol Br Comm* 63:351-354, 1956.
14. Frank L, Ruby A: Familial congenital defect on the scalp. *Arch Dermatol* 75:266-267, 1957.
15. Vineyard WR: Familial congenital defect of the scalp. *Bull Assoc Milit Dermatol* 13:14, 1964.
16. Kjaer M: Congenital skin defects. *Acta Dermatovener* 48:608-611, 1968.
17. Rauschkolb RR, Enriquez SI: Aplasia cutis congenita. *Arch Dermatol* 86:54-57, 1962.
18. Rosenbaum S: Congenital skin defects. *Acta Med Orient* 10:209-215, 1951.
19. Farmer AW, Maxmen MD: Congenital absences of skin. *Plast Reconstr Surg* 25:291-297, 1960.
20. Gomes WJ, DeSilva CC: An unusual example of ectodermal agenesis. *Clin Pediatr* 5:444-445, 1966.
21. Adair FL, Steward CA: Congenital defect of the skin of the newborn. *Am J Dis Child* 27:60-63, 1924.
22. Dowler VB: Congenital defect of the skin in a newborn infant. *Am J Dis Child* 44:1279-1284, 1932.
23. Sutton RL Jr: Congenital defect of the skin of the newborn. *Arch Dermatol Syphilo* 31:855-857, 1935.
24. Anderson NP, Novy FG: Congenital defect of the scalp. *Arch Dermatol Syphilo* 46:257-263, 1942.
25. Degas R, cited by Kjaer M: Congenital skin defects. *Acta Dermatovener* 48:608-611, 1968.

Hand-Schüller-Christian Disease in a Septuagenarian

James F. Dolezal, MD, Stephen T. Thomson, MD

• Hand-Schüller-Christian disease is a disease primarily affecting children, occasionally young adults, and rarely older adults. Very few cases have been reported in individuals past their fifth decade. A review of the English language literature indicates that the onset of Hand-Schüller-Christian disease occurs after the fifth decade in less than 4% of reported cases. A 75-year-old woman's symptoms of Hand-Schüller-Christian disease began in her 76th year, and her cutaneous symptoms were controlled with a topically applied nitrogen mustard.

(*Arch Dermatol* 114:85-87, 1978)

Histiocytosis X is a rare disease with an incidence of one per 3,300,000 per year.[1(p1365)] It is characterized clinically by various combinations of systemic and cutaneous manifestations. The pathologic basis of the manifestations is reticuloendothelial granuloma formation. The cause is unknown.

Histiocytosis X is a collective designation for the spectrum that includes Letterer-Siwe disease, Hand-Schüller-Christian disease, and eosinophilic granuloma. Letterer-Siwe, the acute systemic form, is usually the most severe and often terminates fatally within several years of onset. It usually occurs within the first two or three years of life and often within several months of birth.[1(p1366)] Eosinophilic granuloma is the monosymptomatic form. The onset is usually before 15 years of age; however, cases through the seventh decade have been reported.[1,2]

• Hand-Schüller-Christian disease, the chronic multisystem form, usually occurs within the first five years of life and rarely within the first six months. The clinical manifestations often include skin lesions, which may be hemorrhagic in nature and/or simulate seborrheic dermatitis. Systemic manifestations may include granulomas of the liver and spleen, skeletal system, lungs, gastrointestinal tract, central nervous system, lymph nodes, or bone marrow. Involvement of the pituitary stalk can result in diabetes insipidus. Commonly, the petrous portion of the temporal bone is involved and can result in otorrhea. Exophthalmos can be produced by retro-orbital infiltration. The classical triad of Hand-Schüller-Christian disease consists of bone defects (especially the skull), exophthalmos, and diabetes insipidus. It is uncommon for all of the manifestations of the triad to be seen together in the same patient. The initial manifestations are frequently diabetes insipidus, chronic otitis media, or skin involvement.

We have recently seen a patient with histiocytosis X of the Hand-Schüller-Christian type with onset in the eighth decade whose cutaneous involvement is well controlled with a topically applied nitrogen mustard.

REPORT OF A CASE

A 76-year-old woman was admitted with an eruption on her chest of five months' duration. She complained of a burning sensation that was unresponsive to home remedies. Three months prior to admission she began to have polydipsia, polyuria, and frequent nocturia. About that same time she began having drainage from the right ear. One month prior to admission she began to notice a reduction in appetite and one week prior to admission began to have nausea and vomiting. She was taking no internal medication except an occasional patent medicine. Personal medical history, family history, and review of systems were otherwise noncontributory.

Physical Examination

There were crusted reddish-brown papules and petechiae on the thorax, with erosion and weeping of the inframammary areas (Fig 1). These papules and petechiae were also present in the axillae, right groin, and lumbosacral area (Fig 2).

No soft tissue tumors or defects were palpated in the scalp. The external ear canals were filled with foul-smelling purulent debris. White plaques were present on the buccal mucosa and punctate, and coalescent tan plaques were present on the tongue. There was no lymphadenopathy and the liver and spleen were not palpable. The lungs were clear to auscultation and percussion. The remaining results of the physical examination were either normal or noncontributory.

Laboratory Findings

At admission, values for the following were abnormal: hemoglobin, 11.6 gm/100 ml; hematocrit, 35%; the indexes, however, were normal. The leukocyte count was 10,900/cu mm, with 68% polymorphonuclear leukocytes, 3% band cells, 20% lymphocytes, and 9% monocytes. The platelet count was normal. The specific gravity of the urine was 1.002, which was otherwise normal. The alkaline phosphatase level was elevated at 125 mU/ml (normal, 30 to 115 mU/ml), but the results from the balance of the automated chemical analysis were normal. The protein electrophoresis showed a mild increase in α_2-globulin (1.1 gm/100 ml; normal, 0.51 to 0.93 gm/100 ml) and β-globulin (1.4 gm/100 ml; normal, 0.64 to 1.06 gm/100 ml), with slight decrease in albumin level (3.4 gm/100 ml; normal, 3.5 to 5.5 gm/100 ml). The chest roentgenogram showed a small left pleural effusion but no infiltrate. Study results for the following were normal or negative: serum iron, serum iron-binding capacity, serum B_{12}, serum folate, thyroxine 4, VDRL, immunoglobulin electrophoresis, skull roentgenograms (including temporal bone views), EEG, barium examination of the upper and lower parts of the gastrointestinal tract, and scan of liver and spleen (sodium pertechnetate Tc 99m sulfur colloid, 4 μCi).

A skin biopsy specimen was taken of a papule on the chest region. The epidermis was thinned in areas and in other areas some of the epidermal ridges were enlarged. There was a mixed inflammatory infiltrate, consisting of lymphocytes, histiocytes, and a few eosinophils in the edematous upper dermis (Fig 3). There were also large cells, concentrated in the papillary dermis, that focally invaded the epidermis. The nuclei of these cells were vesicular and multilobulated or kidney-shaped. The abundant cytoplasm was eosinophilic and finely granular (Fig 4). Immunofluorescent skin biopsy from the same area was negative for IgG, IgA, IgM, and C3. Potassium hydroxide examination of oral plaques was positive for pseudohyphae. Fungal culture of the inframammary area was negative, and culture of the mouth was not done.

Hospital Course

The serial leukocyte counts showed a rise to 26,000/cu mm, with as many as 52% monocytes on occasion. Eosinophils were not present in the routine leukocyte differential cell count. The leukocytosis and monocytosis resolved within six weeks. Leukocytosis is not an uncommon finding in histiocytosis X.[3,4] The significance of the leukocytosis and monocytosis in this patient is unclear. Bone marrow aspiration showed the myeloid-erythroid ratio to be increased, mainly by an increase in monocytes with premonocytic cells. Bone marrow findings are usually not diagnostic and may be normal in 60% of biopsies. Histiocytic infiltration has been found in 14% of bone marrow biopsies, whereas nonspecific erythroid and myeloid hyperplasia were present in 25% of biopsies.[3]

Accepted for publication Oct 21, 1976.

From the Department of Dermatology, University of Iowa, Iowa City.

Reprint requests to Department of Dermatology, 2 North Tower, University Hospitals, Iowa City, IA 52242 (Dr Dolezal).

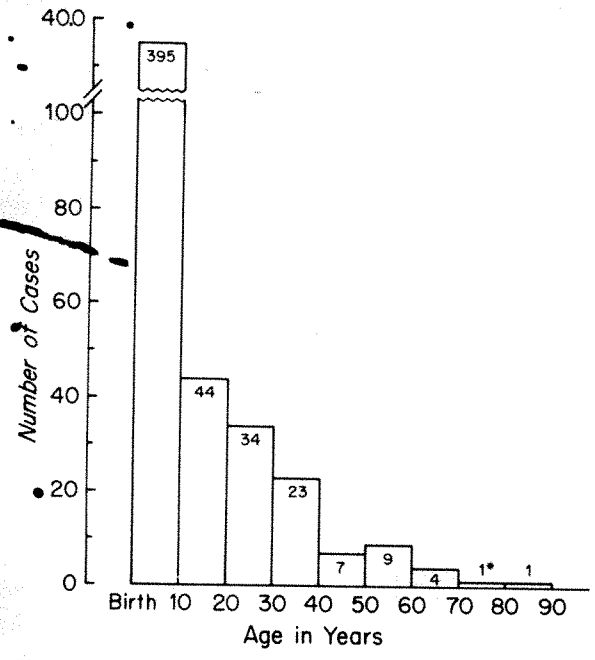

Fig 7.—Age at diagnosis, or onset if stated, of 518 patients with Hand-Schüller-Christian disease. Asterisk indicates present case.

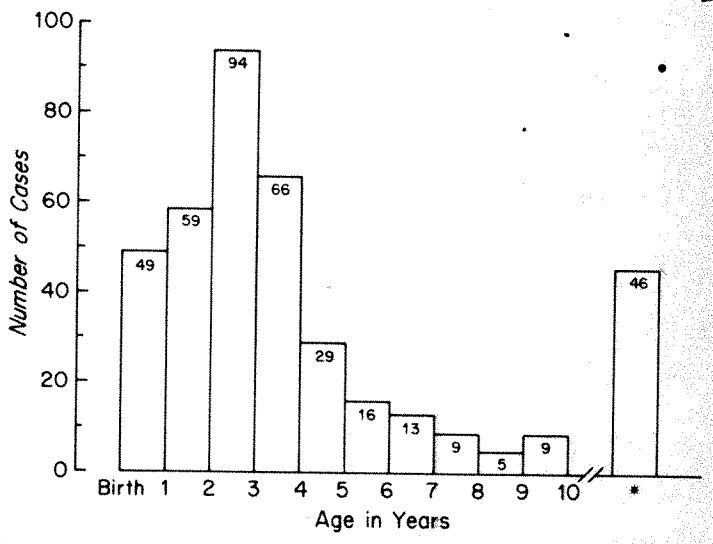

Fig 8.—Age at diagnosis, or onset if stated, of 395 patients under age 10 with Hand-Schüller-Christian disease. Asterisk indicates 46 cases classified only as 0 to 8 years.

lotion without improvement. After interpretation of the skin biopsy, the compresses and nystatin therapy were discontinued. A trial of therapy with a nitrogen mustard (mechlorethamine hydrochloride), 10 mg dissolved in 60 ml water, was initiated, being applied to the lesions on the left side of the thorax once daily, while the right side remained untreated as a control.

After two weeks of this regimen, the side untreated with the nitrogen mustard had advancement of the eruption into previously uninvolved areas, and was unchanged in quality and symptomatology. On the side treated with the nitrogen mustard, advancement did not occur, the papules flattened, the hemorrhagic quality faded (Fig 5), and the discomfort and burning sensation was replaced with a mild itching sensation. At this time, use of the topical flurandrenolide lotion, which had been applied to all areas, was stopped and the topical nitrogen mustard was then applied once daily to all areas of eruption with significant improvement within three months. She has continued daily topical application of the nitrogen mustard to the previously involved areas for one year and the skin remains clear and symptom-free with only residual hyperpigmentation (Fig 6). She experienced no irritation or dermatitis from her treatment.

The absence of skull lesions is notable in that membranous skull lesions are present in most of the cases. Exophthalmos was absent but it is an unusual finding in adults. The nearly simultaneous appearance of diabetes insipidus, otorrhea, and a characteristic skin eruption with histologic features typical of histiocytosis X leaves little doubt about the diagnosis of histiocytosis X, Hand-Schüller-Christian variety. Because Hand-Schüller-Christian disease is primarily a disease of the young, this diagnosis was not initially considered. Ample evidence for postadolescent onset of Hand-Schüller-Christian disease is found in the literature.

AGE OF ONSET OF REPORTED CASES IN THE LITERATURE

Five hundred thirty-eight cases of histiocytosis X classified by the authors as Hand-Schüller-Christian disease, reported in the English language literature, were reviewed with respect to age of patients at diagnosis, or onset if stated (Fig 7 and 8). Of the 538 patients, 518 had ages or ranges of ages specified that were compatible with our tabulation methods. Of 518 patients, 76% developed the disease before age 10, and 91% before age 30. In less than 4% the disease occurred after the fifth decade, and in only one case was the diagnosis first made in a person past the age of 80.

Another 20 cases were reviewed, but the age range was incompatible with our tabulation methods. These were as follows: 12 cases from 6 to 16 years, and four cases each from 17 to 30 years and 31 to 64 years. Even if the four cases in the 31 to 64 group were considered to all be more than 50 years of age, the onset in the second half-century of life would still be less than 4% of all the reported cases.

COMMENT

Systemic alkylating agents have been used to suppress the manifestations of histiocytosis X.[4] Because of our patient's advanced age, and because the internal manifestation was controlled, we felt systemic chemotherapy involved significant risk of morbidity. To our knowledge, topical nitrogen mustard therapy for the cutaneous manifestations of histiocytosis X has not been reported previously; however, topical use of systemic drugs has often proved helpful in dermatologic disorders, and we thought a trial of a topically applied nitrogen mustard might be beneficial.

This case is a reminder that histiocytosis X, Hand-Schüller-Christian variety, can occur at any age.

Merck Sharp & Dohme Co, assumed the cost of reproducing the color photographs.

Bibliography for reports used in age computation is available from the authors on request.

References

1. Beare JM: Histiocytic proliferative disorders, in Rook A, Wilkinson DS, Ebling FJG (eds): *Textbook of Dermatology*. Oxford, Blackwell Scientific Publications, 1972, p 1365.

2. Avery M, McAfee J, Guild H: The course and prognosis of reticuloendotheliosis. *Am J Med* 22:636-652, 1957.

3. Lucaya J: Histiocytosis X. *Am J Dis Child* 121:289-295, 1971.

4. Crocker AC: The histiocytosis syndromes, in Gellis SS, Kagan BM (eds): *Current Pediatric Therapy*. Philadelphia, WB Saunders Co, 1970, vol 4, p 534.

Dermatofibrosarcoma Protuberans With Lymph Node Involvement

A Case Report of Simultaneous Occurrence With an Atypical Fibroxanthoma of the Skin

Richard J. Hausner, MD; Fernando Vargas-Cortes, MD; Ronald W. Alexander, MD

• A 40-year-old man had dermatofibrosarcoma protuberans of the neck with rapid local recurrence, satellite nodules, and a cervical lymph node metastasis, occurring simultaneously with an atypical fibroxanthoma of the scrotum. These two tumors, with distinct clinical and pathologic features, are classified as histogenetically related lesions within the spectrum of the fibrous histiocytomas. The place for the dermatofibrosarcoma protuberans at the malignant end of this spectrum is clinically and ultrastructurally documented further in our patient.

(*Arch Dermatol* 114:88-91, 1978)

Grouped under the designation of fibrous histiocytomas are several lesions of the skin, soft tissues, and bone, thought to be derived from the tissue histiocyte and characterized by a variable combination of cells with fibroblastic and histiocytic features.[1-6]

In the skin, in addition to benign fibrous histiocytic lesions including dermatofibroma, nodular subepidermal fibrosis, sclerosing hemangioma, and juvenile xanthogranuloma, there are two clinically and pathologically distinct lesions. One, the atypical fibroxanthoma, is generally regarded as a fibrous histiocytoma.[1,7] Despite worrisome histologic features, this tumor has previously been considered benign because of its repeated observed indolent clinical course.[7-9] Two cases with metastasis, however, have been reported recently.[10,11] The other, the dermatofibrosarcoma protuberans, is regarded by many to be within the spectrum of fibrous histiocytomas[2,3,6,12] and to be locally invasive or possibly malignant.[6,13] This tumor may recur tenaciously after repeated local excisions, with the formation of satellite nodules.[13,14] Also, instances of distant visceral metastases and, more rarely, of metastases to regional lymph nodes have been reported.[14]

Recently, we studied a patient with the simultaneous and apparently coincidental occurrence of an atypical fibroxanthoma and a dermatofibrosarcoma protuberans that recurred shortly after local excision in association with satellite nodules and involvement of a regional lymph node. The results of our observations, including an electron microscopic study of the dermatofibrosarcoma protuberans, are presented.

REPORT OF A CASE

In May 1974, a 40-year-old man, in good general health for his entire life and with no history of previous radiation therapy, noted slowly growing lesions of the skin of the right side of the neck and the right scrotum.

In September, a dermatofibrosarcoma protuberans was excised from the neck. It was described as flat, gray-white, and 0.5 cm in diameter.

When first seen at the Gainesville Veterans Administration Hospital in January 1975, an atypical fibroxanthoma of the scrotum, appearing as a tender, firm, freely movable, raised and ulcerated 3 × 2-cm nodule, was excised. Three weeks later, a wide local reexcision was done. At this time, a "satellite" lesion in the neck, adjacent to the scar, was noted. The new 1.5-cm-diameter mass was nontender, round, firm, slightly raised, and nonpigmented. In addition, the surgical scar was indurated and fixed to the underlying tissue and an enlarged, firm cervical lymph node was palpable above the scar.

In March 1975, the previous surgical scar and the new lesion were widely excised in association with an ipsilateral radical neck dissection.

Twenty-two months after the neck and scrotal lesions were noted and one year after radical neck surgery, the patient was without evidence of further recurrences or metastases from either primary site.

Gross and Light Microscopic Examination

The Atypical Fibroxanthoma.—The sectioned surface of the original gross specimen was gray-white, uniform, and firm. Microscopically, the lesion was an unencapsulated cellular dermal tumor nodule ulcerating the epidermis. It was composed of a disorganized admixture of oval to polyhedral cells with clear vesicular nuclei and prominent nucleoli, plump interdigitating spindle cells, and bizarre giant multinucleated cells. Mitotic figures, some of them atypical, were seen in all cell types and averaged five to six per ten high-power fields (HPF) (Fig 1). Although generally circumscribed, neoplastic cells infiltrated the adjacent dermis. Tumor was present at the deep margin of the initial resection. In the subsequent wide local reexcision residual tumor was seen, but the final margins were free.

The Dermatofibrosarcoma Protuberans.—The sectioned surface of the primary tumor was described as gray-yellow and firm. Microscopically, this lesion was a dermal nodule infiltrating the subcutaneous fat. It was composed of spindle-shaped cells arranged in a well-defined storiform pattern with mitoses averaging four per ten HPF (Fig 2). A few benign multinucleated cells were present. The specimen of the radical neck procedure contained tumor similar to that previously excised both at the surgical scar and at the clinically apparent satellite nodule. The palpable cervical lymph node was partially infiltrated by tumor (Fig 3). In addition, foci of tumor were found in the grossly normal adipose tissue between the recurrence at the scar and the involved lymph

Accepted for publication Nov 15, 1976.

From the Gainesville (Fla) Veterans Administration Hospital and the Department of Pathology, College of Medicine, University of Florida, Gainesville.

Reprint requests to Department of Pathology, College of Medicine, University of Florida, Gainesville, FL 32610 (Dr Hausner).

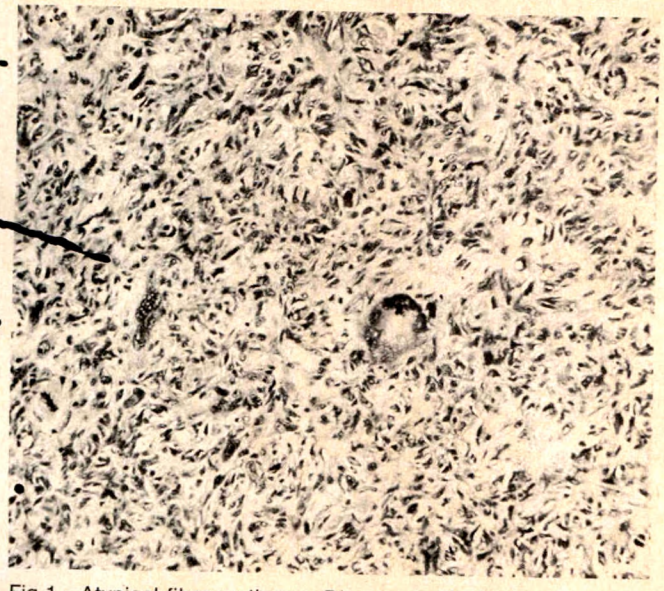

Fig 1.—Atypical fibroxanthoma. Disorganized admixture of interdigitating plump spindle cells and bizarre giant multinucleated cells. Note mitotic figure at lower left (hematoxylin-eosin, ×100).

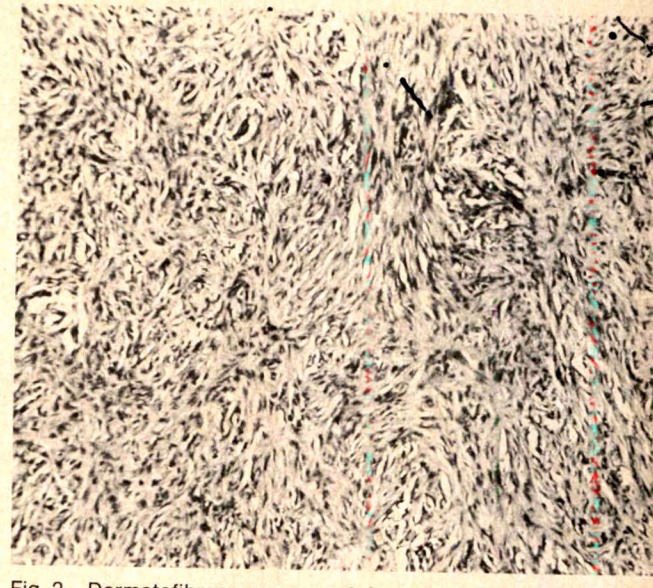

Fig 2.—Dermatofibrosarcoma protuberans. Section from initial excision showing spindle-shaped cells in a storiform pattern (hematoxylin-eosin, ×100).

Fig 3.—Dermatofibrosarcoma protuberans in cervical lymph node (hematoxylin-eosin, ×40).

node. Fifty other cervical lymph nodes were examined and were free of tumor.

Electron Microscopic Examination of the Dermatofibrosarcoma Protuberans

Ultrastructurally, the dermatofibrosarcoma protuberans had a fairly uniform population of tumor cells with minor individual variations. The basic cell type was a spindle cell with long cytoplasmic extensions residing in a background matrix of mature collagen and finely granular material (Fig 4). The individual cells were predominantly separate, with occasional adherens-type junctions between adjacent cells forming a variable intercellular gap of 125 to 200 A (Fig 5). The cell membrane was intimately associated with the extracellular matrix of collagen and finely granular material. No basement membranes were present. The nuclei of the cells were irregular, infolded, and contained prominent nucleoli. The cytoplasm was highly organized with a prominent Golgi complex and large arrays of rough endoplasmic reticulum (Fig 6). Cytoplasmic microfilaments, occasionally containing focal condensations of dense granular material, were present (Fig 7). Numerous large lipid droplets, not membrane bound, were also present. Some of the larger cells showed minor evidence of histiocytic differentiation. They had voluminous cytoplasm filled with mitochondria, clear vesicles, a few lysosomal bodies, and little rough endoplasmic reticulum (Fig 8). Phagocytosis, however, was not present. No true epithelial or neural features were seen. Ultrastructurally, the dermatofibrosarcoma protuberans had the appearance of a fibroblastic tumor with lipid within fibroblasts. Histiocytic differentiation was not a prominent feature and, when present, appeared in basically fibroblastic cells.

COMMENT

The dermatofibrosarcoma protuberans was described by Darier and Ferrand in 1924[15] and named by Hoffmann in 1925.[16] Early investigators considered the tumor to be derived from the mammary ridges, or to be of angiomatous, melanocytic, or neurogenic origin.[17,18] Recently, evidence that the dermatofibrosarcoma protuberans is a variety of fibrous histiocytoma was provided by the tissue culture study of Ozzello and Hamels,[3] in which the cells of the tumor evolved from histiocytes to fibroblast-like cells. Electron microscopic studies have demonstrated cells with fibro-

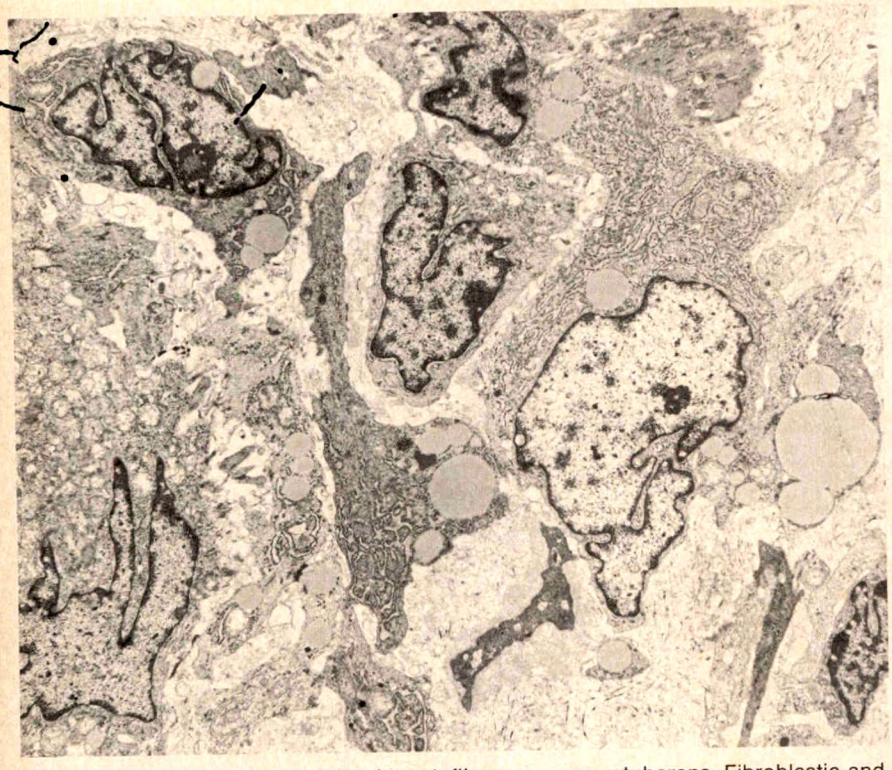

Fig 4.—Electron micrograph of the dermatofibrosarcoma protuberans. Fibroblastic and histiocytic cells, most containing lipid droplets, are intermixed in collagenous matrix (original magnification, ×6,600).

Fig 5.—Electron micrograph of a group of fibroblastic cells. In central portion are several adherens type junctions between adjacent cells (original magnification, ×6,000).

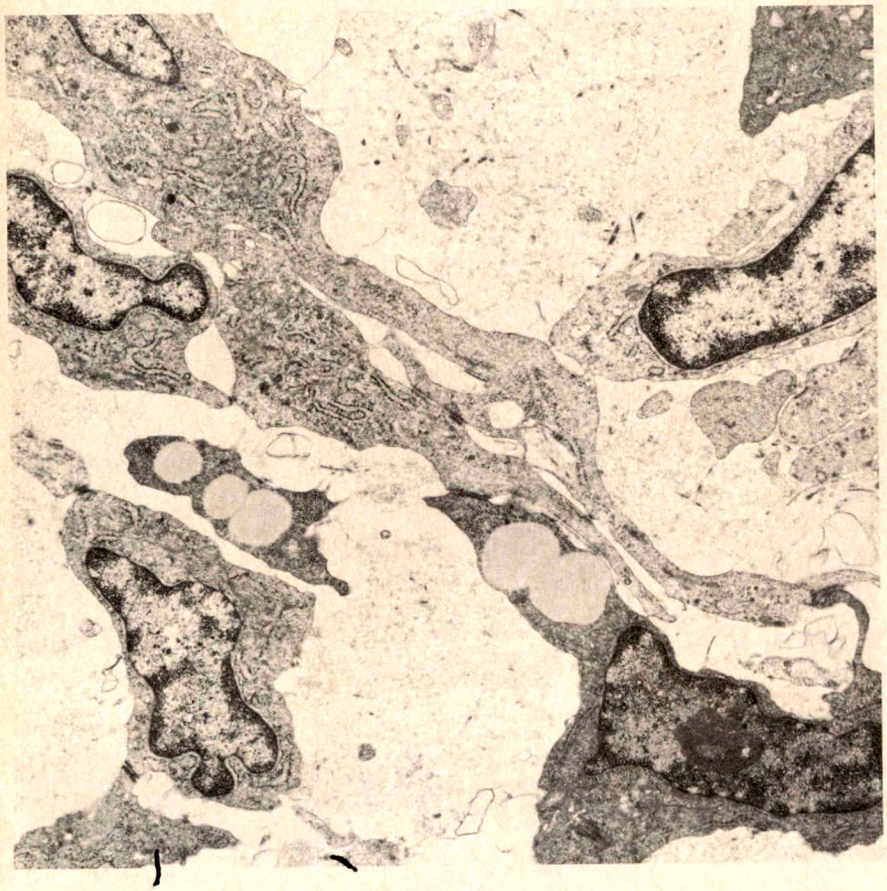

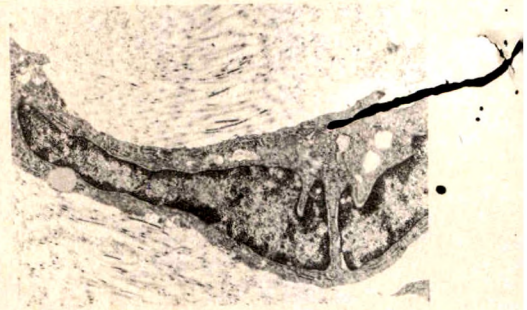

Fig 6.—Typical fibroblastic cell with abundant rough endoplasmic reticulum, well-developed Golgi region, and collagenous extracellular matrix (original magnification, ×8,800).

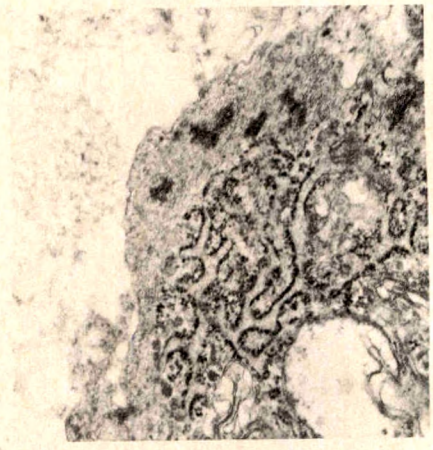

Fig 7.—Cytoplasmic fibrils with aggregates of dense material (original magnification, ×28,900).

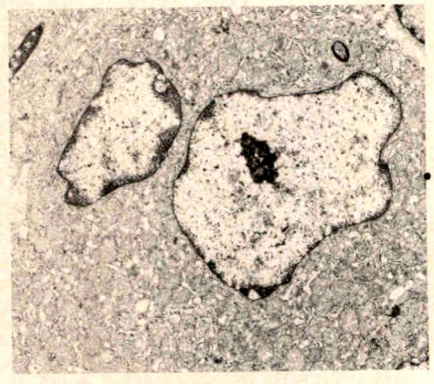

Fig 8.—Histiocytic cell with abundant mitochondria and sparse endoplasmic reticulum but few granules (original magnification, ×6,000).

blastic features[19,20] or varying combinations of histiocytic and fibroblastic features.[21] Hashimoto et al[22] have suggested the cell to be a fibroblast with some neural (perineural and endoneural) features.

Our own ultrastructural observations indicate a modified fibroblast as the basic cell type and support the classification of the dermatofibrosarcoma protuberans as a fibrous histiocytic tumor. The abundant rough endoplasmic reticulum, large Golgi complex, and association of the cell membrane with a collagenous matrix are all features associated with normal and neoplastic fibroblasts.[23] Intracytoplasmic microfilaments are common to both fibroblasts and histiocytes.[1,24]

Phagocytosed lipid is regularly seen in the histiocytes of fibrous histiocytomas.[1,24] The presence of nonmembrane-bound-lipid in fibroblasts is somewhat more unusual but has been observed in these tumors and in numerous other collagen synthesizing situations.[21,25-27] The adherens-type junctions observed between adjacent cells in our case are characteristic of the nonepithelial junctions seen between mesenchymal cells.[28,29]

The malignant potential of the dermatofibrosarcoma protuberans has remained a controversial issue as well. Despite its propensity to recur locally with infiltration of surrounding tissues and the formation of satellite nodules, reports of visceral and lymph node metastases have been rarely described.[14] Indeed, the largest series, which included 115 cases, six with regional lymphadenectomies, did not include a single case of visceral or nodal metastases.[13] In their series of 30 cases Tremblay et al[20] found no instances of metastases, and in a series of 56 cases Burkhardt et al[30] had only one patient who was suspected to die of metastatic spread. However, in another large series of 85 cases, McPeak et al[31] found visceral metastases in five patients. No tumor was found in regional lymph node dissections in eight of the patients in this study. This large series, while substantiating the indolent nature of the tumor, confirmed its infrequent, though definite ability to metastasize, an issue that is now presumably at rest.

The atypical fibroxanthoma of the skin, described by Helwig in 1963,[32] is a lesion that is also considered to be within the family of the fibrous histiocytomas.[1,7] Despite its bizarre and seemingly malignant histologic appearance, reports in the decade after its description emphasized a benign clinical course.[7-9]

Recently, however, a case of blood-borne metastasis was seen by Fretzin and Helwig,[10] and a case of cervical lymph node metastasis was reported by Jacobs et al.[11] It therefore appears that a dogmatic approach to the "pseudosarcomatous" appearance of the atypical fibroxanthoma of the skin may be misleading. Perhaps its superficial location and relatively small size contribute to the usual indolent course.

At the present time, we believe the two lesions under consideration should be treated with a wide local excision, reserving the option of a regional lymph node dissection should evidence of metastasis appear. Reports with long-term follow-up of patients with either lesion with lymph node or visceral metastases are needed to define the best therapy and prognosis for those patients with evidence of metastatic spread.

After this manuscript was accepted for publication and 21 months after radical neck surgery the patient developed other satellite nodules in the neck, a mass in the right axilla, and roentgenographic evidence of lung metastases. Needle biopsy specimen of one satellite nodule showed tumor histologically similar to that seen in previous excisions of the neck mass. No further therapy has been given.

References

1. Fu Y-S, Gabbiani G, Kaye GI, et al: Malignant soft tissue tumors of probable histiocytic origin (malignant fibrous histiocytomas): General considerations and electron microscopic and tissue culture studies. *Cancer* 35:176-198, 1975.
2. Kempson RL, Kyriakos M: Fibroxanthosarcoma of the soft tissues: A type of malignant fibrous histiocytoma. *Cancer* 29:961-976, 1972.
3. Ozzello L, Hamels J: The histiocytic nature of dermatofibrosarcoma protuberans: Tissue culture and electron microscopic study. *Am J Clin Pathol* 65:136-148, 1976.
4. Soule EH, Enriquez P: Atypical fibrous histiocytoma, malignant fibrous histiocytoma, malignant histiocytoma, and epithelioid sarcoma: A comparative study of 65 tumors. *Cancer* 30:128-143, 1972.
5. Spanier SS, Enneking WF, Enriquez P: Primary malignant fibrous histiocytoma of bone. *Cancer* 36:2084-2098, 1975.
6. Stout AP, Lattes R: *Tumors of the Soft Tissues.* Atlas of Tumor Pathology, Armed Forces Institute of Pathology, 1967, series 2, pt 1.
7. Vargas-Cortes F, Winkelmann RK, Soule EH: Atypical fibroxanthomas of the skin: Further observations with 19 additional cases. *Mayo Clin Proc* 48:211-218, 1973.
8. Hudson AW, Winkelmann RK: Atypical fibroxanthoma of the skin: A reappraisal of 19 cases in which the original diagnosis was spindle-cell squamous carcinoma. *Cancer* 29:413-422, 1972.
9. Kempson RL, McGavran MH: Atypical fibroxanthomas of the skin. *Cancer* 17:1463-1471, 1964.
10. Fretzin DF, Helwig EB: Atypical fibroxanthoma of the skin: A clinicopathologic study of 140 cases. *Cancer* 31:1541-1552, 1973.
11. Jacobs DS, Edwards WD, Ye RC: Metastatic atypical fibroxanthoma of skin. *Cancer* 35:457-463, 1975.
12. O'Brien JE, Stout AP: Malignant fibrous xanthomas. *Cancer* 17:1445-1455, 1964.
13. Taylor HB, Helwig EB: Dermatofibrosarcoma protuberans: A study of 115 cases. *Cancer* 15:717-725, 1962.
14. Brenner W, Schaefler K, Chhabra H, et al: Dermatofibrosarcoma protuberans metastatic to a regional lymph node: Report of a case and review. *Cancer* 36:1897-1902, 1975.
15. Darier J, Ferrand M: Dermatofibromes progressifs et recidivants ou Fibrosarcomes de la peau. *Ann Dermatol* 5:545-562, 1924.
16. Hoffmann E: Über das knollentreibende Fibrosarkom der Haut (Dermatofibrosarkoma protuberans). *Dermatol Z* 43:1-28, 1925.
17. Binkley GW: Dermatofibrosarcoma protuberans. *Arch Dermatol* 40:578-592, 1939.
18. Pack GT, Tabah EJ: Dermatofibrosarcoma protuberans: A report of 39 cases. *Arch Surg* 62:391-411, 1951.
19. Aübock L: Zur Ultrastruktur fibröser und histiocytärer Hauttumoren (Dermatofibrom, Dermatofibrosarcoma protuberans, Fibroxanthom und Histiocytom). *Virchow's Arch (Pathol Anat)* 368:253-274, 1975.
20. Tremblay M, Bonenfant J-L, Cliche J: Le dermatofibrosarcome protuberant: Etude clinicopathologique de trente cas avec l'ultrastructure de deux cas. *Union Med Can* 99:871-876, 1970.
21. Fisher ER, Vuzevski VD: Cytogenesis of schwannoma (neurilemoma), neurofibroma, dermatofibroma, and dermatofibrosarcoma as revealed by electron microscopy. *Am J Clin Pathol* 49:141-154, 1968.
22. Hashimoto K, Brownstein MH, Jakobiec FA: Dermatofibrosarcoma protuberans: A tumor with perineural and endoneural cell features. *Arch Dermatol* 110:874-885, 1974.
23. Ross R: The connective tissue fiber forming cell, in Gould BS (ed): *Treatise on Collagen:* II. *Biology of Collagen,* pt A. New York, Academic Press Inc, 1968, p 1.
24. Merkow LP, Frich JC, Slifkin M, et al: Ultrastructure of a fibroxanthosarcoma (malignant fibroxanthoma). *Cancer* 28:372-383, 1971.
25. Fernando NVP, Movat HZ: Fibrillogenesis in regenerating tendon. *Lab Invest* 12:214-229, 1963.
26. Greenlee TK Jr, Ross R: The development of the rat flexor digital tendon: A fine structure study. *J Ultrastruct Res* 18:354-376, 1967.
27. McGee JO'D, Patrick RS: The role of perisinusoidal cells in hepatic fibrogenesis: An electron microscopic study of acute carbon tetrachloride liver injury. *Lab Invest* 26:429-440, 1972.
28. Ross R, Greenlee TK Jr: Electron microscopy: Attachment sites between connective tissue cells. *Science* 153:997-999, 1966.
29. Weinstein RS, McNutt NS: Cell junctions. *N Engl J Med* 286:521-524, 1972.
30. Burkhardt BR, Soule EH, Winkelmann RK, et al: Dermatofibrosarcoma protuberans: Study of 56 cases. *Am J Surg* 111:638-644, 1966.
31. McPeak CJ, Cruz T, Nicastri AD: Dermatofibrosarcoma protuberans: An analysis of 86 cases, five with metastasis. *Ann Surg* 166:803-816, 1967.
32. Helwig EB: Atypical fibroxanthoma. *Tex Med* 59:644-667, 1963.

Angioimmunoblastic Lymphadenopathy

A Generalized Lymphoproliferative Disorder With Cutaneous Manifestations

Ronald B. Matloff, MD, Richard S. Neiman, MD

• Angioimmunoblastic lymphadenopathy (AIBL) is a recently described, systemic disorder characterized by an excessive proliferation of transformed lymphocytes, possibly the result of chronic antigenic stimulation, frequently by drugs. Cutaneous involvement, usually in the form of a pruritic, generalized, maculopapular rash, occurs in about 40% of cases. We saw a patient with AIBL who had an unusual, primarily plaque- and nodular-type of skin involvement and who had been receiving drugs not previously reported as being associated with this disorder. Because cutaneous involvement is a frequent, presenting complaint, dermatologists should be able to recognize this unusual, clinicopathologic entity.

(*Arch Dermatol* 114:92-94, 1978)

Angioimmunoblastic lymphadenopathy (AIBL) has recently been described as a newly recognized, clinicopathologic entity.[1-4] Its manifestations are believed to be the consequence of a persistent, nonneoplastic proliferation of B lymphocytes, possibly precipated by chronic antigenic stimulation, often by drugs. Patients with this disorder are in general elderly and show clinical signs of fever, weight loss, generalized lymphadenopathy (present in all cases), hepatosplenomegaly, maculopapular rash, polyclonal hypergammaglobulinemia, and Coombs'-positive hemolytic anemia. The specific histopathologic triad in biopsy specimens of lymph nodes includes the following: (1) a pleomorphic cellular infiltrate that effaces nodal architecture and is composed of small and large lymphocytes, immunoblasts, and plasma cells, with varying numbers of accompanying histiocytes and eosinophils; (2) arborizing vascular proliferation and endothelial cell hyperplasia; and (3) interstitial deposition of an amorphous, acidophilic material. Morphologic evidence of systemic involvement in skin, bone marrow, liver, spleen, and lung is common, but is not as distinctive as the lesions seen in lymph nodes.[1] Prior to the recognition of this entity, most cases were misdiagnosed as lymphoma, both because of the aggressive clinical behavior seen in some cases and because of the histopathologic tendency of this disease to infiltrate the node capsule and perinodal fat, features often regarded as criteria for malignancy. Because occasional immunoblasts in the lesion appear multinucleate and resemble Reed-Sternberg cells, Hodgkin's disease was the most frequent misdiagnosis. Two general patterns of clinical evolution have been observed: (1) long-term survival with occasional spontaneous remission, with or without therapy (steroid or cytotoxic agents), or (2) rapid, fatal deterioration despite all therapeutic efforts, with death usually secondary to infection.

Involvement of the skin occurs in about 40% of patients with AIBL and is typified by a pruritic, generalized, maculopapular rash. Of those patients with skin involvement, 80% are found to have a history of prior drug use. We treated a patient with AIBL and skin involvement; he has been taking drugs not previously reported as being associated with this disorder. His skin involvement was unusual in that it was manifested primarily by large plaques and nodules.

REPORT OF A CASE

A 77-year-old man, a retired office worker, was admitted to University Hospital, Boston University Medical Center, following the abrupt onset and rapid

Accepted for publication Nov 29, 1976.

From the Departments of Dermatology (Dr Matloff) and Mallory Institute of Pathology (Dr Neiman), Boston University Medical Center.

Reprint requests to Department of Dermatology, Boston University Medical Center, Boston, MA 02118 (Dr Matloff).

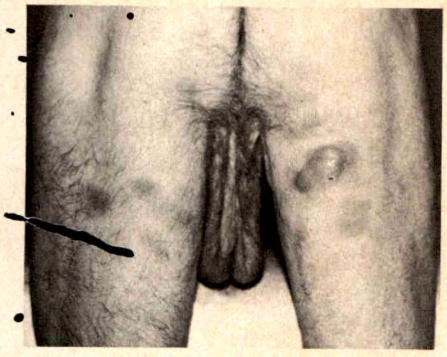

Fig 1.—Plaques and nodules of angioimmunoblastic lymphadenopathy.

enlargement of a painless swelling in the right axilla beginning one week prior to admission.

Approximately one year prior to admission he had noted the onset of a pruritic, generalized, morbilliform eruption. Plaques and nodules subsequently developed, particularly in areas that were rubbed or excoriated. Older lesions eventually regressed and disappeared, while new lesions developed in new areas. Constitutional symptoms were not present. He was first seen two months prior to admission. Skin biopsy findings of a nodular lesion were reported as showing a diffuse monomorphous round cell infiltrate with rare mitoses. Results of a second skin biopsy of another lesion six weeks later showed a noncaseating tuberculoid type granuloma. Both PAS and acid-fast stains were negative for organisms.

The past medical history disclosed mild, essential hypertension since 1962, presently treated with methyldopa, 250 mg/day, and triamterene-hydrochlorthiazide, one capsule daily, which he had been taking regularly for several years. In addition, he had been taking allopurinol, 200 mg/day, since 1973 for gouty arthritis. The review of systems and family history were noncontributory.

Physical examination showed multiple, nontender, firm, purple nodules, tumors, and plaques primarily involving both lower extremities (Fig 1). A soft, approximately 10-cm, right axillary mass was present as well as bilateral, inguinal adenopathy. Liver and spleen were not palpable and results from the remaining physical examination were normal.

Laboratory values were as follows: hemoglobin, 13.1 gm; hematocrit, 38.3%; WBC count, 6,400/cu mm, with 85 polymorphonuclear lymphocytes, 4 band forms, 5

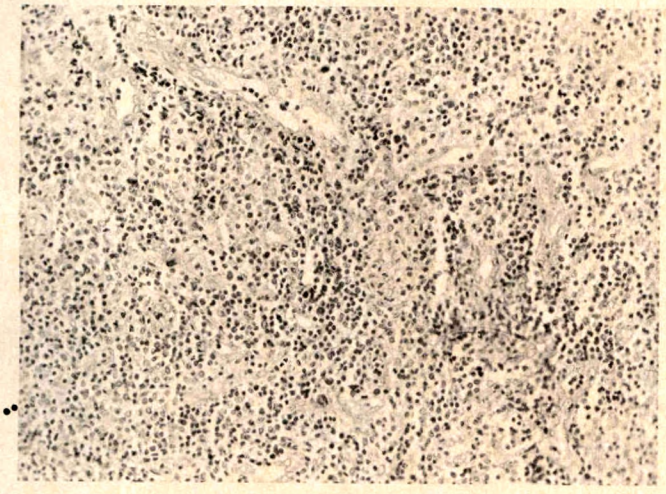

Fig 2.—Lymph node showing lymphocytes, plasmacytoid cells, immunoblasts, vascular proliferation, and interstitial amorphous material, features characteristic of angioimmunoblastic lymphadenopathy with dysproteinemia (PAS, original magnification ×500).

Fig 3.—Low-power view of skin lesion initially believed to represent noncaseating atypical tuberculoid granuloma (hematoxylin-eosin, original magnification ×50).

Fig 4.—Details of skin lesion showing dermal pleomorphic cellular infiltrate and amorphous material (hematoxylin-eosin, original magnification ×400).

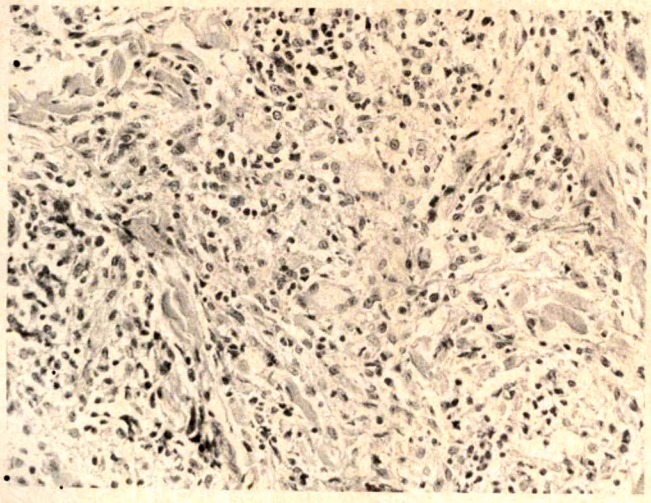

Fig 5.—Different section from same skin lesion as in Fig 4, showing degree of vascular proliferation (PAS, original magnification ×400).

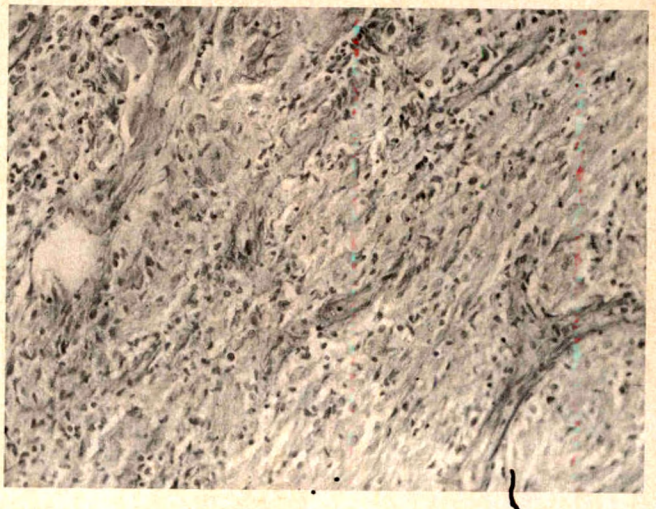

lymphocytes, and 6 monocytes; sedimentation rate, 97 mm/hr; platelets, 385,000/cu mm; prothrombin time, 11.2/11.3; and partial thromboplastin time, 30/33. Urinalysis, chest roentgenogram, and ECG were considered within normal limits. Serum protein electrophoresis showed a polyclonal gammopathy: total protein was 8.8 gm (normal, 6.0 to 8.0 gm); albumin, 4.1 gm (normal 3.5 to 5.5 gm); α_1-globulin, 0.3 gm (normal, 0.2 to 0.4 gm); α_2-globulin, 0.5 gm (normal, 0.5 to 0.9 gm); β-globulin, 0.8 gm (normal, 0.6 to 1.1 gm); and γ-globulin, 3.1 gm (normal, 0.7 to 1.7 gm). Liver-spleen scan indicated splenomegaly. Liver function tests results were normal except for elevated lactic dehydrogenase (LDH) level: SGOT, 40 units (normal, 1 to 40 units); alkaline phosphatase, 109 units (normal, 30 to 115); bilirubin (total), 0.4 mg (normal, less than 1.1 mg); and LDH, 134 units (normal, 30 to 120 units). Coombs' test results were negative. Two additional punch biopsy procedures of skin lesions were reported as showing a noncaseating, atypical tuberculoid-type granuloma with nonspecific perivascular dermatitis. However, results of a biopsy of the right axillary mass were diagnostic of angioimmunoblastic lymphadenopathy (Fig 2). Subsequent review of the skin specimens taken earlier revealed them to be indistinguishable from those described before by Frizerra and his colleagues and showed a lymphocytic cellular infiltration of the dermis, a degree of small vessel proliferation, and amorphous interstitial material (Fig 3 through 5).[1]

Antihistamines were given and skin lesions began to involute during hospitalization. Allopurinol therapy was discontinued. One month following the onset of adenopathy, skin lesions and node enlargement had completely subsided. The patient remains free of any constitutional symptoms or recurrence of lesions four months later. Steroid or cytotoxic therapy has not been needed.

COMMENT

Angioimmunoblastic lymphadenopathy has been the subject of several recent, comprehensive reviews.[1-4] Our purpose in reporting this case is to comment on certain aspects of this unusual disorder as it relates to clinical dermatology and to bring this disorder to the attention of the clinician.

Certain patients with AIBL probably represent those having drug reactions. Previous authors[1,2] have reported penicillin, sulfonamides, aspirin, halothane, phenytoin sodium, and griseofulvin as possible offending agents. Our patient had been receiving several medications not previously reported as associated with this disorder—allopurinol, methyldopa, and triamterene-hydrochlorthiazide. As physicians who are frequently called on to deal with drug reactions, an awareness of this disorder should lead to better and perhaps increased recognition, as well as, ultimately, better understanding of this unusual immunologic disorder.

Almost all cases of AIBL with skin involvement have been characterized as maculopapular eruptions. One patient was reported to have, in addition to a maculopapular rash, several small, painless, subcutaneous nodules of the face and trunk.[1] Frizerra et al have reported that the histopathologic features of AIBL occur in maculopapular-type skin lesions but that the characteristic, vascular proliferative changes seen in lymph nodes are not as apparent. Ultrastructural studies by one of us (R.S.N.) of lymph node, spleen, bone marrow, and skin lesions in six patients support these authors' findings.[5] Our patient originally had a maculopapular rash that became primarily nodular and plaque-like, suggestive of mycosis fungoides or lymphoma cutis. Pseudolymphoma, insect bite reaction, lymphomatoid papulosis, and drug reaction were included in the clinical differential diagnosis. The pathologic changes of our patient's skin lesions initially were interpreted as an atypical tuberculoid granuloma. However, subsequent results of a lymph node biopsy were diagnostic of AIBL, and, on retrospective examination, a pleomorphic cellular reaction, amorphous material, and some degree of vascular proliferation could be seen when specifically looked for after further tissue examination. It is, therefore, apparent to us that the histology of AIBL in skin, an extranodal tissue, may go unrecognized, especially when clinicopathologic correlation with nodal lesions is unavailable. We wish to emphasize that this entity may occur with skin lesions, that dermatologists should be aware of it, and that in suspected cases, a lymph node biopsy should be done to confirm the diagnosis.

Nonproprietary Names and Trademarks of Drugs

Allopurinol—*Zyloprim.*
Hydrochlorothiazide—*Aquarius, Esidrix, Hydril, Hydrodiuril, Oretic.*
Methyldopa—*Aldomet.*

References

1. Frizzera G, Moran EM, Rappaport H: Angioimmunoblastic lymphadenopathy: Diagnosis and clinical course. *Am J Med* 59:803-817, 1975.
2. Lukes RJ, Tindle BH: Immunoblastic lymphadenopathy: A hyperimmune entity resembling Hodgkin's disease. *N Engl J Med* 292:1-8, 1975.
3. Frizzera G, Moran EM, Rappaport H: Angioimmunoblastic lymphadenopathy with dysproteinemia. *Lancet* 1:1070-1073, 1974.
4. Moore S, Harrison E, Weiland L: Angioimmunoblastic lymphadenopathy. *Mayo Clin Proc* 51:273-280, 1976.
5. Neiman RS, Dervan P, Haudenschield C, et al: Angioimmunoblastic lymphadenopathy: Ultrastructural and immunologic studies with review of the literature. *Cancer*, to be published.

Linear Unilateral Basal Cell Nevus With Comedo-like Lesions

Takeshi Horio, MD, Jinro Komura, MD

• A 20-year-old woman had linear unilateral basal cell nevus with comedo-like lesions. Numerous papules were distributed on the left side of the upper aspect of the trunk in a zosteriform fashion. The individual lesions were hemispherical, pearly, and waxy tumors, some of which had central plugs. Histologic examination revealed polymorphous patterns that suggested that the tumor cells differentiated toward the apocrine glands, hair structures, and sebaceous glands. Ultrastructurally, the tumor strands were composed of fairly mature basal cells with well-developed tonofilaments and desmosomes.

(*Arch Dermatol* 114:95-97, 1978)

Few cases of linear unilateral basal cell nevus (LBCN) have been reported since Carney[1] first described a patient. We present a case of LBCN that is very similar to that reported by Carney. Also, we examined the tumor cells electron microscopically.

REPORT OF A CASE

A 20-year-old Japanese woman was first seen in December 1970 because of numerous papules scattered on the left side of the upper aspect of the trunk. These lesions had been present for as long as the patient could remember, and there had been no notable changes in number and size during the past few years. No other members of the family had similar skin lesions.

Examination of the skin showed numerous lesions arranged in zosteriform fashion on the left side of the chest (Fig 1) and upper part of the back (Fig 2). On the left flank, the two patches of lesions were connected by a narrow band of lesions. Individual tumors were hemispherical, pearly, and waxy, and ranged from 1 to 5 mm in diameter. Their color varied from that of normal skin to brown. The tumors situated around the left areola were larger and more pigmented than those in other areas; a few appeared yellowish (Fig 1). Some tumors had central plugs that could be extruded by pressure (Fig 3).

No pit-like depressions were observed on the palms and soles. Roentgenographic examination revealed no skeletal abnormalities. Results of routine laboratory examination remained within normal limits.

LIGHT MICROSCOPICAL FINDINGS

Biopsy specimens from the chest, back, and areola were stained with hematoxylin-eosin (HE), toluidine blue, and PAS. Almost all biopsy specimens had similar histological features and showed strands of new growth of basaloid cell in the upper and middle parts of the dermis (Fig 4). Furthermore, in some sections from the chest and back, several horn cysts were observed within the masses of the basaloid cells, and some sections from the areola revealed numerous sebaceous glands (Fig 5). The histologic examination of the tumor with a clinically evident comedo-like plug showed dilated hair follicle filled with keratinous or sebaceous material. The strands of basaloid cells in the dermis formed a lacelike or latticelike network, and they connected at various sites with the basal layer of epidermis or pilosebaceous follicles. At the periphery of the tumor masses, several buds of basaloid cells projected into the dermis. The size of the tumor cells was about the same as that of the normal epidermal basal cells. The tumor-cell nuclei were more basophilic, and their cytoplasm took a more eosinophilic staining in HE-stained sections. The nuclei were round or oval, and the cytoplasm showed occasionally PAS-positive staining, especially in the center of the tumor masses. The stroma was edematous and showed a marked increase in acid mucopolysaccharide, as revealed by strongly positive metachromatic reaction with toluidine

Fig 1.—Unilateral distribution of multiple hemispherical papules on left side of chest.

Fig 2.—Numerous lesions arranged in zosteriform fashion on left side of back.

Accepted for publication Dec 29, 1976.

From the Department of Dermatology, Faculty of Medicine, Kyoto University, Kyoto, Japan.

Reprint requests to Department of Dermatology, Faculty of Medicine, Kyoto University, Shogoin, Sakyo-ku, Kyoto, Japan (Dr Horio).

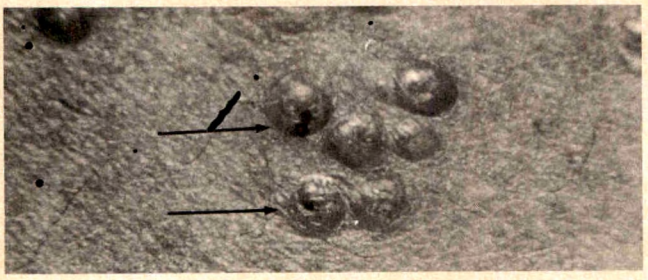

Fig 3.—Papules with comedo-like plug (arrows). Upper arrow shows plug that was extruded by pressure.

Fig 4.—Biopsy specimen from lesion of chest showing basaloid cell new growth that forms lacelike network (hematoxylin-eosin, ×100).

Fig 5.—Biopsy specimen from tumor around areola showing horn cysts and sebaceous gland proliferation (hematoxylin-eosin, ×100).

Fig 6.—Ultrastructurally, strands are composed of elongated dark cells (E), round cells (R), and intermediate cells (I). Intercellular spaces between elongated cells are irregularly dilated, and at periphery they sometimes assume serpiginous configuration (arrow) (uranyl acetate and lead citrate, ×4,500).

blue. Inflammatory cells were minimal to absent in all sections.

ELECTRON MICROSCOPICAL FINDINGS

Half of the biopsy specimen from the chest was fixed in phosphate-buffered, 4% glutaraldehyde, postfixed in 1% osmic acid, dehydrated in ethanol, and embedded in Epon 812. Thin sections were cut with glass knives on an ultramicrotome, stained with uranyl acetate and lead citrate, and examined in electron microscopes.

The tumor strands were composed of the following: elongated, dark-staining cells; round or oval cells; and intermediate cells (Fig 6). The elongated cells made up the major part of the tumor and often palisaded at the periphery. The cytoplasm was sparsely distributed about an oblong nucleus. The nucleus contained uniformly dispersed chromatin and a prominent nucleolus. In the cytoplasm (Fig 7), numerous tonofilaments were pres-

Fig 7.—Cytoplasm of elongated cell contains numerous tonofilaments (t) aligning parallel to nucleus. Well-developed desmosomes (d) occur less frequently (×10,000).

Fig 8.—Part of basaloid cell. Well-developed desmosomes (d), half-desmosomes (hd), and tonofilaments (t) are present and morphologically are not different from those seen in normal basal cells; bl, basal lamina (×21,000).

ent mostly in bundles; free ribosomes were abundant. The intercellular spaces were irregularly dilated and formed vesicular spaces. Desmosomes occurred less frequently but, when present, were well developed. The round cells appeared mostly at the periphery, and resembled normal basal cells (Fig 8). The intermediate cells occurred mostly between the round cells but occasionally among the elongated cells.

In the tumor cells, melanosomes or melanosome complexes were seen uncommonly. At the periphery, the cellular margins assumed a more serpiginous configuration, with deep folds or long villous projections of the cell membranes (Fig 6). Half-desmosomes and unbroken basal laminae were regularly observed along the cell surface adjacent to the stroma (Fig 8).

COMMENT

The clinical features are virtually identical to those in the original case report by Carney[1] and other authors. The characteristics of LBCN are the numerous tumors distributed unilaterally in zosteriform fashion and the hemispherical, pearly, and waxy appearance of individual lesions, some of which had central plugs.

Histologic findings were also typical for this disorder and presented "almost the whole catalogue of benign epithelial tumors," as Kligman has stated.[2] All specimens demonstrated a lace-like pattern of basal cell proliferation that resembled an adenoid basal cell epithelioma. Besides this feature, some specimens had changes that resembled a trichoepithelioma or keratotic basal cell epithelioma, and other specimens appeared like a nevus sebaceus. In addition, the downward projection of buds of tumor cells from the epidermis resembled a superficial basal cell epithelioma.

Electron microscopical examination showed that three types of cells were present in the tumor strands of the patient, each of which possessed well-developed tonofilaments and desmosomes. According to Lever and Hashimoto,[3] the immature cells in basal cell epithelioma show only few tonofilaments and desmosomes, as seen in immature embryonic basal cells, particularly those of the primary epithelial germ. As the cells mature, many thick bundles of tonofilaments and well-developed desmosomes become apparent. In the single specimen that was examined in this study, we did not observe the immature cells described in basal cell epithelioma by other authors[4,5]; rather, the elongated and intermediate cells with distinctive tonofilaments and desmosomes resembled those described by Reidbord et al.[6]

The electron microscopical study of nevoid basal cell epithelioma syndrome by Zackheim et al[7] showed that the tumor cells in this syndrome were similar in most respects to those of the usual basal cell epithelioma.

The ultrastructural features demonstrated that the cells that constitute the tumor strands in LBCN were more mature than those of basal cell epithelioma and the nevoid basal cell epithelioma syndrome.

References

1. Carney RG: Linear unilateral basal-cell nevus with comedones: Report of a case. *Arch Dermatol* 65:471-476, 1952.

2. Kligman AM, in discussion with Thomas CC, Aaronson C, Florence R: Multiple basal cell nevi: Seborrheic keratosis, and keratinous cysts, SOCIETY TRANSACTIONS. *Arch Dermatol* 81:326, 1960.

3. Lever WF, Hashimoto K: Electron microscopic and histochemical findings in basal cell epithelioma, squamous cell carcinoma and some appendage tumors. In Jadasshon W, Shirren CG (eds): *XIII Congressus Internationalis Dermatologiae*, Berlin, Springer-Verlag, 1968, vol 1, p 3.

4. Zelickson AS: An electron microscopic study of the basal cell epithelioma. *J Invest Dermatol* 39:183-187, 1969.

5. Brody I: Contributions of the histogenesis of basal cell carcinoma. *J Ultrastruc Res* 33:60-79, 1970.

6. Reidbord HE, Wechsler HL, Fisher ER: Ultrastructural study of basal cell carcinoma and its variants with comments on histogenesis. *Arch Dermatol* 104:132-140, 1971.

7. Zackheim HS, Howell JB, Loud AV: Nevoid basal cell carcinoma syndrome: Some histologic observations on the cutaneous lesions. *Arch Dermatol* 93:317-323, 1966.

Progressive Cribriform and Zosteriform Hyperpigmentation

J. Marvin Rower, MD; Richard D. Carr, MD; Edmund D. Lowney, MD

• Five cases of progressive cribriform and zosteriform hyperpigmentation are described. The following criteria were fulfilled: (1) uniformly tan cribriform macular pigmentation in a zosteriform distribution; (2) a histologic pattern that consisted of a mild increase in melanin pigment in the basal cell layer and complete absence of nevus cells; (3) no history of rash, injury, or inflammation to suggest postinflammatory hyperpigmentation; (4) onset well after birth with gradual extension; and (5) lack of other associated cutaneous or internal abnormalities.

This appears to be a newly described entity, although it resembles a Becker's nevus without hypertrichosis or an atypical café au lait spot. We believe that such progressive cribriform and zosteriform pigmentation is not uncommon.

(*Arch Dermatol* 114:98-99, 1978)

During the past year, we have seen several patients with zosteriform macular pigmented lesions that had progressively enlarged on the lower trunk or thighs. Since the abnormality in pigmentation differs in one way or another from disorders previously described in the dermatologic literature, we present our experiences with it.

REPORT OF CASES

CASE 1.—A healthy 18-year-old man first noted light brown spots on the lower portion of the right side of his back at the age of 13 years (Figure). They had been asymptomatic, and there was no history of rash or injury to the area. Initially, there was gradual extension of this process, but none had been noted recently.

Physical examination showed cribriform macular pigmentation in a zosteriform distribution over the right flank. All macules were uniformly tan. A test for Darier's sign was negative. Results of physical examination were otherwise unremarkable.

Hematoxylin-eosin stains of sections of skin from an area of hyperpigmentation showed an increase in basal layer pigmentation. No dermal vascular abnormality was noted. No nevus cells were present. When Fontana-Masson's stain was used, the pigment stained as melanin. Further, it demonstrated an increased number of small granules per basal cell. No macrogranules were noted, and the granules were randomly distributed throughout the cell. The increased pigmentation along the basal layer of the section was somewhat patchy, ie, not entirely homogeneous.

CASES 2 TO 5.—Data on patients are summarized in the Table.

COMMENT

Each of our patients had a single area of uniformly tan cribriform macular hyperpigmentation in a zosteriform distribution. The lesions were noted on the lower torso or thighs in all five patients. Age at onset was in the second decade of life in every case, and the patients all believed there had been an unequivocal increase in the size of the

Accepted for publication Nov 24, 1976.

From the Division of Dermatology, Ohio State University College of Medicine, Columbus. Dr Rower is now in private practice in Findlay, Ohio.

Reprints not available.

Clinical Data on Five Cases of Cribriform and Zosteriform Hyperpigmentation

Case No.	Age, yr/ Sex	Age at Onset, yr	Location
1	18/M	13	Right flank
2	28/M	18	Right anterior thigh
3	16/F	11	Right anterior thigh and abdomen
4	16/F	10	Right posterior thigh and upper calf
5	37/M	10	Right buttock and thigh

Cribriform hyperpigmentation in zosteriform distribution (patient 1).

pigmented patches. None could recall previous injury to the involved skin. All were in generally good health and were free of other cutaneous abnormalities. Histologic study of biopsy specimens from the involved skin of each patient showed an increase in basal layer pigmentation. No dermal vascular abnormality was noted. No nevus cells were present. Results of a Fontana-Masson's stain confirmed the pigment to be melanin. Further, it demonstrated an increased number of small granules per basal cell. No macrogranules were noted, and the granules were randomly distributed throughout the cell. The increased pigmentation along the basal layer of the section was somewhat patchy, ie, not entirely homogeneous.

After making a careful attempt to identify these lesions as one of the previously described focal abnormalities of pigmentation, we concluded that they represent a previously unreported entity.

Café au lait spots are the hypermelanotic entities that are most like the abnormality described in this report. Although none of our patients had any abnormalities suggestive of neurofibromatosis, tuberous sclerosis, or Albright's syndrome, it is said that up to 10% of the normal population has one or more café au lait spots.[1,2] The patches are cribriform in our cases, rather than continuously tan-brown as in café au lait macules. The lesions arose later in life than should occur with café au lait patches. The patches herein reported have continued to enlarge which is not expected of café au lait spots. Although the zosteriform distribution seen in our cases can occur in the café au lait macules seen in Albright's syndrome,[3] it would be most unusual in the other café au lait entities.

Another entity, similar to the pigmentary disorder herein reported, is Becker's hairy nevus, which may be free of hypertrichosis during its early stages.[4,5] The lack of evolution of any hypertrichosis after several years, the cribriform configuration, and the progressive increase in size distinguishes the abnormality seen in our patients from Becker's nevus.

Such pigmentary abnormalities as nevus spilus,[6] postinflammatory hyperpigmentation as seen after herpes zoster or erythema ab igne (caloricum), and atypical epithelial nevi can be ruled out by the history, clinical manifestations, and/or histologic findings in our cases. Several unusual macular hyperpigmentation patterns have appeared as case reports in the literature, but these also differed from our cases in various respects.[7-13]

Although this pigmentary abnormality seems to be unreported previously, our observance of five cases within a year makes us believe that it is not uncommon.

H. Michael Miller, MD, provided case 2 for this study.

References

1. Crowe FW, Schull WJ, Neel JW: *A Clinical, Pathological, and Genetic Study of Multiple Neurofibromatosis*, publication 281. American Lecture Series, Springfield, Ill, Charles C Thomas Publisher, 1956.
2. Johnson BL, Charneco DR: Café au lait spot in neurofibromatosis and in normal individuals. *Arch Dermatol* 102:442-446, 1970.
3. Benedict PH, Szabó G, Fitzpatrick TB, et al: Melanotic macules in Albright's syndrome and in neurofibromatosis. *JAMA* 205:618-626, 1968.
4. Becker SW: Concurrent melanosis and hypertrichosis in distribution of nevus unius lateris. *Arch Dermatol Syphilol* 60:155-160, 1949.
5. Copeman PWM, Jones EW: Pigmented hairy epidermal nevus (Becker). *Arch Dermatol* 92:249-251, 1965.
6. Cohen HJ, Minikin W, Frank SB: Nevus spilus. *Arch Dermatol* 102:433-437, 1970.
7. Davis DG, Shaw MW: An unusual human mosaic for skin pigmentation *N Engl J Med* 270:1384-1389, 1964.
8. Selmanowitz VJ, Orentreich N: Tardive patterned pigmented macules. *Arch Dermatol* 102:483-484, 1970.
9. Shumate CA: Pigmented unilateral nevus-like lentigo. *Arch Dermatol Syphilol* 43:410, 1941.
10. Becker SW, Reuter MJ: A familial pigmentary anomaly. *Arch Dermatol Syphilol* 40:987-998, 1939.
11. Cappon D: A case of unilateral lentigines with mental deficiency. *Br J Dermatol* 60:371-374, 1948.
12. McKelway JL: Lentigo: unilateral distribution. *NY State J Med* 80:197-198, 1904.
13. Chernosky ME, Anderson DE, Chang JP, et al: Familial progressive hyperpigmentation. *Arch Dermatol* 103:581-598, 1971.

Ichthyosiform Sarcoidosis

Young C. Kauh, MD; Howard E. Goody, MD; PhD; Herbert A. Luscombe, MD

• A 31-year-old black woman had acquired ichthyosis. Histologic examination of her skin revealed a sarcoidal reaction in the dermis. The diagnosis of sarcoidosis was supported by negative tuberculin (intermediate strength purified protein derivative) and *Candida albicans* extract intradermal skin tests; by a positive Kveim test; and by roentgenographic evidence of bilateral hilar adenopathy, paratracheal node enlargement, and diffuse pulmonary parenchymal changes. Sarcoidosis must be considered when acquired ichthyosis develops in a patient.

(*Arch Dermatol* 114:100-101, 1978)

Sarcoidosis is a multisystem granulomatous disorder of unknown etiology. Since the early descriptions of the disease by Hutchinson,[1,2] Besnier,[3] and Boeck,[4] many reports have been published describing the protean clinical presentations of the disorder, including specific and nonspecific cutaneous manifestations. Among the specific cutaneous lesions, an ichthyosiform eruption has very rarely been reported in dermatologic literature.[5,6(pp274-285)] Our patient had ichthyosis on her shins. Histologic examination revealed ichthyosiform changes in the epidermis and a sarcoidal reaction in the dermis. Subsequent evaluation disclosed the presence of systemic sarcoidosis.

Accepted for publication Dec 21, 1976.

From the Department of Dermatology, Thomas Jefferson University Hospital, Philadelphia.

Reprint requests to Department of Dermatology, Thomas Jefferson University Hospital, 1015 Walnut St, Philadelphia, PA 19107 (Dr Kauh).

REPORT OF A CASE

A 31-year-old black woman had enjoyed good health until three months ago when a mildly pruritic eruption developed on her lower legs with the subsequent appearance of lesions on her thighs, lower abdomen, buttocks, back, and arms. She denied any previous episodes of skin lesions, malaise, fever, shortness of breath, dyspnea on exertion, or weight loss. She has not taken any medications. There is no family history of ichthyosis.

Physical examination revealed a woman with diffuse hyperpigmented and hypopigmented large adherent scaly lesions on the anterior aspect of her lower legs (Fig 1). Multiple erythematous slightly indurated, coin-shaped lesions 0.5 to 1 cm in diameter were scattered over her arms, lower back, buttocks, and thighs. There were no lesions on her face.

LABORATORY DATA

Values for serum lactic dehydrogenase, SGOT serum calcium, and serum phosphate were normal. Hemoglobin level was 9.7 gm/100 ml; hematocrit reading was 31.6%; mean corpuscular volume was 67 cu μ; hemoglobin level was mean corpuscular 20.1 pg; mean corpuscular hemoglobin concentration was 30.4%; reticulocyte count was 0.4%, with +2 anisocytosis, and +1 microcytosis. White blood cell count was 4,100/cu mm, with normal differential except for five atypical lymphocytes and 11 eosinophils. Intradermal skin tests were negative to purified protein derivative (intermediate strength, 0.1 μg/0.1 ml) and *Candida albicans* extract, 500 IU/ml. An intradermal injection of Edinburgh antigen for Kveim test evoked a reddish brown nodule that attained a diameter of 10 mm in six weeks. The nodule was excised and examined

Fig 1.—Ichthyosiform eruption of legs.

Fig 2.—Left and right, Low-power and high-power magnifications, respectively, demonstrating hyperkeratosis, thinning of granular layer and mild acanthosis in epidermis, and noncaseating epithelioid tubercle formation in dermis (hematoxylin-eosin, at left, ×100 and at right ×400).

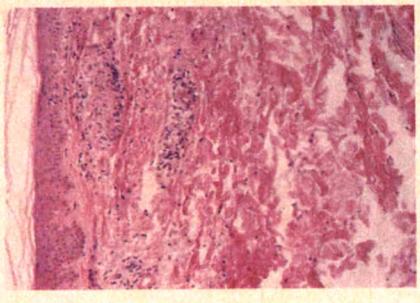

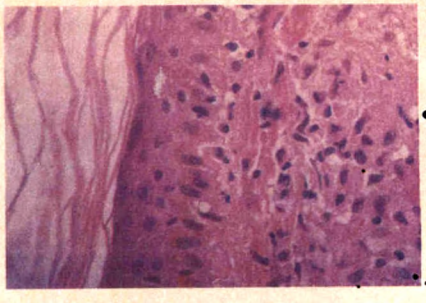

histologically to find epithelioid tubercules. IgG level was within normal limits. IgA and IgM levels were elevated. Results of a routine urinalysis were normal. A roentgenogram of the chest revealed bilateral hilar adenopathy, paratracheal node enlargement, and diffuse parenchymal mottling consistent with sarcoidosis.[7(p1160)]

MICROSCOPIC EXAMINATION

A biopsy specimen from the shin, stained with hematoxylin-eosin, showed epidermal changes consistent with ichthyosis vulgaris, autosomal dominant type, with hyperkeratosis, with thinning or absent granular layer, and with mild acanthosis. In the subepidermal and deeper portions of the dermis, a distinctively noncaseating granulomatous infiltrate was present. Tubercles composed of epithelioid and giant cells were associated with a loose arrangement of lymphocytes (Fig 2). The periodic acid-Schiff reaction and stains for AFB were negative. A biopsy specimen of grossly normal-appearing skin did not show any alteration of normal epidermal and dermal architectures.

COMMENT

Cutaneous manifestations of sarcoidosis are present in approximately 25% to 33% of the cases.[5,8,11] Skin manifestations are classified as specific or nonspecific depending on the presence or absence of noncaseating granulomas. Small papules, primarily on the face, are the commonest specific cutaneous lesions found on patients with sarcoidosis.[5] Erythema nodosum is the most important nonspecific skin response.[11,12] Numerous reports describing various skin eruptions compatible with sarcoidosis appear in the literature; however, a thorough search disclosed only one reference of ichthyosis occurring in conjunction with sarcoidosis.[6]

Acquired ichthyosis has been reported to develop in association with a number of systemic illnesses. It is most frequently associated with Hodgkin's disease.[13,14] It is also known to occur with lymphosarcoma, multiple myeloma,[15] carcinomatosis,[16] drugs,[6(p48)] lepromatous leprosy,[17] and chronic malnutrition.[7(p1162)] In these instances, only ichthyosiform change was present histologically; microscopic alterations suggestive of or diagnostic of the generalized disease process with which they were associated were not present.

Braverman[6] describes one patient in whom an ichthyosis-like eruption developed six months before a diagnosis of generalized sarcoidosis. Histologically, the area of ichthyosis showed a sarcoidial reaction in the dermis.

Other specific cutaneous manifestations of sarcoidosis have also been reported to include ulcerations, alopecia, verrucous lesions, and erythrodermic lesions.[5] Typical noncaseating granulomas have also been described in a persistent pruritic maculopapular dermatosis present for 20 years.[18] Psoriasiform sarcoidosis, histologically demonstrating characteristic changes of both sarcoidosis and psoriasis, is another rare cutaneous manifestation.[5,19-21]

The presence of sarcoidosis in scars and other cutaneous lesions may lead one to postulate the occurrence of a generalized sarcoidal response in the dermis of patients with systemic sarcoidosis. Although no published studies on random skin biopsy specimens of patients with sarcoidosis exist to substantiate or refute this speculation, our histologically normal biopsy specimen results of clinically uninvolved skin do not support this concept.

In our case of ichthyosiform sarcoidosis, we cannot determine whether the ichthyosis and sarcoidosis developed simultaneously or if one change was preceded by the other. No mechanism for the observed changes can be postulated at the present time.

In view of the higher incidence of sarcoidosis among American blacks,[22] coupled with the often asymptomatic nature of the disease,[23] as well as the unusual cutaneous manifestations of sarcoidosis,[24] a patient with acquired ichthyosis needs a skin biopsy. This diagnostic procedure may lead to the discovery of sarcoidosis.

Westwood Pharmaceuticals Inc, New York, assumed the cost of reproducing the color photographs.

Dr Harold Israel of the Department of Internal Medicine, Thomas Jefferson University Hospital performed the Kveim test.

References

1. Hutchinson L: Cases of Mortimer's malady (lupus vulgaris multiplex non-ulcerans et non-serpignosus). *Arch Surg (London)* 9:307-314, 1898.
2. Hutchinson J: *Illustrations of Clinical Surgery*. London, Churchill, 1878, vol 1, p 42.
3. Besnier E: Lupus pernio de la face: Synovites fongueuses (scrofulo-tuberculeuses) symetriques des extremites superieures. *Ann Dermatol Syphiligr (Paris)* 10:333-336, 1889.
4. Boech C: Multiple benign sarcoid of the skin. *J Cutan Genitourin Dis* 17:543-550, 1899.
5. Elgart ML: Skin manifestations of sarcoidosis. Cutis 1:283-291, 1965.
6. Braverman IM: Skin signs of systemic disease. Philadelphia, WB Saunders Co, 1970 pp 68, 274-285.
7. Rook A, Wilkinson DS, Ebey FJG: *Textbook of Dermatology*. Oxford, England, Blackwell Scientific Publications, 1972, vol 2, pp 1162, 1420.
8. Scadding JG: *Sarcoidosis*. London, Eyre & Spottiswoode, 1967, pp 174-194.
9. James DG: Dermatological aspects of sarcoidosis. *Q J Med* 28:109-124, 1959.
10. Sones M, Israel H: *Course and prognosis of sarcoidosis*. *Am J Med* 29:84-93, 1960.
11. Sharma OP: Cutaneous sarcoidosis: Clinical features and management. *Chest* 61:320-325, 1972.
12. Cronin E: Skin changes in sarcoidosis. Postgrad Med J 46:507-509, 1970.
13. Bureau Y, Picard R, Barrire H: Ichthyosis acquire et maladee De Hodgkin. *Ann Dermatologie Syphiligraphe* 85:30-39, 1958.
14. Stephens NA, Rhodes EL: Acquired ichthyosis and steatorrhoea in Hodgkin's disease. *Trans St John's Hosp Dermatol Soc* 50:58-61, 1964.
15. Bluefarb SM: Cutaneous manifestations of multiple myeloma. *Arch Dermatol* 72:506-522, 1955.
16. Van Dijk E: Ichthyosiform atrophy of the skin associated with internal malignant diseases. *Dermatologica* 127:413-428, 1963.
17. Schulz EJ: Ichthyosiform conditions occurring in leprosy. *Br J Dermatol* 77:151-157, 1965.
18. Fong YW, Sharma OP: Pruritic maculopapular skin lesions in sarcoidosis. *Arch Dermatol* 111:362-364, 1975.
19. Klauder JV: Multiple sarcoid-like granulomas of the skin. *Arch Dermatol Syphilol* 12:171-173, 1925.
20. Coombes FC: Sarcoidosis. *Arch Dermatol Syphilol* 27:231-234, 1933.
21. Burgoyne JS, Wood MG: Psoriasiform sarcoidosis. *Arch Dermatol* 106:896-898, 1972.
22. Maycock RI, Bertians P, Morrison CE: Manifestations of sarcoidosis. *Am J Med* 35:67-89, 1963.
23. Bauer HJ, Lofgren S: International study of pulmonary sarcoidosis in mass chest radiography. *Acta Med Scand* 425(suppl):101-105, 1964.
24. Sones M, Israel HL: Course and prognosis of sarcoidosis. *Am J Med* 29:84, 1960.

Dystrophic Xanthomatosis in Mycosis Fungoides

Theodore Rosen, MD

• The condition of a patient with advanced mycosis fungoides was treated with cyclic combination chemotherapy. At the sites of regressing tumors, yellow nodules appeared that were clinically and histologically benign xanthomata. The probable multifactorial pathogenesis of dystrophic xanthomata is discussed and previous case reports are reviewed.

(*Arch Dermatol* 114:102-103, 1978)

The cutaneous manifestations of abnormal lipid metabolism have been of interest for many years. Dystrophic xanthomatosis is the accumulation of lipid-rich foam cells within an area of abnormal or damaged skin. This phenomenon has been infrequently noted in the literature. The purpose of this communication is to report the unusual and striking occurrence of dystrophic xanthomata in conjunction with resolving mycosis fungoides.

Accepted for publication Dec 1, 1976.

From the Department of Dermatology, Baylor College of Medicine, Houston.

Reprints not available.

REPORT OF A CASE

A 56-year-old man had multiple, firm, reddish-pink, lobulated scalp tumors (Fig 1) and a diffuse, pruritic, exfoliative erythroderma. Firm, nontender, matted axillary and inguinal lymphadenopathy was also detected. A diagnosis of plaque-stage mycosis fungoides had been made at another institution 2½ years previously. The patient's condition had been treated with topical mechlorethamine hydrochloride until seven months prior to admission, at which time he was unavailable for follow-up.

With the exception of an elevated lactic dehydrogenase concentration, results of laboratory examinations, including blood chemistry studies performed using automated multiple analysis systems, chest film, ECG, serum protein concentration, and immunoelectrophoresis, were normal. The serum cholesterol level was 214 mg/100 ml, and the level of serum triglycerides was 160 mg/100 ml. A hemogram revealed a hemoglobin level of 14.5 g/100 ml, hematocrit value, 45.2%, WBC count, 13,000/cu mm, and platelet count, 450,000/cu mm. Results of examination of a peripheral leukocyte pellet were negative for Sézary cells.

Histological preparations that had been done 2½ years previously were obtained and reviewed. The specimens showed a polymorphous, dermal infiltrate that included numerous, atypical, mononuclear cells. Pautrier's microabscesses were present in the epidermis. A biopsy specimen from a tumor mass, taken during the current admission, revealed a dense dermal accumulation of large, hyperchromatic, atypical mononuclear cells, with scattered eosinophils and lymphocytes (Fig 2). Electron microscopical examination demonstrated innumerable cells with irregular, serpentine, indented nuclei as described by Lutzner and Jordan.[1]

On light microscopical examination of nodal tissue, dermatopathic lymphadenitis was apparent; electron microscopical investigation, however, revealed sheets and clusters of atypical mononuclear cells with cerebriform nuclei. A lymphangiogram demonstrated greatly enlarged and abnormal inguinal and iliac lymph nodes.

Bone and brain scans were unremarkable, as were upper and lower gastrointestinal series, intravenous pyelogram, and bone marrow aspirate and biopsy studies. Liver-spleen scan indicated splenomegaly. The patient was anergic to streptokinase-streptodornase (SK-SD), *Candida*, purified protein derivative, and *Trichophyton* skin tests.

Cyclic combination chemotherapy for advanced mycosis fungoides was commenced. The therapeutic regimen included: mechlorethamine hydrochloride, 12 mg intravenously (IV), vincristine sulfate, 2 mg IV, and bleomycin sulfate, 4 mg IV on days 1 and 8; prednisone, 80 mg orally, and procarbazine hydrochloride, 200 mg orally on days 2 through 7 and days 9 through 14; rest period (no drugs), days 15 through 28.

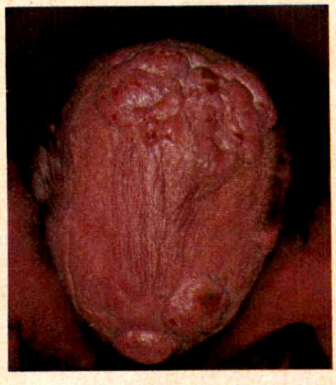

Fig 1.—Mycosis fungoides tumors before therapy.

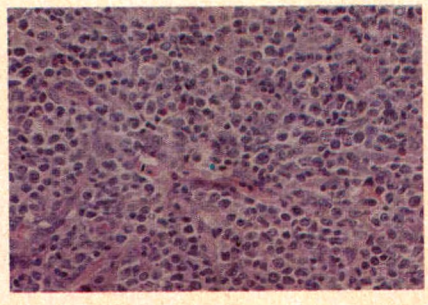

Fig 2.—Cellular infiltrate before therapy (hematoxylin-eosin, original magnification ×160).

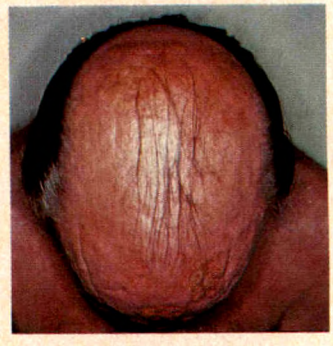

Fig 3.—Dystrophic xanthomata at previous tumor sites.

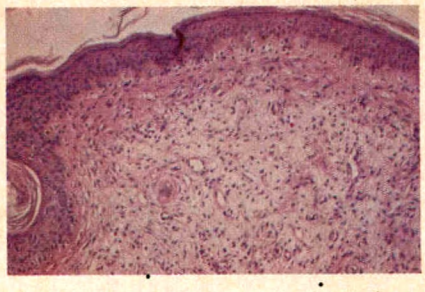

Fig 4.—Biopsy specimen from dystrophic xanthomata showing foam cells (hematoxylin-eosin, original magnification ×80).

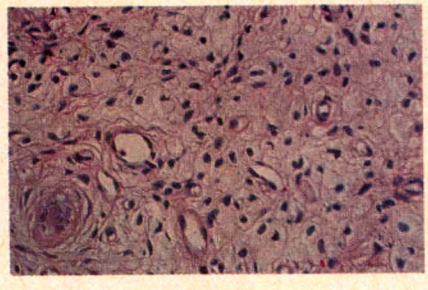

Fig 5.—Cells in dystrophic xanthomata. Note absence of atypical mononuclear cells (hematoxylin-eosin, original magnification ×250).

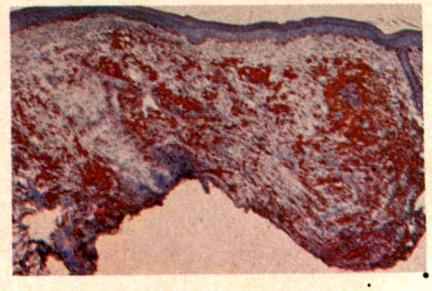

Fig 6.—Abundant lipid within dystrophic lesions (oil-red O, original magnification ×20).

Following four courses of chemotherapy, the scalp nodules regressed notably, but soft, bright-yellow plaques were apparent at the same sites (Fig 3). Tissue that was obtained adjacent to sites of prior biopsy revealed an infiltrate of benign-appearing foam cells and a striking absence of the large, atypical cells previously noted (Fig 4 and 5). Frozen sections stained with oil red O and Sudan IV confirmed heavy lipid deposition (Fig 6). Schultz's stain and Baker's acid hematin stain were positive for cholesterol and phospholipid, respectively. Polariscopical examination was positive for cholesterol esters. The serum cholesterol value was 266 mg/100 ml, and the serum triglyceride level was 224 mg/100 ml (age-corrected normal is up to 180 mg/100 ml). Lipoprotein electrophoresis revealed type IV hyperlipoproteinemia. Serum glucose concentration was within normal limits (114 mg/100 ml) and glycosuria was absent.

COMMENT

In both normolipemic and hyperlipoproteinemic states, substantial lipid deposition can occur in areas of abnormal skin. Such dystrophic xanthomatosis, however, is rarely documented in the literature and is given only cursory mention in most textbooks.

In situations where serum lipids are greatly elevated, dystrophic xanthomata may be encountered in a wide variety of situations. Major[2] described a diabetic with hypercholesterolemia who developed xanthomata at the sites of mosquite bites, and Ochs[3] noted xanthoma formation within fresh vaccination scars in a similar clinical background. Weidman and Stokes and Boston[4,5] reported the occurrence of xanthomata in herpes zoster and laparotomy scars in patients who had underlying hypercholesterolemia. Lipid deposition has been reported within striae[6] and within an epidermal nevus[7] during episodes of marked hyperlipoproteinemia.

Dystrophic xanthomatosis also occurs in the normolipemic patient, largely in areas of persistent inflammation. Walker and Musselman[8] note lipid deposition at the site of recurrent phlebitis and lymphangitis. Marks and Wilson-Jones[9] describe a normolipemic individual whose xanthomata arose within areas of chronic photosensitivity. Walker and Sneddon[10] reported four cases of widespread xanthoma formation following exfoliative erythroderma. Without elaboration, several reviews briefly mention lipid deposition within degenerating, cutaneous neoplasms.[11,12]

The pathogenesis of xanthomatosis in the present case is most likely multifactorial. The patient's hyperlipoproteinemia created a milieu in which xanthoma formation would be a likely event. Initially normal, his serum lipid levels rose following treatment with prednisone. Although steroid administration at first depresses cholesterol and triglyceride levels,[13,14] continued therapy may result in an endogenous hypertriglyceridemia and a type IV hyperlipoproteinemia.[14-16] Tracing of radioactively labeled plasma lipids[17] and sequential electron microscopical examination of experimental xanthomas[18] demonstrate that circulating lipoproteins do indeed contribute to xanthoma formation.

Despite elevated serum triglyceride and normal serum cholesterol levels, however, it is not surprising that the xanthomata contained free cholesterol, cholesterol esters, and phospholipid. In mature xanthomas, it has been demonstrated that the lipid that is deposited bears no distinct relationship to the type of circulating, excess lipoprotein.[19-21] Phospholipids and cholesterol esters are, in fact, the products of local synthetic activities of the histiocytic cells that comprise xanthomata.[22-24] Moreover, in the present case, free cholesterol and other intracellular lipids that are released from degenerating tumor cells would contribute to the ultimate composition of the xanthomas.

It is understandable that the xanthomata were limited to and localized in the sites of tumors. Vascular granulation tissue that replaces degenerating tumor masses would bring circulating monocytes and lipids to these areas. Tissue destruction would favor the functional conversion of monocytes into macrophages and the proliferation of available tissue phagocytes. These mononuclear scavengers, the basic cellular components of xanthomas, then would ingest both locally released lipids and those derived from serum excesses.

In this case, it is unlikely that xanthoma formation is merely secondary to the presence of a reticuloendothelial neoplasm. Xanthomata that have been formed in such instances are flat, generalized, and unassociated with serum lipid abnormalities.[25]

Westwood Pharmaceuticals, Inc, Buffalo, provided the cost of color reproductions.

Nonproprietary Names and Trademarks of Drugs

Bleomycin sulfate—*Blenoxane*.
Vincristine sulfate—*Oncovin*.

References

1. Lutzner MA, Jordan HW: The ultrastructure of an abnormal cell in Sézary's syndrome. *Blood* 31:719-726, 1968.
2. Major RH: Xanthoma diabeticorum. *Bull Johns Hopkins Hosp* 35:27-32, 1924.
3. Wise F, Gilmour A, Fox H, et al, in discussion, Ochs B: Xanthoma tuberosum. *Arch Dermatol Syphilol* 22:922-923, 1930.
4. Weidman FD, Stokes J: Extensive xanthoma tuberosum in childhood due to infectious cirrhosis of the liver: Development of xanthomatous changes in laparotomy scars. *Am J Dis Child* 53:1230-1244, 1937.
5. Weidman F, Boston LN: Generalized xanthoma tuberosum with xanthomatous changes in fresh scars of intercurrent zoster. *Arch Intern Med* 59:793-822, 1937.
6. Asboe-Hansen G: Diabetic hyperlipemia with eruptive xanthomatosis and lipid deposition in striae gravidarum. *Acta Dermato-Venereologica* 39:344-347, 1959.
7. Edelstein AJ, Beerman CA, Greene RC: Secondary eruptive xanthoma and naevus unius lateris with lipoid nephrosis. *Arch Dermatol* 72:275-276, 1955.
8. Walker EE, Musselman MM: Xanthomas at sites of infection and trauma. *Arch Surg* 94:39-40, 1967.
9. Marks R, Wilson-Jones E: Light sensitivity and secondary plane xanthoma. *Br J Dermatol* 85:297-298, 1971.
10. Walker AE, Sneddon JB: Skin xanthoma following erythroderma. *Br J Dermatol* 80:580-587, 1968.
11. Stewart MJ: On the cellular reactions induced by local deposits of cholesterol in tissues. *J Path Bact* 19:305-314, 1915.
12. Polano MK: Cutaneous xanthomatosis in relation to the blood lipoprotein pattern. *Br J Dermatol* 81(suppl):2:39-48, 1969.
13. Kyner JL, Levy RI, Soeldner JS, et al: The short term effect of cortisone acetate upon fasting triglyceride and cholesterol in normal subjects and offspring of diabetic couples. *Metabolism* 21:329-336, 1972.
14. Skanse B, Von Stundnitz W, Skoog N: The effect of corticotrophin and cortisone on serum lipids and lipoproteins. *Acta Endocrinologica* 3:442-450, 1959.
15. El-Shaboury AH, Hayes TM: Hyperlipidemia in asthmatic patients receiving long-term steroid therapy. *Br Med J* 2:85-86, 1973.
16. Bagdade JD, Porte D, Bierman EL: Steroid induced lipemia: A complication of high dosage corticosteroid therapy. *Arch Intern Med* 125:129-134, 1970.
17. Scott PJ, Winterbourn CC: Low-density lipoprotein accumulation in actively growing xanthomas. *J Atheroscler Res* 7:207-223, 1967.
18. Parker F, Odland GF: Experimental xanthoma. *Am J Pathol* 53:537-567, 1968.
19. Baes H, van Gent CM, Pries C: Lipid composition of various types of xanthoma. *J Invest Dermatol* 51:286-293, 1968.
20. Jepson EM, Billimoria JD, Maclagan NF: Serum and tissue lipids in patients with familial xanthomatosis. *Clin Sci* 29:383-390, 1965.
21. Fletcher RF, Gloster J: The lipids in xanthomata. *J Clin Invest* 43:2104-2111, 1964.
22. Wilson JD: Studies on the origin of the lipid components of xanthomata. *Circ Res* 12:472-478, 1963.
23. Day AJ, French JE: The synthesis and hydolysis of cholesterol ester by cells of the reticuloendothelial system. *QJ Exp Physiol* 44:239-243, 1959.
24. Day AJ, Gould-Hurst PRS, Wilkinson GK: The incorporation of ^{14}C-labelled particulate cholesterol into lipoprotein by macrophages. *J Atheroscler Res* 4:497-506, 1964.
25. Lynch PJ, Winkelmann RK: Generalized plane xanthoma and systemic disease. *Arch Dermatol* 93:639-646, 1966.

Smooth Muscle Hamartoma Associated With Becker's Nevus

R. Walter Urbanek, MD, Waine C. Johnson, MD

• Two cases of smooth muscle hamartoma with Becker's nevus are reported. Clinically and histologically the lesions resemble Becker's nevi with the exception that on histologic examination a hamartomatous proliferation of smooth muscle is prominent.

***(Arch Dermatol* 114:104-106, 1978)**

In 1949 Becker[1] described two cases of a nevus with "concurrent melanosis and hypertrichosis in the distribution of nevus unius lateralis" that subsequently became known as Becker's nevus.[2] Some twenty-six years earlier, Stokes[3] described a lesion that clinically appeared similar to Becker's nevus but histologically also showed hyperplasia of smooth muscle. Stokes described the patient as "nevus pilaris with hyperplasia of the nonstriated muscle." To our knowledge, there have been no subsequent reported cases of this entity since Stokes' original description. The purpose of this report is to describe two additional cases.

REPORT OF CASES

CASE 1.—A 13-year-old girl complained of a small asymptomatic brown patch that had started on the distal portion of her left thigh two years previously and had spread proximally toward her left hip. The patient stated that the lesion became much darker than her surrounding skin and much more apparent during each summer's sun exposure. An oxybenzone-dioxybenzone sunscreen during the summer resulted in a better cosmetic appearance although the interfollicular areas of the lesion were much lighter than the normal tan surrounding skin. The patient's mother had symmetrical vitiliginous patches on both ankles since the age of 8. The family, and medical history were otherwise unrevealing.

Results of physical examination revealed an 8 × 12-cm macular brown hyperpigmented patch present on the left anterior thigh and hip (Fig 1). The brown pigmentation was much more pronounced relative to the surrounding skin in areas exposed to sun. Slight perifollicular papular elevations were noted about the hair follicles. The hairs in the brown patch were darker and thicker than in the uninvolved skin. The patch felt barely perceptibly firmer than the surrounding skin, no "squirming" was palpated. The patch measured 9.5 × 12 cm on examination one year later.

Two biopsy specimens showed similar features of hyperkeratosis, a mild regular acanthosis, a large amount of pigment in the basal cell layer, mild chronic inflammation in the superficial corium, and replacement of a considerable amount of connective tissue in the middle and lower corium with smooth muscle (Fig 2). Some of the smooth muscle bundles appeared to connect with the arrectores pilorum muscle bundles or to be related to the hair follicles (Fig 2).

The patient was treated with a number of physical and chemical agents on both the uninvolved right thigh and the involved left thigh. Other than blanching with epinephrine and blanching followed by erythema with cold, no palpable or visual changes could be ascertained by these procedures. However, some subjective differences were noted between the involved and uninvolved areas. Because placebo effect and suggestibility were considered likely, some of the compounds were retested. The results are tabulated. The acetylcholine was used within minutes of preparation. The intensity of the response was measured on a subjective scale of 1 to 10.

CASE 2.—A 25-year-old male medical student complained of the development of a dark spot on his back that he first noted in January 1975. He was certain that the lesion had not been present the year prior. He was uncertain as to any relation to sunlight exposure. The lesion was entirely asymptomatic. Medical history included tinea pedis, tinnitus, and bilateral tone decay at 300 Hz. Family history was unremarkable.

Results of physical examination revealed a 6.5 × 3.2-cm irregular brownish patch present on the left lower back (Fig 3). There was no tenderness on palpation, but the skin felt slightly firmer than the surrounding skin. Darker, coarser hairs were seen to grow from the pigmented skin and to a lesser extent on the adjacent nonpigmented skin. On close examination, it was noted that there were perifollicular papules. The areas of hypertrichosis and hypermelanosis were not completely coextensive. The borders were much more irregular although more sharply defined than in case 1.

A biopsy specimen showed mild hyperkeratosis, a moderate regular acanthosis, and increased melanin in the basal cell layer (Fig 4). Throughout the corium there were smooth muscle bundles that were not organized into a tumor mass but were connected with follicular structures.

COMMENT

Clinically, these cases appeared almost identical to Becker's nevi (pigmented hairy epidermal nevus, Becker's melanosis, nevus pigmentosus et tardus, nevoid melanosis).[4] They showed the characteristic features of unilateral hyperpigmented patches with irregular borders, perifollicular accentuation, and hypertrichosis distributed both within and immediately surrounding the pigmented patches.[1] Although the onset of Becker's nevi is more common in the second decade as in case 1, a number have been reported in the third decade as seen in our case 2.[2,5] The striking onset in the patient in case 1 seemingly related to light was reported in Becker's original article. The finding of the lesion in the patient in case 1 outside the distribution of the trunk, although less typical of the classical Becker's nevus, is compatible with the diagnosis.[2-4] The only clinically perceptible difference between these cases and Becker's nevi was a slight palpable increase in the firmness and elasticity of the skin.

Accepted for publication Nov 24, 1976.

From the Departments of Dermatology (Dr Urbanek) and Pathology (Dr Johnson), Temple University (Philadelphia) School of Medicine, and the Skin and Cancer Hospital of Philadelphia.

Reprint requests to Skin and Cancer Hospital, 3322 N Broad St, Philadelphia, PA 19140 (Dr Johnson).

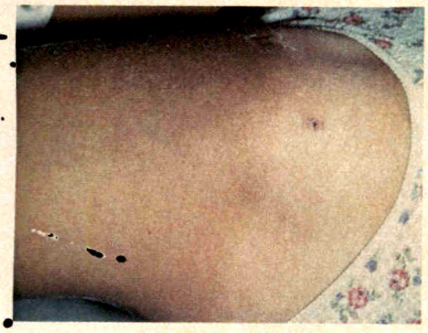

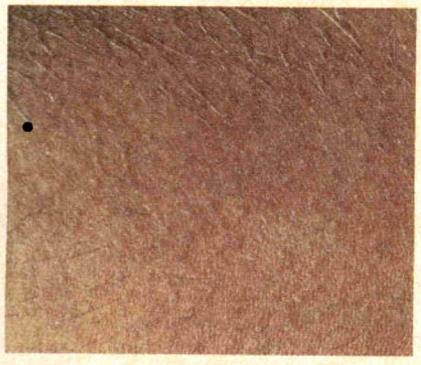

Fig 1.—Top, 8 × 12-cm macular brown hyperpigmented patch is present on left thigh. Bottom, Closer view within patch shows relatively large hairs, perifollicular papules and brownish pigmentation.

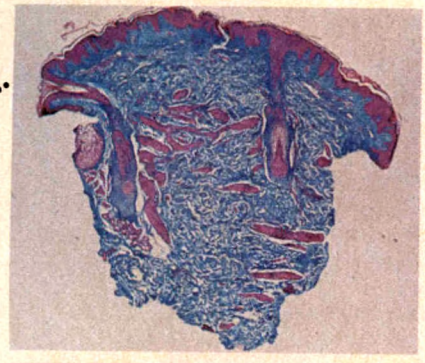

Fig 2.—Top, Biopsy specimen of lesion seen in Fig 1 shows mild acanthosis of epidermis and numerous bundles of smooth muscle in corium, and some bundles appear to connect or be related to hair follicles (Masson's trichrome stain, ×17). Bottom, biopsy of lesion seen in Fig 3 shows numerous large bundles of smooth muscle in corium (Masson's trichrome stain, ×17).

Fig 3.—Irregular brownish patch is present on left lower back and some pigmented areas contain coarse hairs with perifollicular papules.

However, these changes were not "marked" as Stokes[3] had described nor was any "vermicular squirming" or piloerection noted. Unlike most cutaneous leiomyomas, the lesions were neither tender, nodular nor plaque-like.

Histologically, the epidermal changes of acanthosis, of papillomatosis, and of intense pigmentation of the basal cell layer without any evidence of nevus cells are identical to that of Becker's nevus. The interlacing smooth muscle bundles in the corium are perhaps slightly less circumscribed than the usual pilar leiomyomas but are more extensive than the irregularly shaped masses of smooth muscle associated with vellus (lanugo) hair follicles described by Pinkus.[6] The histologic association of the hyperplastic smooth muscle bundles with hair follicles confirms the clinical impression of follicular papules.

Although the arrectores pilorum muscle stains intensely with acetylcholinesterase, most evidence favors adrenomimetic stimulation.[7] We were unable to demonstrate any objective activity of either acetylcholine or the adrenomimetic drugs tested. It should be noted that in the horse, piloerection is caused by norepinephrine and not epinephrine.[8] Although the symptomatic evaluation of the pharmacologic substances seemed to favor some response to adrenergic agents, the lack of response to norepinephrine and the likelihood of a large placebo effect was too great to draw any conclusions.

Electron microscopic examination of pigment formation of Becker's nevi have characterized it as being identical to that produced by normal skin in response to sunlight.[9] Although some studies show a slight increase in melanocytes[10] in Becker's nevi, there is certainly no great hyperplasia of the melanocytic line as is seen in lentigines. The fundamental change in the pigmentary system seems to be one of an inability of the melanocytes to be turned off once the actinic and permissive hormonal influences are combined to activate them.[2]

The increased thickness and size of hair in our cases and Becker's nevi could be explained by an increase in the number of cells in the hair matrix.[11] Burgreen and Ackerman[12] have reported cases of acneiform eruptions limited to Becker's nevi.

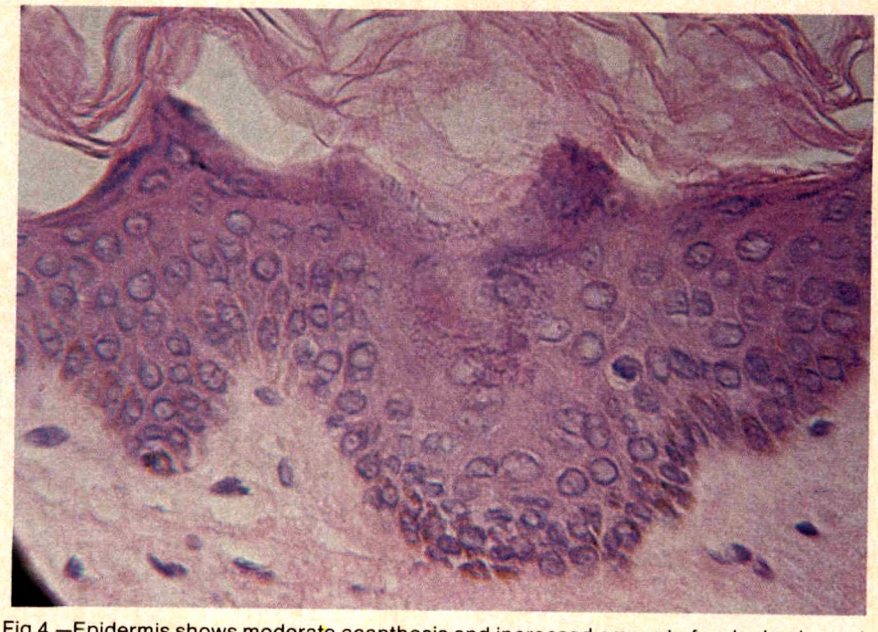

Fig 4.—Epidermis shows moderate acanthosis and increased amount of melanin pigment in lower layers (hematoxylin-eosin, ×430).

Results of Pharmacologic and Physical Tests*

Test Agents	Concentration	Dose	Right Thigh (Normal)			Left Thigh (Hamartoma)		
			Quality	Intensity	Duration	Quality	Intensity	Duration
Acetylcholine	1:10,000	0.1 ml ID	Burning	6/10	15 sec	Burning	7/10	30 sec
Acetylcholine No. 2	1:10,000	0.1 ml ID	Burning	5/10	10 sec	Burning	6/10	24 sec
Ephedrine	1:1,000	0.1 ml ID	Burning	4/10	2 sec	Burning	4/10	8 sec
Ephedrine	1:2,000	0.1 ml ID	None	...	...	Burning	8/10	60 sec
Epinephrine hydrochloride	1:1,000	0.1 ml ID	None	...	...	Burning	7/10	45 sec
Epinephrine No. 2	1:1,000	0.1 ml ID	None	...	...	Burning	6/10	40 sec
Oxytocin	0.01 unit/0.1 ml	0.1 ml ID	Burning	8/10	30 sec	Burning	8/10	30 sec
Oxytocin No. 2	0.01 unit/0.1 ml	0.1 ml ID	None	...	...	Pain	6/10	20 sec
Normal saline	N/A	0.1 ml ID	Burning	1/10	2 sec	Burning	2/10	2 sec
30-gauge needle	N/A	ID	Pain	1/10	...	Pain	3/10	...
Dichlorotetrafluoroethane (Fridgiderm)	1½ in TSD	7 sec	Burning	3/10	7 sec	Burning	5/10	20 sec
Ice	N/A	10 min	Cold	4/10	15 min	Cold and pain	8/10	20 min
Norepinephrine	1:1,000	0.1 ml ID	None	...	...	None	...	...
Norepinephrine	1:10,000	0.1 ml ID	None	...	...	None	...	...
Norepinephrine	1:100,000	0.1 ml ID	None	...	...	None	...	...

*N/A indicates not applicable; TSD, target skin distance; ID, intradermal.

The implication is that there may be some functional alteration of the pilosebaceous apparatus in Becker's nevi. Pinkus and Mehregan[13] have indicated enlargement of the sebaceous glands in Becker's nevi. This, along with the acanthosis with papillary changes seen in Becker's nevi and the hyperplasia of the smooth muscle cells in our cases, emphasizes that structural hyperplasia as well as functional hyperactivity is seen in this group of lesions. It is of interest that although the pigmentation of Becker's nevi often precedes the alterations in hair structure, the structural changes of the hair may persist after the functional changes in the pigmentation have regressed.[1]

Lever et al[14] have suggested that all epithelial nevi lacking nevus cells should be considered hamartomas. Albrecht's original use of the term "hamartoma" to describe a "tumor-like malformation showing a faulty mixture of normal components of the organ in which they occur" would seem to be an appropriate designation for the peculiar hyperplasia of both epithelial and mesenchymal elements demonstrated in our cases.

The significance of the smooth muscle hamartoma is that the hyperplasia of the mesenchymal as well as the epithelial tissue elements may be part of a spectrum of hyperplastic changes seen in association with hyperplasia of the epidermal structures. The further recognition of such structures may give some insight into dermal-epidermal interactions.

Clinically, like Becker's nevi, it is most important to distinguish these lesions from nevus pigmentosus et pilaris or giant hairy nevi in which there is a high incidence of melanoma.[15,16] The perifollicular papules present in our patients contrast with the macular perifollicular pigmentary accentuation seen in Becker's nevi and may serve as a visual clue to distinguish the smooth muscle hamartoma and should encourage palpation of the lesion for evidence of increased firmness and elasticity or Stoke's vermicular squirming. Frain-Bell and Rook[17] reported numerous pale soft papules reminiscent of connective tissue nevus in some portions of some cases of Becker's nevi, but biopsy specimens of the papular areas were probably not taken and their exact nature remain unknown. Generalized smooth muscle hamartomas have been observed in infants and these apparently have not been associated with features of a Becker's nevus.[18]

Nonproprietary Name and Trademarks of Drug

Oxytocin—*Pitocin, Syntocinon, Uteracon.*

References

1. Becker SW: Concurrent melanosis and hypertrichosis in distribution of nevus unius lateris. *Arch Dermatol Syph* 60:155-160, 1949.
2. Copeman PWM, Jones EW: Pigmented hairy epidermal nevus (Becker). *Arch Dermatol* 92:249-251, 1965.
3. Stokes JH: Nevus pilaris with hyperplasia of nonstriated muscle. *Arch Dermatol Syph* 7:479-481, 1923.
4. Siemans HW: Die Naevusähnliche melanose. *Hautartzt* 18:299-303, 1967.
5. Becker's nevus, SOCIETY TRANSACTIONS. *Arch Dermatol* 98:97-98, 1968.
6. Pinkus F: Die glatte Muskulatur der Haut, in Jadassohn J (ed): *Handbuch Der Haut Und Geschlechtskrankheiten.* Berlin, Julius Springer Verlag, 1927, vol 1, part 1, pp 256-262.
7. Koelle GB: Neurohumoral transmission and the autonomic nervous system, in Goodman LS, Gilman A (eds): *The Pharmacologic Basis of Therapeutics.* New York, Maxmillan, 1970, pp 402-465.
8. Evans CL, Smith DFG: Sweating response in the horse. *Proc R Soc Lond B* 145:61-83, 1956.
9. Frenk E, Delacre, Taz J: Zür Ultrastruktur Der Beckareschen Melanose *Hautartzt* 9:397-400, 1970.
10. Pinkus H: Embryology of the Hair, in Montagna W, Elis RA (eds): *Biology of the Hair Growth.* New York, Academic Press, Inc, 1958, pp 1-32.
11. Van Scott EJ, Eckel TM, Auerbach R: Determinants of rate and kinetics of cell division in scalp hair. *J Invest Dermatol* 41:269-273, 1963.
12. Burgreen BL, Ackerman B: Acneform lesions in becker's nevus. *Cutis,* in press.
13. Pinkus H, Mehregan AH: *A Guide to Dermatohistopathology.* New York, Appleton-Century-Crofts Inc, 1969.
14. Lever WF, Schamberg-Lever G: *Histopathology of Skin,* ed 5. Philadelphia, JB Lippincott Co, 1975, p 659.
15. Reed WB, Becker SW Sr, Becker SW Jr, et al: Giant pigmented nevi, melanoma, and leptomeningeal melanocytosis: A clinical and histopathological study. *Arch Dermatol* 91:100-119, 1965.
16. Clark WH, Ainsworth AM, Bernardino EA, et al: The developmental biology of primary human malignant melanomas. *Seminars Oncology* 2:83-103, 1975.
17. Frain-Bell W, Rook A: Pigmented and hypertrichotic epidermal nevus. *Trans St John Hosp Dermatol Soc* 39:51-55, 1957.
18. Transient rippling of the skin (Smooth muscle hamartoma?), SOCIETY TRANSACTIONS. *Arch Dermatol* 110:141, 1974.

Subcutaneous Cysticercosis

Sharon Raimer, MD, John E. Wolf, Jr, MD

Subcutaneous cysticercosis occurred in a 34-year-old man who had multiple asymptomatic subcutaneous nodules. Surgical excision of one lesion revealed a cystic structure with a fibrous capsule that embraced a pork tapeworm larva (*Cysticercus cellulosae*). Such esoteric afflictions as cysticercosis may be seen with increasing frequency in an age of accelerated international travel.

(*Arch Dermatol* 114:107-108, 1978)

Cysticercosis is a rare disease in North America. Occurrences of the potentially deadly infestation may be related to immigration and the increasing popularity of foreign travel. However, this dangerous parasite is more than an accidental intimacy of travel abroad. It is a caveat: Let the traveler beware—and the physician be wary!

We have diagnosed two cases of subcutaneous cysticercosis in the Texas Medical Center within the past 12 months. This is a report of one case.

REPORT OF A CASE

A 34-year-old man was seen in the Dermatology Clinic of Ben Taub (Tex) General Hospital with numerous asymptomatic subcutaneous nodules. The nodules had been present for approximately three years. They were 1 to 2 cm in diameter, firm, nontender, and slightly movable. Lesions were located on the left arm, right shoulder, right scapula, anterior portion of the chest wall, and left thigh.

An excisional biopsy specimen of a nodule on the left arm (Fig 1) revealed a smooth, gelatinous, cystic structure (Fig 2) from which clear fluid was expressed. Microscopic examination showed that the organism *Cysticercus cellulosae* was surrounded by a fibrous capsule and a mild inflammatory reaction (Fig 3).

Accepted for publication Dec 2, 1976.

From the Department of Dermatology, Baylor College of Medicine, Houston.

Reprints not available.

Laboratory evaluation included three negative stool examinations for ova and parasites and a normal complete blood cell count (hemoglobin level, 16.5 gm/100 ml and WBC count, 8,200/cu mm, with 72% neutrophils, 22% lymphocytes, and 6% monocytes). The following studies showed no abnormalities: automated multiple analysis system test panel; chest roentgenogram; skull roentgenographic series; EEG; and brain, liver, spleen and bone scans.

On specific questioning, the patient stated that he had been treated in Mexico three years earlier for tapeworms and was able to sketch a picture of a segmented worm that he had expelled.

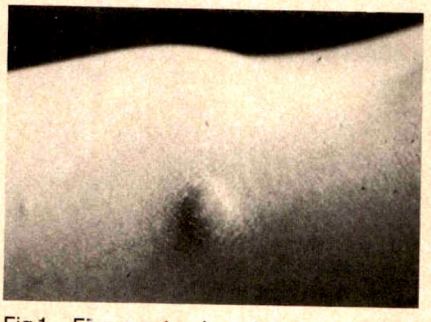

Fig 1.—Firm, nontender subcutaneous nodule on left upper arm.

Fig 2.—Cyst removed from left upper arm by surgical excision.

Fig 3.—Cross section through surgically excised cyst shows fibrous wall and encapsulated *Cysticercus cellulosae* (hematoxylin-eosin, original magnification ×107).

COMMENT

Cysticercosis is an infestation with *C cellulosae*, the larval or bladder worm form of the pork tapeworm *Taenia solium*. The disease is rare in North America but, like other "tropical" afflictions, may now be encountered more frequently because of international travel.

Human infection with *Cysticerus* occurs when man accidentally becomes the intermediate host of *T solium*. Normally, man serves as the definitive host for the organism, whose life cycle begins with human ingestion of viable larvae in inadequately cooked pork. The adult worm attaches by a scolex to the wall of the small bowel, where it may reside for up to 25 years and cause few symptoms. Embryonated eggs and gravid proglottides are released in the feces, deposited in soil, and later consumed by swine. Infection with *T solium* continues to be prevalent in Central and Eastern Europe, South America, Asia, and Africa.[1]

Man may accidentally or incidentally acquire cysticercosis from pork tapeworm eggs in three ways: (1) ingestion of food or water contaminated by infected human feces; (2) oral transmission via the hands of carriers of the adult worm; and (3) internal autoinfection by regurgitation of eggs into the stomach after reversed peristalsis.[2] The larvae (oncospheres) hatch from eggs in the duodenum, penetrate the intestinal wall, and are borne by blood or lymph to various tissues, where the oncospheres develop into cysticerci. A cysticercus is fully developed in two to three months. The oval, opalescent cyst is usually about 5 mm in diameter but may reach several times that size.[2]

The clinical course of cysticercosis is determined by the number of cysts, the tissue invaded, and the reaction of normal tissues to the organism. The onset of symptoms in this insidious disease may be delayed for as long as ten to 20 years. Viable cysticerci produce slight or no inflammatory reaction; however, degeneration of the parasite induces marked infiltration with neutrophils, lymphocytes, histiocytes, and occasionally eosinophils. Disintegration of the cysts may produce a foreign body reaction with multinucleated giant cells, fibrosis, and calcification.[3]

The organism most often invades subcutaneous tissue, eye, brain, skeletal muscle, or heart; but occasionally lung, liver, or kidney may be affected. Involvement of subcutaneous tissue is generally asymptomatic; however, awareness of such lesions may lead to early diagnosis and removal of cysticerci from vital structures before irreversible damage occurs.

In ocular cysticercosis, larvae may lodge anywhere in the orbit, conjunctiva, anterior chamber or vitreous humor; a subretinal location is the favored asylum.[4] Ophthalmoscopic examination may disclose the presence and movement of cysticerci in the vitreous fluid and, thus, confirm the diagnosis.[5]

Involvement of skeletal muscle may cause transient tenderness and either muscular atrophy or hypertrophy.[6] Cardiac involvement may produce focal myocarditis, but clinical abnormalities are rare.

The most serious (and potentially fatal) involvement arises when the organism invades the CNS. In a large series from Central America, cerebral cysticercosis accounted for nearly 25% of the space occupying lesions of the CNS.[7] Involvement may be meningeal, ventricular, parenchymatous, or mixed. Victims usually have symptoms of headache, vomiting, convulsions, mental deterioration, or impaired visual acuity. Physical signs include papilledema, hemiparesis, sensory disturbances, optic atrophy visual field changes, and hydrocephalus.[3] Surgical removal of the organism is indicated whenever possible.

Surgical biopsy and histopathologic examination of cystic lesions lead to the definitive diagnosis of infestation (Fig 3). When CNS involvement is suspected, CSF should be examined; pressure, protein, and mononuclear cells are often increased, eosinophils are frequently present,[8] and the protein electrophoretic pattern of the fluid occasionally reveals increased γ-globulin and decreased albumin levels.[9] The location of avascular cystic lesions may be revealed by skull films (calcification), brain scan (increased uptake), angiography, or pneumoencephalography.[8] Other useful diagnostic tests include hemagglutination, indirect immunofluorescence,[10] gel precipitation, and intradermal skin tests. Complement-fixation tests are not of great value due to frequent false-negative results. Blood eosinophilia is present in approximately 15% of patients with cysticercosis.[11]

The only proven effective treatment of cysticercosis is surgical removal of the organism. Subcutaneous cysticercosis, as reported here, may be asymptomatic and require no treatment. However, surgical excision of at least one subcutaneous cyst is indicated to ascertain a definitive diagnosis. The problems of diagnosis seem apparent since these lesions may mimic much more common, banal entities such as epidermoid cysts or lipomas. Early diagnosis by an alert physician is important in long-term management of the disease; it is, of course, in this area that the dermatologist is most likely to make his contribution.

It seems obvious by now that the jet age is here to stay. Along with the romance of charter tours to Tangiers and Tetiaroa will come the inevitable fallout of contact with exotic "tropical" disease. From Peoria to Brazoria, from Long Island to Los Angeles, the practicing dermatologist shall continue to be confronted by an ever increasing incidence of arcane afflictions.[12-14] Thus, epidermoid cysts will transmogrify into subcutaneous cysticercosis, and papular neurodermatitis will insidiously permute to onchocerciasis.[15] To the vigilant and the curious, shall go the thrill of diagnosing (and hopefully curing) these cryptic concomitants of foreign travel.

References

1. Franken S: Intraocular cysticercosis. *Ophthalmologica* 171:7-10, 1975.
2. Brown HW: *Basic Clinical Parasitology*, ed 5. New York, Appleton-Century-Crofts, 1975, pp 191-192, 203-207.
3. Marcial-Rojas RA: *Pathology of Protozoal and Helminthic Diseases*. Baltimore, Williams & Wilkins Co, 1971, pp 592-617.
4. Bartholomew RS: Subretinal cysticercosis. *Am J Ophthalmol* 79:670-673, 1975.
5. Faust EC, Russell PF, Jung RC: *Craig and Faust's Clinical Parasitology*, ed 8. Philadelphia, Lea & Febiger, 1970, pp 532-534.
6. Salgaokar SV: Muscular hypertrophy in cysticercosis. *J Postgrad Med* 20:48-52, 1974.
7. White JC, Sweet WH, Richardson EP Jr: Cysticercosis cerebri. *N Engl J Med* 256:479-486, 1957.
8. Hoffman SF, Guthrie, TH Jr: Cerebral cysticercosis. *South Med J* 68:105-108, 1975.
9. Oberhauser E, Weinstein V: Estudio comparativo de liquido cefalorra quido y sangre en lués y cisticercosis cerebral. *Acta Neurol Lat Am* 14:74-82, 1968.
10. Rydzewski AK, Chisholm ES, Kagan IG: Comparison of serologic tests for human cysticercosis by indirect hemagglutination, indirect immunofluorescent antibody and agar gel precipitin tests. *J Parasitol* 61:154-155, 1975.
11. Obrador S: Cysticercosis cerebri. *Acta Neurochir* 10:320-364, 1962.
12. Hubler WR Jr, Rudolph AH, Dougherty EF: Dermal myiasis. *Arch Dermatol* 110:109-110, 1974.
13. Hubler WR Jr, Gregory JF, Knox JM, et al: Loaiasis: A case report and review of the literature. *Arch Dermatol* 108:835-836, 1973.
14. Rau RC, Dubin HV, Taylor WB: *Leishmania tropica* infections in travellers. *Arch Dermatol* 112:197-201, 1976.
15. Fitzpatrick TB, Arndt KA, Clark WH, et al (eds): *Dermatology in General Medicine*. New York, McGraw-Hill Book Co Inc, 1971, p 1938.

Balloon Cell Nevus

Summary of the Clinical and Histologic Characteristics

Lt Col Detlef K. Goette, MC, USA, Maj Richard D. Doty, MC, USA

• A 45-year-old man requested excision of an ordinary intradermal nevus. Histologic examination showed that it was composed entirely of balloon cells; to our knowledge, this is only the fifth such case reported.

(*Arch Dermatol* 114:109-111, 1978)

Balloon cell nevus is a rare variant of the nevus cell nevus, characterized histologically by a predominance or complete occurrence of peculiarly large, vesicular, clear cells, generally called balloon cells. Historically, in 1901 Judalewitsch[1] described the first case. In 1935 Miescher[2] published the first well-documented case. In 1963, in a world literature review on balloon cell nevus, Jones and Sanderson[3] found only five well-documented cases in addition to their two reported cases. Since then, to our knowledge, a total of 31 cases of balloon cell nevus have been reported that correspond to the definition above,[4-11] of which only four were composed *entirely* of balloon cells.

This article presents a summary of the clinical, histologic, and ultramicroscopic characteristics illustrated by an additional case of balloon cell nevus.

Accepted for publication Feb 7, 1977.

From the Dermatology Service, Department of Medicine, Letterman Army Medical Center, Presidio of San Francisco.

The opinions or assertions contained herein are the private views of the authors and are not to be construed as official or as reflecting the views of the Department of the Army or the Department of Defense.

Reprint requests to Technical Publications Editor, Letterman Army Medical Center, Presidio of San Francisco, CA 94129.

REPORT OF A CASE

A 45-year-old man had a nevus composed entirely of balloon cells on the left side of the midback (Fig 1). The nodule was 7 mm in diameter, asymptomatic, dark brown, and had been present for many years. The lesion had allegedly increased in size, darkened, and, recently, had shown some erythema. A tentative diagnosis of inflamed intradermal nevus was made and the lesion was removed by deep shave biopsy with the patient under local anesthesia.

Histology

The hematoxylin-eosin stain showed a dome-shaped lesion of vacuolated and partly pigmented cells extending from the epidermis into the lower corium (Fig 2). The overlying epidermis was intact but effaced with rare focal junctional nests of balloon cells. No transmigration of single or clusters of nevus cells through the epidermis was seen. The tumor extended from below the epidermis into the lower corium. It was composed predominantly of minimal to rarely heavily pigmented, comparatively large clear cells of varying sizes, with mild to moderately vacuolated cytoplasm in which mostly fine, but occasionally coarser, brown pigmented granules were suspended (Fig 3). Most cells contained a centrally placed basophilic round nucleus, although multinucleated cells and occasional multinucleated giant cells were observed (Fig 4). The nuclei appeared monomorphic and mitoses were absent. Toward the base of the lesion, pigmented and multinucleated cells were much less prominent. No inflammatory infiltrate was noted. The cells, solidly packed with brown pigment in this lesion, were interpreted as melanophages (Fig 2 through 4). Step sections throughout the entire lesion showed similar findings.

COMMENT

In their series of 18 cases, Schrader and Helwig[10] established the require-

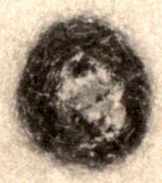

Fig 1.—Clinical appearance of the balloon cell nevus.

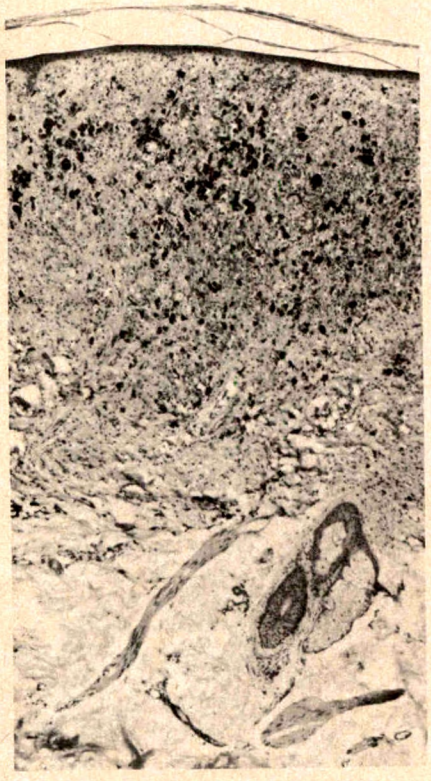

Fig 2.—Scanning view of the histologic specimen of the balloon cell nevus (hematoxylin-eosin, original magnification ×35).

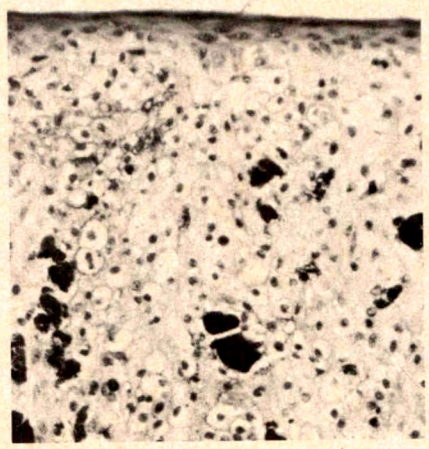

Fig 3.—Mononucleated and occasional multinucleated balloon cells with fine, coarse, and large pigment aggregates (hematoxylin-eosin, original magnification ×100).

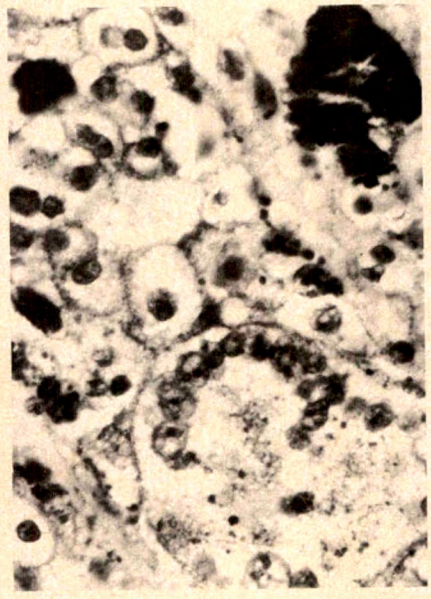

Fig 4.—Mononucleated and multinucleated balloon cells with fine to coarse pigment accumulations (hematoxylin-eosin, original magnification ×450).

ment of a "preponderance (roughly over 50%) of the peculiar foam cells" for qualification as a balloon cell nevus. In fact, they pointed out that characteristically their cases had a (microscopic) mixture of balloon cells and regular nevus cells. Clinically, a balloon cell nevus has no characteristics permitting a differentiation from an ordinary nevus cell nevus.

An epidemiologic review of the 31 cases reported since 1935 indicates that the majority of cases (84%) are seen in the first three decades of life as shown below.

Age, yr	No. of Patients
0-10	11
11-20	8
21-30	7
31-40	1
41-50	2
51-60	2
Total	**31**

The male to female ratio is approximately even (16:15 cases), and the most common site of the lesion appears to be the head and neck area, followed by the trunk and extremities.

Face	6
Neck	7
Conjunctiva	2
Scalp	1
Trunk	11
Extremities	3
Total	**30**

Two cases of balloon cell nevus occurred on the conjunctiva[9,11] and one on the vulva.[10] The duration of the lesion is commonly given as months or years.[10] The nevus is usually asymptomatic, usually smaller than 5 mm,[10] generally brown,[10] and rarely pink.[3] The tumor may appear as a smooth and dome-shaped papule or may be polypoid or verrucous.[3,6,10] Uniformly, the clinical diagnosis is either compound or intradermal nevus cell nevus.[10]

The preferred treatment is an elliptical or shave excision, which generally results in a cure. However, incomplete excision of a balloon cell nevus has prompted a recurrence of the lesion as a regular junction nevus.[12] This phenomenon occasionally occurs when common nevi are not completely removed.[13,14]

Histologically, balloon cell nevus is mostly composed of balloon cells with an admixture of regular nevus cells, observable at the periphery of the lesion.[3,10] The epidermis may be papillomatous, acanthotic, or effaced. Junctional nests may be present at the dermoepidermal interphase or the nevus cells may abut onto the epidermis. Balloon cells are characterized by their comparatively large size; centrally placed, small, round, basophilic nuclei; and their relatively clear, foamy, or vacuolated, well-demarcated cytoplasm.[3,10] Pigment may be absent,[13,15] sparse, or abundant,[15,16] finely granular or, rarely, coarse and clumped (Figs 3 and 4), and may vary from area to area within a single nevus. Multinucleated balloon cells and multinucleated and giant balloon cells are commonly found (Fig 4). Often, especially at the periphery of the lesions, transitional nevus cells with characteristics of balloon cells and common nevus cells can be noted. Such cells have a peculiar "ground glass" type of cytoplasm.[10] This "ground glass" phenomenon was absent in our case, probably because it was composed entirely of foam or balloon cells. To our knowledge, it is only the fifth such case reported.

The balloon cells tend to become smaller toward the base of the lesion

and are gradually replaced by regular nevus cells.[10] Inflammatory infiltrates are mostly absent. Malignant degeneration of balloon cell nevus has not been reported.

In extensive histochemical studies, Schrader and Helwig[10] observed faint PAS-positive diastase-resistant reactivity and could demonstrate RNA and labile acidic mucopolysaccharides in balloon cells. Silver stains indicated the presence of melanin granules. Aside from occasional sudanophilic, superficial nevus cells previously noted by Gartmann[17] and Kreibich,[18] balloon cells did not stain with Sudan dyes, suggesting that neutral fats or cholesterol were absent.[10]

Ultramicroscopic examinations by Okun et al[8] and Hashimoto and Bale[19] showed that balloon cells were formed by progressive vacuolization of melanocytes and/or nevus cells brought about by enlargement and eventual disintegration of melanosomes. Hashimoto and Bale[19] reached the conclusion that the ballooning phenomenon represents a self-destructive process.

There is controversy about the nature of the balloon cell. Some authors considered it to be a xanthomatous[15,20] or sebaceous gland cell.[2] Brunck[16] believed the balloon cell to represent an altered nevus cell, a view supported by Haber,[21] who examined the cases of Jones and Sanderson.[3] Hornstein,[6] reviewing 12 cases of almost exclusively prepubertal patients, theorized that the balloon cell is a regressive variant of a nevus cell found typically only in children and young adults. This hypothesis needs reinterpretation or amplification, as balloon cell nevus has been observed in older patients.[5,9-11] Schrader and Helwig[10] also felt that balloon cells are altered nevus cells, an opinion based on the appearance of transitional cells in their tissue specimens, interposed between common nevus cells and balloon cells. They hypothesized that the appearance of the balloon cell is caused by an arrest in the biosynthesis of melanin in the melanosome. Substantiating evidence is the occurrence of balloon cells in blue nevi, malignant melanomas, and melanocytic tumors of the eye.[22-24] Hashimoto and Bale[19] finally settled the question by showing ultramicroscopically the presence of numerous nonmelanized melanosomes with a tendency to coalescence and subsequent degeneration in balloon cells.

As Schrader and Helwig[10] point out, balloon cells may make up part or all of the lesion of a malignant melanoma. Here the cells are pleomorphic, the nuclei are larger, the cytoplasm is scantier, mitoses can be observed, and, clinically, metastases and the occurrence in older patients support the diagnosis of malignant balloon cell melanoma. This is in accordance with the findings of Gardner and Vasquez[25] on balloon cell melanoma.

Awareness of the existence of balloon cell nevus and familiarity with the histologic presentation will thwart erroneous diagnoses and undue alarm for physician and patient alike.

References

1. Judalewitsch G: Zur Histogenese der weichen Nevi. *Arch Dermatol Syph* 58:15-58, 1901.
2. Miescher G: Umwandlung von Naevuszellan in Talgdrüsenzellen. *Arch Dermatol Syph* 171:114-124, 1935.
3. Jones EW, Sanderson KV: Cellular nevi with peculiar foam cells. *Br J Dermatol* 74:47-54, 1963.
4. Degos R, Civatte J, Garnier G, et al: Naevus naevocellularis partim lipomatoides ou naevus a cellules balloonisantes. *Bull Soc Fr Dermatol* 71:166-172, 1964.
5. Haustein UV: Der Blasenzellnaevus, eine Sonderform des Naevuszellanaevus. *Dermatol Monatsschr* 157:195-198, 1971.
6. Hornstein O: Zur kenntnis des sogenannten Blasenzell naevus. *Arch Klin Exp Dermatol* 226:97-110, 1966.
7. Lewis BL: Clinical appearance of a balloon cell nevus. *Arch Dermatol* 100:312-313, 1969.
8. Okun MR, Donellan B, Edelstein L: An ultrastructural study of balloon cell nevus. *Cancer* 34:615-625, 1974.
9. Pfaffenbach DD, Green WR, Maumenee EA: Balloon cell nevus of conjunctiva. *Arch Ophthalmol* 87:192-195, 1972.
10. Schrader WA, Helwig EB: Balloon cell nevi. *Cancer* 20:1502-1514, 1967.
11. Tao W, Fretzin D, Sundaran L, et al: Balloon cell nevus of the conjunctiva. *Arch Pathol* 96:124-126, 1973.
12. Lewis BL: Junctional activity recurring over an incompletely removed balloon cell nevus. *Arch Dermatol* 104:513-514, 1971.
13. Cox AJ, Walton RG: The induction of junctional changes in pigmented nevi. *Arch Pathol* 79:428-434, 1965.
14. Schoenfeld FJ, Pinkus H: Recurrence of nevi after incomplete removal. *Arch Dermatol* 78:30-35, 1958.
15. Pautrier L, Woringer F: Metaplasie balloonisante dans un naevus pigmentaire cellulaire. *Ann Anat Pathol Med Chir* 1:291-298, 1956.
16. Brunck J: Uber einen metastasierenden, aber klinisch gutartig verlaufenden Naevus mit blasig entarteten Naevuszellen und ueber deren Genese. *Arch Dermatol Syph* 196:170-175, 1953.
17. Gartmann H: Ueber blasige zellen im Naevus-zellnaevus. *Haut Geschlechtskr* 28:148-159, 1960.
18. Kreibich K: Ueber das melanotische pigment der epidermis. *Arch Dermatol Syph* 118:537-555, 1914.
19. Hashimoto K, Bale GF: An electronmicroscopic study of balloon cell nevus. *Cancer* 30:530-540, 1972.
20. Knoth W: Ueber naevus lipomatosus cutaneous superficialis Hoffman-Zurhelle und ueber Naevus naevocellularis partim lipomatoides. *Dermatologica* 125:161-173, 1962.
21. Haber H, cited by Jones EW, Sanderson KV: Cellular nevi with peculiar foam cells. *Br J Dermatol* 74:47-54, 1963.
22. Naumann G, Yanoff M, Zimmerman LE: Histogenesis of malignant melanomas of the uvea: I. *Arch Ophthalmol* 76:784-796, 1966.
23. Naumann G: Pigmentierte Naevi der Aderhaut und des Ciliarkoerpers. *Adv Ophthalmol* 23:187-272, 1970.
24. Yanoff M, Zimmerman LE: Histogenesis of malignant melanomas of the uvea: I. Relationship of uveal nevi to malignant melanomas. *Cancer* 20:493-507, 1967.
25. Gardner AW, Vasquez DM: Balloon cell melanoma. *Arch Pathol* 89:470-472, 1970.

Pathogenesis of Erythromelalgia

Hans Paulli Jørgensen, MD, Jørgen Søndergaard, MD

• A defective prostaglandin metabolism in patients with erythromelalgia may explain several of the clinical features of this condition, such as the red discoloration and burning sensations of the skin. In two patients with erythromelalgia a grossly abnormal bullous reaction to intradermally injected PGE_1, PGE_2, and $PGF_{1\alpha}$ occurred, whereas a normal reaction appeared after injection of histamine, serotonin, and bradykinin. Furthermore, prostaglandin-like material was detected in increased concentration in skin perfusates from these patients. In PGE_1-equivalents the concentration amounted to 2.0 and 3.2 ng/ml of the original perfusate, as compared to 0.1 ng/ml in normal skin. The capacity of synthesizing prostaglandins was increased in skin biopsy material from both patients. At least part of the therapeutic effect of aspirin in these patients may be due to the influence of this drug on prostaglandin metabolism.

(*Arch Dermatol* 114:112-114, 1978)

Erythromelalgia is a rare syndrome characterized by burning distress and red discoloration mainly involving the extremities. In most patients recorded the distress occurs intermittently, and the attacks are usually provoked by elevation of the temperature of the skin of the affected parts (for review, see Babb et al[1]). Over the years the condition has been termed by different names, erythromelalgia,[2] erythermalgia,[3] and erythralgia.[4] The condition has been recorded to occur in two forms, a primary, or idiopathic, and a secondary type, related to nervous, hematologic, peripheral vascular, or other diseases.[3,5,6] Little is known about the pathogenesis and it is also unknown whether the pathogenesis of the secondary type of erythromelalgia is similar to that of the primary type.

One striking clinical observation in erythromelalgia is the prompt relief of symptoms noticed by patients treated with aspirin. The response to aspirin has even been considered characteristic enough to constitute a valuable diagnostic aid.[3] This observation has not previously been tied to pathogenetic mechanisms, although it may provide a clue to a better understanding. One of the actions of aspirin is to potently block prostaglandin synthesis in tissues,[7] including skin.[8] Furthermore, the prostaglandins are highly vasoactive in human skin; thus, when intradermally injected, prostaglandins of the E type in nanogram amounts cause a prolonged erythema[9] and increased amounts are released and synthesized in inflamed human skin.[10-12] When repeatedly injected into human skin, PGE_1 does not cause tachyphylaxis.[13] The prostaglandins are also known to cause hyperalgesia in skin and modulate pain sensation.[14]

This background has prompted us to examine whether the prostaglandins might be involved in the pathogenesis of erythromelalgia, and in the present study we present some evidence obtained in two patients indicating that prostaglandin metabolism may indeed be abnormal.

REPORT OF CASES

CASE 1.—A 20-year-old man had a several-year history of recurrent attacks of burning sensations involving the lower extremities, particularly the feet, evoked by sports. During the last three years his symptoms worsened and became more frequent. They occurred as attacks of intolerable heat, burning and stinging pain, mainly affecting the soles, accompanied by red discoloration sometimes lasting for several hours. The patient had noticed that his symptoms could be relieved by elevating his legs or cooling his feet.

On clinical examination no gross vascular abnormality was visible. His symptoms could easily be reproduced by heating his lower extremities to temperatures above 36 C. This furthermore resulted in a pronounced dark redness of the skin of his feet and subsequent slight dilation of the

Accepted for publication Jan 5, 1977.

From the Departments of Dermatology, Rigshospital and Hvidovre Hospital, University of Copenhagen.

Reprint requests to Department of Dermatology, Hvidovre Hospital, Kettegaard allé 30, DK-2650 Hvidovre, Copenhagen, Denmark (Dr Søndergaard).

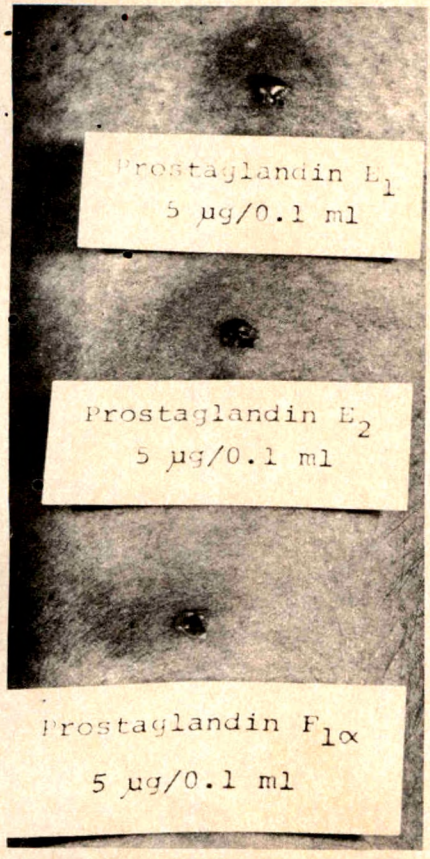

Reactions following intradermal injections of 5 µg PGE_1, PGE_2, and $PGF_{1\alpha}$.

Table 1.—Prostaglandin Activity in Perfusates From Two Patients With Erythromelalgia

	PG* Activity in Perfusates, ng/ml
Normal skin (4)†	0.1 ± 0.1
Erythromelalgia	
Case 1	2.0
Case 2	3.2
Inflamed skin (7)†	0.8 ± 0.2

*PG, prostaglandin expressed as PGE_1-equivalents.
†Number of patients.

regional veins. The clinical abnormalities and the discomfort disappeared within five to ten minutes when the skin temperature measured on his toes fell below 36 C. It was possible to provoke the attacks several times without signs of fatigue. Application of a sphygmomanometer cuff on his thighs insufflated above the diastolic pressure for a couple of minutes resulted in similar attacks. Extensive clinical and laboratory studies during his stay in the ward did not indicate any underlying "secondary" disease. He was treated with aspirin, 3 gm daily, resulting in some improvement but not complete relief of his pains.

Case 2.—During five years, a 62-year-old woman complained of rather severe attacks of burning sensations and red discoloration provoked by heat affecting her arms and legs, particularly her feet and hands. The results of the clinical and laboratory investigations during her stay in the hospital showed no underlying vascular, hematologic, or neurologic disorder. Her symptoms could easily and repeatedly be provoked by heating of her lower extremities to temperatures above 34 to 35 C, and the attacks were relieved by cooling. Occlusion with a sphygmomanometer cuff did not produce typical attacks, but resulted in slight discomfort without any typical skin changes. Treatment with 3 gm of aspirin daily resulted in improvement of her condition.

Table 2.—Biosynthesis of Prostaglandins in Skin From Two Patients With Erythromelalgia

	Biosynthesis of PG* From Endogenous Precursors, ng/mg P-N†	Biosynthesis of PG* From Exogenous Arachidonic Acid, ng/mg P-N†
Normal skin (8)‡	0.09 ± 0.04	4.51 ± 1.24
Erythromelalgia		
Case 1	0.06	6.79
Case 2	0.03	13.90
Inflamed skin (8)‡	0.11 ± 0.07	8.07 ± 1.59

*PG, prostaglandin expressed as PGE_1-equivalents.
†P-N = protein-nitrogen.
‡Number of patients.

METHODS

Intradermal Injections

Prostaglandin E_1 (5 µg), PGE_2 (5 µg), $PGF_{1\alpha}$ (5 µg), histamine (10 µg), and bradykinin (1 µg) were injected intradermally into the flexor aspect of the forearm. A volume of 0.1 ml was injected in each case by means of a 1-ml tuberculin syringe and a needle of an external diameter of 0.5 mm. After 20 minutes and 1, 2, 3, 4, 6, 8, and 24 hours, the reactions were traced on transparent paper and the areas measured planimetrically.

Skin Perfusion

A detailed account of the methods of perfusion and assay has previously been presented.[15] The perfusion experiments were carried out on the flexor aspect of a forearm, both during attacks and symptom-free periods. The perfusates were assayed for histamine, serotonin, kinin activity, and prostaglandin-like material as previously described.[11,15]

Biosynthesis of Prostaglandins

The methods used were adopted from Jonsson and Änggård[16] and have been described elsewhere.[12] Punch biopsy specimens, 6 mm in diameter, were obtained from the thighs during an attack and during a symptom-free period. Determination of the synthesis from endogenous precursors and from labeled arachidonic acid followed exactly the procedures previously described.[12] Informed consent was given by the patients examined.

RESULTS

Intradermal injection of 5 µg PGE_1 and PGE_2 resulted in a reaction different from that seen in healthy individuals. Identical reaction was observed during attacks and symptom-free periods. Within one hour a bullous reaction developed (Figure) at the site of injection, lasting for over 24 hours. The surrounding dusky erythema lasted for 24 hours, and the area and duration of this reaction was similar to that observed in normal human skin. $PGF_{1\alpha}$ caused a similar strong bullous reaction clearly different from that of normal human skin. By contrast, intradermal injection of histamine and bradykinin caused a reaction identical to that observed in a normal control group.

Skin perfusates from both patients contained higher levels of prostaglandin-like activity as compared with perfusates from normal control skin. In PGE_1-equivalents the concentration was 2.0 and 3.2 ng/ml of original perfusate, a value that is considerably higher than previously obtained in perfusate from normal skin and even higher than that obtained in inflamed eczematous skin (Table 1). Histamine, serotonin, and kinin activity was not detected in the perfusates. No difference in concentration was found between results obtained during attacks and a symptom-free period.

The biosynthesis from endogenous precursor acids was similar to that previously obtained in normal human skin. However, when exogenous arachidonic acid was added to the incubation medium the values obtained were higher than those of normal human skin and of the same magnitude as those previously found in inflamed human skin (Table 2). The values obtained during an attack were similar to those found during a symptom-free period.

COMMENT

The results of the present study support the idea already advocated by Lewis in 1933[4] that, from a pathogenetic point of view, erythromelalgia should be included among inflammatory conditions. Furthermore, our

data indicate that the prostaglandins may be the main chemical mediators involved. Thus, a normal reaction occurred after intradermal injection of histamine and bradykinin, whereas the reactions to PGE_1, PGE_2, and $PGF_{1\alpha}$ were grossly abnormal. Furthermore, prostaglandin-like material was released in increased concentration in the perfusates from the patients with erythromelalgia, whereas histamine and kinin activity could not be detected. In addition, prostaglandin synthesis was increased to the same magnitude as previously demonstrated in patients with allergic contact eczema when skin from the patients with erythromelalgia was incubated in the presence of exogenous arachidonic acid.[12] Our present in vitro results cannot be compared directly with the in vivo perfusion studies, where conditions for biosynthesis and metabolism of prostaglandins may be completely different.

The present data may be of particular interest when compared to a different clinical situation characterized by pale and white skin. Penneys et al[17] studied the Woronoff ring, which clinically appears as a white ring surrounding psoriatic lesions treated with ultraviolet light. In this situation the vessels were normally responsive when E prostaglandins were injected intradermally in the ring, whereas PGE synthesis was markedly decreased, probably due to the presence of an inhibitor of prostaglandin synthesis.

The increased rate of synthesis of prostaglandins in patients with erythromelalgia may explain several of the clinical features of this condition, such as the dull redness and the burning sensations of the skin. However, it does not explain what triggers the attacks and why the patients experience symptom-free intervals. Obviously, the defect involved the clinical unaffected skin. Furthermore, the defective prostaglandin metabolism may even include an abnormal enzymatic degrading capacity that might explain the abnormal long-lasting bullous reaction appearing after intradermal injection of both E and F prostaglandins. A defective degradation of prostaglandins in patients with erythromelalgia might help explain why aspirin only partially relieves the symptoms, since this drug inhibits prostaglandin synthetase but has no effect on prostaglandin-degrading enzymes.[7] We are currently evaluating the effect of aspirin on prostaglandin metabolism in our patients with erythromelalgia to provide further data to support the view that the prostaglandins may be involved in the pathogenesis of this condition.

References

1. Babb RR, Alarcon-Segovia D, Fairbairn JF II: Erythermalgia: Review of 51 cases. *Circulation* 29:136-141, 1964.
2. Mitchell SW: On a rare vasomotor neurosis of the extremities and on the maladies with which it may be confounded. *Am J Med Sci* 76:17-36, 1878.
3. Smith LA, Allen EV: Erythermalgia (erythromelalgia) of the extremities: A syndrome characterized by redness, heat and pain. *Am Heart J* 16:175-188, 1938.
4. Lewis T: Clinical observations and experiments relating to burning pain in the extremities, and to so-called "erythromelalgia" in particular. *Clin Sci* 1:175-211, 1933.
5. Alarcon-Segovia D, Babb RR, Fairbairn JF II, et al: Erythermalgia. *Arch Intern Med* 117:511-515, 1966.
6. Alarcon-Segovia D, Diaz-Jouanen E: Erythermalgia in systemic lupus erythematosus. *Am J Med Sci* 266:149-151, 1973.
7. Vane JR: Inhibition of prostaglandin synthesis as a mechanism of action for aspirin-like drugs. *Nature* 231:232-235, 1971.
8. Greaves MW, McDonald-Gibson W: Effect of nonsteroid anti-inflammatory and antipyretic drugs on prostaglandin biosynthesis by human skin. *J Invest Dermatol* 61:127-129, 1973.
9. Søndergaard J, Greaves MW: Prostaglandin E_1: Effect on human cutaneous vasculature and skin histamine. *Br J Dermatol* 84:424-428, 1971.
10. Greaves MW, Søndergaard J, McDonald-Gibson W: Recovery of prostaglandins in human cutaneous inflammation. *Br Med J* 2:258-260, 1971.
11. Søndergaard J. Greaves MW, Paulli Jørgensen H: Recovery of prostaglandins in human primary irritant dermatitis. *Arch Dermatol* 110:556-558, 1974.
12. Paulli Jørgensen H, Søndergaard J: Biosynthesis of prostaglandins by human inflamed skin. *Acta Derm Venereol* 56:11-13, 1976.
13. Paulli Jørgensen H, Søndergaard J: Vascular responses to prostaglandin E_1. *Acta Derm Venereol* 53:203-206, 1973.
14. Ferreira SH: Prostaglandins, aspirin-like drugs and analgesia. *Nature* 240:200-203, 1972.
15. Greaves MW, Søndergaard J: Urticaria pigmentosa and factitious urticaria: Direct evidence for release of histamine and other smooth muscle contracting agents in dermographic skin. *Arch Dermatol* 101:418-425, 1970.
16. Jonsson CE, Änggård E: Biosynthesis and metabolism of prostaglandin E_2 in human skin. *Scand J Clin Lab Invest* 29:289-296, 1972.
17. Penneys NS, Ziboh V, Simon P, et al: Pathogenesis of Woronoff ring in psoriasis. *Arch Dermatol* 112:955-957, 1976.

Contact Dermatitis Due to Multiple Corticosteroid Creams

Ralph J. Coskey, MD

• A patient was allergic to the corticosteroids halcinonide, fluocinonide, desonide, and triamcinolone acetonide. She also was allergic to ethylenediamine hydrochloride, neomycin, thimerosal, formaldehyde solution, and nystatin.

(*Arch Dermatol* 114:115-117, 1978)

A patient was allergic to multiple topical corticosteroid preparations. She had patch tests to the ingredients of these preparations and was found to be allergic to desonide, triamcinolone acetonide, fluocinonide, and halcinonide. In addition, she was allergic to parabens, ethylenediamine hydrochloride, thimerosal, nystatin, and formaldehyde solution.

REPORT OF A CASE

A 16-year-old girl was seen on Sept 18, 1967, because of an axillary eruption of one week's duration. A diagnosis of contact dermatitis from her deodorant was made and she was treated with a cream containing triamcinolone acetonide, neomycin, nystatin, and gramicidin (Mycolog). The eruption cleared and she was seen again on Dec 1, 1967, at which time she was treated with betamethasone valerate cream (Valisone). She was seen one week later and the eruption improved. At that time patch tests were done to 1% mercaptobenzothiazole, 2% formaldehyde solution, and her deodorant. She had a 1+ reaction to formaldehyde. The eruption improved.

This girl was seen on April 26, 1968, because of axillary dermatitis. At that time she was treated once more with betamethasone valerate cream. She was seen again on Nov 12, 1969, because of diffuse dermatitis that had occurred after she had used nystatin vaginal suppositories. She was treated at that time with systemic corticosteroids and the eruption improved. She also was given topical fluocinonide (Lidex) and was advised to avoid nystatin.

This patient was seen on April 14, 1970, at which time she had dermatitis of the eyelids. She was advised to use triamcinolone acetonide cream (Kenalog-S) and avoid cosmetics. Her next visit to the office was Dec 14, 1970. At that time she had dermatitis of the fingers and she was treated once more with Mycolog. The eruption did not improve and she had a patch test to Mycolog cream, 3% nystatin cream in petrolatum, and 1% ethylenediamine hydrochloride in petrolatum. She had a 1+ reaction to Mycolog, 3+ reaction to nystatin, and a 1+ reaction to ethylenediamine hydrochloride.

The patient was seen on April 14, 1971, because of facial dermatitis that resembled seborrheic dermatitis. She was treated with 0.5% triamcinolone acetonide cream. The eruption became worse and she was advised to discontinue use of the cream. The eruption improved and she was not seen again until June 3, 1971. She had a recurrence of the dermatitis of the face and was treated with systemic corticosteroids.

This patient was not seen again until Feb 17, 1972. She had seborrheic dermatitis of her scalp and was treated with a tar shampoo and 0.01% fluocinolone acetonide solution (Synalar). This eruption improved and she was not seen again until Feb 24, 1975, because of dermatitis of her face. At that time she was treated with desonide cream (Tridesilon).

The patient returned on July 2, 1975, and her condition was worse. She was treated with systemic corticosteroids. A diagnosis of contact dermatitis to desonide cream was made and she had a patch test to the ingredients of the cream. She had a positive patch test reaction to desonide in water and in petrolatum. Further patch tests were applied on Oct 3, 1975. These showed positive reactions to ethylenediamine hydrochloride, parabens, thimerosal, neomycin, and the following topical steroids: triamcinolone acetonide (Kenalog), fluorometholone (Oxylone), fluocinonide

Table 1.—Patch Tests to North American Contact Dermatitis Kit

Test Substance	Concentration	Results
Nickel sulfate	2.5% in petrolatum	0
Potassium dichromate	0.5% in petrolatum	0
Thimerosal	0.1% in petrolatum	1+
Ethylenediamine hydrochloride	1% in petrolatum	2+
Balsam of Peru	25% in petrolatum	0
Ammoniated mercury	1% in petrolatum	0
Paraben mix (methyl, ethyl, propyl, butyl, & benzyl, 3% each)	15% in petrolatum	2+
Formaldehyde	2% aqueous	1+
p-Phenylenediamine	1% in petrolatum	0
Turpentine	1% in olive oil	0
Caine mix	8% in petrolatum	0
Wool alcohol	30% in petrolatum	0
Mercaptobenzothiazole mix	1% in petrolatum	0
Thiurum mix	1% in petrolatum	0
p-Phenylenediamine mix	0.6% in petrolatum	0
Carba mix	3% in petrolatum	0
Epoxy resin	1% in petrolatum	0
Lanolin	100% in petrolatum	0
p-Tert-butylphenol	2% in petrolatum	0
PCMX	1% in petrolatum	0
Neomycin	20% in petrolatum	2+
Mercaptobenzothiazole mix	1% in petrolatum	0

Table 2.—Corticosteroid Creams

Test Substance	Concentration	Results
Desonide (Tridesilon)	0.05%	2+
Triamcinolone acetonide (Aristocort)	0.1% cream	2+
Fluorometholone (Oxylone)	0.025% cream	2+
Fluocinonide (Lidex)	0.05% cream	2+
Fluocinolone acetonide (Synalar)	0.025% cream	2+
Flurandrenolide (Cordran)	0.05% cream	2+
Hydrocortisone alcohol (Cort-Dome)	0.50% lotion	2+
Halcinonide (Halog)	0.1% cream	1+
Betamethasone valerate (Valisone)	0.1% cream	0
Control		0
Mycolog	0.1% cream	1+

Accepted for publication Feb 2, 1977.

From the Department of Dermatology, Wayne State University School of Medicine, Detroit.

Reprint requests to 23133 Orchard Lake Rd, Farmington, MI 48024 (Dr Coskey).

Table 3.—Patch Tests to Corticosteroid Creams and Their Ingredients

Preparations	Concentration Used for Patch Testing	Result
0.025% fluocinolone acetonide cream (Synalar)		
Stearic acid	1% aqueous	0
Propylene glycol	10% aqueous	0
Sorbitan monostearate	10% aqueous	0
Monooleate		0
Polyoxyethylene sorbitan monostearate	5% in petrolatum	0
Citric acid	1% aqueous	0
Methylparaben	5% in petrolatum	2+
Propylparaben	5% in petrolatum	2+
Fluocinolone acetonide in alcohol cream	0.025% in petrolatum	0
Hydrocortisone alcohol cream (Cort-Dome)		
Glyceryl monostearate	30% in petrolatum	0
Cetyl alcohol	30% in petrolatum	0
Stearyl alcohol	3% in petrolatum	0
Butyl stearate	25% in olive oil	0
Aluminum acetate	10% aqueous	0
Isopropyl myristate	2% in petrolatum	0
Glycerin	10% in water	0
Water		0
Methylparaben	5% in petrolatum	2+
Hydrocortisone	1%	0
0.1% triamcinolone acetonide (Aristocort)		
Monoglycerides & diglycerides	1% in petrolatum	0
Squalane	As is	0
Polysorbate 80 USP	As is	0
Polysorbate 60	As is	0
Spermaceti	As is	0
Stearyl alcohol	3% liquid paraffin	0
Sorbitol solution	10% aqueous	0
Sorbic acid	5% petrolatum	0
Potassium sorbate	10% aqueous	0
White petrolatum	As is	0
Triamcinolone acetonide 0.025%		2+
Flurandrenolide cream (Cordran)		
Stearic acid	1% aqueous	0
Cetyl alcohol	30% petrolatum	0
Mineral oil	As is	0
Polyoxyl 40 stearate	5% in petrolatum	0
Ethylparaben	5% in petrolatum	2+
Glycerin	10% in water	0
Water		0
Flurandrenolide	0.05%	0
Fluocinonide cream (Lidex) .025%		
Stearyl alcohol	3% liquid paraffin	0
Polyethylene glycol 6000	10% aqueous	0
Propylene glycol	10% aqueous	0
1,2,6-hexanetriol	In petrolatum	0
Citric acid	1% aqueous	0
Fluocinonide	0.05% in petrolatum	1+
Betamethasone valerate cream 0.1% (Valisone)		
Water	As is	0
Mineral oil	As is	0
Petrolatum	As is	0
Polyethylene glycol 1000	10% aqueous	0
Monocetyl ether	Not done	0
Cetostearyl alcohol	Not done	0
Monobasic sodium phosphate	Not done	0
Phosphoric acid	Not done	0
4 chloro-m-cresol	Not done	0
Betamethasone valerate	0.1%	0
Halcinonide 0.1% (Halog)		
Glyceryl monostearate NF XII	30% petrolatum	0
Cetyl alcohol	30% petrolatum	0
Spermaceti synthetic	As is	0
Isopropyl palmitate	2% petrolatum	0
Polysorbate 60	As is	0
Propylene glycol	10% aqueous	0
Water		0
Halcinonide	0.1% in petrolatum	2+
Fluorometholone .025% (Oxylone Cream)		
Glyceryl monostearate	30% petrolatum	0
Spermaceti	As is	0
Polyethylene glycol 400	10% aqueous	0
N,N-diethylaminoethyl stearamide (phosphate salt)	Not done	0
Water		0
Methylparaben	5% in petrolatum	2+
Butylparaben	5% in petrolatum	2+
Fluorometholone	0.025% in petrolatum	0

Table 3.—Continued

Preparations	Concentration Used for Patch Testing	Result
Desonide (Tridesilon)		
Glycerin	As is	0
Methylparaben	5% in petrolatum	2+
Sodium lauryl sulfate	5% aqueous	0
Aluminum acetate	10% aqueous	0
Water		0
Cetyl stearyl alcohol	3% in petrolatum	0
Synthetic B-wax	As is	0
White petrolatum		0
Mineral oil	10% in white petrolatum	0
Spermaceti	As is	0
0.05% desonide	In petrolatum	2+

(Lidex), fluocinolone acetonide (Synalar), flurandrenolide (Cordran), hydrocortisone alcohol (Cort-Dome), halcinonide (Halog), and Mycolog (Tables 1 and 2).

Further patch tests were then done to the ingredients of the above steroid creams and also to the pure corticosteroid powders diluted in petrolatum (Table 3). These confirmed allergy to all of the above preparations, except for fluorometholone, flurandrenolide, fluocinolone acetonide, and hydrocortisone alcohol. In these instances the contact dermatitis was due to the preservative, paraben, in the cream.

COMMENT

There have been several reports in the literature of contact dermatitis due to corticosteroid topical preparations. In some instances the sensitivity has been due to the steroid itself. Thus, sensitivity to pure hydrocortisone,[1-6] methylprednisolone,[7] triamcinolone acetonide,[8-12] betamethasone,[13,14] dexamethasone,[10] and fluocinide[12] have been reported.

However, one or more of the ingredients of the cream or ointment base of the corticosteroid preparation probably accounts for most of the sensitivity reactions to these preparations. Thus, if a person does develop exacerbation of an eruption, after applying one of these preparations, he should be tested to the preparation and its ingredients. Probably the most common sensitizing ingredient of a steroid cream is ethylenediamine hydrochloride,[15] which is found in Mycolog cream, but other authors have found alcohols,[16,17] propylene glycol,[17] parabens,[18,19] and others as a cause of dermatitis. The significance of sensitivity to ingredients of vehicles was brought out in two recent publications.[20,21] The authors performed patch tests on patients suspected of having contact dermatitis to trays containing the ingredients of the vehicles. Positive patch test reactions developed in some instances to the following agents to which I also had tested my patient: ethylenediamine hydrochloride, thimerosal, wool alcohol, lanolin, sorbic acid, parabens, propylene glycol, and polyethylene glycol monostearate.

My patient is distinguished in that she was allergic to several different topical corticosteroid creams. In the case of sensitivity of fluorometholone (Oxylone), fluocinolone acetonide (Synalar), flurandrenolide (Cordran), and hydrocortisone alcohol (Cort-Dome), she was not sensitive to the corticosteroid but was allergic to the preservative, paraben. In the case of halcinonide, fluocinonide, desonide, and triamcinolone acetonide, she was allergic to the steroid itself, and finally she was also allergic to ethylenediamine hydrochloride, neomycin, thimerosal, nystatin, and formaldehyde solution.

The four corticosteroids that she was allergic to are all 16, 17 acetonides of corticosteroids, with identical structures except for the presence and position of fluoro substitution and ring A unsaturation at position 1,2. Halcinonide is 21 chloro substituted. However, there is nothing that systematically distinguishes these compounds from the five that did not produce allergic reactions in this patient. Some of them are also acetonides and also have fluoro substitutions. Thus, I cannot explain why this patient reacted to some corticosteroid preparations and not to others with similar chemical compositions.

The following were supplied by these companies: hydrocortisone and desonide creams and their ingredients, Dome Laboratories; triamcinolone cream and its ingredients, Lederle Laboratories, halcinomide and its ingredients, Squibb; fluorometholone cream and its ingredients, Upjohn Co; fluocinolone acetonide and fluocinonide and its ingredients, Syntex Laboratories; flurandrenolide, Lilly Research Laboratories; and betamethasone valerate, Schering Corp.

Bernard H. Marks, MD, and Jerome Horwitz, PhD, provided information about the chemical compositions of the corticosteroid preparations.

References

1. Kooij R: Hypersensitivity to hydrocortisone. *Br J Dermatol* 71:392-394, 1953.
2. Burckhardt W: Contact eczema caused by hydrocortisone. *Hautarzt* 10:42-43, 1959.
3. Church R: Sensitivity to hydrocortisone acetate ointment. *Br J Dermatol* 72:341-344, 1960.
4. Coskey RJ: Contact dermatitis due to topical hydrocortisone and prednisolone. *Michigan Med* 64:669-670, 1965.
5. Comaish S: A case of hypersensitivity to corticosteroids. *Br J Dermatol* 81:919-925, 1969.
6. Edwards M, Rudner EJ: Dermatitis venenata due to hydrocortisone alcohol. *Cutis* 6:757-758, 1970.
7. Coskey RJ: Contact dermatitis due to methylprednisolone, letter to the editor. *JAMA* 199:136, 1967.
8. Alani MD, Alani SD: Allergic contact dermatitis to corticosteroids. *Ann Allergy* 30:181-185, 1972.
9. Bandmann HJ, Huber-Riffeser G, Woyton A: Kontaktallergie gegen Triamcinolonacetonid. *Hautarzt* 17:183-185, 1966.
10. Wiegel O: XXX. Kontaktallergie durch Kortikosteroid-haltige Externa (Triamcinolonacetonid und Dexamethason). *Medizinische Welt* 13:828-829, 1968.
11. Tegner E: Contact dermatitis to corticosteroids. *Int J Dermatol* 15:520-523, 1976.
12. Lazar V, Capusan I: Skin allergy to cortisone derivatives. *Clujul Med* 48:187-192, 1975.
13. Burney MH: Contact dermatitis due to betamethasone 17 valerate (Betnovat). *Contact Derm Newsletter* 12:318, 1972.
14. Malten KE: Betnelan V lotion contact sensitivity. *Contact Derm Newsletter* 13:360, 1973.
15. Prevost TT, Jillson OF: Ethylenediamine contact dermatitis. *Arch Dermatol* 96:231-234, 1967.
16. Sams WM, Graham Smith J Jr: Contact dermatitis due to hydrocortisone ointment: Report of a case of sensitivity to emulsifying agents in a hydrophilic ointment base. *JAMA* 164:1212-1215, 1957.
17. Shore RN, Shelley WB: Contact dermatitis from stearyl alcohol and propylene glycol in fluocinonide cream. *Arch Dermatol* 109:397-399, 1974.
18. Schorr WF: Paraben allergy. A case of intractable dermatitis. *JAMA* 204:107-110, 1968.
19. Epstein S: Paraben sensitivity: Subtle trouble. *Ann Allergy* 26:185-189, 1968.
20. Fischer AA, Pascher F II, Kanof NB: Allergic contact dermatitis due to ingredients of vehicles: A "Vehicle tray" for patch testing. *Arch Dermatol* 104:286-290, 1971.
21. Hannuksela M, Kousa M, Pirila V: Allergy to ingredients of vehicles. *Contact Derm* 2:105-110, 1976.

Trichophyton simii Infection in the United States Not Traceable to India

Sidney Barsky, MD; David Knapp, MD; Shirley McMillen, MA

To our knowledge, this communication reports the first case of *Trichophyton simii* infection in the United States not traceable to India. The patient was a 40-year-old Nigerian male student who had not been out of the United States for more than three years. He had never been in India or had contact with animals or poultry. A brief review of the literature is included.

***(Arch Dermatol* 114:118, 1978)**

Trichophyton simii is classified as a zoophilic dermatophyte. It is encountered primarily as a cause of ringworm in monkeys and has a striking geographical restriction to India. Numerous cases have been reported of clinical infections in humans caused by this dermatophyte. However, with the exception of that reported by Londero et al,[1] all have been traceable to India. To our knowledge, we report the first case of *T simii* infection occurring in the United States not traceable to India.

REPORT OF A CASE

A 40-year-old man visited the skin clinic because of a pruritic lesion in his groin of three weeks' duration. The patient was from Nigeria, but had not been out of the United States for more than three years. He was a university student who denied contact with animals of any kind, poultry, or with anyone from India. Results of examination showed well-marginated, bilateral, erythematous, scaly lesions in his groin characteristic of tinea cruris. A potassium hydroxide mount was positive. In culture, the organism was a rapidly growing fungus with a velvety to granular surface. The young colonies were flat, but developed crateriform grooves with age. The surface color was faintly lavender, and the underside was vinaceous.

Results of microscopical examination showed abundant microconidia and macroconidia. The macroconidia were approximately 10 × 60 μ and roughly cylindrical with up to ten septa. The walls of the conidia were thin and smooth. The macroconidia were distinctive because of empty or ballooned segments. The patient was treated with topical haloprogin (Halotex), to which he responded well.

Accepted for publication Feb 18, 1977.

From the Divisions of Dermatology (Drs Barsky and Knapp) and Microbiology (Ms McMillen), Cook County Hospital, Chicago.

Reprint requests to Department of Dermatology, Cook County Hospital, 1825 W Harrison St, Chicago, IL 60612 (Dr Barsky).

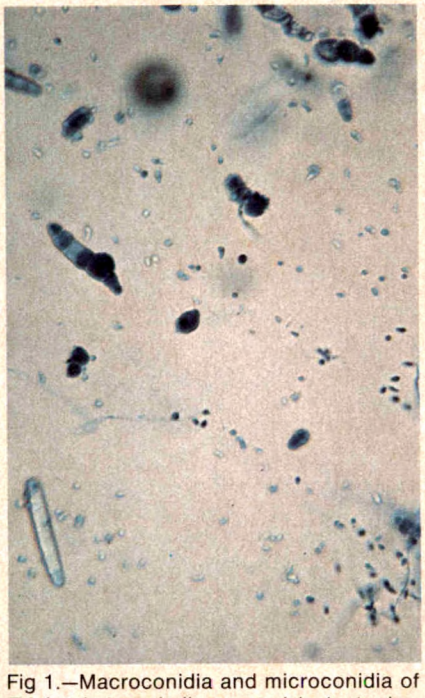

Fig 1.—Macroconidia and microconidia of *Trichophyton simii* mounted in lactophenol cotton blue (original magnification, ×329).

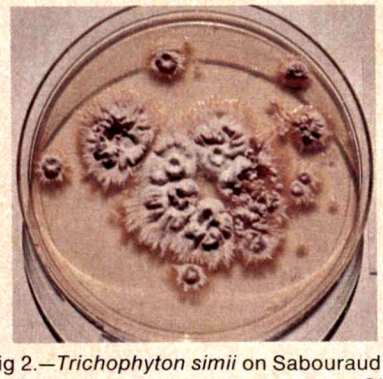

Fig 2.—*Trichophyton simii* on Sabouraud's dextrose agar at room temperature. Obverse view at two weeks.

Fig 3.—Reverse view of Fig 2 demonstrating vinaceous color.

COMMENT

Trichophyton simii was first described in 1912 by Pinoy,[2] who isolated the fungus from the skin lesions of a monkey. The fungus was redescribed in 1965 by Stockdale et al[3] as *T simii* and its perfect stage was described as *Arthroderma simii*. All 31 isolates studied by Stockdale et al were from India and were isolated from ringworm infections of monkeys, poultry, a dog, and a man. Several cases of dermatophyte infections due to *T simii* in man and animals have since been described.[4-10] These cases have all occurred in India or have been traceable in India, with the exceptions of an unexplained isolation of *T simii* on a captive chimpanzee in Japan[11] and from a girl in Brazil.[1]

The clinical appearance of *T simii* dermatophytosis in human cases is indistinguishable from that of other *Trichophyton* infections. It is interesting to note that in our case, unlike in other reported cases, the potassium hydroxide mount was positive.

Nonproprietary Name and Trademark of Drug

Haloprogin—*Halotex*.

References

1. Londero AT, Benevenga JP: *Trichophyton simii*: Its occurrence in Brazil. *Rev Inst Med Trop Sao Paulo* 14:381-383, 1972.
2. Pinoy E: Sur une teigne cutanee du singe. *Comptes Rendus Hebdomadaires des Seances et Memoires dela Societe de Biologie de Paris* 72:59, 1912.
3. Stockdale PM, MacKenzie DWR, Austwick PKC: *Arthroderma simii* sp nov, the perfect state of *Trichophyton simii* (Pinoy) Comb nov *Sabouraudia* 4:112-123, 1965.
4. Gugnani HC, Mulay DN, Murty DK: Fungus flora of dermatophytosis and *T simii* infection in North India. *Indian J Dermatol Venerol* 33:73-82, 1967.
5. Klokke AH, Durairaj P: The causal agents of superficial mycoses isolated in rural areas of South India. *Sabouraudia* 5:153-158, 1967.
6. Rippon JW, Eng A, Malkinson FD: *Trichophyton simii* infection in the United States. *Arch Dermatol* 98:615-619, 1968.
7. Tewari RP: *T simii* infection in chickens, dog and man in India. *Mycopathologia* 39:293-298, 1969.
8. Mohapatra LN, Mahajan VM: *T simii* infection in man and animal. *Mycopathologia* 41:357-362, 1970.
9. Mulay DN, Garg AK: A study on the *T simii* infection in man at Delhi. *Indian J Dermatol Venerol* 36:175-181, 1970.
10. Kamalam A, Thambiah AS: *Trichophyton simii* infection. *Trans St John Hosp Derm Soc* 60:73-76, 1974.
11. Okoshi S, Takashio M, Hasegarva A: Ringworm caused by *T simii* in a captive chimpanzee. *Jap J Med Mycology* 7:204-207, 1966.

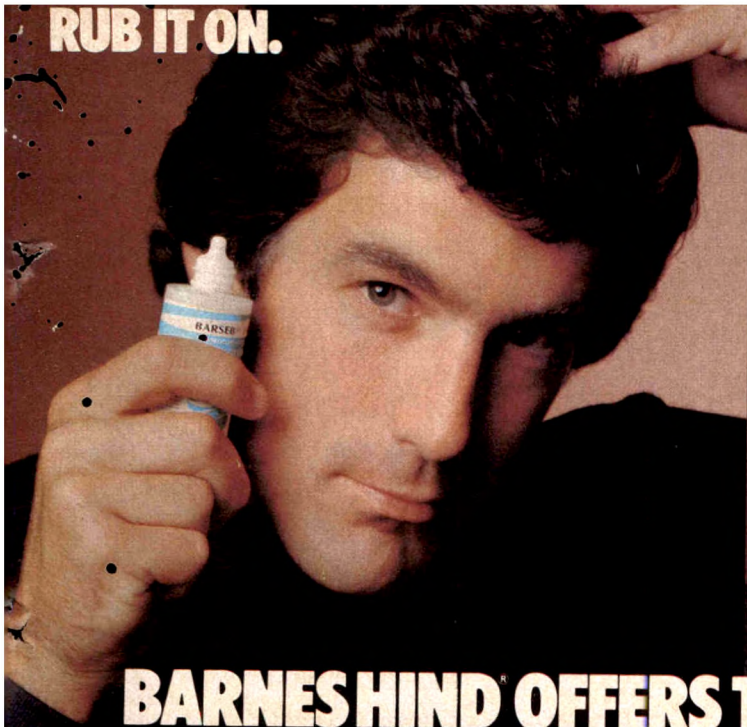

BARNES HIND OFFERS TWO Rx EXCLUSIVES FOR SEBORRHEIC DERMATITIS

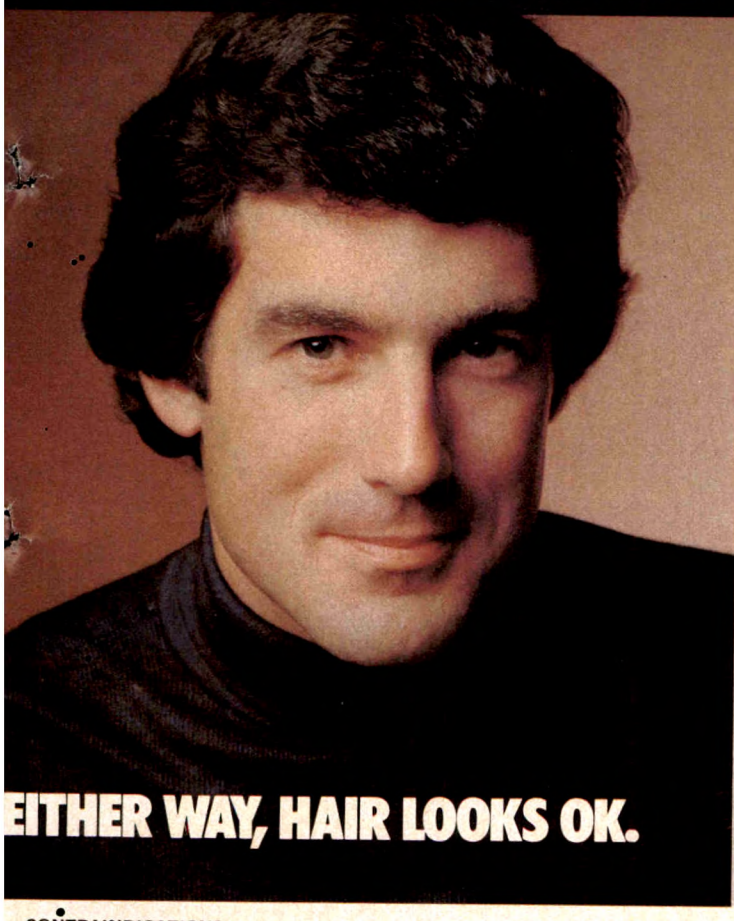

You can offer your seborrheic patients a choice of remedies that are effective yet cosmetically elegant—Barseb® Thera-Spray® and Barseb® HC Scalp Lotion.

Either way, you'll be prescribing Barnes Hind exclusive combinations of hydrocortisone and salicylic acid with their proven anti-inflammatory, antipruritic and keratolytic capabilities.

Without mussing the hair, the Thera-Spray snorkel directs the active ingredients onto the scalp in a vehicle that spreads and penetrates.

The Barseb HC base holds the active ingredients on the skin, not on the hair shafts. Barseb HC won't dry hair, or increase oiliness. And it's compatible with hair sprays, colorings, permanent waves and grooming agents.

Both Thera-Spray and Lotion are clear, non-staining, odorless.

BARSEB® THERA-SPRAY®
BARSEB® HC SCALP LOTION

(hydrocortisone and salicylic acid)

For complete prescribing information, please see package insert.

CONTRAINDICATIONS
Hydrocortisone is contraindicated in tuberculosis, fungal, and most viral infections of the skin (especially herpes simplex, vaccina and varicella, etc).

WARNING
While topical steroids have not been reported to have an adverse effect on pregnancy, the safety of their use has not been absolutely established. Therefore, they should not be used extensively on pregnant patients in large amounts nor for long periods of time.
Avoid inhalation, ingestion or contact with eyes or nose.
BARSEB® THERA-SPRAY
Contents under pressure. Do not puncture, burn or expose to temperatures above 120°F. Avoid inhalation.

PRECAUTIONS
Transient discomfort may occur when first applied to an inflamed scalp. This normally disappears with repeated use. Discontinue use if condition does not improve or if sensitivity reactions occur. The anti-inflammatory action of hydrocortisone may mask the presence of infection. If bacterial or fungal infection exists or supervenes, concomitant antimicrobial or antifungal therapy should be considered. When topical steroids are used on large areas of skin for long periods of time, there is the possibility of systemic absorption. Should adrenal suppression, electrolyte imbalance, metabolic changes, or other symptoms of systemic absorption occur, suitable counter measures should be taken. Precautions should be taken when hydrocortisone is used in the treatment of skin diseases associated with impaired circulation, such as stasis dermatitis.
Avoid spray inhalation, ingestion, or contact with eyes or nose. If medication accidentally gets into eyes, immediately flush with copious amounts of water; if irritation persists, notify your physician. Keep out of reach of children.

CAUTION
U. S. Federal law prohibits dispensing without prescription.

Barnes Hind Pharmaceuticals, Inc.
895 Kifer Road

Psoriasis results without occlusion in only 7 days

Moderate to excellent response in 96% of psoriatic patients.

In two controlled studies, 57 patients with psoriasis were treated with ARISTOCORT A Ointment 0.1% t.i.d. without occlusion for 7 days.*

High degree of patient acceptance.

Patients reported no burning, soreness, drying or itching. ARISTOCORT A Ointment spread easily, rubbed in well, and washed off readily with soap and water.*

*Data on file, Department of Medical Research, Lederle Laboratories.

DESCRIPTION: Each gram of ARISTOCORT A Ointment contains 1 mg. (0.1%) of the highly active steroid, Triamcinolone Acetonide (a derivative of triamcinolone) in a specially formulated base composed of emulsifying wax NF, white petrolatum, and propylene glycol. In addition, the 0.1% Ointment contains Tenox II and lactic acid.
INDICATIONS: For relief of inflammatory manifestations of corticosteroid-responsive dermatoses.
CONTRAINDICATIONS: Viral skin diseases, such as varicella and vaccinia; hypersensitivity to any component (not for ophthalmic use); when circulation is markedly impaired.
WARNINGS: Safety of use in pregnancy has not been absolutely established. Do not use extensively, in large amounts, or for prolonged periods of time in pregnant patients.
PRECAUTIONS: If irritation develops, discontinue

Aristocort® A
Triamcinolone Acetonide
Ointment 0.1% with Propylene Glycol

The triamcinolone in ARISTOCORT A 0.1% Ointment is 100% pre-solubilized for faster release. The slow evaporation of the propylene glycol base holds ARISTOCORT A Ointment to the lesion. Paraben-free and lanolin-free.

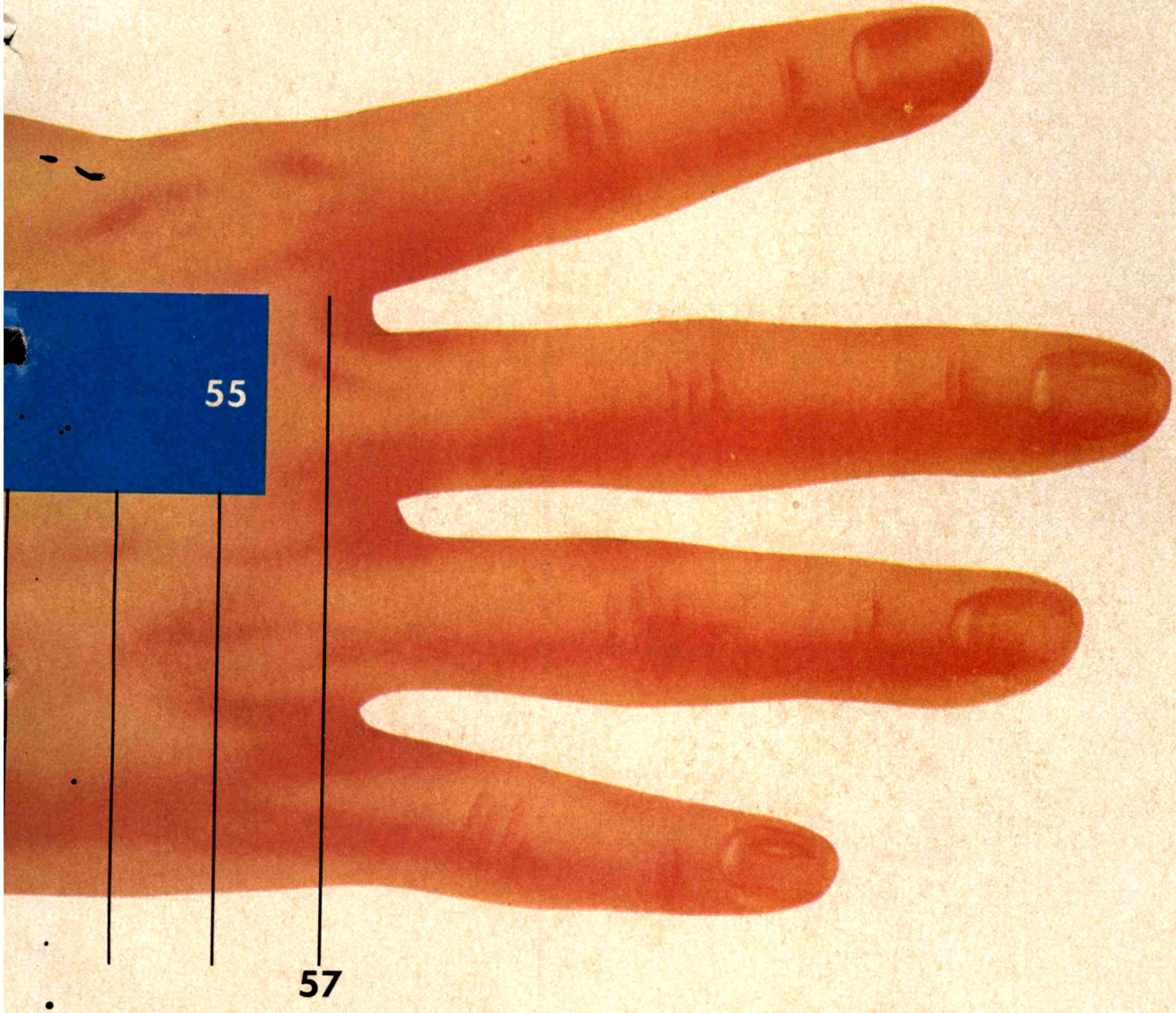

use and institute appropriate therapy. In infections, use appropriate antifungal or antibacterial agents; if a favorable response does not occur promptly, discontinue the corticosteroid until the infection is adequately controlled. If extensive areas are treated or the occlusive technique is used, increased systemic absorption of the corticosteroid may occur; take suitable precautions.

ADVERSE REACTIONS: (local) Burning sensations, itching, irritation, dryness, folliculitis, secondary infection, skin atrophy, striae, hypertrichosis, acne-form eruption and hypopigmentation.

Lederle

LEDERLE LABORATORIES,
A Division of American Cyanamid Company,
Pearl River, New York 10965

059—7R

for dry and itchy winter skin...

EMULAVE® BAR

non-alkaline, soap-free, not only cleans but helps keep moisture in.

Here's why EMULAVE satisfies patients...and you:

- More available natural emollients than any other cleansing bar. EMULAVE is enriched with 29% skin-softening emollients, which help replenish skin lipids and provide the protective coating that seals in normal skin moisture.
- Contains no soap. A special skin-tested synthetic agent provides the cleansing and sudsing action... with minimal drying effect.
- Contains 30% AVEENO Colloidal Oatmeal for soothing, anti-pruritic, anti-inflammatory action.
- EMULAVE pH approximates that of normal skin.

Available in 3-oz. bars.

SOAP-FREE
Emulave
cleansing bar
for dry skin

Cooper Cooper Laboratories, Inc.
Wayne, N.J. 07470

322-9/Dec.,1975

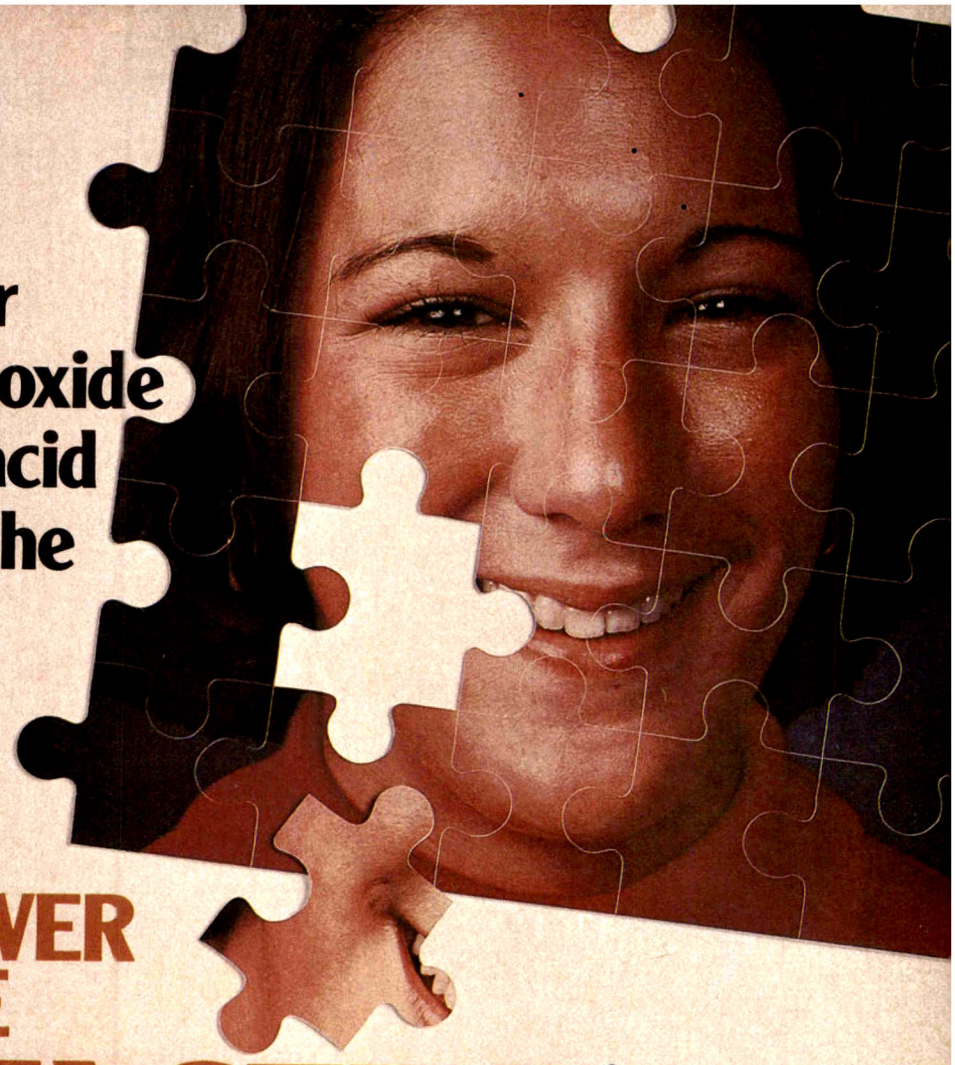

When either benzoyl peroxide or retinoic acid can't solve the puzzle of pustular acne...

THE ANSWER COULD BE SULFACET-R®

(10% sodium sulfacetamide, 5% sulfur)

- **Exerts** broad spectrum antibacterial activity
- **Controls** pustular stages of acne and seborrhea quickly, safely...without unsightly desquamation
- **Safety record**...A low incidence of sensitivity has been observed in thousands of patients during the past two decades
- **Provides** instant "Social Confidence" with the exclusive Dermik Color Blender™ customized tinting to match individual patient skin tones

SULFACET-R® LOTION

DESCRIPTION—Sulfacet-R® Acne Lotion contains (as dispensed) sodium sulfacetamide 10% and sulfur 5% in a flesh-tinted lotion of purified water, alkyl-aryl sulfonic acid salts, hydroxyethylcellulose, propylene glycol, xanthan gum, lauric myristic diethanolamide, polyoxyethylene laurate, cyclohexanediamine tetraacetic acid, butylparaben, methylparaben, silicone emulsion, talc, zinc oxide, titanium dioxide, attapulgite, iron oxides, pH buffers and 2-bromo-2-nitropropane-1, 3-diol.

ACTIONS—Provides keratolytic, peeling, drying and antiseborrheic action.

INDICATIONS—An aid in the treatment of acne vulgaris, acne rosacea and seborrheic dermatitis.

CONTRAINDICATIONS—This product is contraindicated for use by patients having known hypersensitivity to sulfonamides, sulfur or any other component of this preparation. Not to be used by patients with kidney disease.

PRECAUTIONS—For external use only. Keep away from eyes. If irritation develops, discontinue use and consult physician. Sensitivity to sodium sulfacetamide may occur. Therefore, caution and careful supervision should be observed when prescribing this drug for patients who may be prone to hypersensitivity to topical sulfonamides. Particular caution should be employed if areas of denuded or abraded skin are involved. Patients should be carefully observed for possible local irritation or sensitization during long term therapy. Occasionally, certain individuals may be sensitive to one or more components of this preparation.

The object of this therapy is to achieve desquamation without irritation, but sodium sulfacetamide and sulfur can cause reddening and scaling of the epidermis. These side effects are not unusual in the treatment of acne vulgaris, but patients should be cautioned about the possibility. Keep out of the reach of children.

ADVERSE REACTIONS—Previous toxic reactions such as agranulocytosis, acute hemolytic anemia, purpura hemorrhagica, drug fever, jaundice and contact dermatitis indicates hypersensitivity to sulfonamides.

DIRECTIONS—Shake well before using. Apply a thin film 1 to 3 times daily with light massaging to blend in each application in accordance with the physician's directions. Each package contains a "Dermik Color Blender" which enables the patient to alter the basic shade of the lotion so that is matches the skin color exactly.

[Important to the Pharmacist—At the time of dispensing, add contents of vial* to the bottle. Shake well and/or stir with a glass rod to insure a uniform dispersion. Place expiration date of four (4) months on bottle label.]

*"Sulfa-Pak" vial contains 2.4 grams of sodium sulfacetamide.

HOW SUPPLIED—Bottle, 1 oz.

CAUTION—Federal law prohibits dispensing without prescription.

Dermik

Dermik Laboratories, Inc.
Fort Washington, Pa., U.S.A. 19034

Food Allergy

"Skin testing with many foods is unreliable and can be dangerous"

Hoffman D R & Haddad Z H:
Diagnosis of IgE mediated reaction to food antigens by radioimmunoassay.
J. Allerg. clin. immunol. 54 (1974) p. 165

Phadebas RAST is a useful adjunct in the diagnosis of IgE mediated food hypersensitivities.

Phadebas RAST®

Pharmacia Diagnostics AB
Uppsala · Sweden

Pharmacia Diagnostics

Argentina Laboratorios Dr. Gador y Cia., S.A.C.I. Casilla de Correo 4041 1006 BUENOS AIRES. **Australia** Pharmacia (South Seas) Pty. Ltd. P.O. Box 175 4 Byfield Street NORTH RYDE N.S.W. 2113. **Austria** Pharmacia Gesellschaft m.b.H. Rathausplatz 4 A-1010 WIEN. **Belgium** N.V. Pharmacia Belga S.A. Bld. Gen. Jacqueslaan 26 B-1050 BRUSSELS. **Brazil** Emprêsa Medimex Importação e Comércio Ltda. Rua Cardoso Marinho, 40 Caixa Postal 33-ZC-00 RIO DE JANEIRO. **Canada** Pharmacia (Canada) Ltd. 2044 boul. St. Régis Blvd. DORVAL, Québec H9P 1H6. **Denmark** Pharmacia AS, Herredsvejen DK-3400 HILLERÖD. **Finland** Pharmacia OY Norrskensvägen 6, SF-02100 ESBO. **France** Pharmacia France S.A. Rue de Marly Parly 2 F-78150 LE CHESNAY. **German Federal Rebublic** Deutsche Pharmacia G.m.b.H. Munzinger Strasse 9 Postfach 5480 D-7800 FREIBURG. **Great Britain** Pharmacia (G.B.) Ltd. Paramount House 75 Uxbridge Road LONDON W5 5SS. **Greece** G.A. Kambanis Imports-Exports-Representations 3 Iridanou Street ATHENS 612. **Italy** Importex Chimici Farmaceutici S.p.A. P.O. Box 467 Via Flavia 122/124 I-34100 TRIESTE. **Mexico** Internacional Cientifica S.A. Apartado Postal 2-807 Angel del Campo 17-A MEXICO 12 D.F. **The Netherlands** Gist-Brocades N.V. Diagnostics Dept. P.O. Box 324 Frijdastraat 7–9 RIJSWIJK (Z H) 2109. **Norway** Norsk Pharmacia A/S Postboks 2005 Grünerløkka OSLO 5. **Portugal** J.A. Baptista D'Almeida Lda. Apartado 1339 LISBOA 1. **Spain** Atom, Paseo del Monte 34 BARCELONA 12. **Sweden** Pharmacia Norden AB Diagnostics Dept. Box 159 751 04 UPPSALA 1. **Switzerland** Pharmacia -pdf- (Schweiz) A.G. 214 Seefeldstrasse CH-8034 ZUERICH. **USA** Pharmacia Diagnostics Division of Pharmacia Inc. 800 Centennial Avenue PISCATAWAY New Jersey 08854. **Other countries** Pharmacia Diagnostics AB Box 17 S-751 03 UPPSALA 1 Sweden.

Letters to the Editor

Readers are advised that in view of The Copyright Revision Act of 1976, *all Letters to the Editor submitted for publication must contain on the transmittal letter the following language: "The person(s) undersigned hereby grant the American Medical Association permission to publish this Letter and in addition, hereby assigns all copyright ownership therein to the AMA."*

Man Eating Tiger?

To the Editor.—Concerning the article by Shmunes and Shu entitled, "Bullous Disease of Childhood: Report of a Case Demonstrating Antibasal Cell Antibody," which appeared in the March 1977 ARCHIVES (113:325-327), what kind of cell is an antibasal cell? I assume it is a cell found at the "anti-base." Certainly the authors meant anti-basal-cell antibody, which clearly indicates an antibody against the basal cell.

Such hyphenations are useful. Compare "a large comedo-extractor" with "a large-comedo extractor." Compare "I saw a man eating tiger" with "I saw a man-eating tiger." The meanings are quite different. Thus, in the article by Shmunes and Shu, on page 326, the fourth line of the "Comment" section should read: "drug-related eruptions," and line 6 should read: "drug-induced."

Small details, perhaps, but I do think that precision begets clarity, and both are important.

STANLEY A. SPATZ, MD
Hallandale, Fla

In Reply.—I have checked my copy of the original manuscript that I submitted for publication, and I am pleased to tell you that I also included the hyphen in "anti-basal cell." Evidently the hyphen was deleted through the exercise of editorial prerogative. In reviewing the edited manuscript, I must admit that I felt no twinge of pain at the deletion, though I understand and respect the fact that there are those who would view such a change as a transgression.

EDWARD SHMUNES, MD
Columbia, SC

More on Skin Closures

To the Editor.—I have used the new Clearon skin closures by Ethicon in my office for the past year and have not found them as satisfactory as Drs Stegman and Tromovitch indicated in their letter to the editor published in the ARCHIVES (113:1134, 1977). It has been my experience that wounds in the seborrheic areas or in areas of frequent facial movement tend to lose their Clearon skin closures within several days. If the closures are not lost, they are rolled up at the ends and are unsightly. They do not hold well when the patient sweats. I have found a much more satisfactory method of wound support that is both cosmetically elegant and unremovable by normal mechanical forces present on the skin. I use Skin-tone Steri strips (3M), or Skin-tone Micropore paper tape (3M). Prior to application of the Steri strips, the skin is painted with spirit gum. Spirit gum is obtainable at costume stores or actors-supply stores, and is used to attach costume wigs and facial hair. It is flexible, transparent, and sticks like crazy. If the Steri strips are applied while the spirit gum is fairly wet, they become almost transparent and the wound edges are easily visualized. I have worn a set of Steri strips affixed in this manner over a McBurney's incision for six weeks. During that time, I have played racquet ball and bathed as usual. The strips are still in place, and holding well. I have found that supporting a surgical wound until the strips drop off on their own gives a more cosmetic healing. The added advantage of the paper strips is that they "breathe." Spirit gum may be removed, if necessary, with rubbing alcohol or tape solvent.

P. HAINES ELY, MD
Roseville, Calif

Should Therapeutic Coal-Tar Preparations Be Available Over-the-Counter?

To the Editor.—I should like to take issue with the position of the American Academy of Dermatology (AAD) on over-the-counter (OTC) coal-tar products as stated in the AAD Bulletin of July-August 1977.

Nowhere in the AAD statement is reference made to the review of the world literature by Greither et al[1] who found 13 cases of skin cancers in man that were probably induced by prolonged applications of therapeutic tar preparations. All but two patients were men. The most frequent sites of the cancers were the genital areas and the adjacent skin: scrotum, five cases, vulva, one, groin, one, and upper thigh, one. In nine of the cases in which the treatment periods were known, there was a history of prolonged self-medication that ranged from three months to 34 years; it was most commonly used for scrotal pruritus. More recently, Hirohata[2] mentions a patient who had been treating himself for ten years with a tar preparation until he noticed "warts in the lesion."

Rook et al[3] describe one case in detail and cite five others that are also included in Greither's report. Rook's patient was a 60-year-old man who had applied at least one ounce of a tar ointment or paste every two weeks to the groin for 34 years. Two ulcerated squamous cell carcinomas developed on the upper left thigh and were excised. Rook comments on the rarity of carcinomas that are induced by therapeutic applications of tar in contrast to the frequency of occupational tar cancer. He postulates that the infrequency of the former event may be due to an inhibitory effect of the ointment or paste base on the carcinogenic action of tar. Experimental support for this hypothesis is provided by Simpson et al,[4] who found a substantial loss of carcinogenic activity of methylcholanthrene when it was dissolved in lanolin instead of acetone.

In three of the five cases cited by Rook, the tar had been used in solution, which was most likely alcoholic, and in one it was used in an emulsion base. The patient in an additional case of Greither used a tar solution. Rook concludes with the statement: "Meanwhile the possibly greater carcinogen-

ic risk involved in the prolonged application of tar as a paint in aqueous or alcoholic solution, or in the increasingly popular water-miscible emulsion bases, should be seriously considered when tar is prescribed in chronic dermatoses."

What makes this matter of immediate concern is the recent introduction of two coal-tar preparations that use an alcoholic gel-type base and are both available as OTC products. The carcinogenicity of commercially available and commonly used therapeutic tar preparations is well documented in the world literature.[2,5,6] Their prolonged application leads to cutaneous neoplasms, mostly squamous cell carcinomas, in laboratory animals. The carcinogen is most likely benzpyrene, and there is strong correlation between the carcinogenicity of the preparation and its benzpyrene content.[2,5] The AAD statement recommends studies relating to DNA repair, mitotic activity, "or other cutaneous phenomena suggestive of human carcinogenic potential of tar products." A much more direct and simpler approach would be to ask for long-term painting experiments with tar products, including alcoholic gel-base types, and then to observe for the possible development of neoplasms, both cutaneous and internal.

One of the arguments advanced by the AAD for not taking a strong stand against the OTC availability of tar preparations is "cost containment." If we are that concerned about cost, why not advocate making all topical steroids available on an OTC basis? After all, topical steroids are apparently not carcinogenic, have proved to be remarkably safe considering the millions of ounces that have been prescribed, but they are still very expensive.

The purpose of this letter is not to argue against the use of tar preparations in dermatology. They have stood the test of time as effective and reasonably safe medications. Furthermore, the availability of tar in the cosmetically elegant gel base is a distinct advance in therapeutics. It is the uncontrolled use of such preparations that, in my opinion, poses a clear danger. We should not wait for the first case of scrotal cancer from prolonged self-medication with tar gels before we decide that the hazard is real. By that time, there may very well be other cases.

Note: The substance of this letter was sent, prior to the FDA hearings on OTG tar products in June 1977, to Peter N. Horvath, MD, AAD-FDA liaison, who graciously acknowledged its receipt.

HERSCHEL S. ZACKHEIM, MD
Redwood City, Calif

1. Greither A, Gisbertz C, Ippen H: Teerbehandlung und Krebs. *Z Haut-Geschlechtskr* 42:631-635, 1967.
2. Hirohata T, Masuda Y, Horie A, et al: Carcinogenicity of tar-containing skin drugs: Animal experiment and chemical analysis. *Gann* 64:323-330, 1973.
3. Rook AJ, Gresham GA, Davis RA: Squamous epithelioma possibly induced by the therapeutic application of tar. *Br J Cancer* 10:17-23, 1956.
4. Simpson WL, Carruthers C, Cramer W: Loss of carcinogenic activity when methylcholanthrene is dissolved in anhydrous lanolin. *Cancer Res* 5:1-4, 1945.
5. Shabad LM, Khesina AJ, Linnik AB, et al: Possible carcinogenic hazards of several tars and of Locacorten-tar ointment (spectro-fluorescent investigations and experiments in animals). *Int J Cancer* 6:314-318, 1970.
6. Hilfrich J, Mohr U: Vergleichende Untersuchungen zur carcinogenen Wirkung des herkömmlichen Steinkohlenteers und einer neuen synthetischen Teermischung. *Arch Dermatol Forsch* 242:176-178, 1972.

Lessons in Grammar

To the Editor.—The article by Rea and Levan, "Current Concepts in the Immunology of Leprosy" (*Arch Dermatol* 113:345-352, 1977), includes a phrase: "but is a phenomena. . . ." Please note that the singular "phenomenon" is required here. Similarly, on p 348, column 3, line 26, "sequella" (not sequellae) is the required (singular) form. Once again, lines 38 to 40 on this page should read: "Abnormalities [plural] . . . . *have* been proposed."

Another error is that on p 347, column 2, line 6, and is simply quoted from reference 30: " 'frank lepromatous' patients." This should read "frankly lepromatous" (an adverb is needed to modify the adjective "lepromatous").

I submit these corrections constructively and do not mean to detract from the scientific excellence of the article.

STANLEY A. SPATZ, MD
Hallandale, Fla

Lupus Band Test

To the Editor.—In his recent review of the lupus band test (LBT), Monroe[1] stated, "The value of the LBT as a diagnostic tool is well established." Later in the article, he stressed the specificity of this same test for lupus erythematosus when confronted with a patient who had a connective tissue disease with a positive antinuclear antibody (ANA). While I would agree that the LBT should always be included in the diagnostic armamentarium for connective tissue disorders like systemic lupus erythematosus, it is not specific for this disease. Baldassare et al[2] were able to show deposits of IgM in the dermal-epidermal junction zone in eight of 16 patients who were thought to have either definite or classic rheumatoid arthritis. At the time the biopsy specimen was taken from the volar aspect of the right forearm, the rheumatoid factor was positive in 11 of these same 16 patients.

The presence of immune complexes along the dermal-epidermal junction of normal skin cannot be regarded as specific for lupus erythematosus. The presence of these immune complexes once again raises questions that regard their true importance. Only through large surveys that include normal volunteers and patients afflicted with various connective tissue diseases can valid conclusions be reached.

THOMAS G. OLSEN, MD
Bethesda, Md

1. Monroe EW: Lupus band test. *Arch Dermatol* 113:830-834, 1977.
2. Baldassare A, Weiss T, Tsai C, et al: Immune complexes in the skin of patients with rheumatoid arthritis, abstracted. *Arthritis Rheum* 19:788, 1976.

In Reply.—Dr Olsen questions the specificity of the lupus band test (LBT) taken from clinically normal skin as a diagnostic tool. He cites a recent abstract by Baldassare et al[1] (published after the submission of my review article), who found deposits of IgM at the dermal-epidermal junction in eight of 16 patients with rheumatoid arthritis. In my review article, I concluded that "the specificity of the LBT is very high in differentiating LE from other cutaneous disorders that are clinically similar."[2] A review of the literature produces only isolated reports of positive LBTs in other disorders. A recent large series of studies by Burnham and Fine,[3] Grossman et al,[4] Gilliam,[5] and Tuffanelli[6] show that the LBT is positive in a very small percentage of cases of other ANA-positive diseases. By combining these four series, the frequency of positive LBTs in other ANA-positive diseases is as follows: drug-induced lupus erythematosus (one of 27 cases); rheumatoid arthritis (one of 46 cases); scleroderma (none of 65 cases); and dermatomyositis (none of 25 cases).

Thus, the more recent findings by Baldassare et al,[1] in regard to patients with rheumatoid arthritis, are not supported by several previous large

studies. The study by Baldassare et al[1] and the findings by Levitin et al,[7] which both showed that three of six patients with mixed connective tissue disease have positive LBTs, do point out the need for further immunopathologic studies in this area. However, at the current time, the vast majority of scientific studies lead to the conclusion that the LBT is a highly sensitive and specific diagnostic method for discerning lupus erythematosus.

EUGENE W. MONROE, MD
Milwaukee

1. Baldassare A, Weiss T, Tsai C, et al: Immune complexes in the skin of patients with rheumatoid arthritis, abstracted. *Arthritis Rheum* 19:788, 1976.
2. Monroe EW: Lupus band test. *Arch Dermatol* 113:830-834, 1977.
3. Burnham TK, Fine G: The immunofluorescent "band" test for lupus erythematosus: III. Employing clinically normal skin. *Arch Dermatol* 103:24-32, 1971.
4. Grossman J, Callerame ML, Condemi JJ: Skin immunofluorescence studies on lupus erythematosus and other antinuclear-antibody-positive disease. *Ann Intern Med* 80:496-500, 1974.
5. Gilliam JN: The significance of cutaneous immunoglobulin deposits in lupus erythematosus and NZB/NZW F_1 hybrid mice. *J Invest Dermatol* 65:154-161, 1975.
6. Tuffanelli DL: Cutaneous immunopathology: Recent observations. *J Invest Dermatol* 65:145-153, 1975.
7. Levitin PM, Weary PE, Giuliano VJ: The immunofluorescent "band" test in mixed connective tissue disease. *Ann Intern Med* 83:53-55, 1975.

Relapsing Polychondritis With Positive Direct Immunofluorescence

To the Editor.—Relapsing polychondritis (RPC) is a rare, occasionally fatal, disease of unknown origin, and pathogenesis results in chondrolysis and ultimate collapse of all cartilaginous structures. Recent studies suggest an immune disorder with production of autoantibodies possibly to mucopolysaccharides and the perpetuation of cartilaginous inflammation by a reduced protolytic process.

Rogers et al[1] report circulating autoantibodies to cartilage in the sera of patients with RPC. Immunoglobulin reactants against cartilage have not been demonstrated, to date, with the use of direct immunofluorescence. I would like to report a case of RPC that demonstrated the classic clinical and histopathologic changes of relapsing polychondritis with deposition of IgG, IgA, C3 at the fibrocartilaginous junction of the ear cartilage on direct immunofluorescence.

Report of a Case.—A 48-year-old woman was seen in the Department of Dermatology, The Cleveland Clinic Foundation, in 1975, with a history of recurrent episodes of tender, red ears, which spontaneously

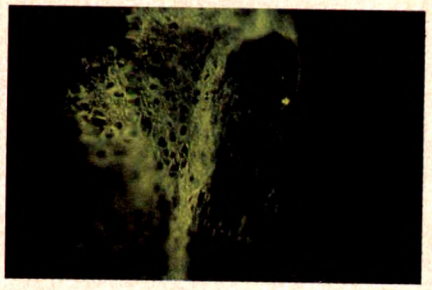

Direct immunofluorescence of cartilage demonstrates coarsely granular deposition of IgG, IgA, and C3 at chondrofibral junction.

resolved without treatment during a period of four to six weeks. This condition had been present since the winter of 1974. History revealed one episode of alopecia areata and allergic contact dermatitis.

On her first visit in 1975, the patient had a four-day history of a red, tender left ear. No other cartilaginous structures were clinically involved. Laboratory testing was unremarkable. She had a normal hemogram and an antinuclear factor of 1:20; results of a blood chemistry study using an automated multiple analysis system were normal.

The skin biopsy specimen of the left ear revealed acute and chronic, dermal inflammation and perichondritis with focal chondrolysis. Direct immunofluorescence of the cartilage demonstrated coarsely granular deposition (3+) of IgG, IgA, and C3 at the chondrofibral junction (Figure), while direct immunofluorescence of the skin was negative for deposition of immunoglobulins at the dermal-epidermal junction.

The patient's condition was treated with dapsone (200 mg/day) for two weeks with resolution of the inflammation of the left ear cartilage.

Since the initial visit, the patient has experienced two exacerbations of RPC, which have been controlled by a two-week treatment period of prednisone (20 mg/day). Dapsone was not resumed because of clinical symptoms of malaise, headache, and nausea.

Comment.—Pearson et al[2] and Dolan et al[3] all attempted to relate the cause of RPC to an autoimmune reaction. They proposed that the disease was an immune disorder with production of autoantibodies to cartilage with the specific suggestion of a defect in mucopolysaccharide metabolism. This could be supported by recovery mucopolysaccharides from urine. In our case, we are further able to support this hypothesis with a demonstration of autoantibodies to cartilage with the use of direct immunofluorescence.

The clinical response to dapsone therapy was recently reported by Martin et al[4] and is probably a result of inhibition of lysosomal enzymes as proposed by Barranco.[5] Other therapies which have also been effective are parenteral corticosteroids and aspirin.

WILMA F. BERGFELD, MD
Cleveland

1. Rogers PH, Boden G, Tourtellotte CD: Relapsing polychondritis with insulin resistance and antibodies to cartilage. *Am J Med* 55:243-248, 1973.
2. Pearson CM, Kline HM, Newcomer VD: Relapsing polychondritis. *N Engl J Med* 263:51-58, 1960.
3. Dolan DL, Lemmon GB Jr, Teitelbaum SL: Relapsing polychondritis: Analytical literature review and studies on pathogenesis. *Am J Med* 41:285-299, 1966.
4. Martin J, Roenigk HH Jr, Lynch W, et al: Relapsing polychondritis treated with dapsone. *Arch Dermatol* 112:1272-1274, 1976.
5. Barranco VP: Inhibition of lysosomal enzymes by dapsone. *Arch Dermatol* 110:563-566, 1974.

Swimmer's Green Hair

To the Editor.—In a recent report, Lampe et al[1] described the occurrence of green scalp-hair in children with blond hair and linked this occurrence to the use of copper-based algicides in swimming pools. In fact, these authors proved their hypothesis by immersing blond hair in a 1% copper sulfate solution for eight hours, thus reproducing the green tint that is imparted on blond hair by swimming pool water.

I have noted green hair in two of my children who have blond hair and who are active swimmers on a swim team. Indeed, I have observed green hair in many blond children who regularly participate in swim-practice or com-

Fig 1.—Green tint appears on blond strands of hair, while darker hair is not tinted.

Fig 2.—Strands of green hair and non-tinted, darker hair of same child.

petitive swimming events. The coloration is best appreciated when wet hair is observed in bright sunlight. However, when the hair is dry, the green coloration can be easily noticed as well (Fig 1 and 2). Regular shampooing reduces the green tint. Immersion of green hair locks in a 3% hydrogen peroxide solution will remove the discoloration in two to three hours.

The examination of green hair under the scanning electron microscope, and the determination of the copper content of green hair as compared with hair of normal color from the same person, would be interesting.

LT COL DETLEF K. GOETTE, MD, USA
Presidio, San Francisco

1. Lampe RM, Henderson AL, Hansen GH: Green hair. *JAMA* 237:2092, 1977.

Lupus Band Test

To the Editor.—I would like to clarify some information presented in the first paragraph of my recent article on the lupus band test (ARCHIVES 113:830-834, 1977). In 1963, Burnham et al[1] were the first to demonstrate a band of localized immunoglobulins at the dermal-epidermal junction in the skin lesions of patients with both discoid and systemic lupus erythematosus (DLE and SLE, respectively). In this original report the uninvolved skin of one patient with DLE and that of a patient with SLE was examined, but, in both cases, the skin was negative for the lupus band.

In 1964, Cormane[2] was the first to demonstrate that certain patients with SLE had a band of immunoglobulins at the dermal-epidermal junction of visibly normal skin.

I wish to thank Dr Burnham for kindly indicating to me that the first sentence of the review article incorrectly implies that he, not Cormane, first reported the lupus band in clinically uninvolved SLE skin.

EUGENE W. MONROE, MD
Milwaukee

1. Burnham TK, Neblett TR, Fine G: The application of the fluorescent antibody technique to the investigation of lupus erythematosus and various dermatoses. *J Invest Dermatol* 41:451-456, 1963.

2. Cormane RH: "Bound" globulin in the skin of patients with chronic discoid lupus erythematosus and systemic lupus erythematosus. *Lancet* 1:534-535, 1964.

Contact Dermatitis Owing to Tincture of Benzoin

To the Editor.—Tincture of benzoin consists of 10% benzoin in alcohol, while compound tincture of benzoin contains 10% benzoin, 2% aloe, 8% storax, and 4% tolu balsum in alcohol. In the last ten years there have been three reports in the English literature of allergy to tincture of benzoin or compound tincture of benzoin.[1-3] I report two cases of contact dermatitis that were due to tincture of benzoin.

Report of Cases.—CASE 1.—A 39-year-old man was seen on Feb 20, 1967 because of an erythematous, eczematous eruption of four days' duration that involved the perianal area, the buttocks, and the back. One day prior to the onset of the eruption, his family physician treated him for pruritus ani by painting the perianal area with Castellani's paint (a mixture containing fuchsin, water, boric acid, acetone, resorcinol, and phenol). A diagnosis of contact dermatitis with an id reaction was made. The patient's condition was treated with systemic corticosteroids and the eruption resolved.

The patient saw his family physician on March 3, 1977 for pruritus ani once more, and the perianal area was painted with tincture of benzoin and gentian violet. Five days later, the patient again developed an eczematous eruption on the back and the buttocks, and also on the elbows. His condition was treated with systemic corticosteroids and the eruption resolved. Patch tests were applied to 1% salicylic acid in petrolatum, 1% aqueous solution of phenol, 3% benzocaine in petrolatum, 1% aqueous solution gentian violet, 5% resorcinol in petrolatum, .05% aqueous solution of mercury bichloride, and 10% benzoin in alcohol. There was a ± doubtful reaction to resorcinol and a 3+ vesicular eruption to tincture of benzoin associated with an id reaction on the elbows, legs, and face.

CASE 2.—A 15-year-old boy was seen Sept 24, 1976, because of a diffuse, eczematous eruption of the right leg. This was associated with a generalized papular eruption on the trunk and other extremities.

The boy was a football player, and for 2½ weeks he had been applying a spray, which contained tincture of benzoin, tannic acid, acetone, rosin, and isopropyl alcohol, to his leg. He would then cover the area with tape for 2½ hours daily. The eruption had appeared on the leg one week before he was seen and had become generalized three weeks before his visit. A diagnosis of contact dermatitis was made. The eruption resolved on treatment with systemic corticosteroids. Patch tests were then applied with 10% tincture of benzoin in alcohol, 10% aqueous solution of tannic acid, acetone, 10% rosin in alcohol, 18% isopropyl alcohol, tape, and the preparation that contained these chemicals. The patient developed a 2+ reaction to tincture of benzoin and also to the preparation mentioned. In addition, he also developed an id reaction on the back that necessitated further treatment with systemic corticosteroids.

Comment.—The first patient was possibly allergic to resorcinol and was highly sensitive to tincture of benzoin. The second patient was also allergic to tincture of benzoin. According to Fisher,[4] benzoin is a rare sensitizer that may be present in adhesives, nail polish, perfumes, cuticle removers, inks, benzoinated lard, water-repellent barrier cream, lozenges, cosmetics, Arning's mixture, raw beeswax, bee glue, and preservatives in adhesives. Benzoin may cross-react with balsam of Peru, storax, eugenol, vanilla, alpha-pinene, benzyl alcohol, and benzyl cinnamate.[4,5]

Tincture of benzoin may be applied to the skin directly for a variety of purposes.[6] A tape adherent, which contains abietic anhydride, parachloro-metaxylenol, and chlorinated solvents, may be applied beneath adhesive tape in cases where the individual is allergic to benzoin.

RALPH J. COSKEY, MD
Detroit

1. Cullen SI, Tonkin A, May FE: Allergic contact dermatitis to compound tincture of benzoin spray. *J Trauma* 14:348-350, 1974.

2. Spott DA, Shelley WB: Exanthem due to contact allergen (benzoin) absorbed through skin. *JAMA* 214:1181-1182, 1970.

3. Luria PP: Allergic reaction to tincture of benzoin compound. *Eye Ear Nose Throat Mo* 46:224-227, 1967.

4. Fisher AA: *Contact Dermatitis*, ed 2. Lea & Febiger Publishers, Philadelphia, 1973.

5. Hjorth N: Eczematous allergy to balsams. *Acta Derm Venereol*, suppl 46, 1961, pp 1-216.

6. Steiner K, Leiter W: Investigation of contact type dermatitis due to compound tincture of benzoin. *J Invest Dermatol* 13:351-359, 1949.

Treatment of Hallopeau's Acrodermatitis With Topical Mechlorethamine

To the Editor.—The therapy for Hallopeau's acrodermatitis (continua, perstans), which includes the use of common topical antipsoriatic agents like tar, cignolin, and corticosteroids, is mentioned in literature, but the extreme resistance of the disease to any therapy is well known.

The systemic use of cytostatic agents (methotrexate) has been described with good results in this disease, but it carries all the inevitable risks of a long-term treatment.[1] Topical use of methotrexate soaks under occlusion, which have been used alternately with betamethasone valerate, has been found to have beneficial results in the treatment of relapsing pustular eruption of the hands and feet.[2]

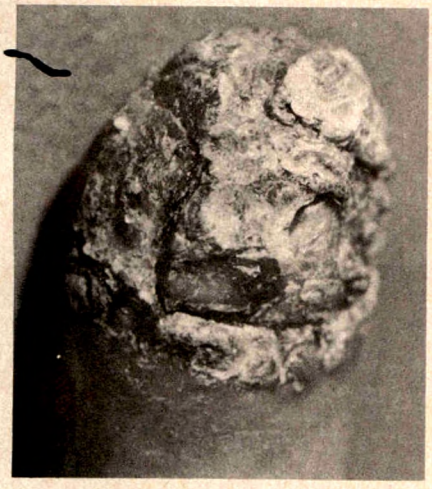

Fig 1.—Tip of right thumb before treatment.

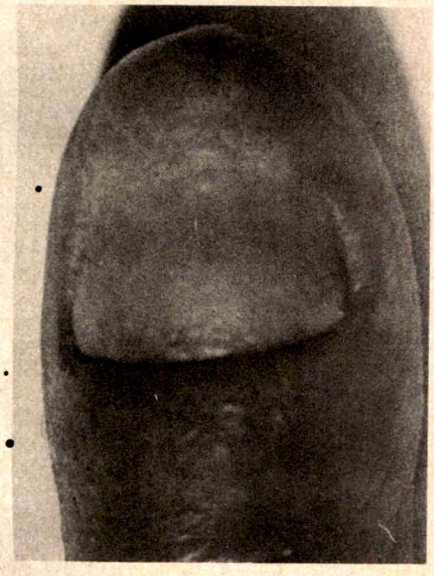

Fig 2.—Tip of right thumb after two months of treatment.

We could not find a report of the topical use of a cytostatic agent in the treatment of Hallopeau's acrodermatitis. Topical application of mechlorethamine hydrochloride (a nitrogen mustard) has been found to be useful in psoriasis.[3,4] We decided to treat a patient with Hallopeau's acrodermatitis with this agent.

Report of a Case.—A 42-year-old woman had Hallopeau's acrodermatitis on the tip of the right thumb (Fig 1) and the left ring finger since the age of 28 years. Topical treatment in the past had consisted of radiation, tar ointments, 0.1% triamcinolone (Kenalog) acetonide, and 0.2% betamethasone (Valisone) valerate, sometimes under occlusion without any lasting effect. In 1970 she was hospitalized and treated with methotrexate soaks alternated with betamethasone under occlusion toward which her condition initially showed a favorable response that lasted only for a very short period. Then she was treated again with pastes and the three following corticosteroid creams: 0.1% triamcinolone acetonide, 0.2% betamethasone valerate, and 0.1% halcinonide (Halog). During this time, she continuously had pustulation and painful desquamation of the affected fingertips which necessitated continuous bandaging.

The nails were shed during the course of this period. She was hospitalized again in April 1976, and it was decided to treat her condition with mechlorethamine topically.

Favorable reports and our own experiences with the use of mechlorethamine in psoriasis, together with the pathogenetic resemblance of these two diseases,[5] made us expect a good response in this disease also. A solution of 10 mg of mechlorethamine hydrochloride in 60 ml of sterile water was applied topically on the affected fingertips twice each day. After two weeks, there were signs of irritation of the surrounding skin though the lesions themselves appeared very well, and the concentration was lowered to 10 mg of mechlorethamine hydrochloride in 120 ml of water once each day, followed by the application of 0.1% fluorinated halcinonide.

Since then, and until the time of writing this communication (seven months after the beginning of the treatment), no new pustules have developed, and the skin of the fingertips looks completely normal except for the absence of the nails (Fig 2). The frequency of application was decreased to twice each week.

Surprisingly, there were, until now, no signs of sensitization to mechlorethamine. We do not know whether the topical use of 0.1% halcinonide after the application of mechlorethamine had anything to do with this. Currently, we have also had favorable, short-term results with the use of mechlorethamine in the treatment of three patients with pustulosis palmaris et plantaris.

Comment.—We think that topical use of mechlorethamine in patients with Hallopeau's acrodermatitis could mean an excellent alternative in the treatment of this recalcitrant disease, as well as in the treatment of pustulosis palmaris et plantaris.

Longer evaluation will be needed to give a sound opinion on the topical treatment of pustular eruptions of the extremities with mechlorethamine. We intend to report on this later.

ALFRED NOTOWICZ, MD
ERNST STOLZ, MD
NELLIE V. D. HEUVEL, MD
Rotterdam, Netherlands

Nonproprietary Name and Trademark of Drug

Mechlorethamine hydrochloride—*Mustargen Hydrochloride.*

1. Konrad K: Acrodermatitis continua suppurativa Hallopeau: Behandlung mit Methotrexat. *Hautarzt* 21:119-123, 1970.
2. Allenby CF: Relapsing pustular eruption of hands and feet treated with local methotrexate. *Br J Dermatol* 78:154-157, 1966.
3. Epstein E Jr, Ugel AR: Effects of topical mechlorethamine on skin lesions of psoriasis. *Arch Dermatol* 102:504-506, 1970.
4. Mandy S, Taylor JR, Halprin K: Topically applied mechlorethamine in the treatment of psoriasis. *Arch Dermatol* 103:272-276, 1971.
5. Lever WF, Schaumburg-Lever G: *Histopathology of the Skin.* Philadelphia, JB Lippincott Co, 1975, p 142.

Causes and Genetic Predisposition in Porphyria Cutanea Tarda

To the Editor.—In his letter, the late Dr Reed[1] poses three basic problems in acquired[2] or symptomatic[3] (hepatic) porphyria cutanea tarda (PCT-S), viz, (1) causes of, (2) predisposition to, and (3) inheritance of the disease.

First, there has been an increase in the factors that cause PCT-S, or in the precipitating agents in predisposed individuals. Synthesis of porphyrins occurs in the liver cell where chemical compounds, such as drugs, are converted or detoxified. Aberrations in the porphyrin synthesis, and subsequently in the excretion, may therefore be regarded as disturbance of the liver function, with PCT-S as a clinical manifestation.[2]

Conceivably, the incidence of PCT-S will be increased by the intensified use of alcohol, oral contraceptives, drugs—with possible cross-reaction, eg, of the "caines," (unpublished data), and very likely, also by increased environmental chemical waste-products, such as lead in fish or

in gasoline fumes and phenol compounds.[4] In Rotterdam, for instance, only two cases of PCT-S were seen between 1952 and 1956, whereas 20 years later, more than five cases a year were diagnosed. Among these patients were several nondrinking Rhine barge-skippers, who had only one reported possible, common precipitating agent, ie, fumes from the exhaust in front of the navigator cabin.

Second, there is increased information regarding the genetic or inherited and the nongenetic or acquired predisposition to PCT-S. The low incidence of PCT-S with the general use of alcohol and oral contraceptives can only be explained by an individual disposition. However, in mass "toxic" PCT-S, such as by hexachlorobenzene, no disposition is required. And in "occupational" PCT-S,[4] the inheritance of such a disposition is, as in contact dermatitis, debatable; however, reported solitary cases of PCT-S in patients with symptom-free parents and eight siblings[2] appear to refute inheritance. Finally, our 80-year-old patient with hepatoma[2] had symptom-free parents and 16 [*sic*] siblings, and her five middle-aged children also showed normal urinary and fecal porphyrins. The patient recovered completely after removal of the tumor, and the porphyrin excretion normalized. Postmortem findings (death was due to another cause) indicated clearly that only the abnormal hepatic porphyrinoma cells could be held responsible for the PCT-S.

In summary, solitary PCT-S cases may apparently have an inherited basis or they may be purely acquired.

Third, consideration has been given to the existence of a hereditary PCT (PCT-H) form. In 1956,[2] the hepatic cutaneous porphyrias in adults were tentatively divided into three categories: mixed[2] or variegated[3] porphyria (PV), acquired[2] or symptomatic[3] PCT (PCT-S), and hereditary PCT (PCT-H).[2] Hereditary PCT was accepted as a separate clinical entity at the First World Conference on the Porphyrias in 1963[3]; but PCT-H was incorporated in the PV group in the latest classification on the porphyrias, in 1972.[5]

Older dermatological literature[2] and more recent literature suggest the existence of a dominantly inherited PCT (PCT-H). In support, we found in one family that, unlike during the purely cutaneous phase of PV, but as in PCT-S, two affected siblings and a clinically "burnt out"[2] aunt showed greater excretion of abnormal urinary porphyrins than abnormal fecal porphyrins. Additionally, in further contrast to PV, and consistent with PCT-S, phlebotomies apparently "cured" the patient.

We are currently working on further refined investigations of the porphyrins, enzymes, and other genetic factors of this disorder. Laboratory findings of decreased uroporphyrinogen decarboxylase activity in the erythrocytes of subclinical members in two of the three families that were examined[6] support the theoretically and clinically assumed existence of PCT-H next to a purely acquired PCT-S.

TIONG HO TIO, MD
Rotterdam, Netherlands

1. Reed WB: Causes of porphyria cutanea tarda. *Arch Dermatol* 113:235, 1977.
2. Tio TH: *Beschouwingen over de Porphyria Cutanea Tarda*, thesis. Amsterdam, 1956.
3. Editorial comment: *S Afr J Lab Clin Med* 9:302, 1963.
4. Tio TH: Evaluation of therapy in acquired porphyria cutanea tarda. *S Afr J Lab Clin Med* 17:197-198, 1971.
5. Marver H, Schmid R: The porphyrias, in Stanbury JB, Wjinjaar JB, Frederichson JS (eds): *The Metabolic Basis of Inherited Diseases*, ed 2. New York, McGraw-Hill Book Co Inc, 1972, pp 1088-1140.
6. Kushner J, Barbuto J, Lee GR: An inherited enzymatic defect in porphyria cutanea tarda. *J Clin Invest* 58:1089-1097, 1976.

Leukoderma as a Sequela of Lichen Planus

To the Editor.—Lesions of lichen planus, as a rule, leave behind a corresponding area of hyperpigmentation on healing. Recently, we observed a patient with lichen planus, in whom the lesions healed with depigmentation.

Report of a Case.—A 22-year-old woman had developed itchy, violaceous papular lesions on the extensors of the upper extremities during a two-month period. The mucous membranes were not involved, and the skin elsewhere was quite normal. There was no evidence of vitiligo. Results of a histopathologic study of a papule confirmed the diagnosis of lichen planus. The patient received prednisolone (20 mg/day) orally. Within three weeks, the lesions started to regress, and all the lesions cleared within 1½ months but left behind depigmented areas that corresponded exactly to the size of the original lesions. Prednisolone therapy was gradually withdrawn, and the patient received a psoralen (40 mg/day) orally. In about two months' time, the depigmented areas became pigmented again.

Comment.—We could not find any previous mention in the literature of lichen planus that left behind depigmented or leukodermal patches. Hence, it was considered worthwhile to report this observation.

AMRINDER J. KANWAR, MD
OM P. SINGH, MD, DVD
New Delhi

Lesions Caused by Canine Ear Mites

To the Editor.—A case that appears to be noteworthy in that it is nearly unheard of for pet owners to complain of lesions when ear mites are found in their dogs' ears is reported here.

Report of a Case.—A diagnosis-defying eruption appeared in a 28-year-old woman. The patient began to develop intensely pruritic, excoriated papules that began on the torso and spread to involve the extremities. The morphologic characteristics of these lesions were suggestive of scabies, but microscopic scrapings were negative for *Sarcoptes scabiei*. The patient's husband was unaffected. Hypersensitivity to sand flea bites was considered, which is a common problem in the San Francisco Bay area, but the clinical picture did not seem consistent with that diagnosis. Finally, the dilemma was solved by a visit to a veterinarian. The patient had recently acquired a cocker spaniel puppy, and results of a microscopic examination of the puppy's cerumen revealed *Otodectes cynotis*: canine ear mites.

Comment.—Human hypersensitivity to other varieties of animal mites is not uncommon (in these instances, the human host is bitten by but not infested with the organism). Since pet owners usually do not complain of these lesions when ear mites are found in the ears of their dogs, further investigation of these instances of infections is needed. This need for further study was also demonstrated when the veterinarian, who examined the patient's puppy, said to my secretary as she left his office with the puppy, "Maybe that's what's been giving me these itchy bites on my arms all these years!"

ROBERT P. HERWICK, MD
San Francisco

IS AQUACARE®/HP TOO MUCH FOR EVERYDAY DRY SKIN?

IF IT WEREN'T SO SAFE AND COSMETICALLY ELEGANT THE ANSWER MIGHT BE YES.

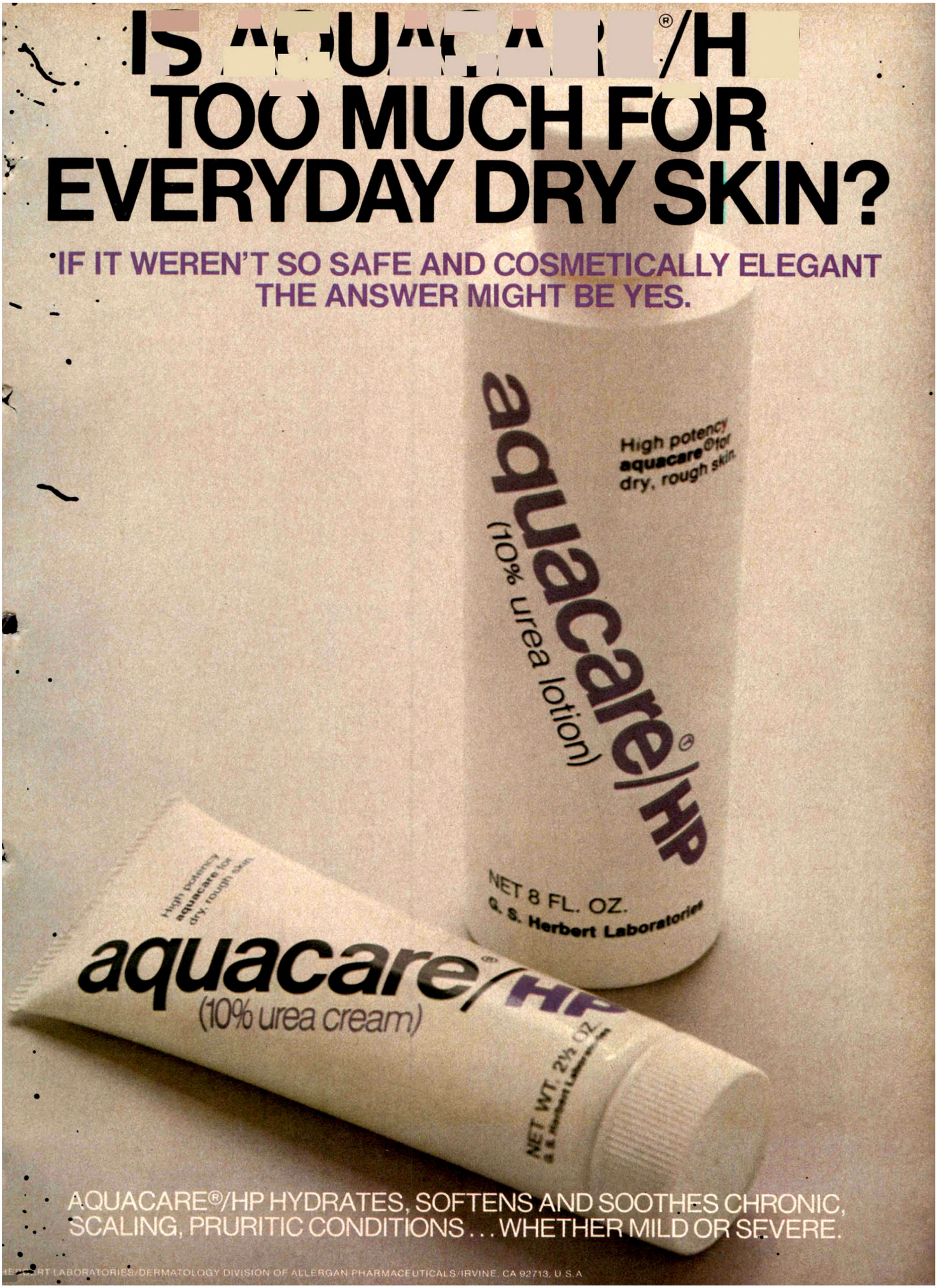

AQUACARE®/HP HYDRATES, SOFTENS AND SOOTHES CHRONIC, SCALING, PRURITIC CONDITIONS . . . WHETHER MILD OR SEVERE.

HERBERT LABORATORIES/DERMATOLOGY DIVISION OF ALLERGAN PHARMACEUTICALS/IRVINE, CA 92713, U.S.A.

anywhere on potency without fluorination

The potency of Tridesilon—*nonfluorinated* antiinflammatory topical corticoid—has again been confirmed. In a recently published clinical study,[1] desonide 0.05% was compared with fluocinonide (in identical concentration) for various dermatologic disorders including contact dermatitis, nummular eczema, lichen simplex chronicus, seborrheic dermatitis, and atopic eczema.

The desonide group showed better improvement scores in erythema and scaling after the first week; the two-week scores were not significantly different. "...desonide demonstrated potency and efficacy equivalent to those of the fluorinated compound in the disorders treated, and no adverse effects were noted with the former."[1]

This is added corroboration that with topical steroids potency and efficacy do not always depend on fluorination. Desonide, though nonfluorinated, has shown clinical comparability with the most widely prescribed fluorinated topical steroids.[2]

*Not for ophthalmic use.

References: 1. Barsky S: Clinical comparison of desonide cream with fluocinonide cream in steroid-responsive dermatologic disorders. *Cutis* 18:826, 1976. **2.** Reprints available on request.

Contraindications: Tridesilon (desonide) 0.05% Crème and Ointment, topical steroids, are contraindicated in vaccinia and varicella, and in those patients with a history of hypersensitivity to any of the components of the preparation.
Precautions: If irritation develops, the drug should be discontinued and appropriate therapy instituted.
In the presence of an infection, the use of an appropriate antifungal or antibacterial agent should be instituted. If a favorable response does not occur promptly, the corticosteroid should be discontinued until the infection has been adequately controlled.
If extensive areas are treated or if the occlusive technique is used, the possibility exists of increased systemic absorption of the corticosteroid and suitable precautions should be taken.
Although topical steroids have not been reported to have an adverse effect on pregnancy, the safety of their uses in pregnant females has not absolutely been established. Therefore, they should not be used extensively on pregnant patients, in large amounts, or for prolonged periods of time.
These products are not for ophthalmic use.
Adverse Reactions: The following local adverse reactions have been reported with topical corticosteroids: burning sensations, itching, irritation, dryness, folliculitis, hypertrichosis, acneform eruptions, hypopigmentation.
The following may occur more frequently with occlusive dressings than without such therapy: maceration of the skin, secondary infection, skin atrophy, striae, miliaria.
Dosage and Administration: Apply a thin film of Tridesilon (desonide) to the affected skin and massage lightly. The usual dosage is two or three times daily.
Depot Stocked: *DPSC:* 15 gm: NSN 6505-00-148-6969; 60 gm: NSN 6505-00-148-6968; 5 lb: NSN 6505-01-004-9217. *VA:* 60 gm: SN 6505-00-136266A; 5 lb: SN 6505-01-012-4486A.

Tridesilon®
(desonide) 0.05% creme and ointment

adjunctive therapy in acute and chronic steroid-responsive dermatoses


Sites of seborrhea...
Seborrhea illustrated by artist.

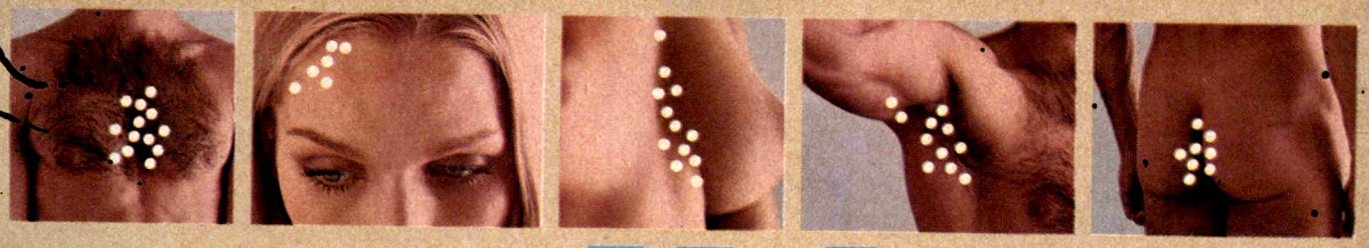

spots for Uticort™ (betamethasone benzoate gel, USP)

a highly effective topical steroid in a special base

UTICORT contains the fluorinated corticosteroid ester — betamethasone benzoate 0.025% — in a specially formulated, clear, self-liquefying gel base to increase steroid activity.

Patients with seborrheic dermatitis treated with UTICORT improved 86% in an average of 11.6 days.

liquefies on application for better surface contact

UTICORT is especially valuable in the treatment of seborrheic dermatitis on hairy areas of the body.

cosmetically acceptable

UTICORT dries to a clear film and can be used confidently on either smooth or hairy skin areas. Moreover, it is greaseless, nonstaining, and nonsticky.

preservative free

Contains no parabens or other potentially sensitizing preservatives.

Brief summary of prescribing information

INDICATIONS. Uticort Gel (betamethasone benzoate gel, USP) is intended for relief of the inflammatory manifestations of corticosteroid-responsive dermatoses.

CONTRAINDICATIONS. Topical steroids are contraindicated in viral diseases of the skin, such as varicella and vaccinia. Topical steroids are contraindicated in patients with a history of sensitivity to any of the components of the preparation.

This preparation is not for ophthalmic use.

PRECAUTIONS. If irritation develops, the gel should be discontinued and appropriate therapy instituted. In the presence of an infection, the use of appropriate antifungal or antibacterial agents should be instituted. If a favorable response does not occur promptly, the corticosteroid should be discontinued until the infection has been adequately controlled.

If extensive areas are treated, or if the occlusive technique is used, the possibility exists of increased systemic absorption of the corticosteroid, and suitable precautions should be taken.

Although topical steroids have not been reported to have an adverse effect on pregnancy, the safety of their use in pregnant females has not absolutely been established. Therefore, they should not be used extensively on pregnant patients, or in large amounts, or for prolonged periods of time.

Due to the alcohol content of the vehicle, Uticort Gel (betamethasone benzoate gel, USP) may cause mild, transient stinging without irritation if used on excoriated skin.

ADVERSE REACTIONS. The following local adverse reactions have been reported with topical corticosteroids: burning sensations, itching, irritation, dryness, folliculitis, secondary infection, skin atrophy, striae, hypertrichosis, acneform eruptions, and hypopigmentation.

DOSAGE AND ADMINISTRATION. Apply to affected areas two to four times daily as needed.

HOW SUPPLIED. N 0071-3025 Uticort Gel is supplied in 15 gram and 60 gram tubes.

Caution: Federal law prohibits dispensing without prescription.

PARKE-DAVIS

UE

PD-JA-2343-1-P (1-78)

PARKE, DAVIS & COMPANY Detroit, MI 48232

Short Report

Chronic Benign Familial Pemphigus

Minimal Involvement Mimicking Chronic Perianal Candidiasis

Jonathan K. Wilkin, MD

Most of the previous reports present chronic benign familial pemphigus (CBFP) in its full clinical expression, or nearly so (a notable exception was reported by Lyles et al).[1]

Report of a Case

A 26-year-old man with a six-year history of "raw skin" in a perianal distribution had been followed up from August 1973 until July 1976 by several physicians, including 17 visits to the Gailor Dermatology Clinic, Memphis. *Candida* sp had been cultured from macerated perianal skin on multiple occasions, and the patient received multiple courses of nystatin-containing topical ointments for moniliasis. The patient was examined for diabetes on several occasions and was always found to have a normal glucose tolerance. The patient reported that the dermatosis was worse during the summer with much pruritus and weeping and that in the winter, although there was never a complete healing, the symptoms were much less.

On examination in July 1976, the perianal dermatosis was found to consist of moist, white, fissured, and excoriated skin. Vesicles had never been seen by the patient or us. Vesicles were not suggested or recorded in accounts of previous examinations.

At this visit, a family history was obtained which disclosed similar, but more extensive, lesions that afflicted the patient's father and paternal uncle. The patient's father had groin, neck, axillary, scalp, intergluteal, and umbilical involvement. His eruption was said to improve during the winter also. At this visit, a 4-mm punch biopsy specimen from the involved perianal area was obtained, which disclosed suprabasal bulla formation and extensive intraepidermal acantholysis (Figure). Some acantholytic cells resembled grains.

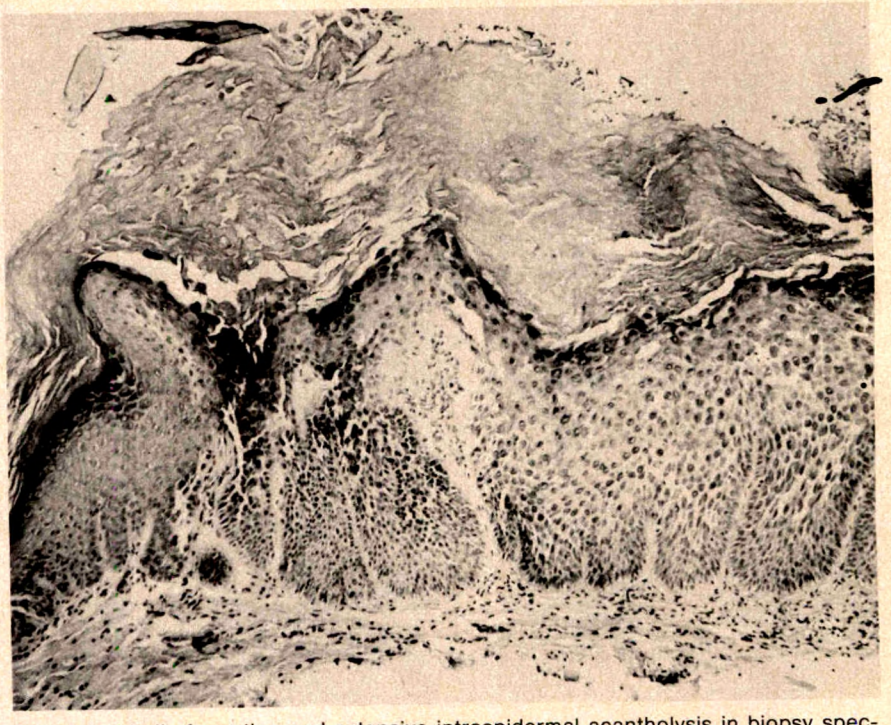

Suprabasal bulla formation and extensive intraepidermal acantholysis in biopsy specimen of perianal skin.

With the diagnosis of CBFP (Hailey and Hailey's disease), the patient was discharged on a regimen of trimeprazine (Temaril) tartrate (2.5 mg four times each day as necessary) and vitamin A which has been gradually increased to 500,000 units/day. There has been a modest objective and an excellent subjective improvement.

Comment

This case indicates the importance of considering minimal involvement of CBFP in the differential diagnosis of chronic resistant intertriginous dermatoses, especially, chronic perianal candidiasis. This case also underscores the utility of the family history and the biopsy specimen in the diagnosis of cutaneous disorders.

George Bale, MD, reviewed the slides of the biopsy specimen.

Reference

1. Lyles TW, Knox JM, Richardson JB: Atypical features in familial benign chronic pemphigus. *Arch Dermatol* 78:446-453, 1958.

From the Department of Dermatology, University of Tennessee Health Sciences Center, Memphis.

Reprint requests to Department of Dermatology, University of Tennessee Health Sciences Center, 66 N Pauline, Memphis, TN 38103 (Dr Wilkin).

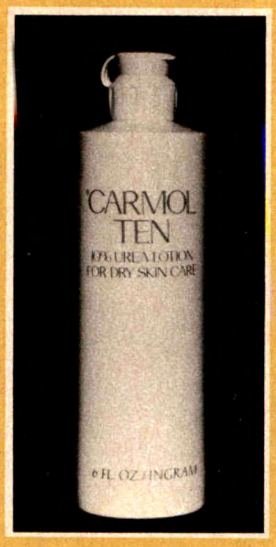

10% Urea Lotion

For simple dry skin: *10% urea* to hydrate dry skin not complicated by hyperkeratosis. Moisturizes and lubricates, relieves the itching of dry skin due to aging, sun or cold weather, soap or detergents. *Lotion base* for total body dry skin care.

vive la différence!

20% Urea Cream

For hyperkeratotic dry skin: *20% urea* to soften and smooth thick, scaly skin in such conditions as ichthyosis, keratosis pilaris, keratosis palmaris et plantaris. *Cream base* for localized application. Especially useful for hands, elbows, knees and heels.

Ingram Pharmaceutical Company,
San Francisco, CA 94111



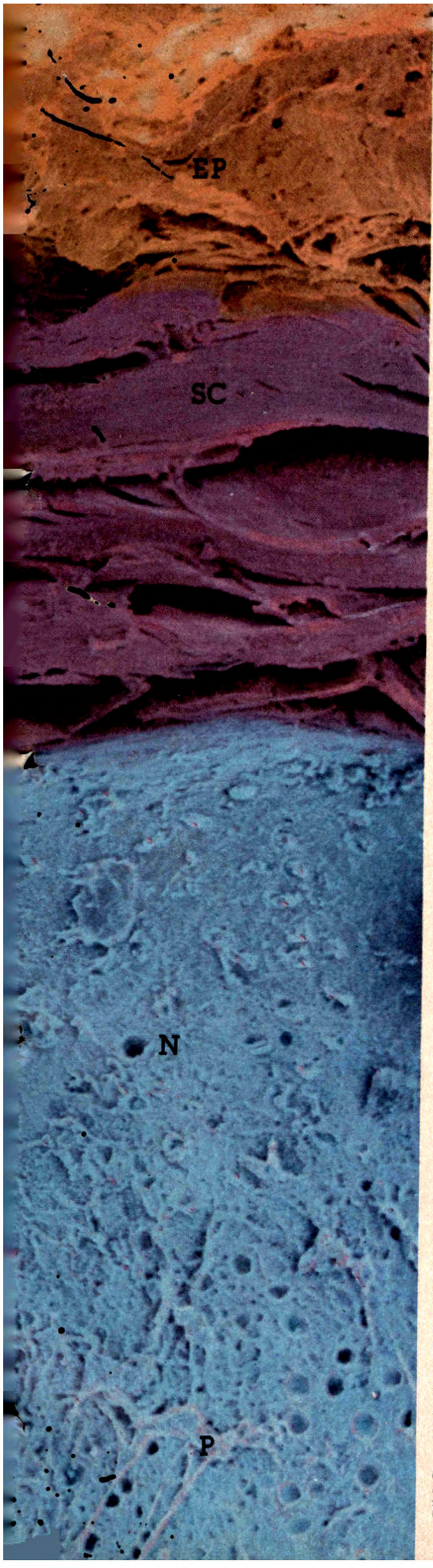

Potency in psoriasis

Potency— A singularly important criterion in selecting a topical steroid for psoriasis, as well as all other acute inflammatory steroid-responsive conditions.

Fluocinonide— A steroid that is 100% dissolved in the Lidex base for optimal lesion penetration. Anti-inflammatory, vasoconstrictive, antipruritic actions, backed by a proven record of performance.

Available in a form that's right for the case at hand—cream, ointment, or Topsyn® (fluocinonide) Gel, 0.05%.

Lidex®
(fluocinonide) 0.05%

See following page for summary of prescribing information.

Cryofractured section of psoriatic epidermis photographed en face. Epidermis (EP) is thickened and stratum corneum (SC) is both thickened and highly disorganized. Dark oval depressions are nuclei (N). Stringy adherent material is exuded serum protein (P).

Color imposed on black-and-white photomicrograph magnified 209X.

SYNTEX
SYNTEX LABORATORIES, INC.
PALO ALTO, CALIFORNIA 94304

LIDEX® (fluocinonide)
Cream and Ointment 0.05%

TOPSYN® (fluocinonide)
Gel 0.05%

Summary of prescribing information

Description
LIDEX cream 0.05%, LIDEX ointment 0.05% and TOPSYN gel 0.05% contain the active compound fluocinonide. Fluocinonide, which is the 21-acetate ester of fluocinolone acetonide, has the chemical formula 6α, 9α-difluoro-11β, 16α, 17α, 21-tetrahydroxypregna-1,4-diene-3, 20-dione, cyclic 16, 17-acetal with acetone 21-acetate. LIDEX cream contains fluocinonide in FAPG® cream, a specially formulated cream base consisting of stearyl alcohol, polyethylene glycol 6000, propylene glycol, 1, 2, 6-hexanetriol and citric acid. This white cream vehicle is greaseless, non-staining, anhydrous and completely water miscible. The base provides emollient and hydrophilic properties. In this formulation, the active ingredient is totally in solution.
LIDEX ointment contains fluocinonide in a specially formulated ointment base consisting of Amerchol CAB (mixture of sterols and higher alcohols), white petrolatum, propylene carbonate and propylene glycol. It provides the occlusive and emollient effects desirable in an ointment. In this formulation the active ingredient is totally in solution.
TOPSYN gel contains fluocinonide in a specially formulated gel base consisting of propylene glycol, propyl gallate, disodium edetate, and Carbopol 940 (carboxypolymethylene) with NaOH and/or HCL added to adjust the pH. This clear, colorless, thixotropic vehicle is greaseless, non-staining and completely water miscible. In this formulation, the active ingredient is totally in solution.

Indications
LIDEX cream and ointment and TOPSYN gel are intended for the relief of inflammatory manifestations of corticosteroid responsive dermatoses.

Contraindications
Topical steroids are contraindicated in vaccinia and varicella. Topical steroids are contraindicated in those patients with a history of hypersensitivity to any of the components of the preparation.

Precautions
If irritation develops, the cream, ointment or gel should be discontinued and appropriate therapy instituted. In the presence of an infection the use of an appropriate antifungal or antibacterial agent should be instituted.
If a favorable response does not occur promptly, the corticosteroid cream, ointment or gel should be discontinued until the infection has been adequately controlled.
If extensive areas are treated, the possibility exists of increased systemic absorption and suitable precautions should be taken.
Although topical steroids have not been reported to have an adverse effect on pregnancy, the safety of their use in pregnant females has not absolutely been established. Therefore, they should not be used extensively on pregnant patients, in large amounts or for prolonged periods of time.
LIDEX® (fluocinonide) cream and ointment and TOPSYN® (fluocinonide) gel are not for ophthalmic use.

Adverse reactions
The following local adverse reactions have been reported with topical corticosteroids:

burning	folliculitis
itching	acneform eruptions
irritation	hypopigmentation
dryness	striae
secondary infection	skin atrophy

Dosage and administration
A small amount should be gently massaged into the affected area three or four times daily, as needed.

How supplied
LIDEX Cream 0.05% – 15 g 30 g and 60 g tubes.
LIDEX Ointment 0.05% – 15 g 30 g and 60 g tubes.
TOPSYN Gel 0.05% 15 g and 60 g tubes.

SYNTEX
SYNTEX LABORATORIES, INC.
PALO ALTO, CALIFORNIA 94304

Books

Readers are advised that in view of The Copyright Revision Act of 1976, *all Letters to the Editor submitted for publication must contain on the transmittal letter the following language: "The person(s) undersigned hereby grant the American Medical Association permission to publish this Letter and in addition, hereby assigns all copyright ownership therein to the AMA."*

Recent Advances in Dermatology, vol 4, edited by Arthur Rook, MD, FRCP, $27.50, 395 pp, with illus, New York, Churchill Livingstone, 1977.

The fourth volume of *Recent Advances in Dermatology* attests anew to Arthur Rook's abilities as an author and as an editor. It is not possible to single out any of the 11 chapters as superior to the others. They are all clearly written and fully documented by data and by bibliographic references. The original publications are evaluated with care and objectivity. The book is uniquely valuable since no other source contains such concise presentations of so much up-to-date knowledge in so many fields important to the dermatologist.

These fields include: "Opportunism and Skin Infections"; "The Sexually Transmitted Diseases"; "Arthropods and the Skin"; "Tropical Skin Diseases in Temperate Climates"; "Sweat Glands and Their Disorders"; "Leg Ulcers"; "Common Baldness and Alopecia Areata"; "Tumours of the Skin" ("ours" despite the fact that the authors of this section are all of the United States); "Topical Therapy"; "Ionizing Radiation in Benign Dermatoses"; and "Drug Reactions."

It is difficult to conceive of a more timely list of subjects and almost impossible to select a more authoritative group of authors. It would be caviling to make any comment except praise about a book that is so well-nigh perfect in accomplishing its stated aims of being "useful and readable." And this reviewer's one negative comment does not apply to the performance of any of the authors or to the contents of any of the chapters. But even at the risk of being considered presumptuous, I feel impelled to voice my opinion on one fact reported in the chapter "Sexually Transmitted Diseases." This fact is the reported recent decision of the Royal College of Physicians and the British Department of Health and Social Security to change the name of the specialty dealing with sexually transmitted diseases from venereology to genitourinary medicine. I submit that the name genitourinary medicine is illogical and likely to confuse. For genitourinary medicine in logic would be obliged to include such diseases as nephroses and nephritis, and such procedures as dialysis by the artificial kidney; and it would exclude, in logic, such conditions as scabies and pediculosis pubis, which are not diseases of the genitourinary tract but of the skin, although frequently transmitted *in venere* and, therefore, properly encompassed by the specialty called venereology. As stated, the preceding comment does not imply an adverse criticism of the superb chapter "Sexually Transmitted Diseases" or of its author. The author simply reports the official decision to adopt the name genitourinary medicine without stating whether he is for or against the change of name. And I take some comfort from the fact that a distinguished authority like Arthur Rook includes the chapter on "Sexually Transmitted Diseases" in this book on advances in dermatology.

Recent Advances in Dermatology, vol 4, is packed with new information and ideas. It is fascinating and stimulating and teaches much about the epidemiology and the basic science aspects of the disorders it covers. One can also learn useful facts about their diagnosis and management.

Not only dermatologists, but all other physicians, biological scientists, and members of the health professions who wish to keep abreast of knowledge in the areas presented, will find this volume rewarding to study, pleasurable to read, and a valuable book of reference.

MARION B. SULZBERGER, MD
San Francisco

IN SKIN INFECTIONS, WHERE CLEANLINESS REQUIRES MORE THAN SOAP

BETADINE® Skin Cleanser

Degerms as it cleanses

Patients can use BETADINE Skin Cleanser to degerm and cleanse face, hands and body, gently and thoroughly—particularly when it is essential to prevent autoinoculation of new sites, as may be the case in infected acne pimples.

BETADINE Skin Cleanser, with its rich, golden lather, provides these advantages:

- Prompt, broad-spectrum microbicidal action—kills both gram-positive and gram-negative bacteria (including antibiotic-resistant strains), fungi, viruses, protozoa and yeasts.
- Maintains microbicidal activity in the presence of blood, pus and serum.
- Virtually nonirritating to skin and mucosa.*
- Nonstaining to skin and natural fabrics.

Supplied: 4 fl. oz. plastic bottles.

*In the rare instance of local irritation or sensitivity, discontinue use by the individual.

Purdue Frederick © COPYRIGHT 1976, THE PURDUE FREDERICK COMPANY

NORWALK, CONN. 06856 A8196 172076

The family for your patients' steroid

Proven clinically effective for prompt relief of mild-to-severe corticosteroid-responsive dermatoses

Valisone® Aerosol 0.15%
For acute contact dermatitis.

Impressive results with Valisone Cream and Ointment in published studies:

contact dermatitis
96% good to excellent results
(81 of 84 patients)*

atopic eczema
92% good to excellent results
(231 of 251 patients)*

psoriasis
85% good to excellent results
(150 of 177 patients)*

Valisone® Cream 0.1%

*Files of Headquarters Medical Research Division, Schering Corporation.

Copyright © 1977, Schering Corporation. All Rights Reserved.

See Clinical Considerations section on opposite page...

# of specialists
responsive problems

Schering



Valisone® Lotion 0.1%
Especially useful in seborrheic dermatitis.

Valisone® Reduced Strength Cream 0.01%
For low-cost maintenance therapy.

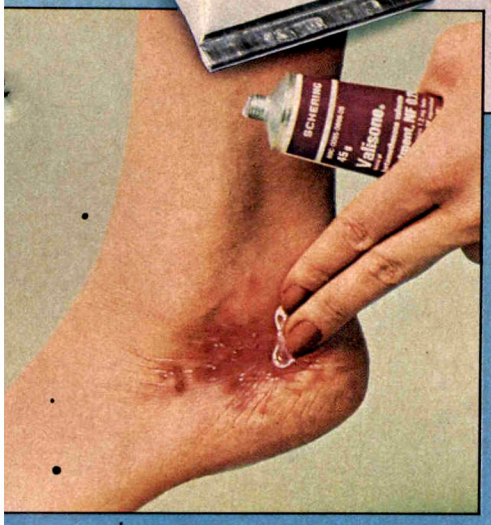

Valisone® Ointment 0.1%
When dryness is a problem.

Clinical Considerations: Indications: VALISONE Cream, Ointment, and Lotion are indicated for relief of the inflammatory manifestations of corticosteroid-responsive dermatoses. VALISONE Reduced Strength Cream is indicated for the relief of the inflammatory manifestations of corticosteroid-responsive dermatoses. VALISONE Aerosol is indicated, solely, for adjunctive topical management for the relief of inflammatory manifestations of acute contact dermatitis. **Contraindications:** Topical steroids are contraindicated in tuberculosis of the skin and some viral diseases of the skin (varicella and vaccinia). Topical steroids are also contraindicated in those patients with a history of hypersensitivity to any of the components of the preparations. VALISONE Aerosol is contraindicated for use under occlusive dressings. **Warnings for VALISONE Aerosol:** Keep the spray away from eyes and other mucous membranes; avoid inhaling. Avoid freezing of the tissue by not spraying for more than 3 seconds, at a distance not less than 6 inches. Contents are under pressure. Do not puncture. Do not store or use near open flame or heat. Exposure to temperatures above 120°F may cause bursting. Keep out of reach of children. Never throw container into fire or incinerator. **Precautions:** If irritation or sensitization develops with the use of VALISONE products, treatment should be discontinued and appropriate therapy instituted. In the presence of infection, the use of an appropriate antifungal or antibacterial should be instituted. If favorable response does not occur promptly, the corticosteroid should be discontinued until the infection has been adequately controlled. If extensive areas are treated, or if the occlusive technique is used, the possibility exists of sufficient systemic absorption to produce adrenal suppression and systemic corticosteroid effects may occur; suitable precautions should be taken. In a few cases, ulceration has been reported with the use of topical steroids for skin conditions involved with impaired circulation (i.e., stasis dermatitis). Prolonged application of corticosteroid-containing products under occlusion may result in striae or atrophy of the skin or subcutaneous tissues. VALISONE products are not for ophthalmic use. **Usage in Women of Childbearing Age:** The use of any drug during pregnancy and the lactation period or in women of childbearing age requires that the potential benefits of the drug be weighed against the possible hazards to the fetus or infant. Topical corticosteroids have not been reported to have an adverse effect on the fetus, but the safety of their use in pregnant patients has not been definitely established. They should not be used extensively or for prolonged periods of time in pregnant patients, unless the condition requiring treatment warrants the risk. **Adverse Reactions:** The following adverse reactions have been reported with topical corticosteroids: burning, itching, irritation, dryness, folliculitis, hypertrichosis, acneiform eruptions, and hypopigmentation. The following may occur more frequently with occlusive dressings than without such therapy: maceration of the skin, secondary infection, atrophy of the skin or subcutaneous tissues, striae, miliaria. **Dosage and Administration:** VALISONE Cream, Ointment, and Reduced Strength Cream are applied as a thin film over the affected skin areas one to three times a day. Clinical studies of VALISONE have indicated that dosage once or twice a day is often feasible and effective. VALISONE Reduced Strength Cream has an aqueous, hydrophilic base that softens and moisturizes the skin. Although occlusive dressings are required infrequently, they may enhance therapeutic efficacy in certain refractory lesions of psoriasis and other dermatoses that are difficult to treat. Apply a few drops of VALISONE Lotion to the affected area of the scalp and massage lightly until it disappears. Apply twice daily, in the morning and at night. Dosage may be increased in stubborn cases; following improvement, apply once daily. Apply VALISONE Aerosol three to four times a day. The container may be held upright or inverted during use. The spray should be directed onto the affected area from a distance of approximately 6 inches and applied for only 3 seconds. Aerosol packaged by Aerosol Techniques, Inc., Armstrong Laboratories Division, West Roxbury, MA. 02132. **For more complete details, consult package insert or Schering literature available from your Schering Representative or Professional Services Department, Schering Corporation, Kenilworth, New Jersey 07033.**

MARCH 1974 (R)

Valisone®
brand of
betamethasone valerate, NF

SLS-914

Immunopathology.—The eighth annual Conference on Immunopathology will be held June 19-23, 1978, at the State University of New York (SUNY) at Buffalo, under the sponsorship of the Departments of Microbiology and Dermatology. The major faculty for the course include Drs Ernst H. Beutner and Russell J. Nisengard and their associates from SUNY at Buffalo, Drs Tadeusz P. Chorzelski and Stefania Jablonska from Warsaw, Poland, Dr Beno Michel from Case Western Reserve University, Dr Thomas Provost from SUNY at Buffalo and Dr Jean-Claude Bystryn from New York University. This course meets the criteria for category I of the American Academy of Dermatology Continuing Medical Education award and of the Physician's Recognition Award of the American Medical Association.

The course this year is for professional personnel interested in immunofluorescence. Tissue antibodies and immunopathology will be studied in sera and in skin and kidney biopsy specimens. The registration fee is $275; for technicians accompanying professional personnel, the registration fee will be $180. For further information write to Mrs Gloria Griffin, 219 Sherman Hall, SUNY/Buffalo, Buffalo, NY 14214.

New Teaching Slides Available.—"Infections of the Skin," the fifth in the series of "A National Library of Dermatologic Teaching Slides," is now available, according to John W. Weiss, MD, clinical professor of medicine and chief of the Section of Dermatology at Loyola University Stritch School of Medicine.

Prepared by the Institute for Dermatologic Communication and Education, the slide collection is available through the American Academy of Dermatology. The set consists of 50 color slides, 35 mm in 2 × 2 mounts. Each mount is numbered and labeled with a diagnosis.

Slides have been selected from the collection of Leonard J. Swinyer, MD, for the American Academy of Dermatology's Committee on Audiovisual Education, by Alfred W. Kopf, MD, Marion B. Sulzberger, MD, Leonard J. Swinyer, MD, John W. Weiss, MD, and Frederick D. Malkinson, MD, chairman of the committee. The collection includes one or more examples of 30 diseases. Each set in the series is priced at $35 (Illinois residents add 5% sales tax, outside the United States and Canada, add $6). Remittance must accompany order. Orders may be sent to Department of Educational Services, American Academy of Dermatology, PO Box 552, Evanston, IL 60204.

Fourth Annual Dermatocryosurgical Seminar.—The Fourth Annual Dermatocryosurgical Seminar, sponsored by the Rudolph Ellender Medical Foundation and cosponsored by the American Society of Contemporary Medicine and Surgery, will be held on March 11 and 12, 1978 at the Fairmont Hotel in New Orleans. The director is Dr Ronald R. Lubritz and the faculty includes Drs Andrew A. Gage, Gloria F. Graham, Douglas R. Torre, and Setrag A. Zacarian. The topics are cryobiology, cryosurgical therapy of benign and malignant lesions, deep malignancies of the head and neck, cryotherapy of acne, and instrumentation. The tuition is $195. This continuing medical education activity meets the criteria for 8 hours of credit in category 1 for the Physician's Recognition Award, and has been approved by the AMA and AAD and endorsed by the American Society for Dermatologic Surgery. For further information contact A. V. Ravagni, business secretary, Roof, Delta Towers, 1732 Canal St, New Orleans, LA 70112, USA.

International Hair Transplant Symposium.—The International Hair Transplant Symposium will be held in Lucerne, Switzerland, Feb 1 to 6, 1978, at the Palace Hotel. Registration fee is $290. An economy travel package is being offered for $685. Multidiscipline faculty will be composed of both Europeans and Americans. For further information contact D. B. Stough III, MD, The Stough Dermatology and Cutaneous Surgery Clinic, PA, Doctors Park, Hot Springs, AR 71901.

European Symposium on Psoriasis.—A European symposium on psoriasis (biology and clinics), organized by Prof Dr C. Scarpa and sponsored by the Italian Society of Dermatology, will be conducted on Friday Oct 20 and Saturday Oct 21, 1978, in Trieste, Italy. The official language will be English. For further information contact Prof Dr C. Scarpa, Clinica Dermatologica dell'Universita, c/o Ospedale Maggiore, Trieste, Italy, 34129.

Pacific Dermatologic Association Essay Contest.—The 30th Annual Meeting of the Pacific Dermatologic Association will be held in San Diego, Sept 17-21, 1978. Each year the Pacific Dermatologic Association encourages young dermatologists to submit essays on original work. The Nelson Paul Anderson Memorial Essay Contest is open to all physicians in graduate dermatologic training or not more than five years from completing such training. Essays may be submitted by doctors residing in the geographical area of the Pacific Dermatologic Association: The Western United States (California, Oregon, Alaska, Nevada, Washington, Idaho, Utah, Arizona, Hawaii, Montana, Wyoming, Colorado, New Mexico), British Columbia and Alberta, Canada, Mexico, Australia, New Zealand, Japan, and the Philippines. The winning essayist will receive a cash prize of $500 and his expenses will be paid to the next annual meeting. Essays will be judged on the following considerations: (1) originality of idea; (2) potential importance of work; (3) evaluation of results; (4) experimental methods and use of control; and (5) clarity of presentation. Six copies of the essay shall be submitted under a nom-de-plume, with no information in the paper that will lead to recognition by the judges of the institution or clinic where the work was done. The essay with nom-de-plume shall be accompanied by a plain sealed envelope enclosing the name and address and nom-de-plume of the author. Entries must be received by the secretary-treasurer, Gerald A. Gellin, MD, 3838 California St, San Francisco, CA 94118, no later than July 15, 1978.

Postgraduate Course.—The American Dermatological Society for Allergy and Immunology announces its 1978 seminar to be at the Denver Airport Hilton Inn, Sept 29 through Oct 1. Title for this postgraduate course is "New Concepts in Treatment and Diagnosis for the Dermatologist in Practice and Training." The keynote speaker will be Dr Robert A. Good, speaking on "Immunodermatology and Cancer Therapy." This post-graduate course is approved for category 1 credit by both the American Medical Association and the American Association for Dermatology. For additional information contact Michael J. Fellner, MD, 30 E 60th St, New York, NY 10017.

Dermatology Foundation Announces Move.—The Dermatology Foundation will relocate its headquarters office from Philadelphia to Evanston, Ill, in January 1978. According to Pres Harry J. Hurley, the foundation will occupy space adjacent to the office of the American Academy of Dermatology, which is now located in Evanston. The board of trustees of the foundation has approved this move, he said, because it is expected that the proximity of the two offices will facilitate communications and coordination of activities between the two organizations. Dr Hurley emphasized that there will be no formal legal or other ties between the two organizations, and that each will maintain its own identity and continue to work toward its stated goals.

Methods of Immunologic Diagnosis.—An "Advanced Institute in Methods of Immunological Diagnosis," conducted under the auspices of the World Health Organization Collaborating Laboratory for the Serology of Autoimmune Diseases at Wayne State University School of Medicine, will be held June 18-24, 1978. The course is to be held on the wooded campus of Cranbrook Educational Community in Bloomfield Hills, Mich. The course will present an up-to-date survey of current immunological methods applicable to the diagnosis of human immunological diseases. Category 1 credit for postgraduate medical education has been approved. Deadline for receiving applications is April 15. Further information may be obtained from Noel R. Rose, MD, PhD, Department of Immunology and Microbiology, Wayne State University School of Medicine, 540 E Canfield, Detroit, MI 48201.

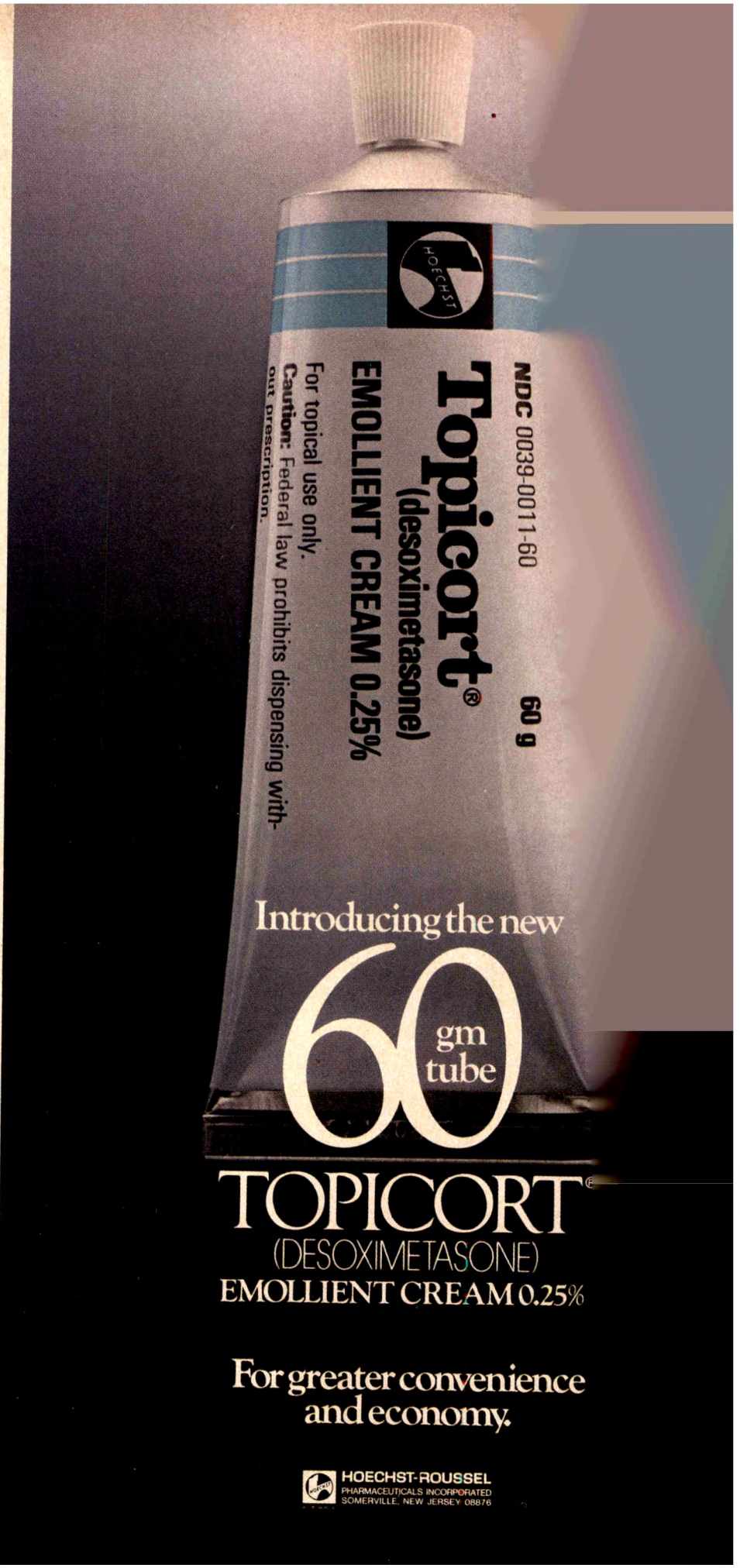

INDEX TO ADVERTISERS

A

Abbott Laboratories 4-5

B

Barnes-Hind Pharmaceuticals 119

C

Cooper Laboratories, Inc. 122

D

Dermik Laboratories 41, 123
Doak Pharmacal Company 35
Dome Laboratories 7, 27, 132-133
Dorsey Laboratories 31-32

E

Ellender, Rudolph, Medical Foundation Inc. 30

G

General Medical Company 14

H

Herbert, G.S., Laboratories, Division of Allergan Pharmaceuticals 15, 131
Hoechst-Roussel Pharmaceuticals 24-26, 145

I

Ingram Pharmaceutical Company 137

L

Lederle Laboratories, Division of American Cyanamid Company 120-121

O

Owen Laboratories, Inc. 3

P

Parke-Davis & Company 10-11, 134-135
Pharmacia Diagnostics 124
Procter & Gamble Company 1, 22, 130A-130F
Professional Office Services 23
Purdue Frederick Company 141

R

Riker Laboratories Inc. 40
Roche Laboratories, Division of Hoffmann-LaRoche, Inc. 20-21
Roerig, J.B., Company Division of Pfizer, Inc. 16-17

S

Schering Corporation 12-14, 142-143
Smith Kline & French Labs. 36-37
Squibb, E.R., & Sons, Inc. 38-40
Stiefel Laboratories, Inc. 33-34
Stuart Pharmaceuticals Div. of ICI Americas Inc. 9
Syntex Laboratories, Inc. ..... 28-30, 138-140, 146-3rd Cover

W

Westwood Pharmaceuticals, Inc. ..... 2nd Cover, 18-19, 42, 4th Cover

While every precaution is taken to insure accuracy, we cannot guarantee against the possibility of an occasional change or omission in the preparation of this index.

SYNALAR®
(fluocinolone acetonide)
CREAM 0.025%
CREAM 0.01%
OINTMENT 0.025%
SOLUTION 0.01%

Description Synalar (fluocinolone acetonide) has the chemical name 6α, 9α-difluoro-16α-hydroxyprednisolone-16, 17-acetonide.

The cream contains fluocinolone acetonide 0.25 mg./g. or 0.1 mg./g. in a water-washable aqueous base of stearic acid, propylene glycol, sorbitan monostearate and monooleate, polysorbate 60, purified water and citric acid with methylparaben and propylparaben as preservatives.

The ointment contains fluocinolone acetonide 0.25 mg./g. in a white petrolatum U.S.P. vehicle.

The solution contains fluocinolone acetonide 0.1 mg./g. in a water-washable base of propylene glycol with citric acid.

Indications For relief of the inflammatory manifestations of corticosteroid-responsive dermatoses.

Contraindications Topical steroids are contraindicated in vaccinia and varicella.

Topical steroids are contraindicated in those patients with a history of hypersensitivity to any of the components of the preparation.

Precautions If irritation develops, the product should be discontinued and appropriate therapy instituted.

In the presence of an infection the use of an appropriate antifungal or antibacterial agent should be instituted. If a favorable response does not occur promptly, the corticosteroid should be discontinued until the infection has been adequately controlled.

If extensive areas are treated or if the occlusive technique is used, the possibility exists of increased systemic absorption of the corticosteroid and suitable precautions should be taken.

Although topical steroids have not been reported to have an adverse effect on pregnancy, the safety of their use in pregnant females has not absolutely been established. Therefore, they should not be used extensively on pregnant patients, in large amounts, or for prolonged periods of time.

Synalar products are not for ophthalmic use.

Adverse reactions The following local adverse reactions have been reported with topical corticosteroids: burning, itching, irritation, dryness, folliculitis, hypertrichosis, acneform eruptions, hypopigmentation.

The following may occur more frequently with occlusive dressings than without such therapy: maceration of the skin, secondary infection, skin atrophy, striae, miliaria.

How Supplied
Synalar (fluocinolone acetonide)
Cream 0.025% — 15 and 60g. tubes and 120 and 425g. jars.
Cream 0.01% — 15, 45 and 60g. tubes and 120 and 425g. jars.
Ointment 0.025% — 15 and 60g. tubes and 425g. jars.
Solution 0.01% — 20cc. and 60cc. plastic squeeze bottles.

Also Available
Synalar-HP® (fluocinolone acetonide)
Cream 0.2% 5g. and 12g. tubes.

SYNTEX
SYNTEX LABORATORIES, INC.
PALO ALTO, CALIFORNIA 94304

AS USEFUL TODAY AS THE DAY IT WAS INTRODUCED

SYNALAR

(FLUOCINOLONE ACETONIDE)

See preceding page for summary of prescribing information.



SYNTEX

When treating tar-responsive dermatoses...

You'll have to tell your patients it's tar.

NEW

estar™

Therapeutic Tar Gel

The odor won't.

For full product information, see PDR.

WESTWOOD
PHARMACEUTICALS INC.
Buffalo, New York 14213

©1976, W.P. Inc.

Published by the American Medical Association

February 1978
Volume 114, Number 2

archives of Dermatology

Are Medical Journals Obsolete? ... A. Soffer 187

Heredity of Chronic Polymorphous Light Eruptions ... C. T. Jansén 188

The Cutaneous Manifestations of Sinus Histiocytosis With Massive Lymphadenopathy ... H. Thawerani, R. L. Sanchez, J. Rosai, R. F. Dorfman 191

Apocrine Gland Adenoma and Adenocarcinoma of the Axilla ... R. L. Warkel, E. B. Helwig 198

Mycetomas Caused by *Streptomyces pelletieri* in Madras, India ... V. V. Taralakshmi, V. V. Pankajalakshmi, R. Kamalakannan, R. Annamalai, B. M. V. Shetty, S. Subramanian, T. K. Shanmugasundaram 204

Selective Immunological Evaluation of Mycosis Fungoides ... P. A. Cooperrider, H. H. Roenigk, Jr 207

Decreased T Cell Levels in Patients With Warts ... J. H. Chretien, J. G. Esswein, V. F. Garagusi 213

Response of Generalized Granuloma Annulare to Alkylating Agents ... S. Kossard, R. K. Winkelmann 216

Ultraviolet Phototherapy and Photochemotherapy of Acne Vulgaris ... O. H. Mills, A. M. Kligman 221

The Glucagonoma Syndrome ... K. H. Swenson, R. B. Amon, J. M. Hanifin 224

Angiolymphoid Hyperplasia With Follicular Mucinosis ... H. H. Wolff, J. Kinney, A. B. Ackerman 229

Woolly Hair Nevus ... S. D. H. Lantis, M. C. Pepper 233

Mutilating Basal Cell Epithelioma ... I. Dvoretzky, B. K. Fisher, O. Haker 239

Stevens-Johnson Syndrome Associated With *Mycoplasma pneumoniae* Infections ... R. D. Sontheimer, R. A. Garibaldi, G. G. Krueger 241

Bullous Pemphigoid and Other Disorders Associated With Autoimmune Phenomena ... J. P. Callen, T. F. Anderson, J. J. Chanda, W. B. Taylor 245

Mycosis Fungoides With Pulmonary Involvement ... R. S. Stein 247

Tinea Faciei ... D. J. Pravda, M. M. Pugliese 250

Erythema Chronicum Migrans in America ... D. N. Naversen, L. W. Gardner 253

Triad of Lichen Planus, Myasthenia Gravis, and Thymoma ... I. K. Aronson, K. Soltani, K-I. Paik, D. Rubenstein, A. L. Lorincz 255

Erythrokeratodermia Variabilis ... G. B. Gewirtzman, N. W. Winkler, R. L. Dobson 259

Pagetoid Reticulosis (Woringer-Kolopp Disease) ... M. Medenica, A. L. Lorincz 262

AMA AMERICAN MEDICAL ASSOCIATION

UNIVERSITY COLLEGE OF MEDICINE LIBRARY

wash it. dry it. peel it.

Fostex,® the flexible therapeutic acne wash that degreases, dries, and peels. Easily integrated with all topical or systemic therapy for acne Grades I, II, and III. Convenient and economical Fostex Liquid and Cream are also effective anti-seborrheic shampoos for oily scalps associated with acne. Available as Fostex Cream in 4½ oz. jars, Fostex Cake in 3¾ oz. bars, and Fostex Liquid in 5 oz. plastic bottles.

Fostril,® the flesh-tinted drying and peeling lotion that conceals as it heals. Adaptable to Grades I, II, or III acne, Fostril is available in 1 oz. plastic tubes.

Transact,® the transparent medicated acne gel. A thin film of Transact will dry the oiliest of skin and is ideal for acne on chest, shoulders, and back. Greaseless, nonstaining, with a fresh clean fragrance. In 1 oz. plastic tubes.

WESTWOOD
PHARMACEUTICALS INC.
Buffalo, New York 14213
In Canada, Belleville, Ontario K8N 1E2

Food Allergy!

"Skin testing with many foods is unreliable and can be dangerous"

Hoffman D R & Haddad Z H:
Diagnosis of IgE mediated reaction to food antigens by radioimmunoassay.
J. Allerg. clin. immunol. 54 (1974) p. 165

Phadebas RAST is a useful adjunct in the diagnosis of IgE mediated food hypersensitivities.

Phadebas RAST®

Pharmacia Diagnostics AB
Uppsala · Sweden

Pharmacia Diagnostics

Argentina Laboratorios Dr. Gador y Cia., S.A.C.I. Casilla de Correo 4041 1006 BUENOS AIRES. **Australia** Pharmacia (South Seas) Pty. Ltd. P.O. Box 175 4 Byfield Street NORTH RYDE N.S.W. 2113. **Austria** Pharmacia Gesellschaft m.b.H. Rathausplatz 4 A-1010 WIEN. **Belgium** N.V. Pharmacia Belga S.A. Bld. Gen. Jacqueslaan 26 B-1050 BRUSSELS. **Brazil** Emprêsa Medimex Importação e Comércio Ltda. Rua Cardoso Marinho, 40 Caixa Postal 33-ZC-00 RIO DE JANEIRO. **Canada** Pharmacia (Canada) Ltd. 2044 boul. St. Régis Blvd. DORVAL, Québec H9P 1H6. **Denmark** Pharmacia AS, Herredsvejen DK-3400 HILLERÖD. **Finland** Pharmacia OY Norrskensvägen 6, SF-02100 ESBO. **France** Pharmacia France S.A. Rue de Marly Parly 2 F-78150 LE CHESNAY. **German Federal Rebublic** Deutsche Pharmacia G.m.b.H. Munzinger Strasse 9 Postfach 5480 D-7800 FREIBURG. **Great Britain** Pharmacia (G.B.) Ltd. Paramount House 75 Uxbridge Road LONDON W5 5SS. **Greece** G.A. Kambanis Imports-Exports-Representations 3 Iridanou Street ATHENS 612. **Italy** Importex Chimici Farmaceutici S.p.A. P.O. Box 467 Via Flavia 122/124 I-34100 TRIESTE. **Mexico** Internacional Cientifica S.A. Apartado Postal 2-807 Angel del Campo 17-A MEXICO 12 D.F. **The Netherlands** Gist-Brocades N.V. Diagnostics Dept. P.O. Box 324 Frijdastraat 7–9 RIJSWIJK (Z H) 2109. **Norway** Norsk Pharmacia A/S Postboks 2005 Grünerløkka OSLO 5. **Portugal** J.A. Baptista D'Almeida Lda. Apartado 1339 LISBOA 1. **Spain** Atom, Paseo del Monte 34 BARCELONA 12. **Sweden** Pharmacia Norden AB Diagnostics Dept. Box 159 751 04 UPPSALA 1. **Switzerland** Pharmacia -pdf- (Schweiz) A.G. 214 Seefeldstrasse CH-8034 ZUERICH. **USA** Pharmacia Diagnostics Division of Pharmacia Inc. 800 Centennial Avenue PISCATAWAY New Jersey 08854. **Other countries** Pharmacia Diagnostics AB Box 17 S-751 03 UPPSALA 1 Sweden.

Archives of DERMATOLOGY

Copyright © 1978 by the AMERICAN MEDICAL ASSOCIATION

VOL 114, NO. 2 FEBRUARY 1978

EDITORIAL

Are Medical Journals Obsolete?
Alfred Soffer, MD, Park Ridge, Ill ... 187

ORIGINAL CONTRIBUTIONS

Heredity of Chronic Polymorphous Light Eruptions
Christer T. Jansén, MD, Turku, Finland ... 188

The Cutaneous Manifestations of Sinus Histiocytosis With Massive Lymphadenopathy
Hasina Thawerani, MD; Ramón L. Sanchez, MD; Juan Rosai, MD; Ronald F. Dorfman, MRCPath, Minneapolis ... 191

Apocrine Gland Adenoma and Adenocarcinoma of the Axilla
Lt Col Raphael L. Warkel, MC, USAR, Elson B. Helwig, MD, Washington, DC ... 198

Mycetomas Caused by *Streptomyces pelletieri* in Madras, India
Venugopal V. Taralakshmi, MD(Path); V. Venugopal Pankajalakshmi, MD(Bact); Rangaraj Kamalakannan, MB, BS; Ruth Annamalai, MD, MD(Dermatol); Brahmayar M. V. Shetty, MD(Path); Sundaram Subramanian, MD, DBact(Lond); Trichirapalli K. Shanmugasundaram, MS, MCh, FRCS, Madras, India ... 204

Selective Immunological Evaluation of Mycosis Fungoides
Peter A. Cooperrider, MD, Henry H. Roenigk, Jr, MD, Cleveland. ... 207

Decreased T Cell Levels in Patients With Warts
Jane H. Chretien, MD; John G. Esswein, MD; Vincent F. Garagusi, MD, Washington, DC ... 213

Response of Generalized Granuloma Annulare to Alkylating Agents
Steven Kossard, MB, PhD, R. K. Winkelmann, MD, PhD, Rochester, Minn ... 216

Ultraviolet Phototherapy and Photochemotherapy of Acne Vulgaris
Otto H. Mills, MA, Albert M. Kligman, MD, PhD, Philadelphia ... 221

CASE REPORTS

The Glucagonoma Syndrome
Keith H. Swenson, MD; Robert B. Amon, MD; Jon M. Hanifin, MD, Portland, Ore ... 224

Angiolymphoid Hyperplasia With Follicular Mucinosis
Helmut H. Wolff, MD, Munich, West Germany; John Kinney, MD, West Palm Beach, Fla; A. Bernard Ackerman, MD, New York ... 229

Woolly Hair Nevus
Sharon D. H. Lantis, MD, Margot C. Pepper, MB, Madison, Wis ... 233

Mutilating Basal Cell Epithelioma
Israel Dvoretzky, MD; Benjamin K. Fisher, MD, FRCP(C), Tel-Hashomer, Israel; O. Haker, MD, Bat Yam, Israel ... 239

Stevens-Johnson Syndrome Associated With *Mycoplasma pneumoniae* Infections
Richard D. Sontheimer, MD; Richard A. Garibaldi, MD; Gerald G. Krueger, MD, Salt Lake City ... 241

Bullous Pemphigoid and Other Disorders Associated With Autoimmune Phenomena
Jeffrey P. Callen, MD; Thomas F. Anderson, MD; Joseph J. Chanda, MD; William B. Taylor, MD, Ann Arbor, Mich ... 245

Mycosis Fungoides With Pulmonary Involvement
Richard S. Stein, MD, Milwaukee ... 247

Tinea Faciei
Douglas J. Pravda, DO, Michael M. Pugliese, MD, Staten Island, NY ... 250

(Continued on page 150)

EDITORIAL BOARD

Chief Editor
John H. Epstein, MD
450 Sutter Street
San Francisco 94108

Assistant Chief Editor
Kimie Fukuyama, MD
San Francisco

Assistant Chief Editor
Denny L. Tuffanelli, MD
San Francisco

Donald C. Abele, MD
Augusta, Ga.

Harry L. Arnold, Jr, MD
Honolulu

Walter C. Lobitz, Jr, MD
Portland, Ore

Frederick D. Malkinson, MD
Chicago

Sigfrid A. Muller, MD
Rochester, Minn

W. Mitchell Sams, Jr, MD
Chapel Hill, NC

John S. Strauss, MD
Iowa City

Morris Waisman, MD
Tampa, Fla

Gerald D. Weinstein, MD
Miami

THREE-IN-ONE THERAPY AGAINST TOPICAL INFECTION

Neosporin® Ointment

(Polymyxin B-Bacitracin-Neomycin)

This potent broad-spectrum antibacterial provides overlapping action to help combat infection caused by common susceptible pathogens (including staph and strep). The petrolatum base is gently occlusive, protective and enhances spreading.

Neomycin

Staphylococcus
Haemophilus
Klebsiella
Aerobacter
Escherichia
Proteus
Corynebacterium
Streptococcus
Pneumococcus

Bacitracin

Staphylococcus
Corynebacterium
Streptococcus
Pneumococcus

Polymyxin B

Pseudomonas
Haemophilus
Klebsiella
Aerobacter
Escherichia

In vitro overlapping antibacterial action of Neosporin® Ointment (polymyxin B-bacitracin-neomycin).

Wellcome

Burroughs Wellcome Co.
Research Triangle Park
North Carolina 27709

Neosporin® Ointment

(Polymyxin B-Bacitracin-Neomycin)

Each gram contains: Aerosporin® brand Polymyxin B Sulfate 5,000 units; zinc bacitracin 400 units; neomycin sulfate 5 mg (equivalent to 3.5 mg neomycin base); special white petrolatum qs; in tubes of 1 oz and 1/2 oz and 1/32 oz (approx.) foil packets.

WARNING: Because of the potential hazard of nephrotoxicity and ototoxicity due to neomycin, care should be exercised when using this product in treating extensive burns, trophic ulceration and other extensive conditions where absorption of neomycin is possible. In burns where more than 20 percent of the body surface is affected, especially if the patient has impaired renal function or is receiving other aminoglycoside antibiotics concurrently, not more than one application a day is recommended.

When using neomycin-containing products to control secondary infection in the chronic dermatoses, it should be borne in mind that the skin is more liable to become sensitized to many substances, including neomycin. The manifestation of sensitization to neomycin is usually a low grade reddening with swelling, dry scaling and itching; it may be manifest simply as failure to heal. During long-term use of neomycin-containing products, periodic examination for such signs is advisable and the patient should be told to discontinue the product if they are observed. These symptoms regress quickly on withdrawing the medication. Neomycin-containing applications should be avoided for that patient thereafter.

PRECAUTIONS: As with other antibacterial preparations, prolonged use may result in overgrowth of nonsusceptible organisms, including fungi. Appropriate measures should be taken if this occurs.

ADVERSE REACTIONS: Neomycin is a not uncommon cutaneous sensitizer. Articles in the current literature indicate an increase in the prevalence of persons allergic to neomycin. Ototoxicity and nephrotoxicity have been reported (see Warning section).

Complete literature available on request from Professional Services Dept. PML.

CONTENTS—Continued

Erythema Chronicum Migrans in America
Maj Douglas N. Naversen, MC, USAF, Larry W. Gardner, MD, San Francisco 253

Triad of Lichen Planus, Myasthenia Gravis, and Thymoma
Iris K. Aronson, MD; Keyoumars Soltani, MD; Kang-Ihnn Paik, MD; Denise Rubenstein, MD; Allan L. Lorincz, MD, Chicago 255

Erythrokeratodermia Variabilis
Garry B. Gewirtzman, MD; Norman W. Winkler, MD, PhD; Richard L. Dobson, MD, Buffalo, NY 259

Pagetoid Reticulosis (Woringer-Kolopp Disease)
Maria Medenica, MD, Allan L. Lorincz, MD, Hines, Ill 262

REGULAR DEPARTMENTS

Short Reports 278

Woronoff's Rings With PUVA Therapy Nicholas J. Lowe, MB, MRCP, Frank Bures, MD, Madison, Wis . . . **Pseudoxanthoma Elasticum With Transepidermal Elimination** Robert Allen Schwartz, MD, MPH, Daniel F. Richfield, MD, Cincinnati . . . **Macroglobulinemia Cutis** Rowan E. Tichenor, MD; Jerold M. Rau, MD; Frank A. Mantz, MD, Kansas City, Kan . . . **Malignant Acanthosis Nigricans** Avigdor Leviatan, MD; Zeev Weshler, MD; Joseph Lowe, MB, ChB; Natalio Walach, MD, Jerusalem . . . **Macular Bowen's Disease** Dennis A. Weigand, MD, Oklahoma City

Letters to the Editor 286

Menthol and Dermatitis Bruce B. Chrisman, MD, Honolulu . . . **Trichilemmoma** A. Bernard Ackerman, MD, New York City . . . **Cutaneous and Urinary Complications of Central Umbilical Artery Injection** Jean-Paul Ortonne, MD; René Jeune, MD; Pierre Souteyrand, MD; Jean Thivolet, MD, Lyon, France . . . **An Unusual Case of Suntanning** Capt Gene P. Ream, MC, USA, Lt Col Richard L. Devillez, MC, USA, Fort Sam Houston, Tex . . . **Glittering With Gold Therapy** Steven R. Kohn, MD, Lawrence J. Denson, MD, New York City . . . **Pseudoxanthoma Elasticum** Michael J. Fellner, MD; Amelia Su-hui Chen; Jonathan B. McCabe, New York . . . **Nike Training Shoe Dermatitis** Jon M. Hanifin, MD, Portland, Ore . . . **Dermatology Patient Visits in the Military** Lt Col Raymond L. Garcia, MC, USAF, Col Charles W. Lewis, MC, USA, San Antonio, Tex . . . **Graft-vs-Host Reaction** Joseph M. Scherzer, MD, Scottsdale, Ariz . . . **Destructive Scalp Alopecia in Psoriasis** Julian Verbov, MD, MRCP, Liverpool, England . . . **IgE Levels in Various Dermatoses** P. Amblard, MD, J. L. Reymond, MD, Grenoble, France . . . **Pseudofolliculitis Capitis** Gary D. Brauner, MD, Fort Lee, NJ, Lt Col Richard B. Odom, MC, USA, San Francisco

News and Notes 302

Books 306

Index to Advertisers 308

Instructions for Authors 158

SUBSCRIPTION RATES: The yearly rate of the ARCHIVES OF DERMATOLOGY is as follows: United States and US Possessions, one year, $18; two years, $28; all other countries, one year, $28; two years, $38. Special yearly price to residents, interns and medical students in the United States and US Possessions, $9.

THE ARCHIVES OF DERMATOLOGY is published monthly by the American Medical Association, 535 N Dearborn St, Chicago, IL 60610, and is an official publication of the Association. Second-class postage paid at Chicago and at additional mailing office.

Selsun®
(SELENIUM SULFIDE LOTION, U.S.P.) ℞

Brief Summary

Contains:
Selenium sulfide, 2½%, w/v; bentonite; lauric diethanolamide; ethylene glycol monostearate; titanium dioxide; amphoteric—2; sodium lauryl sulfate; sodium phosphate (monobasic); glyceryl monoricinoleate; citric acid; captan; perfume; and water.

Indications:
For the treatment of dandruff and seborrheic dermatitis of the scalp.

Contraindications:
Should not be used by patients allergic to any of its components.

Warnings:
Safety for use on infants has not been established.

Precautions:
Cutaneous sensitization of the scalp or adjacent areas has been reported; if sensitivity reactions should occur, discontinue use. Chemical conjunctivitis may result if product enters the eyes. Do not use when acute inflammation or exudation is present as an increase in absorption may occur.

Adverse Reactions:
As with other shampoos, oiliness or dryness of the hair and scalp may occur following use; there have been occasional reports of an increase in the amount of normal hair loss. Hair discoloration may occur; can be avoided or minimized by thorough rinsing.

ABBOTT
7093197

For the benefit of your patients

TRADITIONAL THERAPY

FOR DANDRUFF AND SEBORRHEIC DERMATITIS OF THE SCALP

HAS BEEN IMPROVED

NEW FRAGRANCE
(much milder)

NEW COLOR
(much lighter)

NEW SUDSING
(much better)

SAME EFFICACY AND SAFETY

IMPROVED

Selsun® ℞

SELENIUM SULFIDE, LOTION, U.S.P.

Please see opposite page for Brief Summary.

7093197

Archives of Dermatology

James H. Sammons, MD
Executive Vice-President

Thomas F. Hannon
Group Vice-President, Publishing Operations

William R. Barclay, MD
Group Vice-President, Scientific Publications

Norman D. Richey
Director, Publication Production Division

John T. Baker
Director, Marketing Division

Helen R. Mazur
Acting Fulfillment Manager

John T. Baker, General Sales Manager; **Robert Corcoran,** Eastern Sales Manager; **Fred Bauman, Richard M. Johnson,** Eastern Sales Representatives; **Alice Harvey, William J. Healy,** Midwest Sales Representatives; **Thomas J. Carroll,** West Coast/Northern Sales Representative

PUBLICATION STAFF

Offices: 535 N Dearborn St
Chicago, IL 60610

Robert W. Mayo
Executive Editor and Director, Scientific Publications Division

Sandra Williamson
Administrative Assistant

Marlene M. Hinsch, Production Manager

Editorial Processing Manager: Diana A. Morgan

Copy Editing: Rosanne Schulenberg (Supervisor), Patti Narret, Kathy Swartz

Proofreading: Lorraine L. Kruse (Supervisor), Verna Coffman, Patricia Coyne, Elizabeth Petrikenas, Patricia Poznanski, Mary Kay Tinerella, Dorothy Troy

Production Supervisors: Julia Bero (Layout), Thomas J. Handrigan (Illustrations), Marlene M. Hinsch (Editorial), James P. Bagniewski (Advertising)

Art and Senior Production Assistants: Betty Frigerio, Floriana Hayes, Shirley Latronica, Donna Pender, Nancy Keyes, Marilyn Moroney, Susan Routhier, JoAnne Weiskopf

Production Assistants: Karen Branham, E. Linda Eisenberg, Anna Goins, Lucille Kuznicki, Elaine Starks

Manuscript Records: Denise Henderson

Indexing: Phyllis H. McLaren (Supervisor), Jane P. Mauldin, Helen F. Topel

Please address communications concerning accepted or published communications to: AMA Specialty Journals, 535 N Dearborn St, Chicago, IL 60610.

Conditions for Acceptance of Color Illustrations

Illustrations in full color are accepted for publication in ARCHIVES OF DERMATOLOGY if the editor believes that color will add significantly to the published manuscript.

When color illustrations are accepted, the American Medical Association will pay part of the expense of reproduction and printing, the remainder to be borne by the author or the institution with which he is affiliated. After deducting AMA's contribution, the author's share is $275 for up to six square finished illustrations. Additional illustrations and special effects, such as outlining, opaquing, or surprinting, will be billed to the author at cost.

Color transparencies must be submitted for evaluation. Do not send color prints unless accompanied by original transparencies. If transparencies are mounted in frames or glass, the material should be carefully packed in gauze and sent with the manuscript in a separate container or between two pieces of pressboard.

Advertising and Subscription Information

ADVERTISING OFFICES: 535 N Dearborn St, Chicago, IL 60610, Area Code 312, 751-6000; and 600 Third Ave, New York, NY 10016, Area Code 212-867-6640.

ADVERTISING PRINCIPLES: Each advertisement in this issue has been reviewed and complies with the principles governing advertising in AMA scientific publications. A copy of these principles is available on request.

CHANGE OF ADDRESS: Please notify the publisher at least six weeks in advance, including both old and new address, and a mailing label taken from the most recent copy. Include your new zip code number.

Dome
NOW...
the only stable
nystatin lotion
available.
New
Candex® (nystatin)
Lotion
☐ for a dermatologic need
☐ for control of candidal infections
☐ for cosmetic elegance
New CANDEX Lotion offers excellent penetration around fingernails, into hairy areas and into infected tissue. It soothes inflammation and chafed or macerated skin. And it is paraben-free for the patient with that special sensitivity.
Also Available: CANDEX Creme
(nystatin)
Indications: Candex (nystatin) Lotion and Creme are indicated for the treatment of cutaneous or mucocutaneous mycotic infections caused by Candida species (Monilia). A lotion is preferred on oozing intertriginous areas. Contraindications: Lesions caused by pathogens not susceptible to nystatin, and hypersensitivity to any of the components. Precautions: If irritation or sensitivity occurs and/or infection persists, discontinue use. If new infections appear, appropriate therapy should be instituted. Caution: Federal (USA) law prohibits dispensing without prescription. For external use only. Not for ophthalmic use. Store Candex (nystatin) Lotion below 86 F (30 C); avoid freezing; shake well. Dosage and Administration: Apply two or three times daily. Continue use for one week after clinical cure. How Supplied: Candex (nystatin) Lotion in 30 ml plastic bottles; Candex (nystatin) Creme in 15 g tubes.
Dome Laboratories
MILES
Division Miles Laboratories Inc
West Haven Connecticut 06516 US
© 1977 DOME LABORATORIES, DIVISION MILES LABORATORIES, INC. ALL RIGHTS RESERVED.
DOM-1670

Still the only oral antipruritic with q12h convenience

efore prescribing, see complete prescribing information in SK&F litera-re or *PDR*. The following is a brief summary.

Indications

Based on a review of this drug by the National Academy of Sciences—National Research Council and/or other information, FDA has classified the indications as follows:

Effective: For symptomatic relief of pruritic symptoms in urticaria.

Possibly effective: For relief of pruritic symptoms in neurodermatitis, allergic dermatitis, contact dermatitis, atopic dermatitis, chickenpox, pruritus ani and vulvae.

Final classification of the less-than-effective indications requires further investigation.

ontraindications: Comatose patients; presence of large amounts of C.N.S. epressants; bone marrow depression; idiosyncrasy or hypersensitivity to this ug or other phenothiazines; in newborn or premature children; in nursing others; in acutely ill and/or dehydrated children.

arnings: May impair mental and/or physical ability required for potentially azardous tasks (driving vehicles, operating machinery); may impair mental ertness in children. Concomitant use with alcohol or other C.N.S. depres-ants may have additive effect. Warn patients accordingly.

Use with extreme caution in patients with asthmatic attack, narrow-angle glaucoma, prostatic hypertrophy, stenosing peptic ulcer, pyloroduodenal obstruction, bladder neck obstruction, patients receiving MAO inhibitors.

Do not use in women of childbearing potential. There are reported instances of jaundice and prolonged extrapyramidal symptoms in infants whose mothers received phenothiazines during pregnancy.

Use with caution in children, as administration may result in excitation; overdosage may produce hallucinations, convulsions, sudden death.

Elderly patients (60 or older) are more prone to develop the following phenothiazine side effects: hypotension, syncope, toxic confusional states, extrapyramidal symptoms (especially parkinsonism), excessive sedation.

Precautions: May increase, prolong or intensify sedative action of C.N.S. depressants (when administered concomitantly, narcotic or barbiturate dosage should be reduced to ¼ or ½); lead to restlessness and motor hyperactivity in patient with pain being treated with narcotics; block or reverse the pressor effect of epinephrine. Use cautiously in persons (particularly children) with acute or chronic respiratory impairment, as it may suppress cough reflex; in persons with cardiovascular disease, liver function impairment, or history of ulcer disease. The drug's slight antiemetic action may obscure signs of intestinal obstruction, brain tumor, toxic drug overdose.

Adverse Reactions: (Note: May produce adverse reactions attributable to both phenothiazines and antihistamines, although not all the following have

Controls the itching* promptly
...while you treat the cause

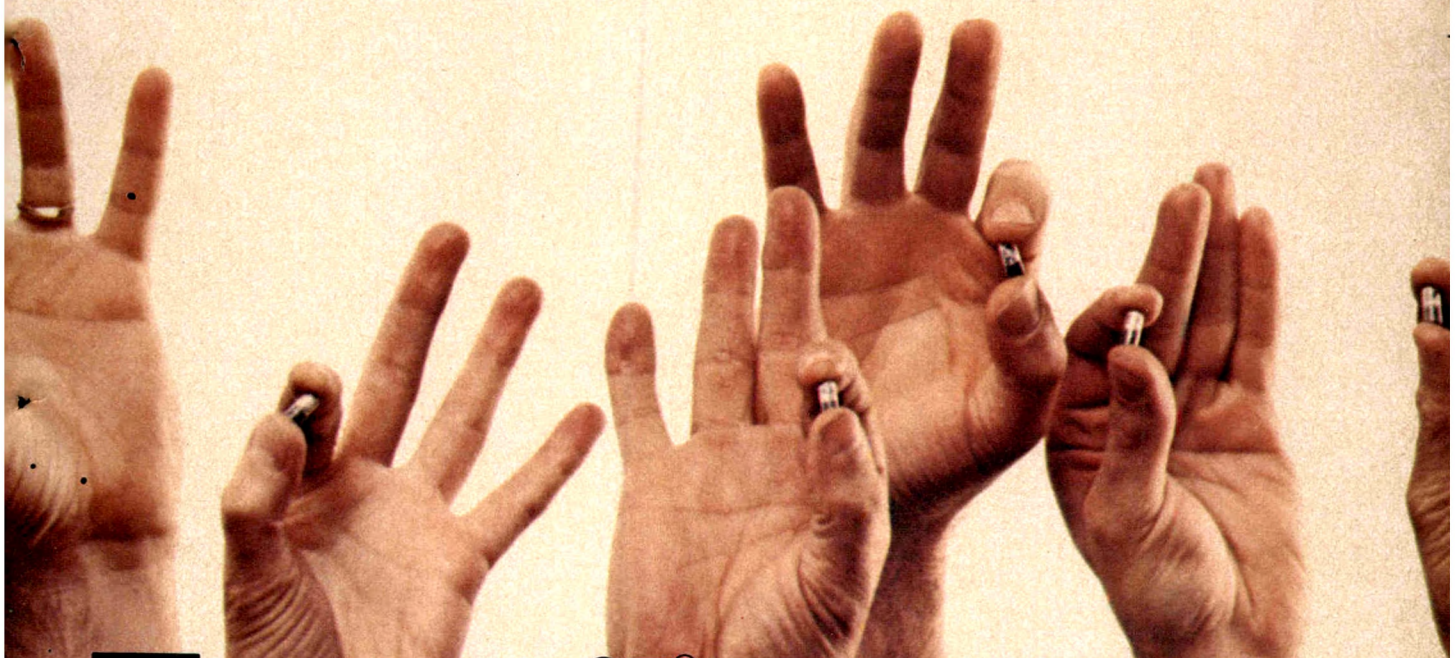

Temaril® Spansule®

Each 'Spansule' capsule contains trimeprazine tartrate equivalent to 5 mg. of trimeprazine.

brand of sustained release capsules

been reported with 'Temaril'. There have been occasional reports of sudden death in patients receiving phenothiazine derivatives chronically.) Drowsiness, extrapyramidal reactions (opisthotonos, dystonia, akathisia, dyskinesia, parkinsonism), particularly with high doses, hyperreflexia in newborn (when used during pregnancy), dizziness, headache, lassitude, tinnitus, incoordination, fatigue, blurred vision, euphoria, diplopia, nervousness, insomnia, tremors and grand mal seizures, excitation, catatonic-like states, neuritis and hysteria, oculogyric crises, disturbing dreams/nightmares, pseudoschizophrenia, intensification and prolongation of action of C.N.S. depressants, atropine, heat, organophosphorus insecticides.

Also postural hypotension, reflex tachycardia, bradycardia, faintness, cardiac arrest, ECG changes, anorexia, nausea, vomiting, epigastric distress, diarrhea, constipation, dry mouth, increased appetite and weight gain, urinary frequency and dysuria, urinary retention, early menses, induced lactation, gynecomastia, decreased libido, inhibition of ejaculation, false positive pregnancy tests, thickening of bronchial secretions, tightness of chest, wheezing, nasal stuffiness; urticaria, dermatitis, asthma, laryngeal edema, angioneurotic edema, photosensitivity, lupus erythematosus-like syndrome, anaphylactoid reactions, leukopenia, agranulocytosis, pancytopenia, hemolytic anemia, elevation of plasma cholesterol levels, thrombocytopenic purpura, jaundice, erythema, peripheral edema, stomatitis, high or prolonged glucose tolerance curves, glycosuria, elevated spinal fluid proteins, reversed epinephrine effects.

After prolonged phenothiazine administration at high dosage, the following have occurred: skin pigmentation, ocular changes (the appearance of lenticular and corneal opacities, epithelial keratopathies, pigmentary retinopathy). Vision may be impaired.

Drug Interactions: MAO inhibitors and thiazide diuretics prolong and intensify anticholinergic effects. Combined use of MAO inhibitors and phenothiazines may result in hypertension and extrapyramidal reactions. Phenothiazines potentiate C.N.S. depressant and analgesic effects of narcotics. Phenothiazine effects may be potentiated by oral contraceptives, progesterone, reserpine, nylidrin HCl.

Supplied: 'Spansule' capsules — in bottles of 50. Syrup — Each 5 ml. teaspoonful contains trimeprazine tartrate equivalent to 2.5 mg. of trimeprazine and alcohol 5.7%, in 4 fl. oz. bottles. Tablets — Each tablet contains trimeprazine tartrate equivalent to 2.5 mg. of trimeprazine, in bottles of 100 and 1000. Tablets and 'Spansule' capsules also available in Single Unit Packages (SUP) of 100, intended for institutional use only.

Smith Kline &French Laboratories
Division of SmithKline Corporation
Philadelphia, Pa.

SK&F
a SmithKline company

Whenever epidermabrasion is needed...

Many skin conditions can benefit from epidermabrasion—the controlled removal of the stratum disjunctum and other keratin excrescences of the stratum corneum. BUF-PUF offers a pleasant, easy-to-use method for patients to achieve thorough cleansing and smoother, healthier skin from head to toe.

Acne
BUF-PUF loosens comedones while it cleans and helps remove excess oil.

Psoriasis
Used wet or dry, BUF-PUF debrides scales from psoriatic lesions without manifesting a Koebner reaction.

Hyperkeratosis
Rapid, often dramatic results can be seen when BUF-PUF is used to remove the upper layers of toughened or scaly skin.

Keratosis pilaris
BUF-PUF is particularly helpful here because its abrasive action concentrates on the elevated areas of the skin surface.

Tinea versicolor
The gently abrasive action of BUF-PUF helps remove the scales, allowing better penetration of topical therapeutic agents.

BUF-PUF®
Nonmedicated Cleansing Sponge

Riker Laboratories, Inc. SUBSIDIARY OF 3M COMPANY
NORTHRIDGE, CALIFORNIA 91324

© 1978, Riker Laboratories, Inc.



"Adolescents especially, may suffer severe loss of self-esteem in our appearance-conscious society as a result of their acne. Some may be more seriously affected emotionally than others and withdraw from normal social interaction."[1]

Help Prevent Both Psychic...And Physical Scarring!

BENZAGEL®

(5% or 10% benzoyl peroxide, 6% polyoxyethylene lauryl ether)

and your counselling are BASIC to Successful Topical Therapy

"Results...Subjective and objective clinical results with this form of therapy were impressive. A rapid improvement could be seen within two weeks...Cysts, pustules and papules decreased in numbers, with a simultaneous reduction of accompanying inflammation. The distinct decline of oily conditions was dramatic."[2]

5 BENZAGEL® ACNE GEL & 10 BENZAGEL® ACNE GEL

Description: 5% or 10% benzoyl peroxide, 6% polyoxyethylene lauryl ether and 40% alcohol in an astringent gel containing colloidal magnesium aluminum silicate, hydroxypropyl methylcellulose, citric acid, fragrance and purified water.

Action: Provides drying, desquamative and antiseptic activity.

Indication: An aid in the treatment of acne.

Dosage and Administration: Wash affected areas prior to application. Apply once or more daily or as directed by physician.

Contraindications: Should not be used by patients having known sensitivity to either benzoyl peroxide or polyoxyethylene lauryl ether.

Precautions: For External Use Only. Not for ophthalmic use. Keep away from eyes and mucosae. Very fair individuals should begin with a single application at bedtime allowing overnight medication. May bleach colored fabrics. Keep this and all other medications out of the reach of children.

Caution: Federal law prohibits dispensing without prescription.

How Supplied: Plastic tubes, 1½ oz. and 3 oz.

REFERENCES:

1. Reisner, R.: The Rational Therapy of Acne, Cutis, Vol. 17, March, 1976, pg. 528.
2. Kuflik, E.: Benzoyl Peroxide Gel in Acne Therapy, Cutis, Vol. 17, January, 1976, pg. 175-177.

Dermik

Dermik Laboratories, Inc.
Fort Washington, Pa. U.S.A. 19034

Instructions for Authors

Send manuscripts by first-class mail to the Chief Editor, John H. Epstein, MD, 450 Sutter St, San Francisco, CA 94108. Manuscripts are received with the understanding that they are not under simultaneous consideration by another publication. Accepted manuscripts become the permanent property of the ARCHIVES and may not be published elsewhere without permission from the publisher (AMA).

In addition, in view of *The Copyright Revision Act of 1976*, effective Jan 1, 1978, transmittal letters to the editor should contain the following language: "In consideration of the American Medical Association taking action in reviewing and editing my submission, the author(s) undersigned hereby transfers, assigns, or otherwise conveys all copyright ownership to the AMA in the event that such work is published by the AMA." We regret that transmittal letters not containing the foregoing language signed by all authors of the submission will necessitate delay in review of the manuscript.

Author Responsibility.—All accepted manuscripts are subject to copy editing. The author will receive an edited typescript rather than galley proofs for approval. The author is responsible for all statements in his work, including changes made by the copy editor.

Designate one author as correspondent and provide his address and telephone number. Order reprints at the time the typescript is returned after editorial processing. Specify address to which requests for reprints should be sent.

Manuscript Preparation.—Submit an original typescript and two high-quality copies of the entire manuscript. All copy (including references, legends, and tables) must be typed double-spaced on 22 × 28-cm (8½ × 11-inch), heavy-duty white bond paper. Ample margins should be provided.

Refer to patients by number (or, in anecdotal reports, by fictitious given names). Real names or initials should not be used in the text, tables, or illustrations.

Titles.—Titles should be short, specific, and clear. They should not exceed 42 characters per line, including punctuation and spaces, and be limited to two lines, if possible. The title page should include the full names and academic affiliations of all authors, the address to which requests for reprints should be sent, and, if the manuscript was presented at a meeting, the name of the organization, place, and date on which it was read.

Style of Writing.—The style of writing should conform to acceptable English usage and syntax. Slang, medical jargon, obscure abbreviations, and abbreviated phrasing are to be avoided.

Informed Consent.—Manuscripts reporting the results of experimental investigations of human subjects must include a statement to the effect that informed consent was obtained after the nature of the procedure(s) had been fully explained.

Abstract.—Provide an abstract (135-word maximum) of the article, including statements of the problem, method of study, results, and conclusions. The abstract replaces the summary.

References.—List references in consecutive numerical order (not alphabetically). Once a reference is cited, all subsequent citations should be to the original number. All references must be cited in the text or tables. Unpublished data and personal communications should not be listed as references. References to journal articles should include (1) author(s), (2) title, (3) journal name (as abbreviated in *Index Medicus*), (4) volume number, (5) inclusive page numbers, and (6) year, in that order. References to books should include (1) author(s), (2) chapter title (if any), (3) editor (if any), (4) title of book, (5) city of publication, (6) publisher, and (7) year. Volume and edition numbers, specific pages, and name of translator should be included when appropriate. The author is responsible for the accuracy and completeness of the references and for their correct text citation.

Metrication.—All measurements must be in metric units. English units may also be given parenthetically if the measurements were originally done in English units.

Illustrations.—Use only those illustrations that clarify and augment the text. Submit illustrations in duplicate, unmounted and untrimmed. Do not send original artwork. Send high-contrast glossy prints (not photocopies). Figure number, name of senior author, and arrow indicating "top" should be typed on a gummed label and affixed to the back of each illustration. All lettering must be legible after reduction to column size. Artwork submitted for publication may be relettered to achieve uniformity of lettering style throughout the journal. Magnification and stain should be provided when pertinent. Illustrations should preferably be in a proportion of 12.5 × 18 cm (5 × 7 inches).

An experienced medical illustrator should be employed whenever possible for the preparation of all artwork. Template lettering or preset type is preferred to hand-lettered labels. If halftone artwork with labels is submitted, affix type and leaders to a clear acetate overlay registered to the base drawing. Labels and leaders should be applied directly to the drawing board surface if the artwork consists only of line ink technique.

Illustrations in full color are accepted for publication if the editors believe that color will add significantly to the published manuscript. The ARCHIVES will pay part of the expense of reproduction and printing color illustrations, the remainder to be borne by the author or his sponsor. After deducting the ARCHIVES contribution, the author's share is $275.00 for up to six square-finished illustrations that can be arranged on a one-page layout. Any additional illustrations or special effects will be billed to the author at cost. Positive color transparencies (35 mm preferred) must be submitted for an evaluation. Do not send color prints unless accompanied by original transparencies. All transparencies should be carefully packed and sent with the manuscript.

Legends.—Legends should be typed double-spaced, beginning on a separate sheet of paper. Length should be limited to a maximum of 40 words.

Photographic Consents.—A letter of consent must accompany all photographs of patients in which a possibility of identification exists. It is not sufficient to cover the eyes to mask identity.

Acknowledgments.—Illustrations from other publications must be acknowledged. Include the following when applicable: author(s), title of article, title of journal or book, volume number, page(s), month, and year. The publisher's permission to reprint should be submitted to the ARCHIVES after the manuscript has been formally accepted.

Statistical Review.—Manuscripts containing statistical evaluations should include the name and affiliation of the statistical reviewer.

Tables.—Each table should be typed double-spaced, including all headings, on a separate sheet of 22 × 28-cm (8½ × 11-inch) paper. Do not use larger size paper. If a table must be continued, use a second sheet and repeat all heads and stubs. Each table must have a title.

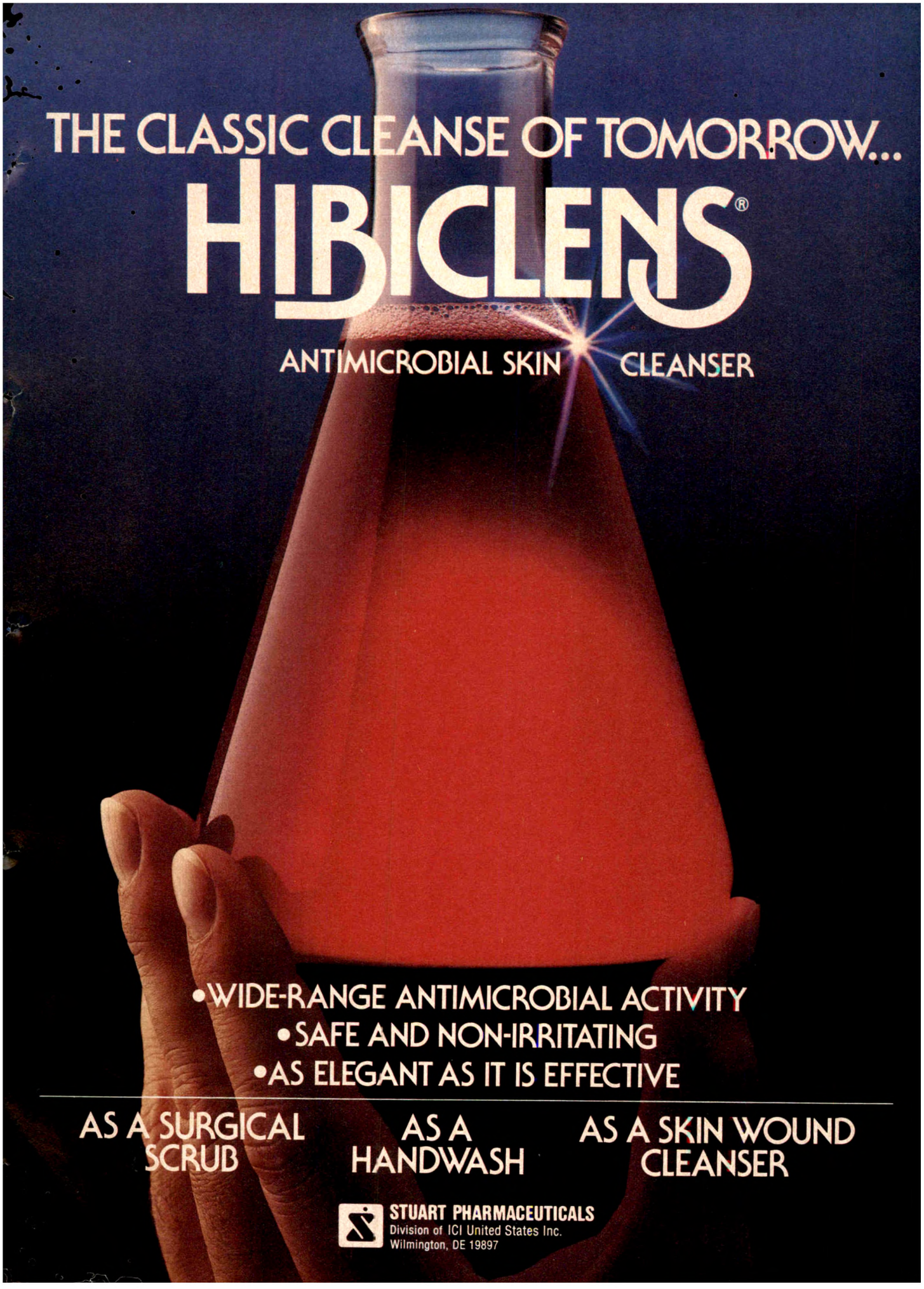
THE CLASSIC CLEANSE OF TOMORROW...
HIBICLENS®
ANTIMICROBIAL SKIN CLEANSER
•WIDE-RANGE ANTIMICROBIAL ACTIVITY
•SAFE AND NON-IRRITATING
•AS ELEGANT AS IT IS EFFECTIVE
AS A SURGICAL SCRUB
AS A HANDWASH
AS A SKIN WOUND CLEANSER
STUART PHARMACEUTICALS
Division of ICI United States Inc.
Wilmington, DE 19897

Psoriasis results without occlusion in only 7 days

Moderate to excellent response in 96% of psoriatic patients.

In two controlled studies, 57 patients with psoriasis were treated with ARISTOCORT A Ointment 0.1% t.i.d. without occlusion for 7 days.*

High degree of patient acceptance.

Patients reported no burning, soreness, drying or itching. ARISTOCORT A Ointment spread easily, rubbed in well, and washed off readily with soap and water.*

*Data on file, Department of Medical Research, Lederle Laboratories.

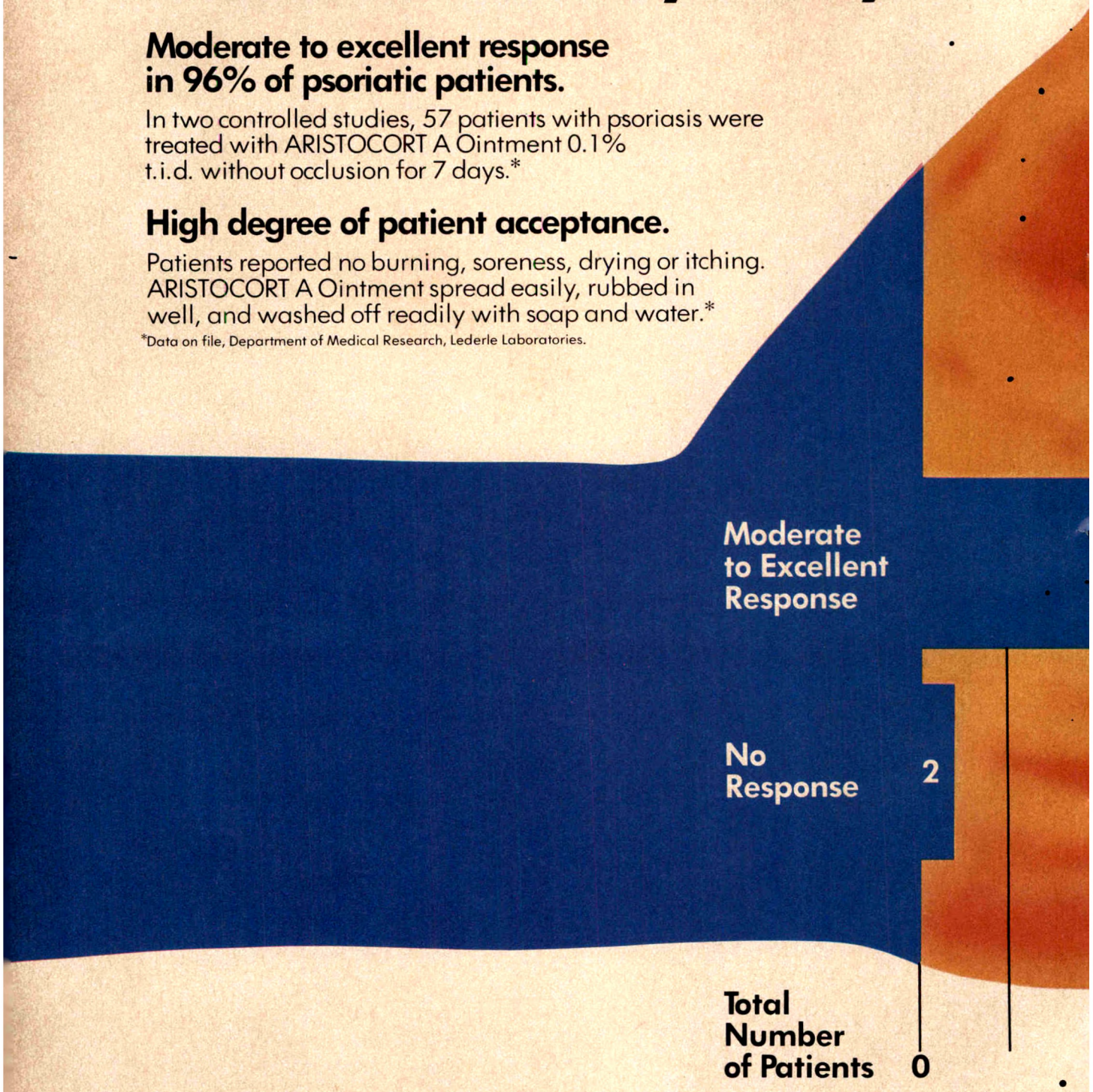

DESCRIPTION: Each gram of ARISTOCORT A Ointment contains 1 mg. (0.1%) of the highly active steroid, Triamcinolone Acetonide (a derivative of triamcinolone) in a specially formulated base composed of emulsifying wax NF, white petrolatum, and propylene glycol. In addition, the 0.1% Ointment contains Tenox II and lactic acid.
INDICATIONS: For relief of inflammatory manifestations of corticosteroid-responsive dermatoses.
CONTRAINDICATIONS: Viral skin diseases, such as varicella and vaccinia; hypersensitivity to any component (not for ophthalmic use); when circulation is markedly impaired.
WARNINGS: Safety of use in pregnancy has not been absolutely established. Do not use extensively, in large amounts, or for prolonged periods of time in pregnant patients.
PRECAUTIONS: If irritation develops, discontinue

Aristocort® A
Triamcinolone Acetonide
Ointment 0.1% with Propylene Glycol

The triamcinolone in ARISTOCORT A 0.1% Ointment is 100% pre-solubilized for faster release. The slow evaporation of the propylene glycol base holds ARISTOCORT A Ointment to the lesion. Paraben-free and lanolin-free.

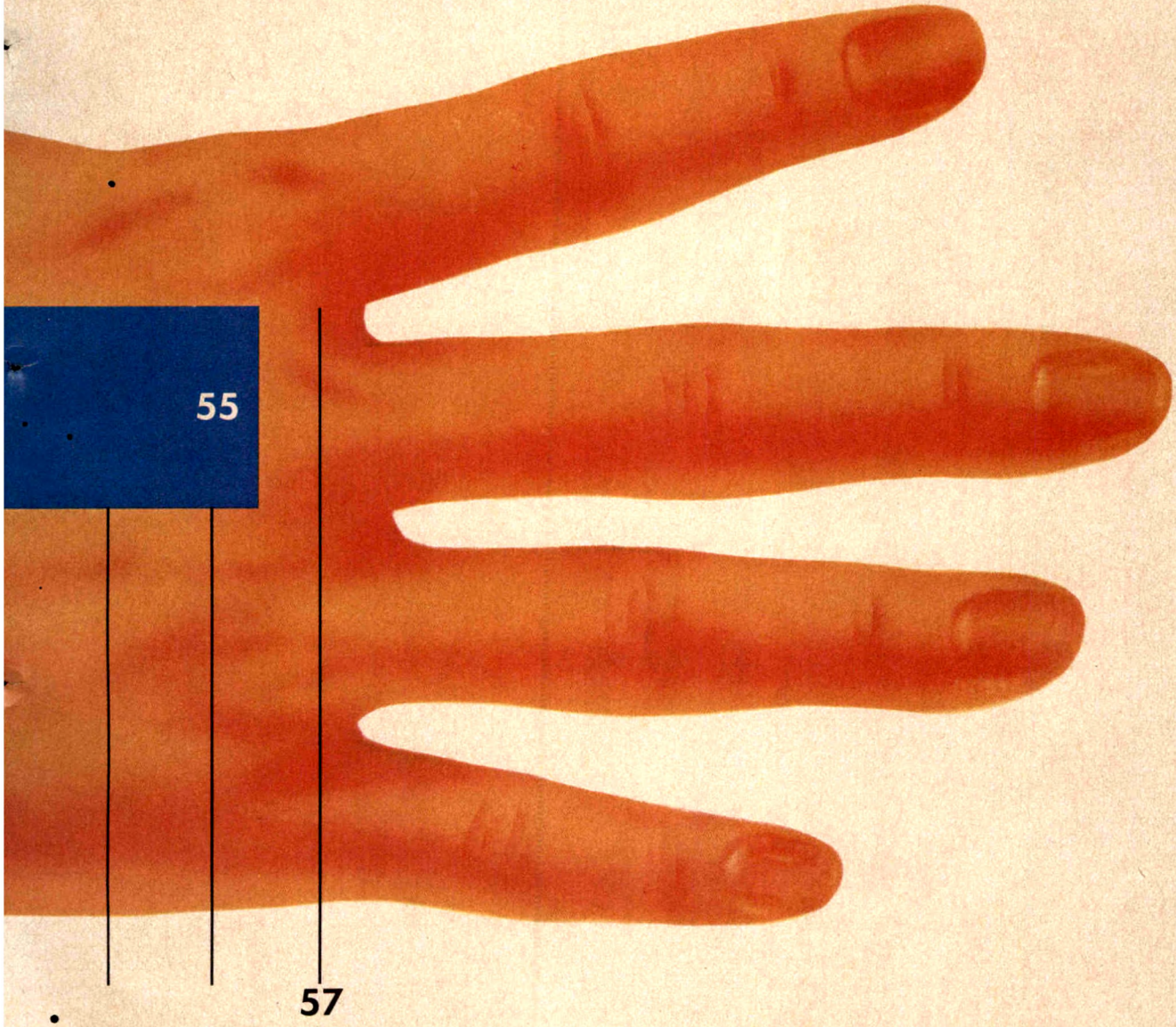

use and institute appropriate therapy. In infections, use appropriate antifungal or antibacterial agents; if a favorable response does not occur promptly, discontinue the corticosteroid until the infection is adequately controlled. If extensive areas are treated or the occlusive technique is used, increased systemic absorption of the corticosteroid may occur; take suitable precautions.

ADVERSE REACTIONS: (local) Burning sensations, itching, irritation, dryness, folliculitis, secondary infection, skin atrophy, striae, hypertrichosis, acne-form eruption and hypopigmentation.

Lederle

LEDERLE LABORATORIES,
A Division of American Cyanamid Company,
Pearl River, New York 10965 059—7R

At the rate lice infestation is growing, every American could have it by 1990.

It has already reached epidemic proportions and must be stopped now.

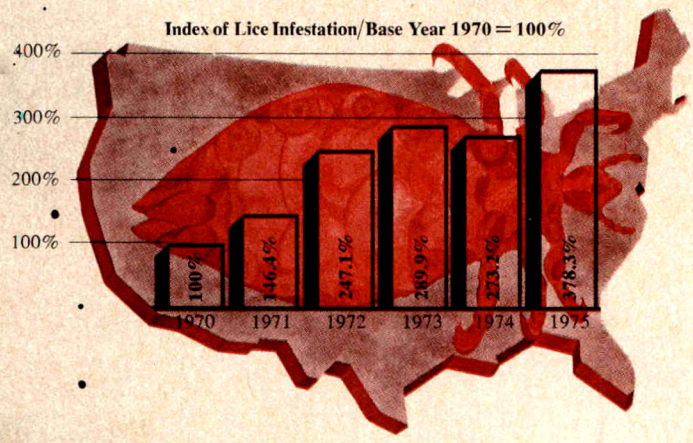

Last year more than 4,000,000 Americans had lice. That's a fourfold increase since 1970. The predictions for this year exceed 5,000,000 cases, and will reach even more staggering levels in the future unless we take the epidemic seriously now.

the status of lice infestation

Unlike lice epidemics of the past, today's problem is no longer due to lack of effective therapy. Nor can it be blamed on overcrowded and unhygienic living conditions. It is more a lack of vigilance and vigorous responsible action.

The facts speak for themselves. Outbreaks are being reported in rural areas of the United States, as well as in crowded big cities. Lice have invaded the wealthy suburbs as well as the inner cities of our nation.

Nondiscriminate in their choice of victims, lice are affecting rich and poor, black and white, individuals and families, the uninformed as well as those who should know better.

What can you do about these alarming trends?

the physician's options

In terms of prevention, isolation of the infested can help. So can instructions on proper hygiene. But not always. For example, pubic lice are usually spread venereally and no physician is going to reverse the sexual revolution.

What then are the options? Public education is one. When a patient is infested, he should be carefully instructed on how to prevent infesting others, and how best to avoid such a problem in the future. When a family is infested, directions should be given on how to delouse the patient and clean the immediate environment of nits, which could reinfest the family and their neighbors for up to a month after treatment of the patient.

In addition to the work being done by medical societies and local public health groups, Reed & Carnrick is contributing its expertise to promote greater professional and public awareness. To this end, we have prepared a comprehensive selection of public health material, patient education brochures and other visual teaching aids. You can request this material from our Professional Relations Department, or from your sales representative.

the standard for treatment

When you see lice in your practice, remember Kwell® (gamma benzene hexachloride). In almost three decades, Kwell has been the subject of the most extensive documentation of any pediculicide. This record shows that Kwell is virtually 100% effective in eradicating lice, mites and their eggs. The record is unsurpassed by any other pediculicide. In fact, since 1949 Kwell has become the standard of therapy.

Furthermore, unlike preparations that must be left on for 24 hours, Kwell is available in a shampoo and in almost all cases can eliminate head or pubic lice in only four minutes. For lice on the less hirsute areas of the body, and for scabies, Kwell is available in cream and lotion form.

A special note: Once lice have gained a foothold in a community, they can quickly become epidemic. Because of this, and because the eradication of lice cannot wait, Reed & Carnrick has developed an early warning system which provides up-to-date information on the status of lice infestation in your community. This helps us to ensure that supplies of Kwell are instantly available and to adjust inventories accordingly.

When you initiate therapy with Kwell, you may be confident that your patient's prescription can be filled immediately.

Contraindications: Kwell is contraindicated in individuals who develop hypersensitivity to the product or to any of its components.

Precautions: If accidental ingestion occurs, prompt institution of gastric lavage will rid the body of large amounts of the toxicant. However, since oils favor absorption, saline cathartics for intestinal evacuation should be given rather than oil laxatives.

Central nervous system manifestations can be antagonized by the administration of pentobarbital or phenobarbital in sufficiently large doses to the limit of their therapeutic effectiveness. It is not desirable to depress the patient to the point of hypnosis. However, persons poisoned with stimulants may tolerate large doses of barbiturate without undue depression and with great benefit. Intravenous calcium gluconate may be used in conjunction with the barbiturates. Epinephrine should not be used because ventricular fibrillation may result.

If accidental contact with eyes occurs, flush with water. If irritation or sensitization occurs, discontinue the product and consult physician.

Adverse Reactions: Eczematous eruptions due to sensitization of this product have been reported.
Available on prescription as Kwell Shampoo and Lotion in 2 and 16 fl. oz. bottles, and as Kwell Cream in 2 oz. and 1 lb. jars. See package insert for complete prescribing information.

Reed & Carnrick/Kenilworth, N.J. 07033

Kwell® Shampoo/Cream/Lotion
gamma benzene hexachloride

For three decades the unsurpassed standard for control of lice.

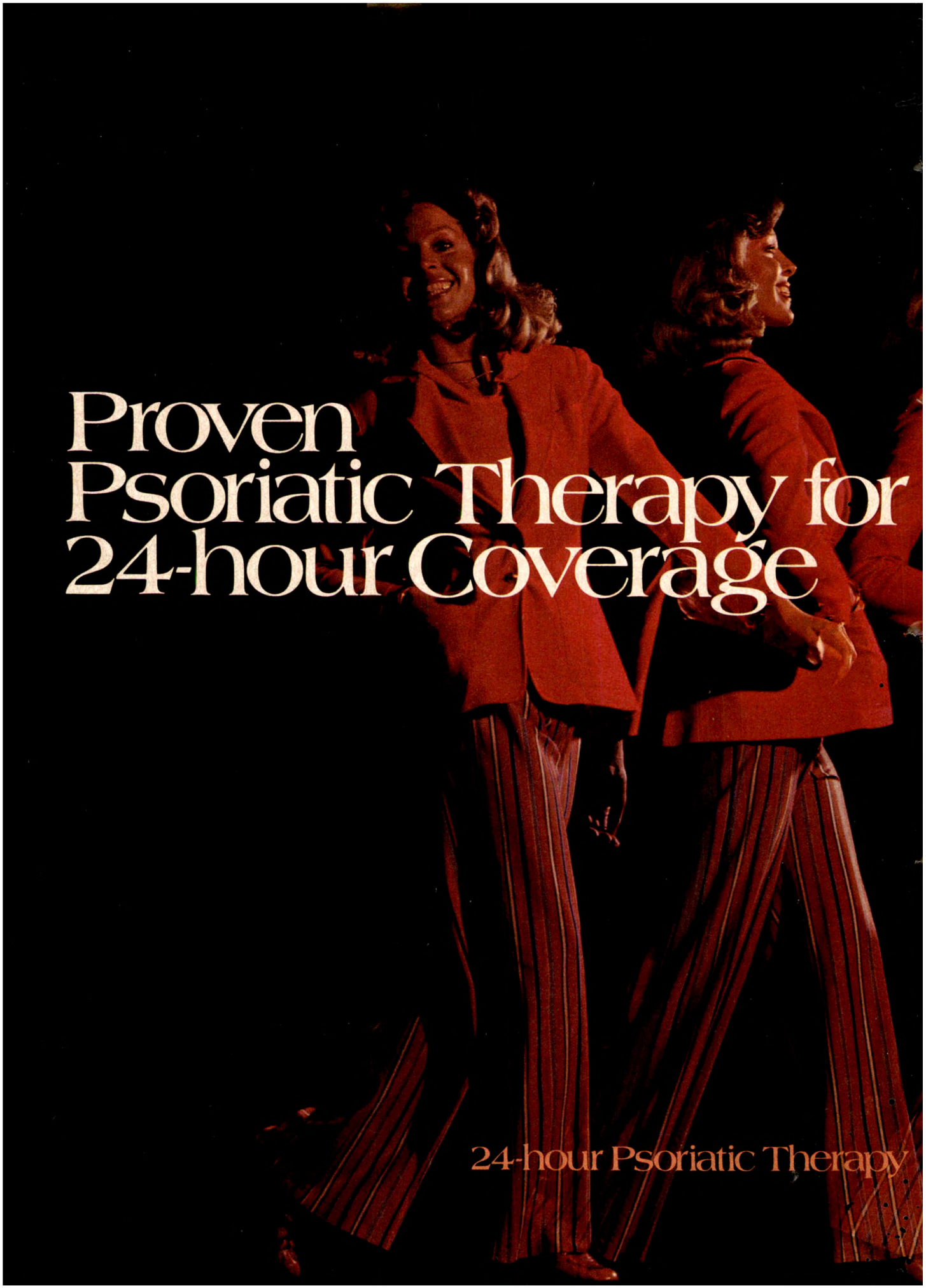
Proven
Psoriatic Therapy for
24-hour Coverage
24-hour Psoriatic Therapy

estar™

Therapeutic Tar Gel

Tar odor won't betray **estar** therapy. Proven **estar** Therapeutic Tar Gel is equivalent to 5% crude coal tar in everything but odor. No sticky, greasy residue to remain on the skin . . . proven therapy to control the formation of psoriatic scales and reduce itching with antipruritic action so that scratching is less likely.

The gel base enables the patient to apply **estar** evenly and smoothly. Tar therapy that doesn't smell like it . . . **estar** Therapeutic Tar Gel.

Balnetar®

Water-dispersible Emollient Tar

Change ordinary water into a psoriatic treatment for patients who bathe before bedtime. **Balnetar** can work through the night to provide keratoplastic, antieczematous, and antipruritic action. It lubricates and moisturizes the skin to relieve and help prevent excessive dryness while it softens and aids in the removal of scales and crusts. One to three capfuls of **Balnetar** added to a tub of warm water can extend the effect of **estar** Therapeutic Tar Gel to twenty-four hour tar therapy. The active ingredient in **Balnetar** treats the skin without staining it or the porcelain of the tub.

Sebutone®

Therapeutic Tar Shampoo

When psoriasis finds its way to the scalp, **Sebutone** can penetrate, soften, and remove scales, crusts, and excess oil with its chemically and biologically standarized tar. Microfine particles of tar remain on the scalp for up to three days (as shown with Wood's light) providing prolonged residual action. The fresh, clean fragrance and excellent cleansing properties of **Sebutone** make no other shampoo necessary when treating scalp psoriasis or any stubborn case of seborrhea or dandruff.

with estar/Balnetar/Sebutone

Please see product information on next page.

©1977, W.P. Inc.

WESTWO
PHARMACEUTICALS
Buffalo, New York 1
In Canada, Belleville, Ontario K

estar™
Therapeutic Tar Gel

Composition: Westwood® Tar (biologically equivalent to 5% Coal Tar USP) in hydro-alcoholic gel (29% alcohol).

Actions and Uses: A therapeutic aid in the treatment of psoriasis and other tar responsive dermatoses such as eczema (atopic dermatitis, lichen simplex chronicus, nummular eczema) and seborrheic dermatitis. **estar** is suitable for use in a modified Goeckerman regimen, either in the hospital or on an outpatient basis; it also can be used in follow-up treatment to help maintain remissions.

Contraindications: estar should not be applied to acutely inflamed skin or used by individuals who are known to be sensitive to coal tar.

Dosage and Administration:

Psoriasis:
The patient should massage **estar** into affected areas, once or twice per day or as directed by physician. Rub in well, allow the gel to remain for five minutes, and then remove excess by patting with tissues.

Chronic atopic dermatitis, Lichen simplex chronicus, Nummular eczema, and Seborrheic dermatitis:

One or two applications per day, as described above, are suggested. If dryness occurs, an emollient may be applied one hour after **estar.**

Caution: AFTER USING, PROTECT TREATED AREAS FROM SUNLIGHT UNLESS DIRECTED BY PHYSICIAN. DO NOT USE ON HIGHLY INFLAMED OR BROKEN SKIN. If used on the scalp, temporary discoloration of blond, bleached, or tinted hair may occur. If undue irritation develops or increases, discontinue use and consult physician. AVOID CONTACT WITH EYES. In case of contact, flush eyes with water.

Slight staining of clothing may occur. Standard laundry procedures will usually remove stains.

For complete prescribing information, see PDR.

SUPPLIED: 3 oz. plastic tube.

Balnetar®
Water-dispersible Emollient Tar

CONTAINS: WESTWOOD® TAR (Equivalent to 2.5% crude coal tar U.S.P.) mineral oil, and lanolin oil

Balnetar is an important adjunct in the management of a wide range of dermatoses, including:

Atopic dermatitis
Psoriasis
Chronic eczematoid dermatitis
Eczematoid dermatitis
Seborrheic dermatitis

Suggested for use in modified Goeckerman regimen.

Directions:
Balnetar should always be used with water—either added to water or rubbed into wet skin.

Bath: Add 1 to 3 capfuls to a tub of warm water. Do not use soap. Soak for 10 to 20 minutes. Pat dry. Frequency depends on nature and severity of condition.

Direct Application: Pat off excess with tissue or old towel to help minimize staining of clothing or linens.

Scalp Application: Mix 2 to 3 capfuls with ¼ cup of water. Rub into scalp with fingertips. Apply once a day, preferably before bedtime. A therapeutic shampoo may be used the following morning.

Contraindication: Not indicated when acute inflammation is present.

CAUTION: If irritation persists, discontinue use and consult physician. In rare instances, temporary discoloration of blond, bleached, or tinted hair may occur. In rare cases, Balnetar may cause allergic irritations attributable to coal tar. Keep out of the reach of children. AVOID CONTACT WITH EYES.

PRECAUTION: After use of Balnetar, avoid exposure to sunlight unless otherwise directed by physician. GUARD AGAINST SLIPPING IN BATHTUB. TO AVOID STAINING, DO NOT USE IN FIBER GLASS BATHTUBS.

SUPPLIED: 8 fl. oz. plastic bottles.

Sebutone®
Therapeutic Tar Shampoo

CONTAINS: WESTWOOD® TAR (equivalent to 0.5% Coal Tar U.S.P.) sulfur 2% and salicylic acid 2% in SEBULYTIC® brand of unique penetrating surface-active combination of soapless cleaners and wetting agents.

CAUTION: If undue skin irritation develops or increases, discontinue use and consult physician. In rare instances, temporary discoloration of blond, bleached, or tinted hair may occur. For external use only. Keep out of the reach of children. AVOID CONTACT WITH EYES. IN CASE OF CONTACT, FLUSH EYES WITH WATER.

SUPPLIED: 4 and 8 oz. bottles and Sebutone Cream in 4 oz. tubes.

WESTWOOD
PHARMACEUTICALS INC
Buffalo, New York 14213
In Canada, Belleville, Ontario K8N 1E2



Let's dispense with unusual amenities.

Cryo-surgery is a highly specialized science and surgical skill. And of course liquid nitrogen storage is especially critical.

Cryenco Biostat® Model 350 LN_2 dispensing dewars are unsurpassed in the field for efficiency, durability and dependability.

Each Model 350 is hand-crafted with long-life stainless steel outer shell construction and a 2-year warranty.

Engineered for consistant service, Model 350 dispenses LN_2 conveniently and efficiently for dermatological use and boasts a working duration of up to 3 months, without a refill.

Engineering, service and design features all add up to a storage facility with truly unusual advantages. Write today for a free catalog or contact your local Cryenco representative.

Cryenco
A HELIX COMPANY

Sales Division / 11055 Leroy Drive
Denver, Colorado 80233 (303) 451-1031

RECENT ADVANCES IN DERMATO-PHARMACOLOGY

Edited by
Phillip Frost, M.D., *Mount Sinai Medical Center of Greater Miami*
Edward C. Gomez, M.D., Ph.D., *New York University School of Medicine*
Nardo Zaias, M.D., *Mount Sinai Medical Center of Greater Miami*

This new book brings into focus both the topical and systemic aspects of dermatopharmacological therapy, assesses current states of knowledge, and provides a guide for the further pursuit of therapeutic progress against skin diseases.

The studies of various drugs and their effects—detailed in the table of contents below—are presented by noted dermatologists, pharmacologists, microbiologists, pathologists, and researchers of infectious diseases. Different drugs are compared and contrasted in terms of topical and systemic therapy, Dozens of photographs, tables and line drawings illustrate the entire book.

CONTENTS: A New Drug Delivery System for Griseofulvin (Michaelis). The Bioavailability and Efficacy of Ultramicrosize Griseofulvin Tablets in Man (Barrett). Topical Treatment of Superficial Mycoses (Zaias). Pharmacodynamics of Silver Sulfadiazine and Related Topical Antimicrobial Agents (Fox Jr.). Transfer Factor for Mucocutaneous Candidiasis (Stevens). An Overview of Corticosteroid-Antibiotic Preparations (Evans). A Cooperative Double Blind Study of an Antibiotic/Corticoid Combination in Impetiginized Atopic Dermatitis (Wachs). The Case for Steroid-Antibiotic Combinations (Kligman and Leyden). Evaluation of New Potent Steroids (Stoughton). Relation of Vehicle to Corticosteroid Potency (Augustine). Adrenal Effects of New Topical Steroids (Gomez, Kaminester and Frost). Topical Nonsteroidal Antiinflammatory Agents (Trancik). Thalidomide for Polymorphous Light-Like Eruptions in American Indians (Londono). Gold Therapy for Pemphigus (Frost). Mycophenolic Acid for Psoriasis (Jones). 8-Methoxypsoralen and Ultraviolet Light for Psoriasis (Parrish). A New Tar Gel—Dermatopharmacology and Clinical Efficacy (Hebborn and Cram). Modulation of Keratinization with α-Hydroxy Acids and Related Compounds (Scott and Yu). The Management of Hyperkeratosis (Baden). Topical Insect Repellents: Volatility Modifications (Maibach and Khan).

1978 **xii + 259pp., illus.** **$20.00**

THE ICHTHYOSES

Edited by
R. Marks
and
P. J. Dykes, *both of the Department of Medicine, Welsh National School of Medicine, Cardiff, Wales*

Seeing a strong need to stimulate interest in ichthyotic disorders, the prestigious European Society for Dermatological Research dedicated its second clinically-oriented symposium to the subject. These proceedings offer insight into the differentiation of the various clinical types of ichthyosis and ichthyosiform diseases; their treatment and genetic analysis; their pathological basis and biochemical characteristics; functional alterations and their possible implications.

CONTENTS: Introduction (Jung). Metabolic Basis for Disturbed Keratinization in Ichthyosis and Other Diseases (Van Scott, Yu). Essential Fatty Acids and Skin Scaliness (Prottey) Epidermal Lipogenesis in Ichthyosis (Cooper, McGibbon, Shuster). Lipid Synthesis in Ichthyotic Conditions (Dykes, Marks). Immunofluorescence Studies in Ichthyosis Vulgaris (Panconesi, Fabbri). Epidermal Growth Characteristics of the Epidermis in the Ichthyotic Disorders (Marks, Dykes). The Protein of the Epidermis in Relationship to Normal and Abnormal Keratinization (Skerrow). The Epidermis in Refsum's Disease (Heredopathia Atactica Polyneuritiformis) (Davies, Reynolds, Marks, Dykes). Ultrastructural Features of Ichthyotic Skin in Refsum's Syndrome (Blanchet-Bardon, Anton-Lamprecht, Puissant, Schnyder). Ultrastructural Criteria for the Distinction of Different Types of Inherited Ichthyosis (Anton-Lamprecht). Preliminary Freeze Fracture Observations in Ichthyosis Vulgaris (Caputo, Innocenti, Gasparini, Peluchetti). Morphological and Quantitative Assessment of Physical Changes in the Horny Layer in Ichthyosis (Nicholls, King, Marks). Less Common Scaling Dermatoses (Frost). Genetic Heterogeneity in the Ichthyoses (Harper). Inherited Ichthyosiform Dermatoses in Infants and Children (Gianotti). Follicular Ichthyosiform Disorder (Waddington, Marks). Two Cases of Unusual Ichthyosis (Howell). The Effect of Urea on the Skin with Special Reference to the Treatment of Ichthyosis (Swanbeck). Pharmaceutical Developments in the Production of Delivery Systems for Treating Ichthyotic Conditions (Ayres). Efficacy of a Skin Cream Containing Pyrrolidone Carboxylic Acid in Reducing the Incidence of Subclinical Dry Skin (Middleton, Roberts). Ichthyosiform Erythroderma: 10 Years Treatment with Retinoic Acid (Milne). Aspects of Long-Term Treatment of Ichthyotic Dermatoses with Vitamin A Acid (Stuttgen, Schalla). Treatment of Disorders of Keratinization with an Oral Stereoisomer of Reinoic Acid (Peck, Yoder).

Spring 1978 **$22.50(Tent.)**

SP MEDICAL & SCIENTIFIC BOOKS
a division of Spectrum Publications, Inc.

175-20 Wexford Terrace, Jamaica, New York 11432

Please send me the titles checked below:

( ) Recent Advances in Dermatopharmacology (022-2)
( ) The Ichthyoses (053-2)

( ) Payment Enclosed ( ) Bill Me

Name _____

Address _____

City/State/Zip _____

Listed prices applicable in the U.S. and Canada only. Publisher will pay postage and handling on all prepaid orders. New York State residents add sales tax.

Superior to the most widely used brand of topical steroid in psoriasis and atopic dermatitis.

Based on the evidence.

In double-blind, parallel studies,* Topicort® (desoximetasone) Emollient Cream 0.25% demonstrated greater efficacy than betamethasone valerate cream 0.1% in the two most common corticosteroid-responsive dermatoses.

		NO. OF PATIENTS	Overall Evaluation: EXCELLENT & GOOD	Overall Evaluation: EXCELLENT (CLEARANCE OF DISEASE)
ATOPIC DERMATITIS	TOPICORT	39	100%	77%
	BETAMETHASONE VALERATE	41	90%	54%
PSORIASIS	TOPICORT	61	84%	43%
	BETAMETHASONE VALERATE	56	63%	21%

These recently conducted U.S. studies confirm the outstanding worldwide acceptance of Topicort in more than 30 countries for up to 4 years.

*Data on file and available upon request from Hoechst-Roussel Pharmaceuticals Inc., Somerville, New Jersey 08876.

Less than 1% incidence of side effects.
Of 488 patients in the clinical trials, side effects were seen in only 4 (0.8%).* And in 2 of the 4 patients, the relationship of side effects to the drug was uncertain.

The convenience of b.i.d. dosage. And the uniqueness of a preservative-free, emollient cream base.
The specially developed, preservative-free Topicort base combines the emollience of an ointment with the cosmetic acceptability of a cream in a water-in-oil emulsion. This makes Topicort (desoximetasone) especially useful in psoriatic and other dry, scaly dermatoses.

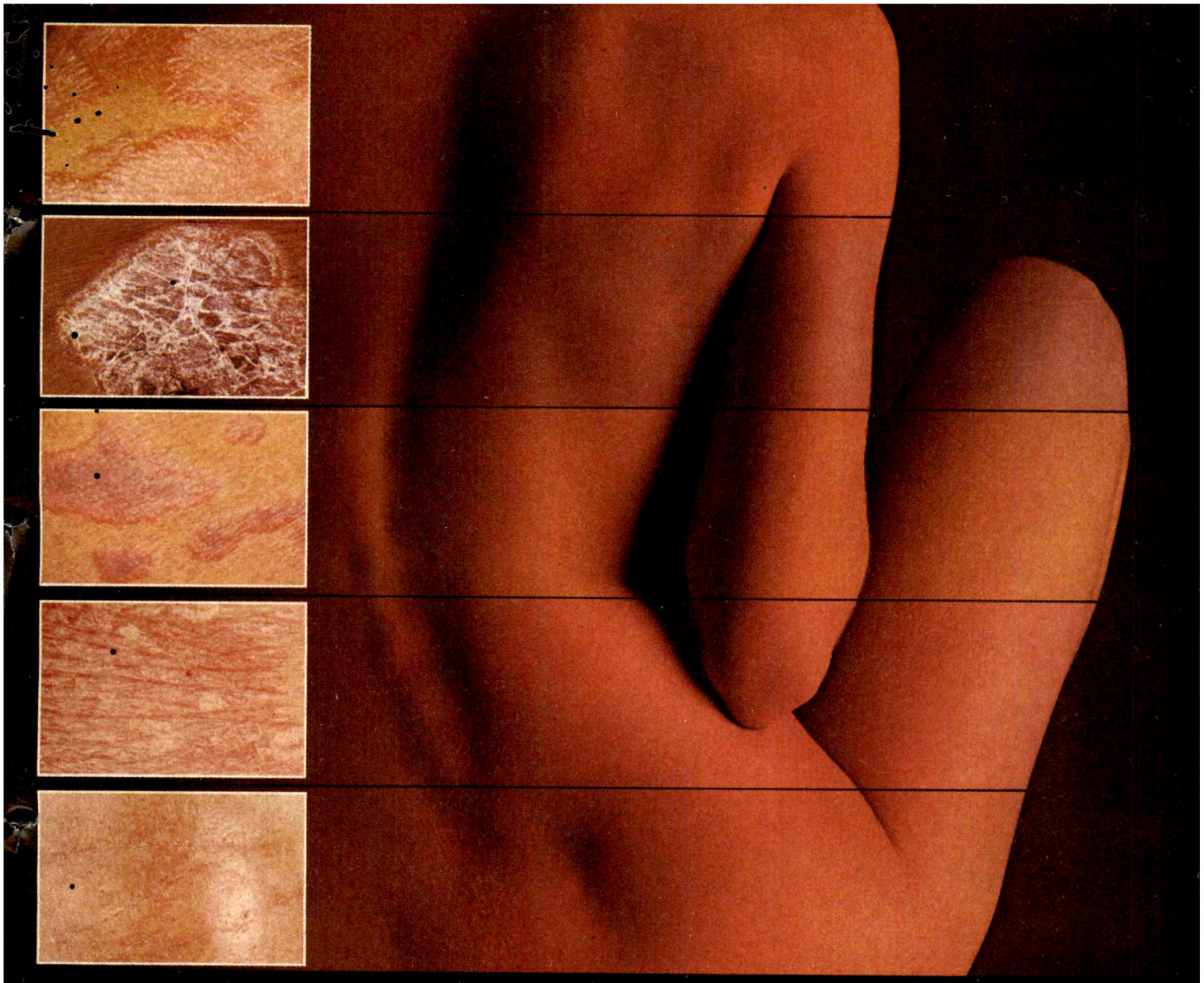

TOPICORT®
(DESOXIMETASONE)
EMOLLIENT CREAM 0.25%

An important innovation from the research laboratories of
Hoechst-Roussel Pharmaceuticals Inc.

Please consult full prescribing information on following page.

EDITION 9/77

TOPICORT® (desoximetasone) EMOLLIENT CREAM 0.25%

Description: Topicort® (desoximetasone) Emollient Cream 0.25% contains the active synthetic corticosteroid desoximetasone. The chemical name of desoximetasone is 9α - fluoro - 11β, 21 - dihydroxy - 16α - methylpregna - 1,4 - diene-3,20-dione. The chemical structure is:

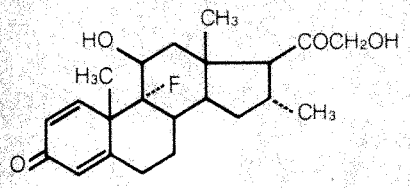

Each gram of Topicort® (desoximetasone) Emollient Cream 0.25% contains 2.5 mg desoximetasone in an emollient cream consisting of isopropyl myristate, cetylstearyl alcohol, white petrolatum, mineral oil, lanolin alcohol and purified water.

Actions: Topicort® (desoximetasone) Emollient Cream is primarily effective because of its anti-inflammatory, antipruritic and vasoconstrictive actions.

Indications: Topicort® (desoximetasone) Emollient Cream is indicated for the relief of inflammatory manifestations of corticosteroid-responsive dermatoses.

Contraindications: Topical steroids are contraindicated in vaccinia, varicella and in those patients with a history of hypersensitivity to any of the components of the preparation. This preparation is not for ophthalmic use.

Precautions: If local infection exists, suitable concomitant antimicrobial or antifungal therapy should be administered. If a favorable response does not occur promptly, application of the corticosteroid should be discontinued until the infection is adequately controlled.

Although systemic side effects associated with absorption of topical corticosteroid preparations are rare, their possible occurrence must be kept in mind when these preparations are used over large areas or for an extended period of time, or if occlusive technique is used.

If irritation or sensitization develops, the preparation should be discontinued and appropriate therapy instituted.

Although topical steroids have not been reported to have an adverse effect on pregnancy, the safety of their use during pregnancy has not been absolutely established; therefore, they should not be used extensively on pregnant patients, in large amounts, or for prolonged periods of time.

Adverse Reactions: The following local adverse reactions have been reported with topical corticosteroids: burning, itching, irritation, striae, skin atrophy, secondary infection, dryness, folliculitis, hypertrichosis, acneform eruptions and hypopigmentation. The following may occur more frequently with occlusive dressings: maceration of the skin, secondary infection, skin atrophy, striae, and miliaria.

Dosage and Administration: Apply a thin film of Topicort® (desoximetasone) Emollient Cream 0.25% to the affected skin areas twice daily. Rub in gently.

How Supplied: Topicort® (desoximetasone) Emollient Cream 0.25% is supplied in 15-gram tubes.

HOECHST-ROUSSEL
PHARMACEUTICALS INCORPORATED
SOMERVILLE, NEW JERSEY 08876

Announcement of
FOURTH ANNUAL
DERMATOCRYOSURGICAL SEMINAR

(To be followed by the First Annual American College of Cryosurgery Program, March 13, 1978)

Sponsored by
RUDOLPH ELLENDER MEDICAL FOUNDATION
Co-sponsored by
American Society of Contemporary Medicine and Surgery
A.M.A. and A.A.D.—Approved

This continuing Medical Education Activity meets with criteria for 8 hours credit in Category 1 for the Physician's Recognition Award

Endorsement—American Society for Dermatologic Surgery
Saturday, March 11, 1978 and
Sunday, March 12, 1978

PLACE: Fairmont Hotel—New Orleans
TOPICS: Cryobiology, Cryosurgical Therapy of Benign and Malignant Lesions, Deep Malignancies of the Head and Neck, Cryotherapy of Acne and Instrumentation
DIRECTOR: Ronald R. Lubritz, M.D., Hattiesburg, Mississippi
FACULTY: Andrew A. Gage, M.D., Buffalo, New York—Gloria F. Graham, M.D., Wilson, North Carolina—Douglas R. Torre, M.D., New York, New York—Setrag A. Zacarian, M.D., Springfield, Massachusetts
CLINICAL DEMONSTRATIONS—Cryosurgical Techniques on patients via closed circuit TV
TUITION: $195.00

For further information contact:
A. V. Ravagni, Business Secretary
Roof, Delta Towers, 1732 Canal Street
New Orleans 70112 USA
Ph: (504) 524-9729

LADIES DAY ACTIVITIES:
Usually tours of the French Quarter and Garden District

The Fairmont Hotel offers course participants a pleasant blend of extracurricular activities; ranging from Bailey's Pub (which never closes), to the Blue Room with name entertainment nightly, to the renowned Sazarac Restaurant, to a new addition featuring swimming pool and tennis courts. For Toll Free Reservations, call 800—527-4727 (in Texas Call 800—492-6622).

Multiple Actinic Keratoses...

cryosurgery?
curettage?
excision?
fulguration?

Or the conservative medical approach?

Fluoroplex.® A medical alternative to surgery. The only topical 5-FU available in low 1% dosage forms...Cream and Solution (both paraben free).

The treatment of choice for facial lesions.

Just as effective as higher dosage forms. Reveals preclinical lesions.[1]

1. Simmonds, W.L. Read before the North American Clinical Dermatologic Society, Athens, Greece, 1975, quoted in Skin and Allergy News 6:3 (Aug) 1975.

Herbert Laboratories
Dermatology Division of
Allergan Pharmaceuticals, Inc.
Irvine, California 92713, U.S.A.

FLUOROPLEX® (fluorouracil) 1% Topical Solution and 1% Topical Cream. **DESCRIPTION:** Fluoroplex® (fluorouracil) 1% Topical Cream is a stable, standardized cream formulation of fluorouracil in an emulsion base with the following formula: fluorouracil...1.0%, with: benzyl alcohol (0.5%), ethoxylated stearyl alcohol, mineral oil, isopropyl myristate, sodium hydroxide, and purified water. Fluoroplex (fluorouracil) 1% Topical Solution is a stable, standardized solution of fluorouracil in a clear propylene glycol base with the following formula: fluorouracil...1.0%, with: propylene glycol, sodium hydroxide-hydrochloric acid to adjust to pH9, and purified water. Fluorouracil is a modified pyrimidine similar to uracil and thymine, with whose metabolism it competes. It is a white crystalline substance with a melting point of 283±2°C., an empirical formula of $C_4H_3FN_2O_2$ and a molecular weight of 130.08. It has a characteristic ultraviolet absorption maximum of 266±1 m in 0.1N HCl. **INDICATIONS:** Fluoroplex (fluorouracil) 1% Topical Solution and Fluoroplex (fluorouracil) 1% Topical Cream are indicated for the topical treatment of multiple actinic (solar) keratoses. **CONTRAINDICATIONS:** Should not be used in patients with known hypersensitivity to any of the components of the drug. **WARNINGS:** 1) If an occlusive dressing is used, there is an increase in the incidence of inflammatory reactions to the adjacent normal skin. 2) The patient should avoid prolonged exposure to sunlight or other forms of ultraviolet irradiation during treatment with Fluoroplex as the intensity of the reaction may be increased. **Use in Pregnancy:** Safety for use in pregnancy has not been established. **PRECAUTIONS:** The medication should be applied with care near the eyes, nose and mouth. Excessive reaction in these areas may occur due to irritation from accumulation of drug. To rule out the presence of a frank neoplasm, a biopsy should be made of those areas failing to respond to treatment or recurring after treatment. **ADVERSE REACTIONS:** Pain, pruritus, burning, irritation, inflammation, dermatitis and telangiectasia have been reported. Occasionally, hyperpigmentation and scarring have also been reported. **DOSAGE AND ADMINISTRATION:** The patient should be instructed to apply sufficient medication to cover the entire face or other affected areas. Apply medication twice daily with non-metallic applicator or fingertips and wash hands afterwards. A treatment period of 2-6 weeks is usually required. Increasing frequency of application and a longer period of administration with Fluoroplex® may be required on areas other than the head and neck. When Fluoroplex is applied to keratotic skin, response occurs with the following sequence: erythema, usually followed by scaling, tenderness, erosion, ulceration, necrosis and re-epithelization. When the inflammatory reaction reaches the stage of erosion, necrosis and ulceration, the use of the drug should be terminated. Responses may sometimes occur in areas which appear clinically normal. These may be sites of subclinical actinic (solar) keratoses which the medication is affecting. **HOW SUPPLIED:** Fluoroplex (fluorouracil) 1% Topical Solution is available in 30 ml plastic dropper bottles. On prescription only. Fluoroplex (fluorouracil) 1% Topical Cream is available in 30 gm tubes. On prescription only. Avoid freezing. Store at controlled room temperature (59°-86°F).

Atopic dermatitis o
hand and wrist
36 year old male

Added versatility in dermatology

new Lidex®-E (fluocinonide) 0.05%

The established potency of fluocinonide, in a soothing emollient base.

Less drying than a cream, with the lubricating qualities of an ointment—cosmetically acceptable to patients.

Especially useful wherever a soothing topical steroid is indicated, as in atopic dermatitis.

Available in 15g and 60g tubes.

SYNTEX

Please see following page for summary of prescribing information

new Lidex® E (fluocinonide) Cream 0.05%

Prescribing Information

Description LIDEX-E cream 0.05% contains the active compound fluocinonide. Fluocinonide, which is the 21-acetate ester of fluocinolone acetonide, has the chemical formula 6α, 9-difluoro-11β, 16α, 17, 21-tetrahydroxypregna-1, 4-diene-3, 20-dione, cyclic 16, 17-acetal with acetone, 21-acetate.

The cream contains fluocinonide 0.5 mg./g. in a water-washable aqueous emollient base of stearyl alcohol, cetyl alcohol, mineral oil, propylene glycol, sorbitan monostearate, polysorbate 60, citric acid and purified water.

Actions Topical steroids are primarily effective because of their anti-inflammatory, antipruritic and vasoconstrictive actions.

Indications For relief of the inflammatory manifestations of corticosteroid-responsive dermatoses.

Contraindications Topical steroids are contraindicated in vaccinia and varicella.

Topical steroids are contraindicated in those patients with a history of hypersensitivity to any of the components of the preparation.

Precautions If irritation develops, the cream should be discontinued and appropriate therapy instituted.

In the presence of an infection, the use of an appropriate antifungal or antibacterial agent should be instituted. If a favorable response does not occur promptly, the corticosteroid cream should be discontinued until the infection has been adequately controlled.

If extensive areas are treated, the possibility exists of increased systemic absorption and suitable precautions should be taken.

Although topical steroids have not been reported to have an adverse effect on pregnancy, the safety of their use in pregnant females has not absolutely been established. Therefore, they should not be used extensively on pregnant patients, in large amounts or for prolonged periods of time.

This product is not for ophthalmic use.

Adverse reactions The following local adverse reactions have been reported with topical corticosteroids: burning sensations, itching, irritation, dryness, secondary infection, folliculitis, acneform eruptions, hypopigmentation, striae, skin atrophy.

Dosage and Administration A small amount should be gently massaged into the affected area three or four times daily, as needed.

How Supplied LIDEX®-E (fluocinonide) cream 0.05% — 15g. and 60g. tubes.

SYNTEX
SYNTEX LABORATORIES, INC.
PALO ALTO, CALIFORNIA 94304

Send us this coupon today and we'll send you a way to slash your claims reporting costs and time

S/J

Return Order Blank To:
American Medical Association
535 North Dearborn
Chicago, Illinois 60610
(312) 751-6000

Type of form		Quantity—in orders of:	Price Including Handling and Postage
☐ Single Form (One page pads of a hundred)	OP-407	1,000 ☐	$ 18.50
		5,000 ☐	78.00
		10,000 ☐	138.00
☐ Two Forms (Original and one carbon)	OP-408	1,000 ☐	28.00
		5,000 ☐	112.00
		10,000 ☐	210.00
☐ Continuous Form (Original and one carbon) (For Computer Printers)	OP-409	1,000 ☐	28.00
		5,000 ☐	112.00
		10,000 ☐	210.00

TOTAL _____

Name _____

Street Address _____

City _____ State _____ Zip _____

Check or money order must accompany this order and be made payable to the American Medical Association.

The Official AMA Uniform Health Insurance Claim Form

Accepted by Medicare, Commercial Carriers, many Blue Shield Plans, and many states for Medicaid.

Developed by the AMA in cooperation with carriers, government agencies, and other groups, this form is the most current and most widely used claim reporting form available. It significantly reduces the time and cost of claims reporting. **Note:** A number of private firms are marketing an outdated, more expensive version of this form. To be certain you are using the most current and acceptable form to third party insurers, we encourage you to use the official AMA form. Order today.

IN SKIN INFECTIONS, WHERE CLEANLINESS REQUIRES MORE THAN SOAP

BETADINE® Skin Cleanser

Degerms as it cleanses

Patients can use BETADINE Skin Cleanser to degerm and cleanse face, hands and body, gently and thoroughly—particularly when it is essential to prevent autoinoculation of new sites, as may be the case in infected acne pimples.

BETADINE Skin Cleanser, with its rich, golden lather, provides these advantages:

- Prompt, broad-spectrum microbicidal action—kills both gram-positive and gram-negative bacteria (including antibiotic-resistant strains), fungi, viruses, protozoa and yeasts.
- Maintains microbicidal activity in the presence of blood, pus and serum.
- Virtually nonirritating to skin and mucosa.*
- Nonstaining to skin and natural fabrics.

Supplied: 4 fl. oz. plastic bottles.

*In the rare instance of local irritation or sensitivity, discontinue use by the individual.

Purdue Frederick © COPYRIGHT 1976, THE PURDUE FREDERICK COMPANY

NORWALK, CONN. 06856 A8196 172076

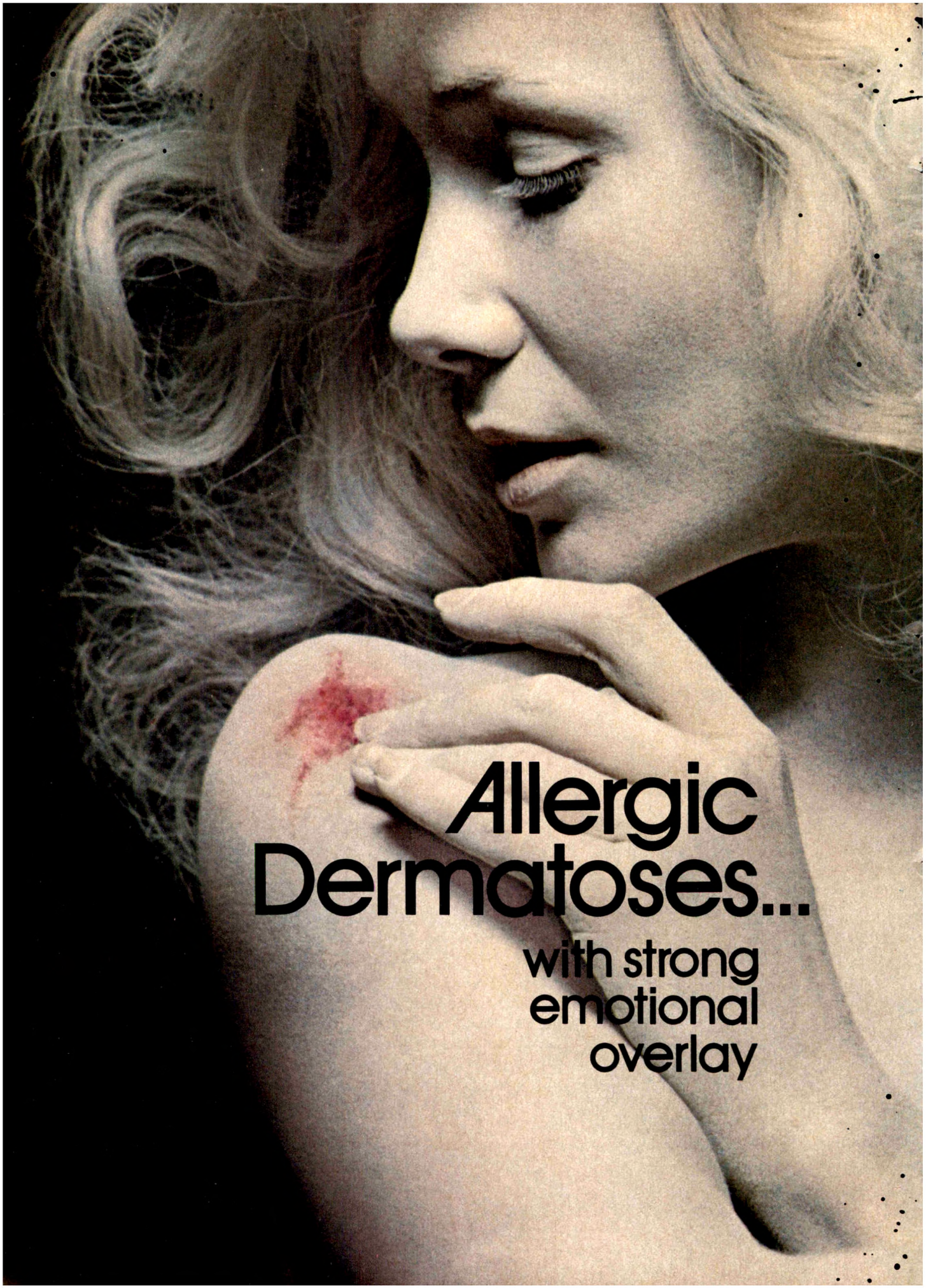
Allergic
Dermatoses...
with strong
emotional
overlay

Contraindications: Hypersensitivity to hydroxyzine. Hydroxyzine, when administered to the pregnant mouse, rat, and rabbit, induced fetal abnormalities in the rat at doses substantially above the human therapeutic range. Clinical data in human beings are inadequate to establish safety in early pregnancy. Until such data are available, hydroxyzine is contraindicated in early pregnancy.

Precautions: Hydroxyzine may potentiate the action of central nervous system depressants such as meperidine and barbiturates. In conjunctive use, dosage for these drugs should be reduced. Because drowsiness may occur, patients should be cautioned against driving a car or operating dangerous machinery.

Adverse Reactions: Drowsiness may occur; if so, it is usually transitory and may disappear in a few days of continued therapy or upon dosage reduction. Dryness of the mouth may occur with higher doses. Involuntary motor activity, including rare instances of tremor and convulsions, has been reported, usually with higher than recommended dosage.

Supply: Tablets, containing 10 mg hydroxyzine hydrochloride, 100's and 500's; Tablets, containing 25 mg or 50 mg, 100's, 500's, and Unit Dose (10 x 10's); Tablets, containing 100 mg, 100's and Unit Dose (10 x 10's); Syrup, containing 10 mg per teaspoonful (5 ml) and ethyl alcohol 0.5% v/v, pint bottles.

Before prescribing or administering, see package circular.

ROERIG Pfizer
A division of Pfizer Pharmaceuticals
New York, New York 10017

as adjunctive therapy

Atarax®
(hydroxyzine HCl)

TABLETS: 10 mg, 25 mg, 50 mg, and 100 mg SYRUP: 10 mg per 5 ml, ethyl alcohol 0.5% v/v

- rapid antianxiety action
- demonstrated antihistaminic/antipruritic activity

The 7 best ways to keep up on what's happening in the practice of medicine...

They're all in American Medical News!

New health care legislation. New federal regulations. New state laws. New delivery systems. Every day there's a lot happening in the world of medicine that could affect the way you practice medicine now and in the future.

What's the best way you have to keep yourself up to date on the latest developments? *American Medical News!* No other publication can match it in providing you with timely, comprehensive coverage of the news in medicine. Here's why:

1 WASHINGTON'S WEEK
Written by a veteran Washington reporter, this weekly column gives you insight into what's happened and what's likely to happen in Congress and the federal regulatory agencies.

2 MEDICINE'S WEEK
Who and what made the news on the national and international medical scene? You'll find all the highlights neatly capsuled in this weekly section.

3 EDITORIALS
Here's where organized medicine speaks out, expressing its views on the issues of concern to the profession, on the practice of medicine, and on the health care of the American people.

4 MY OPINION ARTICLES
In this weekly department, medical leaders and other health care experts share with you their own frank and independent views on topical subjects.

5 FEATURE ARTICLES
Each week, you'll find articles featuring in-depth reporting on subjects of vital interest to you, such as health care legislation before Congress, federal medical and drug regulations, and court actions.

6 IMPACT
This monthly section puts the news of medicine into focus through a thoughtful, in-depth examination of the social forces affecting medicine. In their provocative articles, a wide range of health care authorities seek to explain what is happening in the doctor's world, what forces are shaping your life and practice, and what is likely to come.

7 LETTER PAGE
Here's where you and your colleagues can step up and express your likes and dislikes on what's happening in medicine.

Give *American Medical News* just 30 minutes a week; it will give you all the news you need to know about what's happening in the practice of medicine.

American Medical
NEWS

Keeping your finger on the pulse of medicine

Cleansing & Moisturizing

New Keri Facial Cleanser is formulated to slow moisture loss from the skin, emulsify oil, and remove dirt and debris as it leaves skin softer and smoother.

Cleansing without drying is a Keri tradition.

Patients who routinely use Alpha Keri® Bath Oil and Alpha Keri® Soap should welcome this new addition to the fine line of Keri skin care products.

New Keri® Facial Cleanser

In 4 oz. plastic bottles. Promoted to physicians only.

WESTWOOD
PHARMACEUTICALS INC.
Buffalo, New York 14213

© 1977 W.P. Inc.

Vectrin® Capsules

(minocycline hydrochloride capsules, USP)

50 and 100 mg

effective adjunctive treatment in severe acne

Before Treatment | **After Treatment**

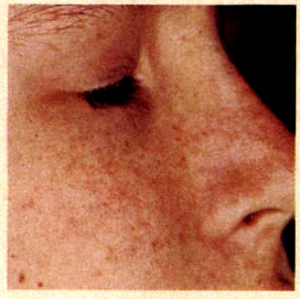

84 DAYS
Vectrin, 50 mg, twice daily

91 DAYS
Vectrin, 50 mg, twice daily

40 DAYS
Vectrin, 100 mg, once daily

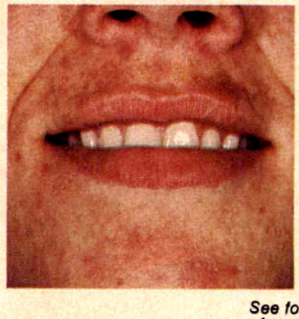

84 DAYS
Vectrin, 100 mg, once daily

PARKE-DAVIS

See following page for brief summary of prescribing information.

VECTRIN Capsules, 50 and 100 mg
(minocycline HCl capsules, USP)
Brief Summary of Prescribing Information

Indicated in severe acne as adjunctive therapy. Consult package insert for complete prescribing information.

Contraindication: Hypersensitivity to any tetracycline.

Warnings: When need for intensive treatment outweighs potential dangers, perform renal and liver function tests before and during therapy; also follow serum concentrations. In renal impairment, usual doses may lead to excessive accumulation and liver toxicity. Under such conditions, use lower total doses, and, in prolonged therapy, determine serum levels. The use of tetracyclines during tooth development (last half of pregnancy, infancy, and childhood to the age of 8 years) may cause permanent discoloration of the teeth (yellow-gray-brown). This is more common during long-term use but has been observed following repeated short-term courses. Enamel hypoplasia has also been reported. Tetracyclines, therefore, should not be used in this age group unless other drugs are not likely to be effective or are contraindicated. Photosensitivity manifested by an exaggerated sunburn reaction has been observed in some individuals taking tetracyclines. Advise patients apt to be exposed to direct sunlight or ultraviolet light that such reaction can occur, and discontinue treatment at first evidence of skin erythema. Studies with minocycline HCl indicated that photosensitivity did not occur. However, reports have been received. In patients with significantly impaired renal function, the antianabolic action of tetracycline may cause an increase in BUN leading to azotemia, hyperphosphatemia, and acidosis. **CNS side effects:** (light-headedness, dizziness, vertigo) have been reported, may disappear during therapy, and always disappear rapidly when drug is discontinued. Caution patients who experience these symptoms about driving vehicles or using hazardous machinery while taking this drug. **Pregnancy:** In animal studies, tetracyclines cross the placenta, are found in fetal tissues, and can have toxic effects on the developing fetus (often related to retardation of skeletal development). Embryotoxicity has been noted in animals treated early in pregnancy. The safety of minocycline HCl for use during pregnancy has not been established. **Newborns, infants, and children:** All tetracyclines form a stable calcium complex in any bone-forming tissue. Prematures, given oral doses of 25 mg/kg every six hours, demonstrated a decrease in fibula growth rate, reversible when drug was discontinued. Tetracyclines are present in the milk of lactating women who are taking a drug in this class.

Precautions: Use may result in overgrowth of nonsusceptible organisms, including fungi. If superinfection occurs, antibiotics should be discontinued and appropriate therapy instituted. In venereal diseases when coexistent syphilis is suspected, darkfield examination should be done before treatment is started and blood serology repeated monthly for at least four months. Patients on anticoagulant therapy may require downward adjustment of such dosage. Test for organ system dysfunction (eg, renal, hepatic, and hemopoietic) in long-term use. Treat all group A beta-hemolytic streptococcal infections for at least 10 days. Avoid giving tetracycline in conjunction with penicillin.

Adverse Reactions: GI: Anorexia, nausea, vomiting, diarrhea, glossitis, dysphagia, enterocolitis, inflammatory lesions (with monilial overgrowth) in anogenital region. **Skin:** Maculopapular and erythematous rashes. Exfoliative dermatitis (uncommon). Photosensitivity is discussed above. (See Warnings.) **Renal toxicity:** Rise in BUN, dose-related. (See Warnings.) **Hypersensitivity reactions:** Urticaria, angioneurotic edema, anaphylaxis, anaphylactoid purpura, pericarditis, exacerbation of systemic lupus erythematosus. In young infants, bulging fontanels have been reported following full therapeutic dosage, disappearing rapidly when drug was discontinued. **Blood:** Hemolytic anemia, thrombocytopenia, neutropenia, eosinophilia. **CNS:** (See Warnings.) When given over prolonged periods, tetracyclines may produce brown-black microscopic discoloration of thyroid glands; no abnormalities of thyroid function studies are known to occur.

NOTE: Concomitant therapy: Antacids containing aluminum, calcium, or magnesium impair absorption; do not give to patients taking oral tetracycline. Studies to date indicate that absorption of VECTRIN (minocycline hydrochloride) is not notably influenced by foods and dairy products.

Full prescribing information available upon request.

PARKE, DAVIS & COMPANY
Detroit, MI 48232

PD-JA-2378-1-P (2-78)

COOK COUNTY GRADUATE
SCHOOL OF MEDICINE

ANNOUNCES

ESSENTIALS OF DERMATOLOGY
May 1-5, 1978

SPECIALTY REVIEW COURSE IN DERMATOLOGY

September 25-29, 1978

For more detailed information and registration forms, address:

REGISTRAR
707 South Wood Street
Chicago, Illinois 60612

Telephone: 312-733-2800

in depth studies of the health care systems of Britain and France...



how they operate and what they mean to users and to people who work in them.

These highly readable, comprehensive studies, prepared by a London research firm and published by the American Medical Association, offer an opportunity to examine other system's organization, problems, and achievements.

You'll learn how and why the present systems evolved...how they are financed...the range and quality of services available...the training and distribution of medical personnel ...and what effects each system has had upon the health of the general population.

Everyone in the medical profession should read both of these fascinating studies on how other nations have organized the delivery of health care.

Both books will be available Fall of 1976. To order your copies, write ORDER DEPT., AMA, 535 N. DEARBORN ST., CHICAGO, ILL. 60610. **The French Health Care System** (OP-460) costs $3.50; the **British Health Care System** (OP-461), $7.50. The set is $10. Remittance must accompany order.

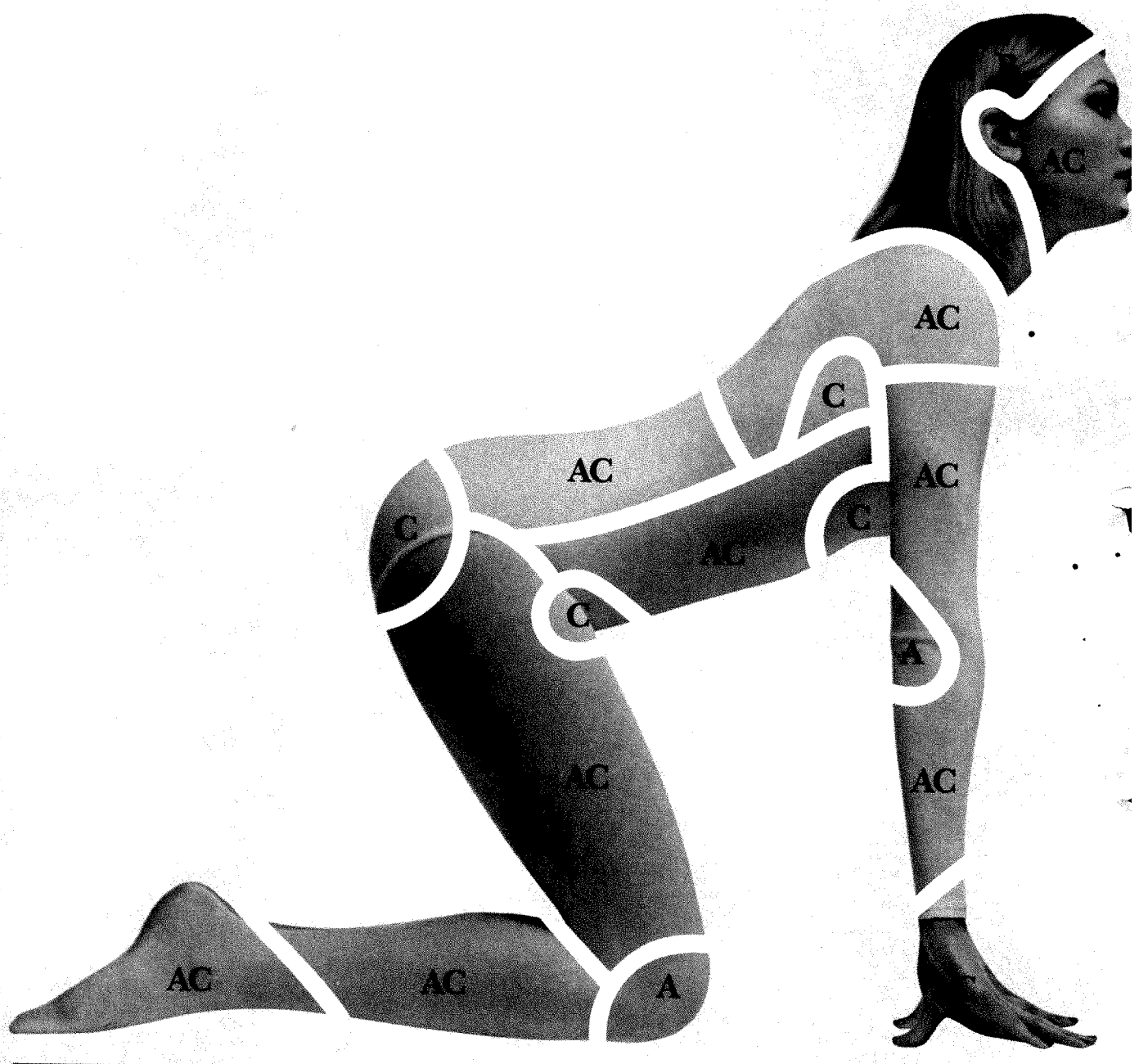

FOR THE

ZONES OF DERMATOSES

For dry areas/lesions

A New Halog® Ointment 0.1%

Halcinonide Ointment 0.1%

For scalp lesions

B New Halog® Solution 0.1%

Halcinonide Solution 0.1%

For moist areas/lesions

Full-strength

C Halog® Cream 0.1%

Halcinonide Cream 0.1%

'Maintenance formula'

Quarter-strength

New Halog® Cream 0.025%

Halcinonide Cream 0.025%

Clinical experience

A total of 984 psoriatic patients in US clinical studies were treated with either the Solution, the Creams, or the Ointment. After 2 weeks' therapy,* 151 (78%) of 194 patients improved with Halog Solution, 407 (92.5%) of 440 patients improved with full-strength (0.1%) Halog Cream, 132 (72%) of 184 patients improved with quarter-strength (0.025%) Halog Cream, and 145 (87%) of 166 patients improved with Halog Ointment.

In general, the preferred topical formulations for lesions in specific areas are: solutions for scalp lesions, creams for moist areas/lesions, and ointments for dry areas/lesions. The studies cited above, however, were not limited to lesions in these specific areas.

*Majority of patients evaluated after 2 weeks' therapy. Data on file at Squibb Institute for Medical Research.

See next page for brief summary.

©1977 E.R. Squibb & Sons, Inc. 357-508

HALOG®

HALCINONIDE

SQUIBB®

HALOG® (Halcinonide)
Cream/Ointment/Solution
Halog Cream 0.025% (Halcinonide Cream 0.025%) and Halog Cream 0.1% (Halcinonide Cream 0.1%) contain 0.25 mg. and 1 mg. halcinonide per gram, respectively, in a specially formulated cream base. Halog Ointment (Halcinonide Ointment 0.1%) contains 1 mg. halcinonide (0.1%) per gram in Plastibase® (Plasticized Hydrocarbon Gel), a polyethylene and mineral oil gel base. Halog Solution (Halcinonide Solution 0.1%) contains 1 mg. halcinonide (0.1%) per ml.
CONTRAINDICATIONS: Topical steroids are contraindicated in vaccinia, varicella, and in those patients with a history of hypersensitivity to any of the components of the preparations. These preparations are not for ophthalmic use.
PRECAUTIONS: *General*—If local infection exists, suitable concomitant antimicrobial or antifungal therapy should be administered. If a favorable response does not occur promptly, application of the corticosteroid should be discontinued until the infection is adequately controlled. If extensive areas are treated or if the occlusive technique is used, the possibility exists of increased systemic absorption of the corticosteroid and suitable precautions should be taken. If irritation or sensitization develops, the preparation should be discontinued and appropriate therapy instituted. Although topical steroids have not been reported to have an adverse effect on pregnancy, the safety of their use during pregnancy has not been absolutely established; therefore, they should not be used extensively on pregnant patients, in large amounts, or for prolonged periods of time.
Occlusive Dressing Technique—The use of occlusive dressing increases the percutaneous absorption of corticosteroids; their extensive use increases the possibility of systemic effects. For patients with extensive lesions it may be preferable to use a sequential approach, occluding one portion of the body at a time. The patient should be kept under close observation if treated with the occlusive technique over large areas and over a considerable period of time. Occasionally, a patient who has been on prolonged therapy, especially occlusive therapy, may develop symptoms of steroid withdrawal when the medication is stopped. Thermal homeostasis may be impaired if large areas of the body are covered. Use of the occlusive dressing should be discontinued if elevation of the body temperature occurs. Occasionally, a patient may develop a sensitivity reaction to a particular occlusive dressing material or adhesive and a substitute material may be necessary. If infection develops, discontinue the use of the occlusive dressing and institute appropriate antimicrobial therapy.
ADVERSE REACTIONS: The following local adverse reactions have been reported with topical corticosteroids: burning, itching, irritation, striae, skin atrophy, secondary infection, dryness, folliculitis, hypertrichosis, acneform eruptions, and hypopigmentation. The following may occur more frequently with occlusive dressings: maceration of the skin, secondary infection, skin atrophy, striae, and miliaria. Contact sensitivity to a particular dressing material or adhesive may occur occasionally (see PRECAUTIONS).
For full prescribing information, consult package insert.
HOW SUPPLIED: The 0.025% and 0.1% Cream and the 0.1% Ointment are supplied in tubes of 15 g. and 60 g., and in jars of 240 g. (8 oz.). The 0.1% Solution is supplied in plastic squeeze bottles of 20 ml. and 60 ml.

SQUIBB®

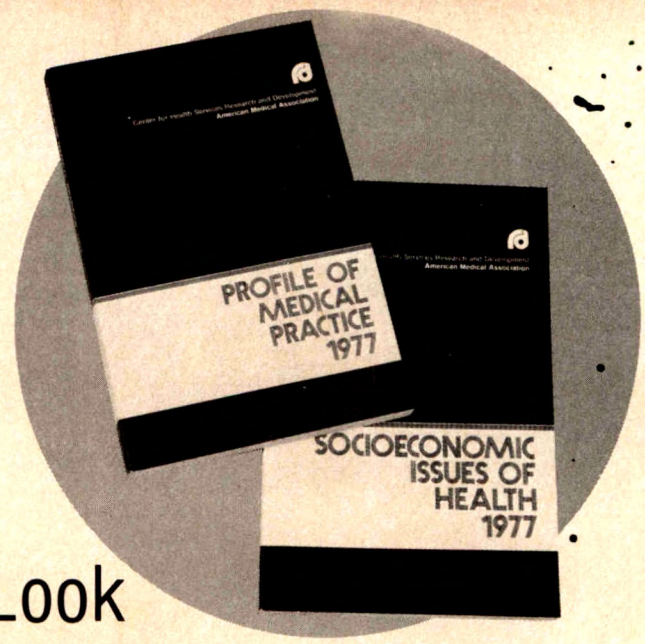

A New Look for the 1977 Red and Blue Books

Those familiar **Red and Blue Books,** published by the American Medical Association's Center for Health Services Research and Development, now have new size. . .new format. . .new data. As a result, you will find them more useful and convenient than ever. Here's a closer look at the 6th annual edition of these authoritative volumes:

Profile of Medical Practice 1977 (Red Book)
The focus is on characteristics of medical practice such as physicians' work patterns, professional expenses, and net income from medical practice. Among the topics covered in short articles are: physician productivity, rural group practice, and hospital utilization by physicians.

Socioeconomic Issues of Health 1977 (Blue Book)
Current data on medical education, medical manpower in the U.S., and financial characteristics of the health services delivery system are featured. Also included are essays on such issues as national health insurance, second surgical opinion programs, and the physician's role in cost accountability.

Quantities are limited, so order today!

S/J

Order Dept.
American Medical Association
535 N. Dearborn
Chicago, IL 60610

_____Profile of Medical Practice (OP-6) $4.50
_____Socioeconomic Issues of Health (OP-5) $4.50

Enclosed is my check for $_____, payable to the American Medical Association.

Name_____

Address_____

City/State/Zip _____

When the fluorinated steroid is gone–

Problems such as striae, or dermal atrophy leading to telangiectasia and fragility, especially on the face, in the groin, anal or axillary areas may be the result.

Consider Starting with Hytone® 2.5% (hydrocortisone)

For rapid control of the majority of inflammatory dermatitides seen in office practice.

Followed by–Hytone® 1% or 0.5%

for maintenance therapy and ultimate control–especially on the face or in children.

Hytone®–the conservative but effective approach

HYTONE® CREAM (hydrocortisone)

DESCRIPTION: Hydrocortisone 2½%, 1% and ½% in a water-washable cream containing purified water, propylene glycol, isopropyl myristate, cholesterol and related sterols, cetyl alcohol, sorbic acid, glyceryl monostearate, polysorbate 60, sorbitan monostearate and polyoxyl 40 stearate. ACTIONS: Topical corticosteroids are effective primarily because of their anti-inflammatory, antipruritic, and vasoconstrictive actions. INDICATIONS: For relief of the inflammatory manifestations of corticosteroid-responsive dermatoses. CONTRAINDICATIONS: In viral diseases of the skin such as varicella and vaccinia and in patients with a history of hypersensitivity to any component. Not for ophthalmic use. Topical steroids should not be used when circulation is markedly impaired. WARNING: Should not be used extensively, in large amounts, or for prolonged periods in pregnancy. PRECAUTIONS: If irritation develops, the product should be discontinued and appropriate therapy instituted. In the presence of an infection, the use of appropriate antifungal or antibacterial agents should be instituted. If a favorable response does not occur promptly, the corticosteroid should be discontinued until the infection has been adequately controlled. If extensive areas are treated or if the occlusive technique is used, the possibility exists of increased systemic absorption of the corticosteroid and suitable precautions should be taken. ADVERSE REACTIONS: The following local adverse reactions have been reported with topical corticosteroids, either with or without occlusive dressings: burning sensations, itching, irritation, dryness, folliculitis, secondary infection, skin atrophy, striae, hypertrichosis, acneform eruption and hypopigmentation. DOSAGE AND ADMINISTRATION: Apply to affected areas 3 or 4 times daily. HOW SUPPLIED: Cream 2½%—Tubes ½ oz. and 1 oz. Cream 1% and ½%—Tube 1 oz. and Jar 4 oz. CAUTION: Federal law prohibits dispensing without prescription.

Dermik

Dermik Laboratories, Inc.
Fort Washington, Pa. 19034

Ideal for dry skin care.

For dry skin care on a day-to-day basis, consider the soothing, softening, nondetergent cleansing properties of Alpha Keri Soap.

- Excellent cleansing properties eliminate harshness and irritation
- Contains Alpha Keri® therapeutic bath oil to soothe and soften skin
- Rich lather and delicate scent create outstanding patient acceptance

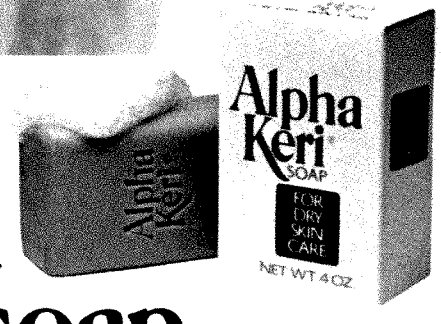

Alpha Keri® soap

The soothing, smoothing detergent-free cleanser

WESTWOOD
PHARMACEUTICALS INC.
Buffalo, New York 14213

In Canada, Belleville, Ontario K8N5E9

©1976, W.P. Inc.

Editorial

Are Medical Journals Obsolete?

This editorial by Alfred Soffer, MD, Chief Editor of the Archives of Internal Medicine, *appeared in the Sept 26, 1977 issue of the* JAMA *(238:1402-1403) and is being reproduced with the permission of Dr Soffer and the publishers of* JAMA.—ED.

The world of multimedia engulfs us. The medical profession has been particularly receptive to innovations in communications, including audiotapes and videotapes. Physicians eagerly embrace newer educational techniques such as the use of the computer as an integral element of workshops and lecture programs. The teacher and practitioner are beguiled daily by advertisements extolling the virtues of multimedia packages with self-assessment features. These packages range from elaborate motion pictures and filmstrip programs to relatively unsophisticated devices, eg, hand-held viewers and workbooks with exotic self-quiz techniques.

Many of these innovations are positive contributions to the physician's learning process. However, in the current national explosion of education programs, technique rather than content threatens to assume a primary role rather than a subsidiary status. Participants in national symposia have suggested that audiotapes and videotapes have made the position of the medical periodical untenable. Were we to believe some enthusiasts, the traditional role of medical periodicals has been dramatically altered. How very refreshing, therefore, to read that in a recent survey in California, clinical journals rate as the first choice in a list of "study devices which are most effective in enhancing the physician's ability to improve patient care." This was a survey of directors of medical and continuing education and specialty society officers; it was an attempt to evaluate the current contributions of education techniques such as hospital staff conferences, audiotapes, selfassessment examinations, and didactic classroom study. One hopes that this expression in the overriding importance of scientific publications will serve to reestablish realistic priorities in medical education.

An apparently infinite number of committee meetings and seminars have been held to determine how best to transmit to the clinician the results of current research. No group has identified a substitute for the indispensable role of scientific journals in the continuing education of the physician. Periodicals provide a permanent reference source for the clinician's office or home library. The clinician is an eclectic reader, and multiple subscriptions make it possible for him to choose those articles relevant to his particular needs and to peruse these communications at the speed best suited to his own learning habits. Journals permit him to return time and time again, conveniently and rapidly, to the information that requires repeated attention. Even the most versatile videotape or computerized program cannot provide this form of personal retrieval capability.

Continuing medical education is no longer a factor of individual responsibility but now is part of a compulsory structure. The bandwagon races on and an increasing number of state governments have notified the medical profession that proof of continuing education will be a requirement for relicensure. Many specialty societies have established similar requirements. The debate rages as to whether proof of participation in postgraduate endeavors such as postgraduate courses of workbook tests results in behavior modification or indicates understanding. Of more immediate concern to the medical editor, however, is evidence that the fundamental role of the published word has been neglected in the emergence of these national trends. A sure sign that an imbalance of priorities has resulted is the fact that budgets for many medical periodicals have not increased adequately to meet the steep rise in production costs. As a result, the number of editorial pages has decreased, and often the quality of publication has been compromised.

Where can we obtain the finances necessary to meet the vastly increased costs of printing and mailing? Advertising dollars frequently cannot even maintain the status quo because the total marketing budget must provide for increased page costs. Subscription costs must remain competitive or else the clinician will drop several of his subscriptions. Private foundations and government agencies have evidenced little interest in supporting scientific periodicals in this time of stress. Thus, medical editorial boards find themselves very low on the list of immediate priorities for the "educational dollar." How very strange that this has occurred when scientific documentation is dependent more than ever before on the subscription journal and the medical society periodical. Scientific periodicals constitute the mirrors of the societies that publish them. An excellent journal reflects the scientific integrity and the intellectual curiosity of the leadership of that society. Nevertheless, the growth of such periodicals has been jeopardized on occasion by relegation of the periodical to a lesser role in the overall budgetary planning. Of course, the frightening increase in medical association administrative costs indicates why the membership dollar, which must provide for multiple membership activities, may become insufficient for publication needs.

Spectacular increases in biomedical research have been made possible by the expenditure of billions of dollars of governmental funds. However, little or no provision has been made for financing the dissemination of the results of these investigations. How can original data contribute to the teaching and practice of medicine if this information does not obtain editorial peer review and ultimate publication in a clinical periodical? Most editors are inundated by a torrent of fine research studies. Even if the most vigorous editorial review procedures are used, increasing numbers of instructive reports cannot be published because of lack of space. These losses may be irretrievable, and yet the situation grows more ominous day by day. English has become the international scientific language, and editorial boards of periodicals published in English have a responsibility to honor excellent investigations from Japan, Israel, and a host of other countries in addition to research funded by the US government. Industrial support of scientific periodicals is a critical element in financing, but in recent decades large sums of money have been diverted from these periodicals to controlled circulation medical newspapers and magazines. The latter perform useful functions, but the primacy of the scientific periodical can no longer be ignored.

There are immediate threats and future dangers to the communication of medical information to the practicing physician. All segments of the biomedical community must accept the responsibility of maintaining and enhancing the vitality of the scientific periodical. We dare not inhibit the capability of the medical editor to accept all superior articles. Restriction of this privilege will initially endanger the research sector of medicine, but ultimately it will limit the ability of the practitioner to practice the highest standards of medicine.

ALFRED SOFFER, MD
Park Ridge, Ill

Heredity of Chronic Polymorphous Light Eruptions

Christer T. Jansén, MD

• The familial occurrence of chronic polymorphous light eruptions (CPLE) was investigated by a thorough interrogation of 91 CPLE patients. Fifty-one of these were aware of the presence of one to five familial cases, a number of which were evaluated and confirmed as CPLE. The secondary cases were usually morphologically similar to the primary case, but notable exceptions were occasionally recorded. The genealogical data pointed toward an autosomal dominant mode of inheritance of the CPLE trait, with a reduced penetrance. In the sibships of 80 persons with presumed or confirmed CPLE, the rate of penetrance was estimated to be 52%. The atopic trait appeared to be a factor promoting the manifestation of the latent CPLE trait.

(*Arch Dermatol* 114:188-190, 1978)

The chronic polymorphous light eruptions (CPLE) constitute a group of itching, recurrent photodermatoses, the etiology of which still remains unknown.[1] Interestingly, a hereditary factor was implied already in the very earliest works on CPLE. Hutchinson,[2] in his classic report on "prurigo aestivalis" mentioned that two brothers of one of the female patients had suffered from a similar rash. Rasch,[3] the first investigator to use the term "polymorphous light eruption," described a mother and daughter suffering from the disease. Although many later publications have confirmed the familial nature of the disease, no author seems to have analyzed the question more closely. In this report, the occurrence of CPLE in the relatives of 91 CPLE patients is described in some detail.

Accepted for publication Aug 4, 1977.

From the Department of Dermatology, University of Turku (Finland).

Reprint requests to Department of Dermatology, University of Turku, 20520 Turku 52, Finland (Dr Jansén).

PATIENTS AND METHODS

Patients

The patients were seen at the University Hospital dermatologic clinic in Oulu, Finland, during the period 1971 to 1973 in connection with a larger clinical study on CPLE.[4] CPLE was defined as a recurring, pruritic summer eruption, confined predominantly to exposed skin, precipitated by sun exposure, and unrelated to the intake of any photosensitizing drugs. To exclude other disease with light sensitivity, such as the porphyrias and lupus erythematosus, appropriate laboratory tests including the antinuclear antibody test, erythrocyte protoporphyrin measurements, and urinary and fecal porphyrin estimations were made. A single exposure to three to six times the minimal erythemal dose of unfiltered light from a xenon arc or a medium-pressure mercury lamp produced a delayed itching, edematous, papular, or eczematous reaction in 72% of the patients but in only 5% of 47 healthy controls. Patients with an eczematous eruption were photopatch-tested with tetrachlorsalicylanilide, bithionol, and hexachlorophane, each 1% in petrolatum. Only one positive reaction to hexachlorophane was recorded, and no logical relationship between the finding and the long history of the patient's light-sensitivity could be recorded.

Table 1.—Familial Cases in Families of 91 Primary Patients Classified According to Morphology of Their Dermatosis

Primary Patients			
Morphological Subtype	Total No.	No. Reporting Familial Cases	Total No. of Familial Cases Reported
Vesicopapular	42	26	44
Prurigo-like	16	10	15
Eczematous	11	2	2
Maculonodular	10	4	5
Other	12	9	9

Recording of Familial Cases

On initial admission, every patient was asked about possible familial cases of itching summer dermatoses. The patients were requested to gather further information about this matter by interviewing their parents and grandparents as well as any other relatives. During the period of the study, every patient was seen on several (five to ten) occasions and each time further inquiries were made. If a positive answer was given, the patient was asked to provide complete information about his family over three generations, including dates of birth and death, the occurrence of skin problems, hay fever, asthma, other allergies, and other possible diseases. Complete information on all of the relatives concerned was given by 31 of the patients with familial cases, while less complete information was given by 20 patients. In the latter cases, information was usually lacking on one or more deceased distant relative; some familial cases of CPLE may thus have been missed. To ascertain that the reported familial cases were suffering from polymorphous light eruptions, detailed information on age of onset, yearly time of exacerbation and remission of the ailment, as well as a detailed description of the symptoms, were obtained through the primary patients. To control the accuracy of these reports, 15 familial cases were personally investigated. Fourteen of these were confirmed as CPLE and one as acne rosacea.

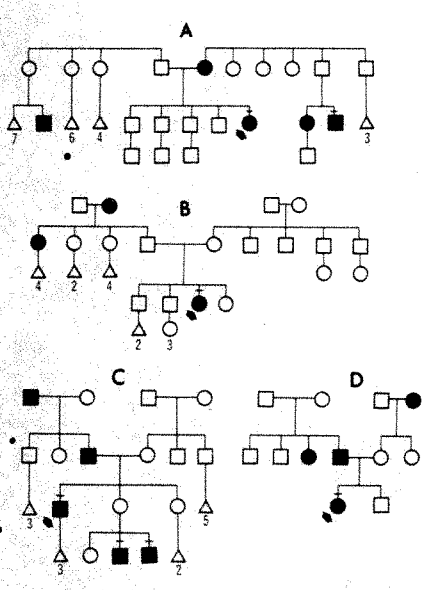

Some examples of familial occurrence of chronic polymorphous light eruptions (CPLE). Circles represent females; squares, males; and triangles, either. Dark symbols denote persons with itching summer eruption. Vertical bars indicate that eruption has been verified to be CPLE by personal investigation.

RESULTS

Frequency of Familial Cases

The frequency of familial cases is given below:

Familial Cases	No. of Patients
None	40
1	38
2	5
3	1
4	6
5	1

Fifty-one of the 91 patients (56%) were aware of one or several familial cases of itching summer dermatosis; the number of light-sensitive relatives ranged from one to five. Furthermore, it may be anticipated that some of the younger relatives could develop the problem with time, as polymorphous light eruption may start at middle age or even later. In our whole series, for example, 23% of the patients had been 31 to 50 years of age at the onset of the disease and 11% had been older than 50 years.

Table 1 shows the abundance of familial cases in the different morphological subtypes of CPLE.[4] Although familial cases could be found in any group of CPLE patients, those suffering from predominantly eczematous lesions seemed to have light-sensitive relatives less frequently than patients with other subtypes of CPLE.

Table 2.—Previous Reports on Familial Occurrence of CPLE*

Source	No. of Primary Patients	Frequency of Familial Cases		No. of Secondary Patients
		No.	%	
Hutchinson,[2] 1878	14	1	7	2
Crocker,[5] 1900	13	2	15	2
Haxthausen,[6] 1919	30	2	7	2
Epstein,[7] 1942	13	1	8	1
Stevanovic,[8] 1960	19	1	5	2
Magnus,[9] 1964	61	2	3	3
Verhagen,[10] 1965	72	7	10	7
Birt,[11] 1968	64	29	45	?
Epstein,[12] 1966	84	12	14	?
Frain-Bell et al,[13] 1969	24	1	4	1
Hojyo-Tomoka & Sota,[14] 1975	27	8	30	?

*Only investigations dealing with ten or more primary patients have been included.

Apparent Mode of Inheritance

The relationship of patients and their light-sensitive relatives are presented below; examples of family trees are given in the Figure. (The relationship of the older familial case to the youngest one is given.)

	No. of Cases
Sibling	18
Parent	23
Grandparent	6
Aunt or uncle	18
Cousin	8

The data point toward an autosomal dominant mode of inheritance, with a reduced rate of penetration.

To estimate the actual rate of penetration, calculations were made from the complete genealogic data obtained from 31 primary patients with familial cases. In these families, a total of 80 persons with itching summer eruptions were recognized; the diagnosis of CPLE in 44 of them was secured by clinical investigation. These diseased persons had a total of 229 healthy siblings. If an autosomal dominant inheritance with full penetration is assumed, the expected number of light-sensitive persons in these sibships should have been 80 + 229/2, that is, 154.5 persons. The penetrance in these sibships, therefore, can be estimated to be 80/154.5, that is 52%.

Phenotype Variation

The morphological subtype[4] of the polymorphous light dermatosis of the propositus and of one or two light-sensitive relatives were recorded by clinical examination in 12 families. The primary patient and secondary patient(s) displayed the same morphological appearance of their dermatosis in seven families, differed in two families, and in three families both identical and differing subtypes were recorded. The differing cases included the following: two sisters with prurigo-like vs vesicular type of CPLE; a boy with a vesicopapular CPLE whose sister suffered from a prurigo-like light dermatosis and whose mother had solar urticaria; two brothers having prurigo-like CPLE, whose uncle suffered from the vesicopapular type of the disease; and a woman with the maculonodular type of the disease, whose daughter had the vesicopapular variant of CPLE.

Relation to Atopic Diseases

Thorough data on a total of 1,083 non-sun-sensitive relatives, excluding the siblings of the sun-sensitive persons, were obtained in the study.

Of these, 59 were reported to suffer or to have suffered from asthma, hay fever, or atopic dermatitis, giving an overall prevalence of 5.4% of atopic ailments. In the same families, data were obtained on 80 persons with light dermatosis and their 229 siblings. Of these 309 persons, 50 were reported to suffer from atopic disease giving an incidence of 16.2%

COMMENT

Table 2 presents some accounts of the familial occurrence of CPLE.[2,5-14] The total number of patients listed is 421, of whom 81 were reported to have familial cases; this is an incidence of 19%. The incidence of 56% found in the present investigation is one of the highest ever published, superseded only by the 75% mentioned by Birt and Davis.[15] This may be due to the exceptionally thorough interrogation in the present study, the patient being questioned on the point several times during a three-year period. On the other hand, there may be racial differences in the incidence of inheritable CPLE, and high figures have been reported particularly in certain Indian tribes of North America[11] as well as in Mexican people.[15]

Unfortunately, few earlier reports have dealt with the mode of inheritance of the CPLE trait, although there are occasional case reports on familial cases of CPLE.[2,3,5-10,13,16-22] The cited articles contain data on the familial relationship of 21 primary patients and their 28 diseased relatives; 19 of the latter were siblings, nine were parents, and nine were grandparents. These data tend to support the conclusion that CPLE is inherited as an autosomal dominant trait. There are in the literature no calculations on the rate of penetrance, nor are sufficient data given to allow calculations to be made. Our estimation of a penetrance rate of 52% is to be taken with the reservation that it refers only to the manifestation of the disease in those sibships in which at least one person suffered from the disease, and thus gives no account of the fact that the trait very often did not express itself in every generation.

Our data indicate that familial cases of CPLE often represent the same morphological subtype. This is in corroboration with most earlier reports, though in the earlier works few exact descriptions are found. Thus, many authors state in passing that the cases looked "similar"[2,6,17,22] and in other papers, the patients are all included in the historical but morphologically vague term "summer prurigo."[20,21,23]

Interestingly, our data show that there are exceptions to this rule of similarity. This has occasionally been noted in the literature, too. Rasch[3] considered the dermatosis of his two patients to be dissimilar, and Epstein[7] described a boy with "summer prurigo" whose father suffered from an eczematous light eruption. Recently, Schnitzler et al[24] described a patient with "actinic reticuloid" whose daughter suffered from solar urticaria. These findings lend some support to the idea that the morphologically quite dissimilar subtypes of CPLE may, after all, represent one single disease entity.[4]

Once a person has inherited the CPLE trait, additional factors may determine whether the predisposition becomes manifest and what the clinical picture will be. In the present study, the atopic state appeared to be a factor that increased the possibility of the inherited trait of CPLE becoming clinically manifest.

References

1. Jansén CT, Helander I: Cell-mediated immunity in chronic polymorphous light eruption. *Acta Derm Venereol* 56:121-125, 1976.
2. Hutchinson J: Summer prurigo: Prurigo aestivalis, seu prurigo adolescentium, seu acne-prurigo. *Med Time Gaz* 50:161-163, 1878.
3. Rasch C: Om et polymorft (erytematøst, vesikuløst og eksematoidt) lysudslet. Hospitalstidende 8:478-480, 1900.
4. Jansén CT: *Polymorphous Light Eruptions: A Clinical Study of 138 Cases.* Turku, Finland, Polytypos, 1975.
5. Crocker R: A clinical study of some winter and summer recurring eruptions. *Br J Dermatol* 12:40-55, 1900.
6. Haxthausen H: *Hudsygdomme Fremkaldt af Lyset.* Copenhagen, Pios Boghandel, 1919, pp 109-161.
7. Epstein S: Studies in abnormal human sensitivity to light: I. Prurigo aestivalis, eczema solare and urticaria photogenica: Report of 17 cases and review of the literature. *J Invest Dermatol* 5:187-196, 1942.
8. Stevanovic DV: Polymorphic light eruption. *Br J Dermatol* 72:261-270, 1960.
9. Magnus IA: Studies with a monochromator in the common idiopathic photodermatoses. *Br J Dermatol* 76:245-264, 1964.
10. Verhagen ARHB: *Onderzoekingen bij Chronische Polymorfe Lichtdermatosen.* Amsterdam, Rototype, 1965.
11. Birt AR: Photodermatitis in Indians of Manitoba. *Can Med Assoc J* 98:392-397, 1968.
12. Epstein JH: Polymorphous light eruptions. *Ann Allergy* 24:397-405, 1966.
13. Frain-Bell W, McKenzie LA, Witham E: Chronic polymorphic light eruption: A study of 25 cases. *Br J Dermatol* 81:885-896, 1969.
14. Hojyo-Tomoka MT, Soto LD: Clinical and epidemiological characteristics of polymorphous light eruptions in Mexico. *Castellania* 2:21-23, 1975.
15. Birt AR, Davis RA: Hereditary polymorphic light eruption of American Indians. *Int J Dermatol* 14:105-111, 1975.
16. Barber HV, Howitt FD, Knott FA: Some observations on light-sensitization. *Guys Hosp Rep* 76:314-341, 1926.
17. Burckhardt W: Polymorphe Lichtdermatose. *Dermatologica* 86:249, 1942.
18. Eheeler GE, Cawley EP, Whitmore CW: Hydroa aestivale in identical twins. *Arch Dermatol* 82:590-594, 1960.
19. Glaubersohn SA, Goldenberg MM: Zur Lehre über die Photodermatosen. *Derm Wochenschr* 91:1625-1633, 1930.
20. Nobl G: Zur Kenntniss solarer Lichtschädigungen der Haut. *Med Wochenschr* 69:382-390, 1919.
21. Pick E: Zur Kenntniss der Sommerprurigo (Hutchinson). *Arch Dermatol Syphil* 146:466-473, 1923.
22. Unna PG: Ueber die Duhrigsche Krankheit und eine neue Form derselben. *Monatshefte Praktische Dermatologie* 9:97-113, 1889.
23. Frain-Bell W, Mason B: The investigation of polymorphic light eruption in identical twins. *Br J Dermatol* 80:314-322, 1968.
24. Schnitzler L, Schubert B, Belperron P, et al: Actinic reticuloid developing in the course of porphyria cutanea tarda. *Br J Dermatol* 91(suppl):30, 1974.

The Cutaneous Manifestations of Sinus Histiocytosis With Massive Lymphadenopathy

Hasina Thawerani, MD; Ramón L. Sanchez, MD; Juan Rosai, MD; Ronald F. Dorfman, MRCPath

• Ten patients with sinus histiocytosis with massive lymphadenopathy (SHML) also had cutaneous involvement. Seven of the ten were children. The skin lesions were solitary in three patients and multiple in seven. They were papular or nodular, up to 4 cm in diameter, and often had a xanthomatous appearance. Microscopically, they were constituted by a dermal infiltrate made up predominantly of histiocytes, plasma cells, and lymphocytes. Some of the histiocytes contained phagocytosed lymphocytes in their cytoplasm. The microscopic differential diagnosis includes dermatofibroma, xanthoma, Tangier disease, histiocytosis X, reticulohistiocytoma, juvenile xanthogranuloma, and leprosy.

(*Arch Dermatol* 114:191-197, 1978)

Sinus histiocytosis with massive lymphadenopathy (SHML)[1-4] is a benign, generally self-limited disease that typically appears with cervical lymphadenopathy (often bilateral, painless, and massive) usually accompanied by fever, leukocytosis with neutrophilia, elevated ESR, and polyclonal hypergammaglobulinemia. Other lymph node groups (such as mediastinal, axillary, and inguinal) also may be involved. The disease occurs in any age group, but shows a marked predilection for the first and second decades of life. There is no sex predilection. Blacks seem to be more susceptible to this disorder, which has a worldwide distribution but is more commonly seen in Africa and the West Indies. The course of the disease is almost invariably benign and tends toward spontaneous resolution, although in some cases the lymphadenopathy may last for years. The cause remains unknown; SHML may represent either a specific infectious process or the manifestation of an immunologic disturbance.[5]

The microscopic appearance of the involved lymph nodes is characteristic. There is marked capsular and pericapsular fibrosis and a striking dilation of the lymph node sinuses. The latter are crowded with inflammatory cells of several types, the predominant cell being a sinus histiocyte with a large, vesicular nucleus, abundant weakly acidophilic cytoplasm, and irregular (somewhat spidery) cytoplasmic outlines. Typically, some of the histiocytes contain in their cytoplasm a large number of phagocytosed lymphocytes and other inflammatory cells. Some of the histiocytes have a foamy (neutral fat-containing) cytoplasm; others may be multinucleated or they may have moderately atypical nuclear features, even simulating the Reed-Sternberg cells of Hodgkin's disease. The medullary cords between the dilated sinuses are often packed with mature plasma cells, some of which contain cytoplasmic Russell bodies.

Through the courtesy of numerous physicians, we have collected 111 examples of this disorder and are presently preparing a thorough clinicopathologic analysis of these cases (unpublished data). In the course of this study, we observed a number of patients who exhibited, in addition to the above-described lymph node manifestations, evidence of extranodal involvement by the same process. These sites included the upper respiratory tract, orbit, skeletal system, testicle, and skin. It is the purpose of this study to describe in detail the last group of patients, that is, those having evidence of cutaneous involvement by SHML.

PATIENTS AND METHODS

Of the total group of 111 patients with SHML, there were 14 in whom cutaneous lesions were documented sometime during the course of the disease. Four of these were eliminated because the clinical description suggested that their skin lesions (although possibly related in some fashion with the basic disease) did not represent cutaneous involvement by the infiltrate of SHML. They were a patient with generalized exfoliative dermatitis; a patient with a multiple scaly erythematous lesions involving the scalp and the lower part of the back, clinically diagnosed as psoriasis; a patient with eczema (in a patient with Wiskott-Aldrich's syndrome);

Accepted for publication April 15, 1977.

• From the Departments of Laboratory Medicine-Pathology and Dermatology, University of Minnesota Medical School, Minneapolis; and the Department of Pathology, Stanford (Calif) University Medical School.

Reprint requests to Box 609, Mayo Building, University of Minnesota Medical School, 420 Delaware St SE, Minneapolis, MN 55455 (Dr Rosai).

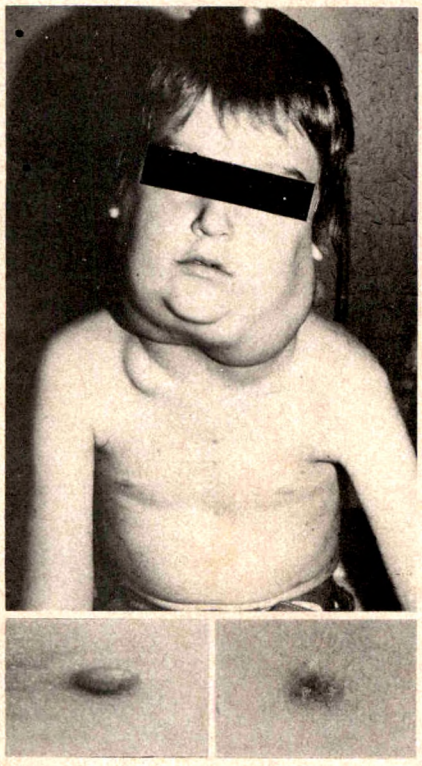

Fig 1.—Patient with SHML. There is massive cervical and supraclavicular lymphadenopathy, as well as multiple red-topped papules in the skin of the chest. Insets represent close-ups of two individual lesions; one is distinctly elevated and nodular and the other is only slightly raised (case 7).

Table 1.—

Case No.*	SHML Case No.	Age, yr/Sex/Race	Origin	Duration at Time of Diagnosis	Cervical Adenopathy
1	5	5/M/black	USA	Several yr	+++
2	31	14/F/Oriental	Japan	4 yr	+++
3	40	8/F/white	Netherlands		+++
4	45	6/M/black	South Africa	5 yr	+++
5	54	3/M/white	USA	Weeks	+++
6	56	3/M/black	Honduras	6 mo	+++
7	69	7½/M/white	USA	5 mo	+++
8	93	40/M/white	Germany	2 yr	+++
9	94	41/M/white	France		+++
10	115	48/M/white	Costa Rica	Several mo	...

* Case 1 has been previously reported by Azoury FJ and Reed RJ: Histiocytosis. Report of an unusual case (*N Engl J Med* 274:928-930, 1966).

Case 6 has been previously reported by Ramos CV: Widespread bone involvement in sinus histiocytosis (*Arch Path Lab Med* 100:606-608, 1976). However, no mention was made on this article about the presence of skin lesions in the patient.

+++ signifies marked; ++ moderate; + scanty.

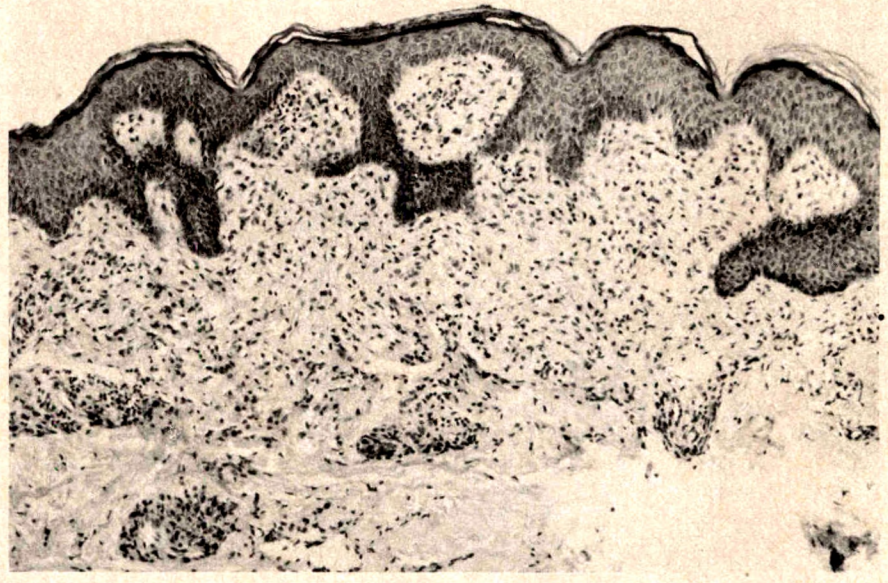

Fig 2.—Cutaneous infiltrate of SHML (case 4). The proliferation predominates in the upper dermis and is accompanied by irregular elongation of the epidermal rete ridges. Vascular proliferation is evident at the periphery (hematoxylin-eosin, ×80).

and a patient in whom transient pinhead-sized erythematous papules suddenly appeared, only to clear spontaneously in three days.

REPORT OF CASES

The most important clinical features of the ten patients included in this study are summarized in Table 1. Seven of the ten patients were children. There were six whites, three blacks, and one Oriental. Eight males were affected as opposed to two females. The nodal manifestations of the disease as well as the symptoms and laboratory abnormalities were in general not different from those of the whole group of SHML patients. Other sites of extranodal involvement were detected in six patients; these included the nasal cavity, tonsil and nasopharynx, salivary gland, orbit, bone, and testicle. In addition, two patients (one of them also having documented extranodal involvement by SHML) were admitted with hepatosplenomegaly.

The features of the cutaneous lesions are listed in Table 2 and illustrated in Fig 1. They were described as multiple in seven cases and as solitary in the other three. No predilection for a particular region of the body was evident; the face, trunk, and upper and lower extremities were all affected. The available clinical descriptions are sketchy, but indicate that most lesions were papular or nodular, up to 4 cm in diameter, and sometimes had either a xanthomatous or erythematous appearance.

The evolution of the cutaneous lesions is known in four cases. In three, they underwent partial or total spontaneous regression, in conjunction with the regression of the other symptoms and signs of the disease. In the other patient (case 7), the skin lesions exhibited an interesting change following the administration of transfer factor given in an attempt to improve the immunologic status of the patient. Following the administration of 1 unit of transfer factor (given in a two-week period) and after an interval of six weeks, more skin lesions appeared; four days after the administration of an additional 4 units of transfer factor, the skin lesions began to fade and flatten out. Ten months after this second treatment, the lesions flattened out even more and their original purplish color changed to a brownish hue, now closely resembling freckles.

MICROSCOPIC APPEARANCE

Microscopic slides were available for review in eight cases. The principal histo-

General Data on SHML Patients With Cutaneous Involvement

Other Adenopathies	Extranodal Sites	Fever	ESR, mm/hr	Hemoglobin (gm/100 ml)	WBC, X cu mm	Serum Gamma Globulins	Evolution
Axillary, inguinal	Testicle, orbit (hepatosplenomegaly)	+	25	10	2,000	2.7 gm/100 ml	Alive with persistent disease 13 yr later
Axillary, inguinal	Tonsil, nasopharynx	+	59	13.1	7,000	Increase of IgG	Alive & well 7 yr later
Mediastinal, inguinal	(Hepatosplenomegaly)	+	25	8.3	"Moderate leukopenia"	Increase of IgG	Alive with persistent disease 3.7 yr later
Axillary	Salivary gland	−		11.4	6,300	Increase of IgG and IgM	Alive with persistent disease 4 yr later
Hilar	...	+	26	12.3	5,800		Alive & well 1.6 yr later
Mediastinal, inguinal	Bone	+		6.7	8,750	2.84 gm/100 ml	Alive with persistent disease 6 mo later
Hilar, inguinal	...	−		9.9	16,600	3.0 gm/100 ml	Alive with persistent disease 2 yr later
Axillary	...					Increased	
Axillary	Nasal cavity	−		Normal	Normal	Increase of IgG, IgA, and IgM	Alive with persistent disease 11 yr later
...	...	−				Markedly increased	Recent case

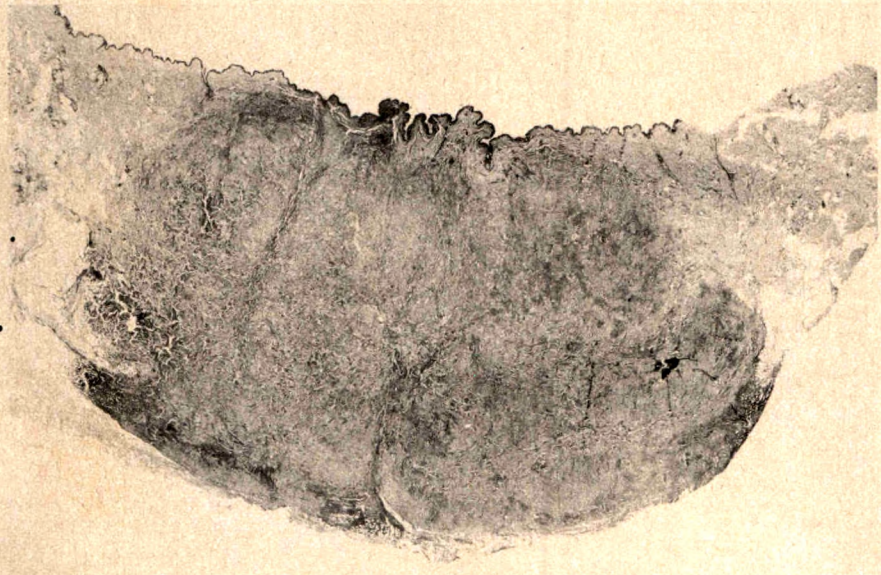

Fig 3.—In this case (case 10), the infiltrate is denser, better circumscribed, and more extensive than in Fig 2. It involves the entire thickness of the dermis and extends into the subcutis (hematoxylin-eosin, ×5).

logic features are summarized in Table 2.

The main abnormality seen was a dense inflammatory infiltrate in the dermis. In the smaller lesions, this was located in the upper dermis in close contact with the epidermal basal layer, without the formation of grenz zone (Fig 2); in the larger nodules, the lesion occupied the entire dermis and extended into the superficial portion of the subcutaneous fat (Fig 3). Although the infiltrate could not be described as well-circumscribed, it exhibited a definite focal quality on low-power examination and in a few cases appeared distinctly nodular (Fig 3). The infiltrate was composed of a variety of cells, all of them of an inflammatory nature. The most important element comprised histiocytes with large vesicular nuclei, generally small single nucleoli, and abundant pale acidophilic cytoplasm (Fig 4). The cell outline was often indistinct and sometimes had an irregular, somewhat spidery configuration. There were scattered binucleated or multinucleated histiocytes in seven cases. The nuclei of some histiocytes contained prominent and/or several nucleoli; others were elongated and comma-shaped, imparting to the cell an endothelioid appearance. A foamy appearance of the cytoplasm, suggestive of lipid accumulation, was also noted in some mononuclear histiocytes, which were often arranged in clusters. Some of these cells exhibited the features of Touton giant cells (Fig 5). Isolated histiocytes combined multiple nuclei and nucleolar prominence to acquire features vaguely reminiscent of Reed-Sternberg cells. Presence of lymphocytes within the cytoplasm of histiocytes (representing either lymphophagocytosis or emperipolesis) was identified in six cases, in one of them accompanied by plasma cells and in another by neutrophils (Fig 6).

Other cells present in the infiltrate included lymphocytes in all patients, plasma cells in six (Fig 7, left), neutrophils in five (Fig 7, center), and epithelioid cells in one (Fig 7, right). The plasma cells were always mature, occasionally binucleated, and sometimes contained typical Russell bodies in their cytoplasm (Fig 7, left). In two cases (one containing neutrophils in the infiltrate and one devoid of them), rare specks of nuclear dust were identified. Eosinophils were encountered only twice and in relatively small numbers. Extravasation of RBCs was not a prominent feature of these lesions, having been noted in only two cases.

A moderate increase in vascularity was a common feature within the nodules. The endothelial cells appeared plump, but there was no evidence of vasculitis. The blood vessels around the nodule often appeared prominent, with a perivascular scattering of lymphocytes, neutrophils, and histiocytes. Deposition of hemosiderin within the histiocytes or elsewhere in the lesion was minimal or absent; on the other hand, the histiocytes of one patient contained a few intracytoplasmic melanin granules. Fibrosis within the lesion was questionable or absent in three patients, mild in four,

Table 2.—Clinical and Microscopic Features

Case No.	Location	No.	Clinical Appearance	Evolution	Distribution of Infiltrate	Epidermis
1	Left side of face	Solitary	"Small lesion"	...	Entire dermis, extending into subcutis	Flattening of rete ridges
2	Upper & lower extremities	Multiple	Exanthema with brownish pigmentation, up to 3-cm in diameter	Began to subside	Entire dermis	Hyperkeratosis & parakeratosis, flattening of rete ridges
3	Extensor surfaces of lower legs	Multiple	Pink-bluish, slightly elevated infiltrates	Regressed completely	Entire dermis, diffuse	Mild hyperkeratosis & parakeratosis, flattening of rete ridges
4	Abdomen	Multiple	Xanthomatous rash	Regressed	Upper dermis, circumscribed	Parakeratosis & slight acanthosis, elongation of rete ridges
5	Right temple eyelid, & chest	Multiple	3 x 4-cm yellow, flat xanthoma (temple), pinpoint xanthelasma (eyelid & chest)	...		
6	Face, trunk, & upper extremities	Multiple	Small yellow papules of xanthomatous appearance	...		
7	Trunk (predominant) & extremities	Multiple	Slightly raised, redtopped papules & plaques 1.5-cm in diameter	Faded & flattened out following transfer factor (see text)	Predominantly in upper dermis	Slight acanthosis & exocytosis
8	"Generalized"	Multiple	...	...	Entire dermis impinging on subcutis	Mild atrophy, with flattening of rete ridges
9	Temple	Solitary	0.2-cm nodule	...	Entire dermis, circumscribed	Flattening of rete ridges
10	Shoulder	Solitary	2.5-cm nodule	...	Entire dermis, extending into subcutis	Unremarkable

* +++ signifies marked; ++ moderate; + scanty.

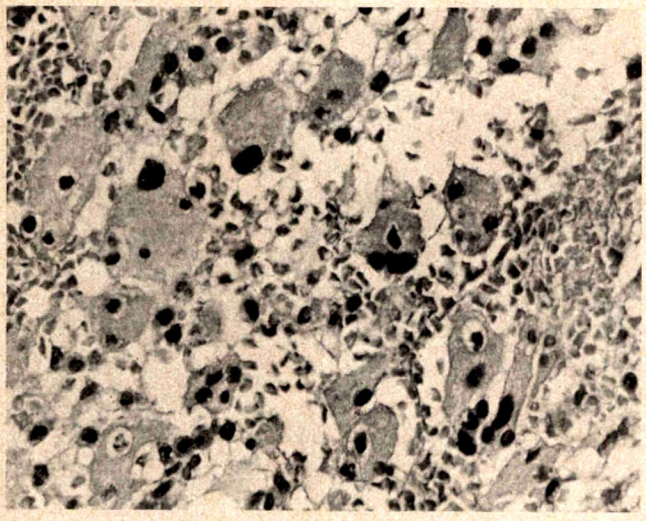

Fig 4.—Case 2. Histiocytes with large nuclei and abundant cytoplasm are present among extravasated red blood cells (hematoxylin-eosin, ×600).

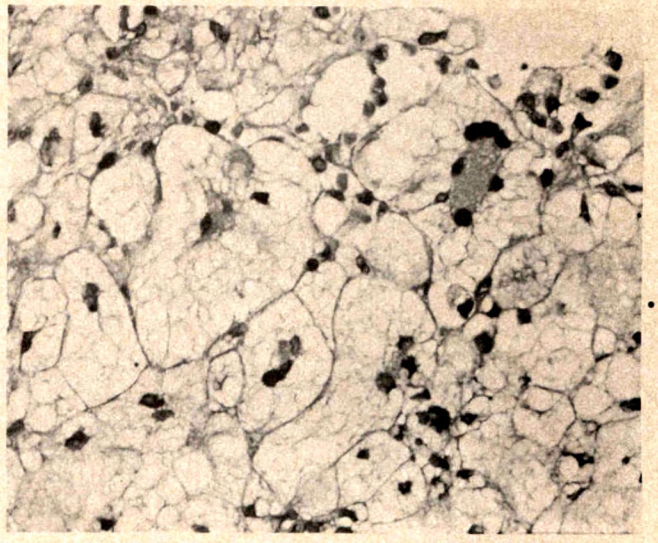

Fig 5.—Case 2. Cluster of foamy histiocytes, some of them exhibiting the features of Touton giant cells (hematoxylin-eosin, ×600).

and prominent in only one. In the latter, the histiocytes and other inflammatory cells were arranged individually or in small groups surrounded by collagen bundles.

The different cell types comprising the infiltrate were, in general, closely intermixed. However, in four patients there were areas in which the histiocytes segregated in clusters in a manner very reminiscent of that commonly seen in the lymph nodes involved by SHML. This similarity was further enhanced by the observation that in two patients these cells seemed to be contained within tissue spaces (possibly lymphatic vessels) resembling lymph node sinuses (Fig 6 top, and 8).

The overlying epidermis was not particularly remarkable, most of the changes observed being probably the result of the underlying dermal process. The basal layer tended to be flat, with effacement of the rete ridges; there was mild acanthosis in two cases and atrophy of the malpighian layer in one. A patchy parakeratosis was recorded in three cases and in two it was accompanied by a slight degree of hyperkeratosis. The dermal infiltrate did not extend into the epidermis; in only one case was a mild degree of lymphocytic exocytosis detected.

In case 7, skin biopsies were performed before and after the administration of transfer factor. The only change that was detected in the posttherapy biopsy was an apparent increase in the number of multinucleated histiocytes. The possibility that this represented a sampling artifact could not be excluded since the pretherapy and posttherapy biopsy specimens were from two different lesions.

COMMENT

Although the cause and pathogenesis of this disorder remain unknown, there is general acceptance that SHML represents a well-defined clinicopathologic entity.[1-4] The microscopic

of the Cutaneous Lesions of SHML*

Histiocytes	Multinucleated Histiocytes	Lymphophagocytosis	Lymphocytes	Plasma Cells	Neutrophils	Vascularity	Fibrosis	Other
+++	+	+	++	+++	−	+	+	Occasional eosinophils, scattered Russell bodies in plasma cells
+++	+	+++	++	+	++	+	−	
+++	+	−	++	−	−	+	++	Occasional nuclear dust
+++	−	−	+	−	−	+	−	Occasional melanin granules in histiocytes
+++	+	+	++	+	+	++	+	Occasional eosinophils
++	+	++	+++	+++	+	++	+	Numerous Russell bodies in plasma cells
+++	+	++	+++	+++	++	+	−	Occasional multinucleated plasma cells, occasional nuclear dust
++	+	+	+++	+++	+	+	+	

appearance of the involved lymph nodes is particularly characteristic. Its recognition is important, as demonstrated by the fact that in the past many cases have been erroneously diagnosed and treated as malignant lymphoma, Hodgkin's disease, and "malignant reticuloendotheliosis," sometimes with disastrous consequences.

Increasing experience with this disease has shown, among other things, that SHML tends to involve extranodal structures more often than indicated in the original descriptions (R. Sanchez; et al, unpublished data). The microscopic appearance of the disease in these sites is quite similar to that seen in the lymph nodes in terms of cellular composition of the infiltrate. On the other hand, the overall architecture is somewhat variable, mainly as a function of the type of tissues and structures involved. Foremost in this regard is the absence in the skin and most other extranodal sites of lymph node sinuses, whose alterations represent one of the most important hallmarks of SHML. It has thus become evident that the designation "sinus histiocytosis" is not appropriate when applied to most extranodal lesions, including those in the skin. The alternative designation that we have chosen to describe this phenomenon is that of "cutaneous involvement by SHML," analogous to the use of terms such as "cutaneous involvement by ulcerative colitis" or "cutaneous involvement by benign mucous membrane pemphigoid" to indicate skin involvement by conditions primarily affecting other organ systems.

The recognition of a cutaneous lesion of SHML is rarely a problem, since the nature of the disease is usually evident on the basis of the lymph nodal manifestations. However, it is important to describe the diagnostic criteria and differential diagnosis of this disease when located in the skin, since this not only may be the first source of biopsy material but (as case 10 demonstrates) it may also be the only obvious site of the disease. In this regard, it should be mentioned that we have now seen several other patients with SHML in whom a extranodal focus (such as an orbital mass) was the predominant manifestation of the disease, whereas the cervical nodal enlargement was minimal or absent. Thus, the designation of "*massive* lymphadenopathy" does not accurately describe this particular group of cases.

The cutaneous lesion of SHML can be defined as a dermal infiltrate predominantly composed of mature histiocytes (some foamy and/or multinucleated), lymphocytes, and plasma cells, with or without associated vascular proliferation and fibrosis and usually accompanied by relatively minor and nonspecific epidermal changes. Two additional features are the segregation between the histiocytes and the other inflammatory cells, the former sometimes arranging in tissue spaces suggestive of lymph vessels; and the presence of lymphocytes and other inflammatory cells within the cytoplasm of the histiocytes. Unfortunately, these features were usually not as prominent in the skin as they were in the lymph nodes, and sometimes they were absent.

The following diseases should be considered in the differential diagnosis on microscopic grounds.

Dermatofibroma (Fibrous Histiocytoma; Subepidermal Nodular Fibrosis)

The vast majority of dermatofibromas should not present a problem in differential diagnosis with SHML. In the typical dermatofibroma, the fibroblastic component is usually more conspicuous and hemosiderin is often present. Collagen fibers are abundant, many of them exhibiting a pale blue color when stained with hematoxylin-eosin. A "storiform" pattern of growth may be present. Lymphocytes are scanty and plasma cells are nearly absent. As a rule, the cytoplasm of the histiocytes is not as abundant as in SHML, and lymphophagocytosis is absent.[6]

Xanthoma

The type more likely to cause clinical and microscopical diagnostic difficulties with SHML is the eruptive xanthoma, since in this lesion the foamy histiocytes are admixed with

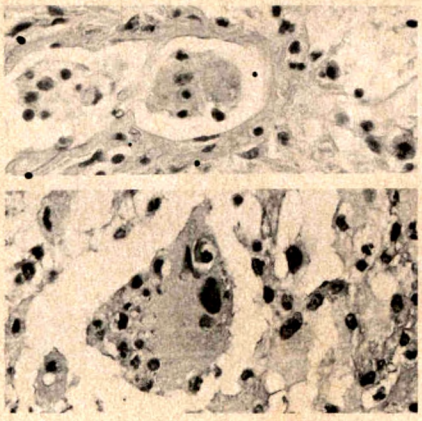

Fig 6.—Top, Case 8. Lymphophagocytosis by histiocytes. The large vesicular nucleus of the histiocytes can be easily distinguished from the smaller and darker nuclei of the phagocytosed lymphocytes, one of which is surrounded by a clear halo (hematoxylin-eosin, ×600). Bottom, Case 2. This histiocyte contains lymphocytes and neutrophils within its cytoplasm (hematoxylin-eosin, ×600).

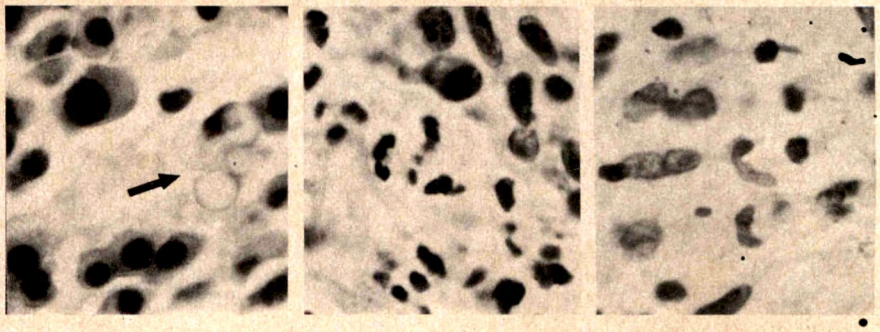

Fig 7.—Left, Case 8. Collection of plasma cells, one of them having a large hyperchromatic nucleus and another containing a clump of Russell bodies (arrow) (hematoxylin-eosin, ×600). Center, Case 9. A small collection of neutrophils between larger mononuclear cells (hematoxylin-eosin, ×600). Right, Case 4. The two histiocytes in the center have an elongated and angulated (endothelioid) nucleus (hematoxylin-eosin, ×375).

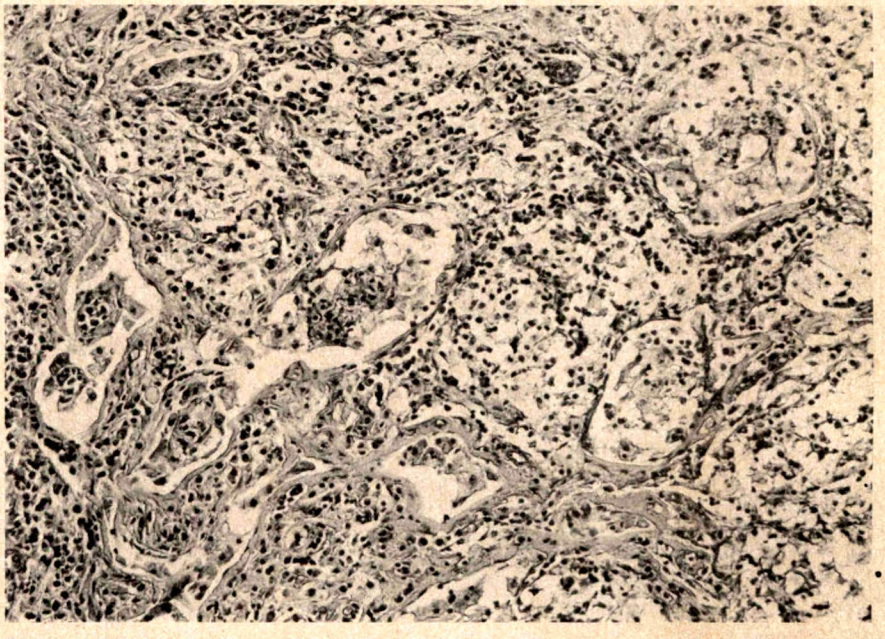

Fig 8.—In this case (case 8), most of the histiocytes are contained within spaces suggestive of lymph vessels, whereas most of the lymphocytes and plasma cells are in the intervening tissue. The appearance is very reminiscent of that usually seen in the lymph nodes involved by this process (hematoxylin-eosin, ×150).

several types of inflammatory cells.[6] Presence of plasma cells and lymphophagocytosis are features in favor of SHML. In their absence, a distinction between these two conditions may be difficult on histologic grounds.

Tangier Disease

In this recessively inherited abnormality, characterized by great decrease of the plasma α-lipoproteins and increase in the level of cholesterol ester in many tissues, cutaneous papules may be found.[7] Microscopically, lipid deposits in the dermis are present both within foamy macrophages and extracellularly. However, lymphocytes and plasma cells are absent. Vascular proliferation is not a feature and lymphophagocytosis is not observed.

Histiocytosis X

The most important microscopic feature of this condition, whether manifesting as Hand-Schüller-Christian disease, Letterer-Siwe disease, or eosinophilic granuloma, is the proliferation of cells with a very distinctive light and electron microscopic appearance.[8] Their nuclei are characteristically traversed by folds and grooves; ultrastructurally, organelles known as Langerhans' granules are seen in their cytoplasm. Although traditionally regarded as ordinary histiocytes, recent evidence suggests that they are components of a specific cell system known as Langerhans' cells.[9]

An outpouring of eosinophils is another common feature of histiocytosis X. Both Langerhans' cells and eosinophils are scanty or absent in the cutaneous lesions of SHML.

Reticulohistiocytoma (Reticulohistiocytic Granuloma)

In this condition, which usually affects women, the cytoplasm of the proliferating histiocytes has a characteristic "ground-glass" appearance, is not foamy, and contains abundant PAS-positive, diastase-resistant material. The cells are arranged individually, separated by an intricate network of newly formed reticulin and collagen fibers. Retraction of the cytoplasm leads to a sharp cellular outline and the formation of a lacuna bound peripherally by connective tissue fibers.[10]

Juvenile Xanthogranuloma (Nevoxanthoendothelioma)

This is the lesion that more closely resembles SHML from a microscopic point of view by virtue of the admixture of histiocytes, giant cells with a "wreath" of nuclei, Touton giant cells, and lymphocytes. However, plasma cells and lymphophagocytosis are not features of this process.[11]

Leprosy

It is well known that the lepromatous form of leprosy can microscopically simulate the appearance of a xanthoma or even that of a dermatofibroma.[6] That being the case, it should not be surprising that we are including this lesion in the differential diag-

nosis, another pertinent factor being that many cases of SHML are seen in areas of the world in which leprosy is endemic. The infiltrate of leprosy has poorly defined boundaries and the population of plasma cells is minimal. Using the Fite stain, innumerable acid-fast organism are identified.

Hodgkin's Disease

An abundance of foamy macrophages in tissues involved by Hodgkin's disease has been reported by Variakojis et al.[12] These authors have also emphasized that this phenomenon may result, at least in lymph nodes, in an erroneous diagnosis of SHML. Cutaneous involvement by Hodgkin's disease is exceedingly rare. Documentation is dependent on the identification of morphologically characteristic Reed-Sternberg cells in an appropriate stromal milieu, which also includes other atypical mononuclear and hyperlobated cells. These are not features of SHML.

A final consideration relates to whether SHML patients with cutaneous involvement show any distinct differences from the group of SHML patients as a whole. By and large, this can be answered in the negative. Seven of our ten patients (70%) were in the first or second decade of life, and this was the case of 81% of the whole population of SHML patients. Three of the ten patients (30%) were black; this was true for 42% of the larger group. The only clinical or laboratory features by which these patients with skin lesions differed somewhat from the other included the M:F sex ratio (4:1 vs 2:1) and the incidence of leukocytosis (12.5% vs 38%). However, the number of cases with cutaneous lesions is too small to determine whether these differences are significant. In five (and possibly six) of our ten patients, there were other extranodal lesions in addition to those of the skin; since the overall incidence of extranodal manifestations of SHML is only 23%, the above figure suggests that once the disease involves structures other than lymph nodes, it has a tendency to involve more than one organ system. In regard to the histology of the nodal lesion in the patients with cutaneous involvement, this did not differ in any way from those who did not exhibit this complication. The evolution of the disease in these cases was also representative of the whole group, in that in two patients the disease regressed completely and six others were found to have persistent disease up to 13 years following the original diagnosis.

The skin lesions had a tendency to involute spontaneously; this applied to all four cases in which we have follow-up information. Whether the remarkable sequence of changes described in case 7 was the direct consequence of transfer factor administration or simply a coincidental event is difficult to say; more cases in which this therapy is used will be needed in order to answer this provocative question.

The following physicians provided the microscopic slides, clinical summary of the cases, clinical photographs, and/or follow-up information: J. Chatten, Philadelphia (case 7); G. Garand, Tours, France (case 9); J. A. Hepp, Pompano Beach, Fla (case 7); P. Jobard, Tours, France (case 9); L. B. Kahn, Cape Town, South Africa (case 4); T.-T. Kuo, Sepulveda, Calif (case 5); C. V. Ramos, St Louis (case 6); R. J. Reed, New Orleans (case 1); W. Sandritter, Freiburg, West Germany (case 8); J. J. Segura F., San José, Costa Rica (case 10); C. Sinclair-Smith, Cape Town, South Africa (case 4); M. A. South, Philadelphia (case 7); N. Tanaka, Tokyo (case 2); A. J. M. v. Unnik, 's-Hertogenbosch, Netherlands (case 3); and C. L. Witzleben, Philadelphia (case 7).

References

1. Rosai J, Dorfman RF: Sinus histiocytosis with massive lymph-adenopathy: A newly recognized benign clinicopathological entity. *Arch Pathol* 87:63-70, 1969.

2. Rosai J, Dorfman RF: Sinus histiocytosis with massive lymph-adenopathy: A pseudolymphomatous benign disorder. Analysis of 34 cases. *Cancer* 30:1174-1188, 1972.

3. A new lymphoma syndrome, editorial. *Lancet* 1:139-140, 1973.

4. Lampert F, Lennert K: Sinus histiocytosis with massive lymphadenopathy: Fifteen new cases. *Cancer* 37:783-789, 1976.

5. Becroft DMO, Dix MR, Gillman JC, et al: Benign sinus histiocytosis with massive lymphadenopathy: Transient immunological defects in a child with mediastinal involvement. *J Clin Pathol* 26:463-469, 1973.

6. Lever WF, Schaumburg-Lever G: *Histopathology of the Skin* ed 5. Philadelphia, JB Lippincott Co, 1975, pp 570-574, 361-367, 284-288.

7. Waldorf DS, Levy RI, Fredrickson DS: Cutaneous cholesterol ester deposition in Tangier disease. *Arch Dermatol* 95:161-165, 1967.

8. Dorfman RF, Warnke R: Lymphadenopathy simulating the malignant lymphomas. *Hum Pathol* 5:519-550, 1974.

9. Nezelof C, Basset F, Rousseau MF: Histiocytosis X: Histogenetic arguments for a Langerhans cell origin. *Biomedicine* 18:365-371, 1973.

10. Orkin M, Goltz RW, Good RA, et al: A study of multicentric reticulohistiocytosis. *Arch Dermatol* 89:640-654, 1964.

11. Helwig EB, Hackney VC: Juvenile xanthogranuloma (nevoxanthoendothelioma). *Am J Pathol* 30:625-626, 1954.

12. Variakojis D, Strum SD, Rappaport H: The foamy macrophages in Hodgkin's disease. *Arch Pathol* 93:453-456, 1972.

Apocrine Gland Adenoma and Adenocarcinoma of the Axilla

Lt Col Raphael L. Warkel, MC, USAR, Elson B. Helwig, MD

• Apocrine tumors from the axilla of 12 patients were studied clinically and pathologically. Based on histologic features, two tumors were classified as adenomas and ten as adenocarcinomas. All of the neoplasms were characterized by a glandular arrangement of large cells with abundant eosinophilic cytoplasm and evidence of decapitation secretion. The cytoplasm of the tumor cells contained PAS-positive, diastase-resistant granules. Intracytoplasmic particles of iron were demonstrable in three of ten tumors. Follow-up was available for all 12 patients. The two patients with apocrine adenoma are alive and well. Two patients with adenocarcinoma died of unrelated causes shortly after diagnosis. Of the remaining eight patients with adenocarcinoma, three have died of disease, and one is living with skeletal metastasis. A correlation appears to exist between tumor differentiation and prognosis.

(*Arch Dermatol* 114:198-203, 1978)

Tumors of the apocrine gland have a rather distinctive histologic appearance but often are categorized nonspecifically by pathologists. Consequently, they are usually reported to clinicians as variants of sweat gland tumor, with—at best—a qualification that they have apocrine features. Part of the explanation for this situation is the rarity of apocrine gland adenomas and adenocarcinomas and their frequent inclusion in the literature under the general heading "sweat gland tumors." Baes and Suurmond[1] reviewed the literature up to 1970 and were able to find only 18 cases of apocrine gland carcinoma.

The purpose of this report is to describe the clinical and pathologic features of 12 tumors of apocrine gland type. To provide the most homogeneous and representative picture of apocrine gland neoplasia, this study has been limited to tumors that arose in the axilla, the principal site of concentration of apocrine glands in the body. Comments will also be made about a few tumors that arose in areas other than the axilla.

MATERIALS AND METHODS

Two adenomas and ten adenocarcinomas were selected for study from the files of the Armed Forces Institute of Pathology (AFIP), which includes cases from military, Veterans Administration, and civilian sources. Clinical data were obtained from clinical records, surgical pathology reports, and follow-up questionnaires.

Hematoxylin-eosin-stained sections were examined in all cases. Sections prepared by the following special staining techniques were also available in many cases: PAS preparation with and without diastase digestion, Mowry's colloidal iron with and without hyaluronidase digestion, Mallory's iron stain, alcian blue at pH 2.5 and 0.4, aldehyde-fuchsin at pH 1.7 and 1.0, mucicarmine, the AFIP method for lipofuscin, Movat's pentachrome, and phosphotungstic acid-hematoxylin (PTAH).[2]

RESULTS

Clinical Features

The neoplasms did not show distinctive clinical findings that would allow a clinician to suspect the diagnosis preoperatively. They appeared as a single or multinodular firm, rubbery, or cystic mass. The overlying skin was red to purple and occasionally was ulcerated. The tumors ranged from 1.5 to 8.0 cm in diameter. Most had a duration of one year or less, although one tumor had been present for 30 years. They often produced discomfort but were usually not painful. Six tumors were located in the left axilla, four in the right axilla, and in two patients the side was unknown.

The age of the patients ranged from 25 to 91 years, the mean being 57.9 years. The tumors were most common in the sixth decade. Only two patients were less than 40 years old. Eight patients were men, and four were women. Excluding military and VA cases, the man-to-woman ratio was 5:4. Seven patients (four men and three women) were white, and four (all men) were black. The race of one woman was unknown.

Pathologic Features

Gross Observations.—The tumors were red or reddish brown. Most were firm and solid, but cystic foci and hemorrhage were sometimes noted. All but one appeared to involve the superficial dermis. The exception was located primarily in the subcutaneous tissue, and at surgical operation it appeared to "shell out."

Histologic Observations.—Two tumors were classified as adenomas; ten as adenocarcinomas. Both adenomas were confined to the upper dermis and mid-dermis and had a similar histologic appearance. They were composed of lobules that showed a complex glandular arrangement with occasional papillary formations (Fig 1). Large glandular lumina were a prominent feature. The glands were lined by a single layer of medium to large cells with abundant eosinophilic cytoplasm. The nuclei were uniform, small, and vesicular. Nucleoli were not prominent. Mitotic figures were rare, and there was minimal pleomorphism and hyperchromasia. Bud-like cytoplasmic projections that constituted decapitation secretion were evident on the luminal borders of many cells. In one adenoma there was a transition between the normal apocrine secretory coils and the tumor. Neither tumor was encapsulated, although one was partially surrounded by fibrous tissue. A few scattered lymphocytes occupied the stroma.

The adenocarcinomas showed marked variation in histologic pattern, not only within a single tumor but also among the different tumors. Most lesions involved only the dermis, but some extended into the epidermis and subcutaneous tissue. One was confined to the subcutaneous tissue. In the uppermost portion of the lesion, closest to the epidermis, the glands had the widest lumina, the most prom-

Accepted for publication Sept 22, 1977.

From the Department of Skin and Gastrointestinal Pathology, Armed Forces Institute of Pathology, Washington, DC.

The opinions or assertions contained herein are the private views of the authors and are not to be construed as official or as reflecting the views of the Department of the Army or the Department of Defense.

Reprint requests to Armed Forces Institute of Pathology, Washington, DC 20306 (Dr Helwig).

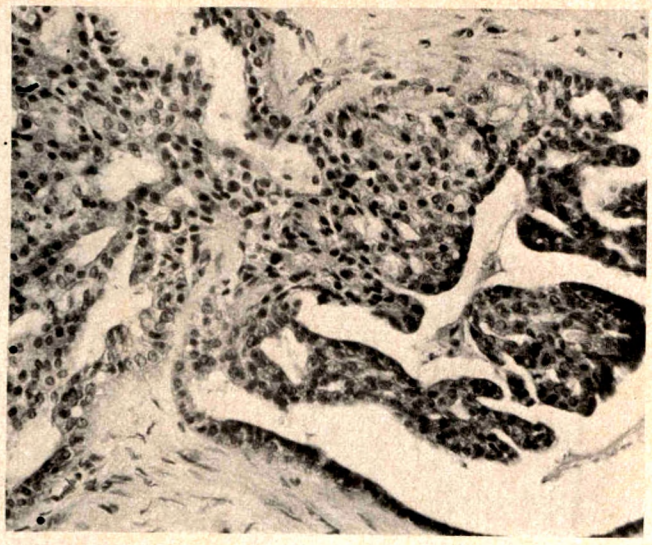

Fig 1.—Apocrine adenoma showing adenomatous and papillary areas (AFIP Neg 77-4439; hematoxylin-eosin, ×210).

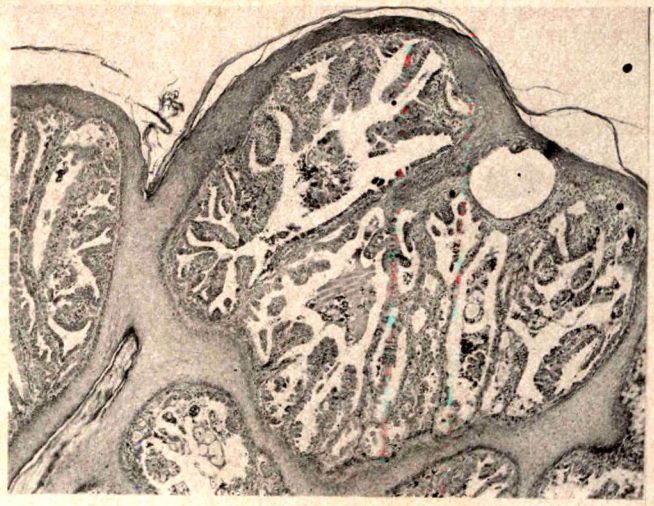

Fig 2.—Subepidermal region of moderately differentiated apocrine adenocarcinoma showing dilated glands with intraluminal papillary projections (AFIP Neg 77-1785; hematoxylin-eosin, ×50).

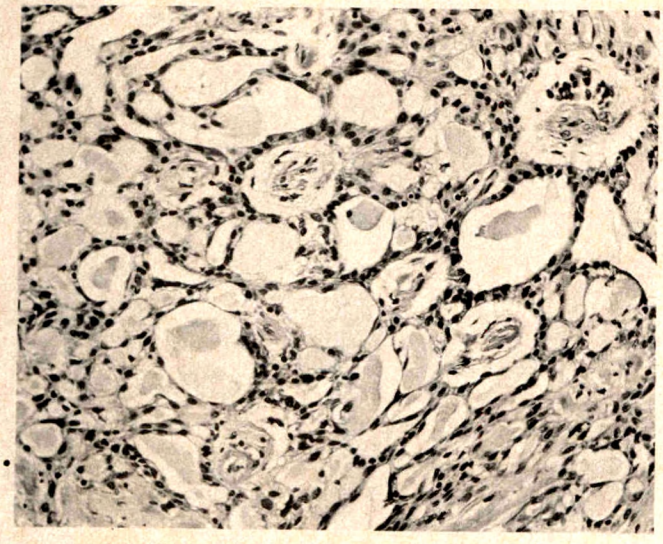

Fig 3.—Well-differentiated apocrine adenocarcinoma showing cells with uniform nuclei arranged in glandular pattern (AFIP Neg 77-4442; hematoxylin-eosin, ×180).

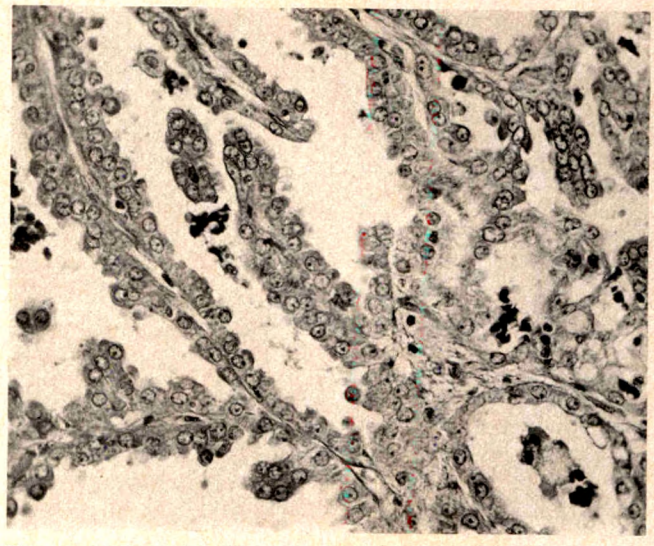

Fig 4.—Moderately differentiated apocrine adenocarcinoma showing primarily glandular histologic pattern with some papillary features (AFIP Neg 77-1787; hematoxylin-eosin, ×300).

inent papillary projections, and usually the greatest resemblance to normal apocrine glands (Fig 2). Histologic patterns included papillary (Fig 2), complex glandular (Fig 3 and 4), anastomosing tubular (Fig 5), solid cellular sheets, and cord-like infiltrations with desmoplasia (Fig 6). A transition between normal apocrine structures and neoplasm was demonstrable in two cases. In one case the glands in the transitional zone appeared hyperplastic (Fig 7). Normal apocrine glands were found in the immediate vicinity of the tumor in six other cases.

Dense lymphocytic infiltrates were noted at the periphery of several lesions. The stroma of eight of the ten adenocarcinomas contained prominent focal collections of plasma cells. None of the tumors were encapsulated. Many showed fibrosis or hyalinization, and foci of necrosis and hemorrhage were occasionally found.

Features present in all the adenocarcinomas were abundant homogeneous or granular eosinophilic cytoplasm and at least some glands that showed pinched-off cytoplasmic projections that resembled the decapitation secretion of normal apocrine glands (Fig 8). Nuclei were vesicular with prominent nucleoli. Pleomorphism and hyperchromasia were present to a variable extent. Mitotic figures were rare in some cases and numbered up to four per high-power field in others. All the tumors showed evidence of stromal invasion except one tumor in which the atypical cells were confined to large, widely spaced glandular structures. A combination of histologic features, including the degree of pleomorphism, hyperchromasia and mitotic activity, and the presence or absence of stromal invasion, were used to separate adenocarcinomas from adenomas.

Lymph nodes were included in two of the surgical specimens. In one specimen the lymph nodes contained metastatic tumor. This was the only example in which evidence of vascular or lymphatic invasion was identified. Material from local recurrences was available in two cases. One tumor recurred five months after initial excision and was morphologically identical to the original. The other

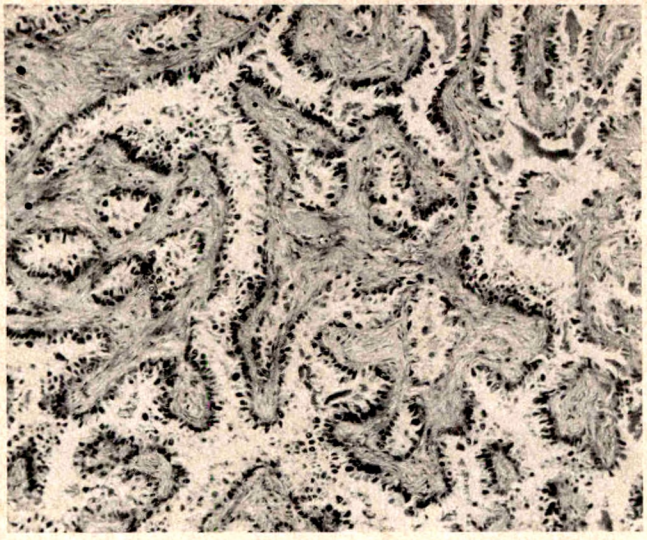

Fig 5.—Poorly differentiated apocrine adenocarcinoma showing anastomosing tubular histologic pattern (AFIP Neg 77-1790; hematoxylin-eosin, ×80).

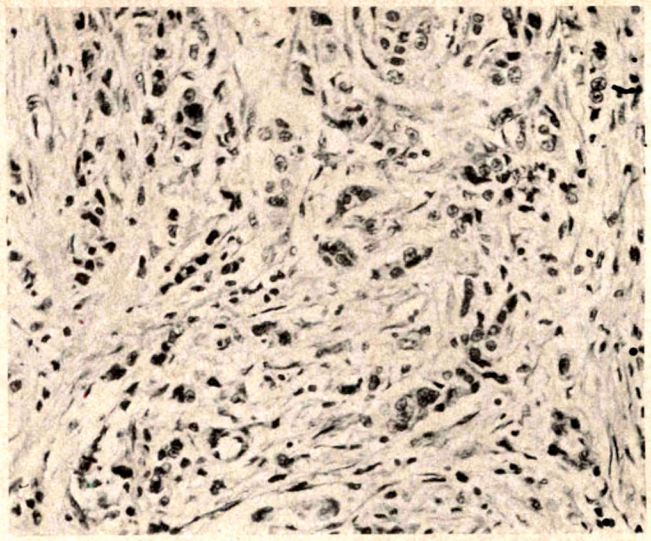

Fig 6.—Poorly differentiated apocrine adenocarcinoma showing area of linearly infiltrating pleomorphic tumor cells with stromal desmoplasia (AFIP Neg 77-2959; hematoxylin-eosin, ×300).

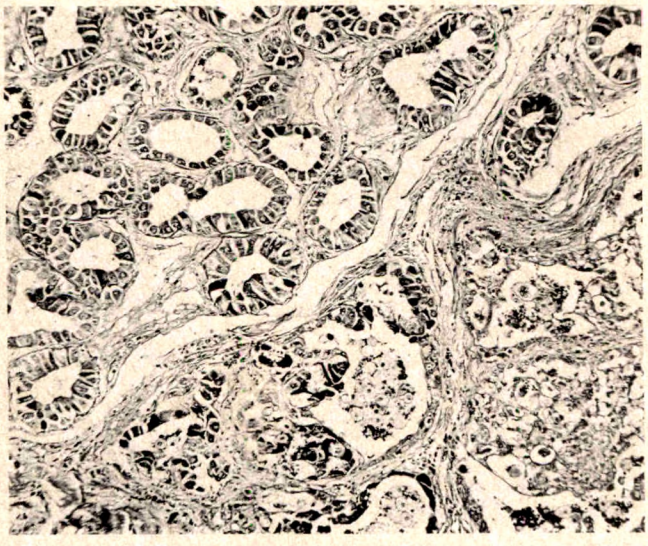

Fig 7.—Transitional zone of moderately differentiated apocrine adenocarcinoma. Hyperplastic, but otherwise normal, apocrine glands at upper left are becoming frankly neoplastic at center (AFIP Neg 77-4444; hematoxylin-eosin, ×100).

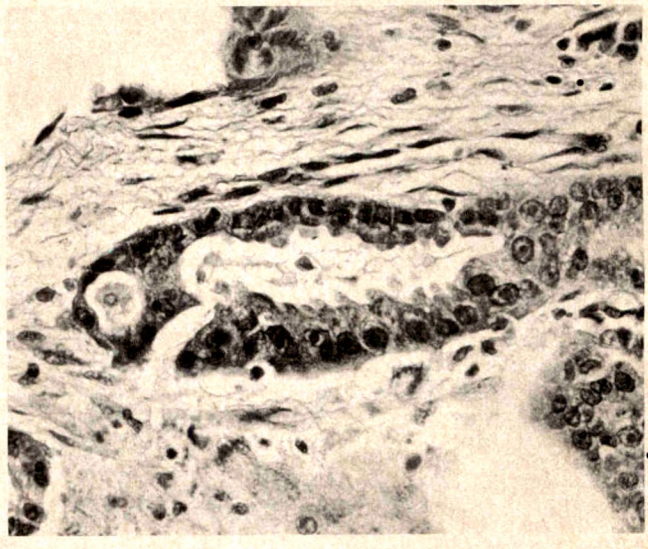

Fig 8.—Decapitation secretion in apocrine adenocarcinoma. This is well-differentiated area from same case shown in Fig 6 that was classified as poorly differentiated (AFIP Neg 77-2960; hematoxylin-eosin, ×395).

recurred ten years after the initial excision and showed considerably more disorganization and cytologic atypia.

Histochemical Observations.—The cytoplasm in all of the neoplasms studied contained PAS-positive, diastase-resistant granules (Fig 9). A moderate amount of mucin was present focally in glandular lumina and as small intracytoplasmic vacuoles. It had staining characteristics similar to the mucin encountered in normal or metaplastic apocrine glands.[3,4] Iron-positive intracytoplasmic granules were demonstrable in the tumor cells of three of the ten specimens. Acid-fastness, a property of lipofuscin, was present as fine intracellular particles in one of six cases. Tumors examined by the PTAH stain failed to show evidence of myoepithelial cells.

Follow-up

Follow-up information was available for all 12 patients. The two patients with adenoma are alive and well, three and four years, respectively, after diagnosis. One patient with carcinoma died of a myocardial infarction 15 days after radical axillary dissection. Another died of a cerebrovascular accident four months after excision. One patient developed a recurrence with metastasis to lymph nodes five months after initial excision and is now living 1½ years after initial excision with radiologic evidence of skeletal metastasis. Three patients had succumbed to their disease at periods of 2 months, 2 years, and 11 years, respectively, after diagnosis. Although autopsies were not performed, death was considered clinically to be due to metastatic adenocarcinoma. The patient who survived two months had metastatic foci in the regional lymph nodes at the time of surgical excision. The patient who survived 11 years had remained free of disease for ten years. The remaining four patients are living and well. One has survived 15 years without any further evidence of disease, but the follow-up interval is short for the others—less than three years.

Fig 9.—Diastase-resistant, PAS-positive intracytoplasmic granules (dark) in moderately differentiated apocrine adenocarcinoma (AFIP Neg 77-4853; PAS, ×115). Inset, Granules at higher magnification (PAS, ×900).

Clinicopathologic Correlation

To determine if there is a relationship between tumor differentiation and clinical behavior, the adenocarcinomas were divided into three histologic groups: well, moderately, and poorly differentiated. The grouping was based on an assessment of the degree of cellular atypicality, structural disorganization, and mitotic activity manifested by the neoplasms. Those lesions that showed slight nuclear pleomorphism and hyperchromasia, few mitotic figures, and a well-developed glandular pattern with little nuclear stratification were considered well differentiated (Fig 3 and 8). The poorly differentiated group showed marked pleomorphism and hyperchromasia with frequent mitotic figures and often an infiltrating growth pattern that was composed of cords of cells or bizarre glandular formations (Fig 5 and 6). Those lesions with histologic features between these extremes were regarded as being of intermediate differentiation (Fig 2, 4, 7, and 9). Tumors with mixed patterns were classified according to their least differentiated areas.

The results of the correlation of these three histologic groups with subsequent clinical behavior is presented in Table 1. The two patients who died from other causes too soon after treatment for follow-up to be meaningful were excluded. The follow-up intervals were somewhat short for the two patients with well-differentiated tumors, two years in one case and three in the other. Follow-up was only seven months for the patient who is alive and well with a neoplasm of moderate differentiation. Nonetheless, the data in Table 1 suggest that there may be a correlation between tumor differentiation and prognosis.

COMMENT

Gates and associates[5] reported the first large series of sweat gland tumors, but they did not distinguish between tumors of apocrine origin and those of eccrine origin. More recently, a larger series of sweat gland tumors was described by McDivitt and Berg[6] and partially updated by El-Domeiri et al.[7] McDivitt and Berg[6] classified six of their 102 tumors as malignant papillary hidradenomas. The histochemical findings in this group were not compatible with an apocrine origin, and therefore, we are uncertain of their nature. The only other report of more than two cases of apocrine gland carcinoma is that of Stout and Cooley.[8] Unfortunately, it is not completely clear which tumors the authors considered to be gland neoplasms. Based on their descriptions and photomicrographs, we believe five are apocrine, including three from the axilla. McDonald[9] classified a group of sweat gland tumors of the vulva as apocrine adenocarcinomas, but all 30 cases that he described were examples of hidradenoma papilliferum.

Baes and Suurmond[1] presented a case of apocrine adenocarcinoma of the chest and reviewed the literature up to 1970. They were able to find 18 cases that they believed represented apocrine adenocarcinoma. In this group are included an adenocarcinoma of Moll's glands[8] and two examples of extramammary Paget's disease.[10,11] Also, several of the cases do not contain sufficient descriptions or photographs of the histologic features of the tumors to be certain of their apocrine nature.[12-15] Nine cases of apocrine adenocarcinoma of the axilla have been reported.[8,16-21] The salient features of these cases are outlined in Table 2.

We were unable to find reports of apocrine adenoma in the literature, but several authors[22,23] mentioned that apocrine adenomas can occur in the axilla and are often confused with adenocarcinoma. Recently, two cases of an unusual apocrine adenoma composed almost exclusively of tubular structures have been reported.[24,25] Both adenomas were located on the scalp and were associated with an organoid epidermal nevus.

The absence of any patient less than 25 years old in this series suggests that these tumors do not develop until after the apocrine glands have achieved full maturity, usually about the time of puberty. To our knowledge, the youngest patients with apocrine carcinomas were two adolescent girls whose cases were reported by Futrell et al.[26] The average age of 57.9 years in our series of patients is slightly older than the average age in most series of patients with all types of sweat gland carcinoma[8,27] and is also higher than the average age of 53.1 for the patients with axillary apocrine adenocarcinoma described in the literature (Table 2).

Reports of sweat gland carcinoma have emphasized a long duration of illness from either the presence of a mass for many years prior to excision or from a protracted course subsequently.[7,8,27] Several of the tumors listed in Table 2 had been present for many years prior to their removal. One of our patients had a mass in his axilla for 30 years prior to excision. Another patient was free of disease for ten years before developing a recurrence, which led to death one year later. The remaining patients whose duration of symptoms were known, however, had been aware of a mass for one year or less, and the two other patients who died of metastatic

disease had short survivals.

The axillary sweat glands are better developed and more numerous in women and black people.[28] Even after excluding military sources, men slightly outnumbered women in this series. Four of the 12 patients were black, which suggests that race could be a factor in the histogenesis of apocrine neoplasms. Sarrat et al[29] noted a high incidence of apocrine carcinomas in West African Negroes. Futrell et al[20] reported a case of two primary apocrine adenocarcinomas, one in the eyelid and one in the axilla, arising in a black woman. One of the three cases of axillary apocrine adenocarcinoma reported by Stout and Cooley[8] occurred in a black woman. They also reported a tumor located on the arm between the axilla and the elbow in a black man. The acceptable cases of apocrine gland adenomas and adenocarcinomas recorded in the literature are too few, however, to form definite conclusions about racial prevalence.

Table 1.—Correlation of Survival With Tumor Differentiation for Eight Apocrine Adenocarcinomas of Axilla

Degree of Tumor Differentiation	No. of Cases	Status: Alive and Well	Status: Alive With Metastasis	Status: Died of Tumor
Well-differentiated	2	2	0	0
Moderately differentiated	3	1	1	1
Poorly differentiated	3	1	0	2
Total	**8**	**4**	**1**	**3**

Table 2.—Features of Nine Cases of Apocrine Adenocarcinoma of Axilla From Literature

Source, yr	Patient: Age, yr/Sex/Race	Duration of Tumor Prior to Removal	Lymph Node Involvement	Course
Moriconi,[18] 1931	59/M/...	6 mo	Yes	Alive and well, 5 yr
Stout and Cooley,[8] 1951				
Case 4	48/F/B	1 yr	Yes	Recurred, 1½ mo after removal
Case 9	47/F/W	10 yr	No	No information
Case 11	63/F/W	30 yr	No	Alive and well, 7 yr 8 mo
Ackerman,[17] 1953	.../M/...	...	...	Recurred; patient died several years after onset
Elliott and Ramsey,[18] 1956	64/M/...	4 yr	Yes	Alive and well, 2 yr
Kipkie and Haust,[19] 1958	28/M/W	"Some time"	No	Recurred, 8 mo
Futrell et al,[20] 1971	64/F/B	...	Yes	Alive and well, 2 yr
Saigal et al,[21] 1971	52/F/...	12 yr	No	...

Differential Diagnosis

We believe that the apocrine derivation of the following tumors is now firmly established:

Classification of Cutaneous Apocrine Neoplasms

Benign
1. Apocrine adenoma
2. Hidradenoma papilliferum
3. Apocrine hidrocystoma (cystadenoma)
4. Ceruminoma

Malignant
1. Apocrine adenocarcinoma
2. Ceruminoma
3. Adenocarcinoma of Moll's glands

We consider the apocrine adenoma and adenocarcinoma to be the prototypes of apocrine gland neoplasia because, of all the apocrine neoplasms, they most closely resemble the secretory portion of the apocrine gland and are not necessarily limited to a specific anatomic site. Most examples, particularly the adenocarcinomas, do arise in the axilla, but this is expected because the axilla is the principal site of apocrine gland concentration in the body. In addition to the axilla, we have found adenomas on the face, trunk, and anogenital region. Excluding ceruminomas and adenocarcinomas of Moll's glands, our files contain two adenocarcinomas from areas other than the axilla. Both were located on the scalp, and one was associated with a nevus sebaceus. Other sites from which apocrine tumors have been reported are the chest,[1] nipple,[8] arm,[8] wrist,[30] and foot.[26]

The apocrine derivation of hidradenoma papilliferum is well accepted.[31,32] It is a variant of apocrine adenoma that is found only in the anogenital region of women (almost invariably white women).[31] Since apocrine glands are most frequent in both women and black people,[28] it is puzzling why hidradenoma papilliferum is so rare in black people.

Mehregan[33] regarded apocrine hidrocystoma (cystadenoma) as a true tumor rather than a cyst. Smith and Chernosky[34] accepted those hidrocytomas with papillary projections into the cystic cavity as tumors but regarded those lesions lacking this feature as retention cysts. Apocrine hidracystoma is usually found on the face, scalp, or ears. Only six cases have been reported at other sites: two on the prepuce[35] and four on the trunk.[34,36,37] We have seen a lesion in the axilla in which the lining cells showed decapitation secretion, but intraluminal papillary projections were absent.

Ceruminoma and adenocarcinoma of Moll's glands of the eyelid represent neoplasms derived from specialized apocrine glands of specific anatomic locations. Ceruminomas are derived from the apocrine ceruminous glands of the external auditory canal. They vary considerably in histologic pattern and may be benign or malignant.[38,39] Apocrine adenocarcinoma of Moll's glands of the eyelid is a rare neoplasm that is virtually identical morphologically to apocrine adenocarcinoma of the axilla.[40]

Extramammary Paget's disease has been omitted from the previous classification of tumors of apocrine derivation. Although we favor involvement of apocrine structures for most of these lesions,[41] it is possible that some examples may show eccrine involvement. Also omitted from the classification were chondroid syringoma, syringocystadenoma papilliferum, and cylindroma; these are benign neoplasms of sweat gland origin, and their exact histogenesis remains controversial.

Microscopically, it may be difficult to separate apocrine tumors from sweat gland neoplasms of eccrine derivation. A combination of histologic features must be relied on. Abundant eosinophilic cytoplasm and glands with large lumina are usually found in apocrine gland adenoma and

adenocarcinomas but are not specific. Cytoplasmic protrusions that resemble decapitation secretion may occasionally be found in nonapocrine neoplasms, but many glands lined by cells that show well-developed decapitation secretion definitely favor an apocrine origin. A transitional zone between normal apocrine glands and tumor confirms an apocrine derivation, but unfortunately this is not often demonstrable.

An iron stain and a PAS stain, with and without diastase preparation, should be applied to all sweat gland neoplasms. Apocrine tumors will show prominent PAS-positive, diastase-resistant intracytoplasmic granules that resemble those seen in normal apocrine glands. In contrast to eccrine tumors, glycogen is virtually absent in apocrine adenoma and adenocarcinoma. Kipkie and Haust[19] required the presence of intracellular iron for the diagnosis of an apocrine tumor. Iron was demonstrable in three of ten of our cases, and although its presence is highly specific, its absence does not exclude the diagnosis. Enzyme studies, if fresh-frozen tissue is available, may be useful.[1,24,42]

Primary apocrine sweat gland adenocarcinoma of the axilla must also be distinguished from metastatic apocrine adenocarcinoma of the breast and from apocrine adenocarcinoma that arises in an axillary prolongation or in ectopic breast. Most patients with metastatic axillary neoplasms will show evidence of disease of the breast after careful clinical investigation. An occult primary would be unusual. Neoplasms that arise in ectopic breast or in an axillary extension may be associated with normal mammary structures or foci of typical intraductal breast carcinoma. Features that favor a primary carcinoma derived from the apocrine glands of the axilla are the presence of relatively mature neoplastic glands high in the dermis, a transitional zone with normal apocrine glands, and the demonstration of intracytoplasmic granules of iron. Frable and Kay[43] did not find iron in any of their cases of apocrine carcinoma of the breast.

Treatment and Prognosis

Follow-up of our cases demonstrated that apocrine adenocarcinomas are similar to other sweat gland carcinomas in their capability for aggressive behavior.[6,7,27] McDivitt and Berg[6] and El-Domeiri and his associates[7] found a correlation between the degree of cellular anaplasia and the ultimate prognosis of sweat gland carcinomas. Although the number of cases in our series is small, and the follow-up intervals are short, the findings (Table 1) suggest that such a correlation also exists for apocrine adenocarcinomas. El-Domeiri et al[7] recommend that extremely well-differentiated sweat gland carcinomas be treated by wide surgical excision alone and that less differentiated tumors be treated by wide local excision and regional lymph node dissection. This therapeutic approach also seems appropriate for apocrine adenocarcinomas.

The effort to distinguish apocrine from eccrine sweat gland tumors is potentially worthwhile. Only if sufficient numbers of sweat gland tumors are separated into groups based on apocrine or eccrine origin and thoroughly analyzed will it be possible to appreciate differences that may have therapeutic or prognostic significance.

References

1. Baes H, Suurmond D: Apocrine sweat gland carcinoma: Report of a case. *Br J Dermatol* 83:483-486, 1970.
2. Luna LE (ed): *Manual of Histologic Staining Methods of the Armed Forces Institute of Pathology*, ed 3. New York, McGraw-Hill Book Co Inc, 1968.
3. Winkelmann RK, Hultin JV: Mucinous metaplasia in normal apocrine glands. *Arch Dermatol* 78:309-313, 1958.
4. Johnson WC, Helwig EB: Histochemistry of the acid mucopolysaccharides of skin in normal and certain pathologic conditions. *Am J Clin Pathol* 40:123-131, 1963.
5. Gates O, Warren S, Warvin WN: Tumors of sweat glands. *Am J Pathol* 19:591-631, 1943.
6. McDivitt RW, Berg JW: Pathology of sweat gland carcinoma, in Sommers SC (ed): *Pathology Annual*, vol 3. New York, Appleton-Century-Crofts, 1968, pp 123-144.
7. El-Domeiri AA, Brasfield RD, Huvos AG, et al: Sweat gland carcinoma: A clinico-pathologic study of 83 patients. *Ann Surg* 173:270-274, 1971.
8. Stout AP, Cooley SGE: Carcinoma of sweat glands. *Cancer* 4:521-535, 1951.
9. McDonald JR: Apocrine sweat gland carcinoma of the vulva. *Am J Clin Pathol* 11:890-897, 1941.
10. Sekiguchi S: Studies on Paget's disease of the nipple and its extramammary occurrence: Reports on 18 cases personally investigated. *Ann Surg* 65:175-198, 1917.
11. Weiner HA: Paget's disease of the skin and its relation to carcinoma of the apocrine sweat glands. *Am J Cancer* 31:373-403, 1937.
12. Hedinger E: Zur Frage des Plasmocytoms (Granulationsplasmocytom in Kombination mit einem krebsig ungewandelten Schweissdrüsenadenom des behaarten Kopfes). *Frankfurt Z Pathol* 7:343-350, 1911.
13. Hufschmitt G, Diss A: Epithélioma sudoripare. *Bull Soc Fr Dermatol Syphilol* 36:503-504, 1929.
14. Eichenberg HE: Hidradenoma vulvae. *Z Geburtshilfe Gynaekol* 109:358-373, 1934.
15. Smith CCK: Metastasizing carcinoma of the sweat-glands. *Br J Surg* 43:80-84, 1955.
16. Moriconi L: Adenocarcinoma delle ghiandole sudoripare. *Policlinico* 38:634-642, 1931.
17. Ackerman LV: *Surgical Pathology*. St Louis, CV Mosby Co, 1953, p 93.
18. Elliott GB, Ramsey DW: Sweat gland carcinoma. *Ann Surg* 144:99-106, 1956.
19. Kipkie GF, Haust MD: Carcinoma of apocrine glands. *Arch Dermatol* 78:440-445, 1958.
20. Futrell JW, Krueger GR, Chretien PB, et al: Multiple primary sweat gland carcinomas. *Cancer* 28:686-691, 1971.
21. Saigal RK, Khanna SD, Chander J: Apocrine gland carcinoma in axilla: Report of a case. *Indian J Dermatol* 37:177-180, 1971.
22. Telon HA: Apocrine adenoma of the anus. *Cancer* 7:367-372, 1954.
23. Kersting DW: Apocrine gland adenoma and adenocarcinoma, in Graham JH, Johnson WC, Helwig EB (eds): *Dermal Pathology*. New York, Harper & Row Publishers Inc, 1972, p 526.
24. Landry M, Winkelmann RK: An unusual tubular adenoma: Histochemical and ultrastructural study. *Arch Dermatol* 105:869-879, 1972.
25. Umbert P, Winkelmann RK: Tubular apocrine adenoma. *J Cutan Pathol* 3:75-87, 1976.
26. Futrell JW, Krueger GR, Morton DL, et al: Carcinoma of sweat gland in adolescents. *Am J Surg* 123:594-597, 1972.
27. Miller WL: Sweat-gland carcinoma: A clinicopathologic problem. *Am J Clin Pathol* 47:767-780, 1967
28. Homma H: On apocrine sweatglands in white and Negro men and women. *Bull Johns Hopkins Hosp* 38:365-371, 1926.
29. Sarrat H, Camain R, Grosshans E: Tumeurs des annexes de la peau chez le noir de l'Ouest Africain. *Int J Dermatol* 13:139-148, 1974.
30. Horn RC Jr: Malignant papillary cystadenoma of sweat glands with metastases to the regional lymph nodes. *Surgery* 16:348-355, 1944.
31. Meeker JH, Neubecker RD, Helwig EB: Hidradenoma papilliferum. *Am J Clin Pathol* 37:182-195, 1962.
32. Hashimoto K: Hidradenoma papilliferum: An electron microscopic study. *Acta Derm Venereol* 53:22-30, 1973.
33. Mehregan AH: Apocrine cystadenoma: A clincopathologic study with special reference to the pigmented variety. *Arch Dermatol* 90:274-279, 1961.
34. Smith JD, Chernosky ME: Apocrine hidrocystoma (cystadenoma). *Arch Dermatol* 109:700-702, 1974.
35. Ahmed A, Jones AW: Apocrine cystadenoma: A report of two cases occurring on the prepuce. *Br J Dermatol* 81:899-901, 1969.
36. Holder WR, Smith JD, Mocega EE: Giant apocrine hidrocystoma. *Arch Dermatol* 104:522-523, 1971.
37. Benisch B, Peison B: Apocrine hidrocystoma of the shoulder. *Arch Dermatol* 113:71-72, 1977.
38. Neldner KH: Ceruminoma. *Arch Dermatol* 98:344-348, 1968.
39. Wetli CV, Pardo V, Millard M, et al: Tumors of ceruminous glands. *Cancer* 29:1169-1178, 1972.
40. Aurora AL, Luxenberg MN: Case report of adenocarcinoma of glands of Moll. *Am J Ophthalmol* 70:984-990, 1970.
41. Helwig EB, Graham JH: Anogenital (extramammary) Paget's disease: A clinicopathological study. *Cancer* 16:387-403, 1963.
42. Hashimoto K, Lever WF: *Appendage Tumors of the Skin*. Springfield, Ill, Charles C Thomas Publisher, 1968.
43. Frable WJ, Kay S: Carcinoma of the breast: Histologic and clinical features of apocrine tumors. *Cancer* 21:756-763, 1968.

Mycetomas Caused by *Streptomyces pelletieri* in Madras, India

Venugopal V. Taralakshmi, MD(Path); V. Venugopal Pankajalakshmi, MD(Bact); Rangaraj Kamalakannan, MB,BS; Ruth Annamalai, MD, MD(Dermatol); Brahmayar M. V. Shetty, MD(Path); Sundaram Subramanian, MD, DBact(Lond); Trichirapalli K. Shanmugasundaram, MS, MCh, FRCS

• Biopsy specimens from 93 patients with mycetoma were examined histologically; *Streptomyces pelletieri* was found in 12 cases. In addition, two cases of actinomycetoma pedis in which *S pelletieri* has been isolated in culture are described. In both, the characteristic red granules were seen.

(*Arch Dermatol* 114:204-206, 1978)

Mycetomas caused by *Streptomyces pelletieri* are common in Africa, but reports are rare from other countries. The first authenticated report of this disease caused by *S pelletieri* in India was by Klokke et al[1] in 1968; Table 1 summarizes subsequent reports from India on this disease.[2-6]

In this article we report 14 additional cases from Madras of mycetoma caused by *S pelletieri*. In two cases, the causative agent has been isolated in culture.

MATERIALS AND METHODS

The material was obtained from the collection of the Department of Pathology, Madras (India) Medical College, for the years 1964 to 1976. Paraffin blocks were resectioned, stained with hematoxylin-eosin, and reclassified according to the morphologic appearance of the granules. All sections of actinomycotic mycetomas were further stained by Brown and Brenn's modification of Gram and Kinyoun's acid-fast methods.

Of 93 cases of mycetoma examined histologically, 12 were found to be due to *S pelletieri*. All cases were in males, the majority in the 11- to 30-year age group. In ten cases, the lesion was localized in the foot, but the thigh and the leg were involved in the other two cases.

REPORT OF CASES

CASE 1.—A 22-year-old Tamilian student from Gummidipundi, Madras State, was admitted to the Department of Orthopedics, Stanley Medical College and Hospital, Madras, on June 22, 1974. About a year prior to admission he had had a minor bicycle accident; multiple small abrasions were present over exposed parts of the body. A few months later, he noticed a small, painless nodule at the middle third of the leg that softened, burst open, and discharged purulent material. Gradually, multiple nodules developed and fused to form sinuses that discharged seropurulent fluid.

Examination disclosed multiple cauliflower-like growths on the lower two thirds of the left leg and foot, with multiple sinuses. The tibia was thickened and tender. Movements at the ankle joint were restricted with pain. A large, hard gland was present in the left inguinal region. Roentgenogram of the left leg and foot showed thickening of the entire lower two thirds of the shaft of the tibia, with areas of rarification and new bone formation (Fig 1). Osteoporosis with areas of destruction were seen in the foot.

CASE 2.—A 40-year-old Tamilian laborer from Madurai was admitted to the Department of Dermatology, Government General Hospital, Madras, on Jan 21, 1975, for pain and swelling of the right ankle. He gave a history of having injured his right ankle while bicycling two years earlier. The wound failed to heal; a few months later, a small nodule developed at the site of the injury that softened down and formed a sinus discharging seropurulent material. Multiple nodules slowly developed on the ankle, ulcerating and discharging serosanguinous fluid.

Clinical examination disclosed a swelling in the region of the right ankle. There were ten sinuses, almost dry, present over the medial side of the ankle, below and behind the medial malleolus. The inguinal lymph nodes were enlarged on both sides.

Roentgenogram of the ankle showed a soft tissue swelling and demineralization of all the bones.

Histopathological Study

Both cases showed granules conforming to the description of *S pelletieri* (Fig 2 and 3). They were small, with denticulate edge, without clubs, and their homogenous matrix stained intensely with hematoxylin. Gram stain did not show the mycelial fragments very clearly, and the granules were not acid-fast by Kinyoun's acid-fast method. The cellular reaction was also characteristic for the actinomycete in that most of the granules were in the center of very large abscess cavities, with an intense, polymorphonuclear leukocytic and lymphocytic infiltration and very little fibrosis. Giant cells were characteristically absent.

The inguinal lymph node biopsy specimen from patient 1 showed only evidence of chronic inflammation. The granules of *S pelletieri* were not seen even after serial sectioning.

Mycologic Study

The serosanguinous fluid from patient 1 and the biopsy specimens from both patients had numerous small, soft, red granules, less than 1 mm in size. When these granules were crushed and examined, the smears in each instance showed thin, delicate, long-branching, Gram-positive filaments that were not acid-fast.

Growth was very slow; the colony appeared after six weeks of incubation in the first case and after four weeks of incubation in the second case. The colonies were irregularly folded, and coral red. Growth was much better at 37 C. The organisms hydrolyzed casein, decomposed tyrosine crystals, and liquified gelatin, but failed to decompose xanthine or to utilize

Accepted for publication July 27, 1977.

From the Departments of Pathology (Drs Taralakshmi and Shetty) and Dermatology (Dr Annamalai), and the Institute of Microbiology (Drs Pankajalakshmi and Subramanian), Madras Medical College; and the Department of Orthopedics, Stanley Medical College (Drs Shanmugasundaram and Kamalakannan), Madras, India.

Reprint requests to Institute of Microbiology, Madras Medical College, Madras 600003, India (Dr Pankajalakshmi).

Streptomyces pelletieri Mycetomas Reported From India						
			Basis of Diagnosis		Cases of *S pelletieri* Mycetoma	
Place	Source	Total No. of Cases Reported	Histopathology	Culture	No.	%
Central zone Jabalpur	Chouhan & Agarwal,[2] 1969	24	+	...	1	4.8
West zone Bombay	Desai et al,[4] 1970	40	+	+	1	2.5
South zone Vishakhapat-nam	Reddy et al,[3] 1972	50	+	...	5	10
Madurai	Klokke et al,[1] 1968	81	+	...	9	11.1
Vellore	Klokke et al,[1] 1968	91	+	...	6	6.6
	Koshi et al,[6] 1972	6	+	+	2	33.3
Pondicherry	Dasgupta et al,[5] 1974	19	...	+	1	5
Madras	Current report	95	+	+(2)	14	14.7

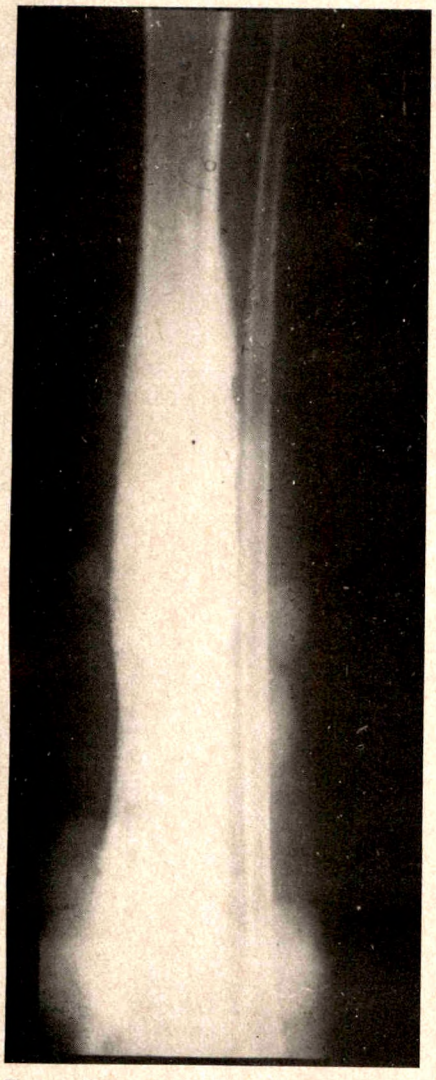

Fig 1.—Case 1. Roentgenogram of leg, showing thickening of shaft of tibia with areas of rarefaction and new bone formation.

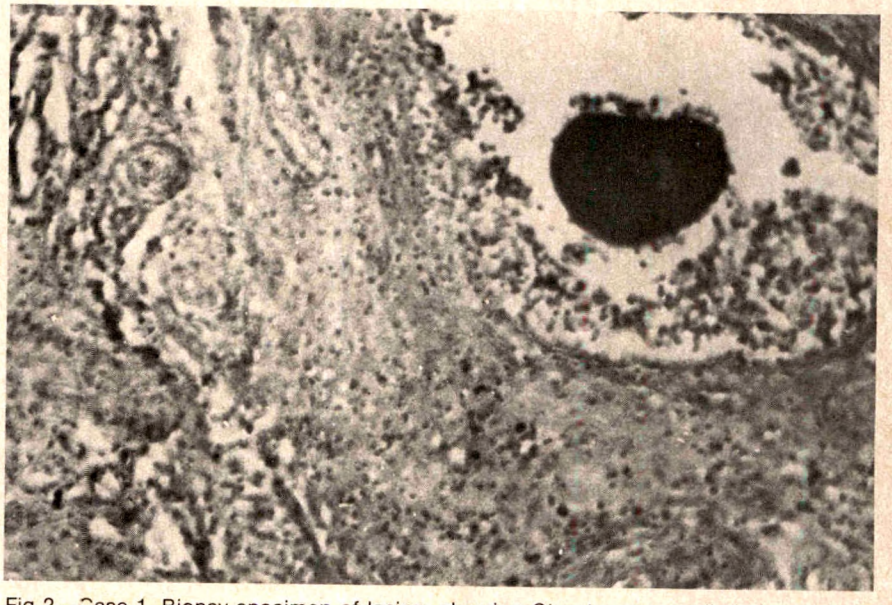

Fig 2.—Case 1. Biopsy specimen of lesion, showing *Streptomyces pelletieri* granule in abscess (hematoxylin-eosin, ×100).

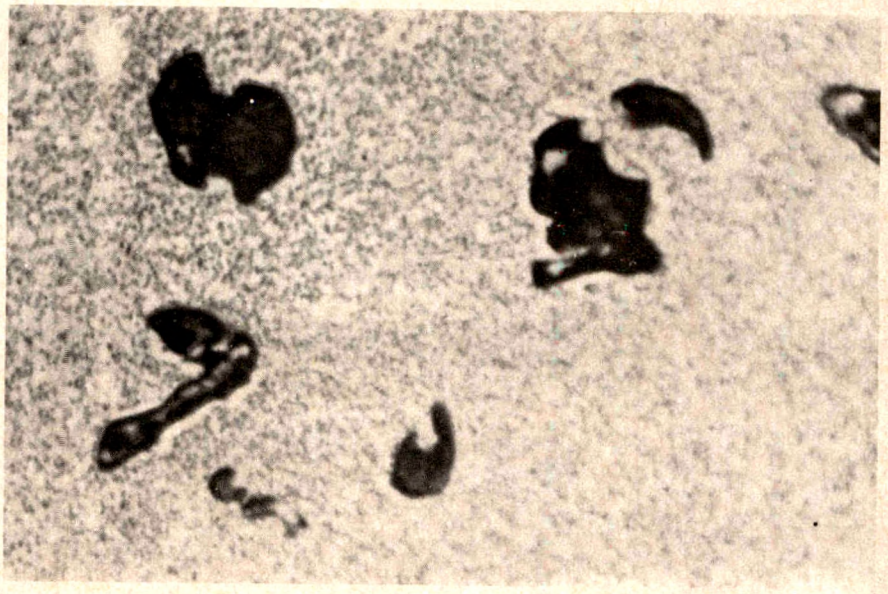

Fig 3.—Case 2. Biopsy specimen of lesion, showing *Streptomyces pelletieri* granules in abscess (hematoxylin-eosin, ×100).

paraffin. Urease was negative. Small puff-ball-like light-red colonies developed in Sabouraud's dextrose broth. The isolate from patient 1 was confirmed as *S pelletieri*.

Therapy

Patient 1 was treated with tetracycline, 1 gm daily, for two months without any improvement. Since the patient could no longer tolerate the severe pain, a below-knee amputation was carried out. The presence of *S pelletieri* in the amputated foot was again confirmed by culture, and the characteristic granules were demonstrated in tissue sections.

Patient 2 was treated with a combination of antibiotics—tetracycline, 1 gm, sulfadiazine, 3 gm, isoniazid, 600 mg, and streptomycin, 1 gm. Marked improvement was noted in a few day's time. Tetracycline was discontinued after ten days; the other drugs were continued for three weeks. The pain disappeared and the lesions had completely healed at the time of the patient's discharge. He was advised to continue sulfadiazine therapy for one year.

COMMENT

The species that cause mycetoma change from country to country. *Streptomyces pelletieri* as a causative agent of mycetoma has mainly been reported from the African countries—Cameroun,[7] Chad,[8] Malagasy,[8] Mali,[9] Niger,[8] Nigeria,[10] Republic of Somalia,[8,11] Republic of South Africa,[12] Senegal,[8] Sudan,[13] Tanzania,[8] and Upper Volta[8]—and the Latin American countries—Brazil,[14-16] Mexico,[17,18] Venezuela,[19] and Cuba.[20] The first case to be reported from Asia was that of Ambrosioni and Mercucci[21] from Yemen in 1942. Mariat,[8] in his global survey on mycetoma, recorded two cases of *S pelletieri* mycetoma from the United States. Bergeron et al[22] had first isolated the organism from case of mycetoma in the United States. Duncan once diagnosed *S pelletieri* in an Indian patient with mycetoma, but the case went unreported.[1] Twenty-five cases of *S pelletieri* mycetoma have been recorded so far from India, 23 of them from southern India. We present here 14 cases from Madras.

Streptomyces pelletieri infection is not seen in northern India, and most of the cases reported from southern India were from Tamil Nadu. The organism is especially prevalent in relatively humid areas where rainfall ranges from 500 to 800 ml or more per year.[9] The tropical climate of Tamil Nadu, with its annual rainfall ranging from 600 to 1,300 ml, may account for the occurrence of *S pelletieri* infection here.

All the 14 patients were adult men, which compares well with the reports of others. Although Rey[9] has estimated that 50% of all cases due to *S pelletieri* are extrapedal, only the lower extremity was involved in all the cases in the present series, and the foot was the main site of localization (85.7%).

A trauma is generally found to be the basis of mycetoma; often, it has been inflicted by a thorn prick. Pain is the most important symptom for which most of our patients seek medical advice. Banerjee et al[23] are of the opinion that mycetomas are usually painful, but Courtois et al[24] mentioned the presence of pain in only one of nine patients. Whether degree of pain varies with the species of fungi or actinomycetes or with the patient's race is not yet certain.[25] Enlargement of the regional lymph node is often attributed to secondary bacterial infection. Rarely, it is caused by actual spread of the fungus to the related lymph node.[4,26] Koshi et al,[6] however, had isolated *S pelletieri* from the lymph node of one of their cases.

We were able to obtain clinical improvement in one of our cases with a combination of antibiotics including sulfadiazine. Bergeron et al[22] reported considerable improvement following 2 gm of a combination of sulfadiazine, sulfamerazine, and sulfamethazine four times a day for four months. Their patient showed no response to penicillin and tetracycline therapy. In our patient 1, because of the extensive bony lesions and intolerable pain, amputation had to be resorted to when the patient showed no improvement with tetracycline therapy.

Prof Balasubramanium Ramamurthi, MS, FRCS, FICS, FACS, FAMS, FASC, Madras Medical College, Madras, gave permission for the publication of this report. Prof Raymond Vanbreuseghem confirmed the identity of the isolate from patient 1.

References

1. Klokke AH, Swamidasan G, Anguli R, et al: The causal agents of mycetoma in South India. *Trans R Soc Trop Med Hyg* 62:509-516, 1968.
2. Chouhan SS, Agarwal S: Histological diagnosis of mycetoma: A clinicopathological study of 24 cases. *Indian J Med Res* 57:71-77, 1969.
3. Reddy CRRM, Sundareshwar B, Pattabhi Rama Rao A, et al: Mycetoma: Histopathological diagnosis of causal agents in 50 cases. *Indian J Med Sci* 26:733-736, 1972.
4. Desai SC, Pardanani DS, Sreedevi N, et al: Studies on mycetoma. *Indian J Surg* 32:427-447, 1970.
5. Dasgupta LR, Sundar Raj T, Agarwal SC: Actinomycetes from mycetomas and other cases around Pondicherry. *Indian J Med Res* 62:765-775, 1974.
6. Koshi G, Victor N, Chacko J: Causal agents in mycetoma of the foot in southern India. *Sabouraudia* 10:14-18, 1972.
7. Gamet A, Brottes H, Essomba R: Nouveaux cas des mycétomas dépistés au Cameroun. *Bull Soc Pathol Exot* 57:1191-1195, 1964.
8. Mariat F: Sur la distribution géographique et la réparition des agents de mycetomes. *Bull Soc Pathol Exot* 56:35-45, 1963.
9. Rey M: *Les mycetomas dans ouest africain.* Paris, Foulan et Cie, 1961.
10. Smith EC: Mycetoma in Nigeria. *Trans R Soc Trop Med Hyg* 22:157-160, 1928.
11. Destombes P, Mariat F, Rosati L, et al: Les myçetomes en République de Somalie. *C R Acad Sci Paris* 263:2062-2064, 1966.
12. Pipjer A, Pullinger BD: South African nocardiosis. *J Trop Med Hyg* 30:153-156, 1927.
13. Abbot P: Mycetoma in the Sudan. *Trans R Soc Trop Med Hyg* 50:11-30, 1956.
14. Selles G: Um caso raro mycetoma observado na Bahia. *Gaz Med Bahia* 49:249-263, 1917.
15. Froes HP: Mycetoma pedis (Madura foot) and its incidence in Brazil. *J Trop Med Hyg* 34:376-378, 1931.
16. Silva F, Araujo E: Actinomyçetoma du pied à grains rouges (second cas brasilien) (nouvelle cspèce d àctinomyces). *Rev Fr Dermatol Venereol* 14:451-460, 1938.
17. Gonzalez-Ochoa A, Sandoval MA: Characteristicas de los actinomycetes patógenos mas comunes. *Rev Inst Saluhr Enferm Trop* 16:149-161, 1955.
18. Saul A, et al: Micetoma por *Streptomyces pelletieri* en Mexico. *Med Cut* 1:15-22, 1966.
19. Rincon Fuenmayor G, et al: Micetoma de granos rojor por *Streptomyces pelletieri* (Cameroon 1906): Waksman Y Henrici 1943, primer caso venezolano. *Rev Soc Med Ouirur Zulia* 35:11-36, 1961.
20. Paido-Costellos V, Trespalacios F: Superficial and deep mycoses in Cuba: A report based on 1174 cases. *South Med J* 52:7-15, 1959.
21. Ambrosioni P, Mercucci E: Micetoma a grani rossi ad Hodeida nello Jemen. *Riv Parassitol* 6:213-223, 1942.
22. Bergeron J, Mullins JF, Ajello L: Mycetoma caused by *Nocardia pelletierii* in the United States. *Arch Dermatol* 99:564-566, 1969.
23. Banerjee AK, Basu SP, Basu N: Studies on mycetoma. *Bull Calcutta Sch Trop Med Hyg* 9:113-115, 1961.
24. Courtois G, de Loof G, Thys A, et al: Neuf cas de pied de madura congolais par *Allecheria boydii, Monosporium apiospermum* et *Nocardia madurae. Ann Soc Belg Med Trop* 34:371-395, 1954.
25. Vanbreuseghem R: Early diagnosis, treatment and epidemiology of mycetoma. *Rev Med Vet Mycol* 6:49-60, 1967.
26. Hassen EAM, Mahgoub ES: Lymph node involvement in mycetoma. *Trans R Soc Trop Med Hyg* 66:165-169, 1972.

Selective Immunological Evaluation of Mycosis Fungoides

Peter A. Cooperrider, MD, Henry H. Roenigk, Jr, MD

• Tests of specific aspects of immune function were conducted on 15 patients with clinically and histologically evident mycosis fungoides of various stages. These tests included peripheral blood lymphocyte counts, T and B cell counts, mitogen stimulation tests to phytohemagglutinin (PHA), concanavalin A (con A), and pokeweed mitogen, as well as determinations of IgE levels and antinuclear factor (ANF). We found that mycosis fungoides patients, as a group, had normal peripheral blood lymphocyte, T cell, and B cell counts, but had decreased stimulation to PHA and con A. When evaluated by stage of disease, the peripheral blood lymphocytes, T and B cell counts did not differ significantly from normal, at least until stage V. Concanavalin A stimulation was decreased by stage II disease, and PHA was decreased by stage III, indicating at least a selective immunological deficit in the plaque stage or in later disease. Values of IgE and ANF were rarely abnormal.

(*Arch Dermatol* 114:207-212, 1978)

Mycosis fungoides is an uncommon disease of unknown origin and controversial pathogenesis. The disease is presently considered by most investigators to be a malignant mixed-cell type lymphoma, as is Hodgkin's disease. Investigators are currently looking more closely at the immunological status of the patient with mycosis fungoides, with the hope that such studies will lend some predictability to the course of the disease and its response to therapy.

There have been several efforts in the past to characterize mycosis fungoides through various tests of immune status. Our aim was to find out whether some of the more recently available tests, especially of cell-mediated immunity, correlated with each other or with the patient's stage of disease. Previous studies have evaluated some tests of cell-mediated immunity separately, but with conflicting results (Table 1). In the majority of patients with mycosis fungoides, relative circulating T cell numbers that were identified by the E rosette method have been normal,[1-5] though in a few cases, the numbers were decreased, especially in leukemic mycosis fungoides.[2,5-7] Lymphocyte transformation to phytohemagglutinin (PHA), thought to be a T cell property, has been shown to be normal in patients with nonleukemic mycosis fungoides[3,4,8] (at least until the tumor stage[9]), and has been generally decreased in leukemic mycosis fungoides.[4,8] Studies of circulating B cells and the function of these cells in patients with mycosis fungoides have also been inconclusive. Whereas the percentage of circulating B cells has been reported variously as normal[8] or decreased,[1,3,10] several factors thought to be indicative of B cell functions have been increased. This includes reports of increased IgA levels in some series of patients[11] (but not in others[1,8]) and, more recently, increased IgE and autoantibody levels.[8] On the whole, levels of IgG and IgM have been normal in patients with mycosis fungoides.[1,8,11] Lymphocyte transformation to pokeweed mitogen, thought to be somewhat indicative of B cell function, has been low in most patients with leukemic mycosis fungoides[4,12] and variable in a few patients with nonleukemic mycosis fungoides.[4]

We therefore collected the following data on our group of patients with mycosis fungoides: peripheral lymphocyte counts, circulating T and B cell counts, mitogen stimulation to PHA, con A, and pokeweed mitogen, and antinuclear factor (ANF) and IgE levels. We then correlated these data with stages of the disease and thereby generated an immunological profile

Accepted for publication July 18, 1977.

From the Department of Dermatology, Cleveland Clinic Foundation. Dr Cooperrider is now in private practice in Kirkland, Wash. Dr Roenigk is now with the Department of Dermatology, Northwestern University Medical School, Chicago.

Reprint requests to the Department of Dermatology, Northwestern University Medical School, 303 E Chicago Ave, Chicago, IL 60611 (Dr Roenigk).

UNIVERSITY COLLEGE OF MEDICINE LIBRARY

Table 1.—Investigations of T Cell and Mitogen Determinations in Mycosis Fungoides*

Investigator, yr	No. of Patients	Mitogen Results	No. of Patients	T Cell Percentage	Comment
Braylan et al,[2] 1973	...	...	3	Decreased, 3	Sézary
			3	Normal, 3	Mycosis fungoides
Brouet et al,[1] 1973	...	...	6	Normal, 5	Sézary
Wybran and Fudenberg,[6] 1973	...	...	2	Decreased, 2	Sézary
Lutzner et al[4] 1974	8	PHA decreased, 6			Sézary
	8	Con A decreased, 6	...	...	Sézary
	6	PWM decreased, 4			Sézary
	3	PHA decreased, 1			Mycosis fungoides
Mendes et al,[7] 1974	...	...	3	Decreased, 3	Mycosis fungoides
Tan et al,[8] 1974	19	PHA normal, 19			Mycosis fungoides
	1	PHA decreased, 1	...	...	Sézary
Zucker-Franklin et al,[3] 1974	11	PHA decreased, 3	16	Normal, 16	Mycosis fungoides and Sézary
Langner et al,[9] 1975	20	PHA normal, 20			Mycosis fungoides, early
	6	PHA decreased, 6	...	...	Mycosis fungoides, tumor
Nordquist et al,[5] 1976	...	...	13	Decreased, 7	Mycosis fungoides
			2	Decreased, 2	Sézary

*PHA indicates phytohemagglutinin; Con A, concanavalin A; PWM, pokeweed mitogen.

predictive of extent of involvement with mycosis fungoides.

SUBJECTS AND METHODS

Subjects

The 15 patients in this study fulfilled our clinical and histological criteria for the diagnosis of mycosis fungoides. These patients were otherwise selected only by the fact that they were accepted histologically as having mycosis fungoides by the National Mycosis Fungoides Cooperative Study Group. Five of the patients were men and ten were women (Table 2). The average age of the patients at the time of diagnosis was 54 years; the skin disease of the patients had persisted an average of 9 years. Staging was accomplished by methods short of laparotomy that consisted of examination of a peripheral blood smear for Sézary cells, diagnostic roentgenograms of the chest and the gastrointestinal tract, lymphangiograms, and liver, bone marrow, and lymph node biopsies. Classification of patients by stage of disease was done according to the National Institutes of Health classification of mycosis fungoides.[4] This system of classification segregates patients by extent of disease and incorporates Sézary syndrome as leukemic mycosis fungoides. Patients with active disease were undergoing various forms of treatment at the time of testing, including one patient who was receiving chemotherapy and other patients who were receiving one or more of topical steroids, topical mechlorethamine hydrochloride, psoralen and ultraviolet A light, and local x-ray therapy.

Table 2.—Mycosis Fungoides Age, Sex, and Duration Characteristics

Patient Sex, Age at Histological Diagnosis (yr)	Duration of Skin Disease at Diagnosis (yr)	Age at Test Date (yr)
F, 48	1	49
M, 47	15	49
F, 58	2	58
F, 62	15	62
F, 60	30	60
F, 60	1	60
F, 61	22	70
F, 62	5	62
M, 54	15	58
M, 62	10	63
M, 47	4	50
M, 50	7	55
F, 54	4	58
F, 42	1	44
F, 41	0	49
Total or average M, 5; F, 10 } 54	**9**	**56**

Methods

Lymphocyte counts were calculated from a standard complete blood count and differential. A hospital mean of 1,286 cells/cu mm was derived for statistical purposes by averaging 50 consecutive lymphocyte counts (excluding counts from hematology and pediatric patients).

T and B cell counts were done by determining the percentages of E and EAC rosettes with peripheral blood lymphocytes. Briefly, mononuclear cells were separated from 20 ml of heparinized blood with polysucrose–sodium and meglumine diatrizoate (Ficoll-Hypaque), washed, and resuspended in 3 ml Hanks-Balanced Salt Solution; 0.5 ml carbonyl iron suspension was added for 30 minutes at 37 C to remove phagocytic cells, and the lymphocytes were again separated with Ficoll-Hypaque. E rosettes were formed by adding neuraminidase-treated sheep RBCs to the lymphocytes in a 100:1 ratio, incubating the cells for five minutes at 37 C, centrifuging the mixture at 300 g for five minutes; the cells were then incubated on ice for 60 minutes and examined. The EAC rosettes were formed by adding sheep RBCs that had been treated with trypsin, 19 S anti-sheep RBC hemolysins, and guinea pig complement to the lymphocyte suspension at a ratio of 100:1. The mixture was then incubated for 5 minutes at 37 C, centrifuged at 300 g for 5 minutes, and examined. Normal values for E rosettes were 75.2% ± 5.3%, and for EAC rosettes were 21.8% ± 6.1%.

Mitogen studies were done with PHA, con A, and pokeweed mitogen as described by Valentine using morphological evaluation of the response.[13] Antinuclear factor was performed by a standard method on rat kidney using antihuman immunoglobulin. IgE levels were determined by radioimmunoassay.

RESULTS

The overall results of mean peripheral blood lymphocytes, T and B cell counts, and mitogen testing appear in Tables 3 and 4. In cases in which a test was performed on the same patient more than once, the tests were done an average of one year apart. The values for persons in the active disease group did not differ signifi-

Table 3.—Peripheral Lymphocyte Count, T and B Cell Count by Stage of Mycosis Fungoides

Stage	No. of Samples	Mean Peripheral Blood Lymphocyte Count	Mean T Cell Count	Mean B Cell Count
0	...	...	...	...
Ia	1	1,210	690	220
IIa	10	1,519	1,008	232
IIIa	6	1,678	1,123	356
IVa	...	...	...	...
Va	2	787	456	175
Remission	4	1,367	993	162
Mean (active disease)	...	**1,472**	**970**	**265**
Mean (normal values)	...	**1,286**	**967**	**280**

Table 4.—Mitogen* Stimulation by Stage of Mycosis Fungoides

Stage	No. of Samples	Mean Lymphocyte Transformation to PHA (%)	Mean Lymphocyte Transformation to Con A (%)	Mean Lymphocyte Transformation to PWM (%)
0	...	...	...	...
Ia	1	49	72	31
IIa	9	60	57	30
IIIa	6	48	46	23
IVa	...	...	...	...
Va	1	49	53	24
Remission	4	72	76	28
Mean (active disease)	...	**54**	**53**	**27**
Mean (normal values)	...	**70**	**73**	**31**

*PHA indicates phytohemagglutinin; Con A indicates concanavalin A; PWM indicates pokeweed mitogen.

cantly from normal values in mean peripheral blood lymphocytes, T, or B cell counts (Fig 1). Mean PHA and con A stimulation was significantly lower in the active disease group ($P < .001$), but mean pokeweed mitogen did not differ significantly (Fig 2).

When divided by stage of disease, again there were no significant differences in the values of mean peripheral blood lymphocytes, T cells, or B cells from normal values, except for stage V, which was too small to evaluate statistically (Fig 3 through 5). However, in the case of the mitogens, stimulation with PHA reveals a definite trend toward lower mean values with worsening disease (Fig 6), reaching a significance of $P < .02$ in stage IIa and then returning to normal in disease remission. Mean stimulation with con A (Fig 7) is significantly lower than normal in stage IIIa as well as in stage IIIa at approximately $P = .02$, and stimulation then becomes normal in remission. Stimulation with pokeweed mitogen (Fig 8) produced no significant difference from the normal value.

We found no correlation of nonrosette-forming cell percentages with stage of disease, and only two instances each of increased IgE levels and ANF.

COMMENT

Our results indicate that in patients with mycosis fungoides, as a group, there are selective defects in cell-

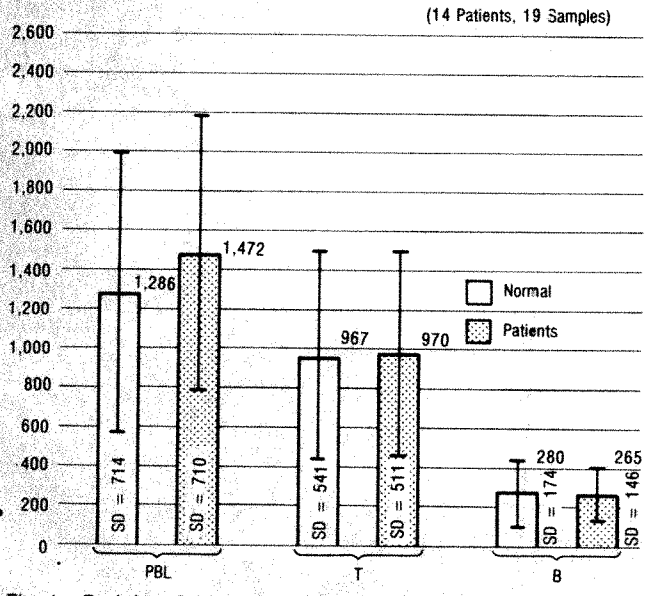

Fig 1.—Peripheral blood lymphocyte (PBL) counts, T cell (T) counts, and B cell (B) counts for normal vs patient group, which included all patients with nonleukemic mycosis fungoides, but excluded those patients in remission.

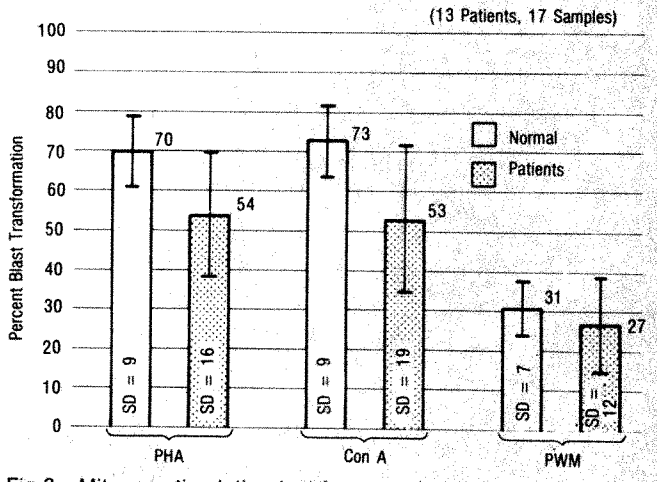

Fig 2.—Mitogen stimulation test for normal vs total patient group, which included all patients with nonleukemic mycosis fungoides, but excluded those patients in remission; PHA indicates phytohemagglutinin; Con A, concanavalin A; PWM, pokeweed mitogen.

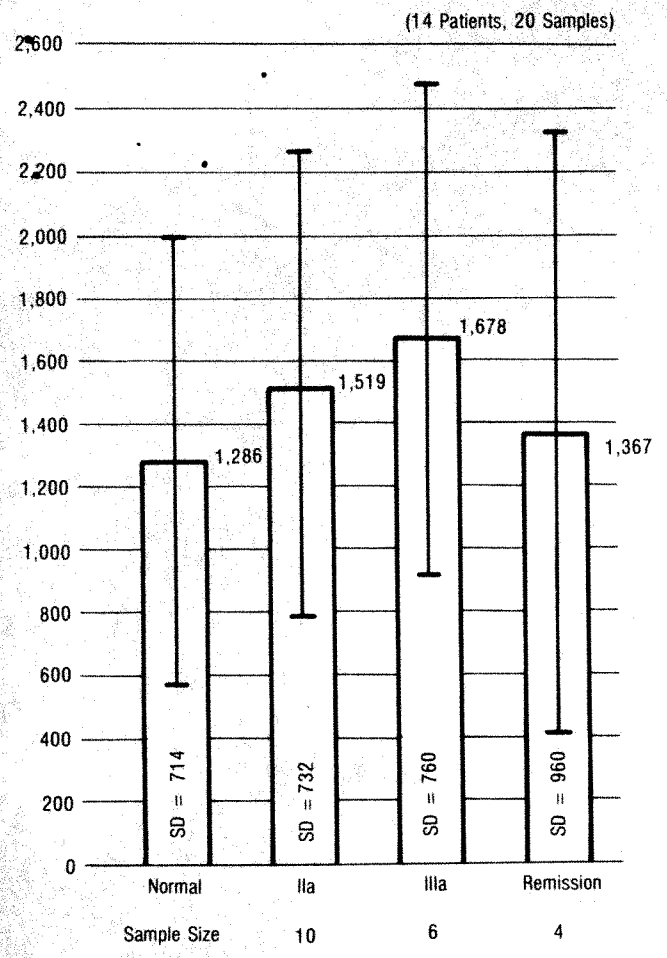

Fig 3.—Peripheral blood lymphocyte counts: normal values vs values for persons with stages IIa, IIIa, and remission of mycosis fungoides.

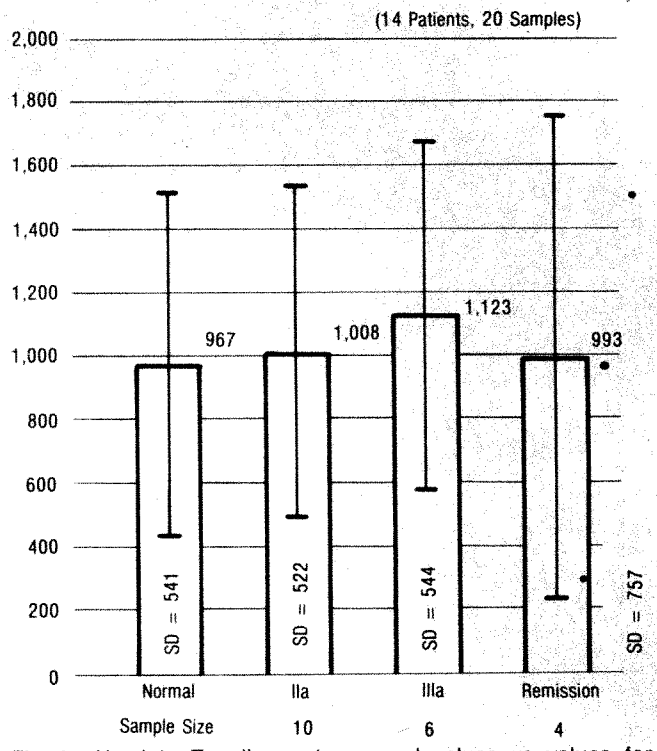

Fig 4.—Absolute T cell counts: normal values vs values for persons with stages IIa, IIIa, and remission of mycosis fungoides.

mediated immunity. This is shown by a defective response to mitogens that, however, does not appear to be owing to or associated with a decrease in absolute numbers of peripheral blood lymphocytes or T cells. Nor is there any consistent associated abnormality of ANF or IgE level.

When patients are analyzed by stage of disease, the defect in mitogen stimulation is present with con A in stages II and III disease, and with PHA in stage III or tumor stage disease. With data from Table 3, one can calculate a decrease in the percentage of circulating T cells in all stages of mycosis fungoides; this decrease might explain the decrease in some of the lymphocyte transformation tests that depend on T cells. However, the number of T cells as expressed in absolute numbers is equal to or greater than the number of T cells in normal controls, and when dealing with a disease that presumably involves a neoplastic transformation, we felt that the number of T cells per cubic milliliter was more important and less deceptive than the percentage of T cells. On the other hand, we did not consider blast transformation in terms of number of transforming cells because this test is more qualitative and the population of cells that are measured may be heterogeneous.

In some malignancies, the decrease in lymphocyte stimulation as the disease progresses is thought to be due to an acquired intrinsic lymphocyte defect, or to be secondary to a circulating factor that acts on the surface of the lymphocyte. An important question that remains is whether the defect that was picked up by our testing is a factor that permits malignant clones of lymphocytes to become established or to systematize. If so, early identification of such a defect might influence the choice of therapeutic modalities and provide a rationale in selected cases for the early institution of aggressive therapy. Alternatively, the defect might simply be a marker that such progression has already taken place or has been undetected by our relatively crude diagnostic and staging methods, and would again be an indication for early aggressive intervention.

The mitogen screen that is routinely done in our laboratory and in most other laboratories may suffer from a lack of sensitivity. This is because the stimulating concentration that is used is designed to represent the amount of lectin necessary to maximally stimulate control lymphocytes without being toxic to them. The concentration of PHA usually used, for example, is 50 μg/ml. Lymphocytes from patients with early stages of Hodgkin's disease that stimulated normally with an optimal dose of PHA, at times reacted considerably less than control lymphocytes to suboptimal doses.[14,15] We have begun testing our newly diagnosed untreated mycosis fungoides patients with a logarithmic range of PHA concentrations from 0.025 μg to 500 μg of PHA per milliliter. We are indeed finding a great variability of response to concentrations of PHA in the 0.1 μg/ml-range among patients with nonimmunologic diseases vs patients with mycosis fungoides, many of whom have normal responses at the usual concentrations.

Some investigators suggest that response to PHA may correlate with the ability of the T lymphocyte to regulate its proliferative capacity, and when this property is decreased, as

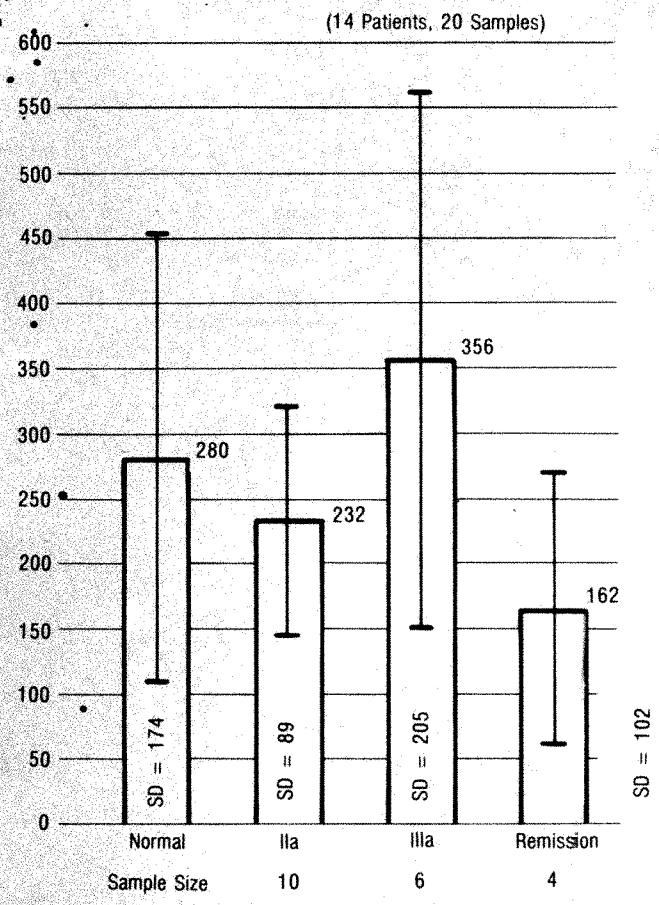

Fig 5.—Absolute B cell counts: normal values vs values for persons with stages IIa, IIIa, and remission of mycosis fungoides.

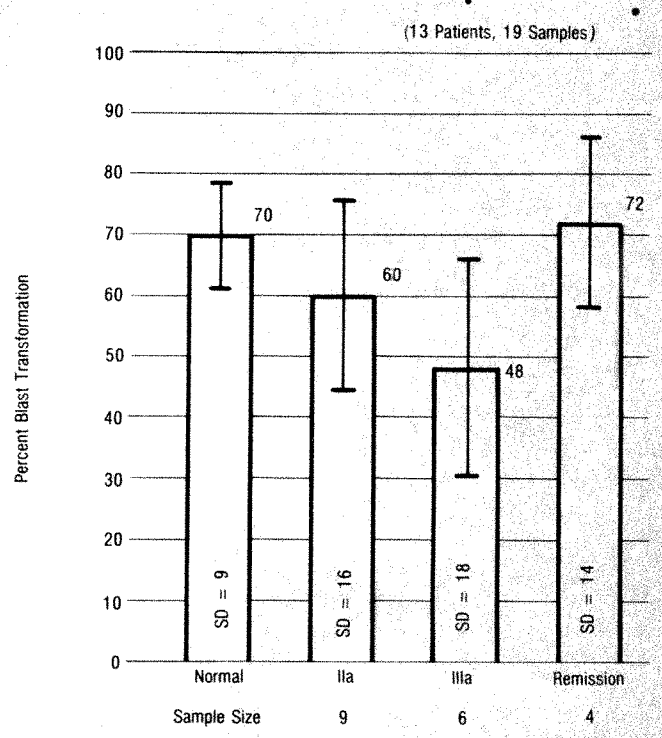

Fig 6.—Phytohemagglutinin mitogen stimulation test: normal values vs values for persons with stages IIa, IIIa, and remission of mycosis fungoides.

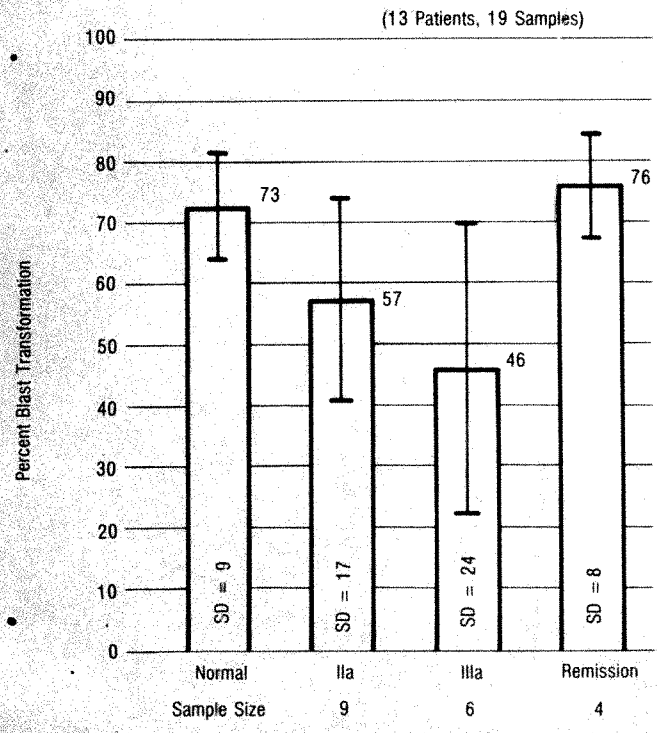

Fig 7.—Concanavalin A mitogen stimulation test: normal values vs values for persons with stages IIa, IIIa, and remission of mycosis fungoides.

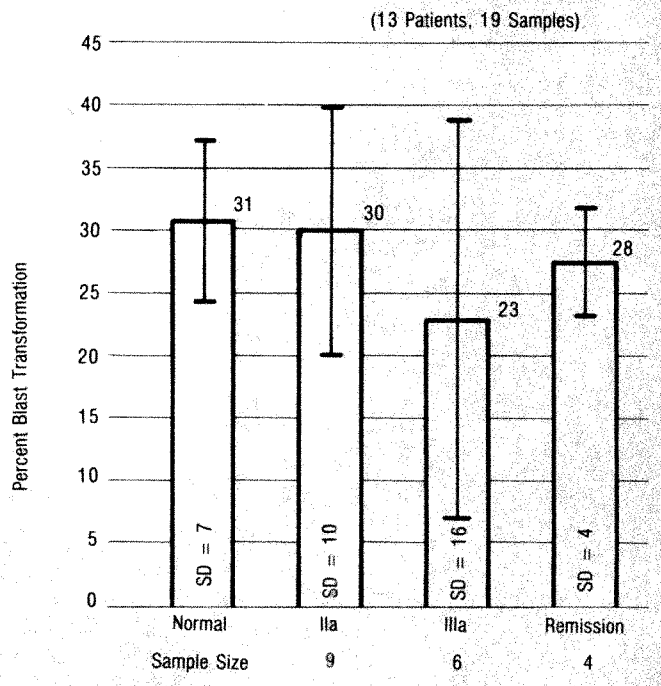

Fig 8.—Pokeweed mitogen stimulation test: normal values vs values for persons with stages IIa, IIIa, and remission of mycosis fungoides.

may happen early in the course of certain lymphomatous disorders such as Hodgkin's disease; the reticulosis may be progressing into a truly malignant disease.[12] Additionally, the number of null cells may correlate with transition of the disease into a malignant process.[5] In some patients with solid tumors who have high null-cell percentages, the lymphocytes are coated with a molecule that can be removed by simple enzymic digestion or washing to reveal T cell markers underneath.[16] This may also be related to the ability of a malignancy to become invasive or to metastasize, although such a relationship has not been shown yet in mycosis fungoides, and our work does not shed any light on these hypotheses.

In Hodgkin's disease, decreasing PHA response seems to correlate with decreasing numbers of circulating T cells as identified by the E rosette method (though not as identified by antithymocyte serum).[17] This relationship has not been demonstrated in mycosis fungoides, and our results did not show such a relationship. An alternative hypothesis is that our assay was too selective in that the lymphocyte counts that we had to use as control values were derived from a clinical population, which may have yielded an artificially low, normal value of 1,286 cells/cu mm. The often accepted range of normal lymphocyte counts is 1,500 to 2,500 cells/cu mm, though we cannot determine any particular basis for this belief. Also, lymphocyte counts and function vary notably with age and even with sex[18-22]; if this is to be accepted, the ideal study will have to use age- and sex-matched controls for this evaluation. That the patients used in our study were on a variety of therapy regimens and were in varying physical states must be kept in mind. Although the majority of the therapies that were used would probably not directly influence lymphocyte characteristics, as only one patient was on systemic chemotherapy, to observe untreated patients would be preferable in such an investigation.

We have shown, therefore, that mitogen stimulation tests with PHA and con A do correlate with stage of disease in mycosis fungoides. We hope that these observations will be extended and refined in such a way that these tests become an important diagnostic and therapeutic tool in the indirect staging of a difficult disease.

J. N. Berritone, PhD, performed the statistical studies.

References

1. Brouet J-C, Flandrin G, Seligmann M: Indications of the thymus-derived nature of the proliferating cells in six patients with Sézary's syndrome. *N Engl J Med* 289:341-344, 1973.
2. Braylan R, Variakojis D, Yachnin S: The Sézary syndrome lymphoid cell: Abnormal mitogenic responsiveness and surface properties, abstracted. *Clin Res* 21:870, 1973.
3. Zucker-Franklin D, Melton JW, Quagliata F: Ultrastructural, immunologic, and functional studies on Sézary cells: A neoplastic variant of thymus derived (T) lymphocytes. *Proc Nat Acad Sci USA* 71:1877-1881, 1974.
4. Lutzner M (mod), in discussion, Edelson P, Schein P, Green I, et al: Cutaneous T-cell lymphomas: The Sézary syndrome, mycosis fungoides, and related disorders. *Ann Intern Med* 83:534-552, 1975.
5. Nordquist BC, Kinney JP: T and B cells and cell-mediated immunity in mycosis fungoides. *Cancer* 57:714-718, 1976.
6. Wybran J, Fudenberg HH: Thymus-derived rosette-forming cells in various human disease states: Cancer, lymphoma, bacterial and viral infections, and other diseases. *J Clin Invest* 52:1026-1032, 1973.
7. Mendes NF, Musatti CC, Tolnai MEH: T and B lymphocyte membrane markers in cells from patients with leukemia and lymphoma. *Int Arch Allergy Appl Immunol* 46:695-706, 1974.
8. Tan RS-H, Butterworth CM, McLaughlin H, et al: Mycosis fungoides: A disease of antigen persistence. *Br J Dermatol* 91:607-616, 1974.
9. Langner A, Glinski W, Pawinska M, et al: Lymphocyte transformation in mycosis fungoides. *Arch Dermatol Forsch* 251:249-257, 1975.
10. Scully RE, Galdabini JJ, McNeely BU: Weekly clinicopathological exercises. *N Engl J Med* 293:598-603, 1975.
11. Blaylock WK, Clendenning WE, Carbone PP, et al: Normal immunologic reactivity in patients with the lymphoma mycosis fungoides. *Cancer* 19:233-236, 1966.
12. Crossen PE, Mellor J, Finley AG, et al: The Sézary syndrome: Cytogenetic studies and identification of the Sézary cell as an abnormal lymphocyte. *Am J Med* 50:24-34, 1971.
13. Valentine F: *In Vitro Methods in Cell Mediated Immunity*, Bloom BR, Glade DR (eds). New York, Academic Press Inc, 1971, pp 443-454.
14. Levy R, Kaplan HS: Impaired lymphocyte function in untreated Hodgkin disease. *N Engl J Med* 290:181-186, 1974.
15. Faguet GB: Quantitation of immunocompetence in Hodgkin's disease. *J Clin Invest* 56:951-957, 1975.
16. Whitehead RH, Thatcher J, Teasdale C, et al: T and B lymphocytes in breast cancer: Stage relationship and abrogation of T lymphocyte depression by enzyme treatment in vitro. *Lancet* 1:330-333, 1976.
17. Bobrove AM, Fuks Z, Strober S, et al: Quantitation of T and B lymphocytes and cellular immune function in Hodgkin's disease. *Cancer* 36:169-179, 1975.
18. Piscioha AV, Westring DW, DePrey C, et al: Mitogenic effect of phytohemagglutinin at different ages. *Nature* 215:193-194, 1967.
19. Del Pozo Perez MA, Prieto Valtueña J, Gonzalez Guilabert MI, et al: Effects of age and sex on T and B lymphocyte populations in man. *Biomedicine* 19:340-344, 1973.
20. Augener W, Cohnen G, Reuter A, et al: Decrease of T lymphocytes during aging. *Lancet* 1:1164, 1974.
21. Diaz-Jouanen E, Williams RC Jr, Strickland RG: Age-related changes in T and B cells. *Lancet* 1:688-689, 1975.
22. Alexopoulos C, Babitis P: Age dependence of T lymphocytes. *Lancet* 1:426, 1976.

Decreased T Cell Levels in Patients With Warts

Jane H. Chretien, MD; John G. Esswein, MD; Vincent F. Garagusi, MD

• Thymus-derived lymphocyte (T cell) levels were determined in 72 healthy patients who had viral warts, in 21 healthy patients who had been cured of warts from one to 15 years previously, and in 35 age-matched normal controls who had no history of warts.

The mean percentage of lymphocytes that formed rosettes with sheep erythrocytes was less in patients with warts and patients previously cured of warts than in normal controls ($P < .001$ and $P < .001$, respectively). The number of total T cells/cu mm was decreased in untreated patients with warts ($P < .01$) but was normal in patients cured of warts for more than one year. In addition, the morphology of the rosettes in the two patient groups differed from the controls; 32% had small numbers of sheep erythrocytes bound loosely to T cells compared with a rosette of numerous erythrocytes closely adherent to the T cell in 91% of the controls.

The results suggest a defect of cellular immunity in many healthy patients with warts.

(*Arch Dermatol* 114:213-215, 1978)

Warts, intraepidermal growths caused by infection of the skin with papilloma virus, occur most frequently in patients with diseases that are associated with a deficiency of cell-mediated immunity.[1] However, a study using the leukocyte migration assay suggests that in the absence of obvious immune defects a subtle impairment in cellular immunity might be present in subjects with warts.[2]

In the present study, T cell levels, an in vitro correlate of cell-mediated immunity, were quantitated in healthy patients with untreated warts, in healthy patients who had been cured of warts for several years, and in age-matched normal controls to compare the immune status of these groups and the changes, if any, that might occur with treatment and resolution of the warts. T cell levels were recorded according to duration of infection, anatomic site, and extent of the lesions.

• Accepted for publication Sept 6, 1977.

From the Student Health Service (Drs Chretien and Esswein), and the Infectious Disease Service (Drs Chretien and Garagusi), Department of Medicine, Georgetown University, Washington, DC.

Reprint requests to Georgetown University, Student Health Service, Washington, DC 20057 (Dr Chretien).

MATERIALS AND METHODS

Patients

A total of 72 patients had virally induced warts. All were healthy university students, with an average age of 22 years, who had no serious illnesses or recent viral infections and who were not receiving any medications when studied. The lesions had been present for less than six months in 34 patients and for six months to eight years in 38 patients. Warts were limited to the hands in 32 patients, feet in 28 patients, hands and feet in nine patients, and face or trunk in three patients. All were studied before initiation of therapy, and 13 were restudied serially three to eight weeks after liquid nitrogen therapy and resolution of the warts.

A total of 21 patients, with an average age of 23 years, gave a history of having had warts between one and 15 years previously when studied. Six reported spontaneous regression and the rest had been treated by cautery, liquid nitrogen, or chemical agents.

The controls were 35 normal subjects, with an average age of 25 years, who had no history of warts.

Rosette Assay

T cells were quantitated by a previously described method.[3] Lymphocytes were separated from 10 ml of heparinized venous blood by means of a lymphocyte separation medium gradient, washed three times in 0.85% phosphate buffered saline (pH of 7.4), and adjusted to a count of 2 to 3 × 10^6/ml. In a 15-ml plastic tube, a 0.25-ml aliquot of lymphocytes was added to 0.2 ml of a thrice-washed 1% solution of sheep erythrocytes and 0.1 ml of pooled heat-inactivated human AB serum that had previously been adsorbed against sheep erythrocytes. The cells were incubated at 37 C for 20 minutes and centrifuged at 1,000 rpm for five minutes. After overnight refrigeration at 4 C, the cell pellet was gently resuspended, a drop of 1% toluidine blue was added to stain the lymphocytes, and the percent of lymphocytes that were surrounded by at least three sheep erythrocytes was counted in a hemocytometer chamber. A total of 200 lymphocytes were counted for each tube. The percent of T cells for each patient was the mean of triplicate samples. All of the samples were coded before the resettes were counted.

A total WBC count and a differential cell count with Wright's stain were also done for each patient. The total number of T cells per cubic millimeter was derived from the product of the total lymphocyte count times the percent of T cells.

Statistics

The percent of rosette-forming lymphocytes in the patients with warts and the patients cured of warts were compared with each other and with the normal controls by Student's t test. The absolute numbers of T cells per cubic millimeter of these groups were compared by the Mann-Whitney test.

RESULTS

Percent of T Cells

The percentage of rosette-forming lymphocytes was lower in patients with warts (64.1%) ($P < .001$) and in patients cured of warts (64.1%) ($P < .001$) than in the normal controls (69.6%) (Fig 1). If untreated, warts tend to become multiple. Only one of the 34 patients (3%) who had warts for less than six months had lesions on both hands and feet, but eight of the 38 patients (21%) who had warts for more than six months before therapy had lesions on both hands and feet. However, when the percent of T cells for patients with warts of less than six months' duration was compared with the percent of T cells for patients with warts of more than six months' duration, there was no correlation of dura-

Fig 1.—Percent of T cells in normal controls, in patients with untreated warts, and in patients cured of warts for more than one year.

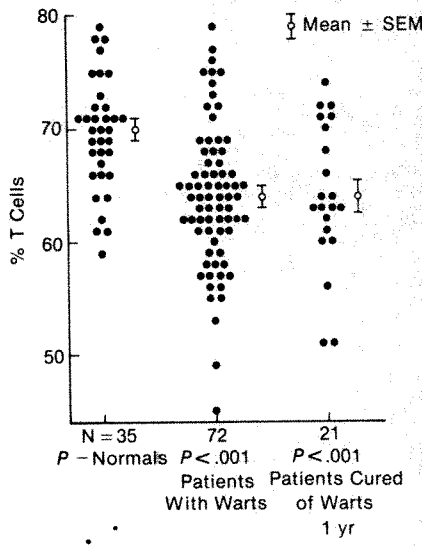

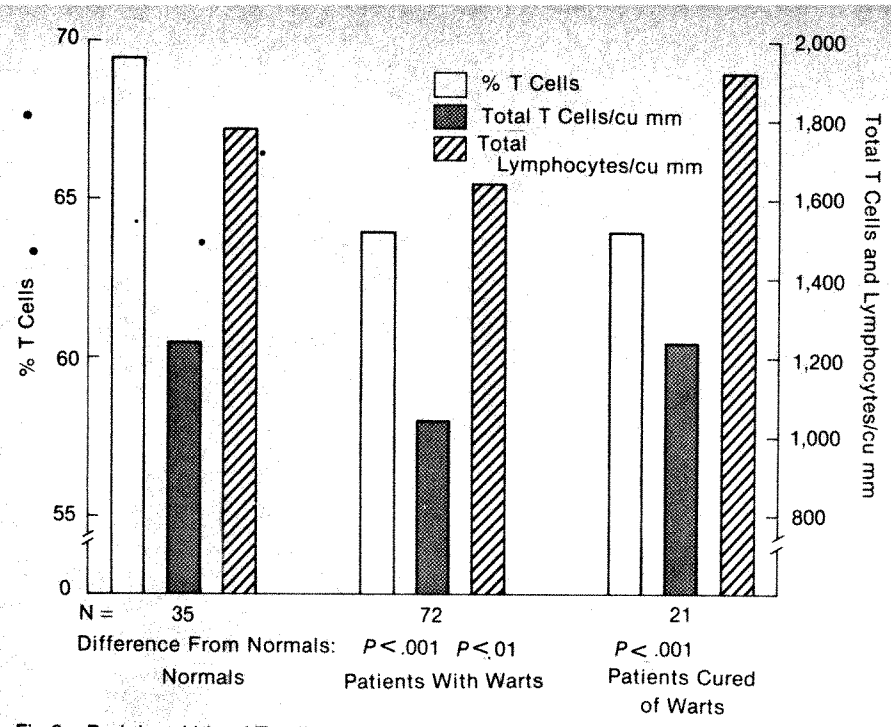

Fig 2.—Peripheral blood T cell and lymphocyte levels in normal controls, in patients with untreated warts, and in patients cured of warts for more than one year.

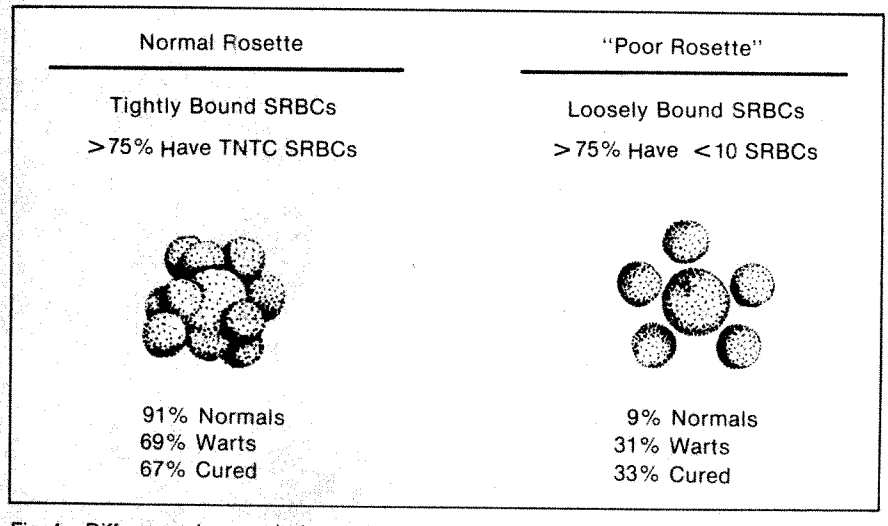

Fig 4.—Difference in morphology of rosettes in normal controls and in patients with warts. SRBCs indicates sheep RBCs; TNTC, too numerous to count.

tion of warts and T cell level. Among the patients cured of warts, there were too few who had undergone spontaneous regression (six of 21) to analyze separately.

Total T Cells

The total T cell count of patients with warts (1,051/cu mm) was significantly lower than in controls (1,237/cu mm) ($P < .01$). The total T cell count of patients previously cured of warts (1,236/cu mm) did not differ from the controls (Fig 2).

Serial T Cell Determinations

Thirteen of the patients with warts were restudied three to eight weeks after the warts had been eradicated. The mean percent of T cells for this group was 61.1% before treatment and 67.2% afterward ($P < .01$) (Fig 3). After exclusion of the patient with an extreme rise in T cell percent from 49% to 74%, statistical significance of $P < .01$ was still attained.

Quality of Rosettes

Normal rosettes consisted of a lymphocyte surrounded by tightly clustered sheep erythrocytes too numerous to count. However, 22 of 72 of the patients with warts (31%) and seven of 21 (33%) of the patients previously cured of warts displayed a substantial number of "poor quality"

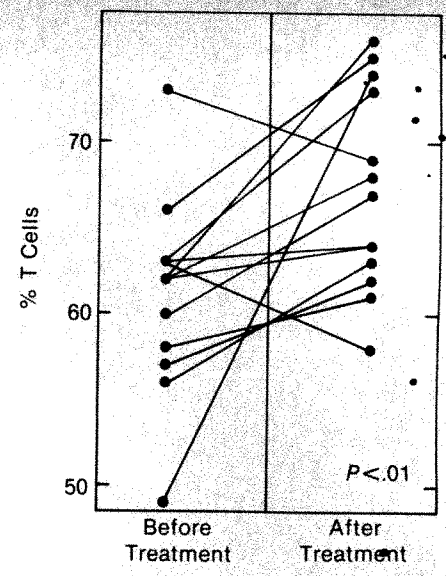

Fig 3.—T cell levels in patients with warts before and three to eight weeks after treatment.

rosettes, which were comprised of loosely attached, scant numbers of sheep erythrocytes (usually three to ten) around the T lymphocyte. Only three of 35 (9%) of the controls showed similar findings (Fig 4).

COMMENT

Human infections with the papilloma virus and the subsequent appearance of warts is common and may be due in part to a defective immunologic mechanism. Certain patients, notably those with defects of cell-mediated immunity, are especially likely to have warts develop. Patients with Hodgkin's disease, lymphoma, and chronic lymphocytic leukemia have an increased incidence of warts compared with normals, but patients with multiple myeloma, whose immunologic deficit is humoral do not.[1] Similarly, renal transplant recipients treated with immunosuppressive drugs have up to a 42% incidence of warts more than one year after transplantation.[4] An association of immunologic abnormalities and warts has been further suggested by a study of schoolchildren vaccinated with Bacillus Calmette-Guérin. Those in whom warts develop are also more likely to be anergic to purified protein derivative.[5]

Humoral immunity is thought to have little role in acquisition, regression, or recurrence of warts, although rapid resolution during treatment by cautery or keratolytic agents has been predicted by the presence of complement-fixing (IgG) antiwart antibodies that appear before or during the course of therapy.[6]

In the present study, an additional immunologic defect is demonstrated

in patients with untreated warts, a decreased percentage and decreased total number of thymus-derived lymphocytes. Two mechanisms might contribute to this defect. A decreased production or differentiation of the thymus-derived lymphocytes may precede the development of warts in a manner similar to patients who have defects of cell-mediated immunity that is due to lymphomas or immunosuppressive drug therapy. T lymphocytes seem to be the effector cells for direct killing of cells infected by virus[7] and even a subtle defect in function might allow for the development of warts. The defect could be a transient immunologic depressed state or could be genetically predetermined, the former being more likely in view of the normal total number of T cells per cubic millimeter in patients cured of warts from one to 15 years previously. That the percentages of T cells were low suggests an expansion of the non-T cell lymphocyte compartment with resolution of the warts. Although B cells were not enumerated in the present study, a rise in the number of B cells accompanying cure could be hypothesized to account for these results. This would complement the previously documented appearance of antibodies with the cure of warts.[6]

An additional factor in the relation of T cell levels to the presence of warts is that the lesion is induced by a virus. In the studies of acute viral infections, the T cell levels are low but return to normal within days after resolution of the viral infection. However, in the case of the papilloma virus, viral particles can be identified in the wart for several months. Such a persistent infection might contribute to depression of the T cells during the life span of warts. Decreased T cell levels have been found in patients with influenza,[8] echovirus 6-induced diarrhea,[9] and viral upper respiratory tract infections.[10] In the latter patients, Wybran and Fudenberg[10] identified "active" rosette-forming cells rather than the "total" rosette-forming cells of the present study. Their method identifies fewer T cells but may be more sensitive, suggesting that its application in patients with warts might provide a larger deviation from normal controls.

The interrelation of warts and defective cell-mediated immunity in otherwise healthy subjects whose warts were difficult to eradicate has been demonstrated in vitro by decreased leukocyte migration inhibition after phytohemagglutinin stimulation.[2] The degree of the defect correlated with the duration of the warts. Specific cell-mediated immunity to human wart antigen improved transiently with therapy and resolution of the warts and was somewhat dependent on the particular treatment modality.[11]

Indirect evidence for defective cell-mediated immunity in patients with warts accrues from successful therapeutic studies with immune modulating agents. Treatment of several patients with papillomatosis of the larynx (a condition thought to be caused by the same virus as common warts) with transfer factor from a resolved case of papillomatosis led to clinical improvement, change in endoscopic appearance, and a histological alteration of the lesions with an influx of small lymphocytes,[12] although a trial of transfer factor in patients with common warts had no effect.[13] The antihelminthic agent, levamisole, which also restores delayed hypersensitivity in anergic patients[14] has been used to cause regression of warts in a few patients with very resistant lesions.[15] Whether the basis for regression was the immune restorative effect of levamisole or whether it was secondary to other properties of the drug must still be determined.

Although untreated patients with warts and patients cured of warts many years previously both had decreased T cell levels, 11 of the 13 patients in this study who had T cell levels determined both before therapy and again shortly after resolution of the warts demonstrated a rise of T cell levels with treatment. This rise may be similar to the transient "rebound" in T cell levels of patients with malignant neoplasms.[16] After reduction of the tumor burden, their T cell levels transiently rise but then over a period of time decrease to the previously low level. As with tumor-bearing patients, a slow subsequent decrease to a lower percent of T cells may occur in patients with warts and thus would account for the decreased T cell levels found in patients who had been cured of warts for a prolonged period.

In addition to the quantitation of the percentage of rosettes, the morphology of the rosettes may also be important as it may also be a measure of the functional status of the thymus-derived cells. Patients infected by influenza virus have both low T cell counts and rosettes that improve qualitatively with the in vitro addition of thymosin.[8] Of the patients with warts in the present study, approximately one third had many abnormal rosettes, which consisted of T cells binding a minimum number of sheep erythrocytes in a very loosely attached configuration. In contrast, only 9% of normal individuals had similar findings. It can be hypothesized that the failure of T lymphocytes to form tightly bound rosettes may reflect impaired function as effector or killer cells. Thus, E-rosette morphology may give additional insight into the qualitative effect of T cell function in host defense.

The presence of T cell abnormalities in many patients with warts suggests a need for evaluating T cell function in those patients who are especially resistant to the usual therapy and a need for establishing trials for the treatment of such patients with immune stimulating agents.

This study was approved by the Human Research Committee, Georgetown University.

Carolyn M. Cizinsky, MT (ASCP), provided technical assistance.

References

1. Morison WL: Viral warts, herpes simplex and herpes zoster in patients with secondary immune deficiencies and neoplasms. *Br J Dermatol* 92:625-630, 1975.

2. Morison WL: Cell-mediated immune responses in patients with warts. *Br J Dermatol* 93:553-556, 1975.

3. Potvin C, Tarpley JL, Chretien PB: Thymus-derived lymphocytes in patients with solid malignancies. *Clin Immunol Immunopathol* 3:476-480, 1975.

4. Spencer ES, Andersen HK: Clinically evident, non-terminal infections with herpes viruses and the wart virus in immunosuppressed renal allograft recipients. *Br Med J* 3:251-254, 1970.

5. Brodersen I, Genner J, Brodthagen H: Tuberculin sensitivity in BCG vaccinated children with common warts. *Acta Dermatol* 54:291-292, 1974.

6. Pyrhönen S, Johansson E: Regression of warts: An immunological study. *Lancet* 1:592-595, 1975.

7. Blanden RV: T cell response to viral and bacterial infection. *Transplant Rev* 19:56-88, 1974.

8. Scheinberg MA, Blacklow NR, Goldstein AL, et al: Influenza: Response of T cell lymphopenia to thymosin. *N Engl J Med* 294:1208-1211, 1976.

9. Utsinger PD: Lymphocyte changes in viral infections. *Ann Intern Med* 83:82, 1975.

10. Wybran J, Fudenberg HH: Thymus derived rosette forming cells in various human disease states: Cancer, lymphoma, bacterial and viral infections and other diseases. *J Clin Invest* 52:1026-1032, 1973.

11. Morison WL: In vitro assay of immunity to human wart antigen. *Br J Dermatol* 93:545-551, 1975.

12. Quick CA, Behrens HW, Brinton-Darnell M, et al: Treatment of papillomatosis of the larynx with transfer factor. *Ann Otol Rhinol Laryngol* 84:607-613, 1975.

13. Stevens DA, Ferrington RA, Merigan TC, et al: Randomized trial of transfer factor treatment of human warts. *Clin Exp Immunol* 21:520-524, 1975.

14. Ramot B, Biniaminow M, Shoham C, et al: Effect of levamisole on E-rosette-forming cells in vivo and in vitro in Hodgkin's disease. *N Engl J Med* 294:809-811, 1976.

15. Helin P, Bergh M: Levamisole for warts. *N Engl J Med* 291:1311, 1974.

16. Dellon AL, Potvin C, Chretien PB: Thymus-dependent lymphocyte levels in bronchogenic carcinoma: Correlations with histology, clinical stage, and clinical course after surgical treatment. *Cancer* 35:687-695, 1975.

Response of Generalized Granuloma Annulare to Alkylating Agents

Steven Kossard, MB, PhD, R. K. Winkelmann, MD, PhD

• The conditions of three patients who had generalized granuloma annulare responded favorably to treatment with alkylating agents. This mode of therapy in two cases was chosen on the basis of recent evidence that implicates delayed hypersensitivity mechanisms as forming part of the pathogenesis of granuloma annulare. Two patients had rapid clearing of their lesions. The response in one of these patients was observed during therapy for a concomitant plasma cell dyscrasia. The third patient had an unusual form of granuloma annulare that had evolved during a period of 28 years, with hand deformities secondary to fascial and tendon involvement and the production of contractures and lymphedema, which responded partially to therapy. The results lend further support to data implicating cellular immunity in granuloma annulare.

(*Arch Dermatol* 114:216-220, 1978)

Granuloma annulare is a dermal or subcutaneous granuloma of unknown cause whose histopathologic changes involve areas of necrobiosis with a histiocytic reaction that is accompanied by a chronic inflammatory infiltrate. Opinions regarding the pathogenesis of this reaction have varied.[1-3] The character of the infiltrate, the occasional association with sarcoidosis, the development of the reaction after tuberculin skin testing, and the beneficial response after corticosteroids and antimalarial therapy have pointed to mechanisms that involve delayed hypersensitivity. Recently, Umbert et al[4] demonstrated circulating lymphokines to macrophages in the serum of patients with granuloma annulare, and also gave ultrastructural and histochemical evidence of lymphokine activation of macrophages in the lesions of this condition.

We report, as further supportive evidence for the participation of delayed hypersensitivity mechanisms, the resolution of generalized granuloma annulare in three patients who were given alkylating agents.

Accepted for publication Aug 10, 1977.

From the Department of Dermatology, the Mayo Clinic and Mayo Foundation, Rochester, Minn.

Reprint requests to Section of Publications, Mayo Clinic, 200 First St SW, Rochester, MN 55901 (Dr Kossard).

REPORT OF CASES

CASE 1.—A 52-year-old man has been examined at the Mayo Clinic during the past ten years because of progressive granuloma annulare that involves primarily his forearms and hands. The process began as asymptomatic papulonodular lesions that occurred one year after an ulnar nerve injury in 1945 and became concentrated over the dorsal aspect of his hands. Additional areas later involved his elbows and the extensor surface of his forearms. When he was seen at our clinic in 1966, he had numerous discrete erythematous annular lesions with a papular border on his forearms (Fig 1, left), nodular rings with a beaded margin on his hands (Fig 1, right), and papular plaques over his elbows that were associated with juxta-articular subcutaneous nodules.

In 1970, the annular lesions on his forearms had enlarged and coalesced, which made an arciform pattern with erythematous papular margins and atrophic central zones. The process on his hands was more diffuse. There was considerable deformity in his hands secondary to fascial and tendon involvement, with fusiform changes of his fingers and flexion deformities. The deeper subcutaneous involvement was also evident, with the development of palmar induration and nodules. Lesions were noted over both ears, but were absent from his trunk and lower limbs.

Since 1972, his sclerosis had progressed, which resulted in restricted mobility and disability with hand involvement and finally the development of lymphedema, which was more gross over his left hand (Fig 2, left). There were no symptoms of recurrent polyarthritis, and joints that were not surrounded by granuloma annulare were fully mobile. There were no eye or respiratory symptoms, and general medical examination was unrevealing except for these previously mentioned findings.

Results of the following laboratory studies were within normal limits: complete blood cell count, leukocyte count, differential cell count, ESR, complete blood chemistry studies, glucose, lipids, thyroid function, and serologic findings. Serum protein electrophoresis showed a slight increase in the level of α_2-globulin. The rheumatoid factor was negative. A roentgenogram of the chest and the ECG were normal. Roentgenograms of the hands showed enormous soft-tissue swelling on his left hand and right wrist, flexion contractures of the fingers, swan-neck deformity of the second finger of his left hand, and erosions of the carpal bones. These changes were interpreted as consistent with rheumatoid arthritis. Delayed-hypersensitivity skin testing showed positive reactions to *Trichophyton*, *Candida*, and streptokinase,

Fig 1.—Case 1. Left, Lesions of granuloma annulare on forearm (1966). Right, Granuloma annulare on hands (1966).

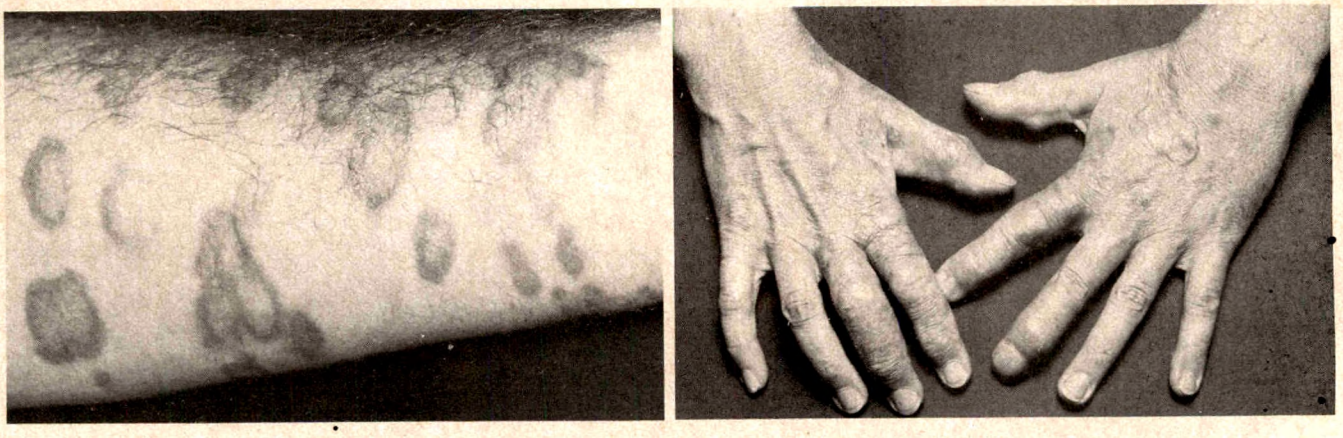

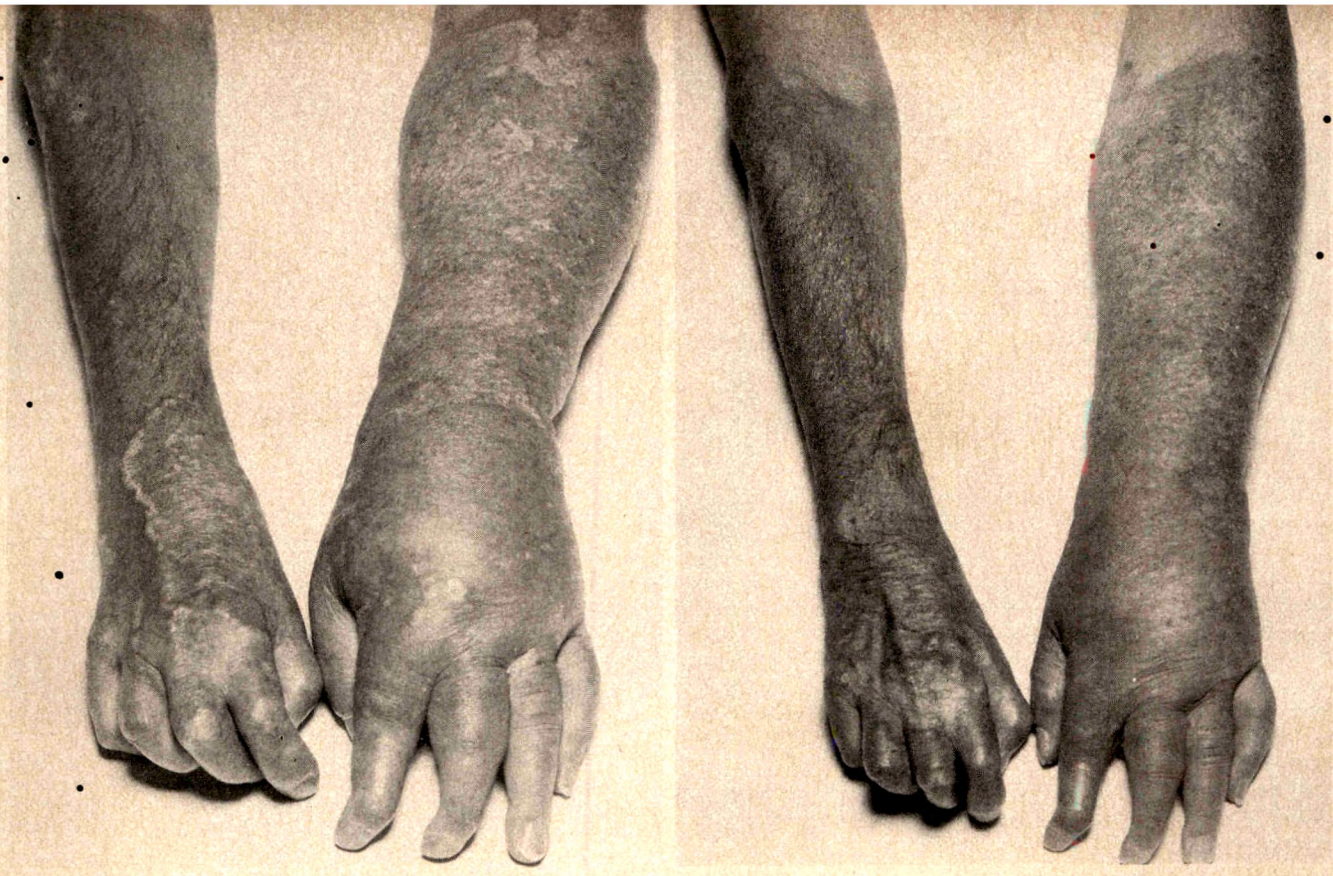

Fig 2.—Case 1. Left, Joint deformities, sclerosis, and lymphedema of hands, with marginated plaques of granuloma annulare of forearms (1975). Right, After therapy with low-dose chorambucil for one year. Note disappearance of marginated active borders of granuloma annulare and diminished edema.

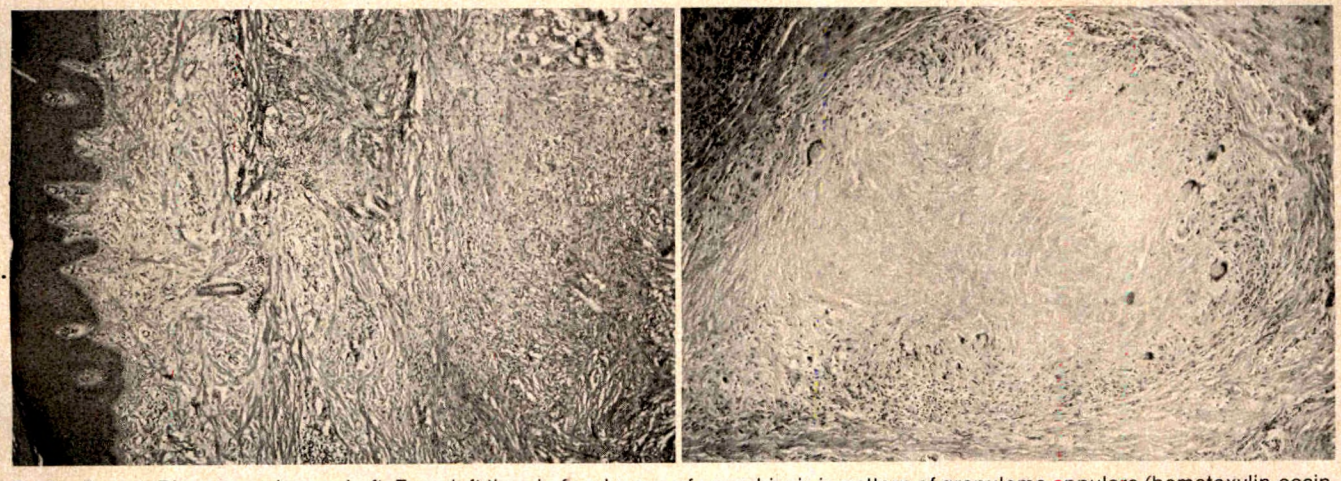

Fig 3.—Case 1. Biopsy specimens. Left, From left thumb, focal areas of necrobiosis in pattern of granuloma annulare (hematoxylin-eosin, original magnification ×160). Right, From left arm, area of necrobiosis with palisading histiocytes and giant cells (hematoxylin-eosin, original magnification ×100).

and negative reactions to purified protein derivative (PPD) and histoplasmin. Cultures of skin biopsy specimens in 1966 and 1975 for tuberculosis, fungi, and anaerobic and general bacteria were negative.

At various times between 1966 and 1975, biopsy specimens also were obtained of a flexor tendon nodule and of a subcutaneous nodule removed from the upper part of the left arm. Some of these specimens were surgically obtained, and they included specimens of deep fascia. All specimens showed granulomas distributed through the dermis, with focal areas of necrobiosis and palisading histiocytes, together with less well-defined collagen degeneration (Fig 3). The diagnosis was granuloma annulare.

In addition to the widespread histiocytic response, there were focal areas of perivascular lymphocytes, scattered giant cells, and occasional plasma cells. Some specimens showed fibrosis and vascular proliferation. Special stains (Fite, silver chromate, PAS-diastase) did not reveal any organisms. Histochemical stains showed palisading collections of lysosomal enzymes (acid phosphatase and esterase).

Treatment between 1966 and 1971 consisted of triamcinolone acetonide injected intralesionally into individual nodules, with minimal response. In May 1971, therapy with isoniazid (100 mg three times a day) and sulfoxone sodium (100 mg twice a day) was started empirically and was continued for one year. In September 1975, the therapy was changed to chlorambucil (2 mg twice a day) because of progressive changes. By February 1976, symptomatic improvement had occurred.

In July the amount of edema of the hands decreased, with softening of the sclerosis and increased mobility of the joints. Most of the plaques and nodules had flattened and lost their inflammatory color

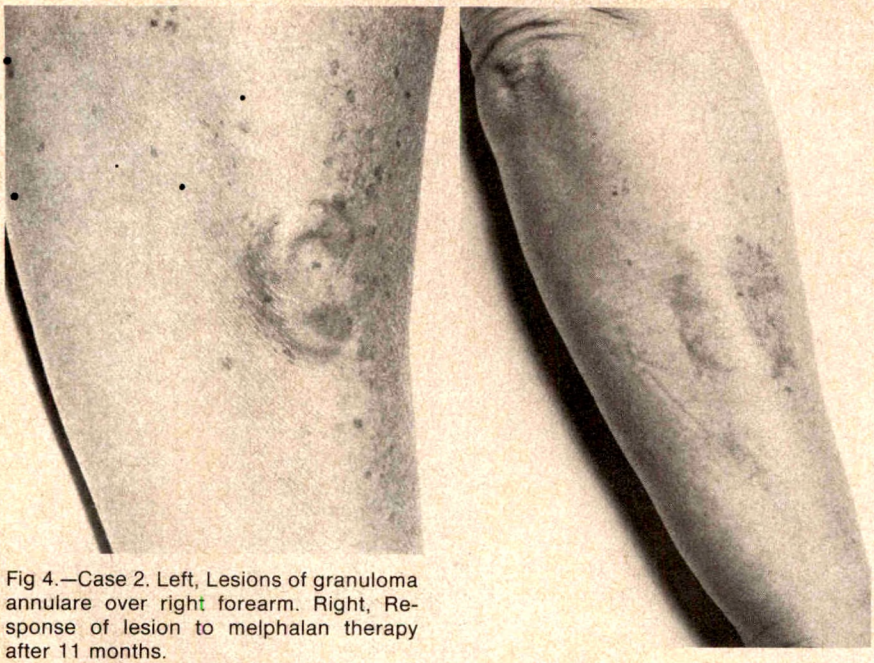

Fig 4.—Case 2. Left, Lesions of granuloma annulare over right forearm. Right, Response of lesion to melphalan therapy after 11 months.

and induration, and many had disappeared (Fig 2, right).

Complicating sclerosis, lymphedema, and hand deformities, such as were seen in case 1, were striking and unusual. Nonetheless, we believe that this patient had granuloma annulare. Classic lesions were present both clinically and histopathologically, but during a 28-year period, deep involvement with granuloma annulare of fascia and tendons occurred and was demonstrated on surgical biopsy specimens. The process was strikingly confined to his upper limbs and ears. Although roentgenograms of the hand were interpreted as being suggestive of rheumatoid arthritis, several features made this unlikely. At no stage were there episodes of recurrent synovitis. Instead, joint changes were insidious in their evolution and paralleled the degree of surrounding fascial and tendon involvement. This was further supported by the complete absence of arthritis and joint changes in areas that were not involved with granuloma annulare, such as the joints of the lower limbs. The bone changes probably represent an extreme manifestation of the depth of tissue involvement of granuloma annulare, which was so unusual in this patient. Although subcutaneous nodules were present over the extensor surfaces of the forearms, these did not show the fibrinoid type of central necrosis typical of rheumatoid nodules; furthermore, repeated tests for rheumatoid factor were negative, and subsequent roentgenograms have not demonstrated progressive joint changes.

Case 2.—A 45-year-old woman was seen at the Mayo Clinic for evaluation of granulomatous skin lesions that had been evolving during a two-year period.

In January 1972, asymptomatic granulomatous plaques had appeared on her right extensor forearm and the left side of her abdomen. A few months later, a subcutaneous swelling developed over the nasal aspect of her orbit. Biopsy specimens of the lesions were variously interpreted elsewhere as showing nonspecific granulomas and foreign-body reaction. The only associated symptoms were some morning stiffness of the lower portion of her back and her knees. Routine investigations were unrevealing except for an elevated sedimentation rate. There was some improvement in the lesions after the intralesional injection of corticosteroids and a short course of orally administered prednisone. The lesions, however, recurred, and in June 1973, a nodular scleritis developed over her right eye. Although this cleared with oral corticosteroid therapy, the plaques persisted. In February 1974, bilateral iritis occurred, which resolved with therapy of local corticosteroid drops.

In May, at her initial visit to our clinic, physical examination showed infiltrated plaques that were 4 × 5 cm on the extensor aspect of her forearm (Fig 4, left) and similar lesions that were 7.5 ×4.5 cm on her abdomen. A subcutaneous swelling was present over the medial aspect of her right orbit. The lesions had a yellowish hue, and the clinical impression was a xanthomatous granuloma with features of granuloma annulare.

Investigations revealed a hemoglobin level of 11.4 gm/100 ml and normal leukocyte and differential cell counts. The sedimentation rate was 109 mm/hr. Quantitative immunoglobulins showed an elevated IgG level of 32.3 mg/ml (normal, 6.4 to 14.3 mg/ml), whereas the levels of IgA and IgM were normal. Special protein studies showed an IgG λ monoclonal protein in the serum, but no monoclonal protein was found in the urine.

A bone marrow aspirate showed mild plasmacytosis, and the bone marrow biopsy specimen showed a diffuse increase in atypical plasmacytes, which is suggestive of a plasma cell dyscrasia. A bone survey did not reveal any lytic lesions. Roentgenograms of the chest showed cervical ribs. A skin biopsy specimen taken from the lesion over the right forearm showed areas of necrobiosis with palisading histiocytes and a granulomatous reaction in the upper dermis. In some areas, the histiocytes resembled those of reticulohistiocytosis. Special stains with Sudan black B showed small amounts of lipid within the histiocytes. No organisms or foreign bodies were found. These changes were interpreted as representing granuloma annulare. The outside tissue was reviewed and was diagnosed as representing granuloma annulare. No treatment was instituted.

The patient's condition was reviewed in January 1975, when the lesion over the nasal aspect of her orbit had enlarged and was associated with pain in her right eye. A new lesion was noted over the right forearm. A repeated bone marrow biopsy specimen showed a diffuse increase in plasma cells, with pleomorphic foci. The monoclonal protein was again demonstrated. Therapy was started with melphalan (10 mg daily) and prednisone (20 mg three times a day) for one week, with the cycles repeated every six weeks.

In April 1975, there was an early response to treatment, with relief of eye symptoms, decreased infiltration of skin lesions (Fig 4, right), and a reduction in the elevated levels of λ-globulin.

By November, the skin lesions had completely resolved and serum electrophoresis showed no abnormalities. Bone marrow examination showed a moderate increase in plasma cells, most of which were mature. Therapy was continued until June 1976. In September, the skin lesions had not recurred, but scattered atypical plasma cells were present on bone marrow examination. The previously elevated globulin levels were now normal, and serum electrophoresis no longer showed a monoclonal protein. However, urine examination now revealed the presence of a small monoclonal λ protein.

This patient had the unusual combination of granuloma annulare and a plasma cell dyscrasia, and the case illustrates the response of the granuloma annulare to therapy with a combination of prednisone and melphalan. The relationship between granuloma annulare and proliferative disorders that involve plasma cells is not defined. Scleromyxedema, which may have an associated monoclonal gammopathy, rarely can be histopathologically confused with granuloma annulare. The initial clinical impression was that of a xanthomatous skin lesion or plane xanthoma rather than granuloma annulare. We do not

dismiss a possible association of granuloma annulare and multiple myeloma, because conditions that have a histiocytic component, such as plane xanthoma,[5] multicentric reticulohistiocytosis,[6] xanthoma disseminatum,[7] scleromyxedema,[8] and sarcoidosis,[9] have occurred in the presence of a monoclonal gammopathy or a malignancy and may form mixed patterns. Alternatively, the two conditions may be unrelated, and the present response could reflect a direct response of granuloma annulare to the therapy.

CASE 3.—A 67-year-old woman was seen at the Mayo Clinic in August 1976 because of a five-year history of recurrent generalized granuloma annulare. In 1971, the process had started as an infiltrated group of papules at the site of an old injury over the left deltoid area. A biopsy specimen was interpreted as sarcoid, and the area was treated with superficial radiotherapy. By the middle of 1971, further lesions had appeared over her right shoulder, right knee, and trunk. The lesions were managed initially with topically applied corticosteroids, but this therapy was changed to hydroxychloroquine and vitamin E after further areas became involved. The larger plaques were injected with steroids. During the next year, the lesions resolved, but resolution was not maintained despite the continued use of hydroxychloroquine. In May 1973, a skin biopsy specimen was interpreted as showing necrobiosis lipoidica. The use of the antimalarial agent was discontinued, and a course of oral corticosteroids was tried for six weeks. Although there was no immediate response, all lesions had resolved five months later.

In December 1975, asymptomatic papules reappeared in a generalized distribution, particularly on the posterior aspect of her thighs, the lower portion of her abdomen, the extensor surface of her arms, and the dorsa of her hands. The lesions did not respond to a second course of orally administered prednisone.

In August 1976, on her initial visit to our clinic, physical examination showed lesions typical of granuloma annulare, with infiltrated papules (Fig 5, top left), which in some areas formed classic annular groups (Fig 5, top right). A biopsy specimen of a lesion over the right forearm revealed focal areas of necrobiosis and a histiocytic infiltrate in the pattern of granuloma annulare.

Results of laboratory studies revealed the following within normal limits: a full blood count, complete blood chemistry studies, including fasting blood glucose, and immunoglobulins. A roentgenogram of the chest showed prominent vessels in the left hilus. The automated reagin test, antinuclear antibody, and rheumatoid factor were negative. Delayed hypersensitivity skin tests were positive for streptokinase, mumps, and *Candida* antigens and were negative for PPD and *Trichophyton* antigen.

Therapy with chlorambucil was started in August at a dosage of 4 mg daily. Within six weeks, there was improvement in all lesions without the development of new areas of involvement. After 12 weeks, all lesions had resolved, and only some atrophic postinflammatory changes remained (Fig 5, bottom left and right).

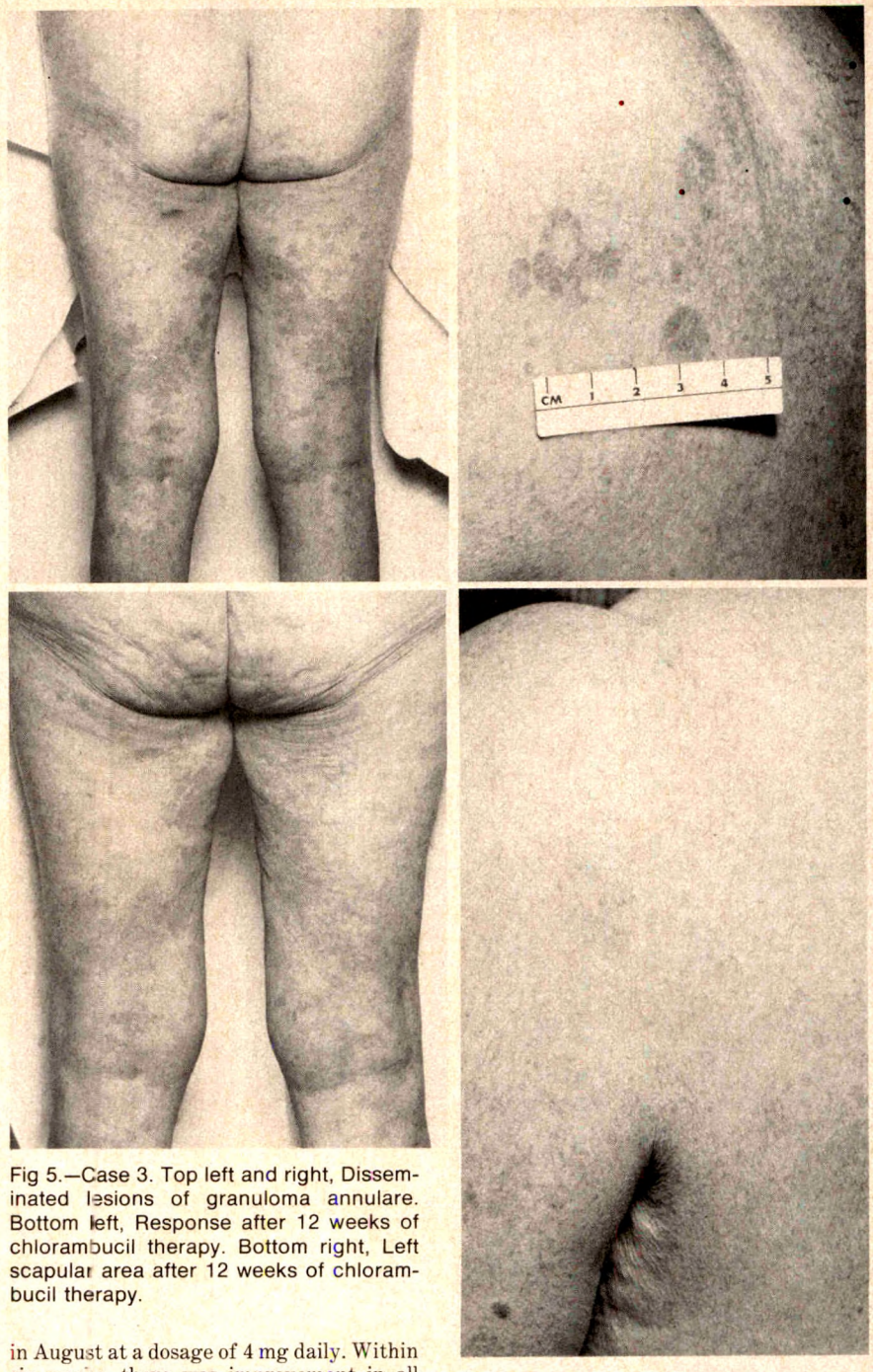

Fig 5.—Case 3. Top left and right, Disseminated lesions of granuloma annulare. Bottom left, Response after 12 weeks of chlorambucil therapy. Bottom right, Left scapular area after 12 weeks of chlorambucil therapy.

This patient had typical generalized granuloma annulare without any complicating factors, and the case best illustrates the response of chronic generalized granuloma annulare to therapy with low-dose chlorambucil, with the prompt response and resolution of all lesions during a 12-week period.

COMMENT

Many modalities have been used to treat granuloma annulare. These include the use of liquid nitrogen, x-rays, gold injections, vitamin E, steroids, and antimalarial agents. Chlorpropamide use and carbohydrate restriction have been reported[10] to be beneficial when diabetes is present. The importance of diabetes in granuloma annulare has been the subject of dispute.[11] To our knowledge, alkylating agents have not previously been used in this condition. Because granuloma annulare may follow a self-limited course and because its pathogenesis has remained uncertain, the effect of such therapy has awaited unusual situations such as reported

herein, ie, patients who require therapy for severe progressive disease or for concomitant conditions.

Many factors have been implicated in the genesis of this reaction, and these include genetic predisposition,[12] trauma, insect bites,[13] autoantibodies,[14] sunlight,[15] and diabetes mellitus. Evidence is accumulating for the involvement of delayed hypersensitivity mechanisms in granuloma annulare. This is not surprising because granuloma annulare was originally considered to be a manifestation of tuberculosis—the very condition from which our present understanding of delayed hypersensitivity evolved.

A relationship to delayed hypersensitivity is supported by the changes in biopsy specimens that revealed histiocytes and mononuclear cells about vessels and among the areas of necrobiosis. Changes in granuloma annulare have developed at the site of tuberculin testing.[16] Improvement of lesions after the use of chloroquine phosphate[17] and corticosteroids also supports this concept. The strongest evidence so far has been the demonstration by Umbert et al[4] that the serum of patients with granuloma annulare can inhibit macrophage migration in vitro. This property was shared by the serum of patients with sarcoidosis, but not by those with necrobiosis lipoidica. This effect probably represented the presence of circulating lymphokines to macrophages that were associated with delayed hypersensitivity. Results of studies on the ultrastructural and histochemical aspects of granuloma annulare[18] have supported the participation of lymphokines. Apart from perivascular collections of lymphocytes, activated macrophages were found between collagen bundles and in areas of necrobiosis. These cells contained increased levels of lysosomes and lysomal enzymes. The capacity of such macrophages to produce collagenase[19] and elastase[20] offers a mechanism for the observed connective tissue changes in granuloma annulare.

The basis for the unusual clinical findings of unilateral sclerosis and lymphedema in our case 1 is unclear, but it reflects a concomitant deep granuloma annulare or sarcoidal reaction. The coexistence of sarcoidosis and granuloma annulare occurs,[21] and the involvement of deep tissues, including muscle and bone, and even the production of lymphedema[22] is well recognized in sarcoidosis.[23] Occasionally, sarcoidosis may be confined to the muscles and may be complicated by contractures.[24] In case 1, the clinical course, the absence of visceral or ocular involvement, the presence of necrobiosis on histopathologic study, and the lack of cutaneous anergy on skin-delayed hypersensitivity testing make this diagnosis unlikely, but a concomitant sarcoidal reaction is not excluded. Subcutaneous linear fibrotic reactions also have been described with rheumatoid arthritis,[25] but for reasons already outlined, this probably was not the primary condition.

The conditions of our patients with generalized granuloma annulare responded favorably to the use of alkylating agents. A response solely on the basis of natural resolution appears to be unlikely because there was a chronic progressive history of granuloma annulare, which was unresponsive to other therapies for more than 20 years in our case 1. One patient's condition (case 3) responded dramatically in six weeks. Although our second patient was given melphalan simultaneously with prednisone therapy, a previous course of prednisone for a complicating scleritis did not resolve the skin lesions.

Chlorambucil influences thymus-dependent lymphocytes both in vitro, where it inhibits blastogenesis induced by phytohemagglutinin,[26] and in vivo in low doses, where it ameliorates the T-cell erythroderma of patients with the Sézary syndrome.[27] The present results, therefore, support the concept that delayed-hypersensitivity pathways have a role in the evolution of granuloma annulare. A response based on the anti-inflammatory effect of chlorambucil is not excluded, and more direct evidence awaits further studies on the effect of chlorambucil on the production of lymphokines in vivo in this condition, and on experimental delayed hypersensitivity.

Although low-dose chlorambucil appears to be effective, this form of therapy is not without risks and requires close supervision. For most patients with granuloma annulare, such therapy is not indicated, but it may offer an approach in patients who have generalized disease with a protracted or disabling course.

Nonproprietary Name and Trademarks of Drugs

Melphalan—*Alkeran, Melsaphine, Meltrol, Melulose, Membrettes.*

References

1. Stankler L, Leslie G: Generalized granuloma annulare: A report of a case and review of the literature. *Arch Dermatol* 95:509-513, 1967.
2. Wells RS, Smith MA: The natural history of granuloma annulare. *Br J Dermatol* 75:199-205, 1963.
3. Dicken CH, Carrington SG, Winkelmann RK: Generalized granuloma annulare. *Arch Dermatol* 99:556-563, 1969.
4. Umbert P, Belcher RW, Winkelmann RK: Lymphokines (MIF) in the serum of patients with sarcoidosis and cutaneous granuloma annulare. *Br J Dermatol* 95:481-485, 1976.
5. Moschella SL: Plane xanthomatosis associated with myelomatosis. *Arch Dermatol* 101:683-687, 1970.
6. Labow TA, Shapiro L: Giant cell reticulohistiocytoma associated with cancer. *NY State J Med* 65:2941-2945, 1965.
7. Maize JC, Ahmed AR, Provost TT: Xanthoma disseminatum and multiple myeloma. *Arch Dermatol* 110:758-761, 1974.
8. Lai a Fat RFM, Suurmond D, Rádl J, et al: Scleromyxoedema (lichen myxoedematosus) associated with paraprotein, IgG, of type kappa. *Br J Dermatol* 88:107-116, 1973.
9. Scadding JG: *Sarcoidosis.* London, Eyre & Spottiswoode Publishers Ltd, 1967, pp 461-462.
10. Haim S, Friedman-Birnbaum R, Shafrir A: Generalized granuloma annulare: Relationship to diabetes mellitus as revealed in 8 cases. *Br J Dermatol* 83:302-305, 1970.
11. Williamson DM, Dykes JRW: Carbohydrate metabolism in granuloma annulare. *J Invest Dermatol* 58:400-404, 1972.
12. Rock A, Davis R, Stevanovic D: Familial granuloma annulare. *Acta Derm Venereol* 37:160-164, 1957.
13. Moyer DG: Papular granuloma annulare. *Arch Dermatol* 89:41-45, 1964.
14. Gross PR, Shelley WB: The association of generalized granuloma annulare with antithyroid antibodies. *Acta Derm Venereol* 51:59-62, 1971.
15. Leppard B, Black MM: Disseminated granuloma annulare: A variant in which the lesions involve the sun-exposed areas. *Trans St John Hosp Dermatol Soc* 58:186-190, 1972.
16. Beer WE, Wilson Jones E: Granuloma annulare following tuberculin Heaf tests. *Trans St John Hosp Dermatol Soc* 52:68-70, 1966.
17. Mandel EH: Disseminated granuloma annulare: Report of a case treated with chloroquine phosphate (Aralen). *Arch Dermatol* 79:352-353, 1959.
18. Umbert P, Winkelmann RK: Histologic, ultrastructural, and histochemical studies of granuloma annulare. *Arch Dermatol* 113:1681-1686, 1977.
19. Wahl LM, Wahl SM, Mergenhagen SE, et al: Collagenase production by lymphokine-activated macrophages. *Science* 187:261-263, 1975.
20. Werb Z, Saimon G: Elastase secretion by stimulated macrophages. *J Exp Med* 142:361-377, 1975.
21. Umbert P, Winkelmann RK: Granuloma annulare and sarcoidosis. *Br J Dermatol*, to be published.
22. Nathan MPR, Pinsker R, Chase PH, et al: Sarcoidosis presenting as lymphedema. *Arch Dermatol* 109:543-544, 1974.
23. Brun A: Chronic polymyositis on the basis of sarcoidosis. *Acta Psychiatr Scand* 36:515-523, 1961.
24. Warburg M: A case of symmetrical muscular contractures due to sarcoidosis. *J Neuropathol Exp Neurol* 14:313-315, 1955.
25. Dykman CJ, Galens GJ, Good AE: Linear subcutaneous bands in rheumatoid arthritis: An unusual form of rheumatoid granuloma. *Ann Intern Med* 63:134-140, 1965.
26. Bontoux D, Kahan A, Brouilhet H, et al: Effect and mode of action of chlorambucil in rheumatoid disease: Value of the lymphoblast transformation test. *Rev Rhum Mal Osteoartic* 38:759-764, 1971.
27. Winkelmann RK, Perry HO, Muller SA, et al: Treatment of Sezary syndrome. *Mayo Clin Proc* 49:590-592, 1974.

Ultraviolet Phototherapy and Photochemotherapy of Acne Vulgaris

Otto H. Mills, MA, Albert M. Kligman, MD, PhD

• The therapeutic value of various ultraviolet treatments was assessed in patients with moderately severe papulopustular acne.

The results did not verify the common belief that ultraviolet radiation is highly beneficial. In no instance was the comedo count appreciably reduced. Modest improvement was observed with sunburn rays (UV-B) and slightly more with the combination of long ultraviolet radiation (UV-A) and UV-B. UV-A alone had the least effect.

Photosensitization with coal tar and UV-A greatly aggravated acne and was notably comedogenic. Photosensitization with methoxsalen (8-methoxypsoralen) applied topically was neither harmful nor helpful.

(*Arch Dermatol* 114:221-223, 1978)

There is well-nigh universal agreement that sunlight is beneficial in moderating acne vulgaris. Teenagers generally enthusiastically endorse heliotherapy, claiming that improvement occurs within a few days of intensive sun exposure. Adolescents are among the most devout practitioners of the sun-worship cult.

Physicians, too, are generally persuaded that sunlight is good for acne. Patients are commonly counseled to get out into the sun as much as possible. Moreover, many dermatologists routinely use ultraviolet radiation as an adjunctive measure.

We are on record in warning against the early deleterious effects of excessive sun exposure on the skin of white children. No other common environmental factor is as hazardous to skin as sunlight.[1-3]

We have found no studies that prove that the high esteem for sunlight in acne therapy is well founded. The risk-to-benefit ratio therefore cannot be estimated. Our skepticism about the therapeutic effects of sunlight grew out of the following observations.

First, a total of 207 patients with acne were asked whether sunlight was helpful to them. The majority had no doubt that it was. To our great surprise, about one fifth declared sunlight to be harmful. These were generally persons of rather light complexion who tended to sunburn easily. Nonetheless, some were good tanners and not especially vulnerable to sunburn. The persons with sunlight-aggravated acne reported that a few days of intensive midday exposure would produce a crop of papulopustules; thus, they almost all avoided sunlight as much as possible.

Second, in a previous study, intensive irradiation with sunburn rays (UV-B) did not reduce open comedones of the back induced by the application of crude coal tar. The skin peeled prodigiously but the comedones would not budge (unpublished observations, 1973).

Third, certain sunscreens have been reported to cause an acneiform eruption.[4] It is possible that sunlight contributed to acnegenicity.

In this report, we have used artificial ultraviolet sources, with and without photosensitizing drugs, to assess the value of phototherapy in acne.

MATERIALS AND METHODS

The subjects were clinic patients with moderately severe papulopustular acne and with variable amounts of open and closed comedones. The patients used no medication during and four weeks before the study, which took place in the winter. Two prestudy clinic visits were required of each candidate to assure relative stability of the disease. Only the face was treated. Exposures were twice weekly for eight weeks. A total count of lesions was done before and a few days after the last exposure. Improvement was scored as excellent, good, fair, poor, or worse according to our published criteria.[5] UV-B dosage was individually adjusted with the aim of increasing the exposures as rapidly as possible to induce erythema and peeling. A minimum erythema dose (MED) was determined on all patients before beginning. Initial exposures were 2 to 3 MEDs. We began cautiously with persons of light complexion who stated that they sunburned easily and tanned poorly. Quick, deep tanners accordingly received far larger quantities of radiation. Regardless of original sensitivity, the final dose was generally three to five times greater than the first one. The eyes

Accepted for publication Sept 8, 1977.

From the Department of Dermatology, University of Pennsylvania School of Medicine, Philadelphia.

Reprint requests to Department of Dermatology, University of Pennsylvania, 3500 Market St, Philadelphia, PA 19104 (Mr Mills).

were protected by cloth during the exposures.

Light Sources

A special reflecting housing was constructed in the shape of an arc containing eight fluorescent bulbs, each 2 feet long. This permitted all areas of the face to be more or less evenly irradiated. Erythemic radiation (UV-B) was obtained from sunlamps (Westinghouse FS 20 fluorescent) that emit a continuous spectrum of between 280 and 340 nm.[6] Long ultraviolet radiation (UV-A) was obtained from fluorescent blacklights (Westinghouse), with peak intensity at about 360 nm.[6]

RESULTS

Study 1: Fluorescent Sunlamps (UV-B)

The 27 patients in this group experienced intense peeling and varying degrees of erythema, which occasionally were severe. We observed no appreciable change in the quantity of open and closed comedones. Pustules declined in number the first few weeks and stayed stable thereafter (Table). Thus, while some improvement occurred, the effects were decidedly less than could be expected with either benzoyl peroxide or tretinoin (Fig 1 and 2).[7]

Study 2: Fluorescent Blacklight (UV-A)

Fifteen patients were treated with this more penetrating radiation. The initial exposure time was 30 minutes, increasing each time by five-minute increments to a top limit of 45 minutes by three weeks. Tanning of variable degree was induced in most patients.

While most subjects seemed to think that the therapy was quite helpful, we ourselves noted appreciable benefit in only two (Table). The tan made the lesions less conspicuous and was also cosmetically pleasing.

The comedo count did not decrease and indeed moderately increased in six of the 15 patients.

Study 3: Combination Therapy With UV-B and UV-A

This group of 34 patients received ascending doses of UV-B followed each time by 45 minutes of blacklight exposure. The addition of UV-A intensifies the sunburn reaction, a phenomenon termed photoaugmentation.[8] We judged that the results were only slightly better than UV-B alone. About one third improved moderately; none were rated excellent. Comedones were not affected (Table); (Fig 2, left and right).

Percentage Reduction of All Countable Lesions at Eight Weeks

Study	Excellent, 75%-100%	Good, 50%-74%	Fair, 26%-49%	Poor, 25%-0%	Worse
1: sunlamp (UV-B) (N = 27)	0	19	44	26	11
2: blacklight (UV-A) (N = 15)	0	13	20	27	40
3: UV-A + UV-B (N = 34)	0	30	40	15	15
4: photochemotherapy with demeclocycline hydrochloride (N = 25)	8	32	40	8	12
5: coal tar photosensitization (N = 14)	0	7	21	0	72
6: 8-MOP* photosensitization (N = 11)	0	18	36	46	0

*8-MOP indicates methoxsalen (8-methoxypsoralen).

Fig 1.—Left, Before exposure to fluorescent sunlamp. Right, Poor results after eight weeks.

Fig 2.—Left, Before exposure to combination of fluorescent sunlamps and blacklights. Right, Poor results after eight weeks.

Study 4: Photochemotherapy With Demeclocycline Hydrochloride

Twenty-five patients received demeclocycline hydrochloride 600 mg daily for eight weeks. The exposure was 45 minutes of fluorescent blacklights (UV-A). The majority unequivocally improved but it was not evident to us that the results were any better than what we usually secure with full doses of demeclocycline alone. Two persons experienced a frank phototoxic reaction toward the end; both became worse.

Study 5: Photosensitization With Crude Coal Tar

Five percent crude coal tar in hydrophilic ointment USP was rubbed over the faces of 14 subjects two hours before exposure to fluorescent blacklights, the ultraviolet dose being adjusted according to individual tolerance. The skin was kept in an inflamed state with considerable redness and peeling. Tanning was prominent in most. The conditions of ten of these 14 subjects became noticeably worse. All lesions increased, especially comedones. Nodulocystic lesions responded at first, but later new ones emerged.

Study 6: Photosensitization With Methoxsalen (8-Methoxypsoralen [8-MOP])

One tenth percent of 8-MOP in propylene glycol and alcohol was applied to 11 subjects two hours before three- to five-minute exposures to UV-A. Strong peeling was evident in all while in about half a deep tan developed. The results were very different than with coal tar. No subject's condition worsened, and in two of the 11 it improved moderately. Nonetheless, the overall results were unimpressive.

COMMENT

The six light programs we evaluated in small groups of patients with acne qualify only as preliminary investigations. We believe that with well-selected patients having numerous inflammatory lesions (papulopustular acne), experienced observers can confidently decide whether a treatment is beneficial.

The various light regimens did not yield results that would warrant further study. Our value system is based not on whether improvement occurs, but whether it is of a degree comparable to therapies of established value, notably antibiotics, benzoyl peroxide, and tretinoin. A total of 70% to 90% of the patients in the groups (except study 4) were classified as having fair to poor results, an outcome we have come to accept with placebos. Comedones were not at all influenced. Such improvement as did occur was usually after the first two or three treatments, mainly evident as a drying up of pustules. Small nodules often seemed to have been helped but not as crisply as with cryotherapy and certainly not nearly as much as with intralesional corticosteroids. Coal tar phototherapy was indisputably harmful. Apparently, the dynamics of the phototoxic reaction failed to prevail over the acnegenicity of the coal tar.

"Drying" effects were noted only by treatments that induced erythema. We attribute drying to scaling and not to a decrease in sebum outflow.

Of the three phototherapies studied (studies 1, 2, and 3) UV-A was the least beneficial. Initially, we entertained the notion that porphyrins secreted by *Propionibacterium acnes* might be photosensitizing and consequently UV-A might have some effect. Some subjects tanned rather well after exposure to UV-A and especially after psoralen therapy. The pigmentation was perceived as having positive cosmetic value. By combining UV-B and UV-A we hoped to take advantage of photoaugmentation with radiation more nearly resembling sunlight. Our expectations were not fulfilled. Sunburn radiation was also discouraging.

It would be foolish to conclude from these studies that sunlight has no ameliorating effect on acne vulgaris. We did not evaluate sunlight, only ultraviolet radiation of different spectral qualities. However, it is a fair inference that it is not only the ultraviolet portion of sunlight that accounts for therapeutic benefit. One could also argue that twice-weekly exposures for eight weeks does not resemble the schedule of the typical sunbather who exposes himself for many hours day after day. Nonetheless, we consider our findings substantive enough to give pause to those who believe strongly in the therapeutic value of sunbathing.

Our current attitudes and practices may be summarized as follows. First, along with questions about exogenous factors that aggravate acne, such as soaps,[9] cosmetics,[10] mechanical forces,[11] we routinely inquire about the effects of sunlight. We advise daily use of sunscreens for those who think they are made worse. Indeed, we have repeatedly encountered patients who do not respond well to conventional treatments until they either stay out of the sun or use sunscreens. Sunscreens containing *p*-aminobenzoic acid or its esters are very suitable for this purpose.[12]

Second, intense sunlight exposure often brings about quicker resolution of papulopustules in much the same way as other traditional peeling agents, namely, sulfur, cryotherapy, phenolics, etc. The patient perceives immediate effects and is therefore gratified, and the ensuing tan implements belief in the worth of the treatment. Nonetheless, we have argued in the case against sulfur[13]; the course of the disease is not appreciably altered. New comedones continue to form and to blow up into pustulopapules. The latter can be mopped up more quickly, thus trapping the victim into the persistent use of a modality that encourages the formation of comedones.

The treatment of acne by sunlight is a complex phenomenon. Some of the supposed beneficial effects may be due to infra-red radiation, tranquilization and reduction in emotional stress, unknown effects on androgen secretion or end organ responsiveness, or enhanced cutaneous blood flow and "hardening" of the skin to inflammatory stimuli. Finally, the well-known tendency for acne to improve in summertime may be influenced by a number of associated factors rather than by sunlight itself. Just as with dandruff ("summertime decline"),[14] and hair loss (increased loss in the fall),[15] there may be cyclical patterns in cutaneous functions such as sebum secretion, keratinization, general reactivity, etc. Any or all of these could modify the processes that determine the expression of the disease.

In any event, it has not come to our attention that dermatologists in areas of high isolation have any lack of patients with acne. And, of course, tropical acne is a devasting disease. All things considered, we hold that the baleful effects of sunlight on skin outweigh the modest benefits of sunlight on acne.

Nonproprietary Name and Trademarks of Drug

Benzoyl peroxide—*Benoxyl, Oxy-5, Persadox.*

References

1. Howell JB: The sunlight factor in aging and skin cancer. *Arch Dermatol* 82:865-869, 1960.
2. Urbach F, Davies RE, Forbes PD: Ultraviolet radiation and skin cancer in man, in Montagna W (ed): *Advances in Biology of the Skin—Carcinogenesis.* London, Pergammon Press, 1966, vol 3, chap 12.
3. Kligman AM: Early destructive effect of sunlight on human skin. *JAMA* 210:2377-2380, 1969.
4. Jadassohn W, Paillard R, Hunziker N, et al: Keratose folliculaire "epidemique." *Dermatologica* 127:152-169, 1963.
5. Mills OH Jr, Marples RR, Kligman AM: Acne vulgaris: Oral therapy with tetracycline and topical therapy with vitamin A. *Arch Dermatol* 106:200-203, 1972.
6. Task Force Report: Report on ultraviolet light sources: Report by the Task Force on photobiology of the national program for dermatology. *Arch Dermatol* 109:833-839, 1974.
7. Kligman AM, Fulton JE Jr, Plewig G: Topical vitamin A acid in acne vulgaris. *Arch Dermatol* 99:469-476, 1969.
8. Willis I, Kligman AM, Epstein J: Effects of long ultraviolet rays on human skin: Photoprotective or photoaugmentative. *J Invest Dermatol* 59:416-420, 1973.
9. Mills OH Jr, Kligman AM: Acne detergicans. *Arch Dermatol* 111:65-68, 1975.
10. Kligman AM, Mills OH: "Acne cosmetica." *Arch Dermatol* 106:843-850, 1972.
11. Mills OH Jr, Kligman AM: Acne mechanica. *Arch Dermatol* 111:481-483, 1975.
12. Willis I, Kligman AM: Aminobenzoic acid and its esters: The quest for more effective sunscreens. *Arch Dermatol* 102:405-417, 1970.
13. Mills OH, Kligman AM: Is sulfur helpful or harmful in acne vulgaris? *Br J Dermatol* 86:620-627, 1972.
14. Kligman AM, Marples RR, Lantis LR, et al: Appraisal of efficacy of anti-dandruff formulations. *J Soc Cosmet Chem* 25:73-91, 1974.
15. Orentreich N: Scalp hair replacement in man, in Montagna W, Dobson R (eds): *Advances in Biology of the Skin.* Oxford, England, Pergammon Press, 1969, pp 99-108.

The Glucagonoma Syndrome

A Distinctive Cutaneous Marker of Systemic Disease

Keith H. Swenson, MD; Robert B. Amon, MD; Jon M. Hanifin, MD

• The glucagonoma syndrome is a rare clinical condition characterized by a distinctive cutaneous eruption associated with a glucagon-secreting islet cell neoplasm of the pancreas. A 19-year-old woman manifested typical features of this condition: a polymorphous skin eruption with characteristic distribution of lesions in perioral and paragenital regions; lesions in sites of cutaneous trauma; a skin biopsy that showed epidermal cleavage; glossitis; weight loss; mild anemia; abnormal glucose tolerance test results. Plasma glucagon levels, determined by radioimmunoassay, were approximately five times normal. Angiography indicated a pancreatic tumor with liver metastases. Islet cell origin was confirmed histologically.

It is hoped that wider recognition of the distinctive clinical features of this syndrome will result in earlier detection and possible surgical cure of the underlying malignancy.

(*Arch Dermatol* 114:224-228, 1978)

Cutaneous syndromes associated with internal malignancies are well known to dermatologists. The importance of recognizing these syndromes rests with the subsequent search for a potentially curable neoplasm.

In 1942, Becker et al first described the association of a distinctive cutaneous eruption with an islet cell carcinoma of the pancreas.[1] Others have subsequently described similar cases.[2-10] McGavran et al, in 1966, were the first to associate the bizarre skin lesions specifically with a glucagon-secreting alpha cell carcinoma of the pancreas.[2] Mallinson et al have subsequently described a group of such patients under the designation "glucagonoma syndrome."[7]

Accepted for publication March 10, 1977.

From the Department of Dermatology, University of Oregon Health Sciences Center, Portland.

Reprint requests to Department of Dermatology, University of Oregon Health Sciences Center, 3181 SW Sam Jackson Park Rd, Portland, OR 97201 (Dr Hanifin).

We report the case of a young woman who was admitted with a cutaneous eruption typical of the glucagonoma syndrome. She was found to have a glucagon-producing tumor of the pancreas with metastases to the liver. Increased awareness of the distinctive dermatologic features of this syndrome should result in earlier recognition of this unique disorder and subsequent earlier detection of the associated neoplasm.

REPORT OF A CASE

In July 1974 a previously healthy 19-year-old woman developed a pruritic vesicular skin eruption over the ankles. The initial diagnosis was contact dermatitis. Treatment with orally administered prednisone produced improvement but the condition relapsed after cessation of prednisone therapy and she was referred to the University of Oregon Health Sciences Center. On admission the patient complained of severe pruritus and mild fatigue but no other symptoms. There was no anorexia nor weight loss. Past history showed hospitalization for depression two years previously. Frequent vaginal yeast infections had been noted. Her mother and a 21-year-old sister had a history of abnormal glucose tolerance and a maternal aunt had diabetes mellitus.

The patient was noted to have a widespread polymorphous skin eruption (Fig 1 through 6) consisting of erythematous papules, plaques, and annular lesions, with vesiculation, exfoliation, crusting, and hyperpigmentation. Lesions were worst over the perioral and paragenital areas, hands and feet, and sites of cutaneous trauma. The tongue was smooth and red; *Candida albicans* was cultured from white surface patches. Laboratory studies showed a normal hemogram, sedimentation rate, and blood chemistry screen. Urine study results (including urinary amino acid screen) were all within normal limits. Results of an oral glucose tolerance test were normal but glycosuria was noted (Table 1). Patch testing to common contactants gave no positive results. Intradermal tests showed positive delayed responses to streptokinase-streptodornase and to mumps antigens, while candidin and trichophytin tests were negative. Several skin biopsy specimens showed only mild lymphocytic vasculitis in the upper reticular dermis. Direct immunofluorescence was negative. The patient was presented to a dermatology conference where suggested diagnoses included erythema multiforme, pityriasis lichenoides, systemic lupus erythematosus, pemphigus erythematosus, keratosis follicularis, allergic contact dermatitis, dermatitis herpetiformis, and cutaneous vasculitis. Treatment with prednisone (60 mg/day) produced clearing of her eruption, but her skin lesions returned one week after discontinuing prednisone therapy.

On readmission to the hospital in October 1974, physical findings were similar to those described previously. Laboratory evaluation, including a glucose tolerance test (Table 1), showed no abnormalities. Further skin biopsies showed mild lymphocytic vasculitis, but direct immunof-

Fig 1.—Facial involvement was accentuated in the perioral and perinasal areas. The tongue was markedly erythematous.

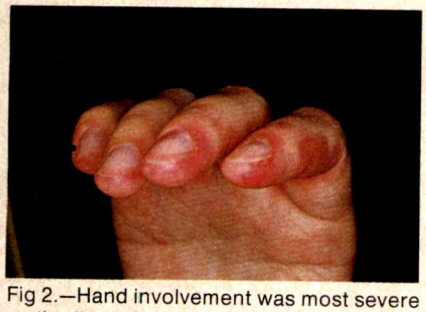

Fig 2.—Hand involvement was most severe on the fingertips, with a superficial erosive process.

Fig 3.—Inner thigh involvement showed erythematous plaques with pustules and scaling.

Fig 4.—The medial part of the foot and ankle displayed an irregularly marginated erythematous scaly plaque with some purpura.

Fig 5.—Annular truncal lesions were prominent during part of the illness. (Black and white contrast is heightened by previous potassium permanganate applications.)

Fig 6.—Erosive involvement of the legs and feet was severe late in the course. (Black and white contrast is heightened by previous potassium permanganate applications.)

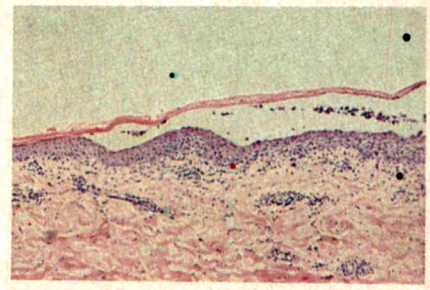

Fig 7.—Skin biopsy specimen showed intraepidermal cleavage (hematoxylin-eosin, ×100).

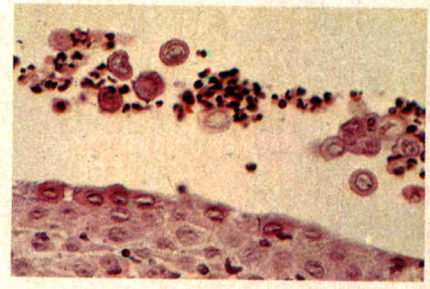

Fig 8.—Intraepidermal vesicles seen in Fig 7. Acantholytic epidermal cells as well as neutrophils and mononuclear cells were present (hematoxylin-eosin, ×450).

Table 1.—Plasma and Urine Glucose Levels After 100 gm D-Glucose Orally

	mg/100 ml					
	0	30	60	90	120	190
September 1974						
Plasma	74	158	92	110	86	70
Urine	0	1+	4+	0	0	0
October 1974						
Plasma	68	101	124	120	125	84
Urine	0	0	0	0	0	0
June 1975						
Plasma	91	218	191	155	121	86
Urine	0	3+	3+	3+	0	0

fluorescence studies from an erythematous papule on the thigh and from a vesicle in the foot now showed granular deposits of C3 present at the dermal-epidermal junction and around blood vessels. Normal skin immunofluorescence was negative. Antinuclear antibody was negative and total hemolytic complement was normal. The patient developed erosive cutaneous lesions in areas of trauma, such as sites of tape application and vena puncture and around waistband areas of rubbing and scratching. She continued to be treated intermittently with orally administered prednisone, but skin lesions reappeared each time the drug therapy was tapered. She continued to feel well, except for periods of mental depression.

In May 1975 the patient was evaluated at another medical center where nickel and chromate allergies were observed and *Candida vaginitis* was diagnosed. No specific diagnosis was given for her skin condition and she returned to the University of Oregon Health Sciences Center where in June 1975 a weight loss of approximately 4.5 kg over a six-week period was recorded. Review of a skin biopsy specimen taken from an erythematous papulovesicular lesion by her private physician showed a cleft high in the malpighian layer forming a blister cavity (Fig 7). Acantholytic epidermal cells as well as neutrophils and lymphocytes were present within the bulla (Fig 8). At this time, because of the distinctive cutaneous and histologic fea-

Table 2.—The Glucagonoma Syndrome Compared With Other Metabolic Disorders Having Similar Cutaneous Morphology

	Glucagonoma Syndrome[1,9]	Acute Zinc Deficiency Secondary to Hyperalimentation[13,14]	Acrodermatitis Enteropathica[12]	Kwashiorkor[15]	Malabsorption States[16]
Erosive periorificial skin lesions	+	+	+	+	+
Nail dystrophies	+	+	+	+	+
Alopecia	–	+	+	+	+
Glossitis	+	+	+	+	+
Diarrhea	+	+	+	+	+
Psychic disturbances	+	+	+	+	+
Weight loss	+	+	+	+	+
Normocytic normochromic anemia	+	+	–	+	+
Increased prevalence of infections	+	?	+	+	+
Elevated serum glucagon level	+	?	?	?	?
Abnormal glucose tolerance	+	?	–	+	+
Decreased serum zinc level	–	+	+	?	?
Glycosuria	+	?	?	?	?

tures, the glucagonoma syndrome was first suspected. An oral three-hour glucose tolerance test and simultaneous plasma glucagon levels were obtained. Peak plasma glucose levels were elevated and the plasma glucagon levels, measured by radioimmunoassay, ranged from 382 to 504 pg/ml, up to five times normal.

On further examination the patient was noted to be mildly anemic and the corrected erythrocyte sedimentation rate was elevated (34 mm/hr). Serum and hair zinc determinations and a complete serum chemistry screen were negative. Visceral angiography showed extensive metastatic disease of the liver with displaced blood vessels in the tail of the pancreas. Liver scan showed a mildly enlarged liver with patchy decrease in radioisotope uptake. Exploratory laparotomy showed a 1.5-cm primary tumor in the tail of the pancreas, along with multiple metastatic nodules in both lobes of the liver. A partial pancreatectomy and splenectomy were performed. Pathologic examination indicated islet cell carcinoma in the pancreas, liver, and adjacent lymph nodes. Electron microscopic examination showed cells containing two types of granules: one resembled alpha cell granules, while the other resembled delta cell granules. Immunofluorescent studies confirmed the presence of glucagon but failed to indicate somatostatin or insulin in tumor tissue.

The patient was treated with combined chemotherapy (fluorouracil and tubercidin). Except for a brief flare of cutaneous lesions postoperatively, she has remained asymptomatic and the tumor has shown no increase in size during a ten-month follow-up period.

COMMENT

Literature Review

Becker et al, in 1942, first described the association of a distinctive cutaneous eruption with an islet cell carcinoma of the pancreas.[1] Their patient, a 45-year-old woman, was admitted with an eight-month history of a widespread pruritic eruption that began on her feet and spread to involve her face, trunk, fingers, groin, vulva, and perianal region. The rash was described as erythematous, papular, and vesicular with areas of annular erythema and purpura. Superficial necrosis of the skin that progressed to crusting and healing with hyperpigmentation was prominent. Associated features included a sore tongue, weight loss, and a diabetic glucose tolerance curve.

In 1966, McGavran et al described a 42-year-old diabetic woman with an unusual "bullous and eczematoid dermatitis of the hands, feet and legs."[2] A metastatic alpha cell carcinoma of the pancreas containing large amounts of glucagon was found and glucagonemia was shown. Church and Crane, in 1967, described a 61-year-old woman with erythematous plaques and superficial necrosis of the skin, combined with a smooth, red tongue, glucose intolerance, anemia, and weight loss.[3] Skin biopsy showed detachment of the upper malpighian stratum with formation of a subcorneal blister without significant acantholysis. Autopsy showed an islet cell carcinoma located in the body of the pancreas with hepatic and lymph node metastases. Wilkinson later used the term "necrolytic migratory erythema" to describe the cutaneous features of a similar case.[4]

In 1974, Sweet described the only surgical cure of such a syndrome.[6] He described a 50-year-old woman who was admitted with a dermatosis characteristic enough to suggest the presence of an islet cell glucagon-secreting tumor. Laparotomy showed the tumor, which was surgically removed with complete resolution of her skin rash as well as normalization of her glucose tolerance curve. Mallinson et al,[7] in 1974, reported their experience with nine patients, including those described by Wilkinson and Sweet. This study delineated several characteristic features of this disorder that Mallinson termed the glucagonoma syndrome. Most recently, Freedberg discussed a case of the glucagonoma syndrome in a *New England Journal of Medicine* clinicopathological exercise.[8] This description alerted us to the correct diagnosis in our patient.

Syndrome Review

At this point it is instructive to compare the findings of Mallinson et al[7] and others[2,3,8-10] with the features noted in our patient.

Age.—The age of onset of the rash in Mallinson's series ranged from 48 to 65 years. Our patient is the youngest so far described. She was 19 years at the onset of her cutaneous eruption. Youth, therefore, should not prevent one from considering the glucagonoma syndrome.

Sex.—The glucagonoma syndrome appears to be predominantly a disease of women. Among the 15 cases reviewed here,[2,3,7,8-10] only four have been men. Whether there is truly a female predisposition cannot be determined on the basis of so few cases.

Distribution of Cutaneous Involvement.—The rash of the glucagonoma syndrome has a characteristic distribution. It is usually widespread, but major sites of involvement are the perioral and paragenital regions, along with fingers, legs, and feet. An interesting feature of this disease that may in part explain this distribution is the predilection for lesions to occur in sites of cutaneous trauma. For example, our patient developed lesions in sites of tape application and on the dorsal feet where her shoes rubbed. Cutaneous trauma could also

explain the involvement of intertriginous areas and fingertips.

Nature of Skin Changes.—The basic process in the skin seems to be one of very superficial epidermal necrosis with fragile blister formation, denudation, crusting and healing with hyperpigmentation. Mallinson offers the following description of this process:

> Lesions began as erythematous areas. They became raised with superficial central blistering, which ruptured early to leave crusts or, in areas exposed to friction, such as the groins or feet, a weeping surface. The lesions tended to heal in the center while the edge spread with a red crusting well-defined edge in an annular or figurate outline. The merging of separate plaques led to a gyrate pattern. Healing was commonly associated with hyperpigmentation. The whole sequence usually took 7 to 14 days to complete. And while some lesions were developing, others were healing, leaving a complex pattern of erythema, epidermal separation and crusting together with normal skin.[7]

We were impressed by the polymorphous nature of our patient's skin lesions. On her face she often had perioral, erythematous papules and plaques with crusting. Her fingertips showed areas of reddish-brown discoloration with very superficial scaling, although no nail changes were present. The lower part of her back, her abdomen, and her buttocks displayed a pattern of annular and figurate erythema. Intertriginous areas such as the natal cleft and inner thighs often presented a weeping, oozing dermatitis. Areas suggestive of purpura were present on the lower part of both legs and on the feet, causing us to entertain a diagnosis of vasculitis, and small fragile vesicles appeared at various areas.

Occasional follicular pustules were seen. Multiple KOH preparations as well as viral, bacterial, and fungal cultures were done. *Staphylococcus aureus* was isolated on more than one occasion from cutaneous pustules. *Candida albicans* was also isolated from cutaneous lesions as well as from the mouth and the vagina. Viral studies were negative. Becker et al demonstrated "monilia" in nail scrapings and cultured the same organism from the corner of the mouth, groin, and tongue in their patient. These organisms probably played no primary role in the pathogenesis of this disease but more likely represented an opportunistic infection predisposed by open skin and/or decreased host resistance.

Skin Biopsy Findings.—Several skin biopsy specimens were obtained from our patient. Initially they showed only a mild lymphocytic vasculitis. One, however, revealed a subcorneal bulla containing acantholytic epidermal cells as well as neutrophils and lymphocytes. The adjacent epidermis was intact. The dermis contained a slight, primarily lymphocytic, perivascular infiltrate. These findings are consistent with the description given by Mallinson, although he noted no acantholysis. Biopsy examination of a fresh skin lesion, therefore, may be a valuable aid in establishing the diagnosis of the glucagonoma syndrome.

Glossitis.—Eight of Mallinson's nine patients had a sore tongue. Our patient noted this throughout her course. Physical findings were subtle but definite; the tongue was erythematous and mildly atrophic. *Candida albicans* was cultured on only one occasion and it appears that *Candida* infection is only an occasional accompaniment of the glucagonoma syndrome.

Weight Loss.—All of Mallinson's patients noted weight loss, presumably due to the catabolic effects of their malignancy. Our patient experienced a 4.5-kg weight loss over a six- to eight-week period just prior to the discovery of her neoplasm. Early in her course, weight loss was not a feature. Weight loss appears to be common but not invariably present in the glucagonoma syndrome.

Diabetes.—Seven of Mallinson's nine cases developed a diabetic glucose tolerance test, as did our patient late in her illness. The presence of high circulating glucagon levels perhaps explains this finding, though this is a subject of some dispute.[11]

Lowered Renal Glucose Threshold.—Glycosuria has been noted among three previously reported patients[7,8] in addition to our patient. In each case, the glycosuria preceded the development of abnormal glucose tolerance by from one to six years. The significance of this finding is unknown.

Anemia.—All of Mallinson's patients were anemic at some point in their illness. Anemia was found in our patient just prior to the discovery of her malignancy and remained mild. Anemia does not appear to be a necessary component of the glucagonoma syndrome.

Serum Glucagon Levels.—Previous authors have reported elevated plasma glucagon levels in patients with the glucagonoma syndrome.[2,6-10] Immunoreactive plasma glucagon levels in our patient were increased fivefold over normal.

Pancreatic Pathology.—Our patient was found to have a malignant islet cell tumor of the pancreas. Of the eight tumors examined in Mallinson's series, all were islet cell in origin. Six were malignant and two were adenomatous.

Pathophysiology Review.—From the standpoint of cutaneous morphology, several other metabolic disorders bear a close resemblance to the necrolytic migratory erythema (NME) of the glucagonoma syndrome (Table 2). Acrodermatitis enteropathica, which manifests lesions similar to NME, is characterized by low plasma zinc levels and is correctable with zinc therapy.[12]

Zinc deficiency, induced by hyperalimentation, likewise has been noted to manifest skin lesions resembling NME.[13,14] A suggestion has been made that similar erosive skin lesions may result as a consequence of essential fatty acid deficiency induced by hyperalimentation.[15] Since essential minerals as well as fatty acids are lacking in standard hyperalimentation formulas, it is not possible at the present time to clearly resolve whether these deficiencies can individually account for the skin lesions.

In addition to cutaneous changes, disturbances of mood have been noted in patients with acute zinc deficiency as well as in patients with the glucagonoma syndrome. Our patient had a history of depression necessitating hospitalization two years prior to the onset of her skin lesions. Throughout the course of her illness, the appearance of skin lesions was accompanied by emotional lability. C. N. Mallinson, MD, in a personal communication, (February 1976), has also noted unusual emotional problems with several of his patients.

The dermatosis of kwashiorkor frequently begins with erythema followed by desquamation or frank erosion of the skin. Descriptive terms such as "flaky paint" or "crazy-paving" dermatosis have been applied to the cutaneous lesions of protein malnutrition.

The cutaneous manifestations associated with malabsorption states are often nonspecific, affecting approximately 20% of patients with steatorrhea.[16] The most common type of skin lesion is a desquamating eczematous eruption affecting the extremities and occasionally the face. In severely debilitated patients, the rash may assume a psoriasiform appearance.

It is impossible at the present time to clearly delineate the pathogenesis of the skin lesions seen in the gluca

gonoma syndrome. Older reports suggested that pancreatic enzymes were responsible for the necrolytic process.[4] Such reports, however, failed to explain the lack of similar skin lesions in patients with other types of islet cell tumors and tumors of pancreatic acinar origin. Additionally, there have been no consistent abnormalities of pancreatic enzymes in urine or plasma.

It is difficult to escape the suggestion that glucagon is the basic factor leading to the skin lesions seen in the glucagonoma syndrome. The mechanism by which this occurs, however, is unknown and purely speculative. Mallinson found markedly decreased plasma amino acid levels in four of his patients and suggested that elevated glucagon levels might be responsible for inadequate levels of amino acids, thus interfering with protein metabolism in the epidermis.[7] Others hypothesized that glucagon being a tryptophan-rich material might lead to depletion of that amino acid and the resultant skin lesions.[8] At present, there is no firm evidence to support either of these considerations.

Glucagon has been shown to stimulate the production of acute-phase proteins.[17] This group of compounds includes fibrinogen, and it is conceivable that increased plasma levels of this glycoprotein might lead to blood flow alterations manifested as annular lesions in the skin.

At present, let us reemphasize that all of these considerations are purely speculative, with the common thread binding together these diseases of like cutaneous morphology seeming to be that of nutritional deficiency.

John Ensinck, MD, performed plasma glucagon determinations and K. Michael Hambidge, MD, performed serum zinc assays.

Matthew Riddle, MD, and Thomas Golper, MD, consulted on the metabolic aspects of this case.

Westwood Pharmaceuticals, Inc, paid for the cost of reproduction of color illustrations.

References

1. Becker SW, Kahn D, Rothman S: Cutaneous manifestations of internal malignant tumors. *Arch Dermatol Syph* 45:1069-1080, 1942.

2. McGavran MH, Unger RH, Recant L, et al: A glucagon-secreting alpha-cell carcinoma of the pancreas. *N Engl J Med* 274:1408-1413, 1966.

3. Church RE, Crane WAJ: A cutaneous syndrome associated with islet-cell carcinoma of the pancreas. *Br J Dermatol* 79:284-286, 1967.

4. Wilkinson DS: Necrolytic migratory erythema with pancreatic carcinoma. *Proc R Soc Med* 64:1197-1198, 1971.

5. Wilkinson DS: Necrolytic migrating erythema with carcinoma of the pancreas. *Trans St Johns Hosp Dermatol Soc* 59:244-250, 1973.

6. Sweet RE: A dermatosis specifically associated with a tumour of pancreatic alpha cells. *Br J Dermatol* 90:301-308, 1974.

7. Mallinson CN, Bloom SR, Warin AP, et al: A glucagonoma syndrome. *Lancet* 2:1-5, 1974.

8. Scully RE, McNeely BU: Case records of the Massachusetts General Hospital. *N Engl J Med* 292:1117-1123, 1975.

9. Danforth DN, Triche T, et al: Elevated plasma proglucagon-like component with a glucagon-secreting tumor. *N Engl J Med* 295:242-295, 1976.

10. Pedersen NB, Jonsson L, Holst JJ: Necrolytic migratory erythema and glucagon cell tumour of the pancreas: The glucagonoma syndrome. *Acta Dermatovener* 56:391-395, 1976.

11. Sherwin RS, Risher M, Hendler R, et al: Hyperglucagonemia and blood glucose regulation in normal, obese and diabetic subjects. *N Engl J Med* 294:455-461, 1976.

12. Neldner KH, Hambidge KM: Zinc therapy of acrodermatitis enteropathica. *N Engl J Med* 292:879-882, 1975.

13. Tucker SB, Schroeter AL, Brown PW, et al: Acquired zinc deficiency: Cutaneous manifestations typical of acrodermatitis enteropathica. *JAMA* 235:2399-2402, 1976.

14. Tasman-Jones C, Kay RG: Zinc deficiency and skin lesions. *N Engl J Med* 293:830, 1975.

15. Riella MC, Broviac JW, Wells M, et al: Essential fatty acid deficiency in human adults during total parenteral nutrition. *Ann Intern Med* 83:786-789, 1975.

16. Wormsley KG (ed): *The Skin and Gut in Disease*. London, Pitman Medical Publishing Co, 1964, pp 19-21.

17. McMillan DE: Deterioration of the microcirculation in diabetes. *Diabetes* 24:944-957, 1975.

18. Buchanan N, Moodley G, Eyberg C, et al: Hypoglycemia associated with severe kwashiorkor. *S Afr Med J* 50:1442-1446, 1976.

Angiolymphoid Hyperplasia With Follicular Mucinosis

Helmut H. Wolff, MD; John Kinney, MD; A. Bernard Ackerman, MD

• Follicular mucinosis is described to our knowledge for the first time in angiolymphoid hyperplasia. In general, follicular mucinosis may be regarded as a peculiar, nonspecific histological reaction pattern in follicular epithelium that may occur on its own or in association with other pathological processes, particularly lymphomas.

The unusual and characteristic features of angiolymphoid hyperplasia revealed by electron microscopy are irregular vessels lined by atypical endothelial cells with convoluted nuclei and large cytoplasmic vacuoles.

(*Arch Dermatol* 114:229-232, 1978)

Follicular mucinosis has been described as occurring (1) idiopathically and harmlessly; (2) more significantly, in secondary association with malignant lymphomas such as mycosis fungoides and familial reticuloendotheliosis; and (3) exceptionally, in inflammatory diseases. We now call attention to the finding of follicular mucinosis in a patient with angiolymphoid hyperplasia.

REPORT OF A CASE

A 46-year-old woman first noted a nodule in the occipital region 2½ years before coming to us. Several satellite nodules appeared soon after that. The nodules were partially alopecic (Fig 1). A biopsy specimen that was taken and read elsewhere was interpreted as nonspecific dermatitis. Recently, the pruritus increased and the nodules, which are firm, have attained sizes of between 0.5 and 1 cm. A complete physical examination revealed no significant pathological findings beyond the cutaneous findings, especially no enlargement of lymph nodes, liver, and spleen. A WBC count showed no increase of eosinophils.

FINDINGS

Biopsy of a nodule by us revealed the following: The epidermis showed slight hyperplasia, with normal keratinization. Throughout the dermis, there were many randomly distributed vascular spaces with bizarre shapes and irregular lumina lined by pleomorphic, plump, abnormal endothelial cells. The endothelial cells often protruded into the lumina giving the appearance of cobblestones (Fig 2). The endothelial nature of these cells some of which contain large vacuoles is clearly demonstrated in semithin sections of tissue prepared for electron microscopy (Fig 3 and 4).

The electron microscope confirms the endothelial nature of these lining cells and also their unusual characteristics. They have variegated shapes (polypoid and cuboidal), protrusions into the lumina, and convoluted, sometimes multilobular nuclei (Fig 5). Their cytoplasm contains fine fibrils, pinocytotic vesicles, but no Weibel-Palade granules. Multiple small and solitary large vacuoles were seen within their cytoplasm (Fig 6). A basal lamina, sometimes multilayered, surrounds the vessels. Smooth muscle cells are present. Besides this vascular component, there is a mixed, inflammatory-cell infiltrate nearby in association with the vessels. It consists mainly of lymphocytes, a few histiocytes, and many eosinophils (Fig 2). Several hair follicles within the lesion show areas of follicular mucinosis characterized by circumscribed cystic or reticular degeneration of the follicular epithelium and accumulation of mucin (Fig 2, left, and 7). The presence of acid mucopolysaccharides within the follicular epithelium was confirmed by the colloidal iron stain.

COMMENT

In 1957, Pinkus[1] reported deposition of mucin in pilosebaceous epithelium. Because hair loss was one mainfestation of this phenomenon, Pinkus called it "alopecia mucinosa."[1] At about the same time, and independently, Braun-Falco studied this clinical and histopathological phenomenon and further histochemically characterized the nature of the accumulated mucinous material. Braun-Falco came to the conclusion that the material consists of acid glycoproteins and is of epithelial origin in contrast to the mucins produced by fibroblasts. Thus, he proposed the term "mucophanerosis intrafollicularis et seboglandularis" (mucophanerosis simply means the appearance of mucin) for this condition.[2] In the same paper, Braun-Falco also separated the mucinous follicular process into two distinct groups, namely (1) a primary (or idiopathic) form that occurs in younger age groups, even in children, has no systemic complications, may resolve quickly or persist, but that ultimately and usually clears spontaneously, and (2) a secondary (or symptomatic) form that is associated with malignant lymphomas, especially with mycosis fungoides. This concept has since been confirmed and is now accepted.[3-8]

In 1959 Jablonska and co-workers[3] criticized the term alopecia mucinosa on the grounds that alopecia can only be detected easily on the very hairy parts of the body and therefore alopecia is but a gross, inconsistent feature of the process. They proposed the designation "follicular mucinosis,"[3] which is also commonly used for the histopathological changes whereas Pinkus' "alopecia mucinosa" remains a good clinical designation.

Most cases of follicular mucinosis are of the primary form and occur without any other associated and concomitant pathological process. In the secondary form, the serious conditions with which follicular mucinosis has been found to be associated are predominantly malignant lymphomas,

Fig 1.—Multiple alopecic cutaneous nodules in occipital region of scalp in case of angiolymphoid hyperplasia. Note that few of follicular openings on some of nodules contain no hairs whereas most of follicles between nodules contain hairs that were clipped short.

Accepted for publication Dec 21, 1976.

• From the Department of Dermatology (Dr Wolff), University of Munich, West Germany, the Departments of Dermatology and Pathology (Dr. Ackerman), New York University School of Medicine New York, and the Palm Beach Medical Group (Dr Kinney), West Palm Beach, Fla.

Reprint requests to Dermatol. Univ.-Klinik, Frauenlobstr. 9-11, D-8000 Munich 2, Germany (Dr Wolff).

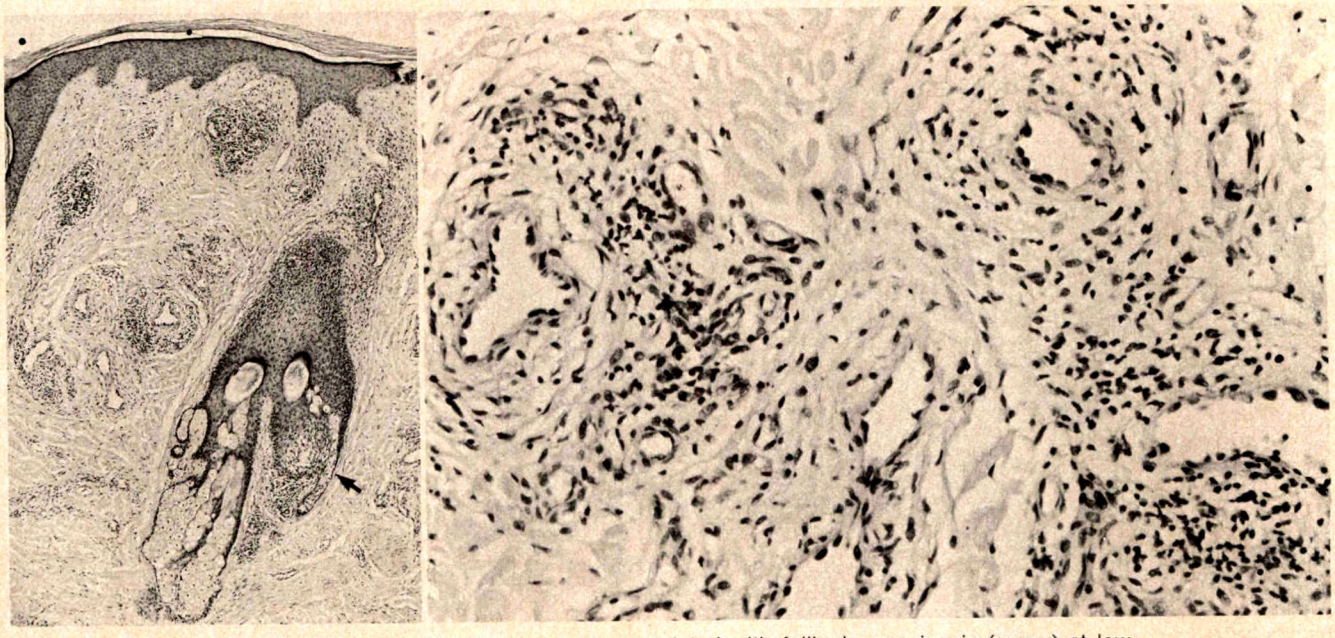

Fig 2.—Left, Angiolymphoid hyperplasia associated with follicular mucinosis (arrow) at low magnification (hematoxylin-eosin, original magnification ×10). Right, Higher magnification of atypical capillaries from area shown at left, (HE, original magnification ×25).

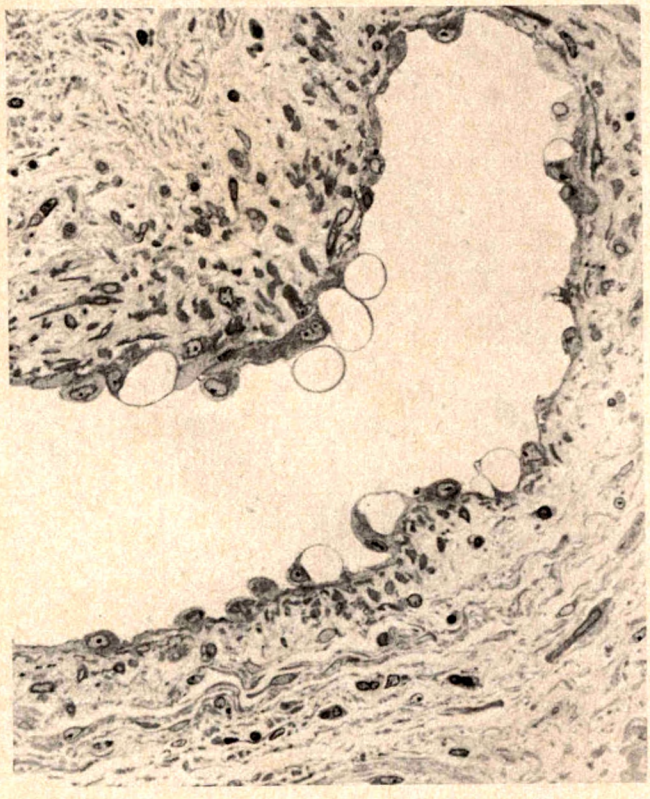

Fig 3.—Part of capillary in angiolymphoid hyperplasia showing bizarre-shaped endothelial cells (glutaraldehyde fixation, epoxy resin embedding, semithin section, methylene blue and azur II, original magnification ×40).

Fig 4.—Endothelial cells of angiolymphoid hyperplasia at higher magnification revealing irregular shape and very large vacuoles (techniques as in Fig 6, original magnification ×100).

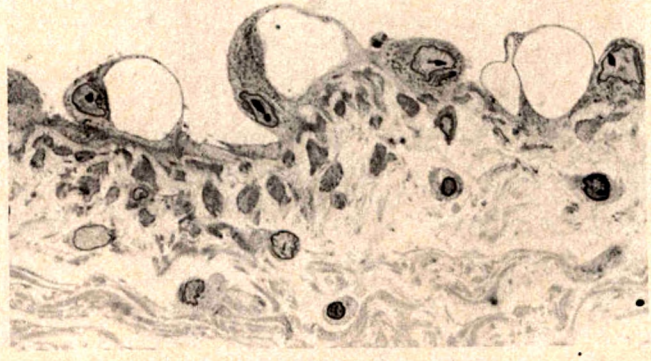

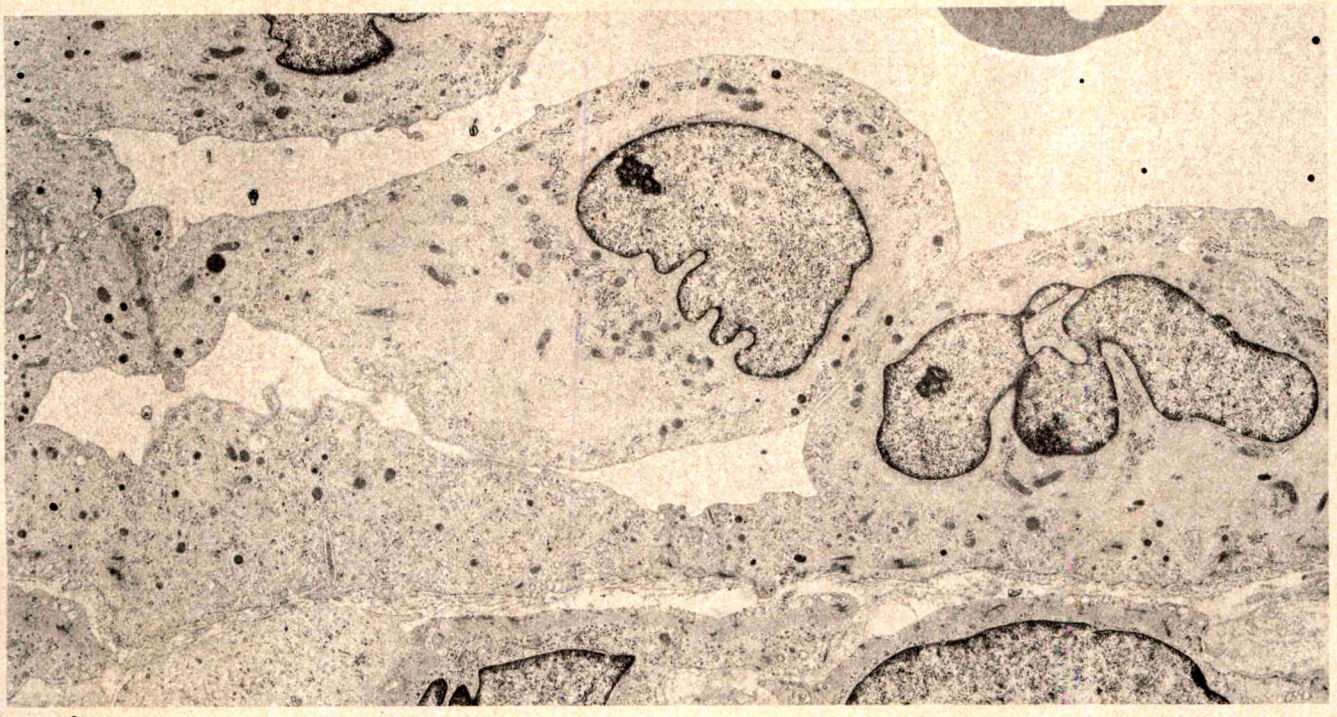

Fig 5.—Viewed with electron microscope, endothelial cells have irregular shapes and their nuclei are convoluted (×6,000).

Fig 6.—Intracytoplasmic vacuoles of various sizes in endothelial cells seen in electron microscope (×10,000).

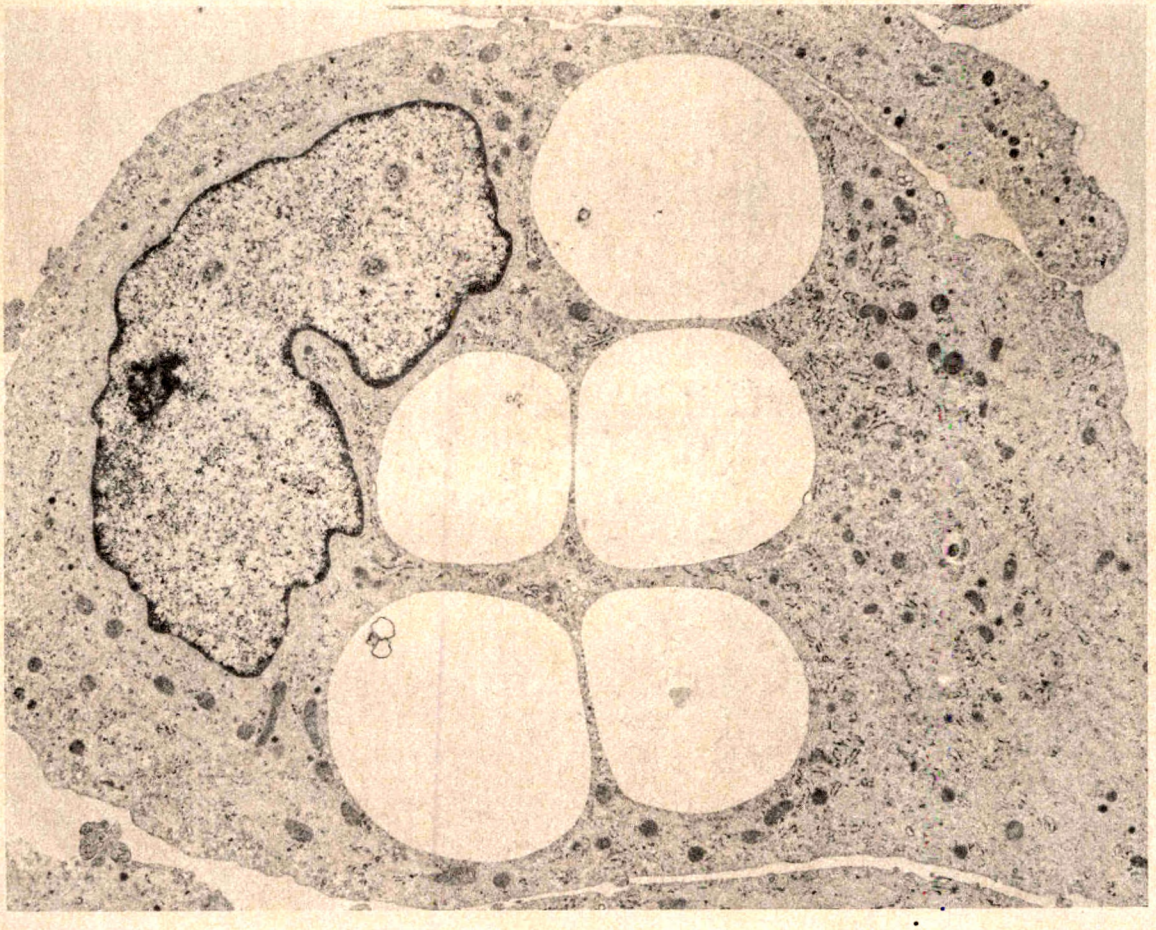

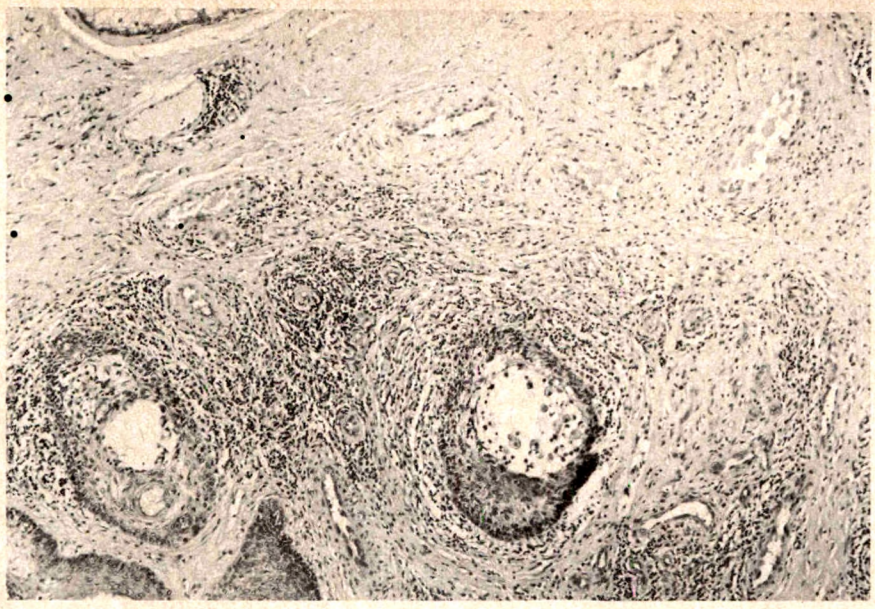

Fig 7.—Two follicles showing intraepithelial collections of mucin, as confirmed by colloidal iron stain in vicinity of irregularly shaped vascular structures and inflammatory cell infiltrates of angiolymphoid hyperplasia (hematoxylin-eosin, original magnification ×25).

and of these, mycosis fungoides is the most common. A single case of familial reticuloendotheliosis with eosinophilia and follicular mucinosis was reported in 1972 by Freeman.[9] Follicular mucinosis has also been reported with inflammatory conditions such as lupus erythematosus[10] and lichen simplex chronicus.[11]

To our knowledge, follicular mucinosis has not been previously reported in association with angiolymphoid hyperplasia. Angiolymphoid hyperplasia is an unusual condition that has been described under a variety of names, originally eosinophilic lymphfolliculosis (Kimura's disease),[12] atypical[13] or pseudo pyogenic granuloma,[14,15] and angioblastic lymphoid hyperplasia with eosinophilia.[16,17] The designation "angiolymphoid hyperplasia with eosinophilia" was proposed by Wells and Whimster,[18] who, in detail, described the clinical and histological features, the differential diagnosis, and the similitude of the conditions to what Kimura described. In 1971, Mehregan and Shapiro[19] summarized the histopathological features in 14 cases and recently, findings by electron microscopy have been reported.[20-22] The large cytoplasmic vacuoles are the most conspicuous feature of the endothelial cells. They have also been described in angiosarcoma of the skin, and may be considered as an intracellular lumen formation.[23]

What in actuality is angiolymphoid hyperplasia? Is it an inflammatory process, a neoplastic process, or a combination of inflammation and neoplasia? Although any answer at this time, in the absence of known cause or mechanism, must of necessity be speculative, our view is that angiolymphoid hyperplasia represents a benign vascular neoplasia with a concomitant inflammatory cell infiltrate.

In the matter of follicular mucinosis, we think it represents a histological reaction pattern common to several unrelated conditions analogous to epidermolytic hyperkeratosis[24] and focal acantholytic dyskeratosis, which also occur nonspecifically.[25] All the histological changes that develop in the epithelium are not limited to a specific disease, but rather are morphological and distinctive manifestations of altered epithelial metabolism that express themselves in a variety of clinical settings. So too it is with follicular mucinosis, which is the best descriptive term in histopathology for the distinctive follicular process that may occur on its own, in malignant lymphomas, and in inflammatory diseases. To them may now be added the finding of follicular mucinosis in angiolymphoid hyperplasia.

Since the submission of this article, a similar case was reported by Konrad et al.[26]

The electron microscopic study was supported by Deutsche Forschungsgemeinschaft.

The technical assistance of Miss E. Januschke is acknowledged.

References

1. Pinkus H: Alopecia mucinosa. *Arch Dermatol* 76:419-426, 1957.

2. Braun-Falco O: Mucophanerosis intrafollicularis et seboglandularis. *Dermatol Wochenschr* 136:1289-1303, 1957.

3. Jablonska ST, Chorzelski T, Lancucki J: Mucinosis follicularis. *Hautarzt* 10:27-33, 1959.

4. Pinkus H: The relationship of alopecia mucinosa to malignant lymphoma. *Dermatologica* 129:266-270, 1964.

5. Kim R, Winkelmann RK: Follicular mucinosis (alopecia mucinosa). *Arch Dermatol* 85:490-498, 1962.

6. Okun MR, Kay F: Follicular mucinosis (alopecia mucinosa): Report of three cases and review of therapy. *Arch Dermatol* 89:809-818, 1964.

7. Plotnik H, Albrecht M: Alopecia mucinosa and lymphoma: Report of two cases and review of literature. *Arch Dermatol* 92:137-141, 1965.

8. Emmerson RW: Follicular mucinosis: A study of seven patients. *Br J Dermatol* 81:395-413, 1969.

9. Freeman RG: Familial reticuloendotheliosis with eosinophilia and follicular mucinosis. *Arch Dermatol* 105:737-738, 1972.

10. Cabré J, Korting GW: Zum symptomatischen Charakter der "Mucinosis follicularis"; ihr Vorkommen beim Lupus erythematodes chronicus. *Dermatol Wochenschr* 149:513-518, 1964.

11. Korting GW, Brehm G: Vakuoläre Follikeldegeneration bei einer Lichenification géante. *Dermatol Wochenschr* 144:1261-1268, 1961.

12. Kawada A, Takahashi H, Anzai T: Eosinophilic lymph-folliculosis of the skin (Kimura's disease) *Jpn J Dermatol* 76:61-72, 1966.

13. Peterson WC Jr, Fusaro RM, Goltz RW: Atypical pyogenic granuloma: A case of benign hemangioendotheliosis. *Arch Dermatol* 90:197-201, 1964.

14. Wilson-Jones E, Bleehen SS: Inflammatory angiomatous nodules with abnormal blood vessels occurring about the ears and scalp (pseudo or atypical pyogenic granuloma). *Br J Dermatol* 81:804-816, 1969.

15. Winer LH, Levin GH: Acquired vascular tumors of the skin in the adult: A report of five unusual cases. *Arch Dermatol* 79:17-31, 1959.

16. Reed RJ, Terazakis N: Subcutaneous angioblastic lymphoid hyperplasia with eosinophilia (Kimura's disease). *Cancer* 29:489-497, 1972.

17. Fattah AA, Fahmy A: Subcutaneous lymphoid hyperplasia with eosinophilia. *Dermatologica* 139:220-224, 1969.

18. Wells GG, Whimster JW: Subcutaneous angiolymphoid hyperplasia with eosinophilia. *Br J Dermatol* 81:1-15, 1969.

19. Mehregan AH, Shapiro L: Angiolymphoid hyperplasia with eosinophilia. *Arch Dermatol* 103:50-57, 1971.

20. Castro C, Winkelmann RK: Angiolymphoid hyperplasia with eosinophilia in the skin. *Cancer* 34:1696-1705, 1974.

21. Daniels DG, Schrodt R, Fliegelman MT, et al: Ultrastructural study of a case of angiolymphoid hyperplasia with eosinophilia. *Arch Dermatol* 109:870-872, 1974.

22. Konrad K, Wolff K, Gschnait F: Angiolymphoid hyperplasia: Pathology at the ultrastructural level. Presented at the second European Meeting on Electron Microscopy Applied to Cutaneous Pathology, Milan, January 1975.

23. Rosai J, Sumner HW, Kostianovsky M, et al: Angiosarcoma of the skin: A clinicopathologic and fine structural study. *Human Pathol* 7:83-109, 1976.

24. Ackerman AB: Histopathologic concept of epidermolytic hyperkeratosis. *Arch Dermatol* 102:253-259, 1970.

25. Ackerman AB: Focal acantholytic dyskeratosis. *Arch Dermatol* 106:702-706, 1972.

26. Konrad K, Gschnait F, Wolff K: Die angiolymphoide Hyperplasie mit Eosinophilie. *Z Hautkr* 51:545-552, 1976.

Woolly Hair Nevus

Two Case Reports and a Discussion of Unruly Hair Forms

Sharon D. H. Lantis, MD, Margot C. Pepper, MB

• Woolly hair is very curly hair that is characteristically unruly and will not form naturally into locks. Woolly hair nevus first appears when the scalp hair begins to grow. It is seen as a patch of unruly, very curly hair, arising in a field of otherwise unremarkable scalp hair. Woolly hair can also be seen as a hereditary trait involving the entire scalp and in acquired forms. It may be distinguished from two other types of unruly hair, pili torti and spun glass hair.

(*Arch Dermatol* 114:233-238, 1978)

Woolly hair nevus was first reported by Wise in 1927.[1] This unusual condition is apparent at birth or when the hair starts to grow. It consists of a patch of tightly curled hair in an otherwise unremarkable field of scalp hair. Wise described two unrelated 5-year-old girls who had soft curly hair on a portion of the scalp that was lighter in color than the remaining straight brown hair. One patient had a pigmented linear nevus of the neck and arm on the ipsilateral side to the woolly hair nevus.

In 1943 Anderson[2] described a 5-year-old girl with a woolly hair nevus on the left side of the scalp. The woolly hair was lighter in color. Underlying this hair was an area of increased pigmentation that extended onto the left side and back of the neck. Ten years later Hoffman[3] described an adult man with a woolly hair nevus that had been present all his life. The woolly hairs were thinner than the smooth hairs. He had a brown pigmentation underlying the nevus and late onset of seborrheic dermatitis confined to the woolly areas.

No additional cases are noted in the literature until 1958 when three cases were published. Born[4] described an 8-year-old boy who had a patch of woolly hair since birth with no associated abnormalities of the scalp or skin. Bell[5] presented a case of a 29-year-old woman with woolly hair on the right side of the scalp. In her midteens she had developed increased thickness and pigmentation of the skin of the face, scalp, and neck on the right side. Post[6] described a 7-year-old boy who had a patch of curly blonde hair amid his straight brown hair apparent at age 2 months. This patch extended to cover a large area of the right side of the scalp by the age of 4 years. The woolly hair gradually got darker by age 7. This child also had an epidermal nevus of the right side of the face and neck and right arm. The nevus became apparent at 2 months of age and enlarged until age 4 years.

Streitmann,[7] in 1959, presented a case of a 7-year-old boy with a patch of blonde woolly hair in a straight black field. The patient also had an epidermal nevus. This woolly hair had darkened with age.

In 1960[8] Grant reported a case of woolly hair nevus in a 6-year-old boy. This child had not grown scalp hair until age 2 years, at which time the woolly portion appeared first. It covered an enlarging area in a patchy nature over both sides of the back of the scalp and the hair was much lighter than the normal dark brown hair. There were no epidermal nevi; however, there was a persistent pupillary membrane of the right eye.

Domonkos[9] described a 4-year-old child with a light-colored woolly hair nevus associated with a linear nevus in 1962. In 1974, Fanconi[10] reported a case of a child with a light blonde woolly hair nevus on the occiput. The normal hair was straight and darker blonde. No other skin changes were noted. In the same year Hutchinson et al[11] presented a case of an 8-year-old boy with a woolly hair nevus in two patches. The woolly and normal hair were reportedly the same color.

None of these patients had a family history of woolly hair. There were no reported changes in teeth or nails. There was no increased fragility or breakage of the hairs. The woolly hair was usually noted to be lighter in color and smaller in diameter.

REPORT OF CASES

Case 1.—A 25-year-old white woman was noted to have onset of a curly patch of hair on the crown of her head during the first year of life. As the hair grew in, it became apparent that the hair in this area was different from the rest of the hair, which was quite straight and darker in color. The curly patch was noted to extend down the right side of the scalp to the temporal area, but thereafter remained stable.

At about age 20 the patient noted itching and scaling of the scalp under the curly hair. Two thickened verrucous plaques developed in the area. A biopsy was done elsewhere and psoriasis was diagnosed. She was treated with a steroid cream and the lesions subsided.

The patient came to us with recurrence of the verrucous plaques that had gradually enlarged during the previous year. She was noted to have a well-defined area of the scalp extending from the crown to the right temple that was erythematous and

Accepted for publication Feb 2, 1977.

From the Section of Dermatology, University Health Service, University of Wisconsin, Madison.

*Reprints not available.

Fig 1.—Case 1. Woolly hair nevus showing patch of curly, unruly hair on scalp of patient with straight hair.

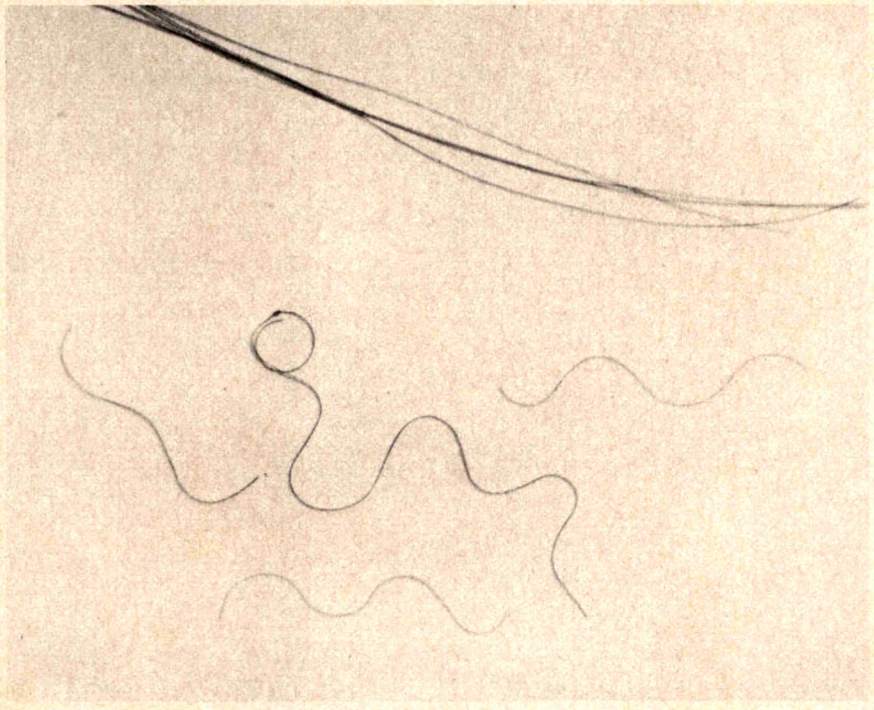

Fig 2.—Case 1. Patient's straight hairs and hairs from woolly hair nevus.

Fig 3.—Case 1. Histopathology of plaque of thickened, itchy skin within woolly hair nevus shows hypertrophic, inflammatory changes as well as inability to evaluate shape of hair follicles in dermis without serial section (4-mm punch biopsy, original magnification ×31).

scaly. These changes extended just beyond the hair line. Within this area were two thick plaques, each about 2 cm in diameter. The hair growing in this area was fine, soft, and tangled (Fig 1). It was very curly but did not form locks. The remaining hair was long, straight, and slightly darker brown in color (Fig 2). The curly hair was cut short for cosmetic reasons, but reportedly grew normally and was not fragile. No nevi were noted and no ectodermal defects were apparent. The teeth and nails were normal. There was no psoriasis or skin rash elsewhere, and the patient was in good health. There was no family history of unusual hair.

A 4-mm punch biopsy (Fig 3) of one of the thickened plaques showed verruciform papillomatosis and hyperkeratosis. The papillary dermis was edematous, with dilated vessels and a scattered mixed inflammatory infiltrate. The reticular dermis contained a prominent perivascular inflammatory infiltrate. Histology findings were the same as those of the previous biopsy specimen.

A diagnosis was made of woolly hair nevus with seborrheic dermatitis confined to the scalp underlying the woolly patch of hair. The patient was treated with tar shampoo and topical steroids. One month later the plaques, erythema, and scaling were gone.

Case 2.—A 22-year-old white man had itching and scaling of part of his scalp. At age 18 months he was noted to have a mosaic pattern of hair, with two different textures and colors in patches over his scalp (Fig 4). He had brown, slightly elevated pigmentation noted at birth on his nose, upper lip, and behind the right ear. At 18 months rough pigmented patches of skin were noted on the trunk and extremities. By age 3 years these had spread into linear areas and extended onto the palms and soles. He also had a six-year history of tremor in both hands and decreased hearing in the left ear.

On examination the patient was noted to have extensive bilateral hypertrophic verrucous nevi. He had erythema with scaling in irregular patches throughout his scalp, which corresponded exactly to the mosaic pattern of fine, curly, light red hair. The scalp underlying the darker red, less tightly curled hair was normal.

The teeth and nails were normal and the patient was in good health. There was no family history of unusual hair, but the patient's father had a similar tremor of unknown cause. He refused photography and biopsy and was lost to follow-up.

A diagnosis was made of woolly hair nevus associated with epidermal nevi and seborrheic dermatitis confined to the scalp underlying the woolly hair.

COMMENT
Woolly Hair

The subject of woolly hair has been confused in the literature by the use of such terms as woolly, kinky, spun glass, crimped, frizzly, and steely to define the clinical appearance of peculiar hair that will not group in locks nor lie down flat and is difficult to comb or brush.

Figure 5 shows a modification of a classification of hair forms developed by anthropologists in the late 19th century. Straight and wavy hair forms are easily determined. Curly hair is spiraled and forms into locks that also spiral. Peppercorn hair is found in some black populations. It curls up so tightly that little nobs are formed with a grid of visible scalp in between the clumps of hair. Woolly hair is a common hair form seen on the scalp in black races and in some white families. It has an unruly appearance because its tightly coiled spirals will not form locks nor lie flat.

The term woolly hair derives from sheep wool. Growing on the sheep, wool fibers are very organized. The fibers form into groups or staples that assume a wave or crimp. The term crimp refers to the wave of the staple rather than to the wave of an individual fiber.[12-14] The fibers of sheep are very numerous (3,000 to 5,000 per sq cm) and very thin (25 μm).[15] They are held together in the staple by the waxy secretions from which lanolin is derived. Wool and hair fibers have the same morphologic components. However, in wool fibers the cortex is divided into two types of keratin, which are wound around each other in phase with the fiber curvature.[16] It is well established that the follicles of highly crimped wool are curved in the dermis, while straighter fleeces have straighter follicles.[17-19]

Removed from the staple and washed, wool fibers become "woolly"; that is, individual fibers, free from constraints, take on a helical formation resulting in an unruly clump that resembles the hair form of most black races. The fibers show slowly twisting spiral forms, often changing direction of curvature along the shaft. When relaxed in boiling water or steam, cleaned wool fibers curl up into a collapsed spiral of regular diameter.[14,20,21]

In an attempt to understand woolly hair better, samples were taken from several black patients with natural hair styles. These hairs were very curly; turning in slow spirals, changing direction of curvature along the shaft as with the wool fibers. When placed in boiling water, they immediately spun into a tight curl of regular diameter (Fig 6), and when held by one end, dangled to form a regular spiral. These spiral forms were quite stable; however, if several hairs were rubbed between the fingers, some spirals were disrupted and changed direction of curvature along the shaft. When this happened, the tangled, woolly appearance was resumed. By laying the curled-up hairs on a flat surface, the radius of the curls could quickly be measured with a ruler. (In all cases examined, the average radius of the curl of hairs from black patients with natural hair styles was less than 5 mm.)



Fig 4.—Case 2. Patient's light-colored, thin woolly hairs and darker curly hairs.

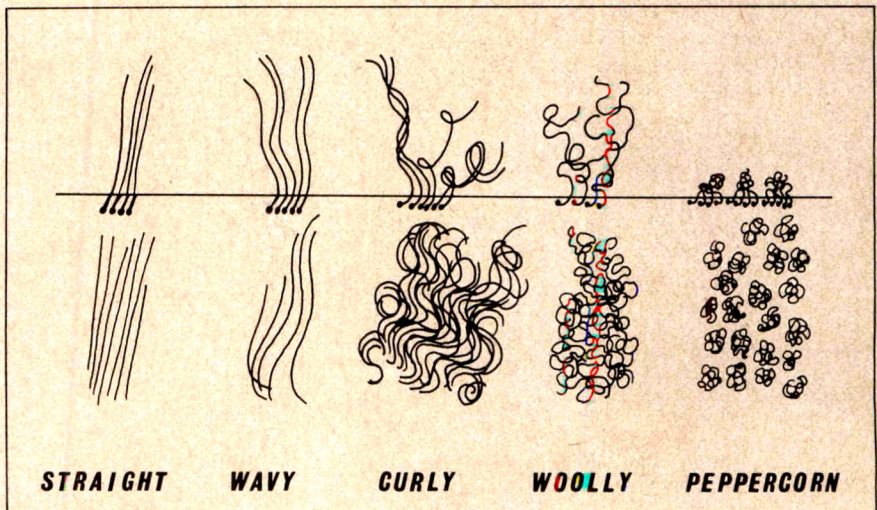

Fig 5.—Normal human hair forms.

The keratin of straight, curly, and woolly hair forms is the same. Studies including amino acid analysis, gel electrophoresis, x-ray diffraction, and stress-strain analysis show identical results.[16,22-24]

In areas examined, woolly hair has been associated with curvature of the follicle in the dermis,[25,26] and this is believed to account for its curly character. This has been nicely demonstrated by Pinkus[27] and Strauss and Kligman[28] in studies on pseudofolliculitis of the beard.

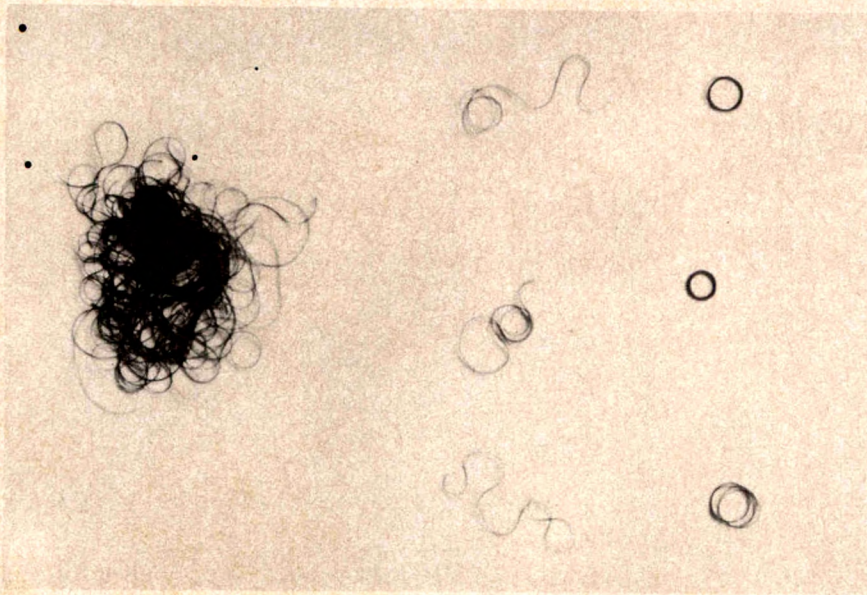

Fig 6.—Woolly hairs from black individual showing lack of lock formation and relaxed spiral form after being placed in boiling water.



Fig 7.—Case 1. Woolly hairs before and after being relaxed in boiling water.

However, early studies by anthropologists attempted to explain the curl on the basis of cross-sectional shape.[25,29,30] It was thought that all straight hairs were round and curly hairs oval. Supposedly, the oval or flattened shape allowed the hairs to curl up like a ribbon. It has since been established that hairs have varying cross-sectional shapes along a single hair shaft, among hairs on the same scalp, and within racial groups.[22,25,31-33]

With recent trends to natural hair styles, woolly hair seems more common in white groups than would be suspected from the sparcity of literature reports documenting the pattern of heredity for this trait.

There are three pedigrees that show pictures of family members and hair samples demonstrating dominant inheritance.[11,34] There are two well-documented reports of families with woolly hair inherited in a recessive pattern.[11,35] There are several additional reports of inherited woolly hair where the description of the hairs was insufficient to determine whether the hair was really woolly or not.[36-40] The hair in these cases was either fragile or grew poorly. No follicle shape, cross sectional or radius of curl studies, has been reported in these families.

Woolly Hair Nevus

Woolly hair nevus is a well-documented and easily diagnosed abnormality. It arises on the scalp as one or more patches of woolly hair in an otherwise normal field. The woolly hairs are usually smaller in diameter and lighter in color than the rest of the hair. It grows normally and is not fragile. In about 50% of cases woolly hair nevus is associated with epidermal nevi on the ipsilateral side.

One previous report noted the association of seborrheic dermatitis confined to the woolly patches.[3] Both of our patients had scaling and itching of the woolly patches as the chief complaint. Most case reports are of young children; it would be interesting to know whether they developed seborrheic dermatitis in the woolly patches at a later date.

Unfortunately, even serial sections of biopsy specimens from patient 1 failed to show whether or not the follicles were curved or straight. The patient was lost to follow-up before another specimen could be obtained. Patient 2 refused a biopsy. It is interesting to speculate that the nevus is caused by a patch of curved follicles.

Examination of the hairs from our patients disclosed that the woolly hairs have slowly spiraling shapes with frequent changes of direction of the spiral. When examined under a dissecting microscope, the hair shafts were noted to twist slowly about their own long axis. When relaxed by placing them in boiling water, they immediately curled up and formed regular spirals (Fig 7). In both our cases, all the spirals formed after relaxing were left-handed. The woolly hairs of patient 1 had an average radius of curl of 4 mm. Woolly hairs from patient 2 had an average radius of curl of 2.5 mm. His normally curly hairs had an average radius of curl of 5.7 mm.

Cross sections of the hairs were performed, using a new technique, embedding the hair in epoxy casting resin A and cutting it with a glass knife.[41] This method allows accurate cross sections to be achieved without distortion. Figure 8 shows the characteristic shape and measurements of hairs from our two patients. It is quite apparent that the woolly hairs in our patients are smaller in diameter. Note also that the cross-sectional shape is not an indicator of the straightness or curliness of the fiber.

In conclusion, woolly hair nevus is the occurrence of patchy areas of unruly hair that are very curly. The hairs when relaxed in hot water form regular spirals, which in our cases had an average radius less than 5 mm. However, on the scalp, the spirals are disturbed, probably by rubbing and combing, so that frequent changes of direction of curvature occur. The hair is fine and soft without other structural abnormalities. It does not lie flat nor form locks.

Another interesting phenomenon is two reports of straight hair nevi in the scalps of black children.[42,43] Both of these patients also had epidermal nevi.

Acquired Progressive Kinking of the Hair

Acquired progressive kinking of the hair is a form of curly hair first reported by Wise and Sulzberger in 1932.[44] Two subsequent cases have been reported.[45,46] This occurs in the late teens as gradual darkening and curling of the hair in the frontal and temporal areas. The hairs are also noted to be shorter than the nonaffected hair; probably due to a shortened anagen phase. The hairs were not structurally abnormal and pictures of the hairs in these reports appear typical of woolly hair. No information on cross-sectional shape, curvature of follicles, or radius of curl is given. There is also a report of

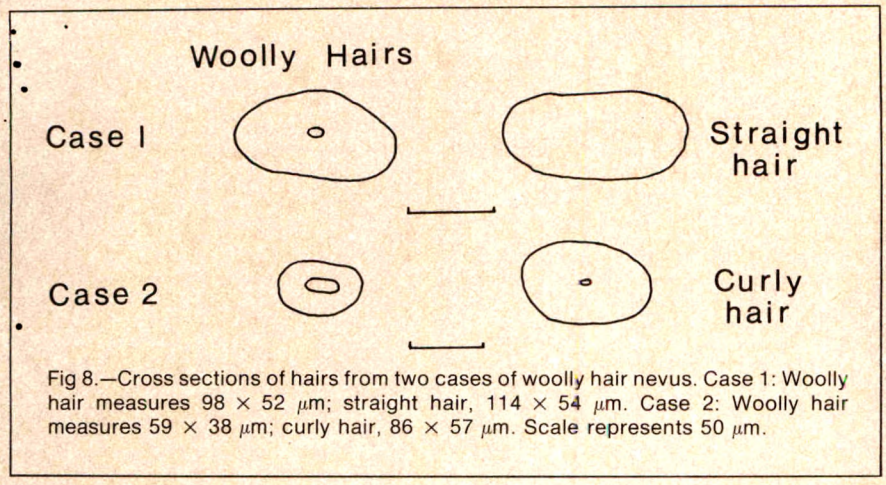

Fig 8.—Cross sections of hairs from two cases of woolly hair nevus. Case 1: Woolly hair measures 98 × 52 μm; straight hair, 114 × 54 μm. Case 2: Woolly hair measures 59 × 38 μm; curly hair, 86 × 57 μm. Scale represents 50 μm.

regrowth of curly hair in a patch of the scalp of a straight-haired woman following x-ray epilation for metastatic carcinoma of the breast.[47] The picture appears to show woolly hair. In this case the straight and woolly hair were the same color. No other information is given.

In contrast to these forms of woolly hair, there are two other types of unruly hair whose nomenclature is confused with that used to describe woolly hair. These are pili torti and spun glass hair.

Pili Torti

There are several types of pili torti. Ronchese[48] described the classic type of this rare hair shaft defect in which the shaft is flattened and twisted tightly on its own axis. The hair is brittle and fragile and has a spangled appearance. It has no tendency to curl. Onset is in early childhood. It is an autosomal-dominant trait and most cases are in females.

Beare[49] described a family with pili torti of adult onset associated with "mental peculiarities."

Menkes' kinky hair syndrome,[50,51] which is a sex-linked, recessive, neurodegenerative disease caused by copper deficiency due to a defect in copper absorption,[52] also shows pili torti. Cooper-deficient sheep develop an abnormality of their fibers that wool breeders call steely wool. These fibers lose their crimp and take on a peculiar shine, but pili torti has not been recorded.[53-56] Nevertheless, some recent reports have used the term Menkes' steely hair syndrome.[57-59] To add to the confusion, this syndrome is also called trichopoliodystrophy.[60,61]

It is postulated that the abnormal hair in both steely wool and Menkes' disease is related to the fact that the formation of disulfide bonds in keratin is copper-dependent.[15,62,63]

Pili torti is also seen as an autosomal-recessive trait and may occur sporadically. It has also been associated with other hair shaft and ectodermal defects.[64] There is one report of localized pili torti where the hair grew in twisted as the temporary sequela of an alopecia following an insect bite to the scalp.[65,66]

Spun Glass Hair

Spun glass hair was described by Stroud and Mehregan in October 1973 at the first human hair symposium.[67] They recognized that their patient had a peculiar frizzly appearing hair form that was not twisted and represented neither pili torti nor woolly hair. The hair also had a glittering or spangled appearance. The female child had pale reddish-blonde hair that had not started to grow well until 18 months of age. Biopsy specimens showed vastly differing cross-sectional shapes of the hair shaft that were reflected in irregular shapes of the inner root sheaths of the follicles. The irregular surface of the hair shafts, caused by the triangular and kidney-shaped cross-sectional shapes, probably causes refraction and reflection of incident light and the resulting spangled appearance. There was no twisting of the hair shafts. No mention is made of follicle curvature. The hair grew normally and was not fragile. No other ectodermal defects were noted.

There are several other reports of "woolly" and frizzly hair that may fit into this category. Sharp[68] published a case report that showed a peculiar form of hair with corrugations along the shaft, but had neither pili torti nor tendency to curl. This child, also a female, had uneven reddish-yellow hair that was slow-growing and split at the ends. Cross sections were reported to be elliptical. Hutchinson et al[11] described a patient, labeled pedigree C in their review of woolly hair, who was a boy with white-blonde hair that appeared "kinky" but did not curl.

The following tabulation shows a classification of unruly hair based on our review of the literature:

- Pili torti
  - Classic (Ronchese)
  - Beare's pili torti
  - Menkes' kinky (steely) hair syndrome
  - Sporadic
  - Localized
- Woolly hair
  - In black races
  - Congenital
    - Generalized
      - Dominant
      - Recessive
      - Sporadic
    - Localized: Woolly hair nevus
  - Acquired
    - Acquired progressive kinking of the hair (Sulzberger-Wise)
    - Following x-ray epilation
- Spun glass hair (Stroud-Mehregan)

Because most of these conditions are rare and reports incomplete, future revisions will probably be necessary. It is important that reports of unruly hair not only describe the hair thoroughly, but also select descriptive terms that are meaningful.

The term woolly hair should be used to describe unruly hair that curls readily in spirals but does not form locks and shows a slow twist on its long axis. This is, in all respects, normal hair, probably the result of a curved follicle within the dermis. Cross sections show variable shape. In the case of woolly hair nevus the hairs are usually lighter and thinner; in the case of acquired woolly hair, the hairs are usually darker and shorter than normal scalp hairs.

Pili torti is an unruly form of hair where the hairs are twisted sharply and quickly on their long axis but are not curly. The hairs are fragile and break off readily. It almost always involves the entire scalp and is the type of hair seen in Menkes' kinky hair syndrome.

Spun glass hair occurs as an unusual frizzly form of hair that shows no pili torti and has no tendency to curl nor any twisting of the shafts. It involves the entire scalp. More information needs to be obtained on this unusual hair form.

Since submission of this article, we have discovered another communication on woolly hair nevus.[69]

Vera H. Price, MD, Berkeley, Calif, and Herman Pinkus, MD, MS, and Amir Mehregan, MD, Monroe, Mich, assisted in the preparation of this review. C. A. Mason, PhD, performed the photomicrography.

References

1. Wise F: Woolly hair nevus: Peculiar form of birthmark of hair of the scalp, hitherto undescribed, with report of two cases. *Med J Rec* 125:545, 1927.

2. Anderson N: Woolly haired nevus of the scalp. *Arch Dermatol* 47:286, 1943.

3. Hoffman E: Über einen Kräuselnaevus innerhalb sonst glatten Kopfhaares im Vergleich zum erblichen Kraushaar und zur Lockenbildung nach Rontgenepilation. *Dermatologica* 107:281-291, 1953.

4. Born W: Über umschriebene Kräuselnaevi innerhalb sonst glatten Kopfhaars. *Dermatologica* 115:119-121, 1958.

5. Bell WF: Case No. 1: Naevus. *Trans St Johns Hosp Dermatol Soc* 41:101, 1958.

6. Post C: Woolly hair nevus. *Arch Dermatol* 78:488-489, 1958.

7. Streitmann B: Beitrag zur Kenntnis des Kräuselhaarnaevus. *Dermatol Wschr* 139:185-187, 1959.

8. Grant PW: A case of woolly hair nevus. *Arch Dis Child* 35:512-514, 1960.

9. Domonkos A: Woolly hair nevus. *Arch Dermatol* 85:568, 1962.

10. Fanconi G: Kraushaar-Nävus. *Dermatologica* 148:299, 1974.

11. Hutchinson PE, Cairns RJ, Wells RS: Woolly hair. *Trans St John Hosp Dermatol Soc* 60:160-177, 1974.

12. Barker SG, Norris MH: A note on the physical relationships of crimp in wool. *J Text Inst* 21:T1-17, 1930.

13. Woods HJ: Crimp forms in Merino wool fibers: 1-Description. *J Text Inst* 26:T93-102, 1935.

14. Horio M, Kondo T: Crimping of wool fibers. *Text Res J* 23:373-387, 1953.

15. Onions WJ: *Wool.* New York, Interscience Publishers, 1962.

16. Menkart J, Wolfram LJ, Mao I: Caucasian hair, Negro hair, and wool: Similarities and differences. *J Soc Cosmetic Chemists* 17:769-787, 1966.

17. Montagna W, Ellis R: *The Biology of Hair Growth.* New York, Academic Press Inc, 1958, p 323.

18. Nay T, Johnson H: Follicle curvature and crimp size in some selected Australian Merino groups. *Aust J Agric Res* 18:833-840, 1967.

19. Mercer EH: The relation between external shape and internal structure of wool fibers. *Text Res J* 24:39-43, 1954.

20. Henderson AE: *Growing Better Wool.* Sydney, Wellington-Auchland, 1968, p 66.

21. Goldsworthy YE, Lang WR: The coiling of wool fibers immersed in various liquids. *J Text Inst* 44:T230-244, 1953.

22. Hrdy D: Quantitative hair form variation in seven populations. *Am J Phys Anthropol* 39:7-18, 1973.

23. Rook A: Racial and other genetic variations in hair form. *Br J Dermatol* 92:599-600, 1975.

24. Behrman HT: *The Scalp in Health and Disease.* St Louis, CV Mosby Co, 1952, pp 64-72.

25. Trotter M: A review of the classifications of hair. *Am J Phys Anthropol* 24:105-126, 1938.

26. Stewart C: Note on the scalp of a Negro. *Mouth Microsc J* 9:54-55, 1873.

27. Pinkus H: Chronic scarring pseudofolliculitis of the Negro beard. *Arch Dermatol* 47:782-792, 1943.

28. Strauss J, Kligman A: Pseudofolliculitis of the beard. *Arch Dermatol* 74:533-542, 1956.

29. Steggerda M: Cross sections of human hair from four racial groups. *J Hered* 31:474-476, 1940.

30. Steggerda M, Seibert H: Size and shape of head hair from six racial groups. *J Hered* 32:315-318, 1941.

31. Trotter M: The form, size and color of head hair in American whites. *Am J Phys Anthrop* 14:433-446, 1930.

32. Kneberg M: Improved technique for hair examination. *Am J Phys Anthrop* 20:51-68, 1935.

33. Siebert H, Steggerda M: Size and shape of human head hair along its shaft. *J Hered* 33:302-304, 1942.

34. Mori A: Contributo allo studio della eridita. *Arch Italino Anat Embriol* 22:123-135, 1925.

35. Salamon T: Über eine Familie mit recessiver Kraushaarigkeit Hypotrichose und anderen Anomalien. *Hautarzt* 14:540-544, 1963.

36. Mohr O: Woolly hair: A dominant mutant character in man. *J Hered* 23:345-353, 1932.

37. Schokking C: Another woolly-hair mutation in man. *J Hered* 25:337-340, 1934.

38. Anderson E: An American pedigree for woolly hair. *J Hered* 27:444, 1936.

39. Boersma D: Kinky woolly hair in two siblings. *Arch Dermatol* 81:292, 1960.

40. Gottheil: Peculiar woolly hair. *J Cutaneous Dis* 37:489, 1919.

41. Pepper MC, Lantis SDH: A new technique for cross sectioning free hair. *J Invest Dermatol* 68:111-112, 1977.

42. Day TL: Straight-hair nevus, ichthyosis hystrix, leukokeratosis of the tongue. *Arch Dermatol* 96:606, 1967.

43. Gibbs R, Berger R: Straight hair nevus. *Int J Dermatol* 9:47, 1970.

44. Wise F, Sulzberger MB: Acquired progressive kinking of the scalp hair accompanied by changes in its pigmentation. *Arch Dermatol* 25:99-110, 1932.

45. Knierer W: Allotrichia Circumscripta Symmetrica Capillitii. *Derm Wschr* 132:794, 1955.

46. Coupe RL, Johnston MM: Acquired progressive kinking of hair. *Arch Dermatol* 100:191-195, 1969.

47. Pfahler: Epilation of half the scalp in a patient with straight hair, followed by a regrowth of curly hair. *Arch Dermatol* 15:214, 1927.

48. Ronchese F: Twisted hairs (pili torti). *Arch Dermatol* 26:98-109, 1932.

49. Beare JM: Congenital pilar defect showing features of pili torti. *Br J Dermatol* 64:366-372, 1952.

50. Menkes JH, Steigleder GK, Weakly DR, et al: A sex-linked recessive disorder with retardation of growth, peculiar hair, and focal cerebral and cerebellar degeneration. *Pediatrics* 29:764-779, 1962.

51. Menkes JH: Kinky hair disease. *Pediatrics* 50:181-182, 1972.

52. Danks DM, Cartwright E, Stevens BJ, et al: Menkes' kinky hair disease: Future definition of the defect in copper transport. *Science* 179:1140-1141, 1973.

53. Marston HR: Nutritional factors involved in wool production by Merino sheep. *Aust J Sci Res* 1:376, 1948.

54. Marston HR: Wool growth, in Hammond J (ed): *Progress in the Physiology of Farm Animals.* London, Butterworths Scientific Publications, 1955, vol 2, p 543.

55. Wynne KN, McClymont GL: Copper-molybdenum-sulphate interaction in induction of ovine hypocupraemia and hypocuprosis. *Aust J Ag Res* 7:45-56, 1956.

56. Burly RW: Experiments on wool from copper: Deficient sheep: I. Some physical measurements on intact fibers and experiments on the dissolution and fractionation of oxidized wool. *Text Res J* 30:473-484, 1960.

57. Danks D: Menkes' steely-hair disease. *Lancet* 1:891, 1973.

58. Lott IT, DiPaolo R, Schwartz D, et al: Copper metabolism in the steely-hair syndrome. *N Engl J Med* 292:197-199, 1975.

59. Editorial: Copper and steely hair. *Lancet* 1:902-903, 1975.

60. Bresnan S: Menkes' kinky-hair syndrome (trichopoliodystrophy). *Am J Dis Child* 125:572-578, 1973.

61. Grover WD, Scrutton MC: Copper infusion therapy in trichopoliodystrophy. *J Pediatr* 86:216-220, 1975.

62. Burley RW: Sulphydryl groups in wool. *Nature* 174:1019-1020, 1954.

63. Danks DM, Campbell PE, Stevens BJ, et al: Menkes' kinky hair syndrome. *Pediatrics* 50:188-201, 1972.

64. Brown AC: Congenital hair defects. *Birth Defects* 8:52-68, 1971.

65. Scott OLS: Localized pili torti. *Br J Dermatol* 62:272, 1950.

66. Scott OLS: Localized pili torti. *Proc R Soc Med Dermatol* 43:68, 1950.

67. Stroud JD, Mehregan AH: "Spun glass" hair: A clinicopathologic study of an unusual hair defect, in Brow A (ed): *The First Human Hair Symposium.* New York, Medcom Press, 1973, pp 103-107.

68. Sharp H: Woolly hair: A rare abnormality. *Aust J Dermatol* 6:91-93, 1961.

69. Fabian A: Allotrichia circumscripta symmetrica capillitii. *Cesk Derm* 36:83-85, 1961.

Mutilating Basal Cell Epithelioma

Israel Dvoretzky, MD; Benjamin K. Fisher, MD, FRCP(C); O. Haker, MD

• A 49-year-old man was found to have a rare, mutilating basal cell epithelioma of the face. Conventional early therapy with surgery and radiotherapy did not halt the progress of the disease in a hospital environment. The patient died 12 years later.
(*Arch Dermatol* 114:239-240, 1978)

Basal cell epithelioma (BCE) of the rodent ulcer type may rarely assume the form of a destructive, mutilating lesion that causes severe damage to the surrounding tissues.[1-4] Degos has described this form of BCE as "epitheliome térebrant."[3] We present here a case that has caused destruction of most of the face, despite early attempts of conventional therapy.

REPORT OF A CASE

A 49-year-old man was seen by us for the first time in 1974, while he was being cared for in a psychiatric hospital. At that time he already had severe destruction of his face and both eyes, which apparently had started from a BCE of many years' duration. He was hospitalized in 1962 at age 37 with paranoid schizophrenia, which was diagnosed in 1960. During his hospitalization a small growth was noticed on the right lower eyelid that grew slowly and bled occasionally. No photograph of the lesion was made at that time, but we were able to locate a passport-size picture taken routinely of patients admitted to psychiatric institutions. This revealed a lesion on the right lower eyelid. A clinical diagnosis of BCE was apparently made at the time, but the patient refused treatment. A forced hospitalization was carried out, and the lesion was excised surgically. Histologic examination of the completely excised lesion confirmed the diagnosis of BCE (Fig 1). Six years later a new lesion appeared next to the surgical scar, and it spread along the entire lower eyelid, involving the lacrimal duct. A wide excision of the entire lesion was then performed. Thereafter, several surgical procedures with plastic repair were done, culminating in the total removal of both eyelids. The patient was kept hospitalized in the psychiatric hospital in order to treat this skin lesion, and was examined regularly by physicians from the departments of plastic surgery, ophthalmology, and oncology of The Chaim Sheba Medical Center. Radiotherapy was used in 1970 (consisting of 15 treatments of 260 rads each, totalling 6,500 rads) during a period of two months. All these treatments were futile, and within three years an advanced destruction of the right orbital floor and maxillary sinus was observed. The patient's general health deteriorated: he lost weight, developed decubitus ulcers on his buttocks, ate and drank poorly, swallowed with difficulty, was tachycardiac, and gradually stopped talking. At this stage it was decided not to pursue surgical therapy and to use only sedative measures. The destruction progressed to involve most of the face. Examination by us at this time showed a thin, cachectic man, who was

Fig 1.—Histologic examination of growth showing typical basal cell epithelioma with pallisading arrangement of peripheral cells (hematoxylin-eosin, ×40).

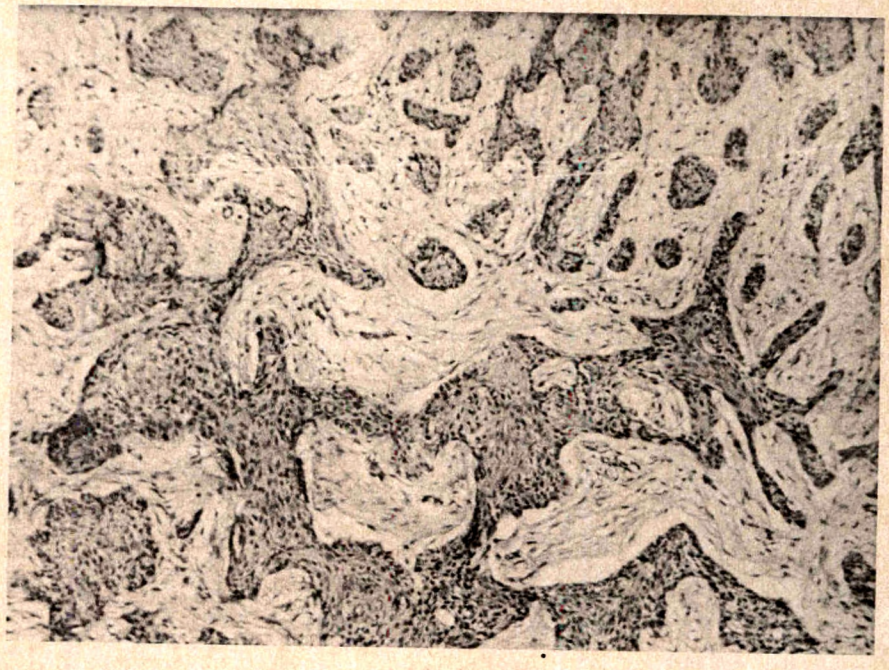

Accepted for publication Jan 1, 1977.
From the Department of Dermatology, The Chaim Sheba Medical Center, Tel-Hashomer, Israel (Drs Dvoretzky and Fisher), and Yehuda Abarbanel Psychiatric Government Hospital, Bat Yam, Israel (Dr Haker). Dr Dvoretzky is now with Yale University, New Haven, Conn. Dr Fisher is now with The Wellesley Hospital and the University of Toronto Medical School, Toronto.

Reprint requests to the Department of Dermatology, The Chaim Sheba Medical Center, Tel-Hashomer, Israel.

Fig 2.—Mutilating basal cell epithelioma with severe destruction of most of face, including upper palate, orbits, most of nose, and lower part of frontal bones. Dura mater is visible below upper border of ulcer.

totally blind, with severe destruction of most of his face, including the upper palate, the orbits, most of the nose, and the lower part of the frontal bones. The dura mater was exposed. Remnants of the left eye could still be seen (Fig 2). The patient was cooperative; he could eat without help and enjoyed smoking. His vocabulary was limited to "yes" and "no." A biopsy specimen from the margin of this huge ulcer again showed BCE. A few months after we saw this patient he died, and we were informed that the cause of death was "generalized sepsis." No further details could be obtained. An autopsy was refused by the family.

COMMENT

Although BCE is the most common human skin cancer, its mutilating or "horrifying" variety is extremely rare. It is usually found in elderly people[5] who neglected therapy[4] or who were not properly treated.[3] Although adequate therapy should theoretically prevent recurrence of BCE, this is not always the case. Jackson,[6] who discusses this problem, pointed out that either the "adequate" therapy was not truly adequate and has left behind residual tumor cells, or, although the original tumor was totally removed, the involved area had a predisposition for malignant change that resulted in a new tumor developing in the same area. This type of tumor, which usually starts on the face in sun-exposed areas,[1,2,4] is usually locally invasive, and the malignant cells invade the surrounding tissues, including bone and cartilage.[3] The skull, dura mater, and the brain may be involved,[2] with a fatal outcome.[1,4]

Jackson and Adams[7] have suggested the following clinical characteristics for the diagnosis of horrifying BCE: (1) onset before the age of 40, (2) reappearance more than two times, despite apparently adequate therapy, and (3) each reappearance occurring within a shorter time period and becoming larger. Our case fits well all these criteria. The diagnosis was made relatively early, and all possible therapy was tried out under hospital supervision for about 12 years. Despite all attempts, the tumor persisted and progressed. With each surgical intervention, histologic examination was performed and always showed BCE with the classic pallisading arrangement of the peripheral cells.[8] Unfortunately, because no autopsy was performed, it is impossible to say whether internal metastases were present. It is known that metastases in BCE are very rare.[8] Possibly, chemotherapy should have been tried on our patient when it became obvious that all conventional treatments were ineffective. Some success with bleomycin in cases of BCE has been reported.[9-10] We can also speculate that chemosurgery, as advocated by Mohs, and if employed early, could have changed the outcome of this case.[11] However, this method of treatment is unfortunately not yet available in Israel.

This study was supported by Canadian Friends of Hospital Tel-Hashomer, Calgary, Alberta, Canada.

References

1. Domonkos AN: *Andrews' Diseases of the Skin*, ed 6. Philadelphia, WB Saunders Co, 1971, pp 755-758.

2. Rook A, Wilkinson DS, Ebling FSG: *Textbook of Dermatology*, ed 2. London, Blackwell Scientific Publications, 1972, vol 2, p 1952.

3. Degos R: *Dermatologie*. Paris, Flamarion, 1973, vol 2, p 878.

4. Van Scott ES: *Dermatology in General Medicine*, Fitzpatrick TB (ed). Toronto, McGraw-Hill Book Co Inc, 1971, pp 466-472.

5. Dillaha CJ, Jansen GT, Honeycutt WM: *Clinical Dermatology*, Demis DJ, Dobson RL, McGuire J (eds). Hagerstown, Md, Harper & Row Publishers Inc, 1976, vol 4, pp 1-21.

6. Jackson R: Why do basal cell carcinomas recur (or not recur) following treatment? *J Surg Oncol* 6:245-251, 1974.

7. Jackson R, Adams RH: Horrifying basal cell carcinoma: A study of 33 cases. *J Surg Oncol* 5:431-464, 1973.

8. Lever WF, Schamburg-Lever G: *Histopathology of the Skin*, ed 5. Philadelphia, JB Lippincott Co, 1975, pp 537-538.

9. Mishima Y, Matunaka M: Effect of bleomycin on benign and malignant cutaneous tumors, *Acta Derm-Venereol* 52:211, 1972.

10. Stephens FO: Bleomycin—a new approach in cancer chemotherapy. *Med J Aust* 1:1277, 1973.

11. Mohs FE: The chemosurgical method for the microscopically controlled excision of cutaneous cancer, in Epstein E (ed): *Skin Surgery*, ed 2. Philadelphia, Lea & Febiger Publishers, 1962, pp 223-242.

Stevens-Johnson Syndrome Associated With *Mycoplasma pneumoniae* Infections

Richard D. Sontheimer, MD; Richard A. Garibaldi, MD; Gerald G. Krueger, MD

• The Stevens-Johnson syndrome is a multisystem inflammatory disorder associated with a widespread erythematous eruption that can result in death. Although usually considered a pediatric disease, this syndrome frequently affects adults. There are many etiologic associations including drugs and infections; however, the pathophysiology of the syndrome remains obscure. Treatment at present is symptomatic and supportive. Although frequently used, the beneficial role of corticosteroids in this syndrome remains to be proved. The case report describes a young woman who after treatment with several drugs developed the Stevens-Johnson syndrome in association with a *Mycoplasma pneumoniae* infection. We include a brief review of the literature with emphasis on the Stevens-Johnson syndrome's association with *M pneumoniae* infections. Those caring for patients with skin disease should be aware of the association between such treatable infections and this syndrome.

(*Arch Dermatol* 114:241-244, 1978)

The Stevens-Johnson syndrome (hereafter called SJ syndrome), or erythema multiforme major, is a well-defined systemic disease with serious cutaneous manifestations. Although frequently seen in the pediatric age group, this disease can also produce a life-threatening illness with multisystem involvement in the adult. Drugs and infections are the most frequent etiologic associations. We saw a young woman who developed the SJ syndrome with severe pulmonary involvement after treatment with multiple drugs in association with a treatable infection, *Mycoplasma pneumoniae*, who responded favorably to a combination of antibiotic and systemic corticosteroid therapy.

Accepted for publication Feb 18, 1977.

From the Divisions of General Internal Medicine (Dr Garibaldi) and Dermatology, (Drs Krueger and Sontheimer) Department of Medicine, University of Utah College of Medicine, Salt Lake City. Dr Sontheimer is presently a Dermatology Foundation Fellow at the University of Texas Health Science Center at Dallas.

Reprint requests to Division of Dermatology, University of Texas Health Science Center at Dallas, 5323 Harry Hines Blvd, Dallas, TX 75235 (Dr Sontheimer).

REPORT OF A CASE

A 23-year-old woman was admitted to our hospital in October 1975, with a history of fever, pain, and redness and swelling in her eyes, mouth, and vagina of three days' duration. She had been well until ten days prior to admission when she developed a flu-like illness consisting of diffuse myalgias, chills without fever, headache, mild sore throat, and a nonproductive cough. She had been treated symptomatically with a cough syrup containing sodium citrate ammonium chloride, chloroform, ethanol, and dextromethorphan hydrobromide, and cold tablets containing chlorpheniramine maleate, aspirin, caffeine, and phenylephrine hydrochloride. She had had no known contact with persons having a similar illness. Three days prior to admission she developed spiking fever, chills, and "blisters" in her mouth within an eight-hour period. The following day she developed similar blisters on her external genitalia and a bilateral conjunctivitis. She was treated with intramuscular penicillin, vaginal suppositories containing propionate sodium and water-soluble chlorophyll derivatives, and a viscous lidocaine gargle without improvement. She was then referred to our hospital. Past medical history was unremarkable except that the patient had undergone her first pregnancy and uncomplicated delivery six weeks prior to admission. Physical examination on admission included an oral temperature of 40 C; pulse, 140 beats per minute; respirations, 24/min; and blood pressure, 120/70 mm Hg. Three nonconfluent, 3-mm vesicles on erythematous bases were observed in a grouped array on the left side of her chin and two other 3-mm erythematous papules were noted on her right pretibial surface. No target lesions were noted at this time. Ophthalmologic examination showed bilateral bulbar conjunctivitis and yellow matted lashes. Hemorrhagic crusting of the upper and lower lips was apparent. An adherent, white, membranous exudate and superficial erosions were observed over her entire oral mucosa. Her tympanic membranes were normal. Bibasilar pulmonary rales were present without evidence of consolidation. Results of heart, abdominal, and rectal examinations were normal. Pelvic examination disclosed bullous lesions on the labia minora and an erythematous vaginal mucosa with the presence of a thick, white discharge. Results from the remainder of the physical examination were within normal limits.

Laboratory studies on admission included the following values: hematocrit, 41%; WBC count, 10,700 (5% band forms, 74% polymorphonuclear neutrophils, 18% lymphocytes, 3% mononuclear cells). Values for serum electrolytes, routine 12-channel screening chemical analyses, and urinalysis were within normal limits. An ECG showed a sinus tachycardia with a rate of 140. Arterial blood gases on room air were as follows: pH 7.51, Po_2, 40 mm Hg; Pco_2, 29 mm Hg; and O_2 saturation, 80.6%. A Tzanck smear of exudate from the base of the vesicles on the left chin was negative for multinucleated giant cells. Chest roentgenogram showed a poorly defined left lower lobe infiltrate. Blood, sputum, and urine cultures taken on admission were all negative for bacterial pathogens; sputum and pharyngeal cultures were also negative for *M pneumoniae*. Cold hemagglutinins on the day of admission were positive to a titer of 1:16 and increased to a titer of 1:128 after one week of hospitalization. The *M pneumoniae* complement fixation titers likewise increased from 1:32 to 1:128. Fluid from skin bullae, which developed later in the course of her illness, was also cultured for *M pneumoniae*; however, these cultures were obtained after intravenous erythromycin therapy had been initiated and were negative.

Hospital Course

The admitting diagnosis was SJ syndrome secondary to *M pneumoniae*, later confirmed by serologic testing. On the night of admission, treatment was initiated with erythromycin lactobionate, 500 mg intravenously every six hours, intravenous fluids and oxygen via nasal prongs. During the second day of hospitalization, the appearance of target lesions on her chin and right leg and the progression of the conjunctivitis prompted the initiation of therapy with hydrocortisone sodium succinate (Solu-Cortef), 80 mg intravenously every six hours. She became afebrile with general symptomatic improvement 12 hours after starting corticosteroid treatment and 36 hours after receiving erythromycin. However, during the next few days

Documented Cases of Stevens-Johnson Syndrome Associated With *Mycoplasma pneumoniae* Infections*

	No. of Cases	Age, yr & Sex	Positive *M pneumoniae* Cultures: Skin Lesions	Positive *M pneumoniae* Cultures: Respiratory Tract	*M pneumoniae* Complement Fixation Titers ≥ 1:64	Cold Agglutinins ≥ 1:64	Pulmonary Involvement
Ludlam et al[26] 1964	5	10-16 (5-M)	NR	0/5	5/5	0/5	3/5
Foy et al[29] 1966	1	14-M	NR	1/1	1/1	NR	1/1
Lyell et al[22] 1967	5	11-19 (3-F, 2-M)	2/5	4/5	2/5	0/5	NR
Katz et al[30] 1967	1	19-M	NR	1/1	1/1	0/1	1/1
Sieber et al[31] 1967	1	22-M	NR	1/1	1/1	NR	1/1
Fleming et al[32] 1967	2	9-M 8-M	NR	2/2	2/2	2/2	1/2
Cannell et al[33] 1969	2	23-M 28-F	NR	1/2	2/2	2/2	2/2
Teisch et al[34] 1970	1	27-M	NR	0/1	1/1	0/1	0/1
Bell et al[35] 1971	1	11-F	NR	1/1	1/1	1/1	1/1
Saunders & Johnson[36] 1971	1	10-M	NR	1/1	1/1	NR	1/1
Kolze[37] 1973	1	18-F	NR	0/1	1/1	1/1	0/1
Lascari et al[38] 1974	1	16-M	NR	0/1	1/1	1/1	1/1
Nathan[8] 1975	1	NR	NR	1/1	0/1	1/1	NR

*NR indicates not reported.

the patient's pulmonary status deteriorated with increasing cough, diffuse rhonchi, deteriorating blood gas levels, and progression of pneumonia by chest roentgenogram. A ventilation and perfusion lung scan was not suggestive of pulmonary emboli. After initiation of intensive chest physiotherapy and postural drainage, the patient's severe hypoxemia and pneumonia gradually resolved. The skin and mucous membrane involvement improved steadily with continued steroid therapy and was almost resolved 17 days after admission when the patient returned home. At home she was gradually tapered off the steroid regimen and has remained well without residual disability.

COMMENT

Hebra is generally given credit for differentiating erythema multiforme (erythema multiforme exudativum) from other erythemas in 1866.[1] In 1922 Stevens and Johnson described two cases that resembled erythema multiforme with associated mucosal and ophthalmic involvement and severe constitutional symptoms.[2] Their names continue to be associated with the clinical illness that modern dermatology texts classify as erythema multiforme major. There continues to be some confusion concerning the terminology of this illness in the modern literature. Some terms that are interchangeably used for the SJ syndrome are eruptive fever associated with stomatitis and ophthalmia, ectodermosis erosiva pluriorificialis, dermatostomatitis, mucosal respiratory syndrome, and a form of the mucocutaneous ocular syndrome.

Although a relatively common cause for hospitalization, there are few data regarding the epidemiology of the SJ syndrome. The incidence of the syndrome is unknown; but it accounted for approximately one case in every 1,250 medical admissions to the Johns Hopkins Hospital between 1952 and 1965.[3] Cases occur more frequently in the spring and fall and rates are slightly higher for males than females. It has been reported to occur in minor epidemics.[4] It is most common in the first three decades of life; however, when older persons are affected, they generally have a more serious form of the illness.

The SJ syndrome usually occurs in individuals without previous underlying debilitating diseases. The prodrome resembles a common upper-respiratory tract infection with fever, malaise, nonproductive cough, sore throat, chest pain, nausea and vomiting, diarrhea, myalgias, or arthralgias lasting from one to 14 days. Mucous membrane involvement is heralded by the appearance of a high spiking fever. Bullous lesions may occur on all mucosal surfaces including conjunctivae, buccal mucosa, tongue, lips, nasal mucosa, genitalia, and the perirectal area. A symmetrical, erythematous cutaneous eruption may appear on the extensor surfaces of the upper and lower extremities, including the palms and soles. The primary lesions on the skin are usually maculopapular or urticarial but occasionally can be vesiculobullous. The primary lesions soon evolve to the typical "iris," "bull's-eye," or "target" lesions characteristic of erythema multiforme. The eruption then spreads from the extremities to the trunk. Lesions appear in crops during the next two to three weeks. The individual lesions heal without scarring in about one week; however, postinflammatory hyperpigmentation or hypopigmentation may result. The mucosal bullous lesions soon become confluent in the mouth and a gray or white pseudomembrane develops over the entire oral mucosa. Hemorrhagic crusting of the lips becomes a prominent feature of the patient's outward appearance. In males, balanitis may produce adhesions between the foreskin and the glans; in females, severe vaginal involvement may result in fibrotic bands and scarring.[5] Eye involvement can remain limited to a simple conjunctivitis or can progress to a severe keratitis; panophthalmitis with subsequent blindness has been reported to occur in 3% to 10% of the cases.[6,7] The course of the illness usually lasts four to six weeks but has been reported to persist as long as two to three months. Relapse rates of 13%[6] and 22%[8] have been reported. It is not entirely clear whether the recurrences are spontaneous or follow the reappearance of an etiologic association, such as recurrent herpes labialis.[9,10]

The majority of individuals recover completely from their skin and mucous membrane disease without complication; however, a small percentage of patients develop life-threatening systemic complications. Death has been reported to occur in 3% to 25% of cases,[3,6,8,11,12] and death is usually attributed to secondary bacterial invasion of pulmonary or cutaneous lesions in elderly individuals with

concurrent debilitating illnesses. Pulmonary involvement occurs in 15% to 30% of the patients.[3,6,8] There are relatively few data regarding the pathophysiology of this complication and no data whatsoever concerning the nature of pulmonary function abnormalities in the SJ syndrome. Pulmonary abnormalities may result from the direct extension of oral and pharyngeal mucosal lesions into the tracheobronchial tree.[13] Pulmonary involvement with the SJ syndrome is believed to be a serious prognostic factor. In individual case reports, the pneumonitis is described as transient, patchy perihilar, or lower lobe infiltrates. When the SJ syndrome is secondary to *M pneumoniae*, it can be very difficult to determine which of these two disease processes is responsible for the pulmonary findings, as was the case in our patient.

In addition to pneumonia, there have been single case reports of pneumothorax[14] and mediastinal emphysema[15] complicating the SJ syndrome. Cardiac complications are rare; there have been several single case reports of pericarditis, pericardial effusion, and atrial arrhythmias temporally related to the SJ syndrome.[16]

Serious gastrointestinal complications are uncommon; case reports have described esophageal strictures,[17] ulcerative colitis, and ulcerative proctitis[18] as complications of the syndrome. Inflammatory renal lesions similar to acute glomerulonephritis, subacute nephritis, nephrotic syndrome, and chronic uremia have been described.[19] One case report documents the development of rim-like calcification of the urinary bladder mucosa during an attack of SJ syndrome.[20]

Many etiologic agents have been implicated as causes of the SJ syndrome:

Drugs
- Amithiozone
- Antipyrine
- Antitoxins
- Antidiabetic agents
- Arsenic
- Barbiturates
- Belladonna
- Bromides
- Carbamazepine
- Cephalexin
- Chloroquine
- Clindamycin
- Codeine
- Digitalis
- Gold salts
- Hydralazine hydrochloride
- Iodides (cough medicines)
- Meprobamate
- Mercurials
- Oral contraceptives
- Penicillins
- Phenacetin
- Phenicarbazide
- Phenophthalein
- Phenylbutazone
- Phenytoin sodium
- Pyrinium
- Quinine
- Salicylates
- Succinimide
- Sulfa eyedrops
- Sulfonamides
- Tetracycline
- Thiouracil
- Trimethadione

Infections
- Viral
  - Coxsackievirus
  - B5
  - Echovirus
  - Herpes simplex
  - Influenza
  - Mumps
- Mycoplasmal
  - *Mycoplasma pneumoniae*
- Bacterial
  - Diphtheria
  - Erysipeloid
  - Meningococcus
  - Pneumococcus
  - Psittacosis
  - Tuberculosis
  - Tularemia
  - Typhoid fever
- Mycotic
  - Coccidiodomycosis
  - Histoplasmosis
- Protozoan
  - Spirochetes
  - Malaria
  - Trichomoniasis

Collagen Diseases
- Systemic lupus erythematosus
- Scleroderma

Food
- Chocolate
- Margarine
- Mushrooms

Contactants
- Coal tar
- Poison ivy

Internal Malignancies

Miscellaneous
- X-ray
- Severe chemical burns
- Vaccines
  - Bacillus Calmette-Guerin
  - Polio
  - Smallpox
- Hormonal
  - Menses
  - Pregnancy
- Unknown

(Adapted from Stillman.[11])

Medications or infections are the most commonly mentioned precipitating factors.[3] Oftentimes, it is impossible to determine whether a certain drug caused the syndrome or was prescribed to treat the early symptoms of the syndrome, which can resemble the early stages of a nonspecific upper-respiratory tract infection. This dilemma is exemplified by our patient who was treated with cold tablets and a cough syrup before developing the mucous membrane lesions. The diversity and number of proposed causes suggest that the syndrome represents a final common hypersensitivity reaction pattern produced by a multitude of stimuli. Some authors, however, argue that the syndrome could result from activation of a latent viral or mycoplasma infection by one of the agents listed.[21,22]

The association of *M pneumoniae* and the SJ syndrome was made in 1945; a total of 17 military recruits with classic atypical pneumonia were described with concurrent conjunctivitis, membranous stomatitis, irregular skin eruptions, and lesions on the penis.[23] This association was called "the mucosal respiratory syndrome." Other similar outbreaks were subsequently reported among nonmilitary populations.[24,25] In 1962 *M pneumoniae* was first culturally isolated and implicated as a causal factor in the atypical pneumonia syndrome. In 1964 Ludlam et al reported finding substantial positive complement fixation titers for *M pneumoniae* in the sera of five consecutive patients with the SJ syndrome.[26] This marked the first documented association between the SJ syndrome and *M pneumoniae* infection. This finding stimulated a great deal of investigation of this relationship with the hope that a treatable disease such as *M pneumoniae* infection could possibly be causally related to a morbid and potentially lethal disease such as SJ syndrome. Since then, at least 23 other cases of well-documented *M pneumoniae* infection associated with SJ syndrome or erythema multiforme have been reported. These cases are characterized in the Table. Cases are not included in which the diagnosis of *M pneumoniae* infection is claimed on the basis of positive cold hemagglutinins alone, since it is well documented that a positive cold hemagglutinin determination is not specific for *M pneumoniae* infection.[27] In some of these cases the patients had been treated with drugs prior to onset of the SJ syndrome and documentation of *M pneumoniae* infection; in these cases, as well as our own, it was impossible to be certain whether the drugs or the *M pneumoniae* infection actually caused the SJ syndrome.

The diagnosis of a recent *M pneumoniae* infection is confirmed by cultural isolation of the organism (technically difficult requiring specialized media) or elevation of the complement fixing antibody titer to 1:64 or above (or a threefold increase in the titer of convalescent sera compared to the acute sera).

Despite convincing evidence that *M pneumoniae* may be responsible for some cases of SJ syndrome, it probably cannot account for the majority of cases. There are many well-documented cases of SJ syndrome, with and without pulmonary involvement, that have been studied culturally and serologically for mycoplasma infection in which no such evidence of infection has been found.[28,29] In addition, it is not yet resolved whether *M pneumoniae* infection is present more commonly in cases of SJ syndrome with pulmonary involvement compared to those without pulmonary abnormalities; however, the majority of cases of SJ syndrome secondary to proved mycoplasma infection (Table) had evidence of pulmonary involvement. As previously cited, in most series of SJ syndrome of diverse

origins, pulmonary involvement is reported in only 15% to 30% of cases. The difference in frequency of pulmonary involvement in SJ syndrome patients with and without *M pneumoniae* infection could have resulted from selection bias alone, however.

Treatment of the SJ syndrome is symptomatic at present because of the lack of understanding of the pathogenesis of the disease. Elimination or treatment of suspected causal factors is always indicated, particularly treatable infections such as *M pneumoniae*. Systemic corticosteroids in dosage equivalents of 60 to 80 mg of prednisone per day is usually reserved for the most severely affected cases. There are no well-controlled studies proving the benefit of systemic corticosteroid therapy at present. In fact, an author recently suggested that corticosteroid treatment may even prolong the illness and produce more medical complications; however, his conclusions are drawn from a retrospective review of cases, the shortcomings of which he clearly points out.[39] In general, the mortality for the disease has not changed since the introduction of corticosteroid therapy.[6] The problems with use of systemic corticosteroids in the SJ syndrome include the added risk of secondary infections and flaring of the disease with premature withdrawal of therapy. Recommendations for the ocular involvement include topical antibiotics, topical corticosteroids, and frequent saline solution irrigations[6]; however, it is unresolved whether the type of therapy used during the acute phase of the disease actually affects the outcome or prevents the late complications of ocular involvement such as blindness.[7]

There are many unanswered questions regarding this potentially fatal illness. In view of the cultural isolation of *M pneumoniae* from bullous fluid in two patients described by Lyell et al,[22] it would be important to know if nonviable *M pneumoniae* antigen could be demonstrated in this bullous fluid. Considering the recent concern over the possible detrimental effects of corticosteroids in this illness, a prospective, controlled trial testing the efficacy and safety of these drugs in the SJ syndrome is warranted, although such a trial would be difficult to carry out. Characterization of pulmonary function abnormalities in the SJ syndrome with or without clinical evidence of pulmonary involvement should be done.

In conclusion, the severe systemic illness comprising the SJ syndrome appears to result from a hypersensitivity state produced by one or a combination of many different drugs, infections, contactants, and metabolic imbalances. The exact nature of the hypersensitivity state has not been investigated. Considering the potential for a morbid or fatal outcome of the SJ syndrome, every effort should be made to uncover any associated treatable pathogenic infection such as *M pneumoniae*. If such infection is found or strongly suspected, appropriate treatment should be initiated as soon as possible, even though it may be impossible to exclude the possibility that prior drug treatment actually caused the syndrome. Finally, the following question should be considered. Should not all patients suffering from severe SJ syndrome with any evidence of pulmonary involvement be given an antimycoplasmal antibiotic such as erythromycin until the possibility of a treatable infection has been excluded?

Nonproprietary Names and Trademarks of Drugs

Amithiozone—*Panrone, Teebazone, Tibione.*

Carbamazepine—*Tegretol.*

Cephalexin monohydrate—*Keforal.*

Clindamycin—*Cleocin.*

References

1. Bukantz SC: The Stevens-Johnson syndrome. *DM*, October 1968, pp 1-36.
2. Stevens AM, Johnson FC: A new eruptive fever associated with stomatitis and ophthalmia: Report of 2 cases in children. *Am J Dis Child* 24:526-533, 1922.
3. Bianchine JR, Macaraeg PVJ, Lasagna L, et al: Drugs as etiologic factors in Stevens-Johnson syndrome. *Am J Med* 44:390-405, 1968.
4. Gustafson SR, Coursin DB: *The Pediatric Patient.* Philadelphia, JB Lippincott, 1966, p 217.
5. Moschella SL: Hypersensitivity and miscellaneous inflammatory disorders, in Moschella SL, Pillsbury DM, Hurley JH (eds): *Dermatology.* Philadelphia, WB Saunders Co 1975, chap 8.
6. Nathan MD: Stevens-Johnson syndrome: Twenty-three cases and their otolaryngologic significance. *Laryngoscope* 85:1713-1724, 1975.
7. Arstikaitis MJ: Ocular aftermath of Stevens-Johnson syndrome: Review of 33 cases. *Arch Ophthalmol* 90:376-379, 1973.
8. Ashby DW, Lazar T: Erythema multiforme exuditivum major (Stevens-Johnson syndrome). *Lancet* 1:1091-1095, 1951.
9. Strom J: Herpes simplex virus as a cause of allergic mucocutaneous reactions (ectodermosis erosiva pluriorificialis, Stevens-Johnson's syndrome, etc.) and generalized infection. *Scand J Infect Dis* 1:3-10, 1969.
10. Shelly WB: Herpes simplex virus as a cause of erythema multiforme. *JAMA* 201:153-156, 1967.
11. Claxton RC: A review of 31 cases of Stevens-Johnson syndrome. *Med J Aust* 50:963-966, 1963.
12. Carrol OM, Bryan PA, Robinson RJ: Stevens-Johnson syndrome associated with long-acting sulfonamides. *JAMA* 195:691-693, 1966.
13. Stillman MT: Stevens-Johnson syndrome. *Minn Med* 51:273-280, 1968.
14. Broadbent RV: Stevens Johnson disease presenting with pneumothorax. *Rocky Mountain Med J* 64:69-72, 1967.
15. Genieser B, Becker MH, Rothman J: Mediastinal emphysema complicating Stevens-Johnson syndrome. *Arch Dermatol* 105:421-423, 1972.
16. Schartum S: Stevens-Johnson syndrome with cardiac involvement: Report of 2 cases. *Acta Med Scand* 179 (pt 6):729-735, 1966.
17. Stein MR, Thompson CK, Sawicki JE, et al: Esophageal stricture complicating Stevens-Johnson syndrome: A case report. *Am J Gastroenterol* 62:435-439, 1974.
18. Bøe J, Dalgaard JB, Scott D: Mucocutaneous-ocular syndrome with intestinal involvement: A clinical and pathological study of four fatal cases. *Am J Med* 25:857-867, 1958.
19. Comaish JS, Kerr DNS: Erythema multiforme and nephritis. *Br Med J* 2:84-88, 1961.
20. Hessl JM, Gaylor LF: Stevens-Johnson syndrome with vesical calcification: A case report. *J Urol* 107:662-664, 1972.
21. Coursin DB: Stevens-Johnson syndrome: Nonspecific parasensitivity reaction? *JAMA* 198:113-116, 1966.
22. Lyell A, Gordon AM, Dick HM, et al: Mycoplasmas and erythema multiforme. *Lancet* 2:1116-1118, 1967.
23. Stanyon JH, Warner WP: Mucosal respiratory syndrome. *Can Med Assoc J* 53:427-434, 1945.
24. Finland M, Jolliffe LS, Parker F Jr: Pneumonia and erythema multiforme exudativum: Report of four cases and three autopsies. *Am J Med* 4:473-492, 1948.
25. Commission on acute respiratory diseases: Association of pneumonia with erythema multiforme exudativum. *Arch Intern Med* 78:687-710, 1946.
26. Ludlam GB, Bridges JB, Benn EC: Association of Stevens-Johnson syndrome with antibody for *Mycoplasma pneumoniae*. *Lancet* 1:958-959, 1964.
27. Murray HW, Masur H, Senterfit LB, et al: The protean manifestations of *Mycoplasma pneumoniae* infections in adults. *Am J Med* 58:229-242, 1975.
28. Lyell A, Gordon AM, Dick HM, et al: The role of *Mycoplasma pneumoniae* infection in erythema multiforme. *Proc R Soc Med* 61:38-39, 1968.
29. Foy HM, Kenny GE, Koler J: *Mycoplasma pneumoniae* in Stevens-Johnson syndrome. *Lancet* 2:550:551, 1966.
30. Katz HI, Wooten JW, Davis RG, et al: Stevens-Johnson syndrome. *JAMA* 199:164-166, 1967.
31. Sieber OF, John TJ, Fulginiti VA, et al: Stevens-Johnson syndrome associated with *Mycoplasma pneumoniae* infections. *JAMA* 200:79-81, 1967.
32. Fleming PC, Kreiger E, Turner JAP, et al: Febrile mucocutaneous syndrome with respiratory involvement, associated with isolation of *Mycoplasma pneumoniae*. *Can Med Assoc J* 97:1458-1459, 1967.
33. Cannell H, Churcher GM, Milton-Thompson GJ: Stevens-Johnson syndrome associated with *Mycoplasma pneumoniae* infection. *Br J Dermatol* 81:196-199, 1969.
34. Teisch JA, Shapiro L, Walyer RA: Vesiculopustular eruption and mycoplasma infection. *JAMA* 211:1694-1697, 1970.
35. Bell WE, Riegle EV, Golden B: Erythema multiforme exudativium (Stevens-Johnson syndrome) in association with *Mycoplasma pneumoniae*. *Clin Pediatr* 10:184-187, 1971.
36. Saunders DY, Johnson HW: Stevens-Johnson syndrome associated with *Mycoplasma pneumoniae* infection. *Am J Dis Child* 121:243-245, 1971.
37. Kolze V: Stevens-Johnson syndrome associated with *Mycoplasma pneumoniae* infection. *J Laryngol Otolaryngol* 87:183-184, 1973.
38. Lascari AD, Garfunkel JM, Mauro DJ: Varicella-like rash associated with mycoplasma infection. *Am J Dis Child* 128:254-255, 1974.
39. Rasmussen JE: Erythema multiforme in children: Response to treatment with systemic corticosteroids. *Br J Dermatol* 95:181-186, 1976.

Bullous Pemphigoid and Other Disorders Associated With Autoimmune Phenomena

Jeffrey P. Callen, MD; Thomas F. Anderson, MD; Joseph J. Chanda, MD; William B. Taylor, MD

• Although bullous pemphigoid is a disease associated with autoantibodies, it rarely has been associated with other diseases associated with autoimmune phenomena. We report the occurrence of bullous pemphigoid, pernicious anemia, and rheumatoid arthritis in a patient.
(*Arch Dermatol* 114:245-246, 1978)

Bullous pemphigoid (BP) is a disorder in which an antibody directed against the basement membrane zone (BMZ) can be demonstrated in the skin by direct immunofluorescence and in the serum by indirect immunofluorescence.[1,2] Other bullous disorders such as dermatitis herpetiformis and pemphigus have been associated with other diseases associated with autoantibodies, particularly of the joints and the hematopoietic system.[3-6] Although felt to be an "autoimmune disorder," BP only rarely has been reported with other disorders associated with autoimmune phenomena.[7-9] Autoantibodies (other than anti-BMZ) have been reported in patients with BP (rheumatoid factor, antinuclear factor)[4]; however, their importance is unknown because their presence in an older population is not unusual.[10,11] We report the occurrence of pernicious anemia, rheumatoid arthritis, and bullous pemphigoid in the same patient.

Accepted for publication Jan 5, 1977.
From the Department of Dermatology, University of Michigan Medical School, Ann Arbor.
Reprint requests to Department of Dermatology, University of Louisville School of Medicine, Louisville, KY 40202 (Dr Callen).

REPORT OF A CASE

History

A 70-year-old woman was admitted to the University Hospital in September 1975 for treatment of a blistering disorder that had been present for six weeks. The patient had been healthy until age 27 when she developed migratory arthralgias, arthritis, and morning stiffness. The arthritis progressed, and at the time of admission she was unable to walk or care for herself. She also had a history of a toxic goiter when in her 20s, tuberculosis in her early 30s, and hypertension and congestive heart failure for the five years preceding admission. Her skin problem began abruptly with successive crops of pruritic, painful, tense blisters on an erythematous base. No symmetry was noted by history, and pruritus was unrelieved by breaking the blisters. She denied a history of previous skin disease, bowel disorders, photophobia, Raynaud's phenomena, or muscle disease.

Her family history did not include relatives with bullous disorders of the skin, rheumatoid arthritis, or other autoimmune disorders. Her medications on admission included digitoxin, and alfalfa seed. The remainder of her history was unremarkable.

Physical Examination

The patient was a cachectic woman with obvious joint deformities and bullous skin lesions. There were multiple, large tense bullae on an erythematous base (Figure) covering 60% to 70% of her body surface. There was no apparent symmetry or grouping of the lesions. Oral erosions were located on the tongue. The Nikolsky sign was absent. The right lobe of the thyroid was firm and slightly enlarged. There was a mild pectus excavatum. Cardiomegaly was not detected. There was a grade 3/6 holosystolic murmur along the lower left sternal border, without any radiation. There was decreased range of motion and pain in the elbows, wrists, metacarpal-phalangeal (MCP) joints, and proximal interphalangeal joints bilaterally. There was ulnar deviation at the MCP joints bilaterally. Demonstrable changes of acute arthritis were not present. Symmetrical synovial thickening was noted in the wrists. Results from the remainder of the physical examination were normal.

Tense bulla.

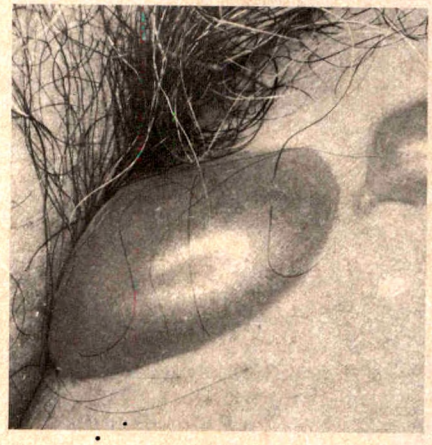

Laboratory Evaluation

The hematocrit level was 22.6%; the WBC count was 3,200/cu mm, with a normal differential cell count. Many hypersegmented polymorphonuclear neutrophils were noted. The reticulocyte count was 2.4%. The mean corpuscular volume was 123 cuμ (normal, 80 to 105). The platelet count was normal. The lactic dehydrogenase (LDH) level was 470 units (normal, 205 units), and the LDH isoenzyme pattern showed elevated fractions 1 and 2 (fast fractions). The bone marrow was hypercellular with evidence of megaloblastosis and impaired maturation of cells. Serum folate level was 4.8 ng/ml (normal, 5 to 15), and the serum B_{12} level was 47 pg/ml (normal, 290 to 440). A Schilling's test was performed and the first stage was substantially low: 0.75% activity (normal, > 10%). The second stage disclosed 15.3% activity, and her reticulocyte count increased to 10%. Following the test, her hematocrit value gradually returned toward normal. Roentgenograms of her upper gastrointestional tract showed atonic stomach. A gastroscopy was performed and disclosed atrophic gastritis; no evidence of carcinoma or ulceration was present. Roentgenograms of her hands showed a narrowed radiocarpal joint, flexion deformities of the MCP joints, and erosions of the MCP heads bilaterally. These findings were suggestive of severe deformity due to rheumatoid arthritis. The rheumatoid factor was positive at 1:2,560. The antinuclear factor was negative. Findings from protein electrophoresis and immunodiffusion were normal. Results of skin biopsy demonstrated a subepidermal bulla consistent with a diagnosis of bullous pemphigoid. Peribullous skin was examined by direct immunofluorescence for IgG, IgM, IgA, C4, and C3. This showed deposition of IgG, C4, and C3 at the BMZ. Serum was collected for indirect immunofluorescence and was negative for pemphigus antibodies, but positive (1:20) for BP antibodies. Tests for parietal cell antibodies and thyroid antibodies were negative.

Hospital Course

The diagnosis of BP, pernicious anemia, and rheumatoid arthritis were firmly established. The patient was treated with parenterally administered cyanocobalamin, and her hematocrit level increased to 40%. Her indexes also were normal within one month. Prednisone (40 mg/day) controlled the BP with only occasional bullae. The hospital course was complicated by a urinary tract infection, and transient syndrome of inappropriate antidiuretic hormone release. The patient was discharged and has been followed up by her local physician.

COMMENT

The demonstration of IgG at the BMZ of the skin and the presence of circulating anti-BMZ antibodies has implicated BP as an "autoimmune disorder."[1,2]

Unlike the other vesiculobullous disorders (pemphigus, dermatitis herpetiformis), there has been little association of BP with diseases associated with autoimmune phenomena.[4] In a previous study, Perrot et al have shown the presence of antinuclear factor in 57% of 28 patients with BP; however, this was an uncontrolled observation.[12] It is known that the prevalence of antinuclear factor is 16% in patients more than 60 years old,[11] and, therefore, results from this study may not be valid. Jordon et al reported the coexistence of BP and systemic lupus erythematosus (SLE) in three patients[9]; however, only one of their patients had SLE according to the American Rheumatism Association (ARA) criteria.[12] Salo and Rasanen have reported the coexistence of BP and rheumatoid arthritis in five of 23 patients they examined.[7] This was an uncontrolled study that did not state the criteria on which the diagnosis of the arthritis was based. Three of the patients in their series with appreciable elevations of rheumatoid factor (> 1:1,000) were more than 65 years of age. In addition, the same authors evaluated antinuclear factor in their patients. Ten of 19 patients tested had a positive antinuclear factor; however, 5 of these were < 1:10, which we would consider negative. The highest titer observed was 1:100 and four of the five patients in whom this was observed were 74 years of age or older. The authors concluded that other autoimmune disorders such as lupus erythematosus and rheumatoid arthritis are more frequent in patients with BP. Careful review of associations of BP with these other diseases that have appeared does not allow us to confirm the diagnosis of arthritis or erythematosus.[7-9]

Our patient had "definite" rheumatoid arthritis, according to the criteria of the ARA (five criteria, see case report), which antedated her BP and pernicious anemia. The diagnosis of BP was firmly established with circulating anti-BMZ antibodies and typical direct immunofluorescence. Although gastric antibodies were not present in the patient's serum, the diagnosis of pernicious anemia was well established. Our patient has three well-established disorders associated with autoantibodies. Although pernicious anemia has been reported in association with other bullous cutaneous disorders (dermatitis herpetiformis and pemphigus) and other "autoimmune" disorders, particularly autoimmune thyroiditis, it has not been reported to be coexistent with BP.[4] Although there are previous reports of the association of BP and rheumatoid arthritis,[7,8] the authors have not substantiated the diagnosis of the arthritis by use of the ARA criteria.

It has been suggested recently that BP is an "autoimmune" disorder because of the presence of immunoglobulins in the skin and serum.[1,2] A prospective controlled study of the incidence of autoantibodies and "autoimmune" diseases in patients with BP is needed to confirm the association we report.

References

1. Beutner EH, Jordon RE, Chorzelski TP: The immunopathology of pemphigus and pemphigoid. *J Invest Dermatol* 51:63-80, 1968.
2. Jordon RE: Complement activation in bullous skin disease. *J Invest Dermatol* 65:162-169, 1975.
3. Mackie RM, Saikia NK, Morley WN: A case of pemphigus in association with addisonian pernicious anemia. *Br J Dermatol* 88:139-141, 1973.
4. Alexander JO: Immunological aspects of dermatitis herpetiformis, in *Dermatitis Herpetiformis*. Philadelphia, WB Saunders Co, 1975, pp 186-224.
5. Whittingham S, MacKay IR: The pemphigus antibody and immunopathies affecting the thymus. *Br J Dermatol* 84:1-6, 1971.
6. Wyburn-Mason R: Coeliac syndrome in dermatitis herpetiformis. *Lancet* 1:1250, 1968.
7. Salo OP, Rasanen JA: Pemphigoid and rheumatoid arthritis. *Ann Clin Res* 4:173-177, 1972.
8. Lillicrap AD: Rheumatoid arthritis and pemphigoid. *Proc R Soc Med* 56:921-922, 1963.
9. Jordon RE, Muller SA, Hale WL, et al: Bullous pemphigoid associated with systemic lupus erythematosus. *Arch Dermatol* 99:17-25, 1969.
10. Rodnan GP, McEwen C, Wallace SL, et al: Primer on the rheumatic diseases. *JAMA* 224 (suppl):799-802, 1973.
11. Svec KH, Veit BC: Age-related antinuclear factors: Immunologic characteristics and associated clinical aspects. *Arthritis Rheum* 10:509-516, 1967.
12. Perrot H, Thivolet J, Quincy C, et al: Paraproteinemies dano la pemphigoide bulleuse. *Arch Klin Exp Dermatol* 239:50-56, 1970.

Mycosis Fungoides With Pulmonary Involvement

A Complete Remission

Richard S. Stein, MD

• Biopsy specimens from a 21-year-old man showed mycosis fungoides involving the skin and lungs. Usually such a case represents a fulminant and fatal course of the disease. This patient had a complete remission of his pulmonary disease following sequential therapy with cyclophosphamide, vincristine sulfate, methotrexate, leucovorin calcium, and cytarabine (COMLA).

(*Arch Dermatol* 114:247-249, 1978)

Despite advances in the treatment of mycosis fungoides limited to the skin, visceral involvement in this disorder has generally been associated with a fulminant clinical course and death.[1-5] Sequential combination of cyclophosphamide, vincristine sulfate (Oncovin), methotrexate, leucovorin calcium, and cytarabine (COMLA) has been shown to be highly effective in producing complete remissions, long-term disease-free survival, and possible cures in patients with advanced histiocytic lymphoma, a disease with a similarly fulminant course.[6-9] A case of mycosis fungoides with extensive, bilateral, biopsy-proved lung involvement is presented. The institution of COMLA therapy led to the complete resolution of the pulmonary disease and nearly complete control of the skin lesions. In contrast to the expected clinical course, the patient continues to be clinically free of visceral disease nearly two years following therapy.

Accepted for publication Feb 16, 1977.

From the Department of Medicine, the Medical College of Wisconsin, and Milwaukee County General Hospital, Milwaukee.

Reprint requests to Department of Medicine, Vanderbilt University Hospital, Nashville, TN 37232 (Dr Stein).

REPORT OF A CASE

A 21-year-old man was referred to Milwaukee County General Hospital in April 1975 for evaluation of mycosis fungoides. The patient had noted itching around the eyes and cheeks in 1967. Multiple biopsy specimens had revealed nonspecific changes. In 1974 he developed a generalized macular and patchy erythematous dermatitis involving the scalp, palms, soles, and trunk.

Physical examination showed generalized plaques compatible with mycosis fungoides (Fig 1, left). Axillary adenopathy (2 × 3 cm), inguinal adenopathy (2 × 3 cm), and small cervical nodes were present. Other findings from the physical examination were normal. There was no hepatomegaly or splenomegaly. Laboratory studies disclosed the following values: hematocrit, 43%; WBC, 8,000/cu mm, with 69% polymorphonuclear leukocytes, 20% lymphocytes, 6% monocytes, and 5% eosinophils. A skin biopsy specimen confirmed the plaque stage of mycosis fungoides. An axillary lymph node biopsy specimen showed only dermatopathic lymphadenopathy. Examination of the buffy coat disclosed multiple clefted lymphocytes, suggestive of Sézary cells, but a PAS stain on the peripheral smear was negative.

Because of the dermatopathic lymphadenopathy, the questionable Sézary cells, and the rapid progression of the disease, total body irradiation (130 rads) was administered in 13 treatments (April 29 to June 5, 1975) using a 6-meV linear accelerator. This procedure was followed by the administration of total skin electron-beam therapy (3,000 rads). Bulky nodes in the axillae and the groin received 1,500 rads in five treatments.

On Sept 10 the patient reported a two-day history of cough and dyspnea. Some findings from a physical examination were a pulse rate of 110 and respirations of 30/min. An examination of the skin showed multiple, scaly, crusted ulcers. A 2 × 3-cm tumor was present below the left eye; a 2 × 3-cm tumor was present on the right lateral thorax. Mobile nodes (2 × 2 cm) were noted in each axilla. Generalized plaques and multiple 1- to 3-cm nodules and tumors were present. The lungs were clear to percussion and auscultation. A chest x-ray film disclosed bilateral infiltrates (Fig 2, left). Blood gases included a Po_2 of 60 mm Hg on 40% oxygen. On the morning after the patient's admission, an open lung biopsy was performed. This biopsy specimen was interpreted as lymphomatous involvement of the lung, compatible with visceral extension of mycosis fungoides. The patient became progressively more dyspneic.

On Sept 16 COMLA therapy was given as follows: (1) cyclophosphamide, 1,500 mg/sq m intravenously (IV), day 1; (2) vincristine sulfate, 1.4 mg/sq m IV, days 1, 8, and 15; (3) methotrexate, 120/mg/sq m, days 22, 29, 36, 43, 50, 57, 64, and 71; (4) cytarabine, 300 mg/sq m IV, days 22, 29, 36, 43, 50, 57, 64, and 71; and (5) leucovorin calcium, 25 mg/sq m orally every six hours for four dosages, starting 24 hours after the first dosage of methotrexate. A two-week "rest period" occurred at the end of each cycle (Fig 3).

The patient made a gradual recovery, and by Sept 25 he was no longer dyspneic

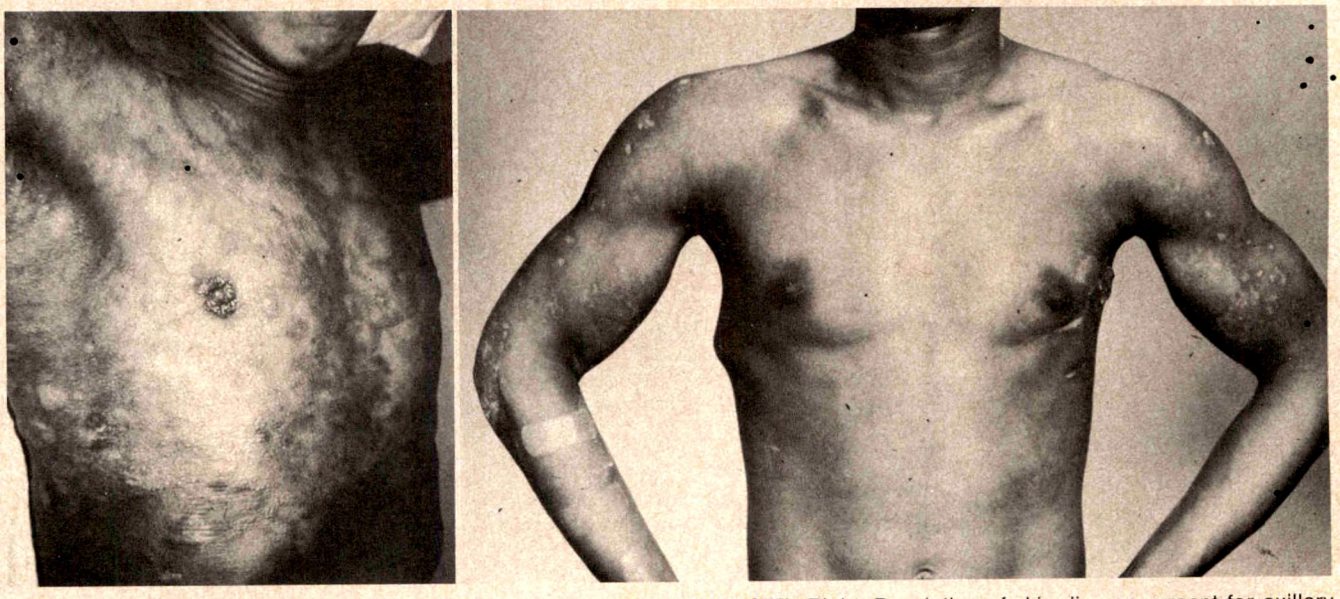

Fig 1.—Left, Extensive skin lesions prior to initiation of therapy (May 27, 1975). Right, Resolution of skin disease, except for axillary tumors, following radiation and COMLA therapy (April 1, 1976).

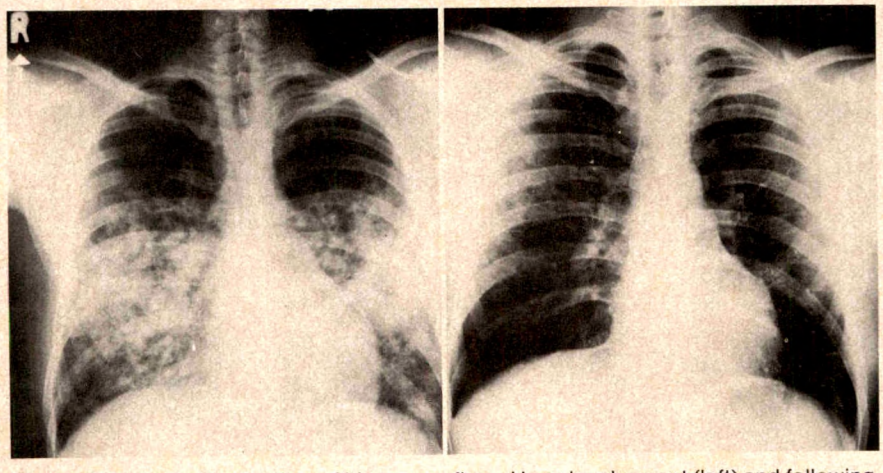

Fig 2.—Chest x-ray films at time of biopsy-confirmed lung involvement (left) and following COMLA therapy (right).

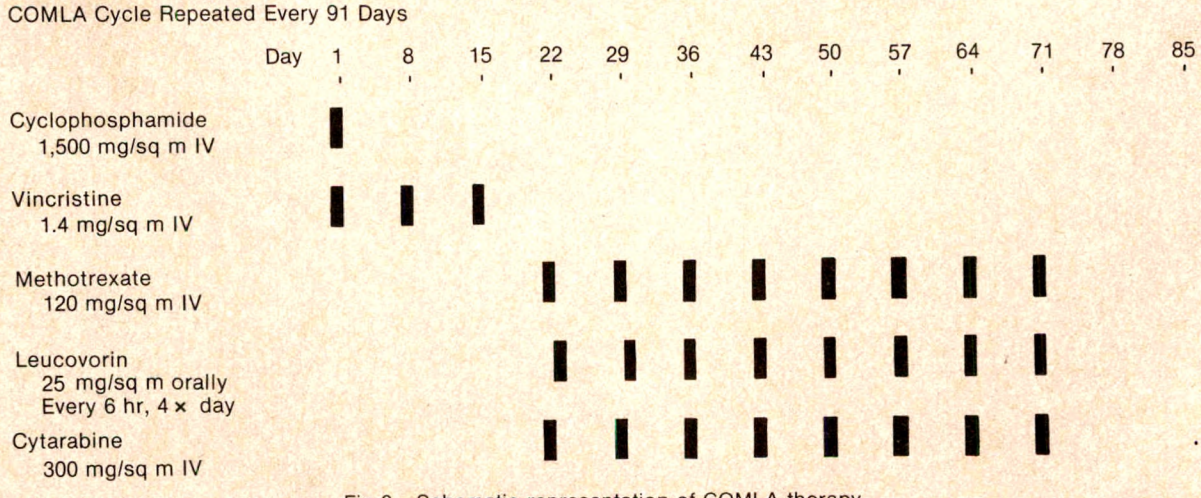

Fig 3.—Schematic representation of COMLA therapy.

at rest or with limited exertion. The chest x-ray film showed minimal improvement in his condition. His hospital discharge was delayed by hemorrhagic cystitis, which slowly resolved. The skin lesions that had been present at the onset of therapy healed.

The pulmonary lesions slowly resolved with continued therapy, and showed complete resolution by March 1976, which was the end of the second cycle of COMLA (Fig 2, right). At this time, the skin disease was completely controlled except for two large necrotic tumors (6 × 6 cm) in each axilla (Fig 1, right). These areas, which were outside the initial axillary ports, were treated by 18 meV electrons, and the tumors had completely resolved by the end of the third cycle. At that time, a final dosage of cyclophosphamide (1,200 mg/sq m) was given and chlorambucil was instituted for maintenance. The patient remained in complete remission until March 1977, when plaques recurred. The pulmonary disease had not recurred as of August 1977.

COMMENT

Skin involvement with mycosis fungoides may respond to radiotherapy,[4,10,11] topical nitrogen mustard,[12] or a number of chemotherapeutic agents, including alkylating agents,[3,12-14] antimetabolites,[15,16] bleomycin,[17] and doxorubicin hydrochloride (Adriamycin).[18] However, visceral lesions eventually occur in 35% to 50% of patients with mycosis fungoides, and usually herald the onset of a fulminant clinical course.[5] Epstein and associates[3] reported a median survival of only three months following the appearance of either hepatomegaly or splenomegaly. In 15 cases of mycosis fungoides in which autopsies were performed, Long and Mihm[19] reported a mean survival of only 11 months following the development of signs of dissemination, including generalized adenopathy.

Pulmonary involvement in mycosis fungoides is not uncommon. In a large autopsy series,[3] pulmonary involvement was exceeded only by involvement of the skin, lymph nodes, and spleen. In the case report, bilateral pulmonary infiltrates developed five months after the diagnosis of mycosis fungoides. An open lung biopsy confirmed the diagnosis of pulmonary mycosis fungoides. In contrast to the expected clinical course, the patient had a dramatic clinical response to sequential combination chemotherapy with COMLA. Following the institution of COMLA therapy, the chest x-ray film was normal, and, except for two axillary skin lesions, the patient achieved a complete remission on chemotherapy.

Since mycosis fungoides is often regarded as an indolent disease, the study of aggressive combination chemotherapeutic regimens in early stages of this disorder has been neglected. Obviously, the presence of an active skin disease may make patients with mycosis fungoides more susceptible to infectious complications of neutropenia, which may result from chemotherapy; however, this was not a problem in the case discussed. While the value of a therapeutic regimen cannot be assessed from a single case, it does illustrate that visceral involvement in mycosis fungoides may not represent a hopeless situation.

Leucovorin calcium for oral administration was furnished by Lederle Laboratories.

Robert Pittelkow, MD, and Maurice Greenberg, MD, referred this patient, and Thomas Russell, MD, reviewed the manuscript.

Nonproprietary Name and Trademark of Drug

Vincristine sulfate—*Oncovin*.

References

1. Block JB, Edgcomb J, Eisen A, et al: Mycosis fungoides: Natural history and aspects of its relationship to other malignant lymphomas. *Am J Med* 34:228-235, 1963.

2. Cyr DP, Geokas MC, Worsley GH: Mycosis fungoides: Hematologic findings and terminal course. *Arch Dermatol* 94:558-573, 1966.

3. Epstein EH, Levin DL, Croft JD, et al: Mycosis fungoides: Survival, prognostic features, response to therapy, and autopsy findings. *Medicine* 15:61-72, 1972.

4. Fuks ZY, Bagshaw MA, Farber EM: Prognostic signs and the management of the mycosis fungoides. *Cancer* 32:1385-1395, 1973.

5. Levi JA, Wiernik PH: Management of mycosis fungoides: Current status and future prospects. *Medicine* 54:73-88, 1975.

6. Levitt M, Marsh JC, DeConti RC, et al: Combination sequential chemotherapy in advanced reticulum cell sarcoma. *Cancer* 29:630-635, 1972.

7. Berd D, Cornog J, DeConti RC, et al: Long-term remission in diffuse histiocytic lymphoma. *Cancer* 35:1050-1054, 1975.

8. Sweet D, Golomb H, Desser R, et al: Chemotherapy of advanced histiocytic lymphoma. *Lancet* 1:1136, 1975.

9. Sweet DL, Golomb HM, Desser RK, et al: Treatment of advanced histiocytic lymphoma with COMLA chemotherapy, abstracted. *Proc Am Assoc Cancer Res* 17:10, 1976.

10. Fromer JL, Johnston DO, Salzman FA, et al: Management of lymphoma cutis with low megavolt electron beam therapy: Nine year follow-up in 200 cases. *South Med J* 54:769-776, 1961.

11. Grolman JH Jr, Bierman SM, Ottoman RE, et al: Total skin electron-beam therapy of lymphoma cutis and generalized psoriasis: Clinical experiences and adverse reactions. *Radiology* 37:908-915 1966.

12. Van Scott EJ, Kalmanson JD: Complete remissions of mycosis fungoides lymphoma induced by topical nitrogen mustard (HN_2). *Cancer* 32:18-30, 1973.

13. Winkelmann RK, Linman JW: Erythroderma with atypical lymphocytes (Sézary syndrome). *Am J Med* 55:192-198, 1973.

14. Van Scott EJ, Grekin DA, Kalmanson JD, et al: Frequent low doses of intravenous mechlorethamine for late stage mycosis fungoides lymphoma. *Cancer* 36:1613-1618, 1975.

15. Haynes HA, Van Scott EJ: Therapy of mycosis fungoides. *Prog Derm* 3:1-5, 1968.

16. McDonald CJ, Calabresi P: Azaribine for mycosis fungoides. *Arch Dermatol* 103:158-167, 1971.

17. Spigel SC, Coltman CA: Therapy of mycosis fungoides with bleomycin. *Cancer* 32:767-770, 1973.

18. Levi JA, Weirnik PH: Adriamycin therapy in advanced mycosis fungoides. *Proc Am Assoc Cancer Res and Am Soc Clin Onco*, abstracted. 17:251, 1976.

19. Long JC, Mihm MC: Mycosis fungoides with extracutaneous dissemination: A distinct clinicopathologic entity. *Cancer* 34:1745-1755, 1974.

Tinea Faciei

Douglas J. Pravda, DO, Michael M. Pugliese, MD

• A 62-year-old man had a long-standing fungal infection of the face. The eruption had been treated as a photosensitivity disorder for 22 years. A literature review revealed only 35 reported cases classified as tinea faciei, most of which also were misdiagnosed originally. Pertinent clinical findings include facila erythema, pruritus, and scaling patches with arcuate or annular borders. The most common organisms isolated were *Trichophyton rubrum or T mentagrophytes.*

To our knowledge, this unique case represents the longest duration of Tinea faciei.

(*Arch Dermatol* 114:250-252, 1978)

Tinea faciei is a dermatophyte infection of the face. Uncommonly reported in this anatomic location, it has the ability to masquerade as a number of other dermatoses. In the literature and texts of dermatology and mycology, tinea faciei generally is not considered to be a unique entity, but is included incidentally under headings of tinea corporis, tinea capitis, or tinea barbae. Because superficial fungal infections of the face have not been emphasized, there is a low index of suspicion, and often an incorrect diagnosis is made.

In 1960, Shanon and Raubitschek[1] reported the cases of four patients with tinea of the face that clinically simulated discoid lupus erythematosus. Gilgor and co-workers[2] reported 14 cases of "tinea faciale" in 1971. Over half of the conditions of their patients were misdiagnosed originally, with most of them described as sunlight-related disorders. During the same year, Shapiro and Cohen[3] reported four additional cases that mimicked other diseases. Thirteen more individual case reports have been found in the literature, and most of these also originally were misdiagnosed.[4-16]

In all of the previously reported cases, the recurrence of disease varied from several months to 11 years before the correct diagnosis was made. The present case, with symptoms and mismanagement for 22 years, appears to be the longest yet recorded in the literature.

REPORT OF A CASE

A 62-year-old man was first seen in the dermatology clinic at the Staten Island (NY) Public Health Service Hospital in August 1974 because of a persistent facial eruption of 22 years' duration. The rash was usually asymptomatic, but was associated occasionally with a slight burning sensation. Although the eruption always was present, it worsened during the summer months.

The patient was first seen by a dermatologist for this problem in 1952. A biopsy specimen was obtained and was interpreted as a sunlight-induced reaction. Treatment with topical steroids and sunscreens was of no benefit. He was seen subsequently by a number of physicians, who concurred with the original diagnosis, and the eruption was treated in a similar fashion. There had been no other dermatologic complaints, and his medical history, other than seasonal hay-fever symptoms, was noncontributory.

On examination the patient displayed a facial eruption of erythematous macules, papules, and plaques, a few of which had arcuate borders (Fig 1). Atrophy was not noted, but telangectasia and minimal scaling were present. All areas of the face and upper neck were involved (Fig 2). Examination of the skin, mucosa, hair, and nails revealed only dystrophy of both great toe nails. Results of a general physical examination were normal. Routine laboratory test results were all negative or within normal limits. In addition, antinuclear antibody and anti-DNA antibody tests were negative, and IgE level and serum immunoelectrophoresis results were within the normal range.

Intradermal skin testing was performed with trichophytin, candidin, mumps vaccine, purified protein derivative (PPD), and streptokinase-streptodornase. At 48 hours, only the mumps test was positive. Interestingly, the trichophytin test resulted in an immediate 40-mm wheal and flare, but the skin showed no response in 48 hours.

A skin biopsy specimen of a facial lesion demonstrated a mild dermal dermatitis with hematoxylin-eosin. Fungal hyphae were demonstrated with PAS. Scrapings from both the facial lesions and the toe nails were positive; cultures from both areas subsequently grew *Trichophyton rubrum.*

The eruption was treated orally with micronized griseofulvin, 500 mg twice daily. Within four weeks, the facial lesions resolved, and the medicine was discontinued. No recurrence has been noted during the subsequent nine months.

COMMENT

With regard to accuracy of clinical diagnosis, our case demonstrates the

Accepted for publication March 8, 1977.

From the Department of Dermatology, US Public Health Service Hospital, Staten Island, NY.

Reprint requests to Department of Dermatology, US Public Health Service Hospital, Staten Island, NY 10304 (Dr Pravda).

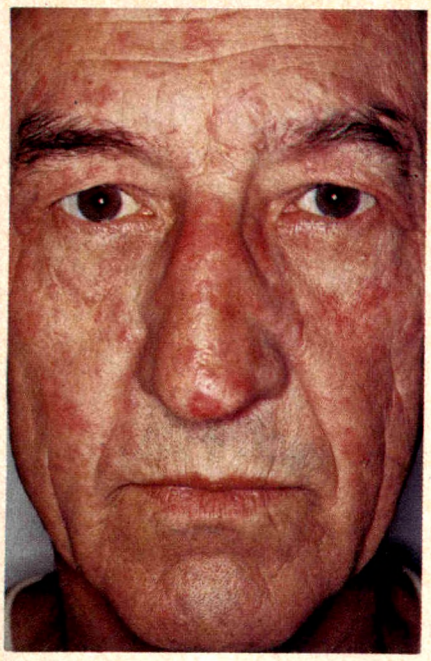

Fig 1.—Diffuse facial eruption consisting or erythematous macules, papules, and plaques. Note minimal amount of scale.

Fig 2.—Prominent annular lesion involving neck.

Table 1.—Initial Clinical Impression of 36 Cases of Tinea Faciei

Original Diagnosis	No. of Patients
Tinea	11
Photosensitive disorders	
Lupus erythematosus (DLE and SLE)	13
Polymorphous light eruption	4
Dermatomyositis	2
"Xeroderma pigmentosum incipiens"	1
Total	**20**
Miscellaneous	
Pyoderma	2
Contact dermatitis	3
Total	**5**

Table 2.—Organisms Isolated From 34 Patients With Tinea Faciei

Organism	No. of Patients
Trichophyton species	
T rubrum	13
T mentagrophytes	10
T tonsurans	3
T verrucosum	1
Total	**27**
Microsporum species	
M canis	2
M gypseum	1
Total	**3**
Miscellaneous	
Contaminant (KOH positive)	2
No growth (KOH positive)	2
Total	**4**

difficulty in the recognition of tinea faciei. Of the total number of cases reviewed (including the present case report), 25 of 36 (69%) at first were diagnosed incorrectly (Table 1). Of these 25 patients, 20 (80%) were believed to have had a photosensitivity disorder. Since the total number of patients is small, it is difficult to estimate the frequency of the most helpful clinical findings. However, of those mentioned, erythema, pruritus, and scaling were among the most common. The combination of raised lesions with annular or arcuate borders is a particularly helpful clue. Sensitivity to sunlight also was mentioned in about one third of the cases.

Superficial fungal infections histologically may appear as a dermal dermatitis, and clinically can resemble such diseases as lupus erythematosus,[1-6] dermatomyositis,[15] acne rosacea,[7] contact dermatitis,[3] lupus vulgaris,[17] or polymorphous light eruption.[2,16] These facts, along with a history of photoaggravation and, at times, the concomitant presence of solar-induced skin damage, account for the common error in diagnosis. Since the treatment of these disorders often involves medications with potentially hazardous side effects, tinea faciei must be included in the differential diagnosis.

A variety of organisms have been isolated from patients with this disease (Table 2). Of those pathogens that have been proved by culture, 27 of 31 (87%) have been of the *Trichophyton* species, with *T rubrum* and *T mentagrophytes* being the most common. Of the few cases in the literature where cultures were reported as negative, the initial scrapings revealed fungal hyphae. Therefore, either potassium hydroxide preparations or fungal culture should be positive in all cases.

In the immunologically competent host, delayed hypersensitivity or cell-mediated immunity follows an initial encounter with a pathogenic fungus, and is the mechanism responsible for the development of resistance. Our patient's skin test reactivity to trichophytin corresponds to that of other patients with chronic superficial fungal infections, ie, an immediate wheal and flare but a negative 48-hour delayed reaction. The positive immediate skin test, which indicates the presence of humoral or serum antibody to trichophytin, correlates strongly with persistent infection. It is this immediate response, in conjunction with a negative delayed reaction, that seems to be associated with

chronic fungal susceptibility.[18]

The incidence of chronic fungal infections has been reported to be higher in atopic individuals,[19] who also can display an impaired immunity to multiple antigens.[19-21] Our patient, who was known to be atopic, demonstrated this pattern by his lack of reaction to candidin, PPD, and streptokinase, as well as to trichophytin. He falls into the group of approximately 80% of those chronically infected patients whose immune systems respond inappropriately to dermatophyte antigens. Further study may clarify the status of the remaining 20% who, by present clinical and laboratory criteria, apparently have normal immune reactivity yet suffer from chronic fungal involvement.[22]

In conclusion, tinea faciei represents an unusual fungal infection that often is not considered by clinicians. The ease of diagnosis and the response to treatment warrants that it be included in the differential diagnosis of sun-sensitive, chronic facial eruptions. This patient also demonstrated the impaired immunologic reactivity that has been described in individuals with chronic dermatophyte infections.

The cost of the color reproduction was paid for by Westwood Pharmaceuticals Inc.

James P. Fields, MD, provided the histopathological diagnosis, gave advice, and assisted in the preparation of this communication.

References

1. Shanon J, Raubitschek F: Tinea faciei simulating chronic discoid lupus erythematosus. *Arch Dermatol* 82:268-271, 1960.
2. Gilgor RS, Tindell JP, Elson M: Lupus-erythematosus-like tinea of the face (tinea facile). *JAMA* 215:2091-2094, 1971.
3. Shapiro L, Cohen HJ: Tinea faciei simulating other dermatoses. *JAMA* 215:2106-2107, 1971.
4. Drouhet E, Robin J: Mycose cutanee simulant un lupis erythemateux. *Bull Soc Fr Dermatol Syphiligr* 76:502-504, 1969.
5. Sirkis L, Tosi MJ: Mycose cutanee dela face simulant un lupus erythemateux chronique. *Bull Soc Fr Dermatol Syphiligr* 73:490-491, 1966.
6. De Graciansky M, Grupper C, Sirkis L: Dermatomycose a *Trichophyton rubrum* simulant un lupus erythemateux tumidus. *Bull Soc Fr Dermatol Syphiligr* 72:809-811, 1965.
7. Duperrat B, Paissant A, Cheikh-Cherif JL, et al: Trichophytie de menton simulant une acne rosacee. *Bull Soc Fr Dermatol Syphiligr* 75:581-582, 1968.
8. Blank H, Taplin D, Zaias N: Cutaneous *Trichophyton* mentagrophytes infections in Vietnam. *Arch Dermatol* 99:135-144, 1969.
9. Tinea of the face, SOCIETY TRANSACTIONS. *Arch Dermatol* 91:184-185, 1965.
10. Tinea facialis, SOCIETY TRANSACTIONS. *Arch Dermatol* 99:504-505, 1969.
11. McEachin BL: Tinea faciale and lupus erythematosus. *JAMA* 21:828, 1971.
12. Ostler BH, Okumote M, Halde C: Dermatophytosis affecting the periorbital region. *Am J Ophth* 72:934-938, 1971.
13. Jacobs AH, Jacobs PH, Moore N: Tinea faciei due to *Microsporum canis* in an 8-day-old infant. *JAMA* 219:1476, 1972.
14. Auger P, Ouimet G, Ricard P: Tinea faciale. *Can Med Assoc J* 106:1102-1104, 1972.
15. Rist TE, Abele DC, Caves JM: Tinea faciale: An often misdiagnosed clinical entity. *South Med J* 67:331-334, 1974.
16. Brody HJ, Castrow FH: Photolocalized tinea facialis. *Cutis* 17:913-915, 1976.
17. Blank H, Smith JG: Widespread *Trichophyton rubrum* granulomas treated with griseofulvin. *Arch Dermatol* 81:779-789, 1960.
18. Jones HE, Reinhardt JH, Rinaldi MG: Model dermatophytosis in naturally infected subjects. *Arch Dermatol* 110:369-374, 1974.
19. Jones HE, Reinhardt JH, Rinaldi MG: A clinical, mycological and immunological survey for dermatophytosis. *Arch Dermatol* 108:61-65, 1973.
20. Lobitz WC, Honeyman JF, Winkler NW: Suppressed cell-mediated immunity in two adults with atopic dermatosis. *Br J Dermatol* 86:317-328, 1972.
21. Jones HE, Lewis CW, McMarlin SL: Allergic contact sensitivity in atopic dermatosis. *Arch Dermatol* 107:217-223, 1973.
22. Jones JE, Reinhardt JH, Rinaldi MG: Immunologic susceptibility to chronic dermatophytosis. *Arch Dermatol* 110:213-220, 1974.

New Requirement for Authors

Congress recently passed *The Copyright Revision Act of 1976*, effective Jan 1, 1978, which affects the American Medical Association's procedure for reviewing manuscripts submitted for publication.

In view of this law, all transmittal letters accompanying manuscripts submitted for publication should contain the following language: "In consideration of the AMA taking action in reviewing and editing my submission, the author(s) undersigned hereby transfers, assigns, or otherwise conveys all copyright ownership to the AMA in the event that such work is published by the AMA."

Erythema Chronicum Migrans in America

Maj Douglas N. Naversen, MC, USAF, Larry W. Gardner, MD

• Erythema chronicum migrans (ECM) developed in a man after a tick bite; the tick was probably *Ixodes pacificus*. Despite extensive laboratory evaluation, including bacterial culture of involved skin, viral and rickettsial titers, biopsy and special stains, animal inoculation, and electron microscopy, the causal agent could not be identified. Although probably unrelated, an elevated measles titer with a twofold drop on serial determinations was of interest. To our knowledge, this report documents the first reported case of ECM acquired in this country in which the tick that caused the disease has been recovered.

***(Arch Dermatol* 114:253-254, 1978)**

Erythema chronicum migrans (ECM) is a tick-borne disease reported most commonly in northern Europe. Cases have been described in Americans who lived in Europe,[1] and in an American traveler who was bitten overseas with manifestation of the characteristic eruption after the person returned to the United States.[2] However, documented cases acquired in this country are distinctly rare.[3-7] This report describes a typical case of ECM with a discussion of origin, treatment, manifestations, complications, and differential diagnosis.

REPORT OF A CASE

A 32-year-old man was bitten on the thigh while he was hiking in Sonoma County, Calif. The next morning the tick was discovered, removed, and saved. One week later the patient noted a slightly raised, erythematous ring around the central punctum with mild pruritus. On initial examination four weeks after the bite, the patient presented the tick to the physician who examined him. An 8 × 12-cm, erythematous, macular, nonscaling, centrifugally spreading ring with a trailing bluish cast was noted. At eight weeks the ring of erythema had expanded to 35 × 35 cm; however, because its intensity had faded, the ring was difficult to visualize at times. The patient was in good health throughout the course of the disease, and results of general physical examination were normal. The patient then received 2 gm of tetracycline hydrochloride daily, and he reported a clearing of the erythematous ring three days later.

Accepted for publication Feb 18, 1977.

From the Department of Dermatology, University of California School of Medicine, San Francisco (Dr Naversen) and the Department of Dermatology, Kaiser-Permanente Medical Center, San Francisco (Dr Gardner). Dr Naversen is now Chief of Dermatology, USAF Hospital, Elmendorf Air Base, Alaska.

Reprint requests to Department of Dermatology, University of California School of Medicine, San Francisco, CA 94143 (Dr Naversen).

Laboratory Data

Evaluation five weeks after the tick bite included the following tests and studies that either showed normal values or were negative: complete blood cell count with a differential cell count; VDRL; FTA-ABS; febrile agglutinins, < 1:8 (*Brucella*, Paratyphoid A, Paratyphoid B, *Proteus* OX-K, *Proteus* OX-19, *Proteus* OX-2, and Typhoid H); and aerobic and anaerobic bacterial skin cultures of both central punctum and ring of erythema. Potassium hydroxide mounts and fungal cultures were not done because of the absence of scale on the clinical lesion. Skin biopsy specimens from both sites showed a normal epidermis with a perivascular, lymphocytic infiltrate that involved the dermis and subcutaneous fat. Although the bite site showed a more dense infiltrate than the ring, neither site showed a true vasculitis. Serial sections of the bite site did not show retained tick parts. Silver and Giemsa's stains from both sites were negative for spirochetes and rickettsia.

Complement fixation titers of serum performed five weeks after the bite by the California State Department of Health, Berkeley, were unremarkable except for an elevated, short-term measles titer of 1:512. Serological studies also included a short-term titer of 1:8 for each of the following: rubella, Q fever, psittacosis, lymphogranuloma venereum, the Rocky Mountain spotted fever group, and three encephalitis viruses (St Louis, Venezuelan, and western equine). Serial determinations of measles titers fell to 1:256 three and six months later, and to 1:128 twelve months later. Other serological studies for measles included elevated fluorescent antibody titer of 1:256, and hemagglutination inhibition titer of 1:2,048. To evaluate the question of recent or old measles infection, pooled sera from the first three specimens (five weeks, three months, and six months) were tested by the sucrose density gradient method to separate IgG and IgM fractions. Complement fixation and hemagglutination inhibition antibodies were present in the IgG fraction but not in the IgM fraction.

Further studies performed by the state laboratory by direct examination of tissue that was taken from the expanding ring of erythema were negative for virus or other organisms by electron microscopy and negative for measles virus by direct fluorescence antibody stain. There was no growth of virus or rickettsia after injection of the patient's whole clotted blood into suckling mice five weeks after the bite. The tick was identified as belonging to the genus *Ixodes*, most probably of the species *pacificus*, by a health department entomologist.

COMMENT

Erythema chronicum migrans is usually transmitted by the bite of the European wood tick *I ricinus*. Mosquito bites[8] and thorn pricks[9] have also caused typical cases. Although allergic and toxic factors have been considered, suggestion of an infectious mechanism exists. Binder et al[10] reported interhuman transmission by serial passages of involved skin that are placed into skin pouches of unaffected volunteers. In addition, Sonck[11] reproduced the disease by inoculating his own arm with skin taken from the erythematous ring of an affected patient.

Infectious agents that were considered included spirochetes, rickettsia, fungus, and virus. The prompt clinical clearing in two to three days after penicillin therapy led Hollström[12] to believe that spirochetes were causal. Lennhoff[13] reported that he saw spirochetes in ECM with the use of a mercury stain and "thick-drop" technique, but he also saw them in a wide range of skin diseases not caused by spirochetes. Degos et al[14] implicated rickettsia, with a microagglutination technique in which he found elevated titers in six of seven patients to various species, including *Rickettsia prowazekii*, *R mooseri*, and *R conorii*. The prompt response to broad-spec-

trum antibiotics such as tetracycline further implicated rickettsia. The general ineffectiveness of penicillin against rickettsia in face of many rapid cures of ECM with penicillin suggested that rickettsia was not the unique causal agent. Fungal origin was inferred by cure of six patients with griseofulvin in a total dose of 25 to 100 tablets.[15] However, Sonck[16] noted lack of response in two patients treated with griseofulvin who were then cured with ampicillin. Finally, viral origin in combination with allergic sensitivity was suggested by Janson.[17] However, little data exist to implicate a specific virus, and there is a possibility of coincidental viral infection after tick bites, which cause ECM. For example, Putkonen et al[18] studied 31 typical cases of ECM and found no involvement of the CNS. They speculated that the meningeal symptoms in other cases of ECM may have been due to coincidental infection with the tick-borne encephalitis virus. Later, Weber[19] studied a patient with CNS involvement and noted that antibiotics rapidly cleared both eruption and meningeal symptoms, and he concluded that the disease was bacterial in origin.

Our patient showed typical clinical features of ECM. Rapid response to broad-spectrum antibiotics was noted, but spontaneous resolution could not be ruled out, because his eruption had largely faded by the time therapy was started. The duration of ECM may normally range from several weeks to 1½ years without therapy.[20] The elevated measles titer with a twofold serial fall suggested recent infection in this patient who reportedly had childhood measles. However, studies on pooled sera showed that complement fixation and hemagglutination inhibition antibodies were lacking on the IgM fraction and were present on the IgG fraction. This suggested an old measles infection; the IgM antibody should rise first after infection, whereas the IgG antibody should rise later in the course of the disease as the IgM fraction disappears.[21] Serial determinations of measles titers in other patients with ECM would be helpful. Manifestations that have been reported but not seen in our patient include a persistent granulomatous papule with retained tick parts, multiple arcuate lesions that may migrate centrifugally from the bite sites to span the length of the body, local burning, hypesthesia, regional lymphadenopathy, lymphangitis, malaise, vomiting, and transient paresis in the affected limb. Atypical febrile and short-term hemorrhagic forms have been observed.[22] In addition, monoarticular or oligoarticular arthritis associated with an eruption that resembled ECM has been noted in a cluster of cases in Connecticut and New England.[23,24] Finally, the most severe complication is meningitis which appears in a small percentage of patients, and characteristically runs a mild course.

Differential diagnosis includes other figurate erythemas such as erythema annulare centrifugum and erythema gyratum repens. Erythema multiforme, erysipelas, annular secondary syphilis and tinea circinata should also be considered. In addition, associations exist with lymphadenosis benigna cutis[8] and acrodermatitis chronica atrophicans.[25] Both ECM and lymphadenosis benigna cutis reportedly may be caused by insect bites, and both can be transmitted by transplanting biopsy specimens of involved skin into healthy skin.[8] Furthermore, biopsy specimens from skin with lymphadenosis benigna cutis, which are transplanted into healthy skin, may develop an "ECM-like" eruption around the implantation sites.[8] As for ECM and acrodermatitis chronica atrophicans, the tick *I ricinus* has been implicated as the vector, which suggests that they may be different stages of a similar disease.[25]

Erythema chronicum migrans is a disease that has been known in Europe for more than half a century but has been observed in America in only the last decade. Reasons for the appearance in this country are not known, but the recent flurry of case reports presages a continued rise in the incidence of this enigmatic disease. It is hoped that this report will enable rapid recognition of ECM and stimulate further study on the origin of this disease, as well as identification of responsible vectors.

Studies were performed at the Department of Health Lab, Berkeley, Calif, and directed by Richard W. Emmons, MD, PhD, public health medical officer. Edwin H. Lennette, MD, PhD, assisted in virologic studies; Lyndon Oshiro, PhD, electron microscopic studies; Natalie Cremer, PhD, pooled sera study; and Robert F. Lane, PhD, entomologic studies.

References

1. Flanagan BP: Erythema chronicum migrans Afzelius in Americans. *Arch Dermatol* 86:410-411, 1962.
2. Wagner L, Susens G, Heiss L, et al: Erythema chronicum migrans: A possibly infectious disease imported from northern Europe. *West J Med* 124:503-505, 1976.
3. Scrimenti RJ: Erythema chronicum migrans. *Arch Dermatol* 102:104-105, 1970.
4. Smith LR, Burgdorf W, Katz HI: Erythema chronicum migrans. *Cutis* 17:962-964, 1976.
5. Mast WE, Burrows WM: Erythema chronicum migrans in the United States. *JAMA* 236:859-860, 1976.
6. Mast WE, Burrows WM: Erythema chronicum migrans and "lyme arthritis." *JAMA* 236:2392, 1976.
7. Hazard GW, Leland K, Mathewson HO: Erythema chronicum migrans and "lyme arthritis." *JAMA* 236:2392, 1976.
8. Hard S: Erythema chronicum migrans (Afzelii) associated with mosquito bite. *Acta Derm Venereol* 46:473-476, 1966.
9. Bessière L: Erythema chronicum migrans par piqûre d'épine. *Bull Soc Fr Dermatol Syphiligr* 73:455-456, 1966.
10. Binder E, Doepfmer R, Horstein O: Experimentelle übertragung des erythema chronicum migrans von Mensch zu Mensch. *Hautarzt* 6:494-496, 1955. Abstracted, *Excerpta Med* 10:453, 1956.
11. Sonck CE: Erythema chronicum migrans with multiple lesions. *Acta Derm Venereol* 45:34-36, 1965.
12. Hollström E: Penicillin treatment of erythema chronicum migrans Afzelius. *Acta Derm Venereol* 38:285-288, 1958.
13. Lennhoff C: Spirochetes in aetiologically obscure diseases. *Acta Derm Venereol* 28:295-324, 1948.
14. Degos R, Touraine R, Arouette J: L'erythema chronicum migrans. *Ann Dermatol Syphiligr* 89:247-260, 1962. Abstracted, *Excerpta Med* 17:414, 1963.
15. Strocka G: Erythema chronicum migrans ein beitrag zur griseofulvintherapie. *Hautarzt* 20:233, 1969. Abstracted, *Excerpta Med* 24:243, 1970.
16. Sonck CE: Griseofulvin: Unwirksam bei erythema chronicum migrans. *Hautarzt* 21:514-516, 1970. Abstracted, *Excerpta Med* 26:149, 1972.
17. Janson P: Häufigkeit, klinisches bild, therapie und aetiologie des erythema chronicum migrans. *Med Klin* 48:1139, 1953. Abstracted, *Excerpta Med* 8:222, 1954.
18. Putkonen T, Mustakallio KK, Salminen A: Erythema chronicum migrans with meningitis: A rare coincidence of two tick-borne diseases? *Dermatologica* 125:184-188, 1962.
19. Weber K: Erythema chronicum migrans meningitis—a bacterial infectious disease? *Munch Med Wochenschr* 116(pt 45):1993-1998, 1974.
20. Leczinsky CG: Case of erythema chronicum migrans with meningitis. *Acta Derm Venereol* 31:464-467, 1951
21. Stewart FS (ed): Antigens and Antibodies, in *Bacteriology and Immunology for Students of Medicine*. Baltimore, Williams & Wilkins Co, 1968, pp 106-107.
22. Brachtel R, Kortin GW: Zur febrilen und hämorrhagischen atypie des erythema chronicum migrans. *Med Welt* 24 (pt 3):81-83, 1973.
23. Steere AC, Malawista SE, Snydman DR, et al: Lyme arthritis: An epidemic of oligoarticular arthritis in children and adults in three Connecticut communities. *Arthritis Rheum* 20:7-17, 1977.
24. Steere AC, Malawista SE, Hardin JA, et al: Erythema chronicum migrans and Lyme arthritis: The enlarging clinical spectrum. *Ann Intern Med* 86:685-698, 1977.
25. Danda J: Die Weltfrequenz der akrodermatitis chronica atrophicans. *Hautarzt* 14:337-340, 1963. Abstracted, *Excerpta Med* 18:176, 1964.

Triad of Lichen Planus, Myasthenia Gravis, and Thymoma

Iris K. Aronson, MD; Keyoumars Soltani, MD; Kang-Inn Paik, MD; Denise Rubenstein, MD; Allan L. Lorincz, MD

• Myasthenia gravis in a woman was followed by the development of severe erosive lichen planus and thymoma. Lichen planus is not ordinarily associated with other cutaneous or systemic disorders. The reported immunologic findings in some patients with lichen planus and especially the occasional association of lichen planus with certain disorders linked with immunologic disturbances suggest an autoimmune pathogenesis for this disorder.

(*Arch Dermatol* 114:255-258, 1978)

Lichen planus is not generally associated with other dermatologic or systemic disorders.[1,2] However, certain disorders that have been linked with immunologic disturbances such as bullous pemphigoid, alopecia areata, vitiligo, chronic ulcerative colitis, and hypogammaglobulinemia have been reported in association with lichen planus.[1-3] Tan and Miller, furthermore, have reported one case of lichen planus associated with myasthenia gravis and another case associated with thymoma.[1,3,4]

To our knowledge, this present report of the triad of lichen planus, myasthenia gravis, and thymoma is the first in the American literature.

MATERIALS AND METHODS

Four-millimeter punch biopsy specimens were obtained from cutaneous and oral lesions and bisected. Half of each specimen was fixed in 10% formaldehyde in saline solution, embedded in paraffin, cut into 5-μ-thick sections, and stained with hematoxylin-eosin for light microscopic studies. The other half was frozen in liquid nitrogen and sectioned in a cryostat at −20 C. Four-μ-thick sections were placed on glass slides and stained with commercially prepared fluorescein-conjugated goat γ-globulin antihuman IgG, IgM, IgA, and C3, using a final total protein concentration of approximately 340 μg/ml and a protein-bound fluorescein isothiocyanate concentration of 4 μg/ml. These slides were examined with a fluorescence microscope with a 200 W mercury arc lamp, exciter filter 702 and barrier filter OG-1, and photographed. Serial dilutions of the patient's serum prepared with phosphate-buffered saline containing 4% bovine serum albumin were used on 5-μ-thick frozen sections of various monkey tissues, using standard indirect immunofluorescence procedures.[5] The tissues included stomach mucosa, striated and smooth muscles, pancreas, ovary, adrenal, and thyroid.

REPORT OF A CASE

A 54-year-old woman was referred to the Dermatology Clinic of the University of Chicago in January 1975 with painful erosive lesions in her mouth and vagina, and pruritic violaceous plaques on the extremities. In May 1974 she developed bilateral ptosis, weakness of mastication, and drooping of the mouth. A diagnosis of myasthenia gravis was made in June 1974 and confirmed by a Tensilon test. She was given oral pyridostigmine bromide but had no amelioration of symptoms. Orally administered prednisone, 30 mg/day, produced a rapid total remission of myasthenic symptoms. Prednisone was gradually tapered and discontinued in May 1975 without recurrence of symptoms.

In October 1974 the patient developed painful erosive lesions in the mouth and vagina, and violaceous plaques on the extremities. The mouth was severely involved with white reticulated and erythematous lesions on the buccal mucosa,

Accepted for publication Feb 16, 1977.

From the Section of Dermatology, Department of Medicine, University of Chicago.

Reprint requests to 950 E 59th St, Box 409, Chicago, IL 60637 (Dr Soltani).

and extensive superficial erosions on the tongue, gingiva, and lips (Fig 1 and 2). Gynecologic examination showed atrophic vulvitis, vaginitis, and cervicitis with some superficial labial erosions. Skin changes included pruritic, hypertrophic, violaceous plaques and papules on the extremities and back. Fingernails were grooved longitudinally and the toenails were thickened and discolored. *Candida* or dermatophytes failed to grow from cultures of the nails. The patient also had open-angle glaucoma in the left eye, for which epinephrine and pilocarpine eye drops were used. A cataract had been extracted from the right eye in 1972.

Except for anterior and posterior uveitis of the left eye, the remainder of the physical examination, including chest, abdomen, bones, joints, and neuromuscular system, did not disclose any abnormal findings. Psychiatric examination showed a mild depression for which amitriptyline hydrochloride (Elavil) was prescribed.

Histologic examination of the oral and cutaneous lesions confirmed the clinical diagnosis of lichen planus. Hematoxylin-eosin preparations from the skin lesions demonstrated hyperkeratosis, focal hypergranulosis, incontinence of melanin, and a band of lymphohistiocytic infiltrate in the papillary dermis, which tended to disrupt the basal layer and obliterate the dermal-epidermal junction but without separation. Direct immunofluorescent studies of the frozen sections of similar biopsy specimens demonstrated large clusters of globular deposits of IgM in the dermal papillae. Deposits of IgG, IgA, or C3 were not detected. Slides were not stained with antifibrin antibodies. There was no immunoglobulin or C3 deposition at the dermal-epidermal junction. Indirect immunofluorescence studies did not disclose circulating pemphigus or pemphigoid antibodies.

The cutaneous lesions and especially the severe erosive stomatitis were recalcitrant to various therapeutic modalities, including topical anesthetics, topical steroids, and heparin sodium mouth rinses. Eating difficulties contributed to a 10-kg weight loss in six months. Episodic oral candidiasis, however, responded to local nystatin treatment.

In May 1975 an increasingly severe, nonproductive cough developed. Chest roentgenographic examination at that time demonstrated no abnormality. In September 1975 the patient developed bilateral rhonchi and a repeated chest roentgenographic examination showed an anterior mediastinal mass that was further defined by tomography. Surgical exploration of the anterior mediastinal area showed a 5- × 6-cm lobulated tumor in the thymus, which grossly appeared to be adherent to the innominate vein, left visceral pleura, and the pericardium (Fig 3). Extensive histologic examination, however, did not demonstrate any microscopic evidence of invasion into the surrounding tissues and the tumor was diagnosed as a benign thymoma, mixed type, without germinal centers (Fig 4).

Various examinations failed to demonstrate evidence of metastasis. Liver and spleen scans, gallium scans, and thyroid scans were all normal. The following studies were negative or normal: urinalysis, hemogram, automated chemical analyses, creatinine, creatine phosphokinase, serum magnesium, iron and total iron-binding capacity, coagulation profile, VDRL, C-reactive protein, hepatitis B surface antigen, sensitized sheep cell agglutination test, latex fixation test, antinuclear immunofluorescence and DNA antibodies, lupus erythematosus preparation, serum protein electrophoresis, free thyroxine index and thyroxine, and serum amylase.

Survey for multiple tissue-specific autoantibodies showed antiparietal cell-circulating antibodies to a titer of 1:640 dilution and low titers of microsomal and thyroglobulin antibodies. Antibodies against striated and smooth muscles and ovarian, pancreatic, and adrenal tissues were not detectable. Intradermal skin test with streptokinase-streptodornase produced 12 mm of delayed erythema without induration. Similar skin tests with purified protein derivative, candidin and coccidioidin were negative. A transient elevation of SGOT and SGPT was attributed to amitriptylin. Erythrocyte sedimentation rate remained abnormally high, levels ranging between 54 and 82 mm/hr, using the Westergren method. Serum immunoglobulin levels were normal, except for slightly low IgM of 50 mg/100 ml (normal level, 90 to 170 mg/ml). Serum hemolytic and immune adherence complement activities were normal. The T cell competence, as measured by E-rosette formation and phytohemagglutinin stimulation was normal. However, specific stimulation with *Candida* antigen and purified protein derivative was not tested. After thymectomy the patient's immunologic status was reevaluated and no significant changes in humoral and cell-mediated immunity measurements were noted.

A few weeks after thymectomy there was some improvement of the mucocutaneous lesions with partial reepithelialization of the oral erosions and a return of taste sensation. The improvement, however, did not last more than several weeks and the mucocutaneous lesions gradually became more extensive and have persisted to the present time.

COMMENT

The essential role of the thymus in immunosurveillance, neuromuscular transmission, transformation of stem cells into immunocompetent lymphocytes, and the pathogenesis of the immunologically mediated disorders has been documented in recent years.[6-11]

Thymomas are classified into three histologic types: predominantly lymphocytic, predominantly epithelial, and mixed.[12] Histologic criteria are often inadequate for distinguishing benign and malignant thymomas. Thymomas are usually considered malignant if dense adhesions, fixation to or invasion into adjacent structures are noted at the time of surgery, or if there is any evidence of metastasis.[6] The relation of the morphologic types of thymic tumors to their clinical behavior and possible associated syndromes requires additional clarification. However, the presence of germinal centers in thymic tumors has been reported to indicate more prolonged and severe disease.[6,12-14] Thymomas have the highest incidence in the sixth and seventh decades of life, but they can occur at any age.[12] According to one view, thymomas appear to represent the late stage of a process in which the earlier manifestations are hyperplasia and germinal cell formation.[15] Disorders associated with thymomas include myasthenia gravis, pure RBC aplasia, leukopenia, thrombocytopenia, pancytopenia, hypogammaglobulinemia, plasma cell myeloma, granulomatous myocarditis, chronic mucocutaneous candidiasis, alopecia areata, systemic lupus erythematosus, rheumatoid arthritis, and pemphigus.[3,6,10,11,16-21]

Myasthenia gravis is characterized by muscular weakness resulting from defective transmission at the neuromuscular junction.[22,23] Circulating factors affecting neuromuscular transmission have long been proposed because of the frequent incidence of antimuscle antibodies in patients' sera, and on the basis of transient neonatal myasthenia gravis, a phenomenon occurring in 12% of babies with myasthenic mothers.[21,23,24] Recently, it has been found that patients with myasthenia gravis have anti-acetylcholine receptor immunoglobulins in their sera and thymus glands, which inhibit neuromuscular transmission.[23,25,26] The serum levels of the specific circulating antibodies do not correlate well with the clinical state of the disease.[25] High levels of cell-mediated immunity to purified acetylcholine receptors have also been demonstrated in myasthenia gravis, the levels seeming to correlate with the clinical state of the disease.[27] Similar to the present case, the patient with thymoma and lichen planus described by Tan et al[28] also had severe erosive oral lesions. One might wonder whether the severe erosive quality of the mucosal lesions is related to the altered immune function.

Although the existing evidence for an immunologic pathogenesis for lichen planus is insufficient, the following points suggest such a mechanism:

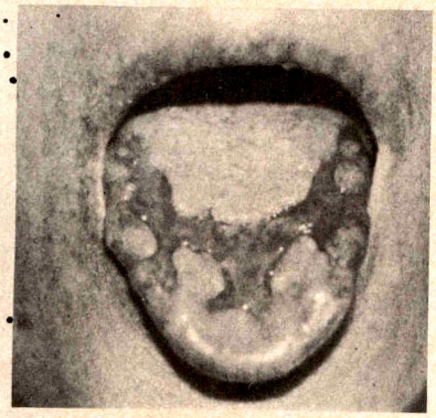

Fig 1.—Severely eroded atrophic lesions of lichen planus involving tongue.

Fig 2.—Hypertrophic plaques of lichen planus on lower leg.

Fig 3.—Gross surgical specimen. Thymic tumor (arrow).

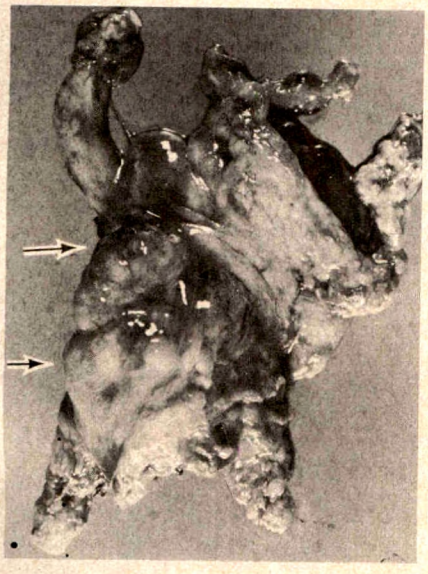

The studies by Sarkany and Garlarde support the concept that in lichen planus the primary abnormality affects basal cells.[29] In their ultrastructural studies of lichen planus, Medenica and Lorincz have found that the primary injury to epidermal basal cells appears to occur in the cell nucleus during the early phase of the mitotic cycle.[30] They speculate that antigens from this primary site may possibly evoke a cell-mediated immune reaction, noting that the nature of the infiltrate, which consists of macrophages, small and large lymphocytes, and frequent attachment sites between lymphocytes and macrophages, is similar to that reported in allergic contact dermatitis. The infiltrating cells in lichen planus lesions have been shown to be predominantly T cells. It seems that B cells play little or no part in the pathogenesis of the disease.[28] Histologic similarities between graft vs host reaction and lichen planus have been described.[31,32] Focal necrosis of the epithelial basal layer and dermal infiltration by lymphocytes are predominant features of both diseases. However, the lymphocytic infiltrate is usually sparse in early cutaneous graft vs host reactions and the clinical aspects may not be lichenoid.[32] Serum levels of IgA and IgM are reported to be low in some patients with lichen planus.[33] The importance of these immunoglobulin abnormalities is unclear. Globular deposits of immunoglobulins, especially IgM and various components of com-

Fig 4.—Histologic section of thymoma showing mixed type with both epithelial and lymphoid cells (hematoxylin-eosin, original magnification ×400).

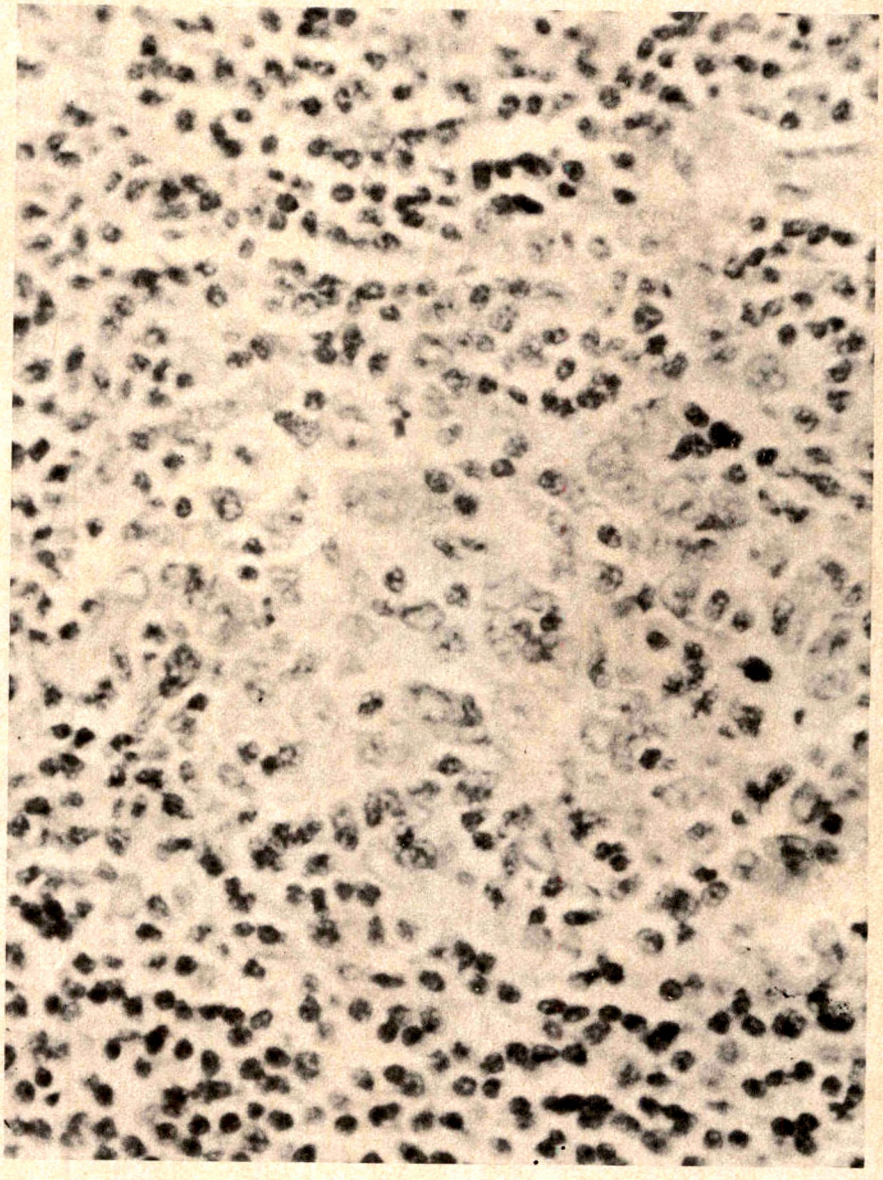

plement and fibrin in the dermal papillae of the lesions and to a lesser extent in uninvolved skin, are usually detected in lichen planus.[34,35] It is likely that these deposits are secondary to vasodilation and increased vasopermeability, and follow the degeneration of the basal cells.[34,35] The occasional association of lichen planus with certain diseases such as bullous pemphigoid, ulcerative colitis, alopecia areata, vitiligo, acquired hypogammaglobulinemia, and, as in our patient, myasthenia gravis and thymoma, although possibly fortuitous, might further suggest an autoimmune pathogenesis for this disorder.

This study was supported in part by the Louis Block Fund, University of Chicago.

References

1. Tan RSH: Ulcerative colitis, myasthenia gravis, atypical lichen planus, alopecia areata, vitiligo. *Proc R Soc Med* 67:195-196, 1974.
2. Stingl G, Holubar K: Coexistence of lichen planus and bullous pemphigoid. *Br J Dermatol* 93:313-320, 1975.
3. Tan RSH: Thymoma, acquired hypogammaglobulinemia, lichen planus, alopecia areata. *Proc R Soc Med* 67:196-197, 1974.
4. Miller TV: Myasthenia gravis, ulcerative colitis and lichen planus. *Proc R Soc Med* 64:807-808, 1971.
5. Beutner EH: Defined immunoflourescent staining: Past progress, present status and future prospects for defined conjugates. *Ann NY Acad Sci* 177:506-507, 1971.
6. Genkins G, Papatestas AE, Horowitz SH, Kornfeld P: Studies in myasthenia gravis: Early thymectomy. *Am J Med* 58:517-524, 1975.
7. Goldstein G, Schlesinger DH: Thymopoietin and myasthenia gravis: Neostigmine-responsive neuromuscular block produced in mice by synthetic peptide fragment of thymopoietin. *Lancet* 2:256-259, 1975.
8. Goldstein G: Myasthenia gravis and the thymus. *Ann Rev Med* 22:119-124, 1971.
9. Wybran J, Levin AS, Fudenberg HH, et al: Thymosine: Effects on normal human blood T-cells. *Ann NY Acad Sci* 249:300-307, 1975.
10. Gilbert EF, Harley JB, Anido V, et al: Thymoma, plasma cell myeloma, red cell aplasia and malabsorption syndrome. *Am J Med* 44:820-829, 1968.
11. Rogers BHG, Manaligod JR, Blazek WV: Thymoma associated with pancytopenia and hypogammaglobulinemia. *Am J Med* 44:154-163, 1968.
12. Salyer WR, Eggleston JC: Thymoma: A clinical and pathological study of 65 cases. *Cancer* 37:229-249, 1976.
13. Reinglass JL, Brickel ACJ: The prognostic significance of thymic germinative center proliferation in myasthenia gravis. *Neurology* 23:69-72, 1973.
14. Papatestas AE, Alpert LI, Osserman KE, et al: Studies in myasthenia gravis: Effect of early thymectomy. *Am J Med* 50:465-474, 1971.
15. Strauss AJL, Van Der Geld HR: The thymus and human diseases with autoimmune concomitants, with special reference to myasthenia gravis, in Wolstenholme GEW, Porter R (eds): *The Thymus, Experimental and Clinical Studies*. Boston, Little Brown & Co, 1966, p 416.
16. Burke JS, Medline NM, Katz A: Giant cell myocarditis and myositis associated with thymoma and myasthenia gravis. *Arch Pathol* 88:359-366, 1969.
17. Montes LF, Cebellos R, Cooper MD, et al: Chronic mucocutaneous candidiasis, myositis and thymoma: A new triad. *JAMA* 222:1619-1623, 1972.
18. Alarcon-Segovia D, Galbraith RF, Maldonado JE, et al: Systemic lupus erythematosus following thymectomy for myasthenia gravis. *Lancet* 2:662-665, 1963.
19. Larsson O: Thymoma and systemic lupus erythematosus in the same patient. *Lancet* 2:665-666, 1963.
20. Lattes R: Thymoma and other tumors of the thymus: An analysis of 107 cases. *Cancer* 15:1224-1260, 1962.
21. Beutner EH, Chorzelski TP, Hale WL, et al: Autoimmunity in concurrent myasthenia gravis and pemphigus erythematosus. *JAMA* 203:845-849, 1968.
22. Grob D: Cause of weakness in myasthenia gravis. *N Engl J Med* 294:722-723, 1976.
23. Bender AN, Ringel SP, Engel WK, et al: Myasthenia gravis: A serum factor blocking acetylcholine receptors of the human neuromuscular junction. Lancet 1:607-609, 1975.
24. Van der Geld HWR, Strauss AJL: Myasthenia gravis: Immunological relationship between striated muscle and thymus. *Lancet* 1:57-60, 1966.
25. Mittag T, Kornfeld P, Tormay A, et al: Detection of anti-acetylcholine receptor factors in serum and thymus from patients with myasthenia gravis. *N Engl J Med* 294:691-693, 1976.
26. Toyka KV, Drachman DB, Griffin DE, et al: Humoral immune mechanisms in myasthenia gravis. *N Engl J Med* 296:125-131, 1977.
27. Richman DP, Patrick J, Arnason BJW: Cellular immunity in myasthenia gravis: Response to purified acetylcholine receptor and autologous thymocytes. *N Engl J Med* 294:694-698, 1976.
28. Tan RSH, Byrum NA, Hays JP: A method of liberating living cells from the dermal infiltrate: Studies on skin reticuloses and lichen planus. *Br J Dermatol* 93:271-275, 1975.
29. Sarkany I and Garlarde PM: Ultrastructural and light microscopic aspects of lichen planus. *Trans St John's Hosp Dermatol Soc* 56:48, 1970.
30. Medenica M, Lorincz AL: Lichen planus: An ultrastructural study. *Acta Dermatovenerologica Acta Derm Venereol* 57:55-62, 1977.
31. Saurat JH, Dider-Jean L, Glauckman E, et al: A graft versus host reaction and lichen planus-like eruption in man. *Br J Dermatol* 92:589, 1975.
32. Touraine R, Revus J, Dreyfus B, et al: Graft versus host reaction and lichen planus. *Br J Dermatol* 92:589, 1975.
33. Stankler L: Deficiency of circulating IgA and IgM in adult patients with lichen planus. *Br J Dermatol* 93:25-27, 1975.
34. Baart De La Faille-Kuyper EH, Baart De La Faille H: An immunofluorescence study of lichen planus. *Br J Dermatol* 90:365-371, 1974.
35. Abell E, Presberg DGC, Mark R, et al: The diagnostic significance of immunoglobulin and fibrin deposition in lichen planus. *Br J Dermatol* 93:17-27, 1975.

Erythrokeratodermia Variabilis

A Family Study

Garry B. Gewirtzman, MD; Norman W. Winkler, MD, PhD; Richard L. Dobson, MD

• Erythrokeratodermia variabilis is a rare genodermatosis; American authors have reported only four previous cases. It had been a problem to obtain a large pedigree for clinical investigation. We studied a family with 12 involved members in five generations.

Symmetrically distributed migratory patches and scaling plaques are characteristic and were found to involute with a combination of keratolytic agents and topical steroids. Exacerbations of these patches and plaques were noted in our female patients during such high estrogen states as pregnancy or oral contraceptive usage.

(*Arch Dermatol* 114:259-261, 1978)

In 1907, DeBuy Wenniger[1] described a 15-year-old girl with erythrokeratodermia of variable configuration. The eponym, Mendes da Costa,[2] has been applied to this disorder since 1925, when this author described two additional cases in a mother and daughter, and reviewed nine previously reported cases. Although the patients of Mendes da Costa were all female, kindred analysis of the larger series of Noordhoek[3] and Schnyder and Sommacal-Schopf[4] established an autosomal dominant mode of inheritance. American authors have described only four previous cases.[5-7]

The clinical features of erythrokeratodermia variabilis (EKV) are symmetrically distributed, sharply marginated areas of erythema that undergo changes in size, shape, and distribution during a period of days. Plaques with thick, yellow-brown scale occur in most of these erythematous areas.

The lower most portion of the stratum corneum is compact, while the majority of the stratum corneum displays a loose basketweave pattern. Other histologic features are papillomatosis, hyperplasia of rete ridges, and a perivascular lymphohistiocytic infiltrate in the papillary dermis. Because inflammation and scale are prominent features, various anti-inflammatory and keratolytic agents were given therapeutic trials.

Accepted for publication March 23, 1977.

From the Department of Dermatology, State University of New York at Buffalo. Dr Gewirtzman is now in private practice in Plantation, Fla.

Reprints not available.

REPORT OF CASES

CASE 1.—A 7-year-old girl developed a widespread skin eruption during her first month of life. The eruption did not itch and improved in warm weather. Her father noted that lesions tended to migrate to various body areas, frequently occurring in previously uninvolved skin. On physical examination, we observed thick, symmetrically distributed scaling erythematous plaques with polycyclic borders that involved the neck and the popliteal and antecubital fossae. Thinner plaques were present on the trunk, and a plaque associated with hypertrichosis was noted over the lumbosacral area.

A biopsy specimen of a plaque on the posterior part of the right thigh displayed papillomatosis and a thin layer of compact stratum corneum underlying a basketweave hyperkeratosis. Hyperplasia of the rete ridges was prominent. A minimal perivascular lymphohistiocytic infiltrate was present in the papillary dermis (Fig 1).

The patient was instructed to apply 5% lactic acid in hydrophilic ointment to the right side of her body three times daily. A mild desquamation was noted after two weeks. Great improvement was seen after six weeks, with almost complete resolution in two months. The left side continued to show extensive involvement.

CASE 2.—A 21-month-old boy, the brother of patient 1, developed skin lesions a few weeks after birth. Results from physical examination were normal except for the skin. The trunk was diffusely involved with circinate, hyperkeratotic, erythematous plaques. All extremities were symmetrically involved. A relative sparing of the face was noted. The intertriginous areas had the thickest plaques. The patient was treated with 5% lactic acid in hydrophilic ointment. Complete clearing of the treated side was noted after four weeks (Fig 2). As a result of this treatment, the diaper area developed a bright erythema. The lactic-

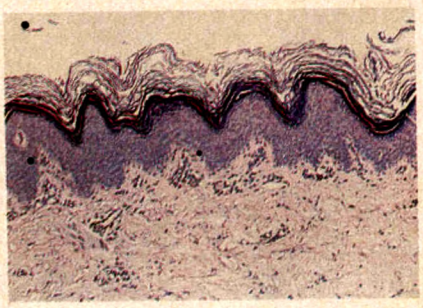

Fig 1.—Plaque demonstrating hyperkeratosis, papillomatosis, and hyperplasia of rete ridges (patient 1; hematoxylin-eosin, original magnification ×140).

Fig 2.—Patient 2. Right side treated with 5% lactic acid in hydrophilic ointment for four weeks.

Fig 3.—Typical plaque occurring in axilla (patient 5).

acid preparation was discontinued and the erythema cleared with application of 1% hydrocortisone cream.

Case 3.—A 30-year-old woman, the aunt of patients 1 and 2, gave a long history of an asymptomatic skin eruption. The patient described severe exacerbations during the last six months of her three pregnancies and when using birth control pills. The patient's trunk, axillae, and antecubital fossae showed symmetric, scaling plaques with polycyclic borders and an underlying erythema. Retinoic acid cream, 0.1%, applied nightly, effectively removed the scale within ten days, but moderate erythema persisted. Subsequent application of flurandrenolide cream, 0.05%, applied twice daily was followed by resolution of the erythema after four days.

Case 4.—A 41-year-old man, the brother of patient 5, complained of a skin eruption present since birth. The patient occasionally worked outdoors and believed cold weather and wind aggravated his condition. He noted clearing with a "freckle cream" containing ammoniated mercury. Almost the entire trunk of the patient was covered with red plaques with a yellow-brown scale. The plaques were thickest in the axillae and antecubital fossae.

Case 5.—A 36-year-old man, the father of patients 1 and 2, had a lifelong history of a dermatosis that worsened in cold weather. The patient had obtained a brief remission with an ammoniated mercury cream but was not using any form of treatment when first seen. Erythematous plaques with yellow-brown scale were symmetrically distributed in the axillae, and popliteal and antecubital fossae (Fig 3). A CBC and results of automated chemical analyses were within normal limits. Serum protein and immunoelectrophoresis values were normal. A 4-mm punch biopsy specimen showed papillomatosis covered by compact cornified cells. Above this compact layer was a loose basketweave orthokeratosis. The papillary dermis showed mild perivascular lymphocytic infiltration. Keralyt gel under occlusion caused rapid resolution of plaques. Erythema remained and the patient complained of mild irritation in the antecubital fossae.

Case 6.—A 30-year-old man, the son of patient 9, complained of a rash present since birth. The lesions tended to remit in summer. He claimed that a white meat of turkey diet for three weeks produced nearly complete clearing, but the diet became intolerable. When first seen, he was using only a bland lubricating cream. Sharply demarcated red plaques with brown scale were distributed mainly on the trunk and upper extremities.

Case 7.—A 65-year-old woman, the mother of patients 3, 4, and 5, complained of a skin rash that was present since birth. She gave a history of good clearing with ammoniated mercury cream. Her condition flared during all pregnancies. Examination disclosed erythematous plaques with a yellow-brown scale only in the antecubital fossae. Retinoic acid cream, 0.1%, was effective in removing the scale, but erythema remained.

Case 8.—A 70-year-old woman, the sister of patient 7, stated that she was born with a rash. She was able to clear her condition with a freckle cream. Her eruption cleared in warm weather and worsened in wind and cold weather. Involvement is now limited to her antecubital fossae.

Case 9.—A 65-year-old woman, the sister of patients 7 and 8, complained of an asymptomatic, lifelong skin eruption. The patient had noted severe flares of her condition during all four pregnancies. Present involvement is limited to an erythematous plaque with a thin yellow-brown scale on the anterior part of her neck.

The women in cases 10 through 12 are deceased, but several family members describe characteristic lesions of EKV in these persons.

COMMENT

The rough yellow-brown scale overlying erythematous areas, and the migratory nature of plaques and patches define EKV as a distinct entity. Our finding of 12 family members in five generations supports an autosomal dominant mode of inheritance (Fig 4).

Several disorders may resemble EKV. The genodermatose en cocardes of Degos is considered a variable circinate erythrokeratodermia, but the plaques have a target configuration.[8] Ichthyosis linearis circumflexa is recessively inherited and bamboo hairs and an aminoaciduria may be present.[9] The symmetrical progressive erythrokeratodermia of Darier and the familial form of pityriasis rubra pilaris do not have transient lesions.[8] The skin lesions of erythrokeratodermia with ataxia often disappear before age 25 years.[10]

The histologic picture of normal-appearing skin in patients with EKV

Fig 4.—Family pedigree of affected members.

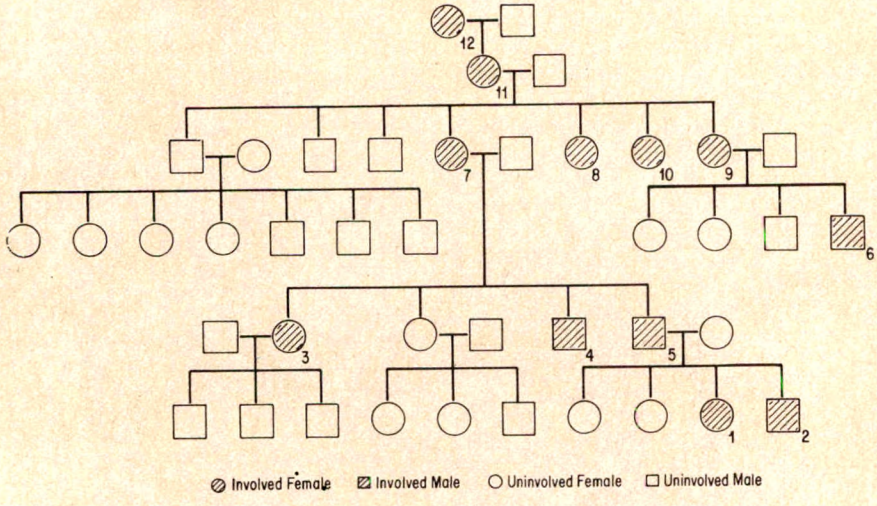

is indistinguishable from that of normal individuals. A mild superficial perivascular infiltrate sparing the dermal-epidermal junction is the earliest change. As the lesion progresses from a patch to a plaque, epidermal changes take place. The epidermis becomes hyperplastic and the stratum corneum develops characteristic changes. A loose basketweave hyperkeratotic upper portion of stratum corneum will overlay a compact lower portion of stratum corneum.

Erythrokeratodermia variabilis is a lifelong dermatosis requiring an efficacious and safe treatment modality. Since lifelong maintenance therapy will likely be necessary, it is best to avoid systemic medication. The patients were studied for a ten-month period, during which several topical preparations were used to treat plaques and erythema. Retinoic acid, keralyt gel, or ammoniated mercury "freckle cream" rapidly removed scale, but were ineffective in treating erythema. Retinoic acid and keralyt gel were frequently irritating. The results obtained with alpha hydroxy acids in ichthyosis by Van Scott and Tu[11] prompted us to apply 5% lactic acid in hydrophilic ointment twice daily. This was irritating only in the occluded diaper area, but clearing frequently was not noted for several weeks. Combinations of various concentrations of retinoic acid and 1% hydrocortisone are presently being evaluated and appear promising.

The role of hormonal factors remains an area for additional investigation. Patient 3 noticed severe flaring of her disease during all three pregnancies and while taking birth control pills. Patients 7 and 9 experienced widespread exacerbations of their disease during each of their pregnancies. Patients 7 through 9 have the least involvement, and each attests to remission at the onset of menopause.

Recent investigative studies of four of our patients, done in cooperation with Ernst Beutner, PhD, disclosed in vivo linear deposits of IgG in the lower portion of the stratum corneum. This pattern of stratum corneum antibody deposition was found in all clinically abnormal sites tested. Indirect and direct immunofluorescence studies of normal-appearing skin sites were negative. At this time it is difficult to know if deposition is a primary event or a phenomenon secondary to inflammation and increased vascular permeability. The importance of these findings continues to be evaluated and will be the subject of a future report.

References

1. DeBuy Wenniger LM: Erythrodermia congenitale ichthyosiforme avec hyperepidermotrophie. *Ned Tijdschr Geneesk* 1A:510-515, 1907.
2. Mendes da Costa S: Erythrodermia and keratodermia variabilis in mother and daughter. *Acta Dermatovener* 6:255-261, 1925.
3. Noordhoek F: *Over Erythro-et Keratodermia Variabilis.* Schiedam, NV Drukkerij de Eendracht, 1950.
4. Schnyder U, Sommacal-Schopf D: Fourteen cases of erythrokeratodermia figurata variabilis within one family. *Acta Genet* 7:204-206, 1957.
5. Barsky S, Bernstein G: Keratosis rubra figurata. *Arch Dermatol* 90:373-374, 1964.
6. Vandersteen P, Muller S: Erythrokeratodermia variabilis: An enzyme histochemical and ultrastructural study. *Arch Dermatol* 103:362-370, 1971.
7. Brown J, Kierland R: Erythrokeratodermia variabilis: Report of three cases and review of the literature. *Arch Dermatol* 93:194-291, 1966.
8. Cram D: Erythrokeratodermia variabilis and variable circinate erythrokeratodermas. *Arch Dermatol* 101:68-73, 1970.
9. Stevanoivic D: Multiple defects of the hair shaft in Netherton's disease: Association with ichthyosis linearis circumflexa. *Br J Dermatol* 81:851-857, 1969.
10. Giroux J, Barbeau A: Erythrokeratodermia with ataxia. *Arch Dermatol* 106:183, 1972.
11. Van Scott E, Tu R: Control of keratinization with alpha hydroxy acids and related compounds: Topical treatment of ichthyotic disorders. *Arch Dermatol* 110:586-590, 1974.

Pagetoid Reticulosis (Woringer-Kolopp Disease)

Histopathologic and Ultrastructural Observations

Maria Medenica, MD, Allan L. Lorincz, MD

• Histopathologic and ultrastructural observations in a case of Pagetoid reticulosis (Woringer and Kolopp disease) are reported. The most important clinical feature of this disease is manifestation as a single very slowly enlarging verrucoid, plaque-type skin lesion without internal organ involvement. Histologically, the epidermis is extremely acanthotic and densely infiltrated with numerous atypical appearing cells that are entirely absent from the dermis, which simply contains a banal dense chronic inflammatory infiltrate. Ultrastructural study showed that there are two major types of unusual cells infiltrating the epidermis. One type is a large lymphoid cell similar to the stimulated lymphocyte. The second type differs from the first in having paler staining of the nucleus and cytoplasm and showing cell membrane damage. These cells probably derive by degeneration from the large lymphoid cells. The presence of transitional forms favors this interpretation. Occasionally, degeneration of these cells proceeds to their complete necrosis.

(*Arch Dermatol* 114:262-268, 1978)

In 1939 Woringer and Kolopp[1] published the first case report of a very chronic localized form of reticulosis confined to the epidermis. Later Gisiger,[2] in 1970, and Braun-Falco et al,[3] in 1973, described similar cases. In all reports this rare disease appeared clinically as a sharply localized erythematous, scaly area that became a thickened verrucous plaque that enlarged slowly over periods ranging from 6 to 16 years. There was never involvement of other organs. Histopathologic examination in all cases showed a markedly acanthotic epidermis within which there was an infiltrate of abnormal mononuclear cells either in disseminated or grouped fashion characterized by relatively pale cytoplasm and large hyperchromatic nuclei. Braun-Falco et al[3] did ultrastructural and cytochemical studies on skin biopsy specimens from their patient and found that the atypical cells in the epidermis were probably of lymphoid origin. Because of the atypical appearance of the cells infiltrating the epidermis, this entity was considered a reticulosis limited to the skin by all authors,[1-3] who published their cases.

We prefer, until more convincing unifying evidence can be brought forth, to distinguish Woringer-Kolopp disease from cases we would call epidermotropic mycosis fungoides such as reported by Grosshans et al,[4] Dupont and Vandaele,[5] Mezzadra and Sapuppo,[6] and Degreef et al[7] in which there is subepidermal and sometimes even internal involvement[5-7] with atypical mononuclear cells. In mycosis fungoides the numbers of atypical cells invading the epidermis can vary greatly and those cases that feature very extensive invasion can be classified as epidermotropic mycosis fungoides. We believe that the designation Woringer-Kolopp disease should be restricted to the rather benign cases showing only a single, slowly enlarging skin lesion without internal involvement and with only extensive epidermal infiltration with highly atypical appearing mononuclear cells confined *strictly* to the epidermis. It is not known why, in spite of the highly atypical appearance of the infiltrating cells, there is no involvement of the dermis or internal organs. We recently encountered a patient with this unusual disorder and carried out extensive clinical, laboratory, and light and electron microscopic histopathologic examinations in efforts to further clarify the nature of this disease.

REPORT OF A CASE

A 68-year-old man was admitted with an asymptomatic lesion on his left flank that started 25 years previously as an erythematous scaly area that gradually enlarged. Family and personal medical histories and review of systems were unremarkable. On examination there was on the left flank a 15 × 30-cm erythematous, indurated, hyperkeratotic plaque with irregular verrucous borders and a partially denuded, oozing scale-crusted center. Results from the remainder of the physical examination were normal, except for the presence of 1- to 2-cm freely movable axillary and inguinal lymph nodes. Inguinal lymph node biopsy examination showed follicular and paracortical hyperplasia. Results of laboratory examinations, including complete hemogram with differential cell count, coagulation parameters, 12-channel automated blood chemical determinations, routine urinalysis, and serum protein electrophoresis, were all normal. A VDRL test was negative. Sézary cells were not present in blood smears. Chest roentgenogram, inferior vena cavogram, excretory urogram, liver, spleen, and bone scans, and a tumor scan after administration of gallium citrate Ga 67 were normal. Skin tests with purified protein derivative of tuberculin (PPD), *Trichophyton*, and *Candida* antigen were positive. Erythrocyte sedimentation rate was modestly elevated to 26 mm/hr (Westergren). Plasma immunoelectrophoresis showed slight polyclonal increases in IgG and IgA. Electrocardiogram showed sinus rhythm with rare premature ventricular contractions and nonspecific T wave changes. Pulmonary function test showed mild obstructive abnormality. The single skin lesion was treated with 6,000 rads of 7.5 meV electron beam radiation from a

Accepted for publication March 14, 1977.

From the Section of Dermatology, Department of Medicine, the University of Chicago Pritzker School of Medicine, and Illinois and Research and Education Services, Veterans Administration Hospital, Hines, Ill.

Reprint requests to Section of Dermatology, Box 409, 950 E 59th St, Chicago, IL 60637 (Dr Medencia).

linear accelerator. The lesion completely involuted, leaving a slightly scarred pink surface with underlying fibrosis (Fig 1).

MATERIALS AND METHODS

A 4-mm punch biopsy specimen was obtained from the skin lesion prior to radiation therapy and bisected. Half was fixed in formalin, embedded in paraffin, and routinely sectioned and stained with hematoxylin-eosin and the PAS method with and without diastase digestion. The other half was cut into four pieces: two were fixed in 3% glutaraldehyde with Millonig's buffered osmic acid. The other two were fixed in collidine buffered osmic acid for one hour 45 minutes. All four pieces were then processed in the same way. They were dehydrated in ethyl alcohol, embedded in epoxy resin, and sectioned on an ultramicrotome. Sections 600 to 800 A thick were stained with uranyl acetate and lead citrate and examined with an electron microscope. Additionally, sections 1 to 2 μ thick were stained with a mixture of 1% pyronin and 1% toluidine blue in a ratio of 1:4 for light microscope viewing.

RESULTS

Light Microscopic Observations

The epidermis shows hyperkeratosis, parakeratosis, marked acanthosis and is partially covered with a thick purulent crust. Numerous small spaces that resemble Pautrier's microabscesses are seen through the whole thickness of the epidermis. These spaces contain single cells or groups of cells that morphologically differ from surrounding keratinocytes (Fig 2 and 3). They are moderately large and have a paler cytoplasm than the epidermal cells. They possess large hyperchromatic and irregularly shaped nuclei. The same type of cell is also present in both the parakeratotic masses and crusts. In the epidermis there are also moderate numbers of cells that have somewhat less hyperchromatic nuclei and ill-defined cytoplasm. A few small lymphocytes and some cellular debris are also present. The upper dermis shows fibrosis and a moderately dense perivascular infiltrate that consists of plasma cells, lymphocytes, and histiocytes (Fig 2). The cells with hyperchromatic nuclei that infiltrate the epidermis are not at all seen in the dermis. The PAS-stained sections showed that the cells that infiltrate the epidermis do not contain glycogen. The PAS-positive basement membrane is clearly delineated in spite of the heavy infiltrate.

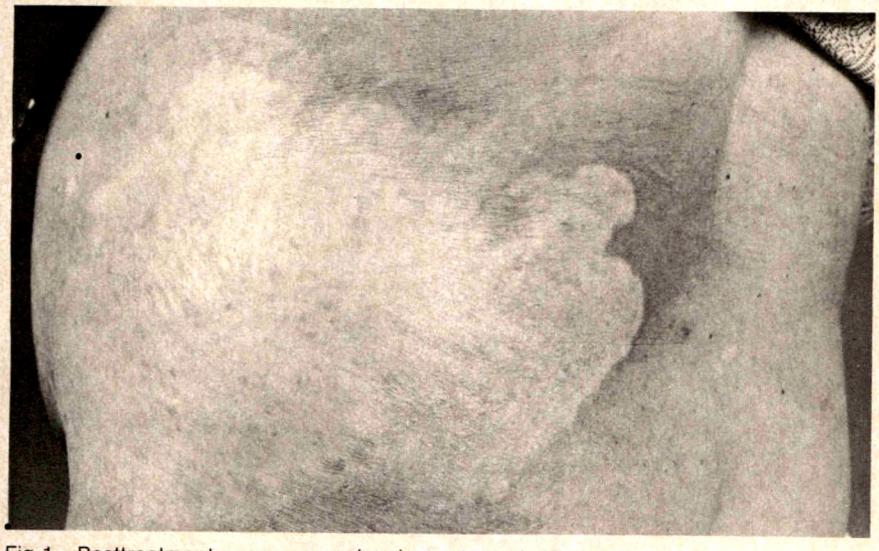

Fig 1.—Posttreatment appearance showing extent of skin involvement.

Electron Microscopic Observations

The greatly acanthotic epidermis is heavily infiltrated with large mononuclear cells, most of which show irregular or folded nuclei. The cytoplasm in these cells is voluminous and filled with densely packed ribosomes that are arrayed as monoribosomes or arranged in rosettes. There is increased smooth endoplasmic reticulum arranged about flattened cisterns. The Golgi apparatus is well developed. Numerous mitochondria show increased numbers of cristae arranged in parallel compact rows. Bands of filaments are also seen. These cells resemble stimulated lymphocytes[8] and are seen individually or in groups

Fig 2.—Histologic section of lesion showing acanthosis and infiltration of the epidermis with large lymphoid cells. Note absence of these cells in the dermis (hematoxylin-eosin, original magnification ×50).

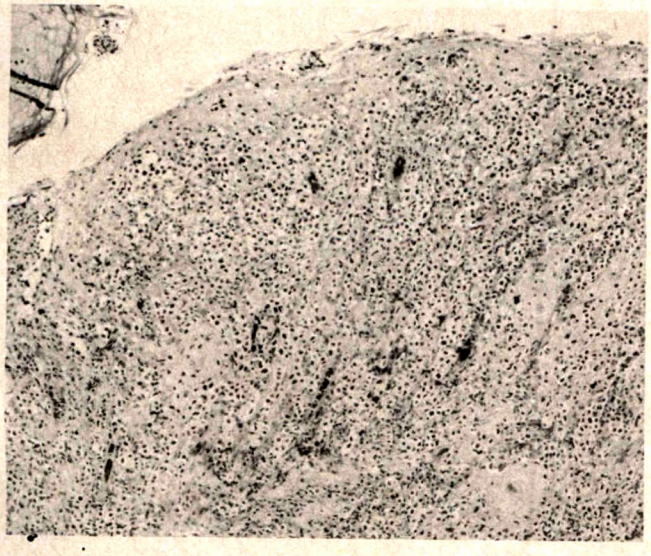

Fig 3.—Higher magnification of Fig 2. Cells infiltrating the epidermis (hematoxylin-eosin, original magnification ×100).

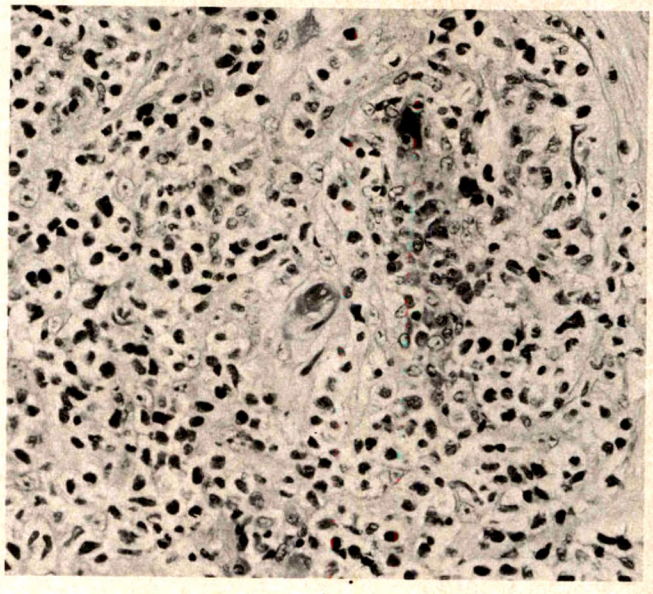

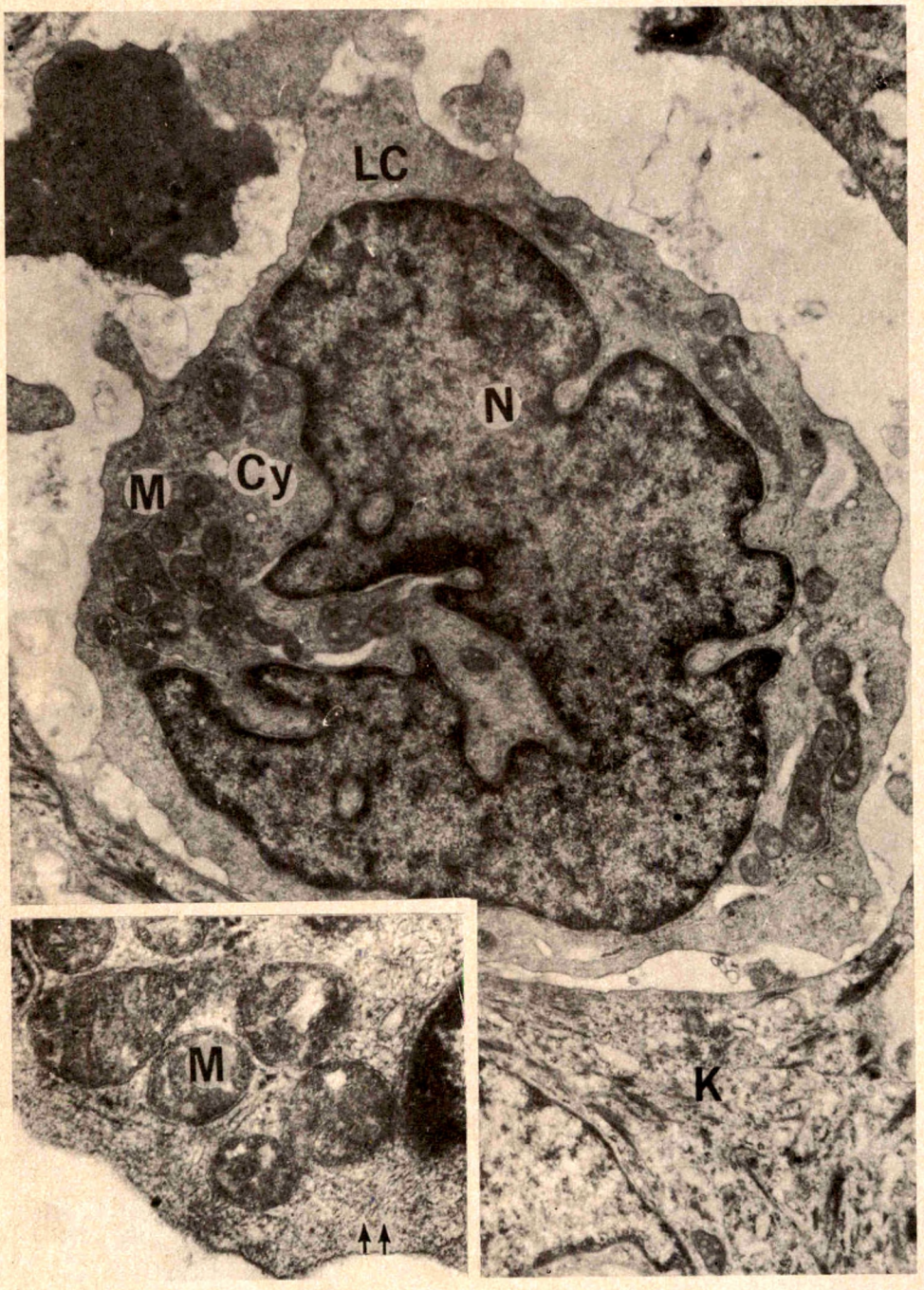

Fig 4.—Lymphoid cell (LC) in epidermis with irregular nucleus (N), considerable amount of cytoplasm (Cy), and cytoplasmic organelles; keratinocyte (K), mitochondria (M), and filaments (double arrows) are also indicated (original magnification ×4,000). Insert (original magnification ×10,000).

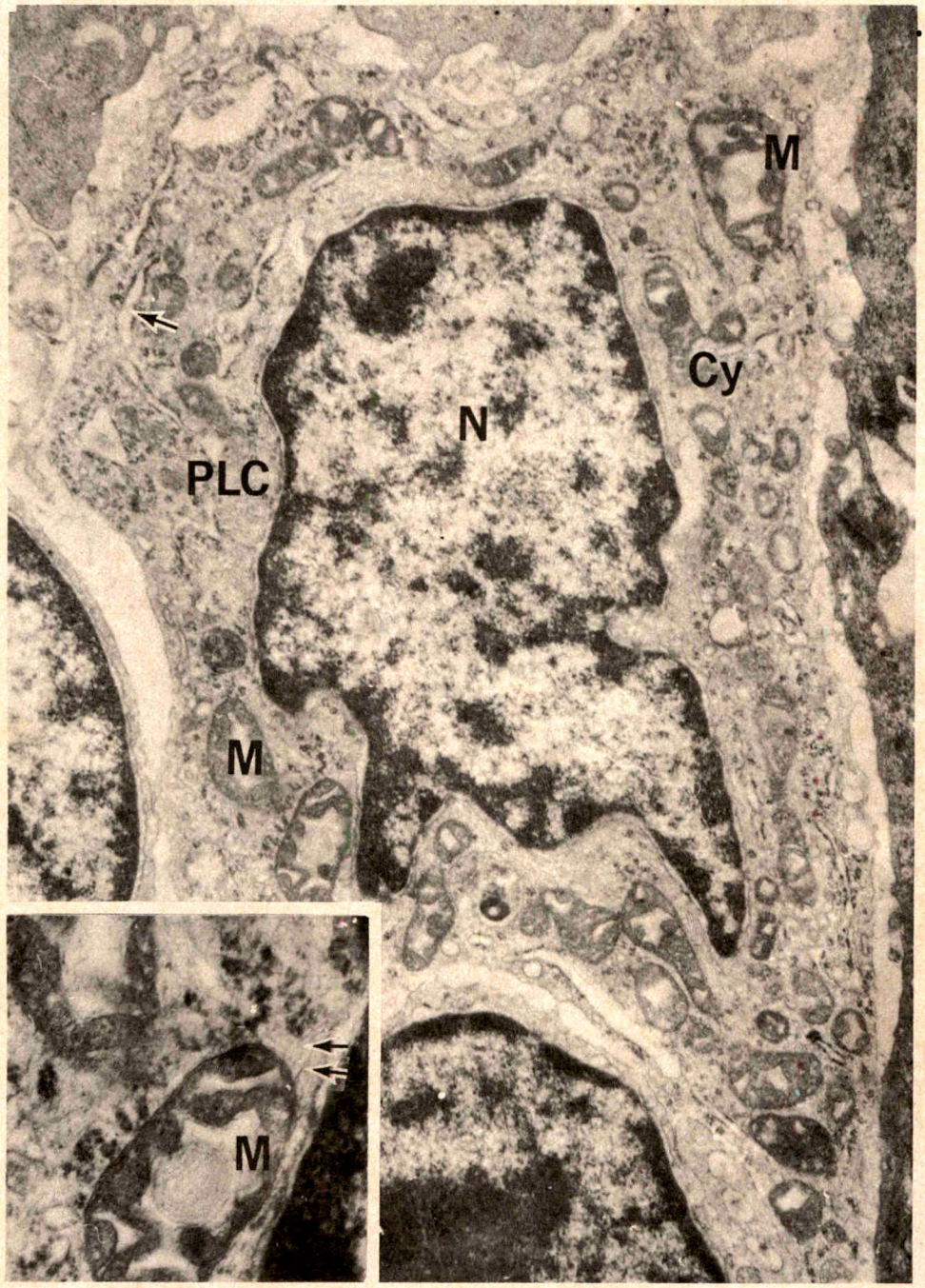

Fig 5.—Pale lymphoid cell (PLC). Nucleus (N) has pale center. The cytoplasm (Cy) has swollen mitochondria (M), dilated endoplasmic reticulum (single arrow), and decreased numbers of ribosomes. Filaments are indicated by double arrows (original magnification, ×4,000). Insert (original magnification, ×10,000).

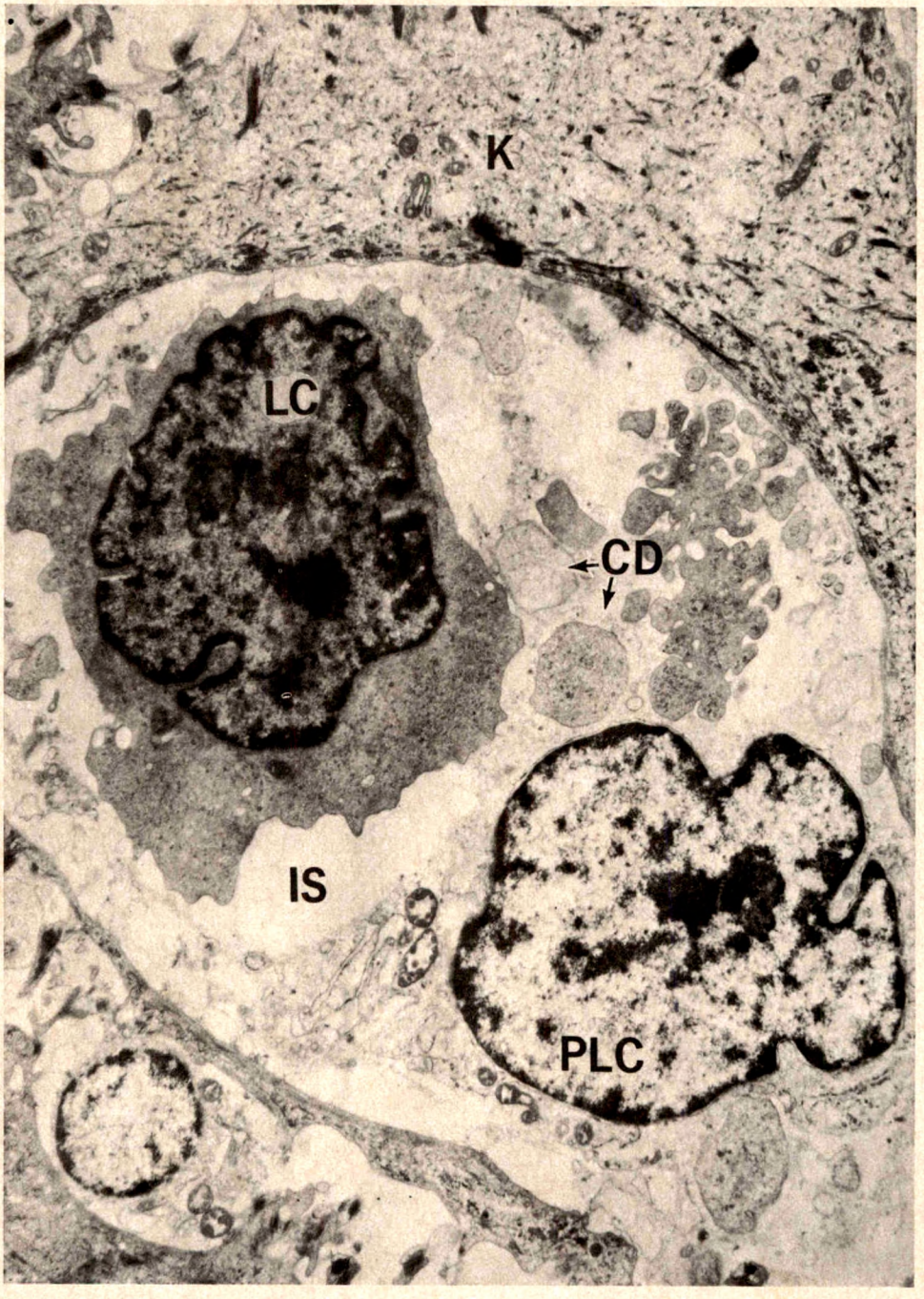

Fig 6.—Intraepidermal space (IS) containing cellular debris (CD), lymphoid cell (LC), and pale lymphoid cell (PLC) that shows interruptions of the cell membrane; keratinocyte (K) (original magnification, ×2,000).

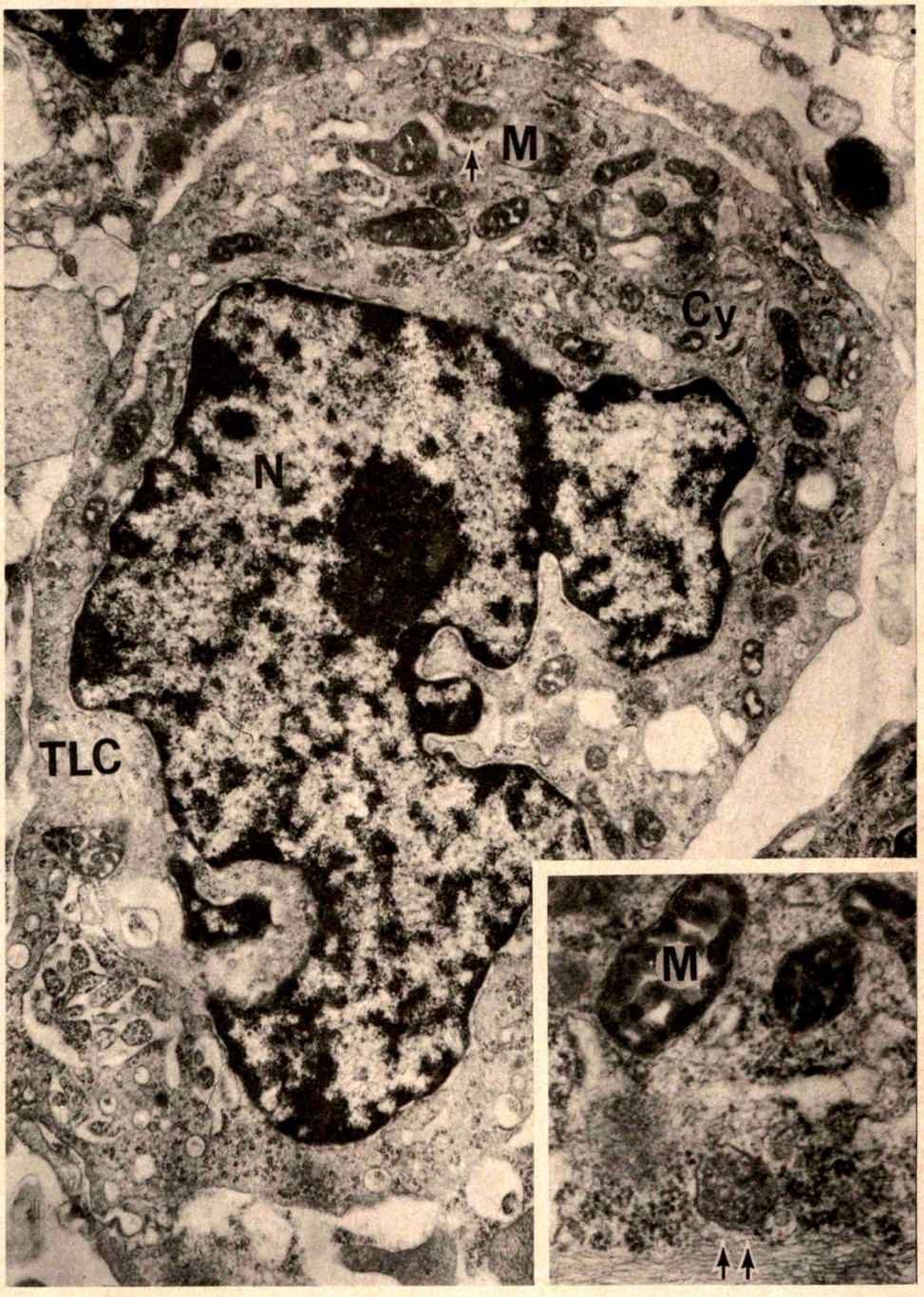

Fig 7.—Transitional lymphoid cell (TLC), which shows moderately swollen mitochondria (M) and some dilation of endoplasmic reticulum (single arrow); filaments (double arrows); nucleus (N); cytoplasm (Cy) (original magnification ×3,500). Insert (original magnification, ×10,000).

between keratinocytes (Fig 4). In addition a considerable number of more pale appearing cells (Fig 5) are also present individually or in groups or mixed with the above-described lymphoid cells (Fig 6). These pale cells have about the same size and similarly shaped nuclei as the lymphoid cells. These cells, however, show signs of degeneration. Their nuclei have pale centers. Mitochondria are swollen and have shortened cristae. The endoplasmic reticulum is dilated and there are numerous vesicles and vacuoles. Ribosomes and filaments are also reduced in number. All of these changes account for the paler appearance of these cells. The membranes of these cells also show numerous interruptions. Finally, degeneration in some of these cells progresses to complete necrosis involving individual or groups of cells. Small spaces are also noted between keratinocytes where only cellular debris is seen. Some cells are also seen that are not pale but show only moderate dilation of endoplasmic reticulum and smaller numbers of degenerated mitochondria and appear to be transitional (Fig 7) between the lymphoid cells and the pale, more degenerated cells. A few small lymphocytes and macrophages are also seen. A considerable number of keratinocytes also show signs of damage ranging up to necrosis. In the upper dermis there are plasma cells, lymphocytes, and macrophages.

COMMENT

The morphologic and histopathologic features of the skin lesion in our patient have the same characteristics as described in the cases of pagetoid reticulosis reported by Woringer and Kolopp[1] and other investigators.[2,3] Clinically there is a resemblance to the plaque stage of mycosis fungoides, but the long duration of an isolated skin lesion and the absence of internal involvement makes the diagnosis of mycosis fungoides unlikely. Histopathologically, the heavily infiltrated epidermis presents a pagetoid appearance. The cellular infiltrate is monomorphous and consists of large cells with hyperchromatic nuclei. Electron microscopic examination of these cells fails to show tonofilaments and desmosomes as previously mentioned, and these absences speak against their epithelial[9,10] origin. From a histopathologic viewpoint, mycosis fungoides requires consideration. The dense infiltrate in the epidermis of large cells with hyperchromatic nuclei in the face of a total absence of these cells in the dermal infiltrate, which consists only of plasma cells, lymphocytes, and histiocytes, is not seen in ordinary mycosis fungoides. Although electron microscopic examination of the infiltrate in the epidermis shows large lymphoid cells (Fig 4) that have irregular or folded nuclei similar to Lutzner cells[11] in mycosis fungoides, the cells nevertheless appear different because of their cytoplasm, which is more voluminous and busy with increased smooth flat endoplasmic reticulum, numerous mitochondria, ribosomes, and filaments. Stimulated lymphocytes show similar nuclear and cytoplasmic changes. Considerable numbers of the epidermis-infiltrating cells similarly resemble large lymphoid cells in size and nuclear shape but show signs of degeneration. Their nuclei have pale centers, mitochondria are swollen with shortening of cristae, and there is dilation of the endoplasmic reticulum with the formation of small vesicles and vacuoles to give the cells a pale appearance. There is also cell membrane damage. This type of cell is not seen in mycosis fungoides. Most likely these cells represent degeneration of large lymphoid cells (Fig 5). The presence of transitional forms (Fig 7) further favors this interpretation. Occasionally degeneration of these cells proceeds to their complete necrosis, forming small intraepidermal spaces filled with cellular debris amidst which occasional swollen mitochondria still can be recognized. Considerable numbers of keratinocytes can also be damaged and even become necrotic contributing to the formation of the intraepidermal spaces. The epidermis reacts with regeneration and acanthosis develops. We believe on the basis of the ultrastructural observations mentioned that the infiltrating cells have features of stimulated lymphocytes and are not the malignant cells seen in mycosis fungoides. The striking epidermotropism of the infiltrating cells might be explained by postulating the presence of a special antigenic stimulus in a localized area of the epidermis that stimulates lymphocytes and leads to their local accumulation. In the case reported by Braun-Falco et al,[3] the area of affected skin was removed and skin grafted. The grafted area remained free of disease. This observation clearly favors a localized pathogenic factor in this unusual disease. The majority of the epidermis-infiltrating cells are removed by desquamation at the skin surface via a process of keratinization of surrounding keratinocytes as previously noted by Braun-Falco et al[3] Others of these cells are destroyed within the epidermis. The probable stimulated lymphocytic nature of the infiltrating cells and the operation of both these cell-removing mechanisms would correlate well with the clinically benign and very chronic nature of the disease.

This investigation was supported in part by American Cancer Society Grant Committee award IN-41-0.

Hirshi Tanaki and Florence Bush prepared the graphics.

References

1. Woringer F, Kolopp P: Lesion erythemato-squameuse polycyclique de l'Avant-bras evoluant depuis 6 ans chez un garconnet de 13 ans histologiquement infiltrat intraepidermique d'apparence tumorale. *Ann Dermatol Syphiligr* 7:945-948, 1939.

2. Gisiger O: Zur differentialdiagnose der von Woringer und Kolopp beschriebenen reticulose. *Dermatologica* 140(suppl 2):19-34, 1970.

3. Braun-Falco O, Marghescu S, Wolff H: Pagetoid reticulose morbus Woringer-Kolopp. *Hautarzt* 24:11-21, 1973.

4. Grosshans E, Hee P, Basset A, et al: Le maladie de Woringer et Kolopp (reticulose cutanee epidermotrope reticulose pagetoide). *Arch Belg Dermatol Syphiligr* 29:195-203, 1973.

5. Dupont D, Vandaele R: Reticulose cutanee epidermotrope accompagnee de lesions gastrigues et vertebrales. *Arch Belg Dermatol Syphiligr* 15:267-274, 1959.

6. Mezzadra G, Sapuppo A: Reticulo-istiocitosi cutanea subacuto-cronica con particlariaspetti clinico istalogici. *G Ital Dermatol* 107:323-336, 1966.

7. Degreef H, Holvoet C, Van Vloten W, et al: Woringer-Kolopp disease: An epidemotropic variant of mycosis fungoides. *Cancer* 38:2154-2165, 1976.

8. Bessis M: *Living Blood Cells and Their Ultrastructure.* New York, Springer-Verlag, 1973, pp 413-463.

9. Sagebiel R: Ultrastructural observations on epidermal cells in Paget's disease of the breast. *Am J Pathol* 57:49-56, 1969.

10. Medenica M, Sahihi T: Ultrastructural study of a case of extramammary Paget's disease of the vulva. *Arch Dermatol* 105:236, 1972.

11. Lutzner M, Hobbs J, Horvath P: Ultrastructure of abnormal cells. *Arch Dermatol* 103:375-387, 1971.

The Corneocyte Count Down.

A high corneocyte count means scaling, flaking and an itchy scalp. Unsightly and unwanted by your dandruff patients.

Chances are they have tried the TV-promoted brands before consulting you about their problem.

Prescribe Exsel® (selenium sulfide) 2.5%. Clinically proven the most potent dandruff shampoo available. It gets rid of the unwanted corneocyte scales and retards their redevelopment for days.*

And Exsel offers one distinct advantage over other Rx anti-dandruff preparations: cosmetic elegance. Pleasing, fragrant lime-scented Exsel shampoo lathers richly, therefore assuring greater patient acceptability and better compliance with your instructions.

Exsel® (selenium sulfide) 2.5% Lotion- CONTAINS: selenium sulfide...2.5% with: edetate disodium; bentonite; sodium linear alkylate sulfonate; alphaolefin sulfonate; glyceryl monoricinoleate; silicone; titanium dioxide; citric acid monohydrate; sodium phosphate monobasic, monohydrate; perfume and purified water. ACTIONS: The mechanism of action of selenium sulfide in seborrheic dermatitis is unknown. INDICATIONS: Selenium sulfide is indicated in the treatment of seborrheic dermatitis of the scalp, including dandruff. CONTRAINDICATIONS: The product should not be used by patients allergic to any of its components. WARNINGS: Safety for use in infants has not been established. PRECAUTIONS: 1. Chemical conjunctivitis may result if this preparation enters the eyes. 2. The product should be used with caution when acute inflammation or exudation is present as an increase in absorption may occur. ADVERSE REACTIONS: 1. Hair loss has been reported with the use of the product. 2. Discoloration of the hair may follow the use of selenium sulfide. This can be minimized by careful rinsing of the hair after treatment. 3. Oiliness of the hair and scalp may increase following the use of this product.

*Kligman, A.M. et al. Dandruff: It's nature and treatment, University of Pennsylvania, Department of Dermatology, Duhring Laboratories. Paper presented at American Academy of Dermatology, San Francisco, 1975.

Herbert Laboratories
Dermatology Division of
Allergan Pharmaceuticals, Inc.
Irvine, California 92713, U.S.A.

Count on Exsel.
(selenium sulfide) 2.5%



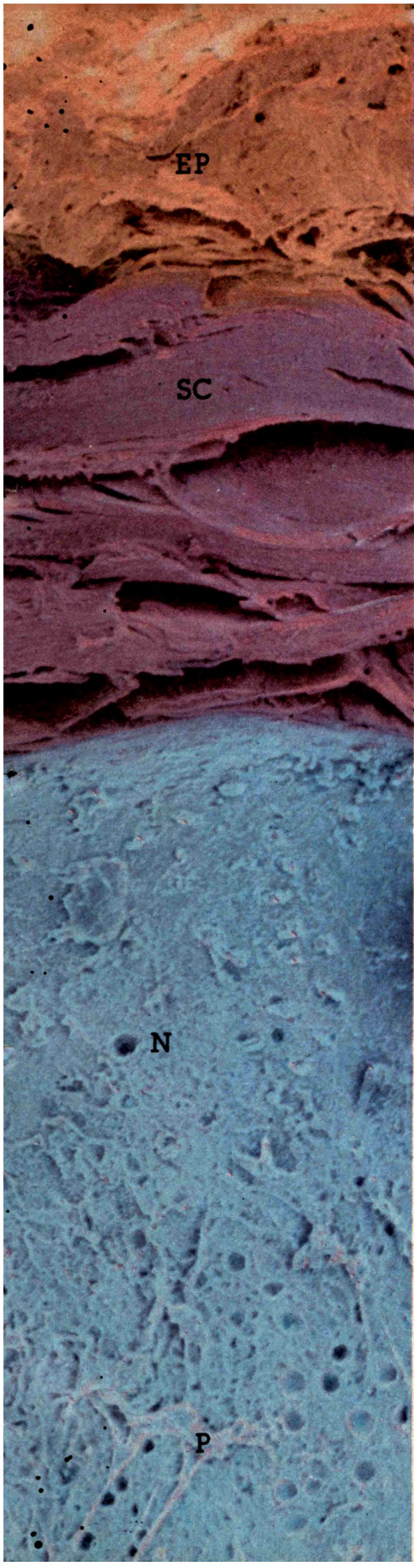

Potency in psoriasis

Potency — A singularly important criterion in selecting a topical steroid for psoriasis, as well as all other acute inflammatory steroid-responsive conditions.

Fluocinonide — A steroid that is 100% dissolved in the Lidex base for optimal lesion penetration. Anti-inflammatory, vasoconstrictive, antipruritic actions, backed by a proven record of performance.

Available in a form that's right for the case at hand — cream, ointment, or Topsyn® (fluocinonide) Gel, 0.05%.

Lidex®

(fluocinonide) 0.05%

See following page for summary of prescribing information.

Cryofractured section of psoriatic epidermis photographed en face. Epidermis (EP) is thickened and stratum corneum (SC) is both thickened and highly disorganized. Dark oval depressions are nuclei (N). Stringy adherent material is exuded serum protein (P).

Color imposed on black-and-white photomicrograph magnified 209X.

SYNTEX

SYNTEX LABORATORIES, INC.
PALO ALTO, CALIFORNIA 94304

LIDEX® (fluocinonide)
Cream and Ointment 0.05%

TOPSYN® (fluocinonide)
Gel 0.05%

Summary of prescribing information

Description

LIDEX cream 0.05%, LIDEX ointment 0.05% and TOPSYN gel 0.05% contain the active compound fluocinonide. Fluocinonide, which is the 21-acetate ester of fluocinolone acetonide, has the chemical formula 6α, 9α-difluoro-11β, 16α, 17α, 21-tetrahydroxypregna-1,4-diene-3, 20-dione, cyclic 16, 17-acetal with acetone 21-acetate. LIDEX cream contains fluocinonide in FAPG® cream, a specially formulated cream base consisting of stearyl alcohol, polyethylene glycol 6000, propylene glycol, 1, 2, 6-hexanetriol and citric acid. This white cream vehicle is greaseless, non-staining, anhydrous and completely water miscible. The base provides emollient and hydrophilic properties. In this formulation, the active ingredient is totally in solution.

LIDEX ointment contains fluocinonide in a specially formulated ointment base consisting of Amerchol CAB (mixture of sterols and higher alcohols), white petrolatum, propylene carbonate and propylene glycol. It provides the occlusive and emollient effects desirable in an ointment. In this formulation the active ingredient is totally in solution.

TOPSYN gel contains fluocinonide in a specially formulated gel base consisting of propylene glycol, propyl gallate, disodium edetate, and Carbopol 940 (carboxypolymethylene) with NaOH and/or HCL added to adjust the pH. This clear, colorless, thixotropic vehicle is greaseless, non-staining and completely water miscible. In this formulation, the active ingredient is totally in solution.

Indications

LIDEX cream and ointment and TOPSYN gel are intended for the relief of inflammatory manifestations of corticosteroid responsive dermatoses.

Contraindications

Topical steroids are contraindicated in vaccinia and varicella. Topical steroids are contraindicated in those patients with a history of hypersensitivity to any of the components of the preparation.

Precautions

If irritation develops, the cream, ointment or gel should be discontinued and appropriate therapy instituted. In the presence of an infection the use of an appropriate antifungal or antibacterial agent should be instituted.

If a favorable response does not occur promptly, the corticosteroid cream, ointment or gel should be discontinued until the infection has been adequately controlled.

If extensive areas are treated, the possibility exists of increased systemic absorption and suitable precautions should be taken.

Although topical steroids have not been reported to have an adverse effect on pregnancy, the safety of their use in pregnant females has not absolutely been established. Therefore, they should not be used extensively on pregnant patients, in large amounts or for prolonged periods of time.

LIDEX® (fluocinonide) cream and ointment and TOPSYN® (fluocinonide) gel are not for ophthalmic use.

Adverse reactions

The following local adverse reactions have been reported with topical corticosteroids:

burning	folliculitis
itching	acneform eruptions
irritation	hypopigmentation
dryness	striae
secondary infection	skin atrophy

Dosage and administration

A small amount should be gently massaged into the affected area three or four times daily, as needed.

How supplied

LIDEX Cream 0.05% – 15 g 30 g and 60 g tubes.
LIDEX Ointment 0.05% – 15 g 30 g and 60 g tubes.
TOPSYN Gel 0.05% 15 g and 60 g tubes.

SYNTEX
SYNTEX LABORATORIES, INC.
PALO ALTO, CALIFORNIA 94304

How are you keeping up with happenings in your specialty?

Keep up-to-date with an AMA Specialty Journal. Month after month, it will bring you articles on original research, news of medical significance, and comments on current events in the specialty field of your interest.

Start an AMA Specialty Journal coming today.

- ☐ American Journal of Diseases of Children
- ☐ Archives of Dermatology
- ☐ Archives of General Psychiatry
- ☐ Archives of Internal Medicine
- ☐ Archives of Neurology
- ☐ Archives of Ophthalmology
- ☐ Archives of Otolaryngology
- ☐ Archives of Pathology and Laboratory Medicine
- ☐ Archives of Surgery

	U.S. & Poss.	All Other Countries
☐ 24 issues.....	$28.00	$38.00
☐ 12 issues.....	$18.00	$28.00

Payment must accompany all orders. Make checks payable to the American Medical Association.

Name _____

Address _____

City _____ State _____ Zip _____

Return to: Subscription Department, AMA
535 North Dearborn St., Chicago, Ill. 60610

S/J

what's best for the care of dry, or premature aging or wrinkled skin... DUE TO EPIDERMAL DEHYDRATION?

SUPPLIED: 2 OZ. TUBES

WRITE FOR SAMPLES

DOAK PHARMACAL CO., INC. WESTBURY, N.Y. 1159

DISTRIBUTOR IN CANADA
TRANS-CANADA DERMAPEUTICS LTD., MONTREAL 23, QUEBE

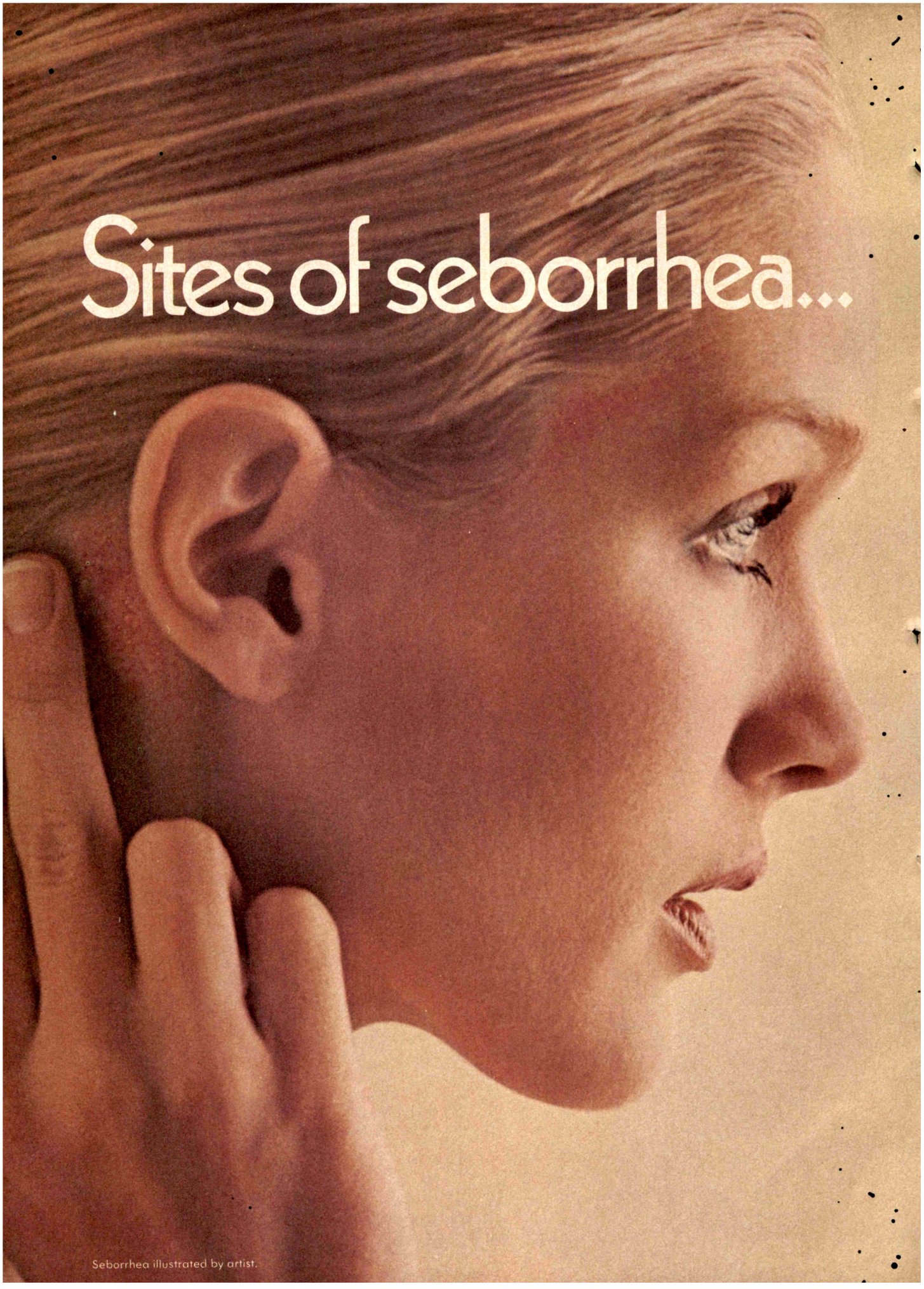
Sites of seborrhea...
Seborrhea illustrated by artist.

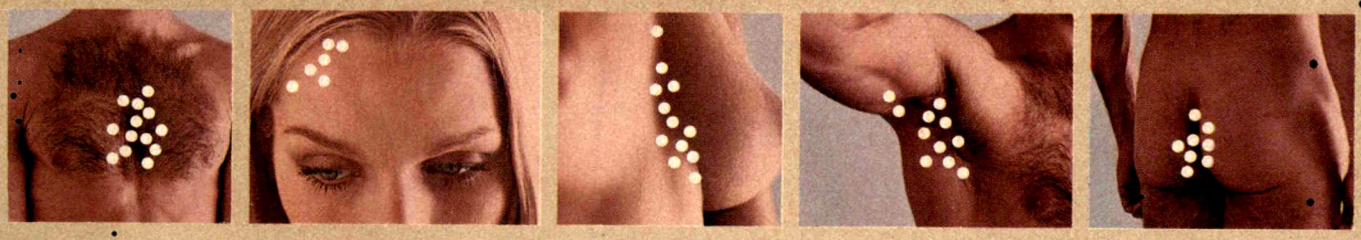

spots for Uticort™ (betamethasone benzoate gel, USP)

a highly effective topical steroid in a special base

UTICORT contains the fluorinated corticosteroid ester — betamethasone benzoate 0.025% — in a specially formulated, clear, self-liquefying gel base to increase steroid activity.

Patients with seborrheic dermatitis treated with UTICORT improved 86% in an average of 11.6 days.

liquefies on application for better surface contact

UTICORT is especially valuable in the treatment of seborrheic dermatitis on hairy areas of the body.

cosmetically acceptable

UTICORT dries to a clear film and can be used confidently on either smooth or hairy skin areas. Moreover, it is greaseless, nonstaining, and nonsticky.

preservative free

Contains no parabens or other potentially sensitizing preservatives.

Brief summary of prescribing information

INDICATIONS. Uticort Gel (betamethasone benzoate gel, USP) is intended for relief of the inflammatory manifestations of corticosteroid-responsive dermatoses.

CONTRAINDICATIONS. Topical steroids are contraindicated in viral diseases of the skin, such as varicella and vaccinia. Topical steroids are contraindicated in patients with a history of sensitivity to any of the components of the preparation.

This preparation is not for ophthalmic use.

PRECAUTIONS. If irritation develops, the gel should be discontinued and appropriate therapy instituted. In the presence of an infection, the use of appropriate antifungal or antibacterial agents should be instituted. If a favorable response does not occur promptly, the corticosteroid should be discontinued until the infection has been adequately controlled.

If extensive areas are treated, or if the occlusive technique is used, the possibility exists of increased systemic absorption of the corticosteroid, and suitable precautions should be taken.

Although topical steroids have not been reported to have an adverse effect on pregnancy, the safety of their use in pregnant females has not absolutely been established. Therefore, they should not be used extensively on pregnant patients, or in large amounts, or for prolonged periods of time.

Due to the alcohol content of the vehicle, Uticort Gel (betamethasone benzoate gel, USP) may cause mild, transient stinging without irritation if used on excoriated skin.

ADVERSE REACTIONS. The following local adverse reactions have been reported with topical corticosteroids: burning sensations, itching, irritation, dryness, folliculitis, secondary infection, skin atrophy, striae, hypertrichosis, acneform eruptions, and hypopigmentation.

DOSAGE AND ADMINISTRATION. Apply to affected areas two to four times daily as needed.

HOW SUPPLIED. N 0071-3025 Uticort Gel is supplied in 15 gram and 60 gram tubes.

Caution: Federal law prohibits dispensing without prescription.

PARKE-DAVIS

UE

PD-JA-2343-1-P (1-78)

PARKE, DAVIS & COMPANY Detroit, MI 48232

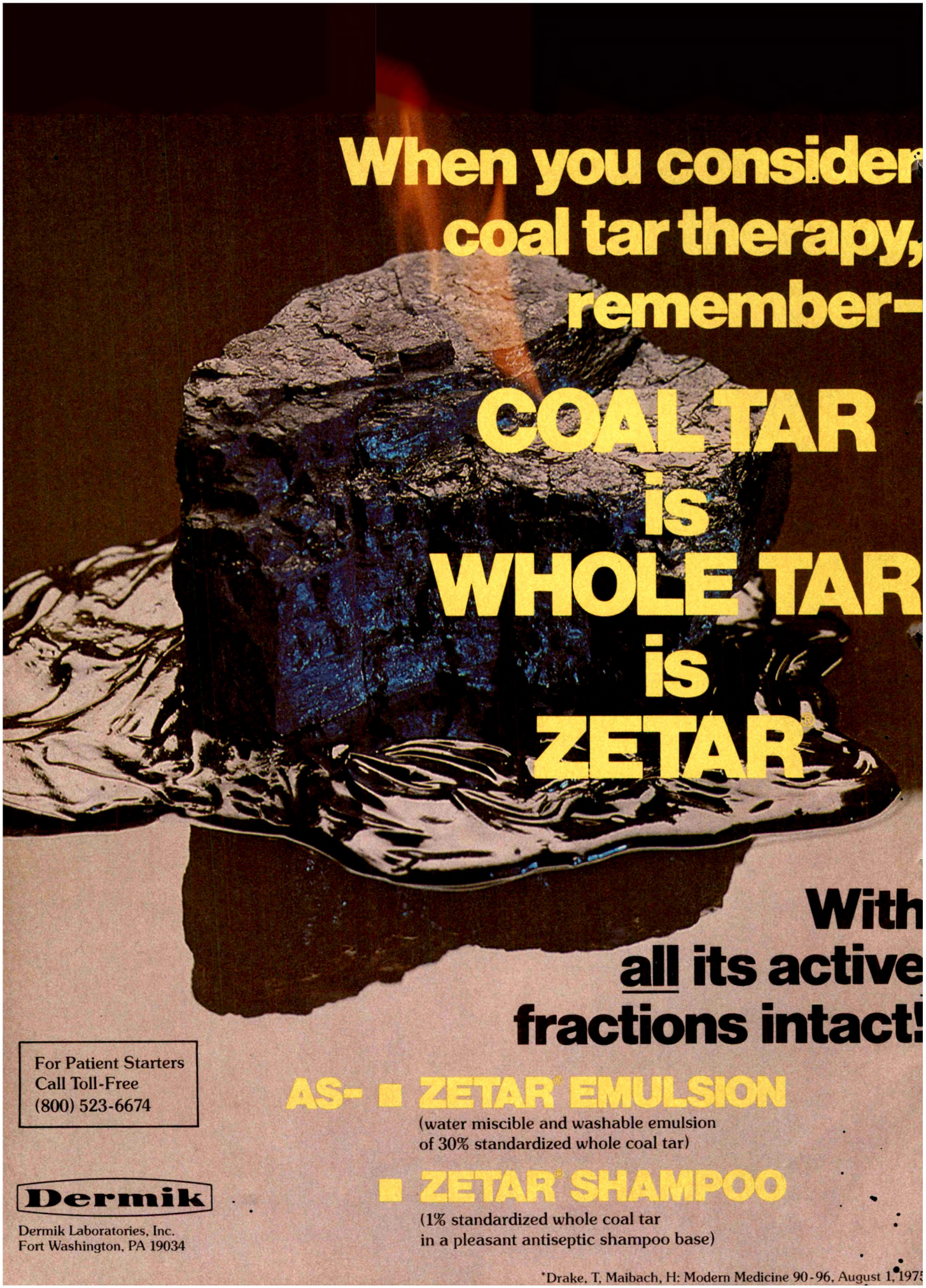
When you consider
coal tar therapy,
remember–
COAL TAR
is
WHOLE TAR
is
ZETAR®
With
all its active
fractions intact!
For Patient Starters
Call Toll-Free
(800) 523-6674
AS- ■ ZETAR® EMULSION
(water miscible and washable emulsion
of 30% standardized whole coal tar)
■ ZETAR® SHAMPOO
(1% standardized whole coal tar
in a pleasant antiseptic shampoo base)
Dermik
Dermik Laboratories, Inc.
Fort Washington, PA 19034
*Drake, T, Maibach, H: Modern Medicine 90-96, August 1, 1975

we named it what it is

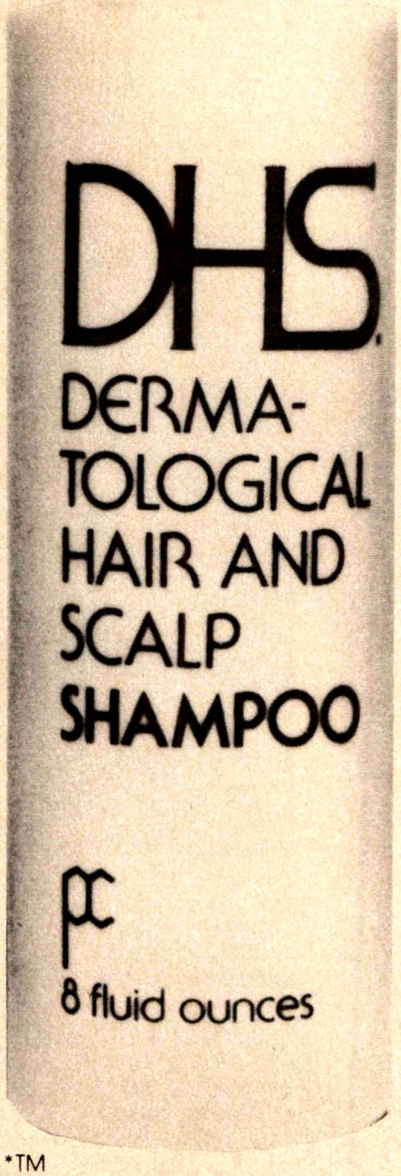

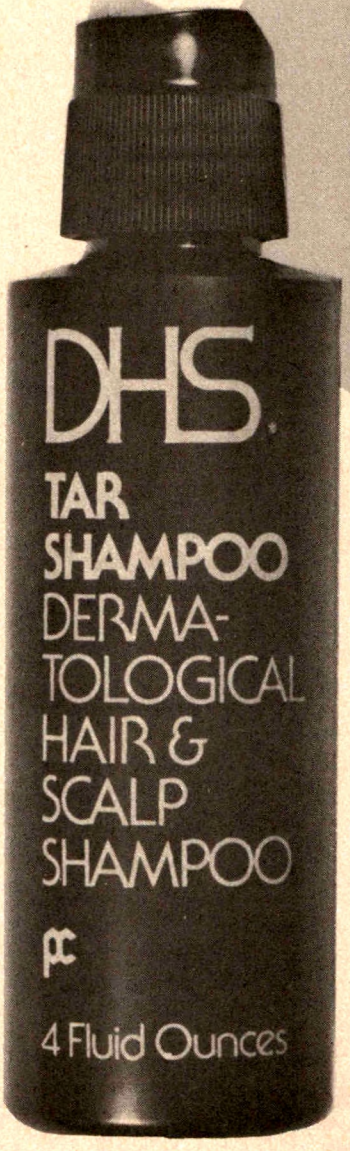

and then we tarred it!

neutral pH
no preservatives

*TM

PERSON & COVEY INC.

616 ALLEN AVE.,
GLENDALE, CA
91201

Woronoff's Rings With PUVA Therapy

Nicholas J. Lowe, MB, MRCP, Frank Bures, MD

A perilesional pale ring of skin that was seen during ultraviolet (UV) treatment of psoriatics was described by Woronoff in 1926.[1] Recent studies into the pathogenesis of Woronoff's ring (WR) phenomenon were conducted by Penneys et al[2] during coal-tar and UV-light treatment of psoriatics. A phenomenon similar to the Woronoff's rings (WR) was observed by us in a patient who was undergoing Psoralen and UVA (PUVA) therapy for psoriasis and this study was conducted to determine the frequency of WR in PUVA-treated psoriatics.

Patient Characteristics With PUVA-Induced Woronoff's Rings*

Group	No. of Treatments at Onset of WR	Mean Starting PUVA, joules/sq cm	No. of Cases With		
			Erythema	Pruritus	Skin Type
WR patients	2.67; range, 1-4	2.8; range, 2.5-3.5	Obvious, 2; minimal asymptomatic, 8	5	II:7 III:3
Non-WR patients	0	3.1; range, 2.5-3.5	Obvious, 2	1	II:4 III:6

*WR indicates Woronoff's rings.
†Skin types are classified according to response to sunlight. Skin type II indicates always burns, but sometimes tans; type III, sometimes burns, but always tans.

Patients and Methods

Twenty patients with psoriasis vulgaris were examined before and during PUVA treatment. The regimen followed that of Parrish et al in 1974.[3] Patients took methoxsalen capsules orally (0.6 mg/kg of body weight) two hours before treatment with long wavelength UV light irradiation. The lamps used were of two types—one with 48 and the other with 36 vertical lamp tubes. Each contained high output barium mesosilicate fluorescent tubes of 85 watts output. Energy emission was between 7.5 and 8.5 mW/sq cm. Initial UVA exposures depended on the patient's previous response to sunlight according to the schedule described.[3] Treatment was on alternate days; UVA energy increased by ½ joule at each treatment unless any undue erythema or pruritus developed.

Results

In ten of 20 psoriatic patients, obvious WR developed around psoriatic areas (Figure). The rings were approximately the same width (0.3 to 0.5 cm) regardless of the area of psoriatic plaque. Woronoff's rings developed after one of the first four treatments (mean onset, 2.67 treatments). The most frequent site of occurrence was the trunk; limbs were less commonly affected. Were it not for the presence of WR, asymptomatic erythema in nonpsoriatic skin would not have been noted in eight of the patients with WR. Onset of erythema and WR occurred about 48 hours after a PUVA treatment. Erythema developed in two of the patients in whom clinically obvious WR did not develop. Mild generalized pruritus was noted in six patients. In five of these pruritic patients WR developed. Pruritus did not appear to vary between involved and noninvolved skin. Tanning of WR was delayed compared with surrounding normal skin. Patient details are summarized in the Table. Results of UVA exposures were similar in WR and non-WR patients.

From the Department of Dermatology, University of Wisconsin Hospitals, Madison.
Reprints not available.

Comment

Penneys et al[2] used Goeckerman's treatment with coal tar and fluorescent light tubes that produced 80% of energy below 320 nm. The UVA lamps used in our study produced most of their energy above 320 nm (UVA range). Penneys et al[2] suggested that an inhibitor of prostaglandin (PG) synthesis diffused outward from psoriatic plaques and inhibited prostaglandin E_2 (PGE_2) formation in WR. Ultraviolet-induced erythema has been shown to be associated with increased skin levels of endogenous PG.[4,5] Recently Lord et al[6] showed that PG biosynthesis was stimulated by methoxsalen and UV irradiation at 360 nm. If WR are induced by the inhibition of PG synthesis,[2] then the observation of WR in some PUVA-treated patients would seem to support the conclusions of Lord et al[6] that the photosensitization from psoralen plus UVA may be a result of increased PG biosynthesis.

It remains puzzling, however, that indomethacin (an inhibitor of PG synthesis) has apparently no effect on PUVA erythema,[7] whereas it produces a reduction of UVB (290 to 320 nm) erythema.[7,8] Therefore, there is a difference between the results of biochemical studies of Lord et al and studies that use topical indomethacin. In summary, WR may be seen following different forms of phototherapy for psoriasis.

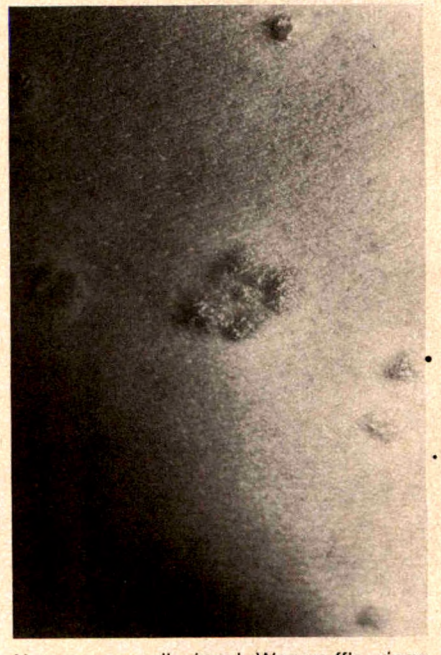

Numerous perilesional Woronoff's rings 48 hours after second PUVA treatment in patient with psoriasis.

Reference

1. Woronoff DL: Die periferen Veranderungen der Haut um die effloreszenzen der psoriasis

vulgaris und syphilis coryimbosa. *Dermatol Wchnschr* 82:249-257, 1926.

2. Penneys NS, Ziboh V, Simon P, et al: Pathogenesis of Woronoff ring in psoriasis. *Arch Dermatol* 112:955-957, 1976.

3. Parrish JA, Fitzpatrick TB, Tanenbaum L, et al: Photochemotherapy of psoriasis with oral methoxsalen and long wavelength ultraviolet light. *N Engl J Med* 291:1207-1211, 1974.

4. Greaves MW, Sondergaard J: Pharmacological agent released in ultraviolet inflammation studied by continuous skin perfusion. *J Invest Dermatol* 54:365-367, 1970.

5. Mathur GP, Ghandi VM: Prostaglandin in human and albino rat skin. *J Invest Dermatol* 58:291-295, 1972.

6. Lord JT, Ziboh VA, Poitier J, et al: The effects of biosynthesis and metabolism of prostaglandin. *Br J Dermatol* 95:397, 1976.

7. Morrison WL, Paul BS, Parrish JA: The effects of Indomethacin on long wave ultraviolet induced delayed erythema. *J Invest Dermatol* 68:120-123, 1977.

8. Snyder DS, Eaglestein WH: Topical Indomethacin and sunburn. *Br J Dermatol* 90:91-93, 1974.

Pseudoxanthoma Elasticum With Transepidermal Elimination

Robert Allen Schwartz, MD, MPH, Daniel F. Richfield, MD

Pseudoxanthoma elasticum (PXE) with transepidermal elimination was observed in a patient and diagnosed histologically in a single cutaneous plaque; it was the only manifestation of her disease. Recently, Lund and Gilbert[1] clearly established that most cases of coexistent PXE and elastosis perforans serpiginosa (EPS) are, in fact, perforating PXE. We suggest that all patients with apparent EPS or with solitary verrucous plaques be carefully examined for possible PXE.

Report of a Case

A 59-year-old woman was first seen in August 1975 for evaluation of a periumbilical hyperpigmented plaque (Fig 1). In about 1970, the patient first noted the asymptomatic lesion, which had not changed in size, color, or other characteristics since. No other lesions were present. She was hospitalized in 1968 for epistaxis; no cause was found. In 1971 during an admission for atrial fibrillation, fluoroscopy showed no intracardiac or coronary artery calcifications.

Her parents, three siblings, five children, and 12 grandchildren all reportedly have normal-appearing skin contour of their necks. One brother had hypertension; another was "born with cataracts." There is no history of parental consanguinity.

On examination, this mildly obese woman had a blood pressure of 188/112 mm Hg and strong peripheral pulses. Two centimeters above the umbilicus was a 2-cm sharply demarcated, hyperpigmented plaque with a fissured, verrucous surface from which no pus could be expressed. The skin of the neck, axilla, antecubital fossa, and inguinal area appeared normal. Results of an eye examination revealed a normal right eye, but a left eye with 2+ asteroid hyalosis and a small angioid streak. The maculae were normal.

Roentgenograms of the hands, forearms, skull, pelvis, and abdomen did not show soft tissue or vascular calcifications.

Pathologic Findings

The slightly acanthotic epidermis had a focal area of perforation with extrusion of altered elastic fibers (Fig 2). An adjacent section showed marked reduction in elastic fibers within its fibrous plaque, presumably due to transepidermal elimination. Verhoeff's stain showed these elastic fibers to be thick, short, and curled. They stained positively for calcium with von Kossa's stain and were positive for phosphotungstic acid-hematoxylin (PTAH) stain with a blue to violet coloration.

Comment

Pseudoxanthoma elasticum is a systemic disorder[2] with both dominant

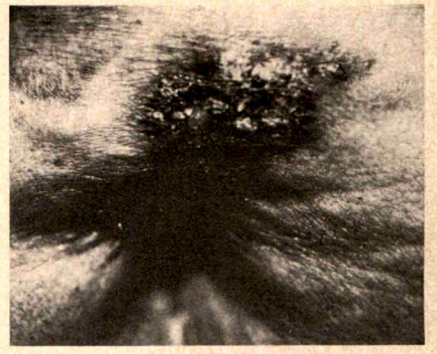

Fig 1.—Verrucous plaque above umbilicus.



Fig 2.—Pseudoxanthoma elasticum. Altered elastic fibers extrude to skin surface. Fibers are thick, short, and curled (Verhoeff's stain, ×50).

From the Departments of Dermatology (Drs Schwartz and Richfield) and Pathology (Dr Richfield), University of Cincinnati Medical Center. Dr Schwartz is now with the Department of Dermatology, Roswell Park Memorial Institute, Buffalo.

Reprint requests to Department of Dermatology, Roswell Park Memorial Institute, 666 Elm St, Buffalo, NY 14263 (Dr Schwartz).

and recessive autosomal forms,[3] which is aptly named for its characteristic xanthoma-like, pebbly lesions and its involvement of elastic tissue. One percent of the population may be carriers of the disease and have severe or premature degenerative vascular, ocular, and gastrointestinal disease.[4] Lund and Gilbert[1] recently reevaluated cases of coexistent PXE and EPS and concluded that seven of eight reports were suggestive if not diagnostic of PXE with associated perforating phenomenon. Their patient had a 14-cm hyperpigmented, verrucous periumbilical plaque. Graham and Hunter[5] reported a 17-year-old boy with an annular neck eruption that was characteristic of EPS clinically, but whose histopathologic features showed PXE. In the cases of PXE reported by Reed et al,[6] the PTAH stain was negative, which was attributed to elastic fiber calcification. The abnormal elastic fibers in our case, which were calcium-positive on von Kossa's stain, were PTAH-positive. Thus, our findings do not support the suggestion by Reed and colleagues[6] that PTAH may be useful in differentiating PXE from EPS; this is a function we think a calcium stain can well serve, since it is positive for PXE and negative for EPS.

Since EPS-like or verrucous lesions of transepidermal elimination may represent the only cutaneous sign of PXE, a potentially serious systemic disease, all cases of EPS should be carefully evaluated for possible PXE. Additionally, the possibility of PXE limited to one organ system, of which this is the first reported case, to our knowledge, deserves further consideration. Such limited disease could represent mosaicism, variable expressivity, or heterozygote expression and may include patients with premature myocardial infarctions and strokes.

References

1. Lund HZ, Gilbert CF: Perforating pseudoxanthoma elasticum. *Arch Pathol* 100:544-546, 1976.
2. McKusick VA: *Heritable Disorders of Connective Tissue*, ed 4. St Louis, CV Mosby Co, 1972, pp 475-520.
3. Pope FM: Two types of autosomal recessive pseudoxanthoma elasticum. *Arch Dermatol* 110:209-212, 1974.
4. Altman LK, Fialkow PJ, Parker F, et al: Pseudoxanthoma elasticum. *Arch Intern Med* 134:1048-1054, 1974.
5. Graham JH, Hunter GA: Perforating pseudoxanthoma elasticum, abstracted. *Arch Dermatol* 112:1781, 1976.
6. Reed RJ, Clark MH, Mihm MC: The cutaneous elastoses. *Hum Pathol* 4:187-205, 1973.

Macroglobulinemia Cutis

Rowan E. Tichenor, MD; Jerold M. Rau, MD; Frank A. Mantz, MD

Abnormal lymphoid cell infiltration, amyloid, and macroglobulin depositions have all been described in patients with Waldenström's macroglobulinemia. The liver, lymph nodes, spleen, kidneys, bone marrow, synovia, skeletal muscle, gastrointestinal tract, CNS, lungs, and skin have all been reported to be involved by these processes.[1,2] The purpose of this report is to describe a patient who had papular skin lesions of the knees that histologically resembled lichen amyloidosus, but on further study were found to be deposits of IgM.

Report of a Case

A 72-year-old man was initially seen at University of Kansas Medical Center in August 1970 with a chief complaint of "numbness of the legs" of three years' duration and a 20-lb weight loss. Results of laboratory studies showed a serum viscosity of 1.80, ESR of 25 mm/hr, a positive Sia water test, and an elevated gamma fraction without peaks on protein electrophoresis. Immunoglobulin assay showed an aberrant IgM precipitant band that was present at 37 C, but complexed with the agar base at 25 C. Ultracentrifugation showed a sharp peak that was compatible with a macroglobulin and comprised 13% to 18% of the total serum protein. Agar immunoelectrophoresis with specific IgM antiserum showed an aberrant IgM band. Bone marrow examination revealed greatly increased abnormal lymphoid cells and moderately increased plasma cells, eosinophils, and tissue basophils. Chlorambucil (4 mg by mouth daily) was instituted and the patient has been maintained on this regimen.

The patient was first seen by us on July 1, 1976 with a two-month history of a pruritic, erythematous, papulonodular eruption that was histologically confirmed to be a panniculitis with vasculitis. This eruption cleared rapidly with prednisone therapy and has not recurred.

A different asymptomatic eruption of pearly, flesh-colored, discrete, 2- to 4-mm papules that was confined to the knees was incidentally noted on the July 1 visit and persisted despite resolution of the panniculitis. Hematoxylin-eosin staining showed focal hyaline deposits in the papillary dermis at the dermoepidermal junction. These stained with Sirius red, but were not birefringent. Results of an immunofluorescent study with antisera (Hyland Biologics) of human IgG, IgM, complement (C3), and fibrinogen (filtrated to 1:20 dilution and with a protein fluorescence ratio of 8 μg/mg) revealed nodular foci of intense apple-green fluorescence with the antibody to IgM, which corresponds to the amorphous hyaline deposits. No such fluorescence was found with antisera to IgA, IgG, complement, or fibrinogen. Electron microscopy from the hyaline nodules showed fluffy, amorphous material deposited in the interstices but there was no evidence of amyloid fibrillae.

Comment

Previous reports have described IgM in the skin, but generally this was in association with tumor infiltrates in which the cellular morphology is consistent with Waldenström's macroglobulinemia. Meiers described a case in which the disease was apparently localized to skin tumors and in which a "significant gradient of the IgM macroglobulin from the skin tumor to the surrounding skin could be demonstrated."[3] Bureau et al described a large tumor of the skin that was composed of a massive cellular infiltrate of the dermis embedded in a gelatinous substance that was not studied, but it is very likely that it was IgM.[4]

D. M. MacDonald (St John's Hospital, London) studied various types of cutaneous amyloid and found immunofluorescence for immunoglobulins, light chains, and complement in "virtually all cases," that "do not interfere with the birefringence of the amyloid stained with Congo red." Also, "in the few cases in which electron microscopy was undertaken, amyloid fibrils could be demonstrated as well as immunoglobulins."[5]

Our patient appears to have papular skin lesions composed of macroglobulin without associated amyloid or cellular infiltration. The derivation of these deposits remains conjectural.

From the Sections of Dermatology, Department of Medicine (Drs Tichenor and Rau) and Pathology (Dr Mantz), University of Kansas Medical Center, Kansas City.

Reprint requests to 1940 E First St, Casper, WY 82601 (Dr Tichenor).

References

1. Bedine MS, Yardley JH, Elliott HL, et al: Intestinal involvement in Waldenström's macroglobulinemia. *Gastroenterology* 65:308-315, 1973.
2. Krajny M, Pruzanski W: Waldenström's macroglobulinemia: Review of 45 cases. *Can Med Assoc J* 114(10):899-905, 1976.
3. Meiers HG, Morbus Waldenström der Haut. *Deutsch Med Wschr* 93:1795-1800, 1968.
4. Bureau Y, Barrière H, Bureau B, et al: Les localisations cutanees de la macroglobulinemie de Waldenström. *Ann Dermatol Syphiligr* 95:125-137, 1968.
5. MacDonald DM: Immunofluorescence findings in lichen amyloedosus. *Br J Dermatol*, to be published.

Malignant Acanthosis Nigricans

Avigdor Leviatan, MD; Zeev Weshler, MD; Joseph Lowe, MB, ChB; Natalio Walach, MD

A woman had had acanthosis nigricans (AN) for six years before a diagnosis of carcinoma of the stomach was made. During the six months just prior to the discovery of the carcinoma, the AN had become severe, and, after chemotherapy and radiotherapy for the tumor, the AN showed regression.

Report of a Case

A 67-year-old woman was admitted to the hospital because of difficulty in swallowing liquid food, epigastric pain, general weakness, and loss of 8 kg of body weight during the last four months.

Six years prior to admission, hyperpigmentation, small papillomas, and roughened skin were noted in the axillae, groins, and under the breasts. Similar lesions appeared six months before admission on the buccal mucosa and gums, and the skin lesions began to itch. A gastric ulcer of the lesser curvature had been diagnosed previously and treated with a diet. In 1968 a cholecystectomy was performed.

On admission, a tender liver 2 cm below the costal margin was palpated, and there was epigastric tenderness. The skin in the areas of the axillae, groins, and under the breasts was dark brown, thickened, and scaly, with small, brown verrucose papillomas 0.3 × 1 cm in diameter and up to 2 cm in length, on a broad base (Fig 1). The skin had the appearance of velvet. The buccal mucosa and the lower gum showed diffuse pigmentation with similar papillomas (brown with roughened surface).

Histological examination of skin from the right groin and axilla demonstrated the presence of acanthosis, hyperpigmentation, and moderate papillomatosis, with a thin malpighian layer at the tips of the papillae, ie, changes typical of AN (Fig 2).

Radiography of the upper gastrointestinal tract indicated a filling defect in the area of the lesser curvature of the stomach that occupied an area from the antrum to the cardia, with a stricture in the area of the antrum.

From the Departments of Dermatology (Dr Leviatan), Oncology (Drs Weshler and Walach), and Orthopaedics (Dr Lowe), Hadassah-University Hospital, Jerusalem.

Reprint requests to Department of Dermatology, Hadassah-University Hospital, Jerusalem, Israel (Dr Leviatan).

Fig 1.—Axilla showing thickened, velvety skin and papillomas.

Fig 2.—Acanthosis, papillomatosis, and hyperkeratosis. Tips of papillae are covered by thin malpighian layer (hematoxylin-eosin, original magnification ×70).

Explorative laparotomy, carried out on Aug 31, 1975, demonstrated a carcinoma occupying the lesser curvature and posterior cardiac region of the stomach with local extension to the pancreas and omentum. The histologic diagnosis was adenocarcinoma (Fig 3) and in view of the extensive local spread, the abdomen was closed without further intervention. The postoperative course was uneventful. The patient received 3,000 rads of local radiotherapy and chemotherapy using ICRF 159, with subjective as well as objective improvement. The abdominal pains, swallowing difficulty, and the skin lesions all regressed. The hyperpigmentation and other changes in the buccal mucosa disappeared completely.

Comment

There are three known varities of AN: benign, pseudo, and malignant.[1] The likelihood of the association of tumor and malignant AN was estimated to be 100%,[2] although in some of these cases the tumor was discovered only at autopsy.[3]

The two other forms of AN are

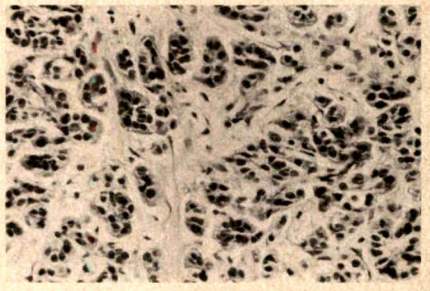

Fig 3.—Adenocarcinoma (hematoxylin-eosin, original magnification ×350).

connected with hormone disturbances, autosomal-dominant trait inheritance (benign AN), or abrasion of skin folds in dark-skinned people (pseudo AN).

Histologically, AN is characterized by papillomas interspersed by papillomatous areas of acanthosis and much hyperkeratosis, the rete ridges not being pronounced. The dark coloration is due mostly to hyperkeratosis and, in some cases, to increased melanin content. There is no way of histological differentiation between benign and malignant AN.[4]

Korting[5] attempted to differentiate between the benign and malignant forms of AN on clinical grounds, the malignant form being more diffusely distributed, appearing on the mucosae, having darker hyperpigmentation, and causing irritation. The phenomena appear after the age of 40 and tend to progress. Brown and Winkelmann[6] estimated the frequency of malignant tumors in AN as between 19.0% and 49.7%, while Curth found malignancies in all 17 patients with AN with long follow-up or by autopsies.

One cannot exclude AN as an early indication of future adenocarcinoma. The signs often disappear following radical surgical treatment of the tumor.[6]

As far as we know, no case has been described in the literature of regression of AN following radiochemotherapy without radical surgical treatment.

References

1. Curth HO: Significance of acanthosis nigricans. *Arch Dermatol* 66:80, 1952.
2. Curth HO: Malignant acanthosis nigricans. *Arch Dermatol* 102:479-482, 1970.
3. Curth HO, Hilberg AW, Machacek GF: The site and histology of the cancer associated with malignant acanthosis nigricans. *Cancer* 15:364-382, 1962.
4. Lever WH: *Metabolic diseases: Histopathology of the skin.* Philadelphia, JB Lippincott Co, 1975.
5. Korting GW: Acanthosis nigricans and pseudo-acanthosis nigricans: *Med Welt* 22:1221-1223, 1973.
6. Brown J, Winkelmann RK: Acanthosis nigricans: A study of 90 cases. *Medicine* 47:33-51, 1968.

Macular Bowen's Disease

Dennis A. Weigand, MD

In the major textbooks, it is rarely indicated that Bowen's disease may be anything but a scaly or crusted plaque, which implies an elevated lesion. Diseases listed in differential diagnoses are seldom those that may be macular. Also, little is said about what difference might exist between early and long-standing lesions.[1-11] We report early, macular Bowen's disease in order to emphasize an apparently unusual clinical presentation.

Report of a Case

A 30-year-old man had a lesion of three months' duration on the right index finger. Further history disclosed no symptoms nor any other disease, except for a recurrent verruca plantaris. There was no history of exposure to arsenic. The patient was a hospital executive of medium complexion, with little actinic damage. On the dorsum of the finger was an 8- by 9-mm, sharply defined, erythematous macule (Fig 1).

Histological examination showed that the tissue had been sectioned diagonally, as indicated by dermal papillae apparently within the epidermis. Therefore it was uncertain whether there was acanthosis. However, the uppermost dermal papillae were quite close to the stratum granulosum, and the relative thickness of the stratum malpighii and stratum corneum were approximately normal, which suggests that the epidermal thickness was close to normal limits. The findings were otherwise characteristic of Bowen's disease, viz, dysplastic cells, mitotic figures, and single-cell keratinization scattered throughout the stratum malpighii; cytoplasmic vacuolization in the upper stratum malpighii; and a distinct dermoepidermal junction (Fig 2).

The lesion was treated by curettement and fulguration. One year later, a recurrence at the proximal margin was treated similarly. Examination another year later revealed a flat, pliable scar.

Comment

Macular Bowen's disease is apparently unusual, judging from well-known sources of information.[1-11] The basis for this clinical variation is uncertain. Bowen's disease on the finger is usually described as scaly and/or verrucose. This case may represent the usual appearance of a very early lesion in which scale has not yet appeared. In a series of 35 patients with Bowen's disease, Graham and Helwig found the duration, from onset to surgery, to range from five months to 30 years.[12] Most discussions of Bowen's disease say little or nothing about changes in clinical characteristics with time, except that invasive squamous cell carcinoma may develop.

Diagonal sectioning made it impossible to assess epidermal thickness accurately in this case. However, the proximity of dermal papillae to stratum granulosum suggests that suprapapillary epidermal thickness was not increased.

Fig 1.—Erythematous, well-circumscribed macule on dorsum of index finger.

Fig 2.—Dyskeratotic cells, vacuolization, and mitotic figures in epidermis (hematoxylin-eosin, original magnification ×100).

From the Department of Dermatology, University of Oklahoma Health Sciences Center and Veterans' Administration Hospital, Oklahoma City.

Reprints not available.

References

1. Sutton RL Jr: *Diseases of the Skin*, ed 11. St Louis, CV Mosby Co Publishers, 1956, p 1193.
2. Ormsby OS, Montgomery H: *Diseases of the Skin*, ed 8. Philadelphia, Lea & Febiger Publishers, 1954, pp 844-846.
3. Pillsbury DM, Shelley WB, Kligman AM: Tumors of the skin, in *Dermatology*. Philadelphia, WB Saunders Co, 1956, p 1162.
4. Domonkos AN: Epidermal nevi and tumors, in *Andrews' Diseases of the Skin*, ed 6. Philadelphia, WB Saunders Co, 1971, p 775.
5. Sanderson KV: Tumors of the skin, in Rook A, Wilkinson DS, Ebling FJG (eds): *Textbook of Dermatology*, ed 2. Philadelphia, FA Davis Co, 1972, pp 1962-1964.
6. Pinkus H: Epithelial neoplasms and precancerous lesions, in Fitzpatrick TB, Arndt KA, Clark WH Jr, et al: *Dermatology in General Medicine*. New York, McGraw-Hill Book Co, 1971, pp 402-403.
7. Everett MA: Bowen's disease, in Demis DJ, Dobson RL, McGuire J (eds): *Clinical Dermatology*. Hagerstown, Md, Harper & Row Publishers, 1976, vol 4, unit 21-14, p 3.
8. Caro WA: Tumors of the skin, in Moschella SL, Pillsbury DM, Hurley HJ (eds): *Dermatology*. Philadelphia, WB Saunders Co, 1975, pp 1338-1339.
9. Lever WF, Schaumburg-Lever G: *Histopathology of the Skin*, ed 5. Philadelphia, JB Lippincott Co, 1975, pp 473-475.
10. Graham JH, Helwig EB: Premalignant cutaneous and mucocutaneous disease, in Graham JH, Johnson WC, Helwig EB (eds): *Dermal Pathology*, ed 1. Hagerstown, Md, Harper & Row Publishers, 1972, pp 581-584.
11. Montgomery H: *Dermatopathology*, New York, Harper & Row Publishers, 1967, pp 968-969.
12. Graham JH, Helwig EB: Bowen's disease and its relationship to systemic cancer. *Arch Dermatol* 80:133-159, 1959.

There are two faces of severe acne vulgaris

Right profile of patient with Grade IV acne after 6 weeks of tetracycline therapy.

BEFORE adjunctive

MINOCIN®

MINOCYCLINE HCl

CAPSULES 50 mg and 100 mg
SYRUP 50 mg/5 ml

200 mg initially, 100 mg *b.i.d.* or
100 or 200 mg initially, 50 mg *q.i.d.*

MINOCIN Minocycline HCl
Oral and Intravenous Brief Summary

Contraindications: Hypersensitivity to any tetracycline.

Warnings: Intravenous use, particularly in pregnancy, in daily doses exceeding 2 grams has been associated with deaths through liver failure. When need for intensive treatment outweighs potential dangers, perform renal and liver function tests before and during therapy; also follow serum concentrations. In renal impairment, usual doses may lead to excessive accumulation and liver toxicity. Under such conditions, use lower total doses, and, in prolonged therapy, determine serum levels. This hazard is of particular importance in I.V. use in pregnant or postpartum patients with pyelonephritis. In such cases, the blood level should not exceed 15 mcgm/ml, and liver function tests should be made at frequent intervals. Do not prescribe other potentially hepatotoxic drugs concomitantly. The use of tetracyclines during tooth development (last half of pregnancy, infancy and childhood to the age of 8 years) may cause permanent discoloration of the teeth (yellow-gray-brown). This is more common during long-term use but has been observed following repeated short-term courses. Enamel hypoplasia has also been reported. Tetracyclines, therefore, should not be used in this age group unless other drugs are not likely to be effective or are contraindicated. Photosensitivity manifested by an exaggerated sunburn reaction has been observed in some individuals taking tetracyclines. Advise patients apt to be exposed to direct sunlight or ultraviolet light that such reaction can occur, and discontinue treatment at first evidence of skin erythema. Studies to date indicate that photosensitivity is rarely reported with MINOCIN *Minocycline HCl*. In patients with significantly impaired renal function, the antianabolic action of tetracycline may cause an increase in BUN leading to azotemia, hyperphosphatemia, and acidosis. CNS si effects (lightheadedness, dizziness, vertigo) have been reported, ma disappear during therapy, and always disappear rapidly when drug is discontinued. Caution patients who experience these symptoms about driving vehicles or using hazardous machinery while taking th drug. **Pregnancy:** In animal studies, tetracyclines cross the placenta are found in fetal tissues, and can have toxic effects on the developi fetus (often related to retardation of skeletal development). Embryotoxicity has been noted in animals treated early in pregnancy. **Newborns, infants and children:** All tetracyclines form a stable calcium complex in any bone-forming tissue. Prematures, given oral doses o 25 mg./kg. every 6 hours, demonstrated a decrease in fibula growth rate, reversible when drug was discontinued. Tetracyclines are prese in the milk of lactating women who are taking a drug in this class.

(cont

There are two faces of severe acne vulgaris

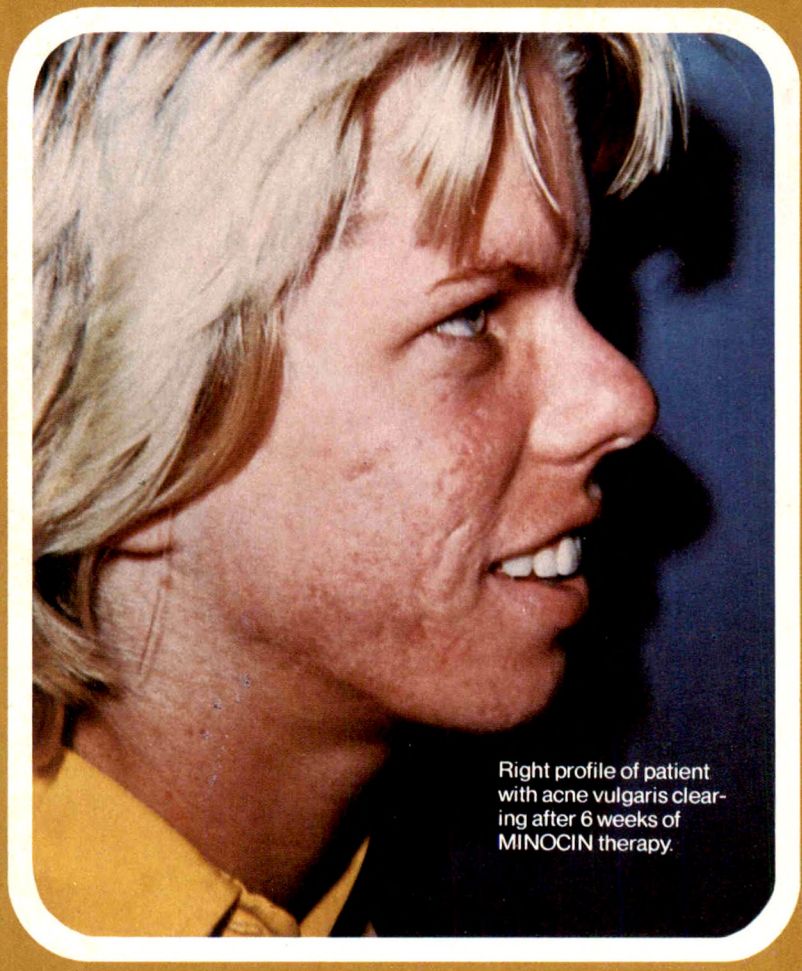

AFTER adjunctive MINOCIN® MINOCYCLINE HCl

CAPSULES 50 mg and 100 mg
SYRUP 50 mg/5 ml

200 mg initially, 100 mg *b.i.d.* or
100 or 200 mg initially, 50 mg *q.i.d.*

MINOCIN Minocycline HCl
Oral and Intravenous Brief Summary (continued)

Precautions: Use may result in overgrowth of nonsusceptible organisms, including fungi. If superinfection occurs, institute appropriate therapy. In veneral diseases when coexistent syphilis is suspected, darkfield examination should be done before treatment is started and blood serology repeated monthly for at least four months. Patients on anticoagulant therapy may require downward adjustment of such dosage. Test for organ system dysfunction (*e.g.*, renal, hepatic and hemopoietic) in long-term use. Treat all group A beta-hemolytic streptococcal infections for at least 10 days. Avoid giving tetracycline in conjunction with penicillin.

Adverse Reactions: GI: (with both oral and parenteral use): anorexia, nausea, vomiting, diarrhea, glossitis, dysphagia, enterocolitis, inflammatory lesions (with monilial overgrowth) in anogenital region. **Skin:** maculopapular and erythematous rashes. Exfoliative dermatitis (uncommon). Photosensitivity is discussed above ("Warnings"). **Renal toxicity:** rise in BUN, dose-related (see "Warnings"). **Hypersensitivity reactions:** urticaria, angioneurotic edema, anaphylaxis, anaphylactoid purpura, pericarditis, exacerbation of systemic lupus erythematosus. In young infants, bulging fontanels have been reported following full therapeutic dosage, disappearing rapidly when drug was discontinued. **Blood:** hemolytic anemia, thrombocytopenia, neutropenia, eosinophilia. **CNS:** (see "Warnings"). When given in high doses, tetracyclines may produce brown-black microscopic discoloration of thyroid glands; no abnormalities of thyroid function studies are known to occur.

NOTE: Concomitant therapy: Antacids containing aluminum, calcium, or magnesium impair absorption; do not give to patients taking oral minocycline. Studies to date indicate that absorption of MINOCIN *Minocycline HCl* is not notably influenced by foods and dairy products.

CNS side effects including light-headedness, dizziness, or vertigo have been reported with MINOCIN. Patients who experience these symptoms should be cautioned about driving vehicles or using hazardous machinery while on minocycline therapy.

Lederle
LEDERLE LABORATORIES
A Division of American Cyanamid Company
Pearl River, N.Y. 10965

Printed in U.S.A.

November 1977

410-8

10% Urea Lotion

For simple dry skin: *10% urea* to hydrate dry skin not complicated by hyperkeratosis. Moisturizes and lubricates, relieves the itching of dry skin due to aging, sun or cold weather, soap or detergents. *Lotion base* for total body dry skin care.

vive la différence!

20% Urea Cream

For hyperkeratotic dry skin: *20% urea* to soften and smooth thick, scaly skin in such conditions as ichthyosis, keratosis pilaris, keratosis palmaris et plantaris. *Cream base* for localized application. Especially useful for hands, elbows, knees and heels.

Ingram Pharmaceutical Company,
San Francisco, CA 94111

©IPC, 1977

Letters to the Editor

Readers are advised that in view of The Copyright Revision Act of 1976, *all Letters to the Editor submitted for publication must contain on the transmittal letter the following language: "The person(s) undersigned hereby grant the American Medical Association permission to publish this Letter and in addition, hereby assigns all copyright ownership therein to the AMA."*

Menthol and Dermatitis

To the Editor.—A 25-year-old woman was recently seen with a chronic dermatitis of the upper lip, which had been treated previously in several ways. I suggested she change her toothpaste and temporarily discontinue the many types of citrus fruit contact that she had. I recently read of a patient who had been found to have chronic urticaria due to the menthol in his cigarettes. I suggested to the patient that she also discontinue her menthol cigarettes temporarily as a trial. She did this, and her dermatitis immediately cleared. After several weeks, she performed a challenge test by resuming the menthol cigarettes, and immediately the dermatitis recurred. Since discontinuing the offending cigarettes again, her condition has remained completely clear.

BRUCE B. CHRISMAN, MD
Honolulu

Trichilemmoma

To the Editor.—Trichilemmoma as a term and concept has had considerable attention in the recent medical literature.[1-4] A diagnosis by that term is now frequently made by many histopathologists, but rarely, if ever, by clinicians. In 1973, Brownstein and Shapiro[5] wrote that "the correct clinical diagnosis was not mentioned in any case in this series (or 40 cases), and we could find no record of trichilemmoma ever having been recognized before biopsy." Goldman and Richfield[2] recently pondered the course of so-called trichilemmoma, asking: "Why does it spread so rapidly sometimes, suggesting a viral infectious agent."

I have an explanation of the phenomenon that I would like to propose to dermatopathologists and clinical dermatologists, namely, that what is now called trichilemmoma by some or most dermatopathologists is nothing more than an old verruca vulgaris, generally on the face, in which the virus has affected the epithelial cells of the upper portion of a hair follicle and the epidermis. What is the evidence for such a possibility? In several of those recent reports about trichilemmoma, a frequent clinical diagnosis cited has been "verruca vulgaris"[5]; in some "a filiform appearance was appreciated clinically"[6]; and in still others, the appearance of lesions of the condition in point is described as "that of small papular warts of even lichen nitidus."[2] Histologically, to my eye, almost every photomicrograph in every article about trichilemmoma is what we in our laboratory see several times daily and diagnose as "verruca vulgaris, old." Several of the lesions I had previously signed out as old warts, Brownstein et al[4] in reviewing them for a paper on Cowden's disease labeled as trichilemmoma. In their histological description of trichilemmoma, Ingrish and Reed[6] wrote that "the hypergranulosis may be prominent and resembles that seen in old lesions of verruca vulgaris;" Brownstein and Shapiro[5] commented that "some lesions of trichilemmoma were frequently verrucous in configuration" and "focally the stratum granulosum was often coarsely granular, resembling a viral wart." What more is needed to establish morphological identity? The absence of viral particles by electronmicroscopy is an expected finding in old verruca.

Several authors remark about the clinical and histological overlap between trichilemmoma and inverted follicular keratosis. For example, Ingrish and Reed[6] write that "the location and overall configuration of trichilemmomas are remarkably similar to those of inverted follicular keratosis." Headington[1] says "verruca vulgaris is a common clinical diagnosis for inverted follicular keratosis" and "differentiation (of trichilemmoma) from the so-called irritated seborrheic keratoses (inverted follicular keratoses) may be difficult." Even Brownstein and Shapiro[5] record that the "clinical diagnosis (of inverted follicular keratosis) is often viral wart," that "overlapping forms occur" with trichilemmoma, and that "trichilemmoma . . . may be indistinguishable from inverted follicular keratosis."

My opinion about inverted follicular keratosis (which is mostly an extroverted rather than an inverted lesion) is similar to that about trichilemmoma. That is, for the latter nearly all are warts and for the former, most are warts and the rest seborrheic keratoses.

A. BERNARD ACKERMAN, MD
New York City

1. Headington JT: Tumors of the hair follicle. *Am J Pathol* 85:480-505, 1976.
2. Goldman L, Richfield DF: Trichilemmoma clinical lesions. *Arch Dermatol* 113:107-108, 1977.
3. Brownstein MH, Shapiro L: The pilosebaceous tumors. *Int J Dermatol* 16:340-352, 1977.
4. Brownstein MH, Mehregan AH, Bikowski JB: Trichilemmomas in Cowden's disease. *JAMA* 238:26, 1977.
5. Brownstein MH, Shapiro L: Trichilemmoma: Analysis of 40 new cases. *Arch Dermatol* 107:866-869, 1973.
6. Ingrish FM, Reed RJ: Trichilemmoma. *Dermatologica Internationalis* 7:182-190, 1968.

Cutaneous and Urinary Complications of Central Umbilical Artery Injection

To the Editor.—V. E. Cutler and G. S. Stretcher (ARCHIVES 113:61-63, 1977) reported a case of unilateral cutaneous necrosis of the buttock of an infant after catheterization of the umbilical artery.

We had the occasion to observe a similar incident with a newborn infant who had mistakenly received directly, via the umbilical artery, a hypertonic solution (Figure). A skin biopsy specimen, carried out eight days after the injection, showed an extensive calcification at the level of the lesions. These calcium deposits were observed in the papillary dermis at the dermoepidermal junction, where there existed in some parts an abscess formation around the sweat glands and the hair follicles and in the adipose subcutaneous tissues. Twelve

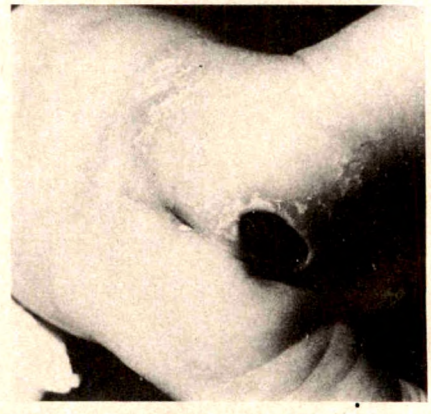

Infant's buttock eight days after the direct umbilical artery injection.

days after the injection, urography showed a ureterohydronephrosis on the right side with a shelled calcification of the bladder.

The cutaneous lesions healed in a period of about 1½ months. Six months after the initial accident, the upper urinary tract on the right side had regained its normal appearance. On the other hand, the calcifications of the trigone persisted.

This case leads us to make several comments:

(1) In our patient, the umbilical artery was not catheterized. The direct injection of the hypertonic solution had probably provoked an arterial spasm with secondary thrombosis.

(2) Serious visceral complications that involve the kidney and the bladder can arise after direct injection into the umbilical artery. Cases of necrosis of the bladder and of the rectum with secondary stenosis were expected in such circumstances.[1]

(3) Finally, the pathogenesis of cutaneous and visceral calcifications that are spontaneously regressive merits discussion. In our case, the injected solution contained no calcium salt. It is likely that several factors came into play. The special constitution of the subcutaneous tissue of the newborn infant probably represents a favorable setting for the formation of calcium deposits. In fact, spontaneously regressive subcutaneous calcinoses secondary to local infusions are often observed in neonatal intensive care.[2] The modifications of the tissue pH, the vascular and perivascular lesions with extravasation of irritant hypertonics, and infection can also be responsible for this phenomenon.

Such cases serve to point out the potential danger that may accompany the use of the arterial-umbilical passage; its use should be limited to cases of strict necessity.

JEAN-PAUL ORTONNE, MD
RENÉ JEUNE, MD
PIERRE SOUTEYRAND, MD
JEAN THIVOLET, MD
Lyon, France

1. Dodat H, Putet G, Pouillarde JA, et al: Complications urinaires de l'injection intra-artérielle ombilicale chez le nouveau-né : Commentaires précoces à propos de 3 observations. *Ann Chir Infant* 18:85-95, 1977.

2. Osty M: *Calcinoses sous-cutanées régressives localisées au territoire des perfusions au cours de la réanimation néo-natale*, thesis, Clermont-Ferrand, France 1977.

An Unusual Case of Suntanning

To the Editor.—This letter describes a patient who came to our clinic and whose condition posed an interesting gamut of differential diagnostic possibilities. This case again points out the importance of a good clinical history.

Fig 1.—Hyperpigmented annular lesions.

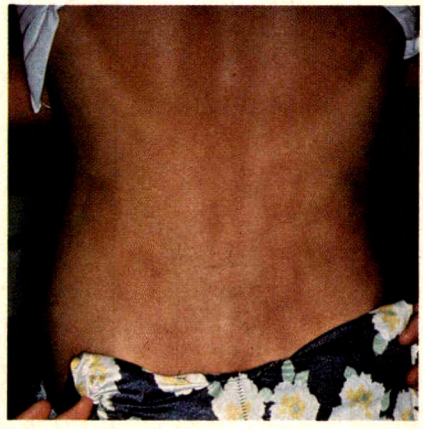

Fig 2.—White flowered areas coinciding with pigmented lesions.

Report of a Case.—In August 1976, a 13-year-old girl came to the Dermatology Clinic (Fort Sam Houston, Tex) complaining of large "spots" on her trunk. The eruption had begun approximately three months before and involved only the skin over the lumbosacral area. The lesions had progressed, spreading outward around the trunk, and were appearing on the lateral borders of her abdomen.

There were multiple solitary and grouped macules 4 to 5 cm in diameter with neither a palpable nor scaly border that were limited to the nonsun exposed area (Fig 1).

Initial differential diagnoses included erythema dyschromicum perstans, gyrate erythema tinea versicolor, inactive fixed drug eruption, leprosy, pinta, and poikiloderma.

On further questioning, the patient stated that the lesions were more noticeable after swimming and that her bathing suit was dark with light flowers. The next day the patient returned with her swimming suit and the light-colored fabric coincided with the clinical lesions (Fig 2). The white petals of the flowers allowed tanning through the fabric while the dark background and bright yellow flower centers blocked out the ultraviolet rays.

Comment.—It is well known that clothing reflects or absorbs light, depending on color. It should again be emphasized that some white fabrics, especially when wet, can transmit ultraviolet light,[1,2] thus producing this unusual pigmentary pattern in our patient.

CAPT GENE P. REAM, MC, USA
LT COL RICHARD L. DEVILLEZ, MC, USA
Fort Sam Houston, Tex

1. Daniels F: Physical factors in sun exposure. *Arch Dermatol* 85:358-361, 1962.

2. Willis I: Photosensitivity, in Moschella SL, Pillsbury DM, Hurley HJ Jr (eds): *Dermatology*. Philadelphia, WB Saunders Co, 1975, p 326.

Glittering With Gold Therapy

To the Editor.—With the increasing use of gold in the treatment of rheumatoid arthritis, and possibly in pemphigus,[1] an increasing incidence of dermatological complications of gold therapy may be expected. This letter describes a previously unreported drug reaction to gold.

As described by other authors, the spectrum of dermatological complications of gold therapy ranges from the blue-grey-purple lesions of exposed skin the chrysiasis to the nondiagnostic macular, papular, erythematous rashes that are the most common form of skin eruption in chrysotherapy.[2] Classifiable skin eruptions that are due to gold therapy include lichen planus-like and pityriasis rosea-like lesions, urticaria, erythema nodosum, exfoliative dermatitis, seborrheic dermatitis, erythema multiforme, pemphigus-like lesions, alopecia, granuloma annulare, and psoriasiform eruptions.[2-4]

A careful search of the literature has failed to reveal any previous report of a patient in whom the skin complication of chrysotherapy manifested itself as actual "glittering" of the skin. The patient we describe is, to the best of our knowledge, the first reported case of glittering that was due to chrysotherapy.

Report of a Case.—A 52-year-old woman had a ten-year history of seropositive rheumatoid arthritis that involved the proximal interphalangeal and metacarpophalangeal joints of both hands, knees, the left shoulder, and the metatarsals. The arthritis was accompanied by morning stiffness, pain on motion, and swelling and tenderness of the joints mentioned. The patient denied having had contact with gold-containing objects and claimed to have used the same brand of facial makeup for the past five to seven years. The patient had received approximately 50 mg/mo (total dose, 4,730 mg) of gold sodium thiosulfate, followed by 50 mg/mo (total dose, 350 mg) of gold sodium thiomalate. She came to us with a recent onset of asymp-

Glittering of gold on right third finger.

tomatic, but clearly visible, glittering of the forehead and both palms (Figure). Results of clinical examination of the remainder of the skin, the oral mucosa, the hair, and the nails were normal.

A sample of the glittering material of the right palm was obtained on filter paper and, with a normal filter paper control, was analyzed by instrumental neutron activation.

The samples, plus comparator standards, were irradiated for 30 minutes in a nuclear reactor at a flux of 1.8×10^{12} neutrons/sq cm/sec. After a decay of four days, the samples were counted on a detector coupled to a multichannel γ-ray spectrometer. The element gold produces gold Au 198, which has a half-life of 3,888 minutes. Filter paper normally contains some gold and therefore, gold was detected in both samples.

Comment.—In our investigation, the normal filter paper control showed 0.00731 ± 0.00078 μg of gold, while the sample from the patient showed 0.0154 ± 0.0011 μg of gold; this difference was considered to be an important indication that gold was present on the skin surface of our patient.

STEVEN R. KOHN, MD
LAWRENCE J. DENSON, MD
New York City

Westwood Pharmaceuticals, Inc, Buffalo, aided in defraying the cost of publishing the color illustration.

1. Penneys NS, Eaglstein WH, Frost P: Management of pemphigus with gold compounds: A long-term follow-up report. *Arch Dermatol* 112:185-187, 1976.
2. Penneys NS, Ackerman AB, Gottlieb NL: Gold dermatitis: A clinical and histopathological study. *Arch Dermatol* 109:372-376, 1974.
3. Bogg A: Skin complications of gold treatment. *Acta Rheum Scand* 4:86-97, 1958.
4. Bluhm GB: The treatment of rheumatoid arthritis with gold. *Semin Arthritis Rheum* 5:147-166, 1975.

Pseudoxanthoma Elasticum

To the Editor.—In describing techniques of autofluorescence, Sams[1] refers to three types of fluorescence. There is specific immunologic staining, nonspecific staining, and autofluorescence. Autofluorescence occurs in many tissues including the skin.

Fig 1.—Close-up of lesions on neck.

Sams noted the autofluorescence of elastic fibers in dermis, and we have reported autofluorescence in epidermis corresponding to the location of melanin.[2,3]

Specific immunologic staining has been used since Beutner et al[4] in 1965 described the presence of specific autoantibodies in serums of patients with pemphigus. Little has been described on autofluorescence findings related to pathological skin conditions.

We report a case of pseudoxanthoma elasticum in which autofluorescent findings highlight features of the skin pathology. Pseudoxanthoma elasticum is an autosomal recessive hereditary disease in which genetically abnormal elastic fibers tend to calcify in the skin, oral mucosa, and eyes. This patient, a 49-year-old woman, had characteristic lesions of a loose, "pebbly" texture and thickened skin, yellow in color, on the neck, groin, and elbows. Figure 1 is a close-up of lesions on the neck.

A hematoxylin-eosin stained section showed the typical irregularly clumped and confluent fibers staining darkly in the lower two thirds of the dermis, in contrast to smooth, discrete fibers higher in the dermis (Fig 2). An unstained section was examined with the fluorescent microscope. The tissue was handled according to procedures described by Sams[1] and Fellner.[2] Fluorescent light was filtered with a BG 3 exciter filter, which has maximal emission in the range from 300 to 480 nm, and with a No. 50 barrier filter that blocks wavelengths shorter than 500 nm.

Examined in this way, smooth, discrete elastic fibers of the upper one third of the dermis emitted a normal, pale yellow-green antofluorescence. The affected area of lower dermis contained elastic fibers emitting bright green autofluroescence with

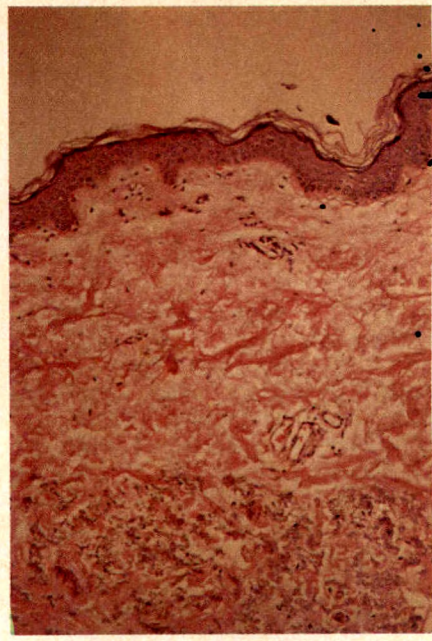

Fig 2.—Typical, irregularly clumped and confluent fibers staining darkly in lower two thirds of dermis, in contrast to smooth, discrete fibers higher in dermis (hematoxylin-eosin).

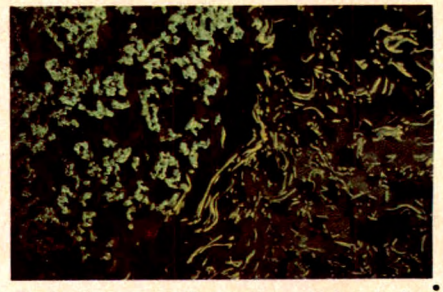

Fig 3.—View of both portions of dermis for comparison.

clumped and irregular shapes. Figure 3 includes a view of both portions of dermis for comparison.

This is the first report of autofluorescence findings associated with pseudoxanthoma elasticum. We think it suggests further possibilities of the use of this type of fluorescence in the search for characteristic features of many skin diseases.

MICHAEL J. FELLNER, MD
AMELIA SU-HUI CHEN
JONATHAN B. MCCABE
New York

1. Sams WM: Pemphigus and pemphigoid, in Fry L, Seah PP (eds): *Immunological Aspects of Skin Diseases*. New York, John Wiley & Sons Inc, 1974 p 10.
2. Fellner MJ: Green autofluorescence in human epidermal cells. *Arch Dermatol* 112:667-670, 1976.
3. Fellner MJ, et al: Patterns and intensity of autofluorescence in human epidermis, abstracted *J Clin Res* 1977, p 182.
4. Beutner EH, Lever WF, Witebsky E, et al: Autoantibodies in pemphigus vulgaris. *JAMA* 192:682-688, 1965.

Nike Training Shoe Dermatitis

To the Editor.—I have become aware in the past year of a new and apparently highly potent source of contact allergy that threatens many of those individuals caught up in the current jogging craze. In a relatively limited consultation practice at the University of Oregon, Health Sciences Center, Portland, I have identified three individuals who are highly allergic to an insole component prepared by Spenco Medical Corporation and used in Nike athletic shoes. This component is easily identified by its bright blue nylon covering that overlies a black neoprene foam pad and covers the entire inner sole area of the shoes. We have traced this allergy to the adhesive that binds the nylon to the neoprene. Patients show no reaction to the neoprene itself, the nylon, the blue dye, nor to any of a complete series of chemicals that have been previously incriminated in shoe contact allergy.

Patients come in with a diffuse plantar dermatitis and in each of the three cases testing with the cured adhesive has produced a considerable flare reaction not only on the feet but also on other areas of the body. Presentation of these cases at a local dermatological conference revealed that the majority of practitioners present had seen one or more cases of Nike training shoe dermatitis in their practices recently. It would seem advisable to alert readers of the ARCHIVES to this potentially highly allergenic source of shoe dermatitis. It should be noted that the offending inner sole material may also be used in the manufacture of certain "wet suits" and, hence, dermatitis may potentially be seen from this source.

We are currently testing chemical components of the allergenic adhesive to identify the exact chemical responsible for these severe allergic reactions. Since learning of the problem, Spenco and Nike have developed and incorporated a new insole that does not cause reactions in our sensitive patients.

JON M. HANIFIN, MD
Portland, Ore

Dermatology Patient Visits in the Military

To the Editor.—We wish to report statistical data from the military population of San Antonio, Tex, that support the conclusion of the manpower study group, ie, that there will be a need for an increase in the number of dermatologists if free access to dermatologic care is instituted (ARCHIVES 113:903-905, 1977). The military has a free-access health care program not only for its active duty personnel but for those retired and all dependents. San Antonio has a total population eligible for military dermatologic care estimated between 250,000 to 300,000. There are two dermatology clinics, Brooke Army Medical Center and Wilford Hall USAF Medical Center, that last year treated a total of 59,000 outpatients. This is a ratio of from 230 to 197 per 1,000 population. This compares to a ratio of 84 per 1,000 for the general population and 193 per 1,000 for civilian prepaid group practices.

LT COL RAYMOND L. GARCIA, MC, USAF
COL CHARLES W. LEWIS, MC, USA
San Antonio, Tex

Graft-vs-Host Reaction

To the Editor.—I must take exception to the statement that Grogan and Odom make in their article titled "Graft-vs-Host Reaction" in the ARCHIVES (113:806-812, 1977). They state: "We now prefer the term 'satellite cell necrosis' (SCN), as it is both descriptively accurate and concise."

Although it may be concise, I do not think that this term is an accurate description of the pathological process in the graft-vs-host reaction. One unfamiliar with this unique histopathological picture would envision necrosis of satellite cells in interpreting the term SCN. Furthermore, this term does not really furnish any information about just what these "necrotic satellites" are revolving around, causing the reader himself to turn in circles of confusion.

"Focal cellular necrosis with lymphocytic satellitosis" would be a more accurate description of the histopathological pattern seen in the acute graft-vs-host reaction. We must try to say just what we mean in medicine, especially in a field like dermatology that relies so heavily on the use of language itself.

JOSEPH M. SCHERZER, MD
Scottsdale, Ariz

Destructive Scalp Alopecia in Psoriasis

To the Editor.—Destructive scalp alopecia in psoriasis is not an easy concept to accept. However, I have a child with chronic psoriasis under my care with the condition.

Report of a Case.—A boy, aged 11, attending a boarding school, came to my clinic in October 1976 with widespread plaqued psoriasis, the scalp and hairline being particularly caked so that the scalp was barely visible through the enveloped hair. According to his mother, he had had a diaper area eruption when 2 months old that cleared when he stopped wearing diapers, and then his skin remained clear until the age of 5 years. At that time, psoriasis appeared first over the buttocks and then spread from that site; the skin had not been free of eruption since that time. Scalp scaling had been present for two years.

A nonsteroid-containing coal tar application and a tar shampoo to be used on the scalp were prescribed and he was treated as an outpatient. He next came to the clinic in May 1977 at which time the scalp psoriasis had responded well. However, two areas of alopecia showing atrophic skin and follicular destruction (scarring alopecia) were visible over the anterior scalp; no active inflammation was visible clinically. A skin biopsy specimen from a bald area showed an atrophic epidermis and no appendages; the dermis contained dense collagen and a sparse lymphoreticular infiltrate. Dr T. W. Stewart reported the appearances as those of a scarred alopecia with no evidence to determine its origin.

Comment.—Shuster[1] emphasized that psoriasis can cause a true destructive alopecia and the aforementioned case report shows this complication.

JULIAN VERBOV, MD, MRCP
Liverpool, England

1. Shuster S: Psoriatic alopecia. *Br J Dermatol* 87:73-77, 1972.

IgE Levels in Various Dermatoses

To the Editor.—We read with great interest the results of O'Loughlin et al concerning IgE in atopic dermatitis and dermatosis (ARCHIVES 113:309-315, 1977). For four years we have performed more than 900 radioimmunosorbent tests in various dermatoses. We consider a value of IgE above 400 IU/ml to be pathological.

Of 70 cases of atopic dermatitis, we found increased IgE levels in 71% of the patients. Spearman and Kendall's test shows an important relationship involving sex (higher level in man), age of onset of the disease, and anatomic extent, but no relationship was found involving age, other allergic diseases, or blood eosinophilia.

Increased IgE levels are seen in bullous pemphigoid, mycosis fungoides, and systemic lupus erythematosus. There is no notable change in localized neurodermatitis, contact dermatitis, nonspecific dermatitis,

chronic urticaria, psoriasis, dysidrosis, ulcus cruris, scabies, systemic sclerosis, malignant lymphoma other than MF, bullous diseases other than bullous pemphigoid, and tinea pedis.

The elevation of the IgE level is of great interest in furthering the research on atopic dermatitis and other dermatosis, but knowledge of this factor is not always useful in usual dermatology.

P. AMBLARD, MD
J. L. REYMOND, MD
Grenoble, France

Pseudofolliculitis Capitis

To the Editor.—One must challenge the propagation of several extraordinary misconceptions cited in a recent report on pseudofolliculitis capitis by Smith and Odom in the March 1977 ARCHIVES (113:328-329).

The fact that pseudofolliculitis has not been seen in this area is probably more a reflection of people not shaving their heads than a trait peculiar to this family. Pseudofolliculitis does indeed "know... anatomical boundaries." On the shaved face, it is never seen on the upper lip and is most severe on the chin, the anterior neckline, and the middle of the cheek.[1,2]

I have examined the necks of thousands of black patients, which are very closely clipped or shaved, and I have never seen pseudofolliculitis there. To consider the already doubly misnomered "acne keloid" now a type of pseudofolliculitis,[3] is an outrage. Though many blacks associate the onset of dermatitis papillaris capillitii (acne keloid) with close shaving of the neck, ingrown or incurving hairs are never a feature of this disease until severe late scarring rotates the direction of remaining hairs that are growing. Examination of early and even scarred lesions clearly show a follicular inflammatory papule with a normal hair exiting centrally. This disease is not acne, is not associated with acne, is not keloidal but hypertrophic in its scarring, is not associated with keloids, and is certainly not from reentry or transfollicular penetration of hairs.

GARY D. BRAUNER, MD
Fort Lee, NJ

1. Brauner G: Cutaneous disease in the black races, in Moschella S, Pillsbury D, Hurley H (eds): *Dermatology*. Philadelphia, WB Saunders Co, 1975, pp 1719-1720.

2. Brauner G, Flandermeyer K: Pseudofolliculitis barbae: II. Treatment. *Int J Trop Dermatol*, to be published.

3. McDonald C, Kelly AP: Dermatology and venereology, in Williams R (ed): *Textbook of Black-Related Diseases*. New York, McGraw-Hill Book Co Inc, 1975.

In Reply.—I wish to thank Dr Brauner for his constructive criticism regarding the article "Pseudofolliculitis Capitis" by Dr Smith and me (ARCHIVES 113:328-329, 1977). I continue to support the concept that pseudofolliculitis barbae is a condition that occurs in certain people who inherit the characteristic of having curved hair follicles that produce curly and kinky hairs. The disease is quite common in black men with curly hair, who shave their faces and necks. In persons with straight hair, pili incarnati is indeed uncommon.

With regard to dermatitis papillaris capillitii, the terms sycosis nuchae, folliculitis cheloidalis, and acne keloid are used interchangeably by various authors. One reference states that the nape of the neck and occipital region of the scalp of black men are the sites of this chronic form of keloid acne. It further states that the patient often has a seborrheic constitution with acne vulgaris or hidradenitis suppurativa.[1] An outstanding British textbook[2] states that folliculitis cheloidalis is commonly associated "with seborrhea and many of those affected suffer or have suffered from acne. We have often seen foreign-body granulomas surrounding fragments of hair and the process may be similar to pseudofolliculitis of the beard." Even Dr Brauner's contribution[3] fails to clarify the underlying mechanisms responsible for this disease and states that "no etiology other than friction from stiff collars and trauma from close hair cutting has been espoused; bacteria are not involved primarily."

Rather than suffering further outrage, perhaps Dr Brauner's energy should be channeled toward publication of a report that would expound the origin and pathogenesis of dermatitis papillaris capillitii; this would be of great interest and educational value to those of us who propagate extraordinary misconceptions.

LT COL RICHARD B. ODOM, MC, USA
San Francisco

1. Munro DD: Disorders affecting the skin appendages, in Fitzpatrick TB, Arndt KA, Clark WH, et al (eds): *Dermatology in General Medicine*. New York, McGraw-Hill Book Co Inc, 1971, p 327.

2. Naylor GRE, Rook AJ: Bacterial infections, in Rook AJ, Wilkinson DS, Ebling FJG (eds): *Textbook of Dermatology*. Philadelphia, FA Davis Co, 1972, pp 491-492.

3. Brauner G: Cutaneous disease in the black races, in Moschella S, Pillsbury D, Hurley H (eds): *Dermatology*. Philadelphia, WB Saunders Co, 1975, pp 1720-1721.

SYNALAR®
(fluocinolone acetonide)
CREAM 0.025%
CREAM 0.01%
OINTMENT 0.025%
SOLUTION 0.01%

Description Synalar (fluocinolone acetonide) has the chemical name 6α, 9α-difluoro-16α-hydroxyprednisolone-16, 17-acetonide.

The cream contains fluocinolone acetonide 0.25 mg./g. or 0.1 mg./g. in a water-washable aqueous base of stearic acid, propylene glycol, sorbitan monostearate and monooleate, polysorbate 60, purified water and citric acid with methylparaben and propylparaben as preservatives.

The ointment contains fluocinolone acetonide 0.25 mg./g. in a white petrolatum U.S.P. vehicle.

The solution contains fluocinolone acetonide 0.1 mg./g. in a water-washable base of propylene glycol with citric acid.

Indications For relief of the inflammatory manifestations of corticosteroid-responsive dermatoses.

Contraindications Topical steroids are contraindicated in vaccinia and varicella.

Topical steroids are contraindicated in those patients with a history of hypersensitivity to any of the components of the preparation.

Precautions If irritation develops, the product should be discontinued and appropriate therapy instituted.

In the presence of an infection the use of an appropriate antifungal or antibacterial agent should be instituted. If a favorable response does not occur promptly, the corticosteroid should be discontinued until the infection has been adequately controlled.

If extensive areas are treated or if the occlusive technique is used, the possibility exists of increased systemic absorption of the corticosteroid and suitable precautions should be taken.

Although topical steroids have not been reported to have an adverse effect on pregnancy, the safety of their use in pregnant females has not absolutely been established. Therefore, they should not be used extensively on pregnant patients, in large amounts, or for prolonged periods of time.

Synalar products are not for ophthalmic use.

Adverse reactions The following local adverse reactions have been reported with topical corticosteroids: burning, itching, irritation, dryness, folliculitis, hypertrichosis, acneform eruptions, hypopigmentation.

The following may occur more frequently with occlusive dressings than without such therapy: maceration of the skin, secondary infection, skin atrophy, striae, miliaria.

How Supplied
Synalar (fluocinolone acetonide)
Cream 0.025% — 15 and 60g. tubes and 120 and 425g. jars.
Cream 0.01% — 15, 45 and 60g. tubes and 120 and 425g. jars.
Ointment 0.025% — 15 and 60g. tubes and 425g. jars.
Solution 0.01% — 20cc. and 60cc. plastic squeeze bottles.

Also Available
Synalar-HP® (fluocinolone acetonide)
Cream 0.2% 5g. and 12g. tubes.

SYNTEX
SYNTEX LABORATORIES, INC.
PALO ALTO, CALIFORNIA 94304

AS USEFUL TODAY AS THE DAY IT WAS INTRODUCED

SYNALAR

(FLUOCINOLONE ACETONIDE)

See preceding page for summary of prescribing information.

SYNTEX

The family for your patients' steroid

Proven clinically effective for prompt relief of mild-to-severe corticosteroid-responsive dermatoses

Valisone® Aerosol 0.15%
For acute contact dermatitis.

Impressive results with Valisone Cream and Ointment in published studies:

contact dermatitis
96% good to excellent results
(81 of 84 patients)*

atopic eczema
92% good to excellent results
(231 of 251 patients)*

psoriasis
85% good to excellent results
(150 of 177 patients)*

Valisone® Cream 0.1%

*Files of Headquarters Medical Research Division, Schering Corporation.

Copyright © 1977, Schering Corporation. All Rights Reserved.

See Clinical Considerations section on opposite page...

# of specialists
responsive problems

Schering

Valisone® Lotion 0.1%
Especially useful in seborrheic dermatitis.

Valisone® Reduced Strength Cream 0.01%
For low-cost maintenance therapy.

Valisone® Ointment 0.1%
When dryness is a problem.

Clinical Considerations: Indications: VALISONE Cream, Ointment, and Lotion are indicated for relief of the inflammatory manifestations of corticosteroid-responsive dermatoses. VALISONE Reduced Strength Cream is indicated for the relief of the inflammatory manifestations of corticosteroid-responsive dermatoses. VALISONE Aerosol is indicated, solely, for adjunctive topical management for the relief of inflammatory manifestations of acute contact dermatitis. **Contraindications:** Topical steroids are contraindicated in tuberculosis of the skin and some viral diseases of the skin (varicella and vaccinia). Topical steroids are also contraindicated in those patients with a history of hypersensitivity to any of the components of the preparations. VALISONE Aerosol is contraindicated for use under occlusive dressings. **Warnings for VALISONE Aerosol:** Keep the spray away from eyes and other mucous membranes; avoid inhaling. Avoid freezing of the tissue by not spraying for more than 3 seconds, at a distance not less than 6 inches. Contents are under pressure. Do not puncture. Do not store or use near open flame or heat. Exposure to temperatures above 120°F may cause bursting. Keep out of reach of children. Never throw container into fire or incinerator. **Precautions:** If irritation or sensitization develops with the use of VALISONE products, treatment should be discontinued and appropriate therapy instituted. In the presence of infection, the use of an appropriate antifungal or antibacterial should be instituted. If favorable response does not occur promptly, the corticosteroid should be discontinued until the infection has been adequately controlled. If extensive areas are treated, or if the occlusive technique is used, the possibility exists of sufficient systemic absorption to produce adrenal suppression and systemic corticosteroid effects may occur; suitable precautions should be taken. In a few cases, ulceration has been reported with the use of topical steroids for skin conditions involved with impaired circulation (i.e., stasis dermatitis). Prolonged application of corticosteroid-containing products under occlusion may result in striae or atrophy of the skin or subcutaneous tissues. VALISONE products are not for ophthalmic use. **Usage in Women of Childbearing Age:** The use of any drug during pregnancy and the lactation period or in women of childbearing age requires that the potential benefits of the drug be weighed against the possible hazards to the fetus or infant. Topical corticosteroids have not been reported to have an adverse effect on the fetus, but the safety of their use in pregnant patients has not been definitely established. They should not be used extensively or for prolonged periods of time in pregnant patients, unless the condition requiring treatment warrants the risk. **Adverse Reactions:** The following adverse reactions have been reported with topical corticosteroids: burning, itching, irritation, dryness, folliculitis, hypertrichosis, acneiform eruptions, and hypopigmentation. The following may occur more frequently with occlusive dressings than without such therapy: maceration of the skin, secondary infection, atrophy of the skin or subcutaneous tissues, striae, miliaria. **Dosage and Administration:** VALISONE Cream, Ointment, and Reduced Strength Cream are applied as a thin film over the affected skin areas one to three times a day. Clinical studies of VALISONE have indicated that dosage once or twice a day is often feasible and effective. VALISONE Reduced Strength Cream has an aqueous, hydrophilic base that softens and moisturizes the skin. Although occlusive dressings are required infrequently, they may enhance therapeutic efficacy in certain refractory lesions of psoriasis and other dermatoses that are difficult to treat. Apply a few drops of VALISONE Lotion to the affected area of the scalp and massage lightly until it disappears. Apply twice daily, in the morning and at night. Dosage may be increased in stubborn cases; following improvement, apply once daily. Apply VALISONE Aerosol three to four times a day. The container may be held upright or inverted during use. The spray should be directed onto the affected area from a distance of approximately 6 inches and applied for only 3 seconds. Aerosol packaged by Aerosol Techniques, Inc., Armstrong Laboratories Division, West Roxbury, MA. 02132. **For more complete details, consult package insert or Schering literature available from your Schering Representative or Professional Services Department, Schering Corporation, Kenilworth, New Jersey 07033.**

MARCH 1974 (R)

Valisone®
brand of
betamethasone valerate, NF

SLS-914

"Doctor, with my baby's sensitive skin... what soap should I use?"

Pure mild Ivory is one of the safest possible soaps you can recommend for sensitive skin. More doctors recommend Ivory than any other soap.

It makes sense. Ivory's absence of many extra ingredients helps minimize chances of irritation.

Thirty-eight years of laboratory testing—including patch tests and arm immersion experiments—confirm that Ivory is one of the mildest, least irritating soaps you can recommend.

And 89 years of safe consumer use support this clinical experience.

Ivory may safely be used as an adjunct to treatment of cradle cap, scabies, impetigo and seborrhea.

AQUACARE®/HP

TOO MUCH FOR EVERYDAY DRY SKIN?

IF IT WEREN'T SO SAFE AND COSMETICALLY ELEGANT THE ANSWER MIGHT BE YES.

AQUACARE®/HP HYDRATES, SOFTENS AND SOOTHES CHRONIC, SCALING, PRURITIC CONDITIONS . . . WHETHER MILD OR SEVERE.

HERBERT LABORATORIES/DERMATOLOGY DIVISION OF ALLERGAN PHARMACEUTICALS/IRVINE, CA 92713, U.S.A.

anywhere on potency without fluorination

The potency of Tridesilon—*nonfluorinated* antiinflammatory topical corticoid—has again been confirmed. In a recently published clinical study,[1] desonide 0.05% was compared with fluocinonide (in identical concentration) for various dermatologic disorders including contact dermatitis, nummular eczema, lichen simplex chronicus, seborrheic dermatitis, and atopic eczema.

The desonide group showed better improvement scores in erythema and scaling after the first week; the two-week scores were not significantly different. "...desonide demonstrated potency and efficacy equivalent to those of the fluorinated compound in the disorders treated, and no adverse effects were noted with the former."[1]

This is added corroboration that with topical steroids potency and efficacy do not always depend on fluorination. Desonide, though nonfluorinated, has shown clinical comparability with the most widely prescribed fluorinated topical steroids.[2]

*Not for ophthalmic use.

References: 1. Barsky S: Clinical comparison of desonide cream with fluocinonide cream in steroid-responsive dermatologic disorders. *Cutis* 18:826, 1976. **2.** Reprints available on request.

Contraindications: Tridesilon (desonide) 0.05% Creme and Ointment, topical steroids, are contraindicated in vaccinia and varicella, and in those patients with a history of hypersensitivity to any of the components of the preparation.
Precautions: If irritation develops, the drug should be discontinued and appropriate therapy instituted.
In the presence of an infection, the use of an appropriate antifungal or antibacterial agent should be instituted. If a favorable response does not occur promptly, the corticosteroid should be discontinued until the infection has been adequately controlled.
If extensive areas are treated or if the occlusive technique is used, the possibility exists of increased systemic absorption of the corticosteroid and suitable precautions should be taken.
Although topical steroids have not been reported to have an adverse effect on pregnancy, the safety of their uses in pregnant females has not absolutely been established. Therefore, they should not be used extensively on pregnant patients, in large amounts, or for prolonged periods of time.
These products are not for ophthalmic use.
Adverse Reactions: The following local adverse reactions have been reported with topical corticosteroids: burning sensations, itching, irritation, dryness, folliculitis, hypertrichosis, acneform eruptions, hypopigmentation.
The following may occur more frequently with occlusive dressings than without such therapy: maceration of the skin, secondary infection, skin atrophy, striae, miliaria.
Dosage and Administration: Apply a thin film of Tridesilon (desonide) to the affected skin and massage lightly. The usual dosage is two or three times daily.
Depot Stocked: *DPSC:* 15 gm: NSN 6505-00-148-6969; 60 gm: NSN 6505-00-148-6968; 5 lb: NSN 6505-01-004-9217. *VA:* 60 gm: SN 6505-00-136266A; 5 lb: SN 6505-01-012-4486A.



Tridesilon®
(desonide) 0.05% creme and ointment

adjunctive therapy in acute and chronic steroid-responsive dermatoses

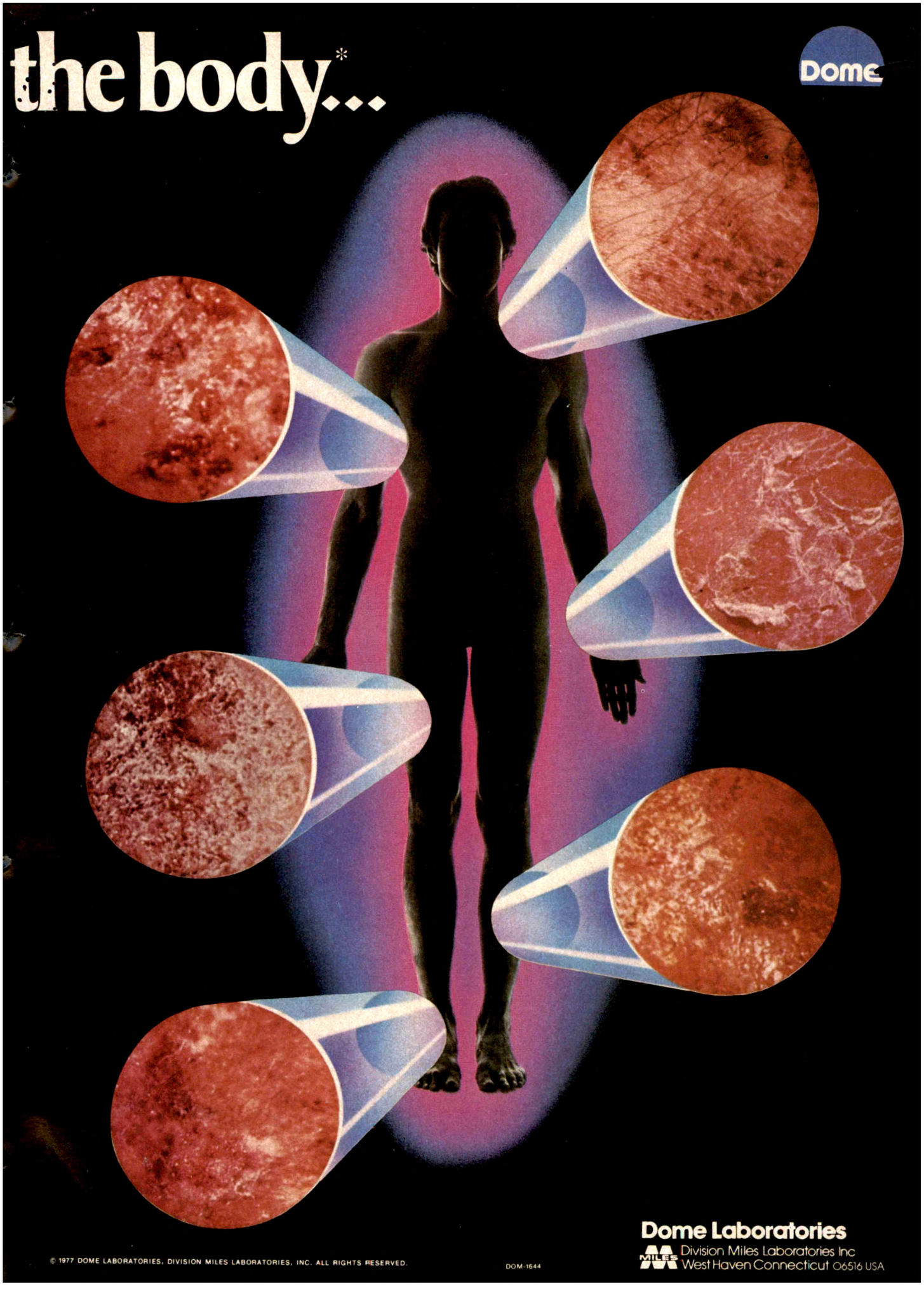
the body*...
Dome
Dome Laboratories
Division Miles Laboratories Inc
West Haven Connecticut 06516 USA
© 1977 DOME LABORATORIES, DIVISION MILES LABORATORIES, INC. ALL RIGHTS RESERVED.
DOM-1644

CHARLES C THOMAS • PUBLISHER

CRYOSURGICAL ADVANCES IN DERMATOLOGY AND TUMORS OF THE HEAD AND NECK

Edited by **Setrag A. Zacarian,** *Boston Univ., Boston. Forewords by* **John G. Bellows** *and* **Edward A. Krull.** *(11 Contributors)* This treatise is a most comprehensive review of cryosurgery for the management of both benign and malignant tumors of the skin, oral cavity, and head and neck. The skills and knowledge of the dermatologist, the general surgeon, the ophthalmologist, the head and neck surgeon, the oral surgeon and the plastic surgeon are all thoroughly interwoven within the chapters of this monograph.

The fundamentals of cryogenesis, the development of the cryolesion, temperature monitoring, double freeze-thaw cycles, and the pathogenesis of cryonecrosis are all reviewed in depth. The selection of various cryosurgical instruments and their respective applications and limitations are frankly discussed. Experimental data and supportive evidence in the area of cryoimmunology are explored and fully outlined.

The contributors, all pioneers and outstanding professionals in their fields, guide the clinician through the laboratory aspects of cryosurgery, from the carefully controlled animal studies to the vast clinical experiences of tumor cryosurgery. The cryosurgical management of patients with acne, benign lesions, and common and advanced skin cancers is outlined in detail. The less common but significant and difficult area of eyelid tumors is thoroughly discussed, clearly outlining the preservation of the lacrimal duct from freezing. The current success in the management of trichiasis is also examined.

This is the definitive text for the application of this procedure in dermatology. The *Journal of Dermatologic Surgery and Oncology* was unrestrained in its praise for this text: "It is by far the most important and up-to-date single textbook on this subject. [The] authors have done a superb job. . . . I recommend it highly." *'77, 296 pp. (7 x 10), 473 il. (122 in color), 31 tables, $33.00*

LOCAL ANESTHETICS (2nd Ed.) *by* **Rudolph H. de Jong,** *Univ. of Illinois College of Medicine, Chicago.* Totally new chapters, sweeping revisions and a shortened title characterize the Second Edition of this comprehensive text on local anesthetics. The book's format has been completely recast to accommodate recent advances in such diverse areas as membrane physiology, cardiovascular pharmacology, biotransformation and pharmacokinetics. A review of the history of local anesthetics opens the book. The next six chapters discuss the basic science and clinical aspects of the subject: axonal physiology, the membrane site of local anesthetic action, and the mechanics of clinical nerve blockage. The remainder of the text is devoted to the pharmacology of local anesthetic drugs. Separate, self-contained chapters delineate the varied systemic effects of local anesthetics in an authoritative analysis of this important but often misunderstood topic. These chapters cover effects on the heart, blood vessels, brain and other key organ systems. The absorption, binding and disposition of anesthetic drugs; biotransformation; and adverse effects such as overdosage, toxicity and allergy are also given detailed consideration. *'77, 364 pp. (6 3/4 x 9 3/4), 72 il., 27 tables, $32.50*

THE ULTRASTRUCTURE OF COLLAGEN: Its Relation to the Healing of Wounds and to the Management of Hypertrophic Scar *edited by* **J. J. Longacre.** *(35 Contributors)* Ever since the earliest recorded writings of man, scar has been a word with unpleasant connotations. However, were it not for the final conversion of granulation tissue into mature scar, no wound would heal firmly. These natural forces must be harnessed and made beneficial to man. This book expounds upon that concept. The text relates the ultrastructure of collagen to the healing of wounds and the surgical management of hypertropic scar. It includes advanced knowledge on causation, treatment and prevention of hypertrophic scarring. A few of the topics discussed include wound sepsis, the basis of the histological demonstration of tension in collagen, the relationship of collagen metabolism and hypertrophic scars, collagen degradation in normal and abnormal tissues, distribution of oxygen and its significance in healing tissue, the role of environmental factors on connective tissue cell metabolism, and behavior of scar tissue through its evolution with and without surgery. *'76, 538 pp. (6 3/4 x 9 3/4), 537 il., 28 tables, $41.50*

SKIN SURGERY (4th Ed.) *edited by* **Ervin Epstein** *and* **Ervin Epstein, Jr.,** *both of the Univ. of California Medical School. (45 Contributors)* A number of prominent authorities in such fields as dermatology, surgery and plastic surgery have contributed their expertise to this greatly expanded Fourth Edition. Over 150 new pages have been added along with 400 new black and white illustrations, fifteen new color illustrations and twenty-two new tables to bring this book up-to-date and in line with the rapidly growing interest in the field. The original five sections — *General Considerations, Cold Steel Surgery, Electrosurgery, Special Procedures,* and *Special Locations of Disease* — have been retained. However, the format within these sections has been rearranged to offer a better perspective of the content and to emphasize new developments. Recent advances, further studies and increasing interest have led to the creation of three new sections: *Chemosurgery, Cryosurgery,* and *Investigative Surgical Therapy of the Skin.* New chapters cover such topics as anesthesia for skin surgery, medicolegal problems, tattoo removal, cryosurgery in the treatment of acne, surgery of the eyelids and oral cavity by dermabrasion, and gadgets and gimmicks in skin surgery. *Plastic and Reconstructive Surgery,* in its comments on this new edition, said, "It is superbly organized, clearly written, and beautifully illustrated . . . It will, no doubt, continue to be a standard reference text for those dermatologists who intend to get involved in surgery." *'77, 864 pp. (7 x 10), 1081 il. (19 in color), 37 tables, $98.75*

THE DIAGNOSIS AND TREATMENT OF FUNGAL INFECTIONS: A Symposium *compiled and edited by* **Harry M. Robinson, Jr.,** *Univ. of Maryland, Baltimore. (38 Contributors)* This book will be of great value as a source book for student and practicing dermatologists. Material has been prepared by professionals in the basic sciences and clinical medicine who were selected for their expertise and current, well-qualified opinions. The book contains a compilation of chapters presenting current thoughts on various topics in the research, diagnosis and treatment of fungal infections. Recent developments in microbiology, laboratory diagnosis, histopathology, immunology and experimental work are covered. Articles are also included which cover various aspects of superficial and deep mycotic infections. *'74, 580 pp., 128 il. (18 in color), 45 tables, $29.50*

Orders with remittance sent, on approval, postpaid

301-327 East Lawrence Avenue • Springfield • Illinois • 62717

They're here... the 75-76 red & blue books

Profile of Medical Practice
Socioeconomic Issues
of Health!

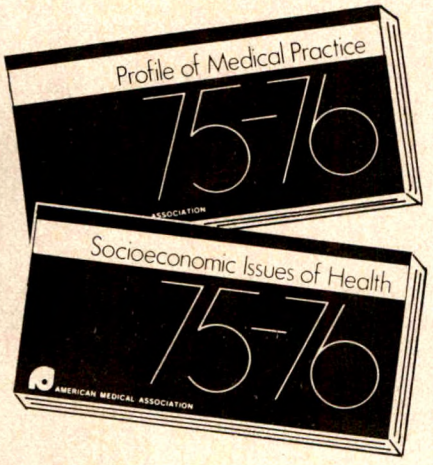

Invaluable for anyone needing a quick, authoritative reference to relevant data on the U.S. health care delivery system, these unique publications are compiled annually by the AMA Center for Health Services Research & Development.

The Red Book, PROFILE OF MEDICAL PRACTICE (OP-463), presents data from the AMA Physician Masterfile and the Periodic Survey of Physicians describing various characteristics of medical practice. It also includes essays on issues affecting the practice of medicine.

The Blue Book, SOCIOECONOMIC ISSUES OF HEALTH (OP-462), compiles data describing the U.S. health care delivery system. Also included are original essays on relevant health issues of general interest.

Both are available now for $4.50 each or $8.50 per set. To order yours, write Order Dept., AMA, 535 N. Dearborn St., Chicago, Illinois 60610. Payment must accompany order.

Previous editions of the Red and Blue books are available upon request.

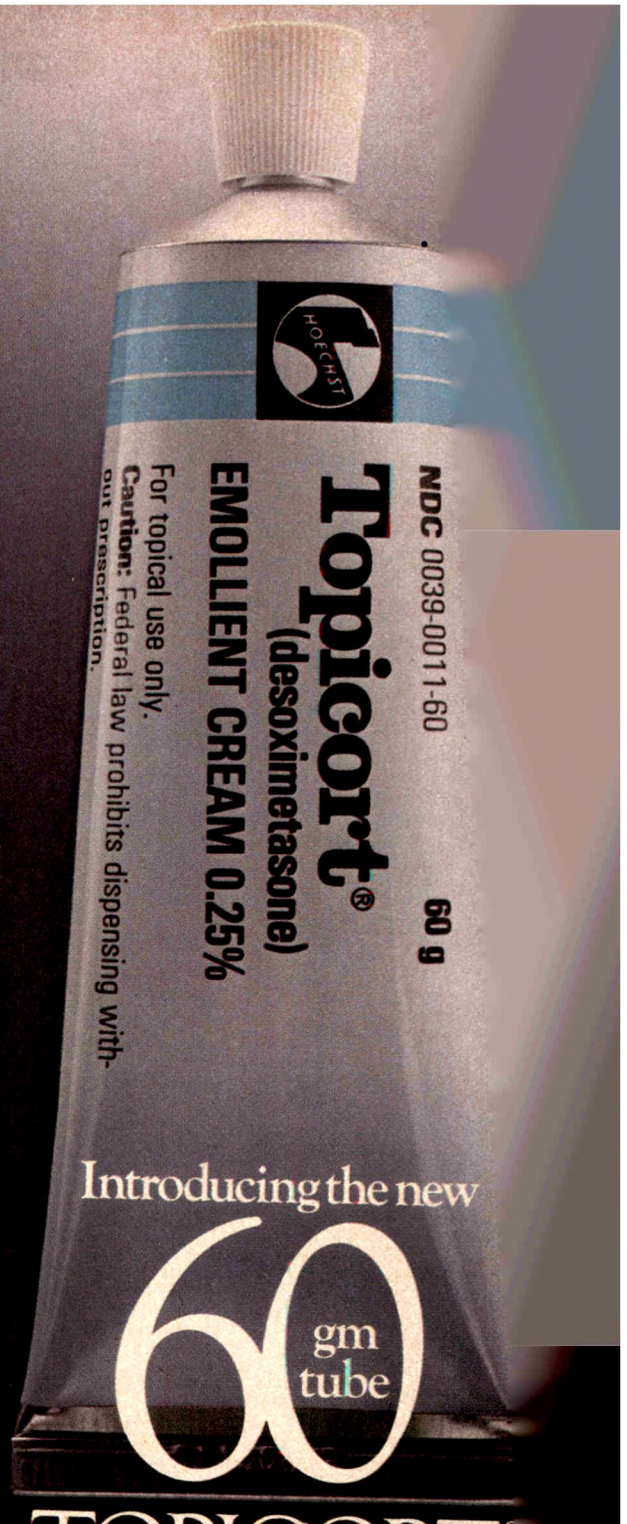

TOPICORT®
(DESOXIMETASONE)
EMOLLIENT CREAM 0.25%

For greater convenience and economy.

HOECHST-ROUSSEL
PHARMACEUTICALS INCORPORATED
SOMERVILLE, NEW JERSEY 08876

When dehydrated stratum corneum and pruritus pose a problem...

Applehead art, hand-carved from an apple and dehydrated in stages. Apple carving is a 250 year old art in this country.

©1977, W.P. Inc.

Recommend our therapeutic moisture system.

"A drier than normal stratum corneum has less surface area than the tissues below and the skin surface first becomes taut and then cracks to form scales, or fissures, where the stratum corneum is very thick... any physiologic condition which decreases the water content of the stratum corneum may lead to tautness and scale formation.

"Conversely, hydration of the stratum corneum makes it more pliable... warmer climates and all conditions increasing the water content of the stratum corneum will be helpful in treating dry skin and scaling dermatoses.

"The application of emollient films to skin still moist from bathing will trap a certain amount of water, increase the volume and surface area of the horny layer, and permit the stratum corneum to cover the body surface more completely and thereby diminish the tautness of skin and scale formation."*

The Alpha Keri® moisture system is a time tested, efficient way to hydrate the stratum corneum. Alpha Keri bath oil's emollient film helps the skin retain moisture with the first bath. And Keri® Lotion can be applied between baths as often as needed. Dryness, scaling and itching are relieved in minutes.

Alpha Keri and Keri Lotion are indicated for adjunctive treatment of the entire range of dry, scaling, pruritic dermatoses. Alpha Keri is available in 4, 8, and 16 oz. plastic bottles, and 5 oz. aerosol shower spray. Keri Lotion, scented and unscented, is available in 6½, 13, and 20 fl. oz. dispenser bottles.

*Moschella SL, Pillsbury DM, Hurley HJ: *Dermatology*, Vol. 2. W. B. Saunders Co., Philadelphia, 1975. p. 1059-60.

WESTWOOD
PHARMACEUTICALS INC.
Buffalo, New York 14213

Academic Positions Available

The following is a list of universities seeking dermatologists for academic positions as of Oct 1, 1977. Dermatologists interested in academic careers should contact the appropriate individual at the university directly.

Johns Hopkins School of Medicine, contact Irwin Freedberg, MD, two to three positions.

University of Iowa College of Medicine, contact John S. Strauss, MD, two positions.

Emory University Affiliated Dermatology Residency Training Program, contact Henry Loney, MD, two positions.

Medical College of Wisconsin, contact Robert E. Jordon, MD, one position.

Wayne State University School of Medicine, contact Donald Birmingham, MD, two positions.

University of Arkansas for Medical Science, contact G. Thomas Jansen, MD, two positions.

University of California, San Diego, contact Dr Stoughton, one position.

University of North Carolina School of Medicine, contact Clayton Wheeler, MD, one to two positions.

Tulane University School of Medicine, contact Lee T. Nesbitt, Jr, MD, one position.

Case Western Reserve University, contact David Bickers, MD, two positions.

Geisinger Medical Center, contact O. Fred Miller, MD, one position.

University of Texas Medical School, contact Marvin Chernosky, MD, three positions.

University of Texas Medical Branch, contact William B. Bean, MD, one position.

UCLA-VA Wadsworth School of Medicine, contact Ronald Reisner, MD, one position.

University of Puerto Rico School of Medicine, contact Jorge Sanchez, MD, one position.

University of California, Irvine Medical Center, contact James H. Graham, MD, one position.

University of California, Sacramento Medical Center, contact Lawrence J. Bass, MD, two positions.

Creighton University Health Foundation, Dermatology Program, Omaha, contact Ramon M. Fusaro, MD, one position.

Cleveland Clinic, contact Philip L. Bailin, MD, one position.

Stanford University Medical Center, contact E. M. Farber, MD, two positions.

University of Cincinnati Medical Center, contact George Hambrick, MD, three positions.

University of California, San Francisco, contact William Epstein, MD, two positions.

George Washington University Medical School, contact Mervyn L. Elgart, MD, one position.

Indiana University, contact Arthur L. Norins, MD, one position.

Southern Illinois University School of Medicine, contact Robert Miller, MD, one to two positions.

Hahnemann Medical College, contact Paul Fleischmajer, MD, one position.

Missouri University, contact Philip Anderson, MD, one position.

University of Maryland, contact Joseph W. Burnett, MD, two positions.

Dartmouth-Hitchcock Medical Center, contact Richard B. Baughman, MD, one position.

University of Tennessee, contact E. W. Rosenberg, MD, one position.

University of Michigan Medical School, contact John J. Voorhees, MD, one position.

Texas Tech University School of Medicine, contact Barbara Way, MD, two positions.

University of Oklahoma College of Medicine, contact Mark A. Everett, MD, one position.

Louisiana State University School of Medicine, contact Henry W. Jolly, MD, one position.

University of Pennsylvania Hospitals, contact Dr Shelley, one position.

In most instances, the salary is negotiable depending on level of experience.

Annual Meeting.—The annual meeting of the Society for Investigative Dermatology, Inc (SID), will be held Monday through Wednesday, May 1-3, 1978, at the St Francis Hotel in San Francisco immediately following the meeting of the American Federation for Clinical Research (AFCR). Beginning with this meeting, a registration fee of $50 will be required of all nonmembers of the SID and AFCR. Admission to the meeting rooms will be by name badge only. To speed registration, members will receive registration forms at the time of the mailing of the annual program. Nonmembers are requested to preregister by writing the secretary-treasurer and enclosing the registration fee. Send forms and fees to W. Mitchell Sams, Jr, MD, secretary-treasurer, Department of Dermatology, N. C. Memorial Hospital, Chapel Hill, NC 27514.

Eastern Regional Meeting.—Abstracts for the April 16, 1978 eastern regional meeting of the Society for Investigative Dermatology (SID) are requested by March 1. Please send them on official SID forms to Dr Stephen Katz, Bldg 10, Rm 12N-238, National Institutes of Health, Bethesda, MD 20014. The meeting will be held at the Hyatt Regency Hotel in Washington, DC from 9 AM to 12:30 PM. This meeting will follow that of the Atlantic Dermatologic Society, which will be held in the same place. The special guest lecturer at the SID meeting will be Edward Scolnick, MD, who is chief of the Tumor Virus Genetics Laboratories at the National Cancer Institute. The title of his talk will be "How Viruses Cause Cancer."

Pediatric Dermatology Course.—The third annual postgraduate course in pediatric dermatology, sponsored by the Society for Pediatric Dermatology, will be held July 13, 14, and 15, 1978, at the Niagara Hilton in Niagara Falls, NY. Guest faculty include Sidney Hurwitz, Nia Terezakis, Jim Leyden, Ron Reisner, Sam Weinberg, Bill Weston, Larry Solomon, Nancy Esterly, Joe McGuire, Norman Ellerstein, Michael Fisher, Allen Drinnan, and Sigfried Muller. For information please write James E. Rasmussen, MD, Children's Hospital of Buffalo, 219 Bryant St, Buffalo, NY 14222.

Nursing Conference.—"Dermatological Nursing: A Practical Approach to Common Skin Diseases," will be held April 6-7, 1978 in San Francisco. The conference is cosponsored by Continuing Education in Nursing, School of Nursing and the Department of Dermatology, School of Medicine, University of California, San Francisco. The two-day conference is designed for registered nurses and other health professionals functioning in a variety of settings, ie, schools, industry, physicians' offices, ambulatory care and acute or long-term hospitals. Common dermatological problems from infancy to senescence will be discussed. Seminar sessions will follow didactic presentations. For more information write to Carolyn Whetzel, Program Assistant, N631X, University of California, San Francisco, CA 94143.

a unique, two step regimen for acne makes better even better

NEW

Potent antibacterial action + Potent comedolytic action

PanOxyl® (benzoyl peroxide 5% and 10%), because of its effectiveness in reducing *P. acnes* and free fatty acids, revolutionized acne therapy. Recently, the concomitant use of a comedolytic agent such as retinoic acid in the treatment of acne has produced widespread interest.[1]

New Saligel™ containing 5% salicylic acid in a special hydroalcoholic gel vehicle, also provides potent comedolytic activity, but without the degree of dermal irritation often seen during retinoic acid therapy. Independent studies confirm the effectiveness and safety of this concept[2,3].

PanOxyl® 5 & PanOxyl® 10

Composition: PanOxyl 5 Gel contains 5% Benzoyl Peroxide, 6% polyoxyethylene lauryl ether and 40% ethyl alcohol in a gel base formulated with colloidal magnesium aluminum silicate, hydroxypropylmethylcellulose, citric acid and purified water. PanOxyl 10 Gel contains 10% Benzoyl Peroxide, 6% polyoxyethylene lauryl ether and 40% ethyl alcohol in a gel base formulated with colloidal magnesium aluminum silicate, hydroxypropylmethylcellulose, citric acid, and purified water.

Caution: Federal Law prohibits dispensing without a prescription.

Action And Uses: The topical use of PanOxyl 5 and PanOxyl 10 provides therapeutic control of acne through drying and desquamative action, as well as providing antiseptic activity.

Indications: Use as an aid in the treatment of acne.

Dosage And Administration: Apply 1 or more times daily to affected areas. Washing the face with soap and water prior to application greatly enhances the efficacy of the medication.

Contraindications: Patients with a known sensitivity to Benzoyl Peroxide should not employ these medications.

Precautions: For external use only. Do not permit products to come in contact with the eyes or mucosal membranes. Keep this and all drugs out of reach of children. Very fair individuals should always be started on a single application at bedtime, allowing the medication to remain on the skin overnight. PanOxyl may bleach hair and colored fabrics. Store below 80F.

How Supplied: 2 oz. and 4 oz. plastic tubes.

Saligel™

Saligel Acne Gel is indicated as a peeling and drying agent in the treatment of acne.

Composition: 5% Salicylic Acid, U.S.P. in a special hydroalcoholic gel containing 40% alcohol.

Directions: Saligel should be applied in the morning and evening, or as required.

Caution: If undue skin irritation develops, discontinue use and consult physician. Avoid getting into eyes or on mucous membranes.

Keep this and all medication out of the reach of children.

Package Information: Saligel is supplied in a 2 ounce plastic tube.

References: 1. Hurwitz, S.: *Cutis*, **17**, 585-590, 1976. 2. Shalita, A.R.: Personal communication. 3. Kligman, A.M.: Personal communication.

Saligel™ Acne Gel

Makes better even better

To obtain Saligel and PanOxyl samples, as well as special patient instruction sheets, write to:

STIEFEL
Logical Dermatologicals

Stiefel Laboratories, Inc.
Oak Hill, N.Y. 12460

7-1331

WHEN DERMATOSES TAKE SHAPE

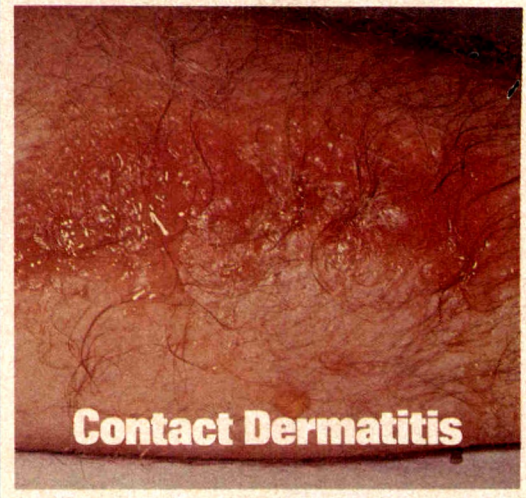

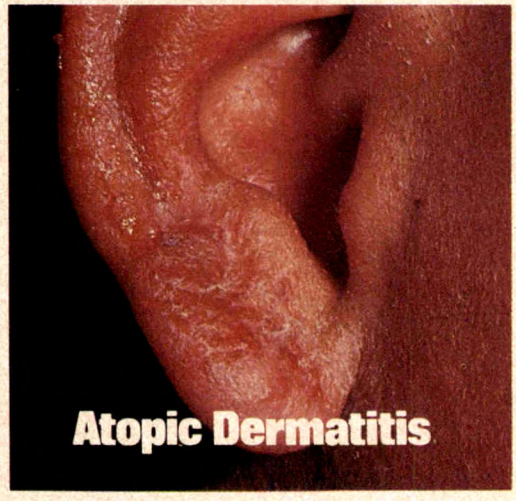

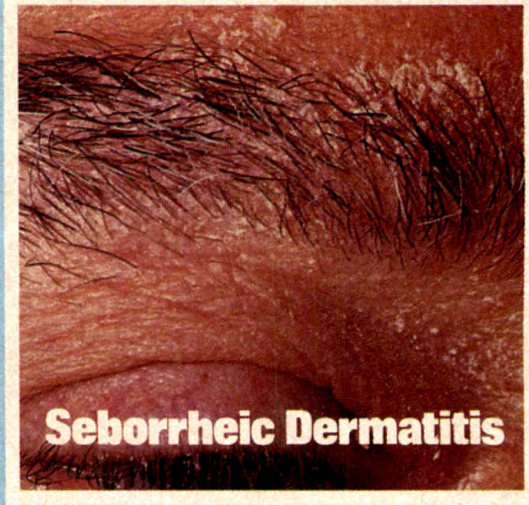

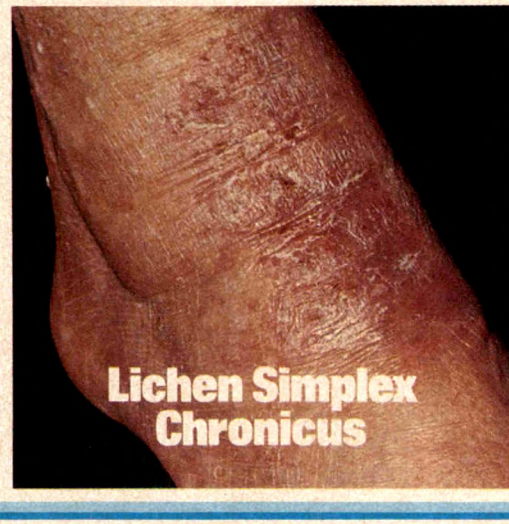

COPYRIGHT © 1977, SCHERING CORPORATION. ALL RIGHTS RESERVED. SLS-866

Schering

DIPROSONE® TAKES CHARGE!

BRAND OF
BETAMETHASONE
DIPROPIONATE

Prompt and Effective Topical Action for Everyday Steroid-Responsive Dermatoses

- Rapid onset of response
- Economy and convenience of b.i.d. dosage
- Occlusive dressings rarely needed
- Sensitivity is unusual



Available for prescribing flexibility in cream, ointment, and lotion.
Also available in aerosol, which is indicated for contact dermatitis only.

Please see Clinical Considerations section which follows...

DIPROSONE®
brand of betamethasone dipropionate
Cream 0.05%, Ointment 0.05%, Lotion 0.05% w/w, Aerosol 0.1% w/w
(Potency expressed as betamethasone)
For Dermatologic Use Only

ACTIONS: DIPROSONE **Cream, Ointment, Lotion,** and **Aerosol** are primarily effective because of their anti-inflammatory, antipruritic, and vasoconstrictive actions.

INDICATIONS: DIPROSONE **Cream, Ointment,** and **Lotion** are indicated for the relief of the inflammatory manifestations of corticosteroid-responsive dermatoses.

DIPROSONE **Aerosol** is indicated solely for the adjunctive topical management for the relief of inflammatory manifestations of acute contact dermatitis.

DIPROSONE **Aerosol** has not been shown to be effective in any steroid-responsive dermatosis other than contact dermatitis.

CONTRAINDICATIONS: DIPROSONE **Cream, Ointment, Lotion,** and **Aerosol** are contraindicated in vaccinia and varicella. Topical steroids are contraindicated in those patients with a history of hypersensitivity to any of the components of such preparations.

DIPROSONE **Aerosol** is also contraindicated for use under occlusive dressings.

WARNINGS FOR DIPROSONE AEROSOL: Keep DIPROSONE **Aerosol** away from eyes or other mucous membranes. Use only as directed; intentional misuse by deliberately concentrating or inhaling the contents can be harmful or fatal. Avoid freezing of the tissue by not spraying for more than three seconds, at a distance of not less than six inches. Contents under pressure. Do not puncture. Do not use or store near heat or open flame. Exposure to temperatures above 120° Farenheit may cause bursting. Never throw container into fire or incinerator. Keep DIPROSONE **Aerosol** out of reach of children.

PRECAUTIONS: If irritation develops with the use of DIPROSONE products, treatment should be discontinued and appropriate therapy instituted. In the presence of an infection, the use of an appropriate antifungal or antibacterial agent should be instituted. If a favorable response does not occur promptly, the corticosteroid should be discontinued until the infection has been adequately controlled.

If extensive areas are treated or if the occlusive technique is used, the possibility exists of increased systemic absorption of the corticosteroid and suitable precautions should be taken. Although topical steroids have not been reported to have an adverse effect on pregnancy, the safety of their use in pregnant females has not been absolutely established. Therefore, they should not be used extensively in pregnant patients, in large amounts or for prolonged periods of time. DIPROSONE products are not for ophthalmic use.

ADVERSE REACTIONS: The following local adverse reactions have been reported with topical corticosteroids: burning; itching; irritation; dryness; folliculitis; hypertrichosis; acneiform eruptions; hypopigmentation. Additionally, the following may occur with DIPROSONE **Aerosol** and also may occur more frequently with occlusive dressings than without such therapy: maceration of the skin; secondary infection; skin atrophy; striae; miliaria.

DOSAGE AND ADMINISTRATION: DIPROSONE **Cream** and **Ointment** are applied as a thin film over the affected skin areas twice daily, in the morning and at night. Clinical studies of DIPROSONE have indicated that applications twice a day are generally adequate.

Apply a few drops of DIPROSONE **Lotion** to the affected areas and massage lightly until it disappears. Apply twice daily, in the morning and at night. For the most effective and economical use, apply nozzle to affected area and gently squeeze bottle.

DIPROSONE **Aerosol** may be held upright or inverted during use. The spray should be directed onto the affected area from a distance of not less than six inches and applied for only three seconds. Apply DIPROSONE **Aerosol** sparingly to the affected skin area three times a day.

Aerosol packaged by Aerosol Techniques, Inc., Armstrong Laboratories Division, West Roxbury, MA. 02132.

For more complete details, consult package insert or Schering literature available from your Schering Representative or Professional Services Department, Schering Corporation, Kenilworth, New Jersey 07033.
DECEMBER 1977

Books

Readers are advised that in view of The Copyright Revision Act of 1976, *all Book Reviews submitted for publication must contain on the transmittal letter the following language: "The person(s) undersigned hereby grant the American Medical Association permission to publish this Book Review and in addition, hereby assigns all copyright ownership therein to the AMA."*

Cutaneous Toxicity, edited by Victor A. Drill, and Paul Lazar, 277 pp, with illus, $14.50, New York, Academic Press Inc, 1977.

The proceedings of the Third Conference on Cutaneous Toxicity are reported in this volume. The publishers have used their rapid press manuscript reproduction method with good effect. The pages look like perfect copies of typescript and are remarkably clear and easy to read. The book is elegant, with its attractive hardback red cover and brightly colored title lettering.

The contents are unusually varied; they range from basic mathematical formulas for calculating flux through the skin to such practical details as directions for animal and human skin testing for allergic and irritant reactions, in vitro testing for irritancy, the relative frequency with which different chemicals are applied to the skin in cosmetics, and controlling hospital infections by hand washing.

Perhaps the best way to convey the broad scope and great variety of authoritative information contained is to analyze the positions held by the contributors to this publication. The text is edited by Victor A. Drill, MD, PhD, for the Society of Toxicology and Paul Lazar, MD, for the American Medical Association, who were cosponsors of the conference. The contributors comprise: ten dermatologists, including several professors of dermatology in large universities; four scientists in distinguished academic positions who are not in the field of dermatology; four US government scientists; 12 scientists employed by industry; one senior scientist of the American Medical Association; and one US senator, author of the bill on cosmetic safety.

These authorities have been brought together by their common interest, experiences, and contributions, which are directly or indirectly related to cutaneous toxicity, its causes, and mechanisms. In addition, there is a discussion of how to protect the public from cutaneous toxicity without too adversely affecting the rights of industry and the principles of free enterprise.

This reasonably priced book is recommended to all who wish to learn about or refer to the many new discoveries that bear upon the approaches to cutaneous toxicity. It presents, with clarity, much of the vast new knowledge of how the skin protects itself and also protects the internal organs from the manifold onslaughts of the modern environment and thus helps each of us to survive.

MARION B. SULZBERGER, MD
San Francisco

Dermatology, edited by R. Marks, and P. D. Samman, 507 pp, with illus, $28.50, New York, Appleton-Century-Crofts, 1977.

Although this small textbook is intended for the British general physician who has an interest in dermatology, the American dermatologist may find this book of interest if he considers it to be a collection of essays on a variety of dermatologic subjects. Because the quality of each of the 33 chapters varies widely, the dermatologist will find only approximately half of the presentations to be useful. Chapters on the epidermis by Marks, on tropical dermatoses seen in Europe by Jopling, on skin markers of malignancy by Samman, and on lupus erythematosus and dermatomyositis by Gold are well worth reading.

This volume could have been improved greatly by much tighter editing by both the authors and the publishers. Misprints abound that a competent manuscript editor should have caught. The references could be more current and might well be less limited to British publications. There are numerous black and white illustrations that serve to point out interesting details, but their reproduction again needs attention.

I have always found such tutorials extremely helpful and I would hope that some of these comments might be incorporated in future volumes. The British School of Dermatology is extremely important, and we Americans need to keep abreast of current thought in that country.

LAWRENCE C. PARISH, MD
Philadelphia

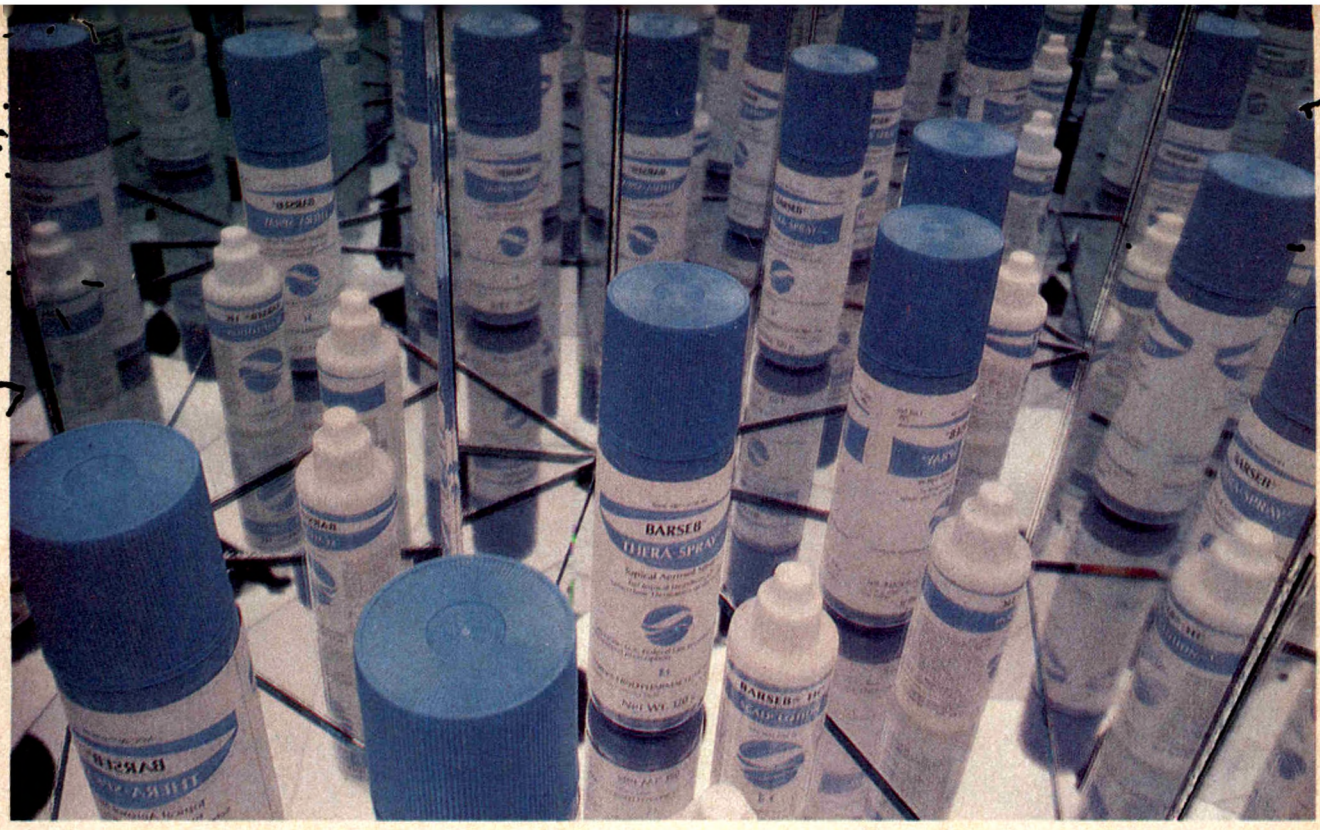

Prescribed hundreds of thousands of times for seborrheic dermatitis. The choice you can count on.

Barseb® is time-tested hydrocortisone + salicylic acid: antipruritic, anti-inflammatory.

It's designed for mild to moderate seborrheic dermatitis because it's effective yet gentle. Barseb relieves itching and inflammation and loosens scales and crusts. Yet Barseb won't discolor hair or cause excessive oiliness.

Available as Barseb® HC Scalp Lotion that's compatible with hair sprays, colorings, permanent waves, grooming agents. And Barseb® Thera-Spray,® a convenient aerosol that won't muss styled or groomed hair.

Both are clear, non-staining, and rapid-spreading.

Barseb — the choice you can count on.

BARSEB® THERA-SPRAY
BARSEB® HC SCALP LOTION

(hydrocortisone and salicylic acid)

For complete prescribing information, please see package insert.

CONTRAINDICATIONS Hydrocortisone is contraindicated in tuberculosis, fungal, and most viral infections of the skin (especially herpes simplex, vaccina and varicella, etc).

WARNING While topical steroids have not been reported to have an adverse effect on pregnancy, the safety of their use has not been absolutely established. Therefore, they should not be used extensively on pregnant patients in large amounts nor for long periods of time.
Avoid inhalation, ingestion or contact with eyes or nose.
BARSEB® THERA-SPRAY
Contents under pressure. Do not puncture, burn or expose to temperatures above 120°F. Avoid inhalation.

PRECAUTIONS Transient discomfort may occur when first applied to an inflamed scalp. This normally disappears with repeated use. Discontinue use if condition does not improve or if sensitivity reactions occur. The anti-inflammatory action of hydrocortisone may mask the presence of infection. If bacterial or fungal infection exists or supervenes, concomitant antimicrobial or antifungal therapy should be considered. When topical steroids are used on large areas of skin for long periods of time, there is the possibility of systemic absorption. Should adrenal suppression, electrolyte imbalance, metabolic changes, or other symptoms of systemic absorption occur, suitable counter measures should be taken. Precautions should be taken when hydrocortisone is used in the treatment of skin diseases associated with impaired circulation, such as stasis dermatitis.
Avoid spray inhalation, ingestion, or contact with eyes or nose. If medication accidentally gets into eyes, immediately flush with copious amounts of water; if irritation persists, notify your physician. Keep out of reach of children.

CAUTION U. S. Federal law prohibits dispensing without prescription.

Barnes-Hind Pharmaceuticals, Inc.
895 Kifer Road
Sunnyvale, California 94086



A safe, economical method of permanent hair removal– from face, legs, body

To save valuable office time, you can confidently recommend Perma Tweez to your patients for their home use.

- Battery-operated instrument self-sterilizes when current flows.
- Patented self-correcting needle.
- No-puncture safety feature helps prevent infection.
- Proved clinically safe (report on request).

FOR PHYSICIAN ORDERING

GENERAL MEDICAL CO., Dept D-94
1935 Armacost Ave.
West Los Angeles, CA 90025
30 DAY FREE TRIAL EXAMINATION.
(May be returned with no obligation.)

☐ PERMA TWEEZ $19.95
☐ ATTACHMENT $3.00
(for treating others)
☐ INVOICE AFTER 30 DAYS
☐ CHECK ENCLOSED

DR_____

STREET_____

C/S_____ ZIP_____

INDEX TO ADVERTISERS

A

Abbott Laboratories 150-151

B

Barnes-Hind Pharmaceuticals 307
Burroughs Wellcome Company 149

C

Cook County Graduate School of Medicine 181
Cryenco 166

D

Dermik Laboratories 157, 185, 276
Doak Pharmacal Company 273
Dome Laboratories 153, 296-297

E

Ellender, Rudolph, Medical Foundation Inc. 170

G

General Medical Company 308

H

Herbert, G.S., Laboratories, Division of Allergan Pharmaceuticals 171, 269, 295
Hoechst-Roussel Pharmaceuticals 168-170, 299

I

Ingram Pharmaceutical Company 285

L

Lederle Laboratories, Division of American Cyanamid Company 160-161, 283-284

O

Owen Laboratories, Inc. ..... 3rd Cover

P

Parke-Davis & Company 180-181, 274-275
Person & Covey, Inc. 277
Pharmacia Diagnostics 147
Procter & Gamble Company 178A-178B, 178A-178F, 294
Purdue Frederick Company 175

R

Reed & Carnrick 162-163
Riker Laboratories, Inc. 156
Roerig, J.B., Company Division of Pfizer, Inc. 176-177

S

Schering Corporation 292-293, 304-306
Smith Kline & French Laboratories 154-155
Spectrum Publications, Inc. 167
Squibb, E.R., & Sons, Inc. 182-184
Stiefel Laboratories, Inc. 303
Stuart Pharmaceuticals Div. of ICI Americas Inc. 159
Syntex Laboratories, Inc. 172-174, 270-272, 290-291

T

Thomas, Charles C., Publisher 298

W

Westwood Pharmaceuticals, Inc. ..... 2nd Cover, 164-166, 179, 186, 300-301, 4th Cover

While every precaution is taken to insure accuracy, we cannot guarantee against the possibility of an occasional change or omission in the preparation of this index.

Give rough, dry skin the soft touch.

Nutraplus® restores softness to excessively rough, dry skin through enhanced absorption and moisture retention.

Nutraplus® cream or lotion with 10% urea ... stable, efficacious, economical, patient-preferred.

Owen
Owen Laboratories, Dallas, Texas 75234
Division of Alcon Laboratories, Inc.

Printed in U.S.A. ©1977

P. acnes comes out in the Wash

A recent research study showed Desquam-X® Wash (4% BENZOYL PEROXIDE) can reduce P. acnes 87.7% in 1 day*

Purpose of the *in vivo* study was to generate data showing the reduction of anaerobic facial bacteria (P. acnes).

Desquam-X Wash was applied b.i.d. No other acne therapy was administered.

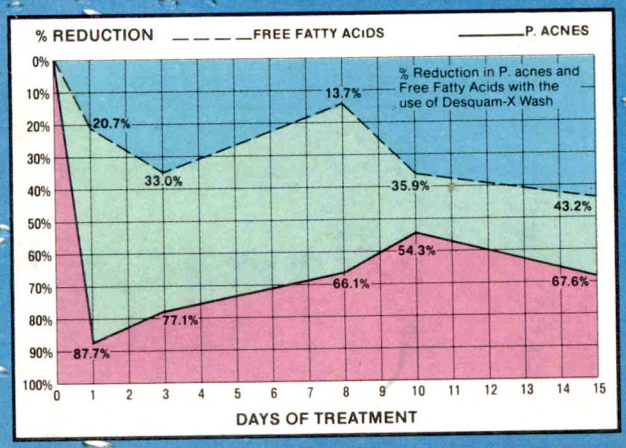

The first benzoyl peroxide cleanser, available only on your Rx.

Desquam-X® Wash (4% Benzoyl Peroxide) THERAPEUTIC CLEANSER

NDC 0072-6900-05

CONTENTS: DESQUAM-X® WASH contains 4% benzoyl peroxide, sodium octoxynol-3-sulfonate, water, sodium dioctyl sulfo-succinate, sodium lauryl sulfoacetate, magnesium aluminum silicate, methocel A4M, EDTA.

INDICATIONS: May be used topically alone for mild to moderate acne vulgaris. In severe, complicated acne Desquam-X Wash may be used as an adjunct to therapeutic regimens which might include antibiotics, retinoic acid products, and/or sulfur and salicylic acid containing preparations.

ACTION: Provides drying and desquamation desirable in the topical treatment of acne. Desquam-X Wash has demonstrated antibacterial activity against Propionibacterium acnes. Desquam-X Wash has also been shown to reduce the concentration of free fatty acids in the sebum.

DIRECTIONS FOR USE: Wash vigorously with Desquam-X Wash once or twice daily, avoiding contact with eyes or mucous membranes. Drying and peeling may be modified by adjusting the dosage schedule.

CONTRAINDICATIONS: Not to be used in patients known to be sensitive to benzoyl peroxide or other ingredients.

PRECAUTIONS: Avoid contact with eyes and mucous membranes. To prevent bleaching, avoid contact with hair. Keep this and all drugs out of the reach of children. For external use only.

NOTE: May bleach colored fabrics. Store below 77°F.

HOW SUPPLIED: Plastic bottles 5 oz. (141.8 g.)

CAUTION: Federal law prohibits dispensing without a prescription.

*Data on file, Westwood Pharmaceuticals.

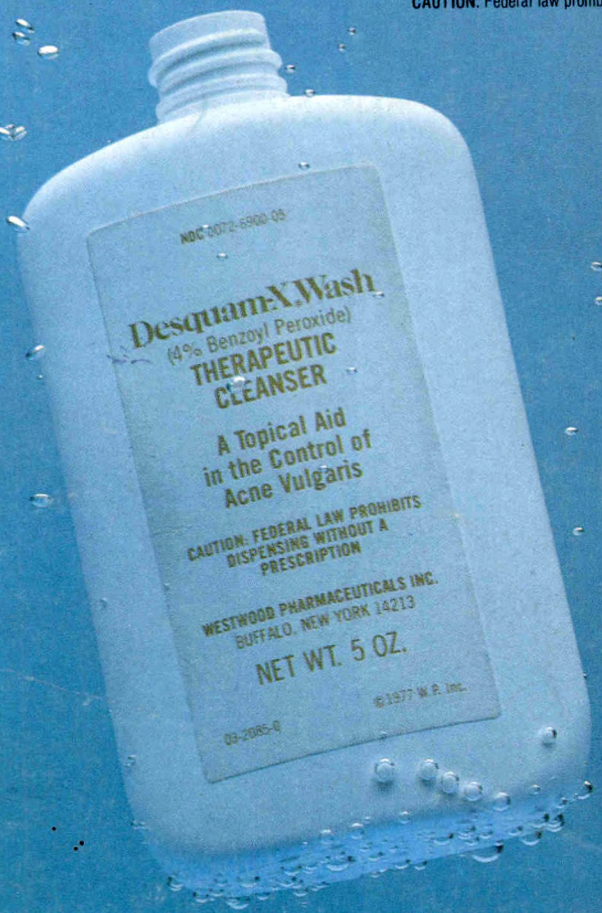

WESTWOOD
PHARMACEUTICALS INC.
Buffalo, New York 14213

©1978, W.P. Inc.

Published by the American Medical Association

March 1978
Volume 114, Number 3

archives of Dermatology

Malignant Melanoma ... *J. P. Callen, J. J. Chanda, M. A. Stawiski* 369

Trichophytin Reactions in Children With Tinea Capitis ... *J. E. Rasmussen, A. R. Ahmed* 371

Generalized Argyria ... *R. J. Pariser* 373

Relationship Between Arsenic Intake and Internal Malignant Neoplasms ... *F. Reymann, R. Møller, A. Nielsen* 378

Diaper Area Granuloma of the Aged ... *Y. Maekawa, Y. Sakazaki, T. Hayashibara* 382

Effects of Occlusive Tape Systems on the Mitotic Activity of Epidermis ... *L. B. Fisher, H. I. Maibach, R. J. Trancik* 384

Photochemotherapy of Psoriasis (PUVA) Without Specialized Equipment ... *J. W. Petrozzi, A. M. Kligman* 387

Atopic Dermatitis, Impaired Cellular Immunity, and Molluscum Contagiosum ... *C. R. Pauly, W. M. Artis, H. E. Jones* 391

Lymphangioma Circumscriptum ... *L. C. Palmer, W. G. Strauch, W. A. Welton* 394

Mycosis Fungoides Involving the Brain and Optic Nerves ... *D. M. Pariser* 397

Reticular Pigmented Anomaly of the Flexures ... *J. B. Howell, R. G. Freeman* 400

Mal Perforans and Spina Bifida Occulta ... *D. S. Lockman, T. M. Jones, D. C. Abele, E. Obbens* 404

Varicella-like Infection Due to Herpes Simplex ... *J. C. Long, C. E. Wheeler, Jr, R. A. Briggaman* 406

Lupus Mastitis ... *R. B. Harris, R. K. Winkelmann* 410

Febrile Neutrophilic Dermatosis in Acute Myelogenous Leukemia ... *S. S. Raimer, W. C. Duncan* 413

Cicatricial Pemphigoid and Rheumatoid Arthritis ... *C. T. Spigel, R. K. Winkelmann* 415

Monocytic Leukemia ... *G. Burg, C. Schmoeckel, O. Braun-Falco, H. H. Wolff* 418

Primary Adenoid Cystic Carcinoma of Skin ... *J. T. Headington, R. Teears, J. E. Niederhuber, R. P. Slinger* 421

Plane Xanthoma and Multiple Myeloma With Lipoprotein—Paraprotein Complexing ... *J. S. Taylor, L. A. Lewis, J. D. Battle, Jr, A. Butkus, A. L. Robertson, S. Deodhar, H. H. Roenigk, Jr* 425

Secondary Cutaneous Mucinosis With Systemic Lupus Erythematosus ... *W. R. Gammon, I. Caro, J. C. Long, C. E. Wheeler, Jr* 432

Inflammatory Linear Verrucose Epidermal Nevus ... *S. J. Hodge, J. M. Barr, L. G. Owen* 436

Uveitis, Poliosis, Hypomelanosis, and Alopecia in a Patient With Malignant Melanoma ... *A. J. Sober, H. A. Haynes* 439

Contact Dermatitis to Homomenthyl Salicylate ... *R. L. Rietschel, C. W. Lewis* 442

AMA AMERICAN MEDICAL ASSOCIATION LIBRARY

Reservoir of moisture

ıch bath with Alpha Keri® Therapeutic Bath Oil is a reservoir of moisture for dry skin. ıe addition of Alpha Keri in the bath helps skin store moisture for days. And feel soft, ıooth, and supple in minutes. (Between baths, a single application of Keri® Lotion tantly restores moisture to dry skin for hours.)

Alpha Keri®

Therapeutic Bath Oil

helps skin keep in touch with moisture

PDR for complete
ıuct information.

ESTWOOD
RMACEUTICALS INC.
alo, New York 14213

© 1976, W. P. Inc.

Take a close look at



Cordran® SP
flurandrenolide

New, improved formulation provides these advantages over original Cream Cordran*

- greater solubility for faster, more complete absorption and, therefore, faster action
- increased vasoconstrictive activity
- greater efficacy in psoriasis
- contains no potentially sensitizing preservatives

*Data on file, Dista Products Company.

Cream Cordran® SP
and
Ointment Cordran®
flurandrenolide

Brief Summary. Consult the package literature for prescribing information.
Description: Cordran is a potent corticosteroid intended for topical use.
Actions: Cordran is primarily effective because of its anti-inflammatory, antipruritic, and vasoconstrictive actions.
Indications: For relief of the inflammatory manifestations of corticosteroid-responsive dermatoses.
Contraindications: Topical corticosteroids are contraindicated in vaccinia and varicella and in patients with a history of hypersensitivity to any of their components.
Precautions: If irritation develops, the product should be discontinued and appropriate therapy instituted.

In the presence of an infection, an appropriate antifungal or antibacterial agent should be used. If a favorable response does not occur promptly, the corticosteroid should be discontinued until the infection has been adequately controlled.

If extensive areas are treated or if the occlusive technique is used, there is a possibility of increased systemic absorption of the corticosteroid, and suitable precautions should be taken.

Although topical corticosteroids have not been reported to have an adverse effect on pregnancy, the safety of their use on pregnant women has not been absolutely established. Therefore, they should not be used extensively, in large amounts, or for prolonged periods of time on pregnant patients.

These products are not for ophthalmic use.
Adverse Reactions: The following local adverse reactions have been reported with topical corticosteroid formulations: acneform eruptions, burning, dryness, folliculitis, hypertrichosis, hypopigmentation, irritation, itching.

The following may occur more frequently with occlusive dressings: maceration of the skin, miliaria, secondary infection, skin atrophy, striae.
Administration and Dosage: For moist lesions, a small quantity of the cream should be rubbed gently into the affected areas two or three times a day. For dry, scaly lesions, the ointment is applied as a thin film to affected areas two or three times daily. [122277]

Additional information available to the profession on request.

DISTA
Dista Products Company
Division of Eli Lilly and Company
Indianapolis, Indiana 46206

800194

Archives of DERMATOLOGY

Copyright © 1978 by the AMERICAN MEDICAL ASSOCIATION

VOL 114, NO. 3 MARCH 1978

EDITORIAL

Malignant Melanoma
Jeffrey P. Callen, MD, Louisville; Joseph J. Chanda, MD; Marek A. Stawiski, MD, Ann Arbor, Mich 369

ORIGINAL CONTRIBUTIONS

Trichophytin Reactions in Children With Tinea Capitis
James E. Rasmussen, MD, A. Razzaque Ahmed, MD, Buffalo, NY 371

Generalized Argyria
Robert J. Pariser, MD, Miami 373

Relationship Between Arsenic Intake and Internal Malignant Neoplasms
Flemming Reymann, MD; Rigmor Møller, MD; Arne Nielsen, MSc, Copenhagen 378

Diaper Area Granuloma of the Aged
Yoshihiro Maekawa, MD; Yoshikado Sakazaki, MD; Toshio Hayashibara, MD, Kumamoto, Japan 382

Effects of Occlusive Tape Systems on the Mitotic Activity of Epidermis
Louis B. Fisher, PhD, La Jolla, Calif; Howard I. Maibach, MD, San Francisco; Ronald J. Trancik, PhD, St Paul 384

Photochemotherapy of Psoriasis (PUVA) Without Specialized Equipment
John W. Petrozzi, MD, Albert M. Kligman, MD, PhD, Philadelphia 387

CASE REPORTS

Atopic Dermatitis, Impaired Cellular Immunity, and Molluscum Contagiosum
Charles R. Pauly, MD; William M. Artis, PhD; Henry E. Jones, MD, Ann Arbor, Mich 391

Lymphangioma Circumscriptum
Louis C. Palmer, MD; William G. Strauch, MD; William A. Welton, MD, Morgantown, WV 394

Mycosis Fungoides Involving the Brain and Optic Nerves
David M. Pariser, MD, Miami 397

Reticular Pigmented Anomaly of the Flexures
J. B. Howell, MD, Robert G. Freeman, MD, Dallas 400

Mal Perforans and Spina Bifida Occulta
David S. Lockman, MD; Terry M. Jones, MD; Donald C. Abele, MD; Eugenie Obbens, MD, Augusta, Ga 404

Varicella-like Infection Due to Herpes Simplex
John C. Long, MD; Clayton E. Wheeler, Jr, MD; Robert A. Briggaman, MD, Chapel Hill, NC 406

Lupus Mastitis
Russell B. Harris, MD, R. K. Winkelmann, MD, PhD, Rochester, Minn 410

Febrile Neutrophilic Dermatosis in Acute Myelogenous Leukemia
Sharon Smith Raimer, MD, W. Christopher Duncan, MD, Houston 413

Cicatricial Pemphigoid and Rheumatoid Arthritis
C. Thomas Spigel, MD, R. K. Winkelmann, MD, PhD, Rochester, Minn 415

(Continued on page 312)

EDITORIAL BOARD

Chief Editor
John H. Epstein, MD
450 Sutter Street
San Francisco 94108

Assistant Chief Editor
Kimie Fukuyama, MD
San Francisco

Assistant Chief Editor
Denny L. Tuffanelli, MD
San Francisco

Donald C. Abele, MD
Augusta, Ga.

Harry L. Arnold, Jr, MD
Honolulu

Walter C. Lobitz, Jr, MD
Portland, Ore

Frederick D. Malkinson, MD
Chicago

Sigfrid A. Muller, MD
Rochester, Minn

W. Mitchell Sams, Jr, MD
Chapel Hill, NC

John S. Strauss, MD
Iowa City

Gerald D. Weinstein, MD
Miami

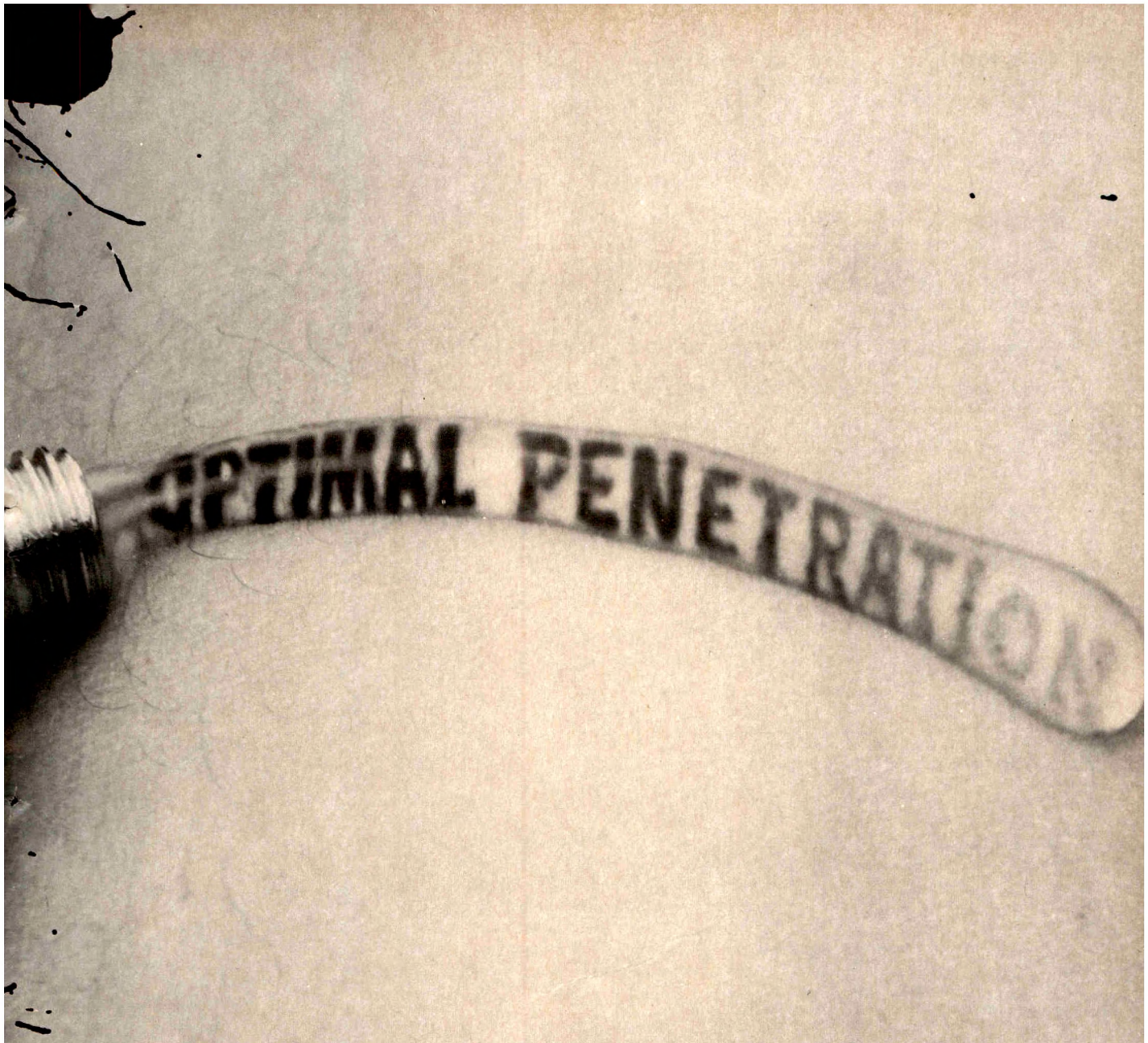

a completely dissolved hydrocortisone for optimal cutaneous penetration with a rapid release vehicle for maximum hydrocortisone effectiveness

nutracort® Gel

(1.0% Hydrocortisone Gel)

DESCRIPTION: Nutracort® Gel 1.0% provides 1.0% hydrocortisone in a non-aqueous clear gel base containing propylene glycol, alcohol 22% (w/w), hydroxypropyl cellulose, and citric acid. CONTRAINDICATIONS: In viral diseases of the skin such as varicella and vaccinia and in patients with a history of hypersensitivity to any component. Not for ophthalmic use. Topical steroids should not be used when circulation is markedly impaired. PRECAUTIONS: If irritation develops, discontinue and institute appropriate therapy. In presence of infection, use of appropriate antifungal or antibacterial agents should be instituted. If a favorable response is not obtained promptly, discontinue until the infection has been adequately controlled. Suitable precautions should be taken against increased systemic absorption which may occur if extensive areas are treated or if the occlusive technique is used. Should not be used extensively, in large amounts, or for prolonged periods in pregnancy.

ADVERSE REACTIONS: Burning sensation, itching, irritation, dryness, folliculitis, secondary infection, skin atrophy, striae, hypertrichosis, acneform eruptio and hypopigmentation have been reported with or without occlusive dressings. DOSAGE: Apply to affected areas 3 to 4 times daily. HOW SUPPLIED: Nutracort® Gel (1.0% hydrocortisone gel) is available in a 60 gram tube. Nutracort® Lotion is available in 0.25%, 0.5% and 1.0% strengths, 2 oz. and 4 oz. bottl Nutracort® Cream available in 0.25%, 0.5% and 1.0% strengths, 2 oz. and 4 oz. jars. Nutracort® Cream 1.0% also available in 1 lb. jars.

Owen Owen Laboratories
Dallas, Texas 75234
Division of Alcon Laboratories, Inc.

CONTENTS—Continued

Monocytic Leukemia
Günter Burg, MD; Christian Schmoeckel, MD; Otto Braun-Falco, MD; Helmut H. Wolff, MD, Munich, West Germany 418

Primary Adenoid Cystic Carcinoma of Skin
John T. Headington, MD; Robert Teears, MD; John E. Niederhuber, MD; Robert P. Slinger, MD, Ann Arbor, Mich 421

Plane Xanthoma and Multiple Myeloma With Lipoprotein—Paraprotein Complexing
James S. Taylor, MD; Lena A. Lewis, PhD; John D. Battle, Jr, MD; Antanas Butkus, PhD; Abel L. Robertson, MD, PhD; Sharad Deodhar, MD, PhD; Henry H. Roenigk, Jr, MD, Cleveland 425

Secondary Cutaneous Mucinosis With Systemic Lupus Erythematosus
Walter R. Gammon, MD; Ivor Caro, MD; John C. Long, MD; Clayton E. Wheeler, Jr, MD, Chapel Hill, NC 432

Inflammatory Linear Verrucose Epidermal Nevus
Steven J. Hodge, MD; James M. Barr, MD; Lafayette G. Owen, MD, Louisville 436

Uveitis, Poliosis, Hypomelanosis, and Alopecia in a Patient With Malignant Melanoma
Arthur J. Sober, MD, Harley A. Haynes, MD, Boston 439

Contact Dermatitis to Homomenthyl Salicylate
Maj Robert L. Rietschel, MC, USA, Col Charles W. Lewis, MC, USA, Fort Sam Houston, Tex 442

IN MEMORIAM

Clark Wylie Finnerud, MD
Marion B. Sulzberger, MD, San Francisco 444

REGULAR DEPARTMENTS

Letters to the Editor 446

Contact Dermatitis Due to Clindamycin Ralph J. Coskey, MD, Detroit . . . **Unilateral Nevoid Telangiectasia** Jean-Paul Ortonne, MD; Gérard Guillet, MD; Henri Perrot, MD, Lyon, France . . . **Ulcerative Sarcoidosis** Mark Meyers, MD, Sidney Barsky, MD, Chicago . . . **Photo-Onycholysis Secondary to Psoralen Use** Robert C. Rau, MD; Franklin P. Flowers, MD; James L. Barrett, MD, Columbus, Ohio . . . **Herpes Gestationis** Judith H. Schiffner, MD; Thomas H. Rea, MD; Francisco P. Quismorio, MD, Los Angeles

Short Reports 457

Kindler's Syndrome Joseph C. Alper, MD, Providence, RI; Howard P. Baden, MD, Boston; Lowell A. Goldsmith, MD, Durham, NC . . . **Bromoderma** Stephen Z. Smith, MD, S. Randolph Scheen, MD, Louisville . . . ***Cysticercus cellulosae* Cutis** Lt Comdr David Schlossberg, MC, USNR, Lt Comdr Jon T. Mader, MC, USNR, Portsmouth, Va . . . **Perianal Basal Cell Carcinoma** Capt Eric W. Kraus, MC, USA, Fort Sam Houston, Tex . . . **Breast Carcinoma Metastatic to the Eyelids** Virginia M. Weimar, MD; Roger I. Ceilley, MD; C. Norman Hurwitz, MD, Iowa City

News and Notes 465

Books 469

Index to Advertisers 472

Instructions for Authors 316

SUBSCRIPTION RATES: The yearly rate of the ARCHIVES OF DERMATOLOGY is as follows: United States and US Possessions, one year, $18; two years, $28; all other countries, one year, $28; two years, $38. Special yearly price to residents, interns and medical students in the United States and US Possessions, $9.

THE ARCHIVES OF DERMATOLOGY is published monthly by the American Medical Association, 535 N Dearborn St, Chicago, IL 60610, and is an official publication of the Association. Second-class postage paid at Chicago and at additional mailing office.



IMPROVED

SELSUN® ℞

(SELENIUM SULFIDE LOTION, U.S.P.)

- **Nicer fragrance**
- **Lighter color**
- **Richer sudsing**
- **Same efficacy and safety**

as the formula proved in millions of cases for over a quarter century

BRIEF SUMMARY

Contains: Selenium sulfide, 2½%, w/v; bentonite; lauric diethanolamide; ethylene glycol monostearate; titanium dioxide; amphoteric—2; sodium lauryl sulfate; sodium phosphate (monobasic); glyceryl monoricinoleate; citric acid; captan; perfume; and water.

Indications: For the treatment of dandruff and seborrheic dermatitis of the scalp.

Contraindications: Should not be used by patients allergic to any of its components.

Warnings: Safety for use on infants has not been established.

Precautions: Cutaneous sensitization of the scalp or adjacent areas has been reported; if sensitivity reactions should occur, discontinue use. Chemical conjunctivitis may result if product enters the eyes. Do not use when acute inflammation or exudation is present as an increase in absorption may occur.

Adverse Reactions: As with other shampoos, oiliness or dryness of the hair and scalp may occur following use; there have been occasional reports of an increase in the amount of normal hair loss. Hair discoloration may occur; can be avoided or minimized by thorough rinsing.

8033233



IMPROVED

Selsun®... the sweet smell of success.

(SELENIUM SULFIDE LOTION, U.S.P.) ℞

- Nicer fragrance
- Lighter color
- Richer sudsing
- Same efficacy and safety

ease see opposite page
Brief Summary.

ABBOTT

Archives of Dermatology

James H. Sammons, MD
Executive Vice-President

Thomas F. Hannon
Group Vice-President,
Publishing Operations

William R. Barclay, MD
Group Vice-President,
Scientific Publications

Norman D. Richey
Director, Publication
Production Division

John T. Baker
Director, Marketing Division

Helen R. Mazur
Director, Circulation-Fulfillment

John T. Baker, General Sales Manager; **Robert Corcoran,** Eastern Sales Manager; **Fred Bauman, Richard M. Johnson,** Eastern Sales Representatives; **Alice Harvey, William J. Healy,** Midwest Sales Representatives; **Thomas J. Carroll,** West Coast/Northern Sales Representative

PUBLICATION STAFF

Offices: 535 N Dearborn St
Chicago, IL 60610

Robert W. Mayo
Executive Editor and Director,
Scientific Publications Division

Sandra Williamson
Administrative Assistant

Marlene M. Hinsch, Production Manager

Editorial Processing Manager: Diana A. Morgan

Copy Editing: Rosanne Schulenberg (Supervisor), Patti Narret, Kathy Swartz

Proofreading: Lorraine L. Kruse (Supervisor), Verna Coffman, Patricia Coyne, Elizabeth Petrikenas, Patricia Poznanski, Mary Kay Tinerella, Dorothy Troy

Production Supervisors: Julia Bero (Layout), Thomas J. Handrigan (Illustrations), Marlene M. Hinsch (Editorial), James P. Bagniewski (Advertising)

Art and Senior Production Assistants: Betty Frigerio, Floriana Hayes, Shirley Latronica, Donna Pender, Nancy Keyes, Marilyn Moroney, Susan Routhier, JoAnne Weiskopf

Production Assistants: Karen Branham, E. Linda Eisenberg, Anna Goins, Lucille Kuznicki, Elaine Starks

Manuscript Records: Denise Henderson

Indexing: Phyllis H. O'Donnell (Supervisor), Jane P. Mauldin, Helen F. Topel

Please address communications concerning accepted or published communications to: AMA Specialty Journals, 535 N Dearborn St, Chicago, IL 60610.

Conditions for Acceptance of Color Illustrations

Illustrations in full color are accepted for publication in ARCHIVES OF DERMATOLOGY if the editor believes that color will add significantly to the published manuscript.

When color illustrations are accepted, the American Medical Association will pay part of the expense of reproduction and printing, the remainder to be borne by the author or the institution with which he is affiliated. After deducting AMA's contribution, the author's share is $275 for up to six square finished illustrations. Additional illustrations and special effects, such as outlining, opaquing, or surprinting, will be billed to the author at cost.

Color transparencies must be submitted for evaluation. Do not send color prints unless accompanied by original transparencies. If transparencies are mounted in frames or glass, the material should be carefully packed in gauze and sent with the manuscript in a separate container or between two pieces of pressboard.

Advertising and Subscription Information

ADVERTISING OFFICES: 535 N Dearborn St, Chicago, IL 60610, Area Code 312, 751-6000; and 600 Third Ave, New York, NY 10016, Area Code 212-867-6640.

ADVERTISING PRINCIPLES: Each advertisement in this issue has been reviewed and complies with the principles governing advertising in AMA scientific publications. A copy of these principles is available on request.

CHANGE OF ADDRESS: Please notify the publisher at least six weeks in advance, including both old and new address, and a mailing label taken from the most recent copy. Include your new zip code number.

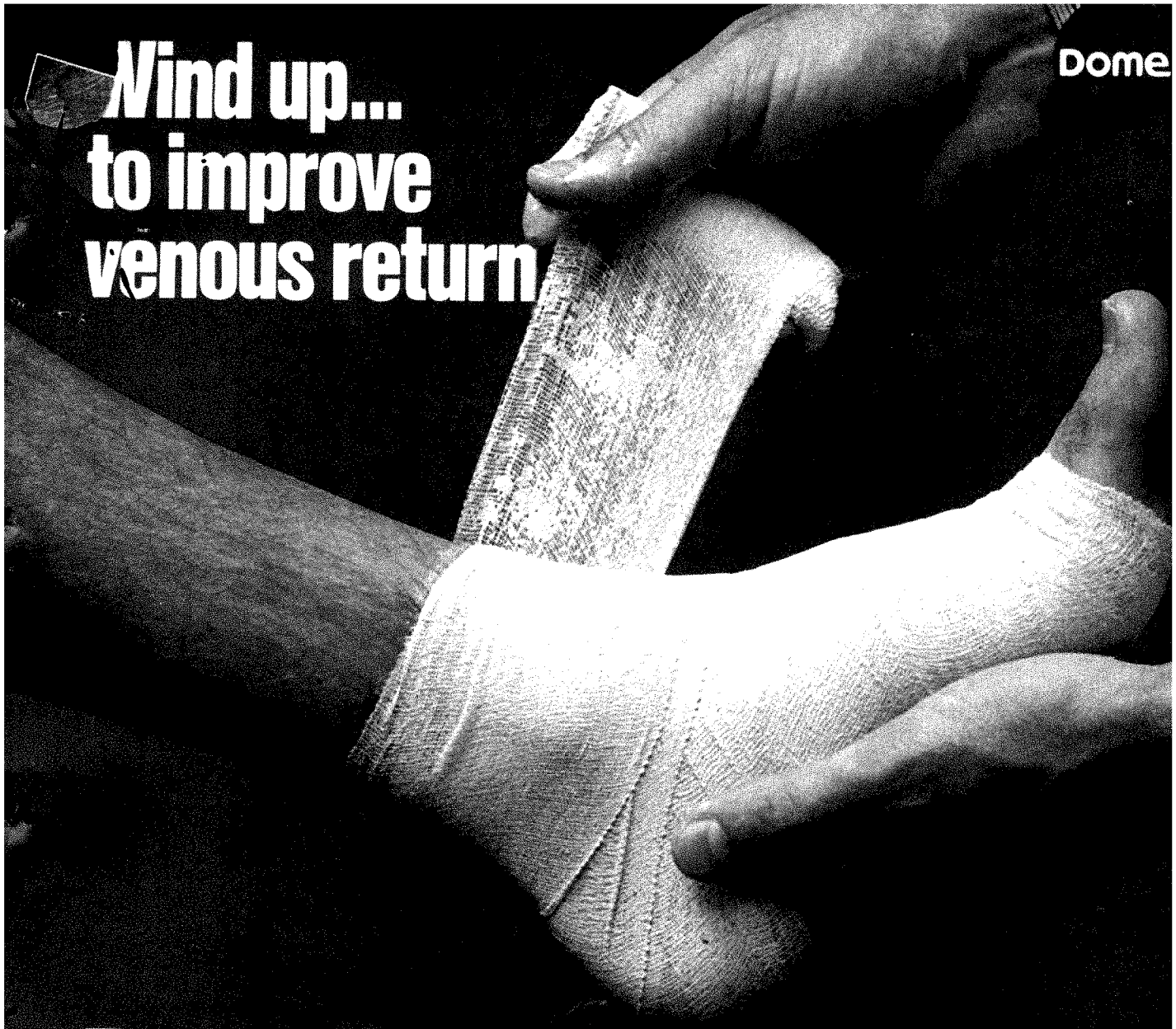

Dome-Paste® Bandage

Modified Unna's Boot

Encourages healing of skin lesions... contributes to patient's comfort

Now a new 3-inch width... easy application for smaller limbs, fewer wrinkling problems than with fraying bandages, greater economy.

- ☐ Also in standard 4-inch width with nonraveling, thread-locked edges.
- ☐ Both sizes in 10-yard rolls; neutral-colored, rayon-reinforced for strength.
- ☐ Uniformly impregnated with zinc oxide, gelatin, calamine.
- ☐ Each roll sealed in a polyethylene bag to preserve freshness.
- ☐ Always ready for immediate use.

DOM-1386R2

Dome Laboratories

Division Miles Laboratories Inc MILES
West Haven Connecticut 06516 USA

Instructions for Authors

Send manuscripts by first-class mail to the Chief Editor, John H. Epstein, MD, 450 Sutter St, San Francisco, CA 94108. Manuscripts are received with the understanding that they are not under simultaneous consideration by another publication. Accepted manuscripts become the permanent property of the ARCHIVES and may not be published elsewhere without permission from the publisher (AMA).

In addition, in view of *The Copyright Revision Act of 1976*, effective Jan 1, 1978, transmittal letters to the editor should contain the following language: "In consideration of the American Medical Association taking action in reviewing and editing my submission, the author(s) undersigned hereby transfers, assigns, or otherwise conveys all copyright ownership to the AMA in the event that such work is published by the AMA." We regret that transmittal letters not containing the foregoing language signed by all authors of the submission will necessitate delay in review of the manuscript.

Author Responsibility.—All accepted manuscripts are subject to copy editing. The author will receive an edited typescript rather than galley proofs for approval. The author is responsible for all statements in his work, including changes made by the copy editor.

Designate one author as correspondent and provide his address and telephone number. Order reprints at the time the typescript is returned after editorial processing. Specify address to which requests for reprints should be sent.

Manuscript Preparation.—Submit an original typescript and two high-quality copies of the entire manuscript. All copy (including references, legends, and tables) must be typed double-spaced on 22 × 28-cm (8½ × 11-inch), heavy-duty white bond paper. Ample margins should be provided.

Refer to patients by number (or, in anecdotal reports, by fictitious given names). Real names or initials should not be used in the text, tables, or illustrations.

Titles.—Titles should be short, specific, and clear. They should not exceed 42 characters per line, including punctuation and spaces, and be limited to two lines, if possible. The title page should include the full names and academic affiliations of all authors, the address to which requests for reprints should be sent, and, if the manuscript was presented at a meeting, the name of the organization, place, and date on which it was read.

Style of Writing.—The style of writing should conform to acceptable English usage and syntax. Slang, medical jargon, obscure abbreviations, and abbreviated phrasing are to be avoided.

Informed Consent.—Manuscripts reporting the results of experimental investigations of human subjects must include a statement to the effect that informed consent was obtained after the nature of the procedure(s) had been fully explained.

Abstract.—Provide an abstract (135-word maximum) of the article, including statements of the problem, method of study, results, and conclusions. The abstract replaces the summary.

References.—List references in consecutive numerical order (not alphabetically). Once a reference is cited, all subsequent citations should be to the original number. All references must be cited in the text or tables. Unpublished data and personal communications should not be listed as references. References to journal articles should include (1) author(s), (2) title, (3) journal name (as abbreviated in *Index Medicus*), (4) volume number, (5) inclusive page numbers, and (6) year, in that order. References to books should include (1) author(s), (2) chapter title (if any), (3) editor (if any), (4) title of book, (5) city of publication, (6) publisher, and (7) year. Volume and edition numbers, specific pages, and name of translator should be included when appropriate. The author is responsible for the accuracy and completeness of the references and for their correct text citation.

Metrication.—All measurements must be in metric units. English units may also be given parenthetically if the measurements were originally done in English units.

Illustrations.—Use only those illustrations that clarify and augment the text. Submit illustrations in duplicate, unmounted and untrimmed. Do not send original artwork. Send high-contrast glossy prints (not photocopies). Figure number, name of senior author, and arrow indicating "top" should be typed on a gummed label and affixed to the back of each illustration. All lettering must be legible after reduction to column size. Artwork submitted for publication may be relettered to achieve uniformity of lettering style throughout the journal. Magnification and stain should be provided when pertinent. Illustrations should preferably be in a proportion of 12.5 × 18 cm (5 × 7 inches).

An experienced medical illustrator should be employed whenever possible for the preparation of all artwork. Template lettering or preset type is preferred to hand-lettered labels. If halftone artwork with labels is submitted, affix type and leaders to a clear acetate overlay registered to the base drawing. Labels and leaders should be applied directly to the drawing board surface if the artwork consists only of line ink technique.

Illustrations in full color are accepted for publication if the editors believe that color will add significantly to the published manuscript. The ARCHIVES will pay part of the expense of reproduction and printing color illustrations, the remainder to be borne by the author or his sponsor. After deducting the ARCHIVES contribution, the author's share is $275.00 for up to six square-finished illustrations that can be arranged on a one-page layout. Any additional illustrations or special effects will be billed to the author at cost. Positive color transparencies (35 mm preferred) must be submitted for an evaluation. Do not send color prints unless accompanied by original transparencies. All transparencies should be carefully packed and sent with the manuscript.

Legends.—Legends should be typed double-spaced, beginning on a separate sheet of paper. Length should be limited to a maximum of 40 words.

Photographic Consents.—A letter of consent must accompany all photographs of patients in which a possibility of identification exists. It is not sufficient to cover the eyes to mask identity.

Acknowledgments.—Illustrations from other publications must be acknowledged. Include the following when applicable: author(s), title of article, title of journal or book, volume number, page(s), month, and year. The publisher's permission to reprint should be submitted to the ARCHIVES after the manuscript has been formally accepted.

Statistical Review.—Manuscripts containing statistical evaluations should include the name and affiliation of the statistical reviewer.

Tables.—Each table should be typed double-spaced, including all headings, on a separate sheet of 22 × 28-cm (8½ × 11-inch) paper. Do not use larger size paper. If a table must be continued, use a second sheet and repeat all heads and stubs. Each table must have a title.

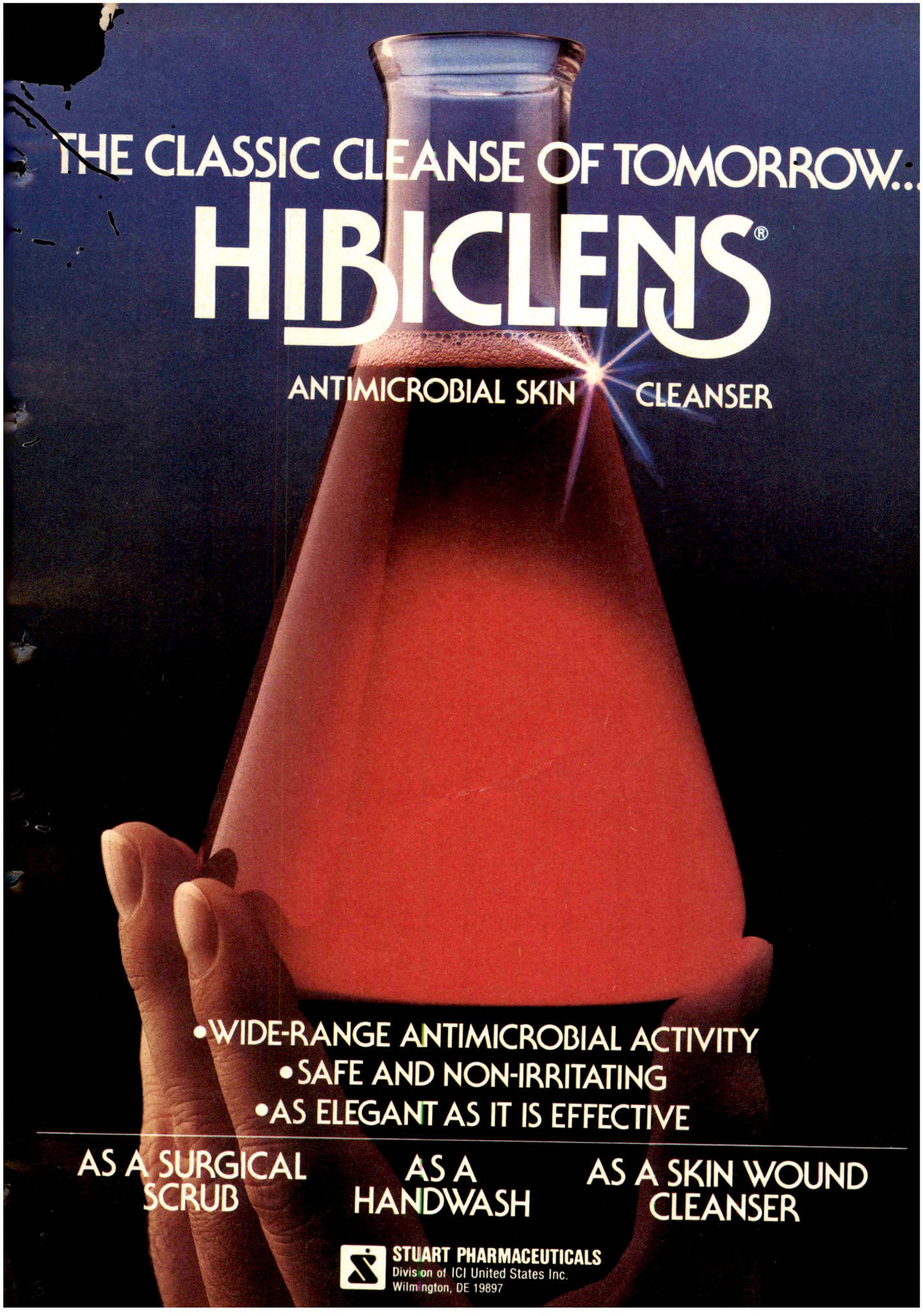
THE CLASSIC CLEANSE OF TOMORROW...
HIBICLENS®
ANTIMICROBIAL SKIN CLEANSER
•WIDE-RANGE ANTIMICROBIAL ACTIVITY
•SAFE AND NON-IRRITATING
•AS ELEGANT AS IT IS EFFECTIVE
AS A SURGICAL SCRUB
AS A HANDWASH
AS A SKIN WOUND CLEANSER
STUART PHARMACEUTICALS
Division of ICI United States Inc.
Wilmington, DE 19897

Get down to the level of normal skin.

Remove hyperkeratotic build up safely and effectively.



Keralyt® Gel is clear, and easy to apply. Keralyt Gel's mechanism of action is believed to be its ability to dissolve the intracellular material that binds the cells of the stratum corneum, thus aiding the simple, safe removal of excessive hyperkeratotic skin.

Keralyt's keratolytic action is an important preliminary to other topical agents. After the hyperkeratotic barrier is removed, tar, steroids, and other therapy can function with less impediment.

Keralyt® GEL

NDC-0072-6500-01

Rx CAUTION: FEDERAL LAW PROHIBITS DISPENSING WITHOUT PRESCRIPTION.

CONTENTS: 6% salicylic acid in a gel containing propylene glycol (60%), ethyl alcohol (19.4%), hydroxypropyl cellulose and water.

ACTION AND USES:

For Dermatological Use: Keralyt is a topical aid in the removal of excessive keratin in hyperkeratotic skin disorders, including the various ichthyoses (vulgaris, sex-linked and lamellar), keratosis palmaris and plantaris, keratosis pilaris, pityriasis rubra pilaris, psoriasis (including body, scalp, and palms and soles). Keralyt has been reported as helpful as adjunctive therapy for fungal infections.

For Podiatric Use: Keralyt is a topical aid in the removal of excessive keratin in dorsal and plantar hyperkeratotic lesions. Keralyt has been reported as helpful as adjunctive therapy for verruca plantaris.

DIRECTIONS FOR USE: The preferable method of use is to apply thoroughly to the affected area and place under occlusion at night. The skin should be hydrated for at least five minutes prior to application. The medication is washed off in the morning, and if excessive drying and/or irritation is observed, a bland cream or lotion may be applied. Once clearing is apparent, the occasional use of Keralyt will usually maintain the remission. In those areas where occlusion is difficult or impossible, application may be made more frequently, and hydration by wet packs or baths prior to application apparently enhances the effect. Unless hands are being treated, rinse hands thoroughly following application.

CONTRAINDICATIONS: Not to be used in patients known to be sensitive to any ingredient of Keralyt.

PRECAUTIONS: In view of the salicylic acid content, use in children under 12 years of age should be limited to no more than one tube (1 oz.) in 24 hours. Avoid contact with eyes and mucous membranes. For external use only. Keep this and all medications out of reach of children.

HOW SUPPLIED: Plastic tubes 1 oz. (24.8 gm.)

Keralyt® GEL

6% salicylic acid in a gel containing propylene glycol (60%), ethyl alcohol (19.4%), hydroxypropyl cellulose and water.
Please see full prescribing information.

WESTWOOD
PHARMACEUTICALS INC.
Buffalo, New York 14213

©1977, W.P. Inc.

Available only on your prescription.

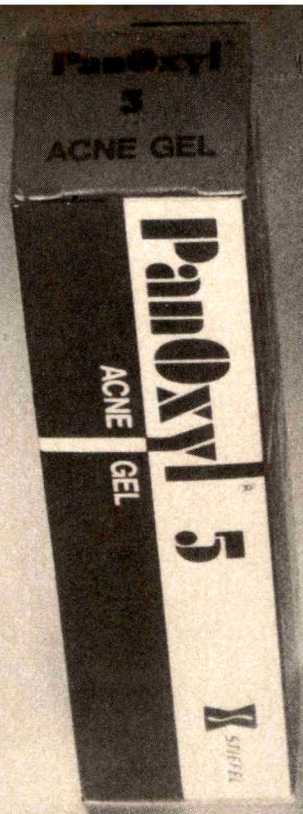

a unique, two step regimen for acne makes better even better

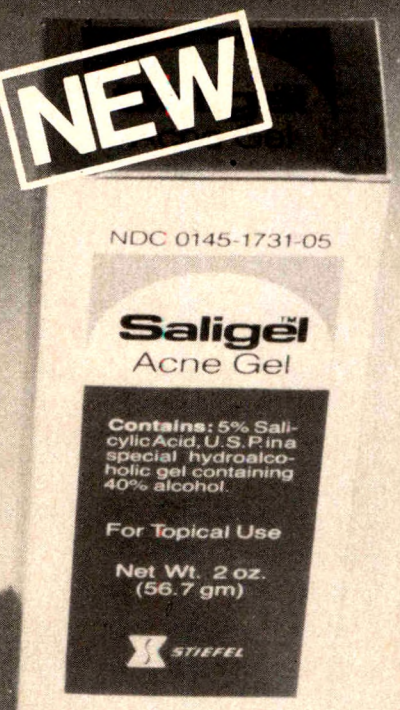

Potent antibacterial action

PanOxyl® (benzoyl peroxide 5% and 10%), because of its effectiveness in reducing *P. acnes* and free fatty acids, revolutionized acne therapy. Recently, the concomitant use of a comedolytic agent such as retinoic acid in the treatment of acne has produced widespread interest[1].

+

Potent comedolytic action

New Saligel™ containing 5% salicylic acid in a special hydroalcoholic gel vehicle, also provides potent comedolytic activity, but without the degree of dermal irritation often seen during retinoic acid therapy. Independent studies confirm the effectiveness and safety of this concept[2,3].

PanOxyl® 5 & PanOxyl® 10

Composition: PanOxyl 5 Gel contains 5% Benzoyl Peroxide, 6% polyoxyethylene lauryl ether and 40% ethyl alcohol in a gel base formulated with colloidal magnesium aluminum silicate, hydroxypropylmethylcellulose, citric acid and purified water. PanOxyl 10 Gel contains 10% Benzoyl Peroxide, 6% polyoxyethylene lauryl ether and 40% ethyl alcohol in a gel base formulated with colloidal magnesium aluminum silicate, hydroxypropylmethylcellulose, citric acid, and purified water.

Caution: Federal Law prohibits dispensing without a prescription.

Action And Uses: The topical use of PanOxyl 5 and PanOxyl 10 provides therapeutic control of acne through drying and desquamative action, as well as providing antiseptic activity.

Indications: Use as an aid in the treatment of acne.

Dosage And Administration: Apply 1 or more times daily to affected areas. Washing the face with soap and water prior to application greatly enhances the efficacy of the medication.

Contraindications: Patients with a known sensitivity to Benzoyl Peroxide should not employ these medications.

Precautions: For external use only. Do not permit products to come in contact with the eyes or mucosal membranes. Keep this and all drugs out of reach of children. Very fair individuals should always be started on a single application at bedtime, allowing the medication to remain on the skin overnight. PanOxyl may bleach hair and colored fabrics. Store below 80F.

How Supplied: 2 oz. and 4 oz. plastic tubes.

Saligel™

Saligel Acne Gel is indicated as a peeling and drying agent in the treatment of acne.

Composition: 5% Salicylic Acid, U.S.P. in a special hydroalcoholic gel containing 40% alcohol.

Directions: Saligel should be applied in the morning and evening, or as required.

Caution: If undue skin irritation develops, discontinue use and consult physician. Avoid getting into eyes or on mucous membranes.

Keep this and all medication out of the reach of children.

Package Information: Saligel is supplied in a 2 ounce plastic tube.

References: 1. Hurwitz, S.: *Cutis*, **17**, 585-590, 1976. 2. Shalita, A. R.: Personal communication. 3. Kligman, A. M.: Personal communication.

Saligel™ Acne Gel

Makes better even better

To obtain Saligel and PanOxyl samples, as well as special patient instruction sheets, write to:

STIEFEL
Logical Dermatologicals

Stiefel Laboratories, Inc.
Oak Hill, N.Y. 12460

7-1331

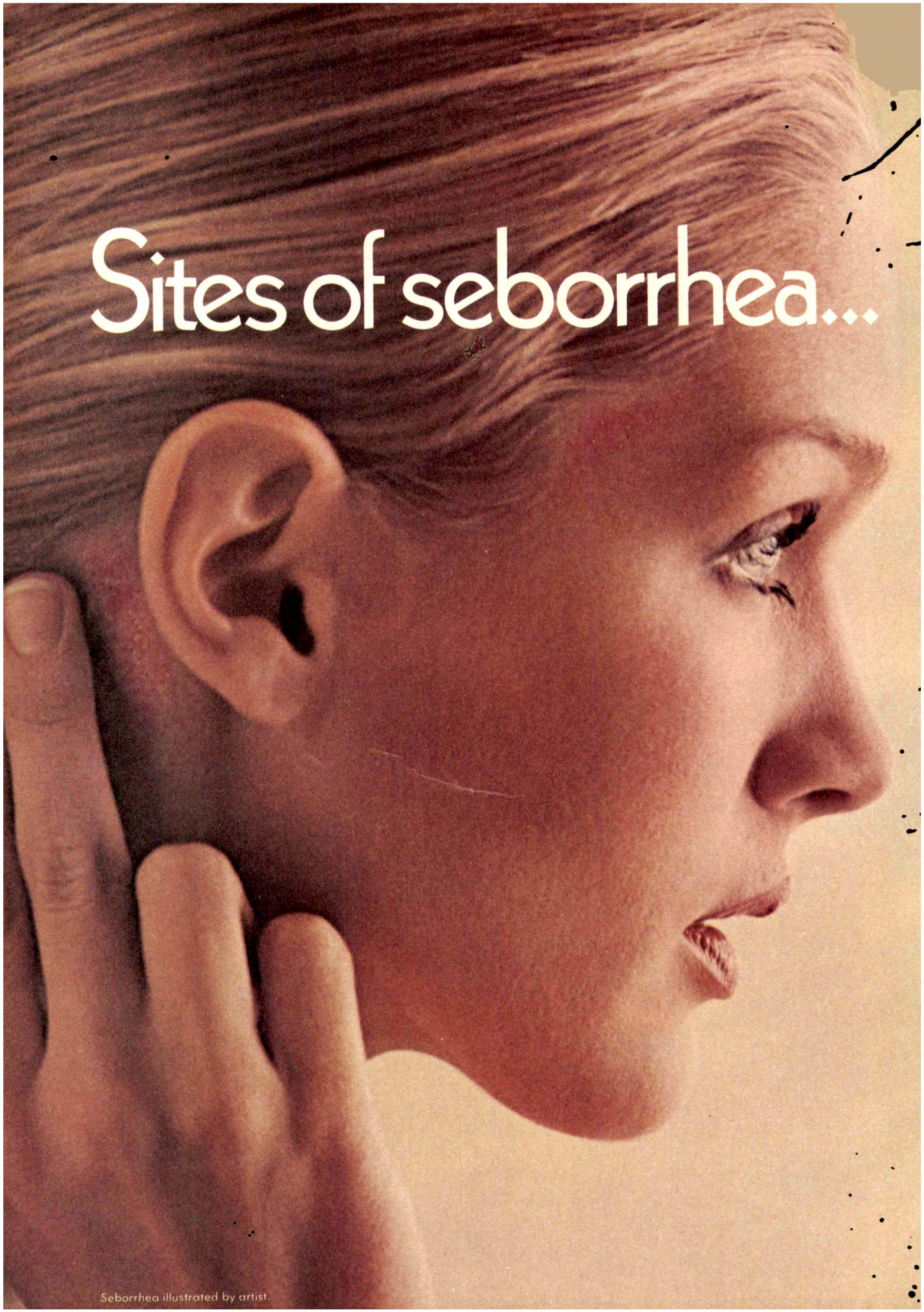
Sites of seborrhea...
Seborrhea illustrated by artist.

spots for Uticort™ (betamethasone benzoate gel, USP)

a highly effective topical steroid in a special base

UTICORT contains the fluorinated corticosteroid ester — betamethasone benzoate 0.025% — in a specially formulated, clear, self-liquefying gel base to increase steroid activity.

Patients with seborrheic dermatitis treated with UTICORT improved 86% in an average of 11.6 days.

liquefies on application for better surface contact

UTICORT is especially valuable in the treatment of seborrheic dermatitis on hairy areas of the body.

cosmetically acceptable

UTICORT dries to a clear film and can be used confidently on either smooth or hairy skin areas. Moreover, it is greaseless, nonstaining, and nonsticky.

preservative free

Contains no parabens or other potentially sensitizing preservatives.

Brief summary of prescribing information

INDICATIONS. Uticort Gel (betamethasone benzoate gel, USP) is intended for relief of the inflammatory manifestations of corticosteroid-responsive dermatoses.

CONTRAINDICATIONS. Topical steroids are contraindicated in viral diseases of the skin, such as varicella and vaccinia. Topical steroids are contraindicated in patients with a history of sensitivity to any of the components of the preparation.

This preparation is not for ophthalmic use.

PRECAUTIONS. If irritation develops, the gel should be discontinued and appropriate therapy instituted. In the presence of an infection, the use of appropriate antifungal or antibacterial agents should be instituted. If a favorable response does not occur promptly, the corticosteroid should be discontinued until the infection has been adequately controlled.

If extensive areas are treated, or if the occlusive technique is used, the possibility exists of increased systemic absorption of the corticosteroid, and suitable precautions should be taken.

Although topical steroids have not been reported to have an adverse effect on pregnancy, the safety of their use in pregnant females has not absolutely been established. Therefore, they should not be used extensively on pregnant patients, or in large amounts, or for prolonged periods of time.

Due to the alcohol content of the vehicle, Uticort Gel (betamethasone benzoate gel, USP) may cause mild, transient stinging without irritation if used on excoriated skin.

ADVERSE REACTIONS. The following local adverse reactions have been reported with topical corticosteroids: burning sensations, itching, irritation, dryness, folliculitis, secondary infection, skin atrophy, striae, hypertrichosis, acneform eruptions, and hypopigmentation.

DOSAGE AND ADMINISTRATION. Apply to affected areas two to four times daily as needed.

HOW SUPPLIED. N 0071-3025 Uticort Gel is supplied in 15 gram and 60 gram tubes.

Caution: Federal law prohibits dispensing without prescription.

PARKE-DAVIS

UE

PD-JA-2343-1-P (1-78)

PARKE, DAVIS & COMPANY Detroit, MI 48232

Superior to the most widely used brand of topical steroid in psoriasis and atopic dermatitis.

Based on the evidence.

In double-blind, parallel studies,* Topicort® (desoximetasone) Emollient Cream 0.25% demonstrated greater efficacy than betamethasone valerate cream 0.1% in the two most common corticosteroid-responsive dermatoses.

		NO. OF PATIENTS	Overall Evaluation: EXCELLENT & GOOD	Overall Evaluation: EXCELLENT (CLEARANCE OF DISEASE)
ATOPIC DERMATITIS	TOPICORT	39	100%	77%
	BETAMETHASONE VALERATE	41	90%	54%
PSORIASIS	TOPICORT	61	84%	43%
	BETAMETHASONE VALERATE	56	63%	21%

These recently conducted U.S. studies confirm the outstanding worldwide acceptance of Topicort in more than 30 countries for up to 4 years.

*Data on file and available upon request from Hoechst-Roussel Pharmaceuticals Inc., Somerville, New Jersey 08876.

Less than 1% incidence of side effects.
Of 488 patients in the clinical trials, side effects were seen in only 4 (0.8%).* And in 2 of the 4 patients, the relationship of side effects to the drug was uncertain.

The convenience of b.i.d. dosage. And the uniqueness of a preservative-free, emollient cream base.
The specially developed, preservative-free Topicort base combines the emollience of an ointment with the cosmetic acceptability of a cream in a water-in-oil emulsion. This makes Topicort (desoximetasone) especially useful in psoriatic and other dry, scaly dermatoses.

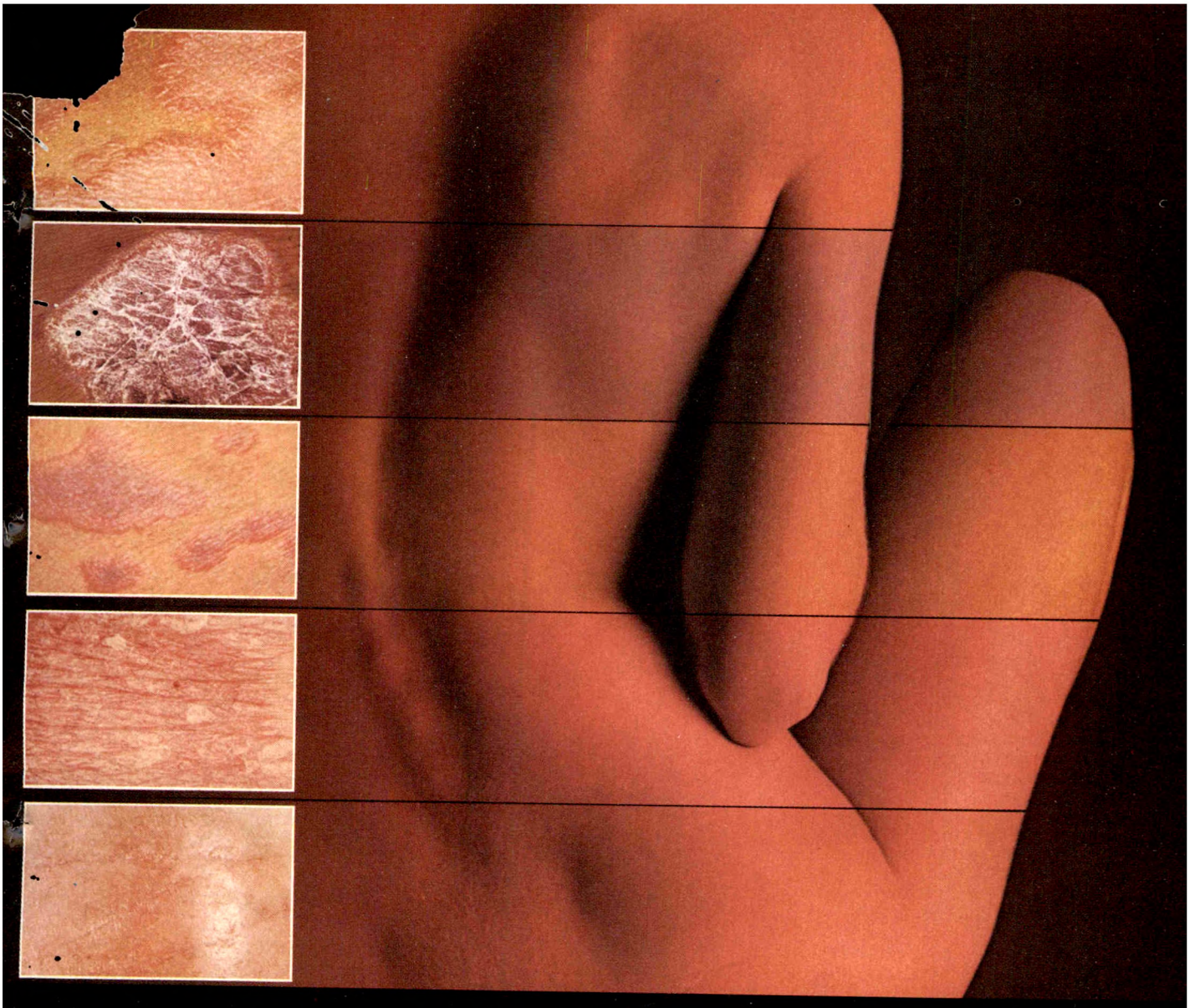

TOPICORT®
(DESOXIMETASONE)
EMOLLIENT CREAM 0.25%

An important innovation from the research laboratories of
Hoechst-Roussel Pharmaceuticals Inc.

Please consult full prescribing information on following page.

EDITION 9/77

TOPICORT®(desoximetasone) EMOLLIENT CREAM 0.25%

Description: Topicort® (desoximetasone) Emollient Cream 0.25% contains the active synthetic corticosteroid desoximetasone. The chemical name of desoximetasone is 9α- fluoro - 11β, 21 - dihydroxy - 16α - methylpregna - 1,4 - diene-3,20-dione. The chemical structure is:

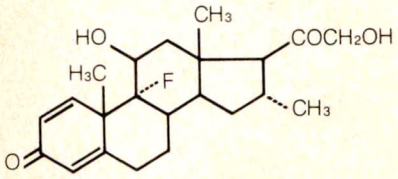

Each gram of Topicort® (desoximetasone) Emollient Cream 0.25% contains 2.5 mg desoximetasone in an emollient cream consisting of isopropyl myristate, cetylstearyl alcohol, white petrolatum, mineral oil, lanolin alcohol and purified water.

Actions: Topicort® (desoximetasone) Emollient Cream is primarily effective because of its anti-inflammatory, antipruritic and vasoconstrictive actions.

Indications: Topicort® (desoximetasone) Emollient Cream is indicated for the relief of inflammatory manifestations of corticosteroid-responsive dermatoses.

Contraindications: Topical steroids are contraindicated in vaccinia, varicella and in those patients with a history of hypersensitivity to any of the components of the preparation. This preparation is not for ophthalmic use.

Precautions: If local infection exists, suitable concomitant antimicrobial or antifungal therapy should be administered. If a favorable response does not occur promptly, application of the corticosteroid should be discontinued until the infection is adequately controlled.

Although systemic side effects associated with absorption of topical corticosteroid preparations are rare, their possible occurrence must be kept in mind when these preparations are used over large areas or for an extended period of time, or if occlusive technique is used.

If irritation or sensitization develops, the preparation should be discontinued and appropriate therapy instituted.

Although topical steroids have not been reported to have an adverse effect on pregnancy, the safety of their use during pregnancy has not been absolutely established; therefore, they should not be used extensively on pregnant patients, in large amounts, or for prolonged periods of time.

Adverse Reactions: The following local adverse reactions have been reported with topical corticosteroids: burning, itching, irritation, striae, skin atrophy, secondary infection, dryness, folliculitis, hypertrichosis, acneform eruptions and hypopigmentation. The following may occur more frequently with occlusive dressings: maceration of the skin, secondary infection, skin atrophy, striae, and miliaria.

Dosage and Administration: Apply a thin film of Topicort® (desoximetasone) Emollient Cream 0.25% to the affected skin areas twice daily. Rub in gently.

How Supplied: Topicort® (desoximetasone) Emollient Cream 0.25% is supplied in 15-gram tubes.

HOECHST-ROUSSEL
PHARMACEUTICALS INCORPORATED
SOMERVILLE, NEW JERSEY 08876



a quick reference to the AMA's large collection of medical films

and its yours free with the coupon below

You'll find nearly 100 pages of medical motion picture titles and descriptions in this new catalog—well over 300 titles and many of them brand new! All are available on loan basis for a slight servic charge.

American Medical Association S/.
535 N. Dearborn St.
Chicago, Ill. 60610
ATTN: Dept. of Audio Visual
Self Learning Programs.

Please send me your catalog:
AMA Medical Health Film Library 1976

Name _____

Title _____

Organization _____

Address _____

City _____

State/Zip _____

P. acnes come out in the Wash

A recent research study showed Desquam-X® Wash (4% BENZOYL PEROXIDE) can reduce P. acnes 87.7% in 1 day*

Purpose of the *in vivo* study was to generate data showing the reduction of anaerobic facial bacteria (P. acnes).

Desquam-X Wash was applied b.i.d. No other acne therapy was administered.

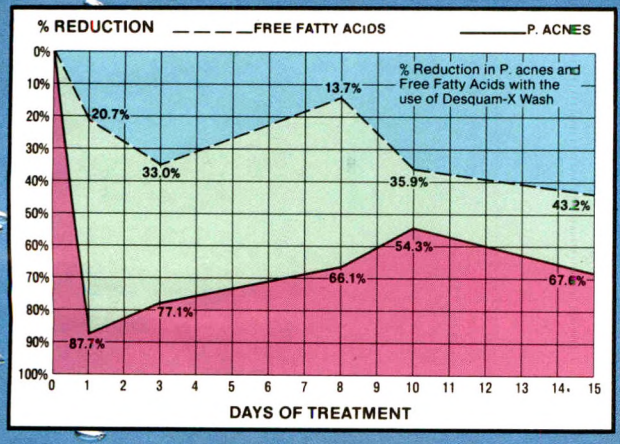

The first benzoyl peroxide cleanser, available only on your Rx.

Desquam-X® Wash (4% Benzoyl Peroxide) THERAPEUTIC CLEANSER

NDC 0072-6900-05

CONTENTS: DESQUAM-X® WASH contains 4% benzoyl peroxide, sodium octoxynol-3-sulfonate, water, sodium dioctyl sulfo-succinate, sodium lauryl sulfoacetate, magnesium aluminum silicate, methocel A4M, EDTA.

INDICATIONS: May be used topically alone for mild to moderate acne vulgaris. In severe, complicated acne Desquam-X Wash may be used as an adjunct to therapeutic regimens which might include antibiotics, retinoic acid products, and/or sulfur and salicylic acid containing preparations.

ACTION: Provides drying and desquamation desirable in the topical treatment of acne. Desquam-X Wash has demonstrated antibacterial activity against Propionibacterium acnes. Desquam-X Wash has also been shown to reduce the concentration of free fatty acids in the sebum.

DIRECTIONS FOR USE: Wash vigorously with Desquam-X Wash once or twice daily, avoiding contact with eyes or mucous membranes. Drying and peeling may be modified by adjusting the dosage schedule.

CONTRAINDICATIONS: Not to be used in patients known to be sensitive to benzoyl peroxide or other ingredients.

PRECAUTIONS: Avoid contact with eyes and mucous membranes. To prevent bleaching, avoid contact with hair. Keep this and all drugs out of the reach of children. For external use only.

NOTE: May bleach colored fabrics. Store below 77°F.

HOW SUPPLIED: Plastic bottles 5 oz. (141.8 g.)

CAUTION: Federal law prohibits dispensing without a prescription.

*Data on file, Westwood Pharmaceuticals.

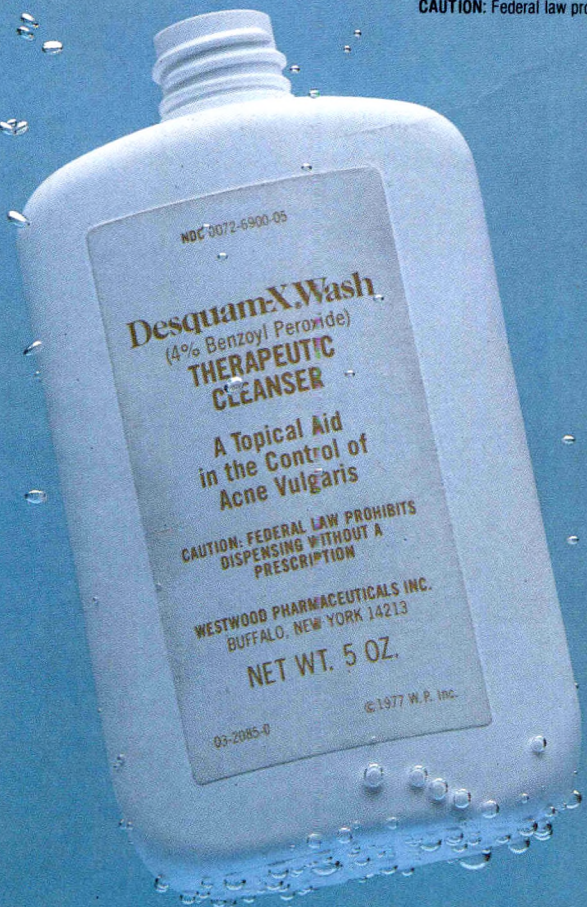

WESTWOOD
PHARMACEUTICALS INC.
Buffalo, New York 14213

©1978, W.P. Inc.

New Desquam-X®

(5 OR 10% BENZOYL PEROXIDE, 6% LAURETH-4)

water base gel is not watered down.

Clinically as effective as the alcohol formulation and even more cosmetically acceptable than before.

One study shows Desquam-X10®
(10% BENZOYL PEROXIDE, 6% LAURETH-4)
reduced P. acnes 99.9% in 3 days*

Purpose of the *in vivo* study was to generate data showing the reduction of anaerobic facial bacteria (P. acnes).

Desquam-X 10 was applied b.i.d. No other acne therapy was administered.

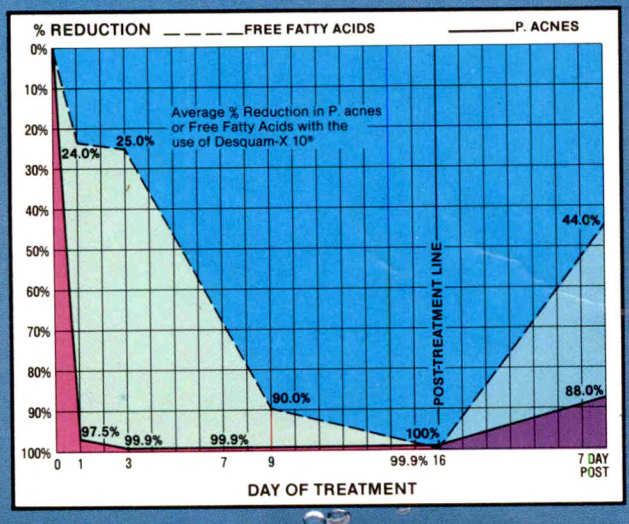

- **Large new 3 oz. tube for patient economy and convenience**
- **Eliminates alcohol sting**

Desquam-X5®	Desquam-X10®
NDC 0072—6621-01—1.5 oz.	NDC 0072—6721-01—1.5 oz.
NDC 0072—6621-03—3 oz.	NDC 0072—6721-03—3 oz.

CONTENTS: Desquam-X5 contains 5% Benzoyl Peroxide, 6% laureth-4, carbomer 940, di-isopropanolamine, disodium edetate and water.

Desquam-X10 contains 10% Benzoyl Peroxide, 6% laureth-4, carbomer 940, di-isopropanolamine, disodium edetate and water.

INDICATIONS: May be used topically alone for mild to moderate acne vulgaris and as an adjunct in therapeutic regimens for severe, complicated acne which might include systemic antibiotics, retinoic acid products and/or sulfur and salicylic acid containing preparations.

ACTION: Provides the desirable drying and desquamation needed in the topical treatment of acne. Desquam-X has been demonstrated to have anti-bacterial effects, especially against Propionbacterium acnes.

DIRECTIONS FOR USE: After washing as instructed, rub Desquam-X into affected areas twice daily. In fair skinned individuals or under excessively dry atmospheric conditions it is suggested that therapy be initiated with one application daily.

The desired degree of drying and peeling can be obtained by modification of the dosage schedule.

CONTRAINDICATIONS: Not to be used in patients known to be sensitive to any ingredient of Desquam-X.

PRECAUTIONS: Avoid contact with eyes and mucous membranes. For external use only. Keep this and all drugs out of the reach of children.

Store below 75°F.

NOTE: May bleach colored fabrics.

HOW SUPPLIED: Plastic tubes 1.5 oz. (42.5g); 3 oz. (85 g).

CAUTION: Federal law prohibits dispensing without prescription.

*Data on file, Westwood Pharmaceuticals.



WESTWOOD
PHARMACEUTICALS INC.
Buffalo, New York 14213

©1978, W.P. Inc.

Food Allergy

"Skin testing with many foods is unreliable and can be dangerous"

Hoffman D R & Haddad Z H:
Diagnosis of IgE mediated reaction to food antigens by radioimmunoassay.
J. Allerg. clin. immunol. 54 (1974) p. 165

Phadebas RAST is a useful adjunct in the diagnosis of IgE mediated food hypersensitivities.

Phadebas RAST®

Pharmacia Diagnostics AB
Uppsala · Sweden

Pharmacia Diagnostics

Argentina Laboratorios Dr. Gador y Cia., S.A.C.I. Casilla de Correo 4041 1006 BUENOS AIRES. **Australia** Pharmacia (South Seas) Pty. Ltd. P.O. Box 175 4 Byfield Street NORTH RYDE N.S.W. 2113. **Austria** Pharmacia Gesellschaft m.b.H. Rathausplatz 4 A-1010 WIEN. **Belgium** N.V. Pharmacia Belga S.A. Bld. Gen. Jacqueslaan 26 B-1050 BRUSSELS. **Brazil** Emprêsa Medimex Importação e Comércio Ltda. Rua Cardoso Marinho, 40 Caixa Postal 33-ZC-00 RIO DE JANEIRO. **Canada** Pharmacia (Canada) Ltd. 2044 boul. St. Régis Blvd. DORVAL, Québec H9P 1H6. **Denmark** Pharmacia AS, Herredsvejen DK-3400 HILLERÖD. **Finland** Pharmacia OY Norrskensvägen 6, SF-02100 ESBO. **France** Pharmacia France S.A. Rue de Marly Parly 2 F-78150 LE CHESNAY. **German Federal Rebublic** Deutsche Pharmacia G.m.b.H. Munzinger Strasse 9 Postfach 5480 D-7800 FREIBURG. **Great Britain** Pharmacia (G.B.) Ltd. Paramount House 75 Uxbridge Road LONDON W5 5SS. **Greece** G.A. Kambanis Imports-Exports-Representations 3 Iridanou Street ATHENS 612. **Italy** Importex Chimici Farmaceutici S.p.A. P.O. Box 467 Via Flavia 122/124 I-34100 TRIESTE. **Mexico** Internacional Cientifica S.A. Apartado Postal 2-807 Angel del Campo 17-A MEXICO 12 D.F. **The Netherlands** Gist-Brocades N.V. Diagnostics Dept. P.O. Box 324 Frijdastraat 7–9 RIJSWIJK (Z H) 2109. **Norway** Norsk Pharmacia A/S Postboks 2005 Grünerløkka OSLO 5. **Portugal** J.A. Baptista D'Almeida Lda. Apartado 1339 LISBOA 1. **Spain** Atom, Paseo del Monte 34 BARCELONA 12. **Sweden** Pharmacia Norden AB Diagnostics Dept. Box 159 751 04 UPPSALA 1. **Switzerland** Pharmacia -pdf- (Schweiz) A.G. 214 Seefeldstrasse CH-8034 ZUERICH. **USA** Pharmacia Diagnostics Division of Pharmacia Inc. 800 Centennial Avenue PISCATAWAY New Jersey 08854. **Other countries** Pharmacia Diagnostics AB Box 17 S-751 03 UPPSALA 1 Sweden.



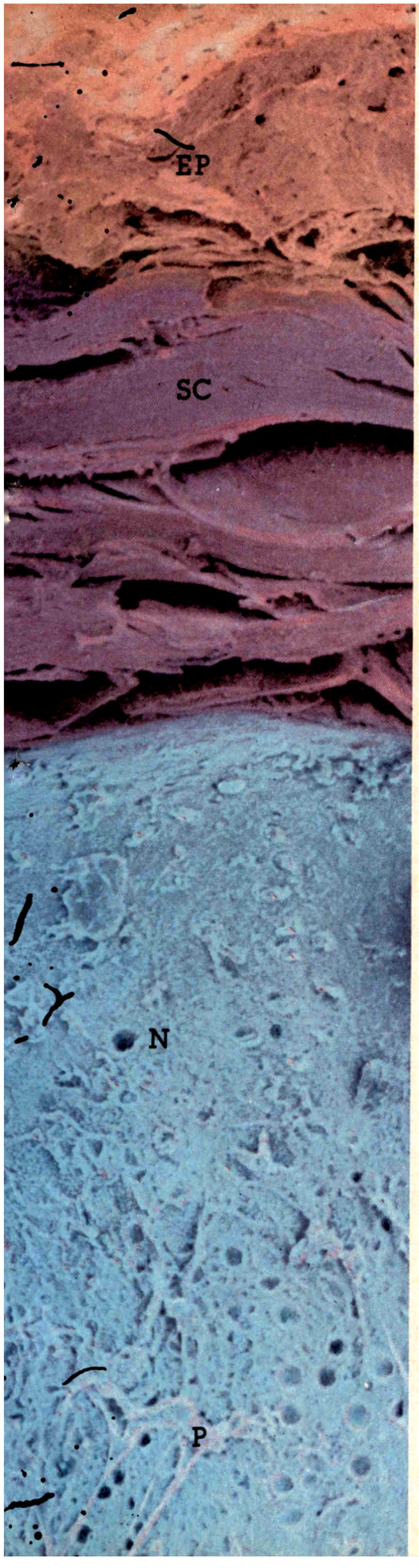

Potency in psoriasis

Potency— A singularly important criterion in selecting a topical steroid for psoriasis, as well as all other acute inflammatory steroid-responsive conditions.

Fluocinonide — A steroid that is 100% dissolved in the Lidex base for optimal lesion penetration. Anti-inflammatory, vasoconstrictive, antipruritic actions, backed by a proven record of performance.

Available in a form that's right for the case at hand — cream, ointment, or Topsyn® (fluocinonide) Gel, 0.05%.

Lidex®

(fluocinonide) 0.05%

See following page for summary of prescribing information.

Cryofractured section of psoriatic epidermis photographed en face. Epidermis (EP) is thickened and stratum corneum (SC) is both thickened and highly disorganized. Dark oval depressions are nuclei (N). Stringy adherent material is exuded serum protein (P).

Color imposed on black-and-white photomicrograph magnified 209X.

SYNTEX
SYNTEX LABORATORIES, INC.
PALO ALTO, CALIFORNIA 94304

LIDEX® (fluocinonide)
Cream and Ointment 0.05%

TOPSYN® (fluocinonide)
Gel 0.05%

Summary of prescribing information

Description
LIDEX cream 0.05%, LIDEX ointment 0.05% and TOPSYN gel 0.05% contain the active compound fluocinonide. Fluocinonide, which is the 21-acetate ester of fluocinolone acetonide, has the chemical formula 6α, 9α-difluoro-11β, 16α, 17α, 21-tetrahydroxypregna-1,4-diene-3, 20-dione, cyclic 16, 17-acetal with acetone 21-acetate. LIDEX cream contains fluocinonide in FAPG® cream, a specially formulated cream base consisting of stearyl alcohol, polyethylene glycol 6000, propylene glycol, 1, 2, 6-hexanetriol and citric acid. This white cream vehicle is greaseless, non-staining, anhydrous and completely water miscible. The base provides emollient and hydrophilic properties. In this formulation, the active ingredient is totally in solution.

LIDEX ointment contains fluocinonide in a specially formulated ointment base consisting of Amerchol CAB (mixture of sterols and higher alcohols), white petrolatum, propylene carbonate and propylene glycol. It provides the occlusive and emollient effects desirable in an ointment. In this formulation the active ingredient is totally in solution.

TOPSYN gel contains fluocinonide in a specially formulated gel base consisting of propylene glycol, propyl gallate, disodium edetate, and Carbopol 940 (carboxypolymethylene) with NaOH and/or HCL added to adjust the pH. This clear, colorless, thixotropic vehicle is greaseless, non-staining and completely water miscible. In this formulation, the active ingredient is totally in solution.

Indications
LIDEX cream and ointment and TOPSYN gel are intended for the relief of inflammatory manifestations of corticosteroid responsive dermatoses.

Contraindications
Topical steroids are contraindicated in vaccinia and varicella. Topical steroids are contraindicated in those patients with a history of hypersensitivity to any of the components of the preparation.

Precautions
If irritation develops, the cream, ointment or gel should be discontinued and appropriate therapy instituted. In the presence of an infection the use of an appropriate antifungal or antibacterial agent should be instituted.

If a favorable response does not occur promptly, the corticosteroid cream, ointment or gel should be discontinued until the infection has been adequately controlled.

If extensive areas are treated, the possibility exists of increased systemic absorption and suitable precautions should be taken.

Although topical steroids have not been reported to have an adverse effect on pregnancy, the safety of their use in pregnant females has not absolutely been established. Therefore, they should not be used extensively on pregnant patients, in large amounts or for prolonged periods of time.

LIDEX® (fluocinonide) cream and ointment and TOPSYN® (fluocinonide) gel are not for ophthalmic use.

Adverse reactions
The following local adverse reactions have been reported with topical corticosteroids:

burning	folliculitis
itching	acneform eruptions
irritation	hypopigmentation
dryness	striae
secondary infection	skin atrophy

Dosage and administration
A small amount should be gently massaged into the affected area three or four times daily, as needed.

How supplied
LIDEX Cream 0.05% — 15 g 30 g and 60 g tubes.
LIDEX Ointment 0.05% — 15 g 30 g and 60 g tubes.
TOPSYN Gel 0.05% 15 g and 60 g tubes.

SYNTEX
SYNTEX LABORATORIES, INC.
PALO ALTO, CALIFORNIA 94304

Acne on back and shoulders—within easy reach

BUF™ BODY SCRUB

features BUF-PUF® Nonmedicated Cleansing Sponge on a contoured reusable handle

- thoroughly cleanses the skin and removes excess oil
- helps loosen and remove comedones
- aids removal of hyperkeratotic skin

Also helps manage psoriasis

Clinical investigation* revealed BUF-PUF debrided thick psoriatic scales. The adjunctive use of BUF-PUF to mechanically remove scale build-up may help topical anti-psoriatic agents to better penetrate the stratum corneum. No evidence of any Koebner reaction or other adverse effects was observed.

*Shellow, W. V.R., "The Use of a Polyester Fiber Sponge as an Adjunct in the Treatment of Psoriasis." Submitted for publication.

©1977 Riker Laboratories, Inc.
NORTHRIDGE, CALIFORNIA 91324
SUBSIDIARY OF 3M COMPANY

ACNE'S ANXIETY

BENZAGEL® 5% Acne Gel 10% Acne Gel

(5% or 10% benzoyl peroxide, 6% polyoxyethylene lauryl ether, 40% alcohol)

Early visible improvement helps to relieve anxiety and promotes patient cooperation—Simple and pleasant to use

- Benzoyl peroxide in a special alcohol gel base—Reliable and predictable, imparts a pleasant cooling sensation with controlled drying of sebaceous oils. Accelerates desquamation.
- "BP base/bond" for uniform therapeutic deposition of benzoyl peroxide—Reduces burning sensation on application, for greater patient acceptance.
- Effective antibacterial and comedolytic action—Rapid improvement is seen, often within two weeks.

BENZAGEL® a basic component of acne therapy

Description: 5% or 10% benzoyl peroxide, 6% polyoxyethylene lauryl ether and 40% alcohol in an astringent gel containing colloidal magnesium aluminum silicate, hydroxypropyl methylcellulose, citric acid, fragrance and purified water.

Action: Provides drying, desquamative and antiseptic activity.

Indication: An aid in the treatment of acne.

Dosage and Administration: Wash affected areas prior to application. Apply once or more daily or as directed by physician.

Contraindications: Should not be used by patients having known sensitivity to either benzoyl peroxide or polyoxyethylene lauryl ether.

Precautions: For External Use Only. Not for ophthalmic use. Keep away from eyes and mucosae. Very fair individuals should begin with a single application at bedtime allowing overnight medication. May bleach colored fabrics. Keep this and all other medications out of the reach of children.

Caution: Federal law prohibits dispensing without prescription.

How Supplied: Plastic tubes, 1½ oz. and 3 oz.

For Patient Starters
Call Toll-Free (800) 523-6674

Dermik

Dermik Laboratories, Inc.
Fort Washington, Pa. U.S.A. 19034

UNIVERSITY COLLEGE OF LIBRARY

Lederle
NDC 0005-5131-54
Aristocort®
Triamcinolone
Acetonide
Cream 0.1%
R
REGULAR POTENCY
Not For Ophthalmic Use
STORE AT ROOM TEMPERATURE
AVOID FREEZING
Aristocort
Triamcinolone
Acetonide
Ointment
0.1%
aristogel
D1

Stop at our place

before you go to more expensive topical steroids

Aristocort®

Triamcinolone Acetonide

Effective initial therapy in a wide range of steroid-responsive dermatoses.

Clinical efficacy proven again and again over almost 20 years of clinical use—a standard among fluorinated topicals.

One of the most *economical* topical steroids available—in forms, strengths and sizes for every susceptible steroid-responsive problem (large-size tubes and jars lower treatment costs even more for patients with chronic or widespread conditions...free trial samples available, too).

The *first* triamcinolone preparation to remove common sensitizers—contains no parabens, phenol preservatives, lanolin.

Indications: For relief of inflammatory manifestations of corticosteroid-responsive dermatoses.

Contraindications: Viral skin diseases, such as varicella and vaccinia; hypersensitivity to any component (not for ophthalmic use); when circulation is markedly impaired.

Warnings: Safety of use in pregnancy has not been absolutely established. Do not use extensively, in large amounts, or for prolonged periods of time in pregnant patients.

Precautions: If irritation develops, discontinue use and institute appropriate therapy. In infections, use appropriate antifungal or antibacterial agents; if a favorable response does not occur promptly, discontinue the corticosteroid until the infection is adequately controlled. If extensive areas are treated or the occlusive technique is used, increased systemic absorption of the corticosteroid may occur; take suitable precautions.

Adverse Reactions: (local) Burning sensations, itching, irritation, dryness, folliculitis, secondary infection, skin atrophy, striae, hypertrichosis, acneform eruption and hypopigmentation.

Supplied: Cream 0.5%—Per Gm.: triamcinolone acetonide 5 mg., sorbic acid 0.1% and potassium sorbate 0.1% as preservatives; *Cream 0.1%*—Per Gm.: triamcinolone acetonide 1 mg., sorbic acid 0.1% and potassium sorbate 0.1% as preservatives: *Cream 0.25%*—Per Gm.: triamcinolone acetonide 0.25 mg., sorbic acid 0.1% and potassium sorbate 0.1% as preservatives; all potencies are in a water base of mono and diglycerides, squalane, polysorbate 80 USP, polysorbate 60, cetyl esters wax NF, stearyl alcohol USP, Tenox 11, and sorbitol solution USP. *Ointment 0.5%*—Per Gm.: triamcinolone acetonide 5 mg.; inactive ingredient: white petrolatum; *Ointment 0.1%*—Per Gm.: triamcinolone acetonide 1 mg.; inactive ingredient: white petrolatum. *ARISTOGEL® Gel 0.1%*—Per Gm.: triamcinolone acetonide 1 mg., 1.8% benzyl alcohol as preservative, inactive ingredients in a water base: polysorbate 80 USP, polyoxyethylene (20) cetyl ether, glycerin USP, and citric acid USP.

004-7

Lederle

Lederle Laboratories
A Division of American Cyanamid Company, Pearl River, New York 10965

[illegible]mplete an[illegible]ontinu[illegible]us [illegible]er[illegible]ge or t[illegible]r-re[illegible]p[illegible]n i[illegible]e dermatoses encourages full patient co-operation 24 hours a day.

estar® Gel is transparent and virtually odor-free for inconspicuous daytime therapy.

A Balnetar® bath in the evening helps relieve irritating symptoms throughout the night.

Elegant Sebutone® extends tar therapy to the scalp in psoriasis, seborrhea, itchy scalp.

Westwood® Tar products contain the first chemically and biologically standardized tar, bioassayed to insure uniform therapeutic activity. Westwood® Tar is anti-pruritic, keratoplastic, and anti-eczematous.

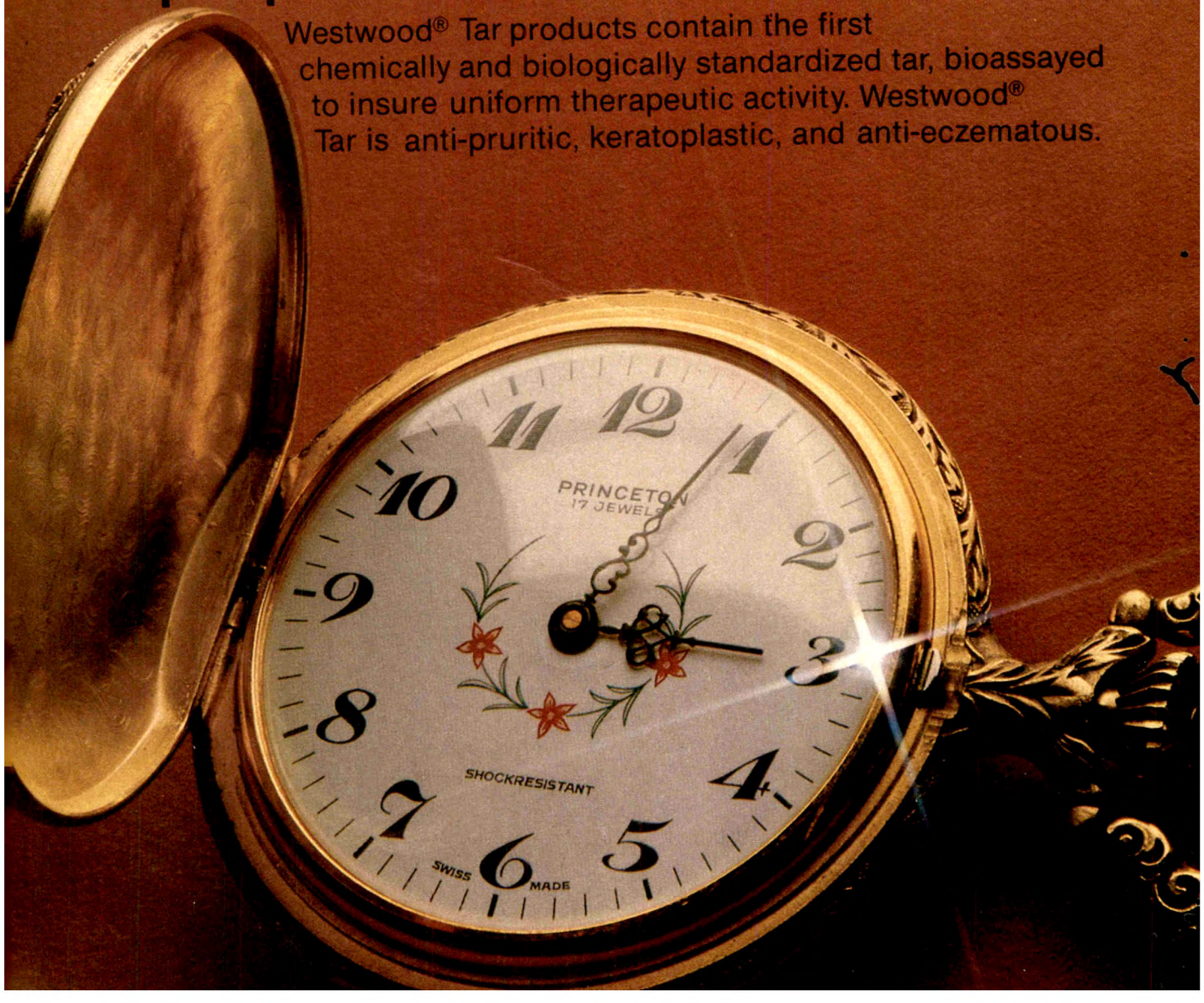

Therapeutic Tar Gel, 3 oz. Plastic Tube. Equivalent to 5% Coal Tar USP

Therapeutic Emollient Tar Bath, 8 fl. oz. Plastic Bottles. Equivalent to 2.5% Coal Tar USP

Antiseborrheic Liquid Tar Shampoo, 4 and 8 oz. Plastic Bottles. Equivalent to 0.5% Coal Tar USP

estar®

Therapeutic Tar Gel. 3 oz. Plastic Tube.

CAUTION: AFTER USING, TREATED AREAS SHOULD BE PROTECTED FROM SUNLIGHT, ESPECIALLY IF ESTAR HAS BEEN USED ON THE FACE. THIS PRECAUTION SHOULD BE TAKEN FOR AT LEAST 24 HOURS AFTER APPLICATION, UNLESS OTHERWISE DIRECTED. ESTAR SHOULD NOT BE USED ON HIGHLY INFLAMED OR BROKEN SKIN. If used on the scalp temporary discoloration of blond, bleached, or tinted hair may occur. If undue irritation develops or increases, the usage schedule should be changed or ESTAR discontinued. Contact with the eyes should be avoided. In case of contact, flush eyes with water.

Slight staining of clothing may occur. Standard laundry procedures will usually remove stains. For external use only.

Balnetar®

Therapeutic Emollient Tar Bath. 8 fl. oz. Plastic Bottle.

CAUTION: If irritation persists, discontinue use. In rare instances temporary discoloration of blond, bleached or tinted hair may occur. In rare cases BALNETAR may cause allergic irritation attributable to coal tar.

PRECAUTION: After use of BALNETAR, patient should avoid exposure to direct sunlight unless sunlight is being used therapeutically in a supervised, modified Goeckerman regimen. Contact with eyes should be avoided. Patient should be cautioned against slipping when BALNETAR is used in bathtub. Also advise patient that use in a plastic or fiberglass tub may cause staining of the tub.

Sebutone®

Antiseborrheic Liquid Tar Shampoo. 4 oz. and 8 oz. Plastic Bottles.

CAUTION: If undue skin irritation develops or increases, discontinue use. In rare instances, temporary discoloration of blond, bleached or tinted hair may occur.

PRECAUTION: Contact with the eyes is to be avoided. In case of contact flush eyes with water.

WESTWOOD
PHARMACEUTICALS INC.
Buffalo, New York 14213
In Canada, Belleville, Ontario K8N 5E9

Clinically proven.
Cosmetically superior.
Conveniently packaged and economically priced.

The family
for your patients' steroid

Proven clinically effective for prompt relief of mild-to-severe corticosteroid-responsive dermatoses

Valisone® Aerosol 0.15%
For acute contact dermatitis.

Impressive results with Valisone Cream and Ointment in published studies:

contact dermatitis
96% good to excellent results
(81 of 84 patients)*

atopic eczema
92% good to excellent results
(231 of 251 patients)*

psoriasis
85% good to excellent results
(150 of 177 patients)*

Valisone® Cream 0.1%

*Files of Headquarters Medical Research Division, Schering Corporation.

Copyright © 1977, Schering Corporation. All Rights Reserved.

See Clinical Considerations section on opposite page...

# of specialists
responsive problems

Schering

Valisone® Lotion 0.1%
Especially useful in seborrheic dermatitis.

Valisone® Reduced Strength Cream 0.01%
For low-cost maintenance therapy.

Valisone® Ointment 0.1%
When dryness is a problem.

Clinical Considerations: Indications: VALISONE Cream, Ointment, and Lotion are indicated for relief of the inflammatory manifestations of corticosteroid-responsive dermatoses. VALISONE Reduced Strength Cream is indicated for the relief of the inflammatory manifestations of corticosteroid-responsive dermatoses. VALISONE Aerosol is indicated, solely, for adjunctive topical management for the relief of inflammatory manifestations of acute contact dermatitis. **Contraindications:** Topical steroids are contraindicated in tuberculosis of the skin and some viral diseases of the skin (varicella and vaccinia). Topical steroids are also contraindicated in those patients with a history of hypersensitivity to any of the components of the preparations. VALISONE Aerosol is contraindicated for use under occlusive dressings. **Warnings for VALISONE Aerosol:** Keep the spray away from eyes and other mucous membranes; avoid inhaling. Avoid freezing of the tissue by not spraying for more than 3 seconds, at a distance not less than 6 inches. Contents are under pressure. Do not puncture. Do not store or use near open flame or heat. Exposure to temperatures above 120°F may cause bursting. Keep out of reach of children. Never throw container into fire or incinerator. **Precautions:** If irritation or sensitization develops with the use of VALISONE products, treatment should be discontinued and appropriate therapy instituted. In the presence of infection, the use of an appropriate antifungal or antibacterial should be instituted. If favorable response does not occur promptly, the corticosteroid should be discontinued until the infection has been adequately controlled. If extensive areas are treated, or if the occlusive technique is used, the possibility exists of sufficient systemic absorption to produce adrenal suppression and systemic corticosteroid effects may occur; suitable precautions should be taken. In a few cases, ulceration has been reported with the use of topical steroids for skin conditions involved with impaired circulation (i.e., stasis dermatitis). Prolonged application of corticosteroid-containing products under occlusion may result in striae or atrophy of the skin or subcutaneous tissues. VALISONE products are not for ophthalmic use. **Usage in Women of Childbearing Age:** The use of any drug during pregnancy and the lactation period or in women of childbearing age requires that the potential benefits of the drug be weighed against the possible hazards to the fetus or infant. Topical corticosteroids have not been reported to have an adverse effect on the fetus, but the safety of their use in pregnant patients has not been definitely established. They should not be used extensively or for prolonged periods of time in pregnant patients, unless the condition requiring treatment warrants the risk. **Adverse Reactions:** The following adverse reactions have been reported with topical corticosteroids: burning, itching, irritation, dryness, folliculitis, hypertrichosis, acneiform eruptions, and hypopigmentation. The following may occur more frequently with occlusive dressings than without such therapy: maceration of the skin, secondary infection, atrophy of the skin or subcutaneous tissues, striae, miliaria. **Dosage and Administration:** VALISONE Cream, Ointment, and Reduced Strength Cream are applied as a thin film over the affected skin areas one to three times a day. Clinical studies of VALISONE have indicated that dosage once or twice a day is often feasible and effective. VALISONE Reduced Strength Cream has an aqueous, hydrophilic base that softens and moisturizes the skin. Although occlusive dressings are required infrequently, they may enhance therapeutic efficacy in certain refractory lesions of psoriasis and other dermatoses that are difficult to treat. Apply a few drops of VALISONE Lotion to the affected area of the scalp and massage lightly until it disappears. Apply twice daily, in the morning and at night. Dosage may be increased in stubborn cases; following improvement, apply once daily. Apply VALISONE Aerosol three to four times a day. The container may be held upright or inverted during use. The spray should be directed onto the affected area from a distance of approximately 6 inches and applied for only 3 seconds. Aerosol packaged by Aerosol Techniques, Inc., Armstrong Laboratories Division, West Roxbury, MA. 02132. **For more complete details, consult package insert or Schering literature available from your Schering Representative or Professional Services Department, Schering Corporation, Kenilworth, New Jersey 07033.**

MARCH 1974 (R)

Valisone®
brand of
betamethasone valerate, NF

SLS-914

what's best for the care of dry or premature aging or wrinkled skin... DUE TO EPIDERMAL DEHYDRATION?

SUPPLIED: 2 OZ. TUBES

WRITE FOR SAMPLES

DOAK PHARMACAL CO., INC. WESTBURY, N.Y. 1

DISTRIBUTOR IN CANADA
TRANS-CANADA DERMAPEUTICS LTD., MONTREAL 23, QU

IN SKIN INFECTIONS, WHERE CLEANLINESS REQUIRES MORE THAN SOAP

BETADINE® Skin Cleanser

Degerms as it cleanses

Patients can use BETADINE Skin Cleanser to degerm and cleanse face, hands and body, gently and thoroughly—particularly when it is essential to prevent autoinoculation of new sites, as may be the case in infected acne pimple

BETADINE Skin Cleanser, with its rich, golden lather, provides these advantages:

- Prompt, broad-spectrum microbicidal action—kills both gram-positive and gram-negative bacteria (including antibiotic-resistant strains), fungi, viruses, protozoa and yeasts.
- Maintains microbicidal activity in the presence of blood, pus and serum.
- Virtually nonirritating to skin and mucosa.*
- Nonstaining to skin and natural fabrics.

Supplied: 4 fl. oz. plastic bottles.

*In the rare instance of local irritation or sensitivity, discontinue use by the individual.

Purdue Frederick © COPYRIGHT 1976, THE PURDUE FREDERICK COMPANY

NORWALK, CONN. 06856 A8196 172076



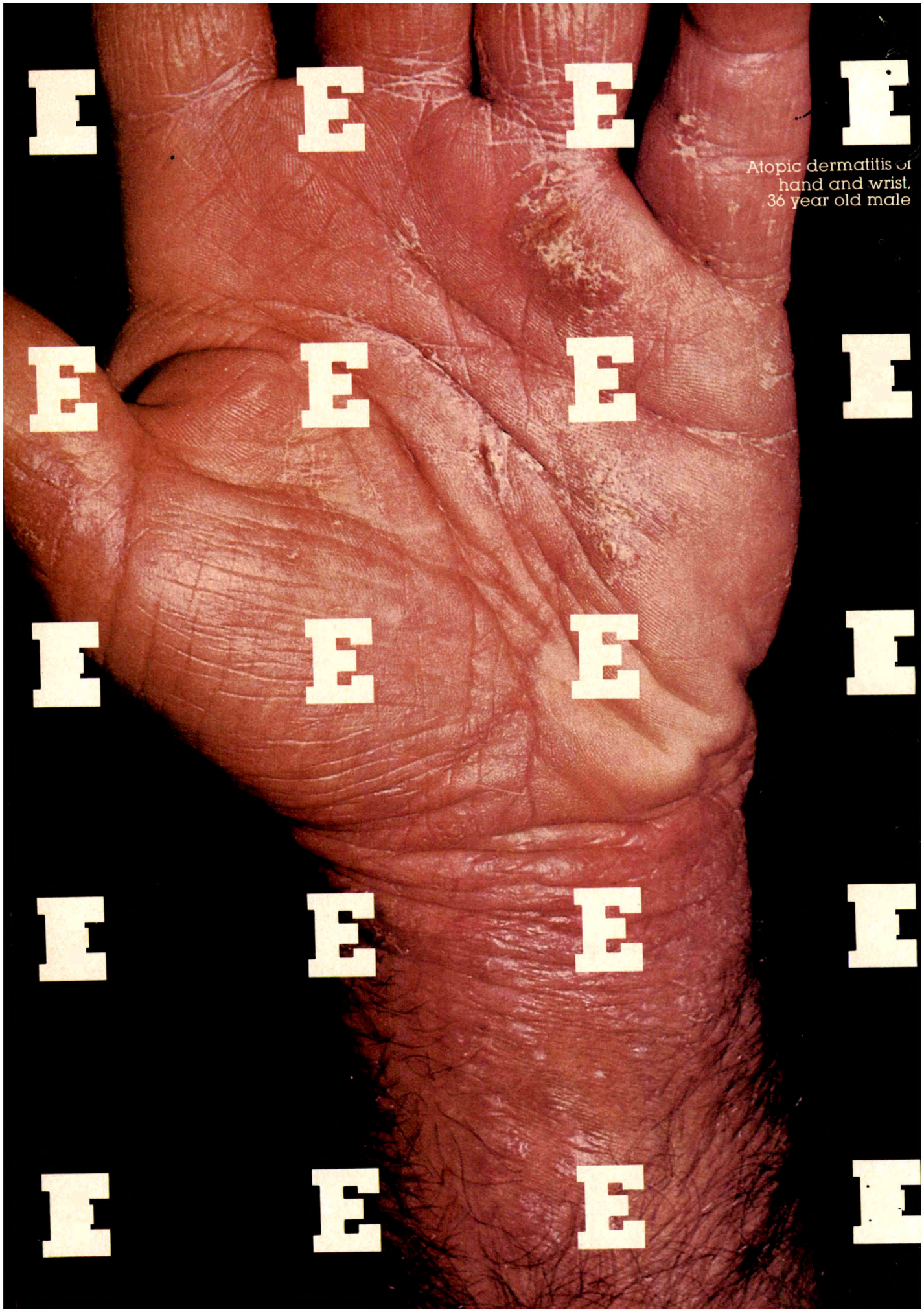

Atopic dermatitis of hand and wrist, 36 year old male

Added versatility in dermatology

new Lidex®-E

(fluocinonide) 0.05%

The established potency of fluocinonide, in a soothing emollient base.

Less drying than a cream, with the lubricating qualities of an ointment–cosmetically acceptable to patients.

Especially useful wherever a soothing topical steroid is indicated, as in atopic dermatitis.

Available in 15g and 60g tubes.

SYNTEX

Please see following page for summary of prescribing information

new Lide® E (fluocinonide) Cream 0.05%

Prescribing Information

Description LIDEX-E cream 0.05% contains the active compound fluocinonide. Fluocinonide, which is the 21-acetate ester of fluocinolone acetonide, has the chemical formula 6α, 9-difluoro-11β, 16α, 17, 21-tetrahydroxypregna-1, 4-diene-3, 20-dione, cyclic 16, 17-acetal with acetone, 21-acetate.

The cream contains fluocinonide 0.5 mg./g. in a water-washable aqueous emollient base of stearyl alcohol, cetyl alcohol, mineral oil, propylene glycol, sorbitan monostearate, polysorbate 60, citric acid and purified water.

Actions Topical steroids are primarily effective because of their anti-inflammatory, antipruritic and vasoconstrictive actions.

Indications For relief of the inflammatory manifestations of corticosteroid-responsive dermatoses.

Contraindications Topical steroids are contraindicated in vaccinia and varicella.

Topical steroids are contraindicated in those patients with a history of hypersensitivity to any of the components of the preparation.

Precautions If irritation develops, the cream should be discontinued and appropriate therapy instituted.

In the presence of an infection, the use of an appropriate antifungal or antibacterial agent should be instituted. If a favorable response does not occur promptly, the corticosteroid cream should be discontinued until the infection has been adequately controlled.

If extensive areas are treated, the possibility exists of increased systemic absorption and suitable precautions should be taken.

Although topical steroids have not been reported to have an adverse effect on pregnancy, the safety of their use in pregnant females has not absolutely been established. Therefore, they should not be used extensively on pregnant patients, in large amounts or for prolonged periods of time.

This product is not for ophthalmic use.

Adverse reactions The following local adverse reactions have been reported with topical corticosteroids: burning sensations, itching, irritation, dryness, secondary infection, folliculitis, acneform eruptions, hypopigmentation, striae, skin atrophy.

Dosage and Administration A small amount should be gently massaged into the affected area three or four times daily, as needed.

How Supplied LIDEX®-E (fluocinonide) cream 0.05% — 15g. and 60g. tubes.

SYNTEX
SYNTEX LABORATORIES, INC.
PALO ALTO, CALIFORNIA 94304



A safe, economical method of permanent hair removal— from face, legs, body

To save valuable office time, you can confidently recommend Perma Tweez to your patients for their home use.

- Battery-operated instrument self-sterilizes when current flows.
- Patented self-correcting needle.
- No-puncture safety feature helps prevent infection.
- Proved clinically safe (report on request).

FOR PHYSICIAN ORDERING

GENERAL MEDICAL CO., Dept D-95
1935 Armacost Ave.
West Los Angeles, CA 90025
30 DAY FREE TRIAL EXAMINATION.
(May be returned with no obligation.)

☐ PERMA TWEEZ $19.95
☐ ATTACHMENT $3.00
(for treating others)
☐ INVOICE AFTER 30 DAYS
☐ CHECK ENCLOSED

DR_____

STREET_____

C/S_____ ZIP_____

When Griseofulvin is indicated...

TINEA PEDIS*

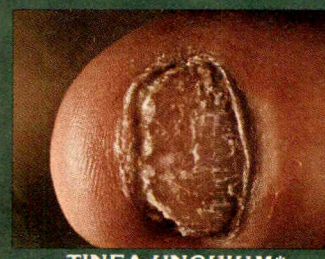

TINEA UNGUIUM*

TINEA CRURIS*

TINEA CAPITIS*

*Also *Tinea barbae* and *Tinea corporis* when caused by fungi from genera known to be sensitive to griseofulvin.

Gris-PEG®

(griseofulvin ultramicrosize) Tablets 125 mg

offers effective therapy with 1/2 the dose.†

- Can be taken on an empty stomach
- Absorption nearly complete without fatty meals
- Reduced cost for patients
- Once-a-day or b.i.d. dosage

†250 mg of Gris-PEG® provides plasma levels equivalent to those obtained with 500 mg microsize griseofulvin. This improved absorption permits the oral intake of half as much griseofulvin but there is no evidence, at this time, that this confers any significant clinical difference in regard to safety or efficacy.



Dorsey LABORATORIES
Division of Sandoz, Inc.
LINCOLN, NEBRASKA 68501

Please see other side for full prescribing information.

Gris-PEG®

(griseofulvin ultramicrosize) Tablets 125 mg

The ½ dose griseofulvin.

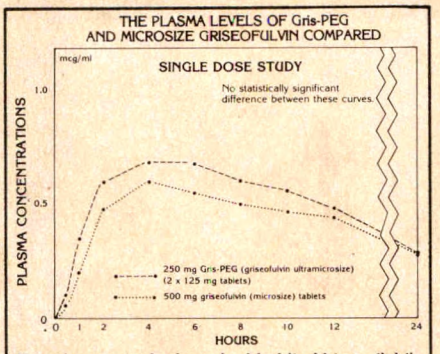

Based on a single dose double-blind bioavailability study conducted in 24 human volunteers comparing the average griseofulvin (microsize) and Gris-PEG plasma levels. There is no significant difference between peak plasma levels, times to peak, and areas under the curve. Gas chromatographic assay.

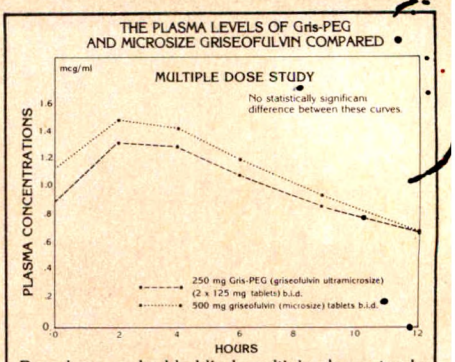

Based on a double-blind multiple dose steady state crossover bioavailability study conducted in 17 human volunteers comparing the average griseofulvin (microsize) and Gris-PEG plasma levels obtained on days 9, 11 and 13. There is no significant difference between times to peak, peak plasma levels, and areas under the curve. Gas chromatographic assay.

DESCRIPTION

Griseofulvin is an antibiotic derived from a species of *Penicillium*.

Gris-PEG is an ultramicrocrystalline solid-state dispersion of griseofulvin in polyethylene glycol 6000.

Gris-PEG Tablets differ from griseofulvin (microsize) tablets USP in that each tablet contains 125 mg of ultramicrosize griseofulvin biologically equivalent to 250 mg of microsize griseofulvin.

ACTION

Microbiology: Griseofulvin is fungistatic with *in vitro* activity against various species of *Microsporum*, *Epidermophyton* and *Trichophyton*. It has no effect on bacteria or other genera of fungi.

Human Pharmacology: The peak plasma level found in fasting adults given 0.25 g of Gris-PEG occurs at about four hours and ranges between 0.37 to 1.6 mcg/ml.

Comparable studies with microsize griseofulvin indicated that the peak plasma level found in fasting adults given 0.5 g occurs at about four hours and ranges between 0.44 to 1.2 mcg/ml.

Thus, the efficiency of gastrointestinal absorption of the ultramicrocrystalline formulation of Gris-PEG is approximately twice that of conventional microsized griseofulvin. This factor permits the oral intake of half as much griseofulvin per tablet but there is no evidence, at this time, that this confers any significant clinical differences in regard to safety and efficacy.

Griseofulvin is deposited in the keratin precursor cells and has a greater affinity for diseased tissue. The drug is tightly bound to the new keratin which becomes highly resistant to fungal invasions.

INDICATIONS

Gris-PEG (griseofulvin ultramicrosize) is indicated for the treatment of the following ringworm infections:

Tinea corporis (ringworm of the body)
Tinea pedis (athlete's foot)
Tinea cruris (ringworm of the thigh)
Tinea barbae (barber's itch)
Tinea capitis (ringworm of the scalp)
Tinea unguium (onychomycosis, ringworm of the nails)

when caused by one or more of the following genera of fungi:

Trichophyton rubrum
Trichophyton tonsurans
Trichophyton mentagrophytes
Trichophyton interdigitalis
Trichophyton verrucosum
Trichophyton megnini
Trichophyton gallinae
Trichophyton crateriform
Trichophyton sulphureum
Trichophyton schoenleini
Microsporum audouini
Microsporum canis
Microsporum gypseum
Epidermophyton floccosum

NOTE: Prior to therapy, the type of fungi responsible for the infection should be identified.

The use of the drug is not justified in minor or trivial infections which will respond to topical agents alone.

Griseofulvin is *NOT* effective in the following:

Bacterial infections
Candidiasis (Moniliasis)
Histoplasmosis
Actinomycosis
Sporotrichosis
Chromoblastomycosis
Coccidioidomycosis
North American Blastomycosis
Cryptococcosis (Torulosis)
Tinea versicolor
Nocardiosis

CONTRAINDICATIONS

This drug is contraindicated in patients with porphyria, hepatocellular failure, and in individuals with a history of sensitivity to griseofulvin.

WARNINGS

Prophylactic Usage: Safety and Efficacy of Griseofulvin for Prophylaxis of Fungal Infections Has Not Been Established.

Animal Toxicology: Chronic feeding of griseofulvin, at levels ranging from 0.5 to 2.5% of the diet, resulted in the development of liver tumors in several strains of mice, particularly in males. Smaller particle sizes result in an enhanced effect. Lower oral dosage levels have not been tested. Subcutaneous administration of relatively small doses of griseofulvin, once a week, during the first three weeks of life has also been reported to induce hepatomata in mice. Although studies in other animal species have not yielded evidence of tumorigenicity, these studies were not of adequate design to form a basis for conclusions in this regard.

In subacute toxicity studies, orally administered griseofulvin produced hepatocellular necrosis in mice, but this has not been seen in other species. Disturbances in porphyrin metabolism have been reported in griseofulvin treated laboratory animals. Griseofulvin has been reported to have a colchicine-like effect on mitosis and cocarcinogenicity with methylcholanthrene in cutaneous tumor induction in laboratory animals.

Usage in Pregnancy: The safety of this drug during pregnancy has not been established.

Animal Reproduction Studies: It has been reported in the literature that griseofulvin was found to be embryotoxic and teratogenic on oral administration to pregnant rats. Pups with abnormalities have been reported in the litters of a few bitches treated with griseofulvin. Additional animal reproduction studies are in progress. Suppression of spermatogenesis has been reported to occur in rats, but investigation in man failed to confirm this.

PRECAUTIONS

Patients on prolonged therapy with any potent medication should be under close observation. Periodic monitoring of organ system function, including renal, hepatic and hematopoietic, should be done.

Since griseofulvin is derived from species of *Penicillium*, the possibility of cross sensitivity with penicillin exists; however, known penicillin-sensitive patients have been treated without difficulty.

Since a photosensitivity reaction is occasionally associated with griseofulvin therapy, patients should be warned to avoid exposure to intense natural or artificial sunlight. Should a photosensitivity reaction occur, lupus erythematosus may be aggravated.

Griseofulvin decreases the activity of warfarin-type anticoagulants so that patients receiving these drugs concomitantly may require dosage adjustment of the anticoagulant during and after griseofulvin therapy.

Barbiturates usually depress griseofulvin activity and concomitant administration may require a dosage adjustment of the antifungal agent.

ADVERSE REACTIONS

When adverse reactions occur, they are most commonly of the hypersensitivity type such as skin rashes, urticaria, and rarely, angioneurotic edema, and may necessitate withdrawal of therapy and appropriate countermeasures. Paresthesias of the hands and feet have been reported rarely after extended therapy. Other side effects reported occasionally are oral thrush, nausea, vomiting, epigastric distress, diarrhea, headache, fatigue, dizziness, insomnia, mental confusion, and impairment of performance of routine activities.

Proteinuria and leukopenia have been reported rarely. Administration of the drug should be discontinued if granulocytopenia occurs.

When rare, serious reactions occur with griseofulvin, they are usually associated with high dosages, long periods of therapy, or both.

DOSAGE AND ADMINISTRATION

Accurate diagnosis of the infecting organism is essential. Identification should be made either by direct microscopic examination of a mounting of infected tissue in a solution of potassium hydroxide or by a culture on an appropriate medium.

Medication must be continued until the infecting organism is completely eradicated as indicated by appropriate clinical or laboratory examination. Representative treatment periods are—*tinea capitis*, 4 to 6 weeks; *tinea corporis*, 2 to 4 weeks; *tinea pedis*, 4 to 8 weeks; *tinea unguium*—depending on rate of growth—fingernails, at least 4 months; toenails, at least 6 months.

General measures in regard to hygiene should be observed to control sources of infection or reinfection. Concomitant use of appropriate topical agents is usually required particularly in treatment of *tinea pedis*. In some forms of athlete's foot, yeasts and bacteria may be involved as well as fungi. Griseofulvin will not eradicate the bacterial or monilial infection.

An oral dose of 250 mg of Gris-PEG (griseofulvin ultramicrosize) is biologically equivalent to 500 mg of griseofulvin (microsized) USP (see ACTION Human Pharmacology).

Adults: A daily dose of 250 mg will give a satisfactory response in most patients with *tinea corporis*, *tinea cruris* and *tinea capitis*. One 125 mg tablet twice per day or two 125 mg tablets once per day is the usual dosage. For those fungal infections more difficult to eradicate such as *tinea pedis* and *tinea unguium*, a divided daily dose of 500 mg is recommended. In all cases, the dosage should be individualized.

Children: Approximately 5 mg per kilogram (2.5 mg per pound) of body weight per day is an effective dose for most children. On this basis the following dosage schedule for children is suggested: Children weighing over 25 kilograms (approximately 50 pounds) 125 mg to 250 mg daily; children weighing 15-25 kilograms (approximately 30 to 50 pounds) 62.5 mg to 125 mg daily; children 2 years of age and younger, dosage has not been established.

Dosage should be individualized, as is done for adults. Clinical experience with griseofulvin in children with *tinea capitis* indicates that a single daily dose is effective. Clinical relapse will occur if the medication is not continued until the infecting organism is eradicated.

HOW SUPPLIED

Gris-PEG (griseofulvin ultramicrosize) Tablets (white) differ from griseofulvin microsized tablets (USP) in that each tablet contains 125 mg of ultramicrosize griseofulvin, biologically equivalent to 250 mg of microsized griseofulvin. Two 125 mg tablets of Gris-PEG are biologically equivalent to 500 mg of microsized griseofulvin. In bottles of 100 and 500 scored, film-coated tablets.

Dorsey
LABORATORIES
Division of Sandoz, Inc. • LINCOLN, NEBRASKA 68501

OY-Y

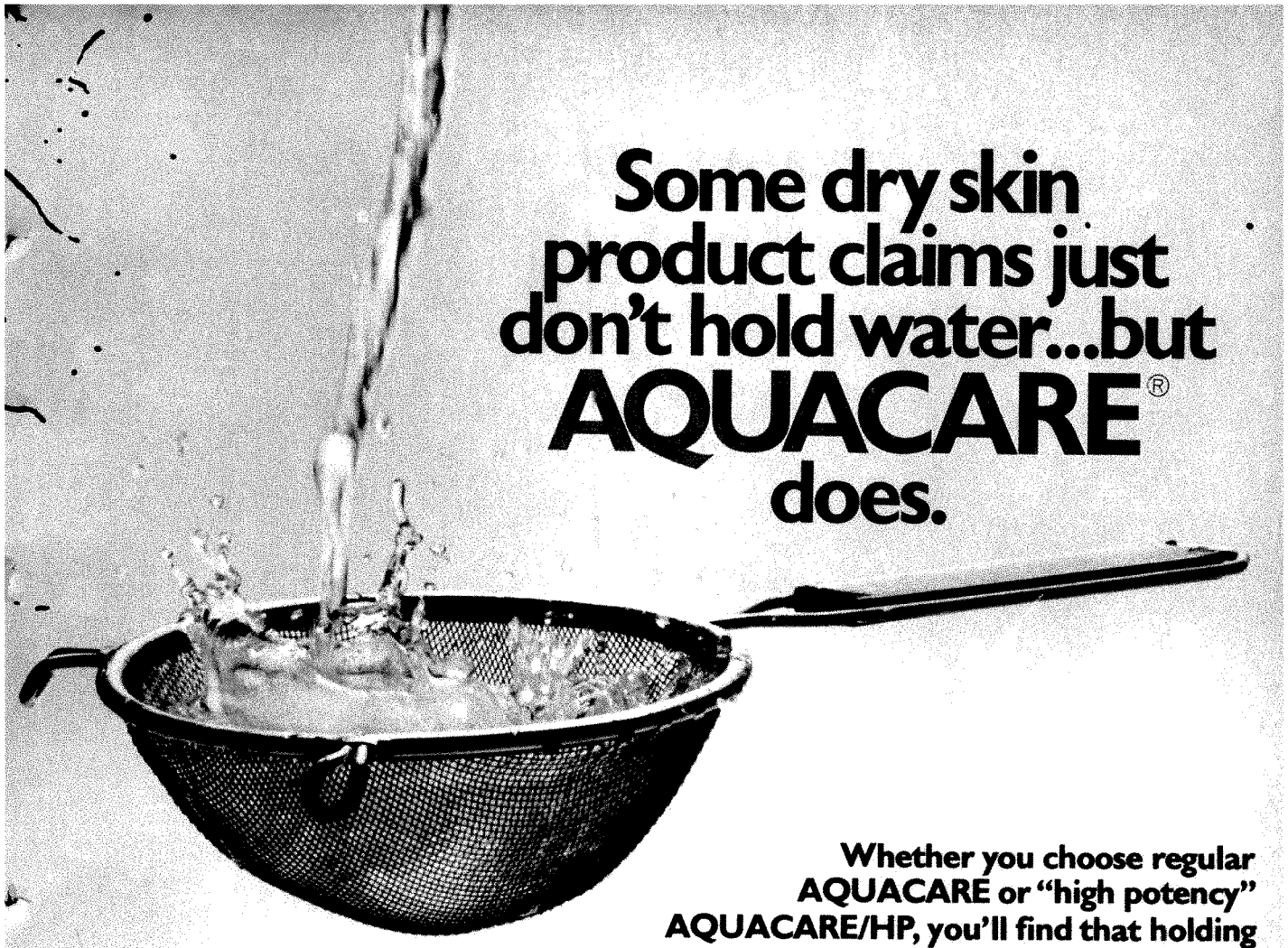

Some dry skin product claims just don't hold water...but AQUACARE® does.

Whether you choose regular AQUACARE or "high potency" AQUACARE/HP, you'll find that holding water is only one of the things they do well.

AQUACARE®/HP for severe ichthyotic conditions. With the superb moisturizing capability provided by 10% urea, AQUACARE/HP restores suppleness even to severly xerotic skin. Enhanced by the hygroscopic action of glycerin, the active water phase (water, urea and glycerin) of AQUACARE/HP accomplishes effective hydration where you need it.

And the AQUACARE/HP active oil phase lubricates severely dry skin by supplementing the reduced lipid content and helping to keep water in contact with the dehydrated tissues. And a unique three-emulsifier system unifies the phases in an oil-in-water emulsion which resists washoff.

AQUACARE® for "everyday" dry skin problems. AQUACARE, with 2% urea, has the same exquisite moisturizing base as its higher potency companion. This makes it ideal for minor complaints of dishpan hands, mild atopic dermatitis, pruritis, etc. Both AQUACARE and AQUACARE/HP bring a silky, soothing, "coolness" to dry skin, by virtue of the oil-in-water emulsion. And they are both formulated at a pH of 6 to avoid skin irritation. The lack of an oily appearance on the skin helps insure that your "cosmetic conscious" patients will like AQUACARE's looks as well as its feel.

Excellent compounding vehicle. Because of their stability, and their compatibility with a great many useful dermatological preparations, both AQUACARE and AQUACARE/HP are outstanding compounding vehicles. You can't choose a more pleasing base for your "tailor-made" prescriptions.

Mild dry skin problems or severe, AQUACARE is one moisturizing product that really holds water.

Herbert Laboratories
Dermatology Division of Allergan Pharmaceuticals, Inc.
Irvine, California 92713, U.S.A.

2834

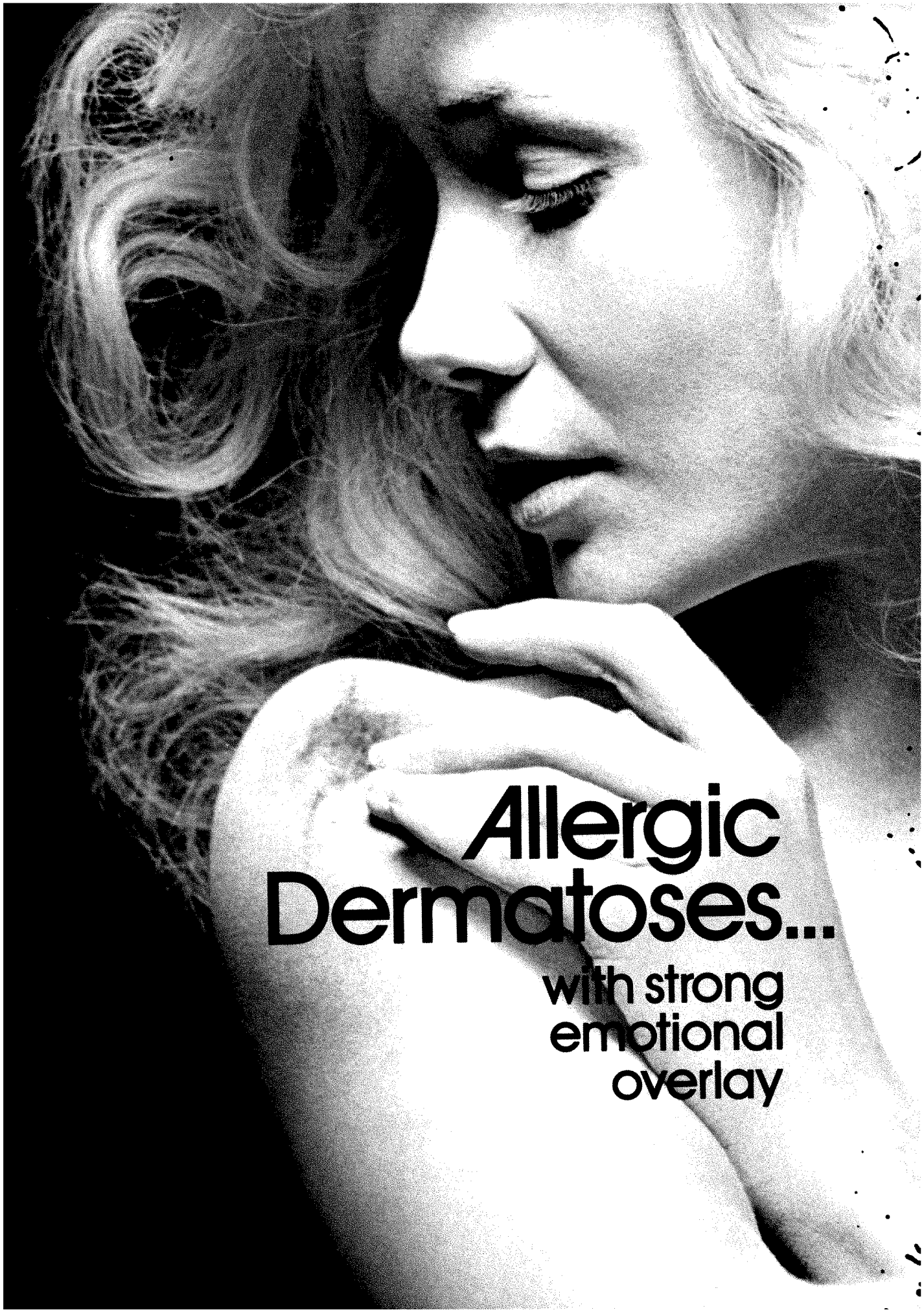
Allergic
Dermatoses...
with strong
emotional
overlay

Contraindications: Hypersensitivity to hydroxyzine. Hydroxyzine, when administered to the pregnant mouse, rat, and rabbit, induced fetal abnormalities in the rat at doses substantially above the human therapeutic range. Clinical data in human beings are inadequate to establish safety in early pregnancy. Until such data are available, hydroxyzine is contraindicated in early pregnancy.

Precautions: Hydroxyzine may potentiate the action of central nervous system depressants such as meperidine and barbiturates. In conjunctive use, dosage for these drugs should be reduced. Because drowsiness may occur, patients should be cautioned against driving a car or operating dangerous machinery.

Adverse Reactions: Drowsiness may occur; if so, it is usually transitory and may disappear in a few days of continued therapy or upon dosage reduction. Dryness of the mouth may occur with higher doses. Involuntary motor activity, including rare instances of tremor and convulsions, has been reported, usually with higher than recommended dosage.

Supply: Tablets, containing 10 mg hydroxyzine hydrochloride, 100's and 500's; Tablets, containing 25 mg or 50 mg, 100's, 500's, and Unit Dose (10 x 10's); Tablets, containing 100 mg, 100's and Unit Dose (10 x 10's); Syrup, containing 10 mg per teaspoonful (5 ml) and ethyl alcohol 0.5% v/v, pint bottles.

Before prescribing or administering, see package circular.

ROERIG Pfizer
A division of Pfizer Pharmaceuticals
New York, New York 10017

as adjunctive therapy

Atarax® (hydroxyzine HCl)

TABLETS: 10 mg, 25 mg, 50 mg, and 100 mg SYRUP: 10 mg per 5 ml, ethyl alcohol 0.5% v/v

- rapid antianxiety action
- demonstrated antihistaminic/antipruritic activity

For Skin That Needs Your Special Skills...
Neutrogena...
for exceptional patient compliance.*

For Skin without Water

Neutrogena® Dry-Skin Soap**
Neutrogena® Rainbath® Bath Gel**
Neutrogena® Hand Cream**

Neutrogena®
Dedicated to Sensitive Skin Care.

Neutrogena Corp., 5755 West 96th Street, Los Angeles, California 90045

*Journal reprints on clinical evaluation describing patient compliance are available on request.
**Available as unscented formulas.

NEW



U.V. PHOTOTHERAPY RADIOMETER for PHOTOCHEMOTHERAPY of PSORIASIS

Features:
- Direct readout in milliwatts/cm².
- Spectral response to match the photosensitization of skin.
- Sensitivity from 0.3 to 100 milliwatts/cm², full scale.
- Wide field of view to match the cosine receiving function of human skin.
- Small, rugged and battery operated for full portability and safety.
- L.E.D. battery status indicator lamp.
- Silicon photodiode detector for maximum stability..

Write Dept. A

international light INC
Specialists in Light Measurement
DEXTER INDUSTRIAL GREEN
NEWBURYPORT, MA. 01950 617 465-5923

ACADEMIC DERMATOLOGIST

Position available as Assistant Professor for qualified dermatologist with prior experience in the field of photobiology. Candidates must have demonstrated competence in teaching, research and patient care. Previous research experience with laboratory animals is also necessary. Address replies to: Leonard C. Harber, M.D., Department of Dermatology, College of Physicians & Surgeons of Columbia University, 630 West 168 St. New York, N.Y. 10032. An equal opportunity/affirmative action employer.

OBJECTIVE: TO SEEK OUT AND DESTROY SOLAR KERATOSES

BEFORE

2/6/75—Diffuse hyperplastic solar keratoses over the dorsa of both hands were present at the start of treatment with twice daily applications of Efudex® (fluorouracil) 5% Cream.

DURING

2/21/75—After slightly more than two weeks of therapy, lesions had become inflamed and excoriated, and subclinical lesions not visible before treatment had become inflamed. Treatment was terminated on 2/27/75 and healing was complete within 2 to 3 weeks.

AFTER

8/4/77—There was no evidence of recurrence at follow-up visit 30 months later. (Note: The redness seen in this photograph is the result of insect bites and is unrelated to the course of therapy.)

Please consult summary of product information on third page of this advertisement.

■ AN EFFECTIVE TOPICAL ALTERNATIVE TO SURGERY FOR MULTIPLE LESIONS AND DIFFICULT TREATMENT SITES.

■ COSMETICALLY GRATIFYING RESULTS, WITH MINIMAL OR NO SCARRING.

■ HIGH DEGREE OF SAFETY...SYSTEMIC TOXICITY RARE.

■ CONVENIENT, ECONOMICAL B.I.D. APPLICATION. APPLY WITH CARE NEAR EYES, NOSE AND MOUTH.

AN EXCLUSIVE ROCHE FORMULATION

Efudex® 5% Cream
fluorouracil/Roche

Solar Keratosis—a premalignant lesion

Among any light-skinned population, extended exposure to the sun may lead to solar keratoses, which commonly occur as multiple lesions on exposed portions of the skin. Because they are the most common types of lesions that progress from minor alteration to cancer,[1] they should be treated. Efudex is a proven cytotoxic agent, with a marked effect on more rapidly growing cells.

1. Pinkus H: The border line between cancer and noncancer, in *Year Book of Dermatology*, edited by Kopf AW, Andrade R. Chicago, p. 16. Copyright© 1967 by Year Book Medical Publishers, Inc. Used by permission.

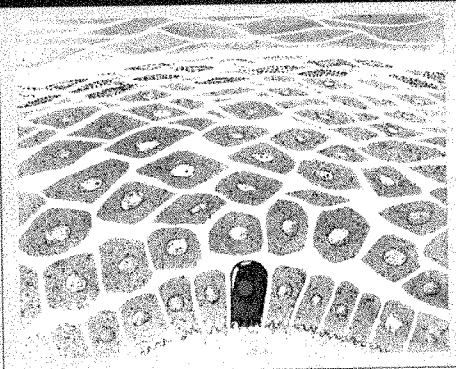

The development of a precancerous epidermal lesion from a germinal basal cell*

This mother cell, with a slightly higher mitotic rate, produces more dysplastic basal cells and also prickle cells.

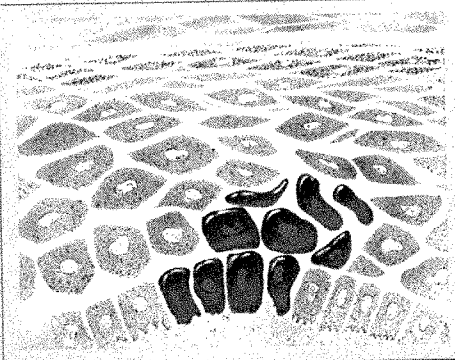

When these prickle cells reach the surface, a visible clinical lesion results.



These cells undergo parakeratosis and form a scale. The heavy outline denotes dysplastic cell.

*Adapted from Pinkus H: The border line between cancer and noncancer, in *Year Book of Dermatology*, edited by Kopf AW, Andrade R. Chicago, p. 17. Copyright© 1967 by Year Book Medical Publishers, Inc. Used by permission.

An excellent blend of clinical efficacy and cosmetic acceptance. Now indicated for seborrheic dermatitis.

Obviously, efficacy is foremost in your mind when you recommend a therapeutic shampoo. And efficacy, coupled with cosmetic acceptability, usually guarantees a successful therapeutic course.

That's why Head & Shoulders is so highly regarded in the treatment of dandruff.

Clinically effective

For years, Head & Shoulders has proved effective in the treatment of dandruff—whether for initial therapy or long-term control. And now, research shows that Head & Shoulders is effective in the treatment of seborrheic dermatitis.*

Cosmetically pleasing

Head & Shoulders lathers well, has a pleasant odor and appearance, and need not be left on the scalp for an extended period of time. Also, it leaves hair clean, manageable, and attractive.

Head & Shoulders®

You'll like it for its therapeutic benefits. Your patients will like it for its cosmetic appeal.

*Orentreich, N.: A clinical evaluation of two shampoos in the treatment of seborrheic dermatitis, J. Soc. Cosmet. Chem. 23:189 (March 3) 1972.

© 1974 Procter & Gamble HS

Still the only oral antipruritic with q12h convenience

Before prescribing, see complete prescribing information in SK&F literature or *PDR*. The following is a brief summary.

Indications

Based on a review of this drug by the National Academy of Sciences—National Research Council and/or other information, FDA has classified the indications as follows:

Effective: For symptomatic relief of pruritic symptoms in urticaria.

Possibly effective: For relief of pruritic symptoms in neurodermatitis, allergic dermatitis, contact dermatitis, atopic dermatitis, chickenpox, pruritus ani and vulvae.

Final classification of the less-than-effective indications requires further investigation.

Contraindications: Comatose patients; presence of large amounts of C.N.S. depressants; bone marrow depression; idiosyncrasy or hypersensitivity to this drug or other phenothiazines; in newborn or premature children; in nursing mothers; in acutely ill and/or dehydrated children.

Warnings: May impair mental and/or physical ability required for potentially hazardous tasks (driving vehicles, operating machinery); may impair mental alertness in children. Concomitant use with alcohol or other C.N.S. depressants may have additive effect. Warn patients accordingly.

Use with extreme caution in patients with asthmatic attack, narrow-angle glaucoma, prostatic hypertrophy, stenosing peptic ulcer, pyloroduodenal obstruction, bladder neck obstruction, patients receiving MAO inhibitors.

Do not use in women of childbearing potential. There are reported instances of jaundice and prolonged extrapyramidal symptoms in infants whose mothers received phenothiazines during pregnancy.

Use with caution in children, as administration may result in excitation; overdosage may produce hallucinations, convulsions, sudden death.

Elderly patients (60 or older) are more prone to develop the following phenothiazine side effects: hypotension, syncope, toxic confusional states, extrapyramidal symptoms (especially parkinsonism), excessive sedation.

Precautions: May increase, prolong or intensify sedative action of C.N.S. depressants (when administered concomitantly, narcotic or barbiturate dosage should be reduced to ¼ or ½); lead to restlessness and motor hyperactivity in patient with pain being treated with narcotics; block or reverse the pressor effect of epinephrine. Use cautiously in persons (particularly children) with acute or chronic respiratory impairment, as it may suppress cough reflex; in persons with cardiovascular disease, liver function impairment, or history of ulcer disease. The drug's slight antiemetic action may obscure signs of intestinal obstruction, brain tumor, toxic drug overdose.

Adverse Reactions: (Note: May produce adverse reactions attributable to both phenothiazines and antihistamines, although not all the following have

Controls the itching* promptly
...while you treat the cause

Temaril® Spansule®

Each 'Spansule' capsule contains trimeprazine tartrate equivalent to 5 mg. of trimeprazine.

*Brand of sustained release capsules

been reported with 'Temaril'. There have been occasional reports of sudden death in patients receiving phenothiazine derivatives chronically.) Drowsiness, extrapyramidal reactions (opisthotonos, dystonia, akathisia, dyskinesia, parkinsonism), particularly with high doses, hyperreflexia in newborn (when used during pregnancy), dizziness, headache, lassitude, tinnitus, incoordination, fatigue, blurred vision, euphoria, diplopia, nervousness, insomnia, tremors and grand mal seizures, excitation, catatonic-like states, neuritis and hysteria, oculogyric crises, disturbing dreams/nightmares, pseudoschizophrenia, intensification and prolongation of action of C.N.S. depressants, atropine, heat, organophosphorus insecticides.

Also postural hypotension, reflex tachycardia, bradycardia, faintness, cardiac arrest, ECG changes, anorexia, nausea, vomiting, epigastric distress, diarrhea, constipation, dry mouth, increased appetite and weight gain, urinary frequency and dysuria, urinary retention, early menses, induced lactation, gynecomastia, decreased libido, inhibition of ejaculation, false positive pregnancy tests, thickening of bronchial secretions, tightness of chest, wheezing, nasal stuffiness, urticaria, dermatitis, asthma, laryngeal edema, angioneurotic edema, photosensitivity, lupus erythematosus-like syndrome, anaphylactoid reactions, leukopenia, agranulocytosis, pancytopenia, hemolytic anemia, elevation of plasma cholesterol levels, thrombocytopenic purpura, jaundice, erythema, peripheral edema, stomatitis, high or prolonged glucose tolerance curves, glycosuria, elevated spinal fluid proteins, reversed epinephrine effects.

After prolonged phenothiazine administration at high dosage, the following have occurred: skin pigmentation, ocular changes (the appearance of lenticular and corneal opacities, epithelial keratopathies, pigmentary retinopathy). Vision may be impaired.

Drug Interactions: MAO inhibitors and thiazide diuretics prolong and intensify anticholinergic effects. Combined use of MAO inhibitors and phenothiazines may result in hypertension and extrapyramidal reactions. Phenothiazines potentiate C.N.S. depressant and analgesic effects of narcotics. Phenothiazine effects may be potentiated by oral contraceptives, progesterone, reserpine, nylidrin HCl.

Supplied: 'Spansule' capsules — in bottles of 50. Syrup — Each 5 ml. teaspoonful contains trimeprazine tartrate equivalent to 2.5 mg. of trimeprazine and alcohol 5.7%, in 4 fl. oz. bottles. Tablets — Each tablet contains trimeprazine tartrate equivalent to 2.5 mg. of trimeprazine, in bottles of 100 and 1000. Tablets and 'Spansule' capsules also available in Single Unit Packages (SUP) of 100, intended for institutional use only.

Smith Kline & French Laboratories
Division of SmithKline Corporation
Philadelphia, Pa.

SK&F
a SmithKline company

anywhere on potency without fluorination

The potency of Tridesilon—*nonfluorinated* antiinflammatory topical cor ticoid—has again been confirmed. In a recently published clinical study,[1] des onide 0.05% was compared with fluocinonide (in identical concentration) fo various dermatologic disorders including contact dermatitis, nummula eczema, lichen simplex chronicus, seborrheic dermatitis, and atopic eczem

The desonide group showed better improvement scores in erythema an scaling after the first week; the two-week scores were not significantly dif ferent. "...desonide demonstrated potency and efficacy equivalent to those o the fluorinated compound in the disorders treated, and no adverse effect were noted with the former."[1]

This is added corroboration that with topical steroids potency an efficacy do not always depend on fluorination. Desonide, though nonfluori nated, has shown clinical comparability with the most widely prescribed fluo rinated topical steroids.[2]

*Not for ophthalmic use.

References: 1. Barsky S: Clinical comparison of desonide cream with fluocinonide cream in steroid-responsive dermatologic disorders. *Cutis* 18:826, 1976. **2.** Reprints available on request.

Contraindications: Tridesilon (desonide) 0.05% Creme and Ointment, topical steroids, are contraindicated in vaccinia an varicella, and in those patients with a history of hypersensitivity to any of the components of the preparation.

Precautions: If irritation develops, the drug should be discontinued and appropriate therapy instituted.

In the presence of an infection, the use of an appropriate antifungal or antibacterial agent should be instituted. If a favo.abl response does not occur promptly, the corticosteroid should be discontinued until the infection has been adequately controlle

If extensive areas are treated or if the occlusive technique is used, the possibility exists of increased systemic absorption of th corticosteroid and suitable precautions should be taken.

Although topical steroids have not been reported to have an adverse effect on pregnancy, the safety of their uses in pregnar females has not absolutely been established. Therefore, they should not be used extensively on pregnant patients, in larg amounts, or for prolonged periods of time.

These products are not for ophthalmic use.

Adverse Reactions: The following local adverse reactions have been reported with topical corticosteroids: burning sensations itching, irritation, dryness, folliculitis, hypertrichosis, acneform eruptions, hypopigmentation.

The following may occur more frequently with occlusive dressings than without such therapy: maceration of the skin, secon ary infection, skin atrophy, striae, miliaria.

Dosage and Administration: Apply a thin film of Tridesilon (desonide) to the affected skin and massage lightly. The usua dosage is two or three times daily.

Depot Stocked: *DPSC:* 15 gm: NSN 6505-00-148-6969; 60 gm: NSN 6505-00-148-6968; 5 lb: NSN 6505-01-004-9217. *VA:* 6 gm: SN 6505-00-136266A; 5 lb: SN 6505-01-012-4486A.



Tridesilon®

(desonide) 0.05% creme and ointment

adjunctive therapy in acute and chronic steroid-responsive dermatoses

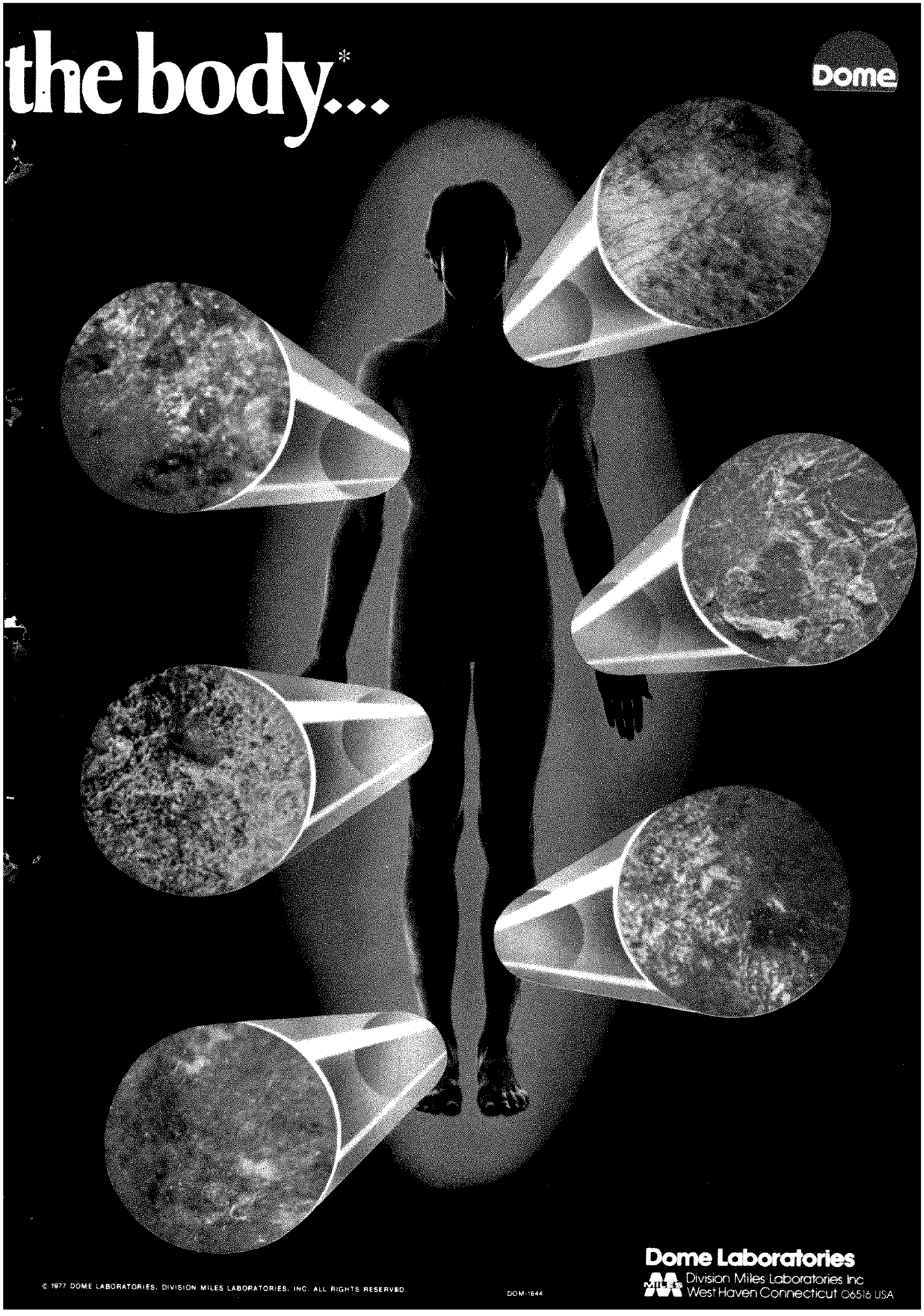
the body*...
Dome
Dome Laboratories
Division Miles Laboratories Inc
West Haven Connecticut 06516 USA
© 1977 DOME LABORATORIES, DIVISION MILES LABORATORIES, INC. ALL RIGHTS RESERVED.
DOM-1644

"Doctor, with my delicate skin... what kind of soap should I use?"

Pure mild Ivory is one of the safest possible soaps you can recommend for delicate skin. More doctors recommend Ivory than any other soap.

It makes sense. Ivory's absence of many extra ingredients helps minimize chances of irritation.

Thirty-eight years of laboratory testing—including patch tests and arm immersion experiments—confirm that Ivory is one of the mildest least irritating soaps you can recommend.

And 89 years of safe consumer use support this clinical experience.

Ivory may safely be used as an adjunct to treatment of scabies, seborrhea and impetigo.

There are two faces of severe acne vulgaris

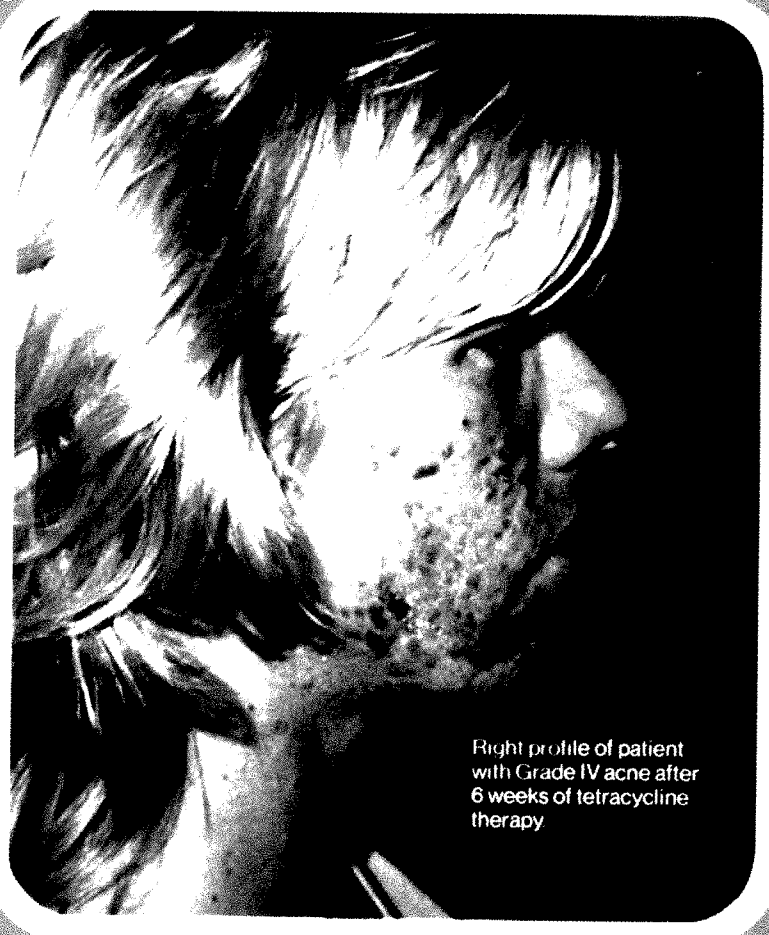

Right profile of patient with Grade IV acne after 6 weeks of tetracycline therapy.

BEFORE adjunctive

MINOCIN®

MINOCYCLINE HCl

CAPSULES 50 mg and 100 mg
SYRUP 50 mg/5 ml

200 mg initially, 100 mg *b.i.d.* or
100 or 200 mg initially, 50 mg *q.i.d.*

MINOCIN Minocycline HCl
Oral and Intravenous Brief Summary

Contraindications: Hypersensitivity to any tetracycline.
Warnings: Intravenous use, particularly in pregnancy, in daily doses exceeding 2 grams has been associated with deaths through liver failure. When need for intensive treatment outweighs potential dangers, perform renal and liver function tests before and during therapy; also follow serum concentrations. In renal impairment, usual doses may lead to excessive accumulation and liver toxicity. Under such conditions, use lower total doses, and, in prolonged therapy, determine serum levels. This hazard is of particular importance in I.V. use in pregnant or postpartum patients with pyelonephritis. In such cases, the blood level should not exceed 15 mcgm/ml, and liver function tests should be made at frequent intervals. Do not prescribe other potentially hepatotoxic drugs concomitantly. The use of tetracyclines during tooth development (last half of pregnancy, infancy and childhood to the age of 3 years) may cause permanent discoloration of the teeth (yellow-gray-brown). This is more common during long-term use but has been observed following repeated short-term courses. Enamel hypoplasia has also been reported. Tetracyclines, therefore, should not be used in this age group unless other drugs are not likely to be effective or are contraindicated. Photosensitivity manifested by an exaggerated sunburn reaction has been observed in some individuals taking tetracyclines. Advise patients apt to be exposed to direct sunlight or ultraviolet light that such reaction can occur, and discontinue treatment at first evidence of skin erythema. Studies to date indicate that photosensitivity is rarely reported with MINOCIN *Minocycline HCl*. In patients with significantly impaired renal function, the antianabolic action of tetracycline may cause an increase in BUN leading to azotemia, hyperphosphatemia, and acidosis. CNS side effects (lightheadedness, dizziness, vertigo) have been reported, may disappear during therapy, and always disappear rapidly when drug is discontinued. Caution patients who experience these symptoms about driving vehicles or using hazardous machinery while taking this drug. **Pregnancy:** In animal studies, tetracyclines cross the placenta, are found in fetal tissues, and can have toxic effects on the developing fetus (often related to retardation of skeletal development). Embryotoxicity has been noted in animals treated early in pregnancy. **Newborns, infants and children.** All tetracyclines form a stable calcium complex in any bone-forming tissue. Prematures, given oral doses of 25 mg./kg. every 6 hours, demonstrated a decrease in fibula growth rate, reversible when drug was discontinued. Tetracyclines are present in the milk of lactating women who are taking a drug in this class.

(cont'd)

There are two faces of severe acne vulgaris

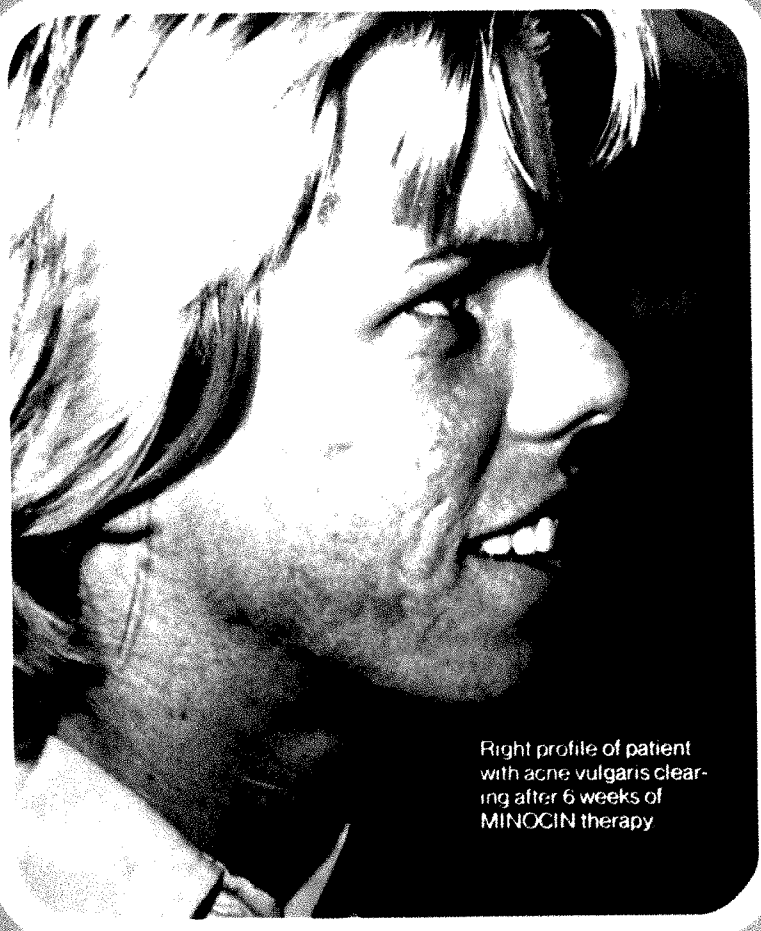

Right profile of patient with acne vulgaris clearing after 6 weeks of MINOCIN therapy

AFTER adjunctive MINOCIN® MINOCYCLINE HCl

CAPSULES 50 mg and 100 mg
SYRUP 50 mg/5 ml

200 mg initially, 100 mg *b.i.d.* or
100 or 200 mg initially, 50 mg *q.i.d.*

MINOCIN Minocycline HCl
Oral and Intravenous Brief Summary (continued)

Precautions: Use may result in overgrowth of nonsusceptible organisms, including fungi. If superinfection occurs, institute appropriate therapy. In veneral diseases when coexistent syphilis is suspected, darkfield examination should be done before treatment is started and blood serology repeated monthly for at least four months. Patients on anticoagulant therapy may require downward adjustment of such dosage. Test for organ system dysfunction (*e.g.*, renal, hepatic and hemopoietic) in long-term use. Treat all group A beta-hemolytic streptococcal infections for at least 10 days. Avoid giving tetracycline in conjunction with penicillin.

Adverse Reactions: **GI:** (with both oral and parenteral use): anorexia, nausea, vomiting, diarrhea, glossitis, dysphagia, enterocolitis, inflammatory lesions (with monilial overgrowth) in anogenital region. **Skin:** maculopapular and erythematous rashes. Exfoliative dermatitis (uncommon). Photosensitivity is discussed above ("Warnings"). **Renal toxicity:** rise in BUN, dose-related (see "Warnings"). **Hypersensitivity reactions:** urticaria, angioneurotic edema, anaphylaxis, anaphylactoid purpura, pericarditis, exacerbation of systemic lupus erythematosus. In young infants, bulging fontanels have been reported following full therapeutic dosage, disappearing rapidly when drug was discontinued. **Blood:** hemolytic anemia, thrombocytopenia, neutropenia, eosinophilia. **CNS:** (see "Warnings"). When given in high doses, tetracyclines may produce brown-black microscopic discoloration of thyroid glands; no abnormalities of thyroid function studies are known to occur.

NOTE: Concomitant therapy: Antacids containing aluminum, calcium, or magnesium impair absorption; do not give to patients taking oral minocycline. Studies to date indicate that absorption of MINOCIN *Minocycline HCl* is not notably influenced by foods and dairy products.

CNS side effects including light-headedness, dizziness, or vertigo have been reported with MINOCIN. Patients who experience these symptoms should be cautioned about driving vehicles or using hazardous machinery while on minocycline therapy.

Lederle

LEDERLE LABORATORIES
A Division of American Cyanamid Company
Pearl River, N.Y. 10965

Printed in U.S.A.

November 1977

410-6

Prevent over-abrasion. Prescribe the natural cleansing control of Komex.

For patients with oily skin or acne, the natural cleansing control of Komex offers a gentle alternative to harsh abradants. Oil, sebum, make-up and surface debris are cleansed away gently by the unique Komex combination of surface active agents and naturally occurring water soluble cleansing particles. The more water your patients use the more gently Komex cleanses.

For thorough cleansing and conditioning without over-abrasion, prescribe the natural cleansing control of Komex.

Caution: Avoid contact with eyes.
Do not use on inflamed skin.

Barnes-Hind Pharmaceuticals, Inc.
895 Kifer Road
Sunnyvale, California 94086

Komex®

r the n hell



ACNAVEEN® BAR

Soothes and cleans sensitive skin, and helps bring their guards down...

Hiding their embarrassment compounds the misery. Incessant picking and rubbing of acne lesions often causes more irritation. Urge them to wash with soap-free ACNAVEEN® Bar, logical adjunctive therapy in whatever treatment you've chosen:

- 2% salicylic acid and 2% sulfur provide a peeling and drying effect.
- Aveeno Colloidal Oatmeal soothes the skin and reduces irritation.

ACNAVEEN® BAR: Special mild cleansing bar for acne.

Available in 3.5 oz. bars

Cooper Cooper Laboratories, Inc., Wayne, New Jersey 07470

Schering

When it's all you want, it's all they get.

pure and simple

Chlor-Trimeton® 12mg.

brand of
chlorpheniramine maleate, USP
brand of
Repetabs® Tablets, repeat-action tablets

Available on prescription only.

Also available:
Chlor-Trimeton®
8 mg. Repetabs®
Injection 100 mg./ml.
and 10 mg./ml.

Copyright © 1977. Schering Corporation. All rights reserved.

SWW-9340



FOR THE ZONES OF DERMATOSES

For dry areas/lesions

A **New Halog® Ointment 0.1%**

Halcinonide Ointment 0.1%

For scalp lesions

B **New Halog® Solution 0.1%**

Halcinonide Solution 0.1%

For moist areas/lesions

Full-strength

C **Halog® Cream 0.1%**

Halcinonide Cream 0.1%

'Maintenance formula'

Quarter-strength

New Halog® Cream 0.025%

Halcinonide Cream 0.025%

Clinical experience

A total of 984 psoriatic patients in US clinical studies were treated with either the Solution, the Creams, or the Ointment. After 2 weeks' therapy,* 151 (78%) of 194 patients improved with Halog Solution, 407 (92.5%) of 440 patients improved with full-strength (0.1%) Halog Cream, 132 (72%) of 184 patients improved with quarter-strength (0.025%) Halog Cream, and 145 (87%) of 166 patients improved with Halog Ointment.

In general, the preferred topical formulations for lesions in specific areas are: solutions for scalp lesions, creams for moist areas/lesions, and ointments for dry areas/lesions. The studies cited above, however, were not limited to lesions in these specific areas.

*Majority of patients evaluated after 2 weeks' therapy. Data on file at Squibb Institute for Medical Research.

See next page for brief summary.

©1977 E.R. Squibb & Sons, Inc. 357-508

HALOG®

HALCINONIDE

SQUIBB®

HALOG® (Halcinonide)
Cream/Ointment/Solution
Halog Cream 0.025% (Halcinonide Cream 0.025%) and Halog Cream 0.1% (Halcinonide Cream 0.1%) contain 0.25 mg. and 1 mg. halcinonide per gram, respectively, in a specially formulated cream base. Halog Ointment (Halcinonide Ointment 0.1%) contains 1 mg. halcinonide (0.1%) per gram in Plastibase® (Plasticized Hydrocarbon Gel), a polyethylene and mineral oil gel base. Halog Solution (Halcinonide Solution 0.1%) contains 1 mg. halcinonide (0.1%) per ml.
CONTRAINDICATIONS: Topical steroids are contraindicated in vaccinia, varicella, and in those patients with a history of hypersensitivity to any of the components of the preparations. These preparations are not for ophthalmic use.
PRECAUTIONS: *General*—If local infection exists, suitable concomitant antimicrobial or antifungal therapy should be administered. If a favorable response does not occur promptly, application of the corticosteroid should be discontinued until the infection is adequately controlled. If extensive areas are treated or if the occlusive technique is used, the possibility exists of increased systemic absorption of the corticosteroid and suitable precautions should be taken. If irritation or sensitization develops, the preparation should be discontinued and appropriate therapy instituted. Although topical steroids have not been reported to have an adverse effect on pregnancy, the safety of their use during pregnancy has not been absolutely established; therefore, they should not be used extensively on pregnant patients, in large amounts, or for prolonged periods of time.
Occlusive Dressing Technique—The use of occlusive dressing increases the percutaneous absorption of corticosteroids; their extensive use increases the possibility of systemic effects. For patients with extensive lesions it may be preferable to use a sequential approach, occluding one portion of the body at a time. The patient should be kept under close observation if treated with the occlusive technique over large areas and over a considerable period of time. Occasionally, a patient who has been on prolonged therapy, especially occlusive therapy, may develop symptoms of steroid withdrawal when the medication is stopped. Thermal homeostasis may be impaired if large areas of the body are covered. Use of the occlusive dressing should be discontinued if elevation of the body temperature occurs. Occasionally, a patient may develop a sensitivity reaction to a particular occlusive dressing material or adhesive and a substitute material may be necessary. If infection develops, discontinue the use of the occlusive dressing and institute appropriate antimicrobial therapy.
ADVERSE REACTIONS: The following local adverse reactions have been reported with topical corticosteroids: burning, itching, irritation, striae, skin atrophy, secondary infection, dryness, folliculitis, hypertrichosis, acneform eruptions, and hypopigmentation. The following may occur more frequently with occlusive dressings: maceration of the skin, secondary infection, skin atrophy, striae, and miliaria. Contact sensitivity to a particular dressing material or adhesive may occur occasionally (see PRECAUTIONS).
For full prescribing information, consult package insert.
HOW SUPPLIED: The 0.025% and 0.1% Cream and the 0.1% Ointment are supplied in tubes of 15 g. and 60 g., and in jars of 240 g. (8 oz.). The 0.1% Solution is supplied in plastic squeeze bottles of 20 ml. and 60 ml.

SQUIBB®

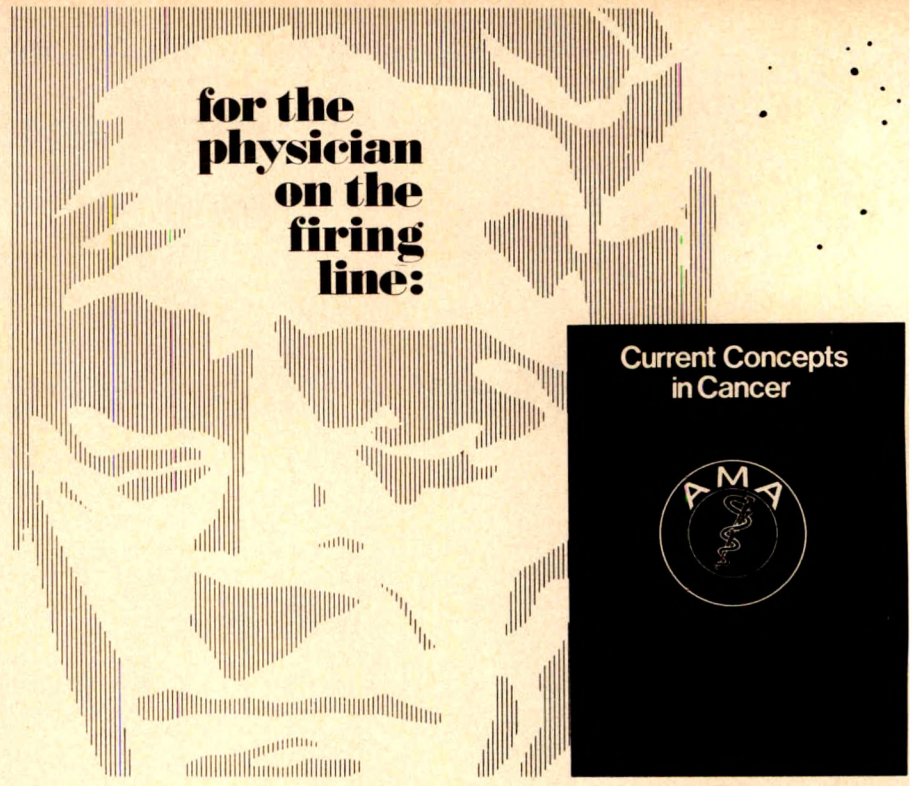

A valuable guide to diagnostic and therapeutic procedures for the cancer patient

Current Concepts in Cancer

While national attention focuses on cancer through specialized cancer centers, physicians are aware that the majority of cancer patients are treated in office practices. For most practicing physicians, cancer treatment is not a research objective, but a very practical problem in patient management.

Current Concepts in Cancer, a compilation of articles originally published in the *Journal of the American Medical Association,* is designed to be a guide for the practitioner in the choice of diagnostic and therapeutic procedures for many types of malignancies. It presents an objective interdisciplinary view by MDs outstanding in their respective fields, emphasizing principles of diagnosis and surgical radiotherapeutic, and chemotherapeutic treatment.

Make this important resource a part of your reference file. Order your copy today.

American Medical Association S/J
535 North Dearborn Street
Chicago, Illinois 60610

Please send me _____ copy(ies) of **Current Concepts in Cancer** (OP-281). Price is $10 per copy. Please enclose your remittance with order.

Please Print

Name _____

Address _____

City _____ State _____ Zip _____

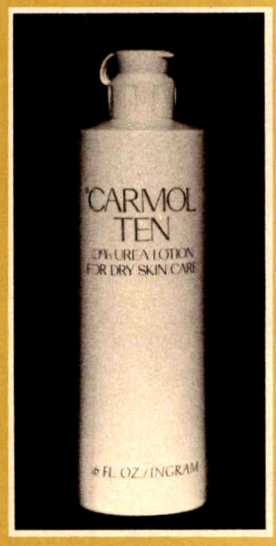

10% Urea Lotion

For simple dry skin: *10% urea* to hydrate dry skin not complicated by hyperkeratosis. Moisturizes and lubricates, relieves the itching of dry skin due to aging, sun or cold weather, soap or detergents. *Lotion base* for total body dry skin care.

vive la différence!

20% Urea Cream

For hyperkeratotic dry skin: *20% urea* to soften and smooth thick, scaly skin in such conditions as ichthyosis, keratosis pilaris, keratosis palmaris et plantaris. *Cream base* for localized application. Especially useful for hands, elbows, knees and heels.

Ingram Pharmaceutical Company,
San Francisco, CA 94111

Malignant Melanoma

Recent epidemiologic evidence has documented both an increase in incidence of and in mortality from malignant melanoma.[1] The importance of this relatively uncommon malignant neoplasm (incidence less than 5/100,000 population) is attested to by the fact that despite accounting for only 3% of all cutaneous malignant neoplasms, malignant melanoma causes 67% of the deaths attributable to skin cancer.[2] Research interest in melanoma has paralleled its increased frequency, and the current literature is replete with numerous articles that provide new information on the subject. Because of the large volume of new information scattered in numerous journals, the comprehensive review article provides a valuable tool for updating the reader and refreshing his memory on the subject. Recently, Kopf et al[2] have written an extensive review of malignant melanoma. The article is current, comprehensive, and well written. The only drawback to the article is its length of more than 80 pages. Therefore, we have written this communication to briefly emphasize those facets of the article we consider most important.

The role of sunlight as a causal factor in the development of melanoma has been carefully reviewed by Kopf et al.[2] Although the majority of the evidence is epidemiologic (increased incidence of melanomas in light-complexioned individuals, in latitudes closer to the equator, and on sun-exposed areas of the body,[1,3] it strongly suggests that sunlight plays a major role in the development of melanomas. This is particularly bothersome in view of the recently projected decreases in the protective ozone layer of the atmosphere secondary to environmental indiscretions.

PROGRESSION AND PROGNOSIS OF MELANOMAS

The terms radial- and vertical-growth phase are mentioned several times by Kopf et al[2] and are important in understanding the developmental biology and thereby, progression and prognosis of melanomas.[4] Most melanomas originate in a radial-growth phase that is characterized by peripheral growth and minimal or absent dermal invasion. This phase of the tumor is associated with a low incidence of metastases and a good prognosis. Gradually, the melanoma progresses to a vertical-growth phase that is characterized by dermal invasion, high incidence of metastases, and poor prognosis. Lentigo maligna and superficial-spreading melanomas originate in a radial-growth phase; nodular melanomas originate in a vertical-growth phase.

The concepts of radial- and vertical-growth phases can readily be related to tumor mass and thickness and ultimately, prognosis. Breslow[5] and Hansen and McCarten[6] all have recently emphasized the importance of tumor thickness in predicting the prognosis of melanoma and as a guide to therapy. As outlined by Kopf et al,[2] the results of these authors indicate that melanomas less than 0.76 mm in thickness (as measured by an ocular micrometer) rarely, if ever, metastasize and are associated with a good prognosis, whereas those lesions that measure 1.5 mm in thickness or greater frequently metastasize early and are associated with a poor prognosis. The importance of these observations lies in the fact that thick lesions may occasionally occupy a low-number Clark's level and thin lesions, a high-number Clark's level.[4] Therefore, tumor thickness may identify level 3 and 4 melanomas with a good prognosis.

In addition to tumor thickness, location on the body, the presence of clinically positive nodes, the presence of lymphatic or angioinvasion, and the degree of pleomorphism, which are observed, are also important prognostic factors. Considering all of these prognostic factors, we think, that the measurement of tumor thickness may prove to be the single most important prognostic parameter, since it provides an assessment of tumor mass. Since much of the information necessary for prognostication is based on a histologic examination, we think that a biopsy report of a malignant melanoma should include at least the following information: (1) clinical-pathologic type of lesion (superficial-spreading, lentigo maligna, and nodular melanomas); (2) level of invasion; (3) maximum thickness in millimeters; (4) pleomorphism (slight, moderate, marked); (5) angioinvasion or lymphatic invasion (present or absent); (6) lymphocytic infiltrate (slight, moderate, marked); and (7) mitotic rate (less than one per high-power field, greater than one per high-power field). This type of report would provide maximum information on which to base therapeutic decisions.

The clinical descriptions and photographs of melanomas provided by Kopf et al[2] are excellent. The authors point out that no uniform classification for the clinical staging of melanoma is in use at the present time. It is important that a uniform staging system be used to guide investigators and clinicians. In this way, results of clinical trials would be comparable and therefore, interpretable.

The discussion and approach to congenital nevi by Kopf et al[2] is well

detailed and emphasizes the controversy that surrounds the incidence of giant congenital nevi and their potential for malignancy. Although the data are not sufficient, it does appear that the giant congenital nevus is a premalignant lesion and should be excised when possible.

THERAPY

The discussion of surgical therapy by Kopf et al[2] is also excellent. We wish only to highlight a few points. If at all possible, the biopsy specimen of the lesion should be an excisional biopsy specimen. Even though incisional biopsy specimens do not adversely affect the prognosis, maximum histologic information is obtained from excisional biopsy specimens. We think that the treatment of primary melanoma is surgical, except on rare occasions. Although there have been differing viewpoints in the literature, the usefulness of an elective regional lymph node dissection (RLND) seems to correlate with tumor thickness.[5] When the lesion is less than 0.76 mm, a RLND is unnecessary with clinically negative nodes; however, when the depth is greater than 1.5 mm, a RLND is prognostically beneficial. Lesions in between these levels must be further studied, but currently, the surgeon must decide the appropriateness of an RLND.

The therapy of disseminated melanoma remains discouraging, as evidenced by the poor survival of stage 1 and 2 patients.[2] Dacarbazine (DTIC-Dome) remains the single most effective chemotherapeutic agent for disseminated melanomas.[7] Initial promising results with combination chemotherapy have not been borne out in controlled studies that involve large numbers of patients.[8,9] Regional perfusion chemotherapy appears to be a promising tool in anatomically accessible lesions, but its effectiveness requires substantiation in carefully controlled studies. Radiotherapy, except on rare occasions, remains palliative.[10]

Much attention in the recent literature has been given to the immunology and immunotherapy of melanoma. Kopf et al[2] did not discuss the immunology or immunotherapy of melanoma, but Sober[11] has provided an adequate discussion in his recent review article. Both arms of the immune response appear to be involved in melanomas, but at the current time, the cell-mediated immunity (CMI) appears to be most important. Immunotherapy, both alone and in combination with chemotherapy, centers around the use of immune adjuvants to stimulate the CMI. Generally, Bacillus Calmette-Guérin immunotherapy has been used, but the most efficacious strains and mode of administration are not known.[12] However, side effects and particularly tumor enhancement limit the usefulness of immunotherapy.[13] At the present time, the immunotherapy for melanoma remains an investigative modality—the results of which have engendered cautious optimism, but which requires substantiation in large, controlled clinical studies.

In conclusion, melanomas continue to be an important tumor despite advances in their therapy. Early recognition and treatment are important particularly prior to their development of a vertical-growth phase, if at all possible. In general, many of the current modes of therapy and decisions, which regard their usage, remain controversial. Hopefully, the use of carefully controlled studies will help to find the best possible therapy for malignant melanomas.

JEFFREY P. GALLEN, MD
Louisville
JOSEPH J. CHANDA, MD
MAREK A. STAWISKI, MD
Ann Arbor, Mich

References

1. Elwood JM, Lee JAH: Recent data on the epidemiology of malignant melanoma. *Sem Oncol* 2:149-154, 1975.
2. Kopf AW, Bart RS, Rodriguez-Sains RS: Malignant melanoma: A review. *J Dermatol Surg Oncol* 3:41-125, 1977.
3. Fears TR, Scotto J, Schneiderman MA: Skin cancer, melanoma, and sunlight. *Am J Public Health* 66:461-464, 1976.
4. Clark WH, Ainsworth, AM, Bernardine EA, et al: The developmental biology of primary human malignant melanomas. *Sem Oncol* 2:83-103, 1975.
5. Breslow A: Tumor thickness, level of invasion and node dissection in stage 1 cutaneous melanoma. *Ann Surg* 182:572-575, 1975.
6. Hansen MG, McCarten AB: Tumor thickness and lymphocytic infiltration in malignant melanoma of the head and neck. *Am J Surg* 128:557-561, 1974.
7. Luce JK: Chemotherapy of melanoma. *Sem Oncol* 2:179-185, 1975.
8. McKelvey EM, Luce JK, Vaitkevicius VK, et al: Bis chloroethyl nitrosourea, vincristine, dimethyl triazeno imidazole carboxamide and chlorpromazine combination chemotherapy in disseminated malignant melanoma. *Cancer* 39:5-10, 1977.
9. McKelvey EM, Luce JK, Talley RW, et al: Combination chemotherapy with bis chloroethyl nitrosourea (BCNU), vincristine and dimethyl triazeno imidazole carboxamide (DTIC) in disseminated malignant melanoma. *Cancer* 39:1-4, 1977.
10. Habermalz HJ, Fischer JJ: Radiation therapy of malignant melanoma. *Cancer* 38:2258-2262, 1976.
11. Sober AJ: Immunology of cutaneous malignant melanoma. *Int J Dermatol* 15:1-18, 1976.
12. Morton DL, Eibler FR, Holmes EC, et al: BCG immunotherapy of malignant melanoma: Summary of a seven-year experience. *Ann Surg* 180:635-643, 1974.
13. McKhann CF, Hendrickson CG, Spitler LE, et al: Immunotherapy of melanoma with BCG: Two fatalities following intralesional injection. *Cancer* 35:514-520, 1975.

Trichophytin Reactions in Children With Tinea Capitis

James E. Rasmussen, MD, A. Razzaque Ahmed, MD

Of 52 patients with proved *Trichophyton tonsurans* infection of the scalp, 16 had an inflammatory reaction to this infection (kerion), while the rest had only slight scaling and broken hairs (black dot ringworm). Each patient was tested with trichophytin antigen to determine whether cell-mediated immunity (CMI) was responsible for the differences in these different clinical presentations. Fifteen of 16 with kerion had a 48-hour reaction > 10 mm, while none of the 36 with noninflammatory (black dot) tinea capitis had a similar response. This suggests that the patient's immune response (CMI) may be responsible for kerion infections of the scalp and that therapy could be directed initially toward suppressing this reaction.

(*Arch Dermatol* 114:371-372, 1978)

There has been much recent interest in the immunology of chronic fungal infections of the adult skin.[1-3] Cell-mediated immunity (CMI) to a 48-hour trichophytin skin test is frequently absent in patients with chronic infection with *Trichophyton rubrum*, although many of the individuals have a wheal-and-flare reaction within 15 to 30 minutes of the trichophytin injection.[1-3] The immunology of acute dermatophytosis in children has, however, received much less attention.

The cause of tinea capitis in eastern American cities has changed considerably in the last 50 to 100 years. *Microsporum canis* and *Maudouinii* were formerly the most common causative organisms, but with changing racial patterns in large cities, *Trichophyton tonsurans* has become an important pathogen.[4] Ringworm of the scalp caused by this organism produces two distinct clinical patterns: patches of alopecia punctuated by hairs broken flush with the scalp (black dot ringworm) or an edematous pustular mass (kerion).[5] Infection with this fungus almost invariably occurs in blacks,[4] frequently producing multiple cases within the children of a family, some with the black dot variety and others with kerion.

There is no known explanation for these distinctively separate patterns, but the difference could be immunological. To investigate this possibility, we studied immediate and delayed reactions to intradermally administered trichophytin antigen in patients with *T tonsurans* infection of the scalp.

MATERIALS AND METHODS

Patients

All patients included in this study had *T tonsurans* scalp infections as demonstrated by a positive KOH preparation and culture on dermatophyte test medium.[6] Colony morphology was invariably that of *T tonsurans* var *sulfureum*.[7] Patients were included in a consecutive fashion from the

Table 1.—Fifty-two Patients With Tinea Capitis

Type of Infection	No. of Patients	Age*	Sex, M:F	Race, B:W	Duration*	Skin Tested While: Disease Active	Skin Tested While: On Griseofulvin Therapy
Kerion	16	64	9:7	16:0	4	14	9
Black dot	36	73	21:15	35:1	5	29	21

*Mean in weeks.

Table 2.—Results of Skin Tests

Type of Infection	No. of Patients	Diameter of Induration at 48 hr, mm: 0	1-4	5-9	10
Kerion	16	0	1	0	15
Black dot	36	28	8	0	0

Accepted for publication July 15, 1977.

From the Department of Dermatology, State University of New York at Buffalo (Drs Rasmussen and Ahmed); Children's Hospital of Buffalo (Dr Rasmussen); and Buffalo General Hospital (Dr Ahmed), Buffalo, NY. Dr Ahmed is now with the Clinical Immunology Service, Department of Immunology and Microbiology, UCLA School of Medicine, Center for Health Sciences, Los Angeles.

Reprint requests to Children's Hospital of Buffalo, 219 Bryant St, Buffalo, NY 14222 (Dr Rasmussen).

outpatient population of the Buffalo (NY) Children's Hospital as the diagnosis was confirmed during the years 1975 and 1976.

Antigens

We used commercially prepared trichophytin antigen, as well as our own trichophytin from *T tonsurans* grown, harvested, and prepared according to the method of Codner et al,[8] but we used it only for a short period of the study.

A 0.1-ml dose of commercial trichophytin was administered intradermally into the skin of the arm and observed for reaction at 15 to 30 minutes and 48 hours. The control injection site received saline. Nine patients were tested after their infection had healed and the rest while infection was still active.

RESULTS

Fifty-two patients met all the criteria for this study and completed their skin testing. Their age, sex, race, and type of tinea capitis are given in Table 1. Six other patients, all with black dot ringworm, were tested but did not return for a 48-hour measurement and are not included in this report. Fifteen patients had induration of greater than 10 mm in diameter at 48 hours, and these patients all had kerion. Thirty-seven patients had little or no reaction (Table 2) at 48 hours and only one of these had kerion. There were no observed wheal-and-flare patterns at 20 minutes and no patient reported any swelling that resolved before the 48-hour examination.

COMMENT

Little is known about the immunology of tinea capitis in children. Fungal infections in adults[1,2] and animals,[9] however, are significantly influenced by the development of CMI to trichophytin. Jones et al[2] produced experimental fungal infections in experienced immune subjects (those with a history of healed cutaneous fungal infection) and fungal "virgins" (those with no history of fungal disease). In the experienced immune population, the induced disease was brief and violently inflammatory. The experimentally infected virgins had prolonged spreading disease until they developed an inflammatory reaction associated with the onset of CMI as measured by 48-hour trichophytin skin tests. Adults with chronic fungal infection of the feet usually have no 48-hour reaction to trichophytin or a combination of both immediate and delayed types.[1,2] The authors who have reported these results believe that the immediate reaction (wheal and flare) has little to do with natural resistance to dermatophytes and may interfere with CMI.

Animal experiments give confirmatory results. Resistance to infection is associated with accelerated inflammatory local reaction and positive results of a tuberculin-type of skin test to trichophytin. This immunity can be transferred with "immune cells" but not with serum.[9]

All the children reported in this study had tinea capitis caused by *T tonsurans*, and yet their clinical presentation suggested two distinct diseases. These differences could be due to the host's response or some characteristic of the invading organism. *Trichophyton tonsurans* var *sulfureum* grew from infected hairs of all patients, and while all cultures appeared grossly similar, a more invasive (or antigenic?) strain might have infected those with kerion. At least two laboratory and clinical observations suggest that this is not so. There are no major antigenic differences between trichophytin isolated from genera *Trichophyton*, *Microsporum*, or *Epidermophyton*.[9] This suggests that antigenic differences among culturally similar isolates of *T tonsurans* are not likely to account for the disparity between black dot and kerion patterns. In addition, there were six families with two or more infected children and a history suggesting intrafamily spread. Each family had a child with kerion and one or more with black dot ringworm. If a more or less invasive variety of *T tonsurans* had spread from sibling to sibling, then the original pattern of infection should have been reproduced, but it was not.

A more logical explanation for these different manifestations of tinea capitis involves the host's immune responses.[10] This hypothesis predicts an immune host will develop an inflammatory reaction—a kerion—while those without CMI to trichophytin enjoy a more benign relationship—black dot ringworm.

The results of skin testing children with *T tonsurans*-caused tinea capitis do not *prove* this hypothesis, but strongly support it since 15 of 16 children with a kerion had a 48-hour reaction greater than 10 mm of induration, and none with black dot pattern had 48-hour induration of 10 mm or more.

These results do not *prove* that CMI coincides with and causes the inflammation characteristic of a kerion. Inflammation from other causes could release antigens,[10] stimulating the patient to develop a CMI response. Several clinical observations suggest, however, that CMI is responsible for kerion: (1) Patients with tinea capitis due to *T tonsurans* have an all-or-none reaction to this organism: there is no merging of patches of scalp with black dot and kerion. (2) Patients whose tinea is initiated by a black dot pattern may convert to a kerion, and when this occurs the change is simultaneous in all involved areas. We have never seen the reverse (kerion to black dot). (3) Corticosteroids (oral or intralesional administration) are beneficial in kerion. (4) Three patients (not included in this study) were tested while they had black dot and again when they converted to a kerion. Forty-eight hour readings were negative (without induration) during the black dot stage and positive (> 10 mm) in the kerion.

This study does not prove a conclusive relationship between CMI and the development of kerion. Consequently, any application of this hypothesis to therapy of kerion should be approached with caution. It may be possible, however, to improve the rate of healing of a kerion with the use of systemically or intralesionally administered corticosteroids.

Thomas Johnson, MD, prepared the *Trichophyton tonsurans* extract used in the early part of the study. Maryann Renner, MT(ASCP), assisted in identifying our early cultures. Cheryl Seifert, RN, and staff of Children's Hospital of Buffalo assisted with much of the skin testing.

References

1. Hanifin JM, Ray LF, Lobitz WC Jr: Immunologic reactivity in dermatophytosis. *Br J Dermatol* 90:1-8, 1974.
2. Jones HE, Reinhardt JH, Rinaldi MG: Immunologic susceptibility to chronic dermatophytosis. *Arch Dermatol* 110:213-220, 1974.
3. Jones HE, Reinhardt JH, Rinaldi MG: A clinical, mycological, and immunological survey for dermatophytosis. *Arch Dermatol* 108:61-65, 1973.
4. Blank F, Mann SJ, Reale RA: Distribution of dermatophytosis according to age, ethnic group and sex. *Sabouraudia* 12:352-361, 1974.
5. Beare JB, Gentles JC, Mackenzie DWF: Mycology, in Rook A, Wilkinson DS, Ebling FJG (eds): *Textbook of Dermatology*, ed 2. Oxford, England, Blackwell Publications, 1972, p 710.
6. Taplin D, Zaias N, Rebel G, et al: Isolation and recognition of dermatophytes in a new medium (DTM). *Arch Dermatol* 99:203-214, 1969.
7. Ray LF, Campbell MC: *A Fungus Syllabus*. Portland, Ore, University of Oregon Medical School, 1970.
8. Codner RC, Cruickshank ND, Trotter MD, et al: The production of *Trichophyton* antigens in submerged culture of *T. mentagraphytes*. *Sabouraudia* 1:116-122, 1961.
9. Grappel SF, Bishop TC, Blank F: Immunology of dermatophytosis. *Bacteriol Rev* 38:222-245, 1974.
10. Zaslow L, Derbes VJ: The immunologic nature of kerion celsi formation. *Dermatologica Internationalis* 8:1-4, 1969.

Generalized Argyria

Clinicopathologic Features and Histochemical Studies

Robert J. Pariser, MD

• In three cases of generalized argyria, the degree of slate-gray cutaneous discoloration varied from barely perceptible to pronounced. Deposition of silver-containing granules in and around cutaneous adnexal structures was best seen with darkfield microscopy. Histochemical studies suggested that the granules consisted of silver sulfide. Indiscriminate use of currently available silver-containing medications can result in generalized argyria.

(*Arch Dermatol* 114:373-377, 1978)

Generalized argyria, the systemic dissemination and tissue deposition of silver-containing particles, is characterized by distinctive pigmentary changes most pronounced in exposed skin. The cases summarized below illustrate many of the features of this disorder. Histochemical studies of skin from these patients were performed to determine the chemical nature of the silver-containing particles.

REPORT OF CASES

CASE 1.—An 83-year old man, originally admitted to the Miami Veterans Administration Hospital for an inguinal hernia, was seen in consultation for evaluation of "cyanosis." Although details of his medical history were clouded by senile dementia, he stated that his skin has been discolored as long as he could remember. He denied the use of oral medications, but did use nose drops regularly. The nose drops he was using at the time of admission did not contain silver, but he was unable to remember the names of the preparations he had used in the past. His landlady stated that his skin color had not changed in the past three years; she was unable to find any silver-containing medications on the premises. There was no history of cardiopulmonary disease or of heavy metal treatments.

Physical examination showed a thin, elderly man with slate-gray discoloration of the skin, most pronounced on the face, neck, and arms, but present to a lesser degree over the entire skin surface (Fig 1, left). The proximal half of the fingernail beds were azure; the color extended slightly beyond the lunulae (Fig 1, right). The color was less marked on the toenails. The oral mucosa had a slight blue-gray discoloration. Other cutaneous findings were an ulcerated pearly papule at the left inner canthus and a 2 × 1.5 cm irregularly shaped, black macula with a slightly papular center and scalloped borders on the lower part of the back. Other physical findings were a systolic murmur, a reducible right inguinal hernia, lower leg edema, and mild tremor and cogwheel rigidity of the right arm.

Routine laboratory studies revealed no abnormalities of blood, liver, or kidney. Results of pulmonary function studies and arterial blood gases were normal. Cutaneous tissue from three sites was obtained under local anesthesia. Other than for silver deposition (described below), the sites and pathologic diagnoses were (1) biopsy of a pearly papule of the left inner canthus—basal cell carcinoma, (2) biopsy and subsequent excision in toto of black lesion on lower part of the back—atypical junctional nevus, (3) biopsy of abnormally pigmented skin of neck—solar elastosis.

CASE 2.—An elderly woman (she would not reveal her exact age) was being treated in the dermatology clinic of the Miami Veterans Administration Hospital for impetiginized stasis dermatitis and basal cell carcinoma. She had been seen on several occasions by different examiners, and no abnormal skin color was noted. On routine questioning about medications, she stated that she had used mild silver protein (Argyrol) nose drops intermittently for many years for "sinus trouble" on the recommendation of an otolaryngologist. There was no history of heavy metal treatments. Except for osteoarthritis of the lumbar spine, there were no active medical problems.

Physical examination showed an obese, elderly woman with normally colored skin. The only cutaneous findings were faint bluish discoloration of the proximal portion of the nail beds (Fig 2), a scar on the upper lip at the site of curettage of a basal cell carcinoma, the changes of stasis dermatitis on the lower legs, and two well-healed surgical scars on the abdomen. Findings from the remainder of the physical examination were unremarkable.

Cutaneous tissue was obtained under local anesthesia from both upper arms. Other than for silver deposition, no pathologic changes were present.

CASE 3.—A 58-year-old man, hospitalized for treatment of a cardiac arrhythmia, was seen in consultation by the dermatology service of the Miami Veterans Administration Hospital because of a history of argyria. He had had his throat painted with mild silver protein repeatedly from age 3 to 12 for prevention and treatment of colds, and he occasionally had used mild silver protein as nose drops. Darkening of his skin became apparent in childhood. As he grew up, the abnormal color became less noticeable, but was sufficient to prompt the clinical diagnosis of argyria during a hospitalization for a cardiac arrhythmia at age 25. He felt that his abnormal pigmentation had continued to lessen in his adult years. He had not received heavy metal treatments.

Examination revealed a subtle, sallow, grayish discoloration of the skin of the face and dorsa of the hands and arms. This color was most apparent in the periorbital area. Unexposed areas of skin were normally colored. The proximal third of the fingernail beds were faintly bluish. Mucous membranes were not discolored. The general physical examination revealed no abnormalities except for a tachyarrhythmia.

Results of routine laboratory studies and arterial blood gases were normal. An electrocardiogram disclosed paroxysmal atrial tachycardia. Biopsies of normal appearing skin from the buttock were obtained under local anesthesia. Other than for silver depo-

Accepted for publication Aug 30, 1977.

From the Dermatology Services, Veterans Administration Hospital, and the Department of Dermatology, University of Miami (Fla) School of Medicine.

Reprint requests to Department of Dermatology, University of Miami School of Medicine, PO Box 520875, Biscayne Annex, Miami, FL 33152 (Dr Pariser).

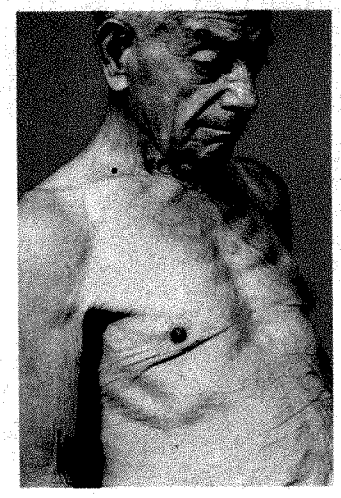

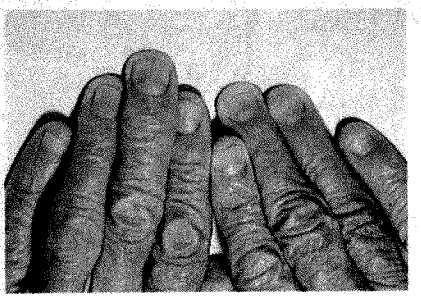

Fig 1

Fig 2

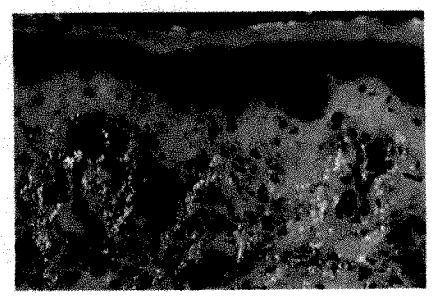

Fig 3

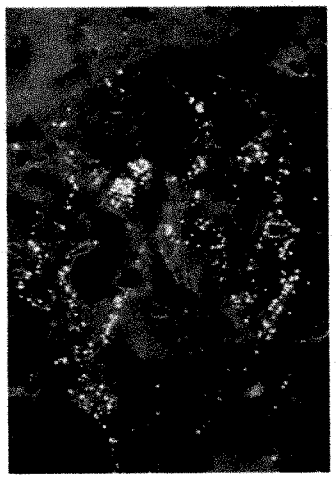

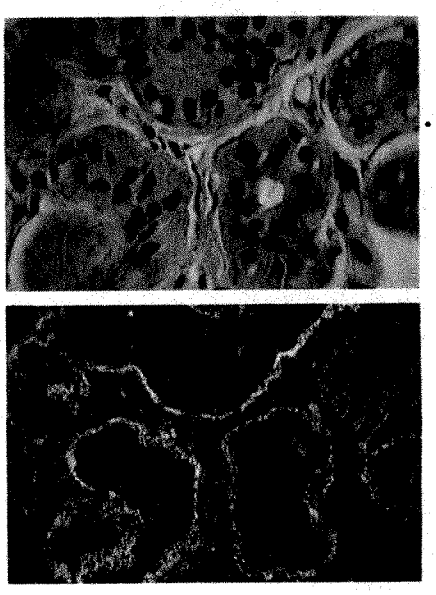

Fig 4



Fig 5

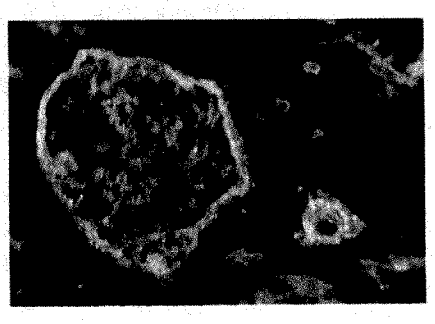

Fig 6

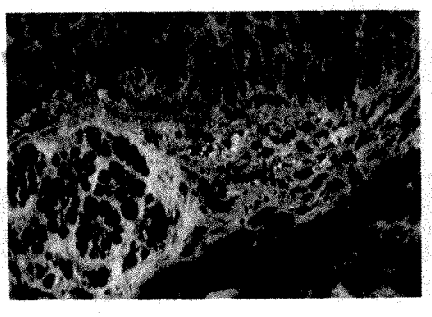

Fig 7

Fig 1.—Left, Abnormal pigmentation is most prominent in sun-exposed areas. Right, Azure-blue color of nail beds extends slightly beyond lunulae (case 1).

Fig 2.—Bluish discoloration of proximal nail bed is fainter and less extensive than in case 1 (case 2).

Fig 3.—Left, Skin from lower part of back. Silver-containing granules appear as bright particles in superficial dermis (hematoxylin-eosin, darkfield illumination, original magnification ×200). Right, Higher power view of section at left. Granules are deposited along elastic fibers in a "chain of streptococci" pattern (case 1), original magnification ×400).

Fig 4.—Left, Skin from neck. Silver-containing granules are visible as inconspicuous dark particles surrounding secretory coils of eccrine sweat glands (hematoxylin-eosin, brightfield illumination, original magnification ×400). Right, Same section as at left but under darkfield illumination. Granules stand out as bright particles in basal lamina of glands. (case 1).

Fig 5.—Left, Skin from lower part of back. Some larger granules can be seen in smooth muscle of arrector pili (hematoxylin-eosin, brightfield illumination, original magnification ×400). Right, Same section as at left, but under darkfield illumination. Extent of silver deposition is more fully revealed (case 1).

Fig 6.—Skin from upper arm shows a cutaneous arteriole (lower right) and nerve. Scattered silver-containing granules, invisible with brightfield microscopy, appear in arterioral wall and in perineural tissue (case 2, hematoxylin-eosin, darkfield illumination, original magnification ×400).

Fig 7.—Skin from upper arm. Granules in connective tissue surrounding sebaceous glands could be seen only with darkfield illumination (case 2, hematoxylin-eosin, original magnification ×400).

sition, no microscopic abnormalities were present.

HISTOLOGICAL STUDIES

Formaldehyde-fixed, paraffin-embedded sections were stained with hematoxylin-eosin. All sections were examined for silver deposition under ordinary (brightfield) and darkfield illumination; the latter reveals particles that would otherwise be missed.[1] The histologic localization of the sliver-containing granules in the skin sections is summarized in Table 1. All biopsy specimens from all cases shared the following findings: No granules were present in the epidermis, follicular epithelium, or sebaceous glands. In the papillary and upper reticular dermis, granules were located along vertically oriented elastic fibers in an arrangement that has been likened to "chains of streptococci"[2] (Fig 3). In the remainder of the dermis, the granules were scattered throughout the collagen bundles, more densely in the superficial than the deep dermis, giving the appearance under darkfield illumination of "stars in the heavens."[2] There were few granules in the hypodermis.

Table 1.—Histologic Location of Silver-Containing Particles

Microscopic Location	Case 1	Case 2	Case 3
Basal lamina of secretory portion of eccrine glands	+ + +*	+ +	+ +
Elastic fibers, papillary dermis	+ + +	+ +	+ +
Dermal collagen	+ +	+	+
Connective tissue around pilosebaceous structures	+ +	+	+ +
Arrector pili muscles	+ +	+	+
Arteriolar walls	+	+	+
Perineura tissue	+	+	+

*Grading of density of granules: abundant, + + +; moderate, + +; sparse, +.

The most striking localization of granules was around the eccrine sweat glands (Fig 4). The basal lamina surrounding the secretory portion of the glands was studded with granules. Granules were not deposited around the ductal portion of the glands. Less dense localizations of granules were present in the connective tissue surrounding pilosebaceous units, in arteriolar walls, in perineural tissue, and in arrector pili muscles (Fig 5 to 7).

In case 1 neither the basal cell carcinoma nor the atypical junctional nevus contained granules, although they were present in the immediately adjacent normal skin.

Darkfield examination of 25 skin biopsy specimens from elderly patients with various dermatoses other than argyria failed to show similar granules.

HISTOCHEMICAL STUDIES

The differential solubility methods of Buckley et al[3] were used to determine the chemical nature of the silver-containing particles. For these studies both formaldehyde-fixed, paraffin-embedded, unstained sections and unfixed frozen sections were used. Treatments were (1) thiosulfate (Kodak F-5) fixing bath, which dissolves mercaptides, oxides, chlorides, bromides, iodides, carbonates, and phosphates of silver, (2) ferricyanide-bromide bleach (2% potassium ferricyanide plus 1% potassium bromide), followed by 2 thiosulfate fixing bath, which removes metallic silver, and (3) 5% sodium cyanide, which dissolves the most insoluble silver salts such as sulfides. Sections were immersed in each solution for five minutes. Sections were observed and photomicrographs were taken before and after each treatment. The results are summarized in Table 2.

The granules in all biopsy specimens from all sites dissolved in the cyanide solution but not in the other reagents (Fig 8). The results were the same for sections treated individually with each reagent, or sequentially in the order shown in Table 2. Extending treatment times to 30 minutes did not alter the results. Both formaldehyde-fixed and unfixed frozen sections reacted identically. This pattern of solubility is what would be expected of silver sulfide.

COMMENT

In their monograph on argyria, Hill and Pillsbury summarized the historical and clinical findings of generalized argyria.[4] This disorder generally arises through gastrointestinal absorption of silver-containing substances in medicinal or industrial products or via parenteral administration. Absorption of sufficient quantities of silver through damaged skin or via the respiratory tract to produce generalized argyria has been suggested.[4] Clinical findings in argyria are limited to discoloration of the skin, mucous membranes, and nails. The peculiar color of the skin and mucous membranes has been variously described as slatey, metallic, blue-gray,[5,6] or most descriptively, as "resembling a corpse suddenly come to life."[7] This color is said to be due to both the silver itself and to a silver-induced increase in melanin, most pronounced in sun-exposed areas.[2,8-10] The color of the nail beds is azure-blue.[11] Although of no apparent physiologic significance, silver has been detected in most internal organs[4] and in the blood[5,12] in cases of argyria. Silver is said not be deposit in neural tissues or in epithelia,[2,5] although one recent study reported the presence of silver-melanin complexes in the epidermis.[9]

In the skin, the silver-containing

particles have consistently been observed in the basal lamina of the secretory portion of the eccrine sweat glands, the dermal elastic fibers, blood vessel walls, connective tissue around the sebaceous glands, and dermalcollagen fibers.[4,13,14] In some cases granules have been observed at the dermoepidermal junction, the arrector pili muscles, and the perineural tissue.[2-4] The subjects described above demonstrated most of these pathological findings.

On the basis of theoretical considerations, the chemical nature of the particles in generalized argyria has variously been stated to be metallic silver, silver albuminate, chloride, oxide, sulfate, or sulfide.[4] In the histochemical studies described above, the granules behaved as would be expected of silver sulfide. Although this evidence, as to chemical nature of the granules is not conclusive, it does indicate that the granules are not composed of the more soluble silver salts such as those suggested in the literature. The study of Buckley and Terhaar of a case of generalized argyria presented evidence that the silver in the skin was present in the metallic form.[9] The reason for this discrepancy with the current study is unknown but might relate to the nature of the ingested silver compound. The patient of Buckley and Terhaar ingested silver nitrate; in cases 2 and 3, and possibly in case 1, of this report, mild silver protein was the offending agent. The fact that formaldehyde-fixed and frozen sections behaved identically confirms that, as had been assumed in other studies, fixation in formaldehyde does not alter the chemical nature of the deposited particles.

Table 2.—Histochemical Treatments

Treatment	Results
Thiosulfate fixing bath	+*
Ferricyanide bromide bleach	+
Sodium cyanide	−

*Plus sign indicates granules present in same location and density after treatment as in control sections. Minus sign indicates granules dissolved by the treatment. All biopsy specimens from all cases behaved indentically. Details of procedure in text.

Other studies have suggested the deposition of silver-sulfur compounds in tissues. In a study in which silver nitrate was fed to rats, granules deposited in the renal glomeruli were said to consist of silver combined with sulfur, on the basis of preliminary x-ray diffraction studies.[15] In their study of localized argyria due to contact with photographic fixing bath (containing silver thiosulfates), Buckley et al found the deposits to consist of silver sulfide.[3]

The minimum amount of silver needed to produce observable color change in the skin is not known with certainty. It has been estimated that generalized argyria has been produced by total doses of 6 gm of orally administered silver nitrate and 6.3 gm of intravenously given silver arsphenamine,[4] corresponding to 3.8 and 0.9 gm of elemental silver, respectively. That there may be no "safe" limit of silver intake was suggested by Gaul and Staud, whose studies of normal people and patients receiving silver arsphenamine demonstrated subclinical deposition of silver in both.[16-18] The amount of silver in the skin was directly proportional to the age of the controls, and the authors attribute its presence to the gradual accumulation of silver from environmental exposure to silver-containing utensils, containers, etc. A more recent study using neutron activation has demonstrated the presence of silver in the skin, bone, and liver of people without history of silver intake.[19]

The findings in case 2 and 3 confirm that microscopically demonstrable silver deposition in the skin can occur with few, if any, clinical signs. The ability of darkfield microscopy to demonstrate "subclinical argyria" is based on its superiority to ordinary microscopy in detecting small particles.[20] In cases 2 and 3 the size and density of the silver particles in the skin was such that they were virtually invisible under brightfield illumination, yet could easily be seen with darkfield illumination. Darkfield microscopy also has the advantage of being more readily available than chemical or physical-chemical techniques for screening skin specimens.

No specific symptoms or physiologic alterations have been associated with the tissue deposition of silver; however, in the absence of a thorough search for subtle effects, this possibility remains open. Even in the absence of specific organ damage, cosmetic disability in full-blown cases of argyria can be profound. The unacceptability of the ashen complexion of argyria is evidenced by the prolonged and painful treatments patients have

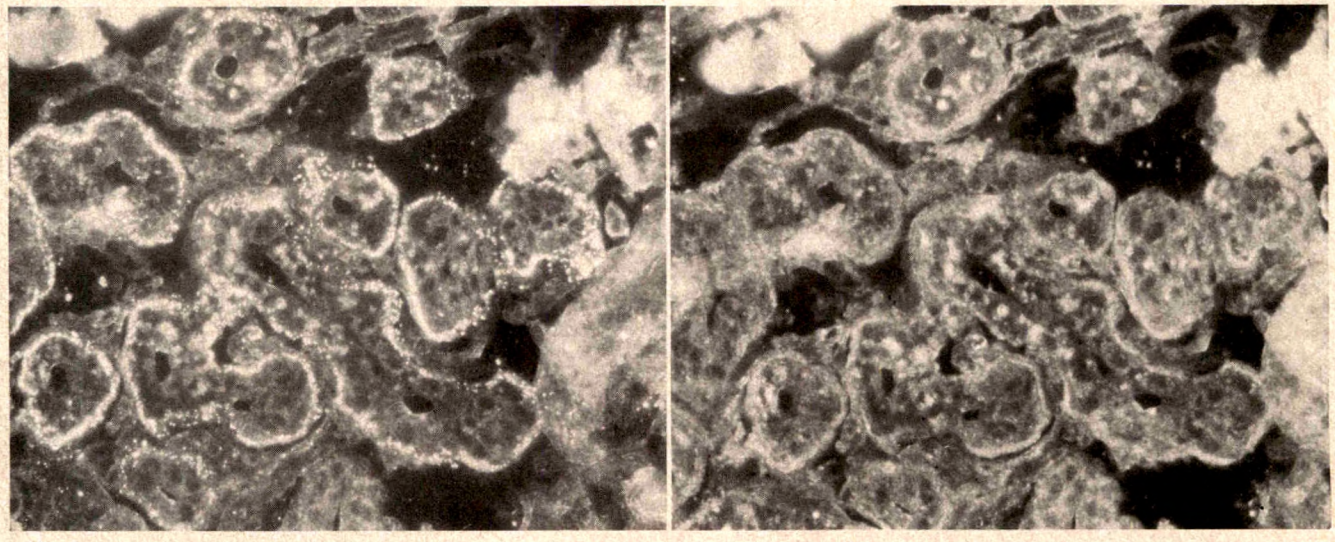

Fig 8.—Skin from lower part of back shows differential solubility of silver-containing granules. Sections were formaldehyde-fixed, unstained, and unmounted. (Case 1, darkfield illumination, original magnification ×400). Left, Granules around sweat glands; no treatment. Appearance of these sections was unchanged by treatment with thiosulfate fixing bath and by ferricyanide-bromide bleach. Right, Same section after treatment with sodium cyanide.

been willing to undergo in attempts to remove the pigment (see below).

Establishing the diagnosis of generalized argyria assumes particular importance when differentiation from other causes of cutaneous discoloration must be made. In full-blown cases of argyria the slatey-blue discoloration of the skin, accentuated in sun-exposed areas and associated with azure lunulae, presents a diagnostic picture. Probably because of unfamiliarity with the disease, it has been confused with cyanosis, as occurred in case 1 of this report and a number of reported cases, and patients have been subjected to expensive and invasive diagnostic procedures in a fruitless search for cardiopulmonary disease.[6,21] Methhemoglobinemia and polycythemia have been considered in the differential diagnosis, but these conditions have other associated findings and the abnormal color can be blanched by pressure.[6] The hyperpigmentation due to Addison's disease, hemochromatosis, and Wilson's disease and the melanosis due to widespread melanoma can usually be distinguished clinically.[2,6,21] Bluish skin discoloration can result from antimalarial therapy[22,23] or chlorpromazine,[24] but the history and histology differentiate those conditions from argyria. It may be more difficult to differentiate pigmentation from other metals such as gold, mercury, and particularly bismuth,[9,25-27] but histologic or histochemical study should clarify questionable cases. Blue discoloration of the nails may occur in Wilson's disease[28] and in *Pseudomonas* onychia,[29,30] or following the systemic administration of quinacrine hydrochloride.[31] Local applications of mercury can produce temporary black discoloration of the nail plate.[32,33]

There is no effective treatment for argyria, although potassium iodide,[34] methenamine,[35] and thiosulfate sodium[36] have been the subject of anecdotal reports. Lightening of the skin in patients with argyria has been produced by intradermal injection of a mixture of potassium ferricyanide and thiosulfate sodium (photographic reducing solution),[37-40] a painful and tedious procedure, but whether this solution removed silver or simply bleached melanin is not clear. Biopsy of argyric skin so treated was not reported in these studies, nor were injections into normal or simply hypermelanotic skin reported. If, as suggested by the current study, the silver present in the skin is a sulfide, photographic reducing solution would not be expected to dissolve it.

The potential for the production of generalized argyria still exists, as there are a number of silver-containing products available, some without prescription, for use on skin and mucous membranes, including silver protein (Argyrol, Protargol), colloidal silver iodide (Neo-Silvol), silver nitrate, and sulfadiazine silver (Silvadene). Outside the United States, a number of other silver-containing products are available.[41] Indiscriminate use of the products in the mouth or nose can result in ingestion of enough silver to cause generalized argyria.

Cost of color reproduction was paid in part by Westwood Pharmaceuticals.

References

1. Zoon JJ: Ueber histologische befunde bei argyria cutis. *Dermatol Z* 70:125-133, 1934.
2. Hill WR, Montgomery H: Argyria: With special reference to the cutaneous histopathology. *Arch Dermatol* 44:588-598, 1941.
3. Buckley WR, Oster, CF, Fassett DW: Localized argyria: II. Chemical nature of the silver containing particles. *Arch Dermatol* 92:697-705, 1965.
4. Hill WR, Pillsbury DM: *Argyria: The Pharmacology of Silver*. Baltimore, Md, Williams & Wilkins Co, 1939, pp 6-99.
5. Brinton WD: Argyria: Report of a case. *Guys Hosp Rep* 98:88-94, 1949.
6. Rich LL, Epinette WW, Nasser WK: Argyria presenting as cyanotic heart disease. *Am J Cardiol* 30:290-297, 1972.
7. Bryant BL: Argyria resulting from intranasal medication. *Arch Otolaryngol* 31:127-139, 1940.
8. Peterson WC Jr: Argyria. *Minn Med* 51:533-534, 1968.
9. Buckley WR, Terhaar CJ: The skin as an excretory organ in argyria. *Trans St Johns Hosp Dermatol Soc* 59:34-44, 1973.
10. Mehta AC, Dawson-Butterworth K: Argyria: Electron microscopic study of a case. *Br J Dermatol* 78:175-179, 1966.
11. Whelton MJ, Pope FM: Azure lunules in argyria. *Arch Intern Med* 121:267-279, 1968.
12. Blumberg H, Carey TN: Argyremia: Detection of unsuspected and obscure argyria in the spectographic demonstration of high blood silver. *JAMA* 103-1521-1524, 1934.
13. Gettler AO, Rhoads CP, Weiss S: A Contribution to the pathology of generalized argyria with a discussion of the fate of silver in the human body. *Am J Pathol* 3:631-651, 1927.
14. Prose PH: An electron microscopy study of human generalized argyria. *Am J Pathol* 42:293-299, 1963.
15. Van Breemen VL, Reger JF, Cooper WG: Observations on the basement membranes in rat kidney. *J Biophysic Biochem Cytol* 2(suppl):283-285, 1956.
16. Gaul LE, Staud AH: Clinical spectroscopy: A study of biopsy material from patients who had received intravenous injections of silver arsphenamine. *Arch Dermatol* 30:433-438, 1934.
17. Gaul LE, Staud AH: Clinical spectroscopy: Quantative distribution of silver in the body or its physiopathologic retention as a reciprocal of the capillary system. *Arch Dermatol* 32:775-780, 1935.
18. Gaul LE, Staud AH: Clinical spectroscopy: Seventy cases of generalized argyria following organic and colloidal silver medication, including biospectrometric analysis of ten cases. *JAMA* 104:1387-1390, 1935.
19. Czitober H, Frischauf H, Leodolter I: Quantative Untersuch ungen bei universeller argyrose mittels neutronenaktivierungs analyze. *Virchows Arch [Pathol Anat]* 350:44-51, 1970.
20. Barer R: Microscopes, microscopy, and microbiology. *Annu Rev Microbiol* 28:371-389, 1974.
21. Levine SA, Smith JA: Argyria confused with heart disease. *N Engl J Med* 226:682-684, 1947.
22. Zachariae H: Pigmentation of skin and oral mucosa after prolonged treatment with chloroquine. *Acta Derm Venereol (Stockh)* 43:149-153, 1963.
23. Tuffanelli D, Abraham R, Dubois EI: Pigmentation from antimalarial therapy. *Arch Dermatol* 88:419-426, 1963.
24. Hays GB, Lyle CB Jr, Wheeler CE: Slate-gray color in patients receiving chlorpromazine. *Arch Dermatol* 90:471-476, 1964.
25. Spiegel L: A discoloration of the skin and mucous membranes resembling argyria following the use of bismuth and silver arsphenamine. *Arch Dermatol* 23:266-286, 1931.
26. Lueth HC, Sutton DC, McMullen CJ, et al: Generalized discoloration of skin resembling argyria following prolonged use of bismuth: A case of "bismuthia." *Arch Intern Med* 57:1115-1124, 1936.
27. Burge KM, Winklemann RK: Mercury pigmentation: An electron microscopic study. *Arch Dermatol* 102:51-61, 1970.
28. Bearn AG, McKusick VA: An unusual change in the finger nails in two patients with hepatolenticular degeneration (Wilson's disease). *JAMA* 166:904-906, 1958.
29. Bauer MF, Cohen H: The role of *Pseudomonas aeruginosa* in infections about the nails. *Arch Dermatol* 75:394-396, 1957.
30. Chernosky MF, Dukes CD: Green nails: The importance of *Pseudomonas aeruginosa* in onychia. *Arch Dermatol* 88:548-553, 1963.
31. Lutterlok CH, Shallenberger DL: Unusual pigmentation developing after prolonged suppressive therapy with quinacine HCl. *Arch Dermatol* 53:349-354, 1946.
32. Calloway JL: Transient discoloration of the nails due to mercury bichloride. *Arch Dermatol* 36:62-64, 1937.
33. Butterworth T, Stream LP: Mercurial pigmentation of the nails. *Arch Dermatol* 88:55-57, 1963.
34. Yandell LP Jr: Cyanosis from nitrate of silver removed by iodide of potassium. *Am Pract* 5:329-330, 1872.
35. Crispin AM: Argyrism following the use of callargol. *JAMA* 62:1394, 1914.
36. Cannon AB: Value of silver arsphenanine in treatment of early syphilis. *JAMA* 102:268-273, 1934.
37. Stillians AW, Lawless TK: An intracutaneous method in treating argyria. *Arch Dermatol* 17:153-155, 1928.
38. Stillians AW, Lawless TK: The intradermal treatment of argyria. *JAMA* 92:20-21, 1929.
39. Stillians AW: Argyria: The practical value of its endermic treatment, in *Report of the Eighth International Congress of Dermatology and Syphilis*. 1930, pp 714-718.
40. Stillians AW: Argyria. *Arch Dermatol* 35:67-77, 1937.
41. Blacow NW (ed): *Martindale: The Extra Pharmacopoeia*, (ed 26). London, The Pharmaceutical Press, 1972.

Relationship Between Arsenic Intake and Internal Malignant Neoplasms

Flemming Reymann, MD; Rigmor Møller, MD; Arne Nielsen, MSc

• An attempt has been made to assess the carcinogenic effect of arsenic intake by analyzing a group of patients who were treated with arsenic for various skin diseases in the 1930s. When compared with the expected incidence of malignant internal neoplasms, based on figures obtained from the Danish Cancer Registry, a significant increase in the incidence of internal malignant neoplasms was observed in females with multiple basal cell carcinomas. A group comprising 53 patients with arsenic keratoses presented a considerable increase in the incidence of internal malignant neoplasms. However, these patients were so specifically selected that no regular statistical analysis can be made of this group. It may be said that arsenic has a carcinogenic effect even in the relatively small doses applied in dermatological therapy.

(*Arch Dermatol* 114:378-381, 1978)

Two previous studies[1,2] investigated whether Bowen's disease and multiple basal cell carcinoma of the skin are associated with an increase in the incidence of internal malignant neoplasms. No such relationship could be demonstrated with certainty, although a few patients from the latter group had a remarkably high incidence of internal malignant neoplasms. These patients had a history of arsenic intake but the figures were too low to prove a connection between arsenic and internal malignant neoplasms. It was concluded from the findings that a more comprehensive systematic study should be undertaken to ascertain whether arsenic intake might be the cause of later malignant internal tumors. In this article, the results are reported of such a systematic study carried out in collaboration between the Danish Cancer Registry and the Department of Dermatology of the Finsen Institute, Copenhagen.

Accepted for publication Sept 22, 1977.

From the Department of Dermatology and the Danish Cancer Registry (Drs Reymann and Møller), Finsen Institute, and the University of Copenhagen (Mr Nielsen), Copenhagen.

Reprint requests to Department of Dermatology, Finsen Institute, 49 Strandboulevard, DK-2100 Copenhagen, Denmark (Dr Reymann).

MATERIAL AND METHODS

The composition of the patient material is given in Table 1. In the 1930s, arsenic was used in the treatment of lichen planus and verruca plana. From the period 1930-1939, our files contain records of a total of 292 patients with lichen planus, 161 of whom had been treated with arsenic. Of those patients with verruca plana, 72 had received arsenic treatment. Generally, psoriasis was not treated with arsenic, but among the patients with psoriasis treated with methotrexate in our department, 93 had been treated with arsenic drugs in other units. From the investigations aforementioned concerning the relationship between internal malignant neoplasms and Bowen's disease or multiple basal cell carcinoma, 36 and 51 patients, respectively, were found to have received arsenic. As the preliminary studies seemed to indicate a correlation between internal malignant neoplasms and arsenical keratoses, the total number of patients with keratoses from all the groups aforementioned and an additional 30 patients, who were registered in the diagnostic records under this heading, were collected in a special group comprising 53 patients. Dosage and type of arsenic agents used are given in Tables 2 and 3. Although the assessment of the total arsenic dose is rather inaccurate, an attempt was nevertheless made to classify the patients according to dosage of arsenic.

All of the patients have been traced through the population register and for those who died, death certificates were procured.

The patients were also traced from the records of the Danish Cancer Register. All cases of internal malignant neoplasms in Denmark treated by physicians are reported to this registry, and all death certificates, which are collected in the National Health Service's registry, are forwarded to the Cancer Registry. This procedure ensures a high degree of accuracy in registration.[3,4]

The following number of patients were excluded from the study: 11 who did not appear in the population register because of emigration, etc., nine who had died, and two who had emigrated before 1943. An additional two patients were excluded because they already suffered from internal malignant neoplasms at their first appearance in the Department of Dermatology. The study then comprised 389 patients who had been treated with arsenic and, in a special group, 53 patients with arsenical keratoses.

For each of these 389 patients, the length of the observation period is calculated as described in a previous report,[2] and the expected number of internal malignant neoplasms is calculated on the basis hereof.

RESULTS

It appears from the data given in Table 1 that in 41 of the arsenic-treated patients, 20 males and 21 females, internal cancer had developed during the period 1943-1974, the expected number being 44.6. Hence, no significantly higher incidence of internal cancer was found in the material as a whole.

Table 1.—Distribution of Patients and No. of Observed/Expected Cases of Internal Malignant Neoplasms

	No. of Patients, Men/Women	No. of Patients with Internal Malignant Neoplasms		
		Men, Observed/Expected	Women, Observed/Expected	Total, Observed/Expected
Multiple basal cell carcinoma	17/34	2/1.1	5/1.2	7/2.3
Bowen's disease	16/20	3/2.4	2/2.4	5/4.8
Psoriasis	50/42	0/2.8	0/2.3	0/5.1
Verruca plana	19/45	1/0.7	8/4.1	9/4.8
Lichen planus	68/78	14/12.4	6/15.3	20/27.7
Total	**170/219**	**20/19.4**	**21/25.3**	**41/44.7**

Table 2.—Distribution of Patients With Internal Malignant Neoplasms According to Dosage of Arsenic

	Men, Observed/Expected	Women, Observed/Expected	Total, Observed/Expected
Minor dose, ie, standard daily dose* for less than 1 mo	6/4.1	1/7.0	7/11.1
Medium dose, ie, standard daily dose* for 1 to 3 mo	3/3.8	6/7.0	9/10.8
Large dose, ie, standard daily dose* for more than 3 mo	4/3.7	2/2.8	6/6.5
Dose unknown	7/7.8	12/8.6	19/16.4
Total	**20/19.4**	**21/25.4**	**41/44.8**

*Standard daily dose is 6 to 8 mg As_2O_3.

Table 3.—Distribution of Internal Malignant Neoplasms According to Type of Arsenic Agents

	Men, Observed/Expected	Women, Observed/Expected
Fowler's solution	5/3.8	11/9.8
Allylarsonic acid	6/7.8	3/8.6
Miscellaneous agents	4/2.2	3/1.3
Unknown agents	5/5.6	4/5.5
Total	**20/19.4**	**21/25.2**

As regards the individual skin diseases, only women with multiple basal cell carcinoma had a significantly higher incidence of internal cancer: five observed compared with the expected 1.2 ($P < .05$). The same trend, although not significant, was found in women with verruca plana: eight observed compared with the expected 4.1. However, as regards women with lichen planus, a significantly lower incidence of internal cancer was observed: six compared with the expected 15.3 ($P < .05$). In an attempt to explain this surprising difference, 131 patients with lichen planus from the period 1930-1939, who had not been treated with arsenic, were examined in the same way. Among the men, nine cases of internal cancer were observed compared with the expected number of 9.8, and among the women, seven were observed compared with the expected 11.7. The tendency is the same as for the arsenic-treated patients although none of the deviations is significant.

Neither the total dose of arsenic (Table 2) nor the type of arsenic agent (Table 3) seems to affect the incidence of internal cancer. The relatively few cases in women observed in the individual groups can be explained by a preponderance of female patients with lichen planus. By dividing the observation period into five-year periods (Table 4), it will be seen that the cases of internal cancer are distributed as expected over the entire period from 1943 to 1974.

The 19 men and 34 women with arsenical keratoses were not analyzed in the same way because this diagnosis is almost always established quite accidentally.

Eight of the men with arsenical keratoses died before 1974: two in the age group 45 to 64 years and six in the age group 65 to 84 years. In four of the cases, the diagnosis was internal cancer. According to "Causes of Death in Denmark"[5] for the years 1951 to 1974, 28% of the deaths in the 45 to 64 years old age group and 22% in the 65 to 84 years old age group were due to internal cancer. Consequently, 1.9 of the eight deaths could be expected to be caused by internal cancer. Ten of the women of this group had died, five in the age group 45 to 64 years old and five in the age group 65 to 84 years old. Five of these died form internal cancer. In women, internal malignant neoplasms is the cause of death in 44% of all deaths in the 45 to 64 years old age group and in 22% in the 65 to 84 years old age group, giving an expected figure of 3.3. Collectively, nine deaths were caused by internal cancer against the expected number of 5.2, ie., almost double that expected. In none of the groups are the differences significant.

On an average, the patients with arsenical keratoses have received higher doses of arsenic than the 389 patients included in the group first described. However, "dose unknown" applies to approximately 43% in both instances.

COMMENT

Arsenic has been used extensively in dermatological therapy right up to the midtwentieth century despite the fact that as early as 1887 Hutchinson[6] (and after him several other authors) pointed out the probable correlation between arsenic intake and the development of various precancerous and malignant skin tumors. Although a statistical analysis of these conditions is not available, it must be considered clinically evident that arsenic intake can give rise to the development of skin tumors.[7,8]

Investigations in Taiwan and in the Mosel Valley indicate that arsenic intake can cause development of internal malignant neoplasms in the same way as inhalation of arsenic-containing fumes or dust is presumed to cause lung cancer. However, because of lack of suitable control materials, this has never been definitely proved.

The Danish Cancer Registry, which covers the whole of Denmark, has existed since 1943, and from this

Table 4.—Distribution of Internal Malignant Neoplasms According to Period of Observation

Period	Men, Observed/Expected	Women, Observed/Expected	Total, Observed/Expected
1943-1947	2/1.6	2/2.6	**4/4.2**
1948-1952	3/2.2	0/2.9	**3/5.1**
1953-1957	2/2.5	2/3.5	**4/6.0**
1958-1962	5/2.9	2/4.1	**7/7.0**
1963-1967	6/3.3	5/4.5	**11/7.8**
1968-1972	1/4.5	8/5.3	**9/9.8**
1973-1974	1/2.2	2/2.4	**3/4.6**
Total	**20/19.2**	**21/25.3**	**41/44.5**

Table 5.—Distribution of the Entire Material and of Patients With Observed Arsenical Keratoses According to Dosage of Arsenic

	Men, Entire Material/Keratoses	Women, Entire Material/Keratoses
Minor dose	35/1	45/5
Medium dose	32/1	52/3
Large dose	30/9	26/11
Dose unknown	74/8	95/15
Total	**171/19**	**218/34**

registry very accurate control material can be obtained.

The population in Taiwan,[8] and the winegrowers in the Mosel Valley[9,10] have through the drinking water and through pesticides, respectively, been exposed to massive influence of arsenic over many years, similar to certain miners.[11] The drinking water in Denmark contains no arsenic, and arsenic-containing sprays used for disinfestation have not been applied to the same extent as in the wine-producing countries. Neither is there a mining industry in Denmark. Hence, compared to the aforementioned population groups, the Danish patients have received very low amounts of arsenic, and this makes a comparison rather difficult.

On the other hand, arsenic-containing drugs, in particular those combined with iron, have been used widely in Denmark in the treatment of various diseases and debilities. Apart from the dose of arsenic recorded, the patients comprised by the present study might well have been treated with such arsenic-containing drugs many years ago and in unknown amounts. No doubt the total doses stated are minimum ones, but even so, compared with the aforementioned population groups, they are very moderate.

The Taiwan group in particular proves that the individual latent period varies very much as regards development of skin tumors and other arsenic complications as, eg, Blackfoot disease.[8] It is not known whether the difference in the capability of retaining arsenic intake, demonstrated by Bettley and O'Shea,[12] is of any importance in this connection. The latent period for the development of skin cancer or arsenical keratoses is most often 20 to 30 years or more.

It is characteristic that the development of arsenical keratoses depends on the dosage.[7,8,13] Most people will have keratoses develop if they have received sufficiently high doses of arsenic for longer periods of time.

Table 1 shows that among women with multiple basal cell carcinoma treated with arsenic there is a significantly increased incidence of internal malignant neoplasms. The figures for women with verruca plana support the assumption that arsenic is responsible for this preponderance, although the difference is not significant. It is remarkable that this applies only to women, whereas there is close agreement between expected and observed numbers of neoplasms in men.

During a previous study,[1] no increased incidence of internal malignant neoplasms was found among Danish patients with Bowen's disease contrary to the findings in a number of American studies. Nor in the present material comprising patients with Bowen's disease treated with arsenic was there an increase in the incidence of internal malignant neoplasms.

Similar to the findings in American patients with Bowen's disease, women with multiple basal cell carcinoma and verruca plana (Table 1) had an increased incidence of internal malignant neoplasms. If this is compared to the fact that the development of arsenical keratoses depends on the size of the dose, the question arises as to whether the women in our material and the American patients with Bowen's disease had received more arsenic through fattening cures or in arsenic-containing drinking water, respectively. Unfortunately, it is not possible to investigate these problems further.

We have not been able to explain the surprisingly low number of cases of internal malignant neoplasms among women treated with arsenic for lichen planus. In the entire material (Table 1), this has the result that the increased incidence of internal malignant neoplasms in the groups "multiple basal cell carcinoma" and "verruca plana" is not expressed. Consequently, it is not possible on the basis of the entire material to assess whether moderate treatment with arsenic will cause increased incidence of internal malignant neoplasms.

The group of patients with arsenical keratoses is rather special because the patients have not been studied systematically with this disease in mind. Therefore, the cases found form a rather inhomogenous group, and no other statistical assessment than the one done here is possible. The diagnosis of arsenical keratosis is established on clinical grounds only and includes keratoses both on plantae and volae and on the body and the extremities. These patients, in whom a remarkably high incidence of internal malignant neoplasms was observed, cannot, because of the method of selection, be subjected to a close statistical review. Consequently, it is not possible to decide whether the observed increase in internal malignant neoplasms is statistically significant.

Despite the incomplete statistical analysis, it is permissible to conclude, on the existing basis, that patients in whom arsenical keratoses develop have a higher morbidity than the normal population as far as internal malignant neoplasms are concerned. If the two groups of arsenic-treated patients with multiple basal cell carcinoma and patients with arsenical keratoses are compared, there is no irrefutable statistical evidence to suggest that arsenic in low doses will cause increased incidence of internal malignant neoplasms, but the studies have rendered this highly possible.

Previous studies have given rise to the assumption that there is a relationship between internal malignant neoplasms and palmar keratoses,[11] but

arsenic could not be proved to be a common etiologic factor. In the present material, this correlation seems to be obvious, although it must again be emphasized that the material is selected.

It appears from Table 5 that the intake of arsenic is high in patients with keratoses, but it should be pointed out that the total dose is unknown in about 43% of the cases in both groups. The amount of arsenic taken seems thus to influence the development both of arsenical keratoses and of internal malignant neoplasms.

For women in the entire material, the latent period for development of internal malignant neoplasms is 33.5 years and for men it is 24.9 years. In patients with arsenical keratoses, the latent period is 35 years for women and for men it is 20 years. These figures diverge considerably but there is nothing to indicate that internal malignant neoplasms develop earlier in patients with arsenical keratoses.

The distribution of type and site of the internal malignant neoplasms found corresponds to that expected according to the tables of the Cancer Registry, both for the entire material and for the patients with arsenical keratoses.

CONCLUSIONS

From the findings, it is concluded that arsenic should not be used in human therapy.

A further conclusion is that in patients with verified arsenical keratoses and in arsenic-treated patients with multiple basal cell carcinoma, special attention should be paid to the possibility that internal malignant neoplasms may develop.

References

1. Andersen LaCours, Nielsen A, Reymann F: Relationship between Bowen disease and internal malignant tumors. *Arch Dermatol* 108:367-370, 1973.
2. Møller R, Nielsen A, Reymann F: Multiple basal cell carcinoma and internal malignant tumors. *Arch Dermatol* 111:584-585, 1975.
3. Clemmesen J: *Statistical Studies in Malignant Neoplasms I.* Copenhagen, Munksgaard, 1965.
4. Clemmesen J: *Statistical Studies in Malignant Neoplasms II.* Copenhagen, Munksgaard, 1969.
5. National Health Service: *Causes of Death in Denmark 1974.* Copenhagen, National Health Service of Denmark, 1976.
6. Hutchinson J: Arsenic cancer. *Br Med J* 2:1280-1281, 1887.
7. Fierz U: Katamnestische Untersuchungen über die Nebenwirkungen der Therapie mit anorganischen Arsen bei Hautkrankheiten. *Dermatologica* 131:41-58, 1965.
8. Yeh S, How SW, Lin CS: Arsenical cancer of skin. *Cancer* 21:312-339, 1968.
9. Denk R, Holzmann H, Lange HJ, et al: Über Arsenspätschäden bei obduzierten Moselwinzern. *Med Welt* 20:557-567, 1969.
10. Roth F: Über die chronische Arsenvergiftung der Moselwinzer unter besonderer Berücksichtigung des Arsenkrebses. *Z Krebsforsch* 61:287-319, 1956.
11. Rockstroh H: Zur Ätiologie des Bronchialkrebses in arsenverarbeiteten Nickelhütten. *Arch Geschwulstforsch* 14:151-162, 1959.
12. Bettley FR, O'Shea JA: The absorption of arsenic and its relation to carcinoma. *Br J Dermatol* 92:563-568, 1975.
13. Pinto SS, Bennett BM: Effect of arsenic trioxide exposure on mortality. *Arch Environ Health* 7:583-591, 1963.
14. Dobson RL, Young MR, Pinto JS: Palmar keratoses and cancer. *Arch Dermatol* 92:553-556, 1965.

New Requirement for Authors

Congress recently passed *The Copyright Revision Act of 1976*, effective Jan 1, 1978, which affects the American Medical Association's procedure for reviewing manuscripts submitted for publication.

In view of this law, all transmittal letters accompanying manuscripts submitted for publication should contain the following language: "In consideration of the AMA taking action in reviewing and editing my submission, the author(s) undersigned hereby transfers, assigns, or otherwise conveys all copyright ownership to the AMA in the event that such work is published by the AMA."

Diaper Area Granuloma of the Aged

Yoshihiro Maekawa, MD; Yoshikado Sakazaki, MD; Toshio Hayashibara, MD

• Nine women, aged 77 to 89 years, suffered from diaper dermatitis, and many granulomas were seen in the genital or gluteal region restricted to the lesion of dermatitis. Because these granulomas resembled granuloma gluteale infantum of Tappeiner and Pfleger, we propose to call this condition diaper area granuloma of the aged.

(*Arch Dermatol* 114:382-383, 1978)

There have been a number of reports on granuloma gluteale infantum (GGI) since it was first reported by Tappeiner and Pfleger in 1971.[1] A variety of etiologic factors have been proposed, ranging from *Candida* to detergents to fluorinated corticosteroids. However, no definitive cause has been pinpointed.

We have found similar granulomas in the diaper areas of aged women who wore diapers because of hemiplegia and other diseases. It would be interesting to compare the features of our cases with those of GGI, especially for the clarification of the cause of GGI. We propose to call this condition "diaper area granuloma of the aged."

REPORT OF CASES

Case 1.—A 79-year-old woman was first seen at the Dermatology Clinic on June 7, 1976, because of many granulomas over the buttocks and genital region. She had been confined to bed for the last two years because of hemiplegia following a stroke. She had diaper dermatitis due to incontinence of urine and feces for one year. She did not receive any treatment other than dusting powder.

Two months after the onset of diaper dermatitis, slightly elevated flat nodules developed in the diaper area and increased in number. The granulomas were round or spindle shaped, reddish-purple, 1 to 2 cm in diameter, asymptomatic, and elastically hard. In places, they eroded with bleeding (Fig 1 and 2). The diaper dermatitis improved with corticosteroid-antibiotic ointment, but the granulomatous lesions did not respond to treatment. An attempt was made to keep the diaper area clean, and in two months the granulomas became smaller and, finally, flat.

The results of routine laboratory studies were within normal limits. Fungal elements were not proved by the potassium hydroxide method or by culture. Results of patch tests with cotton or paper diapers, dusting powder, and other standard series were negative except for iodine. Results of skin tests with purified protein derivative (PPD) and *Candida* antigen were negative.

Histologic examination of the granulomas showed acanthosis with partial orthohyperkeratosis, partial parakeratosis, and spongiosis with exocytosis of mononuclear cells (Fig 3). In the dermis, an inflammatory infiltrate composed of many plasma cells, lymphocytes, eosinophils, and histiocytes was seen. Proliferated and enlarged blood capillaries and RBCs also were seen in the dermis (Fig 4). In the granulomas, foreign bodies or fungal elements were not found by polarized microscopy and PAS staining. No proliferation of Gitter fibers and collagen fibers were found, but elastic fibers were stained by acid orcein in the granuloma (Fig 5).

Case 2 to Case 9.—Clinical findings were essentially the same as in case 1. Histories and results of laboratory examinations are summarized in the Table.

Fig 1.—Several reddish-purple nodules, 1 to 2 cm in diameter and round or spindle shaped, appeared over the diaper region of 79-year-old woman (case 1).

Fig 2.—Few granulomas resembling granuloma gluteale infantum of Tappeiner and Pfleger developed over diaper dermatitis (case 3).

COMMENT

All nine patients were women, ranging in age from 77 to 89 years, and had been confined to bed. The granulomas developed in the diaper region three weeks to ten months after the onset of diaper dermatitis. These granulomas showed some similarities to GGI because of preceding diaper dermatitis, shape or color, and the lesions developed. But, they were different from GGI because (1) they were not arranged parallel with the dermatome and developed strictly in the diaper area; and (2) corticosteroid ointment was not used for the treatment of the diaper dermatitis. Also, the lesions were rather similar to condyloma latum, though only one patient had positive serologic test results for syphilis.

Candida was obtained from the scales in two cases. Gram-negative cocci and bacilli were isolated from three cases each. But, it is assumed that these fungal or bacterial infections were coincidental because the region was polluted by the patients' urine or feces.

Results of patch tests did not offer any conclusive information about the

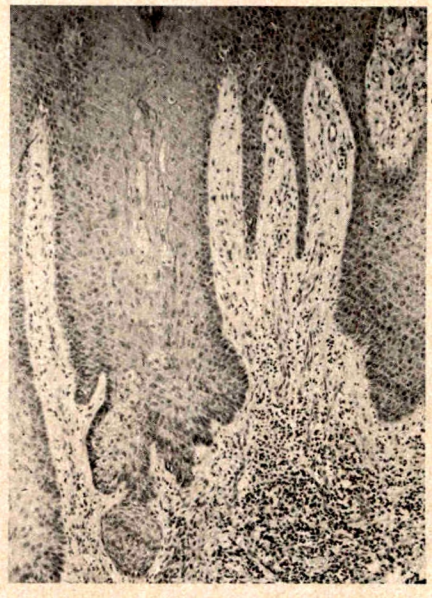

Fig 3.—Epidermis shows remarkable acanthosis and spongiosis with exocytosis of mononuclear cells (hematoxylin-eosin, original magnification ×100).

Accepted for publication Feb 11, 1977.

From the Department of Dermatology, Kumamoto University Medical School, Kumamoto, Japan.

Reprint requests to Department of Dermatology, Kumamoto University Medical School, 860 Honjo 1-1-1, Kumamoto, Japan (Dr Maekawa).

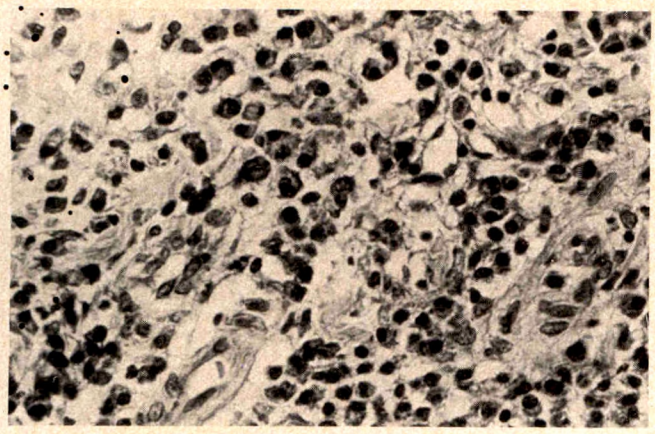

Fig 4.—Inflammatory infiltrate composed of many plasma cells, lymphocytes, eosinophils, and histiocytes was seen in cermis (hematoxylin-eosin, original magnification ×600).

Fig 5.—Elastic fibers were clearly stained but broken down in granuloma (acid-orcein Verhoff, original magnification ×400).

Clinical Features of Nine Patients With Diaper Area Granuloma of the Aged

Patient/ Sex/ Age, yr	Preceding Disease	Time From Onset of Dermatitis to Granuloma	Localization	Culture		Patch Test		Intracutaneous Test	
				Fungus	Bacillus	Diaper	Standard Series	*Candida*, mm	PPD, mm
1/F/79	Diaper dermatitis 9/75	2 mo	Buttocks, genitalia	...	Gram-negative cocci	...	Iodine	3 × 3	3 × 4
2/F/83	Diaper dermatitis 7/23/75	10 mo	Buttocks, genitalia	...	...	...	Urushiol	7 × 7	4 × 7
3/F/79	Diaper dermatitis 6/75, candidiasis cutis	3 wk	Buttocks, perianal	*Candida*	ND*	...	Iodine	20 × 15	16 × 15
4/F/77	Diaper dermatitis	Not known	Buttocks	...	Gram-negative bacilli, cocci	...	...	9 × 10	8 × 9
5/F/85	Diaper dermatitis 6/75	8 mo	Buttocks	...	ND	...	Urushiol, iodine, $K_2Cr_2O_7$, Bergamot oil	11 × 11	8 × 12
6/F/83	Diaper dermatitis	Not known	Buttocks, genitalia	...	ND	...	...	ND	ND
7/F/83	Diaper dermatitis 7/25/75	10 mo	Buttocks	*Candida*	Gram-negative bacilli	...	ND	7 × 7	4 × 3
8/F/79	Diaper dermatitis	Not known	Buttocks, genitalia	...	Gram-negative bacilli, cocci	...	...	7 × 7	5 × 6
9/F/89	Diaper dermatitis	Not known	Buttocks, genitalia	..	...	...	ND	ND	ND

*Not done.

immunopathologic mechanisms of the granulomas. The patch test results of used, 48-hour-old diaper material and dusting powder were negative in all cases, and the standard series did not yield any pathologic findings. The possibility exists that the lesions could be the result of the impaired cellular immunity of the aged person because of lower sensitivity to PPD or milder reactions to intracutaneously given *Candida* antigen.

Results of histologic examination, performed in cases 1 to 3, differ from the GGI reported by Kelly and Campbell[2] in which starch granules were found in the lesions. Kikuchi and Jono[3] assumed that GGI occurs as a reaction to some unknown factors, and they used corticosteroid tape on GGI with benefit. In the granulomas, no proliferation of collagen and Gitter fibers was found. These histologic findings were very similar to those from GGI described by Tappeiner and Pfleger,[1] except for a deposition of hemosiderin in the dermis.

After the onset of these granulomas, we tried to clean the region without using any corticosteroids or other ointments. The granulomas disappeared after two to three weeks. We assumed that these granulomas may have developed as a reaction to urine or feces. Therefore, careful good nursing and keeping the diaper area clean would be the best treatment. Since we have not found descriptions of the same condition in the literature, we propose to call this condition diaper area granuloma of the aged.

References

1. Tappeiner J, Pfleger L: Granuloma gluteale infantum. *Hautarzt* 22:383-388, 1971.
2. Kelly R, Campbell PE: Granuloma gluteale infantum with starch granules in the lesion. *Med J Aust* 2:438-439, 1973.
3. Kikuchi I, Jono M: Fluandrenolide impregnated tape for granuloma gluteale Infantum. *Arch Dermatol* 112:1788, 1976.

Effects of Occlusive Tape Systems on the Mitotic Activity of Epidermis

With and Without Corticosteroids

Louis B. Fisher, PhD; Howard I. Maibach, MD; Ronald J. Trancik, PhD

• This study was designed to elaborate on the effects of occlusion and corticosteroids on human epidermal mitotic activity. The experimental variables included tape delivery systems that afforded total, partial (50%), or no occlusion to normal human skin. In some experiments, hydrocortisone, flurandrenolide, betamethasone, betamethasone valerate, and fluorometholone were added to these tape systems. Using demecolcine cream, biopsies were taken, and mitotic figures were determined. Results suggest that potent antimitotic effects occur with semiocclusive and nonocclusive tapes that contain corticosteroids, and that total occlusion is not necessary for this physiological effect. This suggests the possibility that the presumably better tolerated nonocclusive and partially occlusive systems might be used as dermatological drug delivery systems.

(*Arch Dermatol* 114:384-386, 1978)

Previously, we demonstrated a profound effect of either occlusion and/or corticosteroids on the mitotic activity of normal skin.[1,2] The present investigation extends these studies to determine whether tape systems, which are either nonocclusive or 50% occlusive, are mitotic inhibitors. We also examine whether hydrocortisone exhibits a dose-response effect on human epidermal mitosis when delivered from tape systems of varying occlusivity.

MATERIALS AND METHODS

The method used for the assay of mitosis has been published.[2] Groups of four or five healthy men volunteers were studied. Several treatments were used simultaneously on each subject and cumulative results are presented in the Tables. This technique enabled each subject to act as his own control. The drugs examined were hydrocortisone, flurandrenolide (Cordran), betamethasone valerate (Valisone), betamethasone (Celestone), and fluorometholone (Oxylone).

Treatments were applied to the upper back in the morning, daily, for four days. On the morning of the final day, the materials were removed and 0.5% demecolcine (Colcemid) in hydrophilic ointment was applied under an occlusive patch. Six hours later, biopsies were taken with a 3-mm punch and fixed in Davidson's fixative (30 ml 95% ethyl alcohol; 20 ml formaldehyde solution; 10 ml glacial acetic acid; and 30 ml distilled water). Biopsy specimens were dehydrated, embedded, cut at 7 μ, and stained with the Feulgen reaction for DNA. Twelve sections that were cut from each specimen were scanned for mitoses as previously described.[2] The counts were expressed as the number of mitoses per 1,000 viable cells (mitotic rate). All cells below the granular layer were included in the scan, since mitoses frequently appear to occur suprabasally.[2] The use of demecolcine blocked the cells in metaphase, increasing the counts and enhancing the ease and reliability of the procedure. The results were statistically analyzed by comparing all treated data to untreated control data using the Student *t*-test. We counted 12,000 to 25,000 viable cells for each specimen.

Corticosteroids were formulated in tape delivery systems by the following procedure: The drug was solubilized in a solvent compatible with the acrylate adhesive, which was, in most cases, acetone. This solution was mixed in the adhesive dispersion and coated on a silicone-release paper (liner) using a knife-edge hand spreader. The desired backing (polyethylene, nonwoven rayon, or microporous film) was laminated to the adhesive/liner, affording a drug-in-tape system of desired occlusivity. The concentration of the drug per unit of tape was regulated by the coated thickness of the adhesive and the weight percentage of drug in the dry adhesive. Corticosteroid tapes were assayed by extracting drug with methanol followed by dinitrophenylhydrazine (DNPH) colorimetric analysis of the extracts.[3]

Three tape systems of different occlusivities were used. The occlusive tape had a polyethylene backing that was impervious to moisture vapor transmission. The nonocclusive tape had a porous, nonwoven rayon backing that allowed moisture vapor transmission. The microporous film (MPF) tape afforded approximately 50% occlusion, because it had an ethylene-vinyl acetate (90:10) film backing that was rendered microporous by the leachable filler technique using sodium chloride of 2 to 3-μ particle size.[4] Depending on the amount of sodium chloride and its particle size, the occlusivity of the tape system can be controlled by regulating the porosity of the backing. The degree of the occlusivity was determined by measuring the transepidermal water loss (TEWL) of a given skin site and using the following equation:

$$\% \text{ Tape occlusivity} = (\text{TEWL skin} - \text{TEWL skin with tape}/\text{TEWL skin}) \times 100$$

Accepted for publication Aug 26, 1977.

From the Division of Dermatology, Scripps Clinic and Research Foundation, La Jolla, Calif (Dr Fisher); the Department of Dermatology, University of California, San Francisco Medical Center (Dr Maibach); and Riker Laboratories Inc, 3M Company, St Paul (Dr Trancik).

Reprint requests to Department of Dermatology, University of California, San Francisco Medical Center, San Francisco, CA 94143 (Dr Maibach).

Table 1.—The Effect of Nonmedicated Tapes, Saran, and Hydrocortisone Occluded with Saran on Mitotic Activity

Treatment	n*	Mitotic Index Mean ± SD	% Inhibition	P†
Normal skin control	13	0.48 ± 0.46	...	...
Occlusive tape	17	0.78 ± 0.90	63‡	< .01
Nonocclusive tape	9	0.22 ± 0.14	54	< .01
Partially (50%) occlusive tape	9	0.83 ± 1.19	73	< .05
Plastic film (Saran)	4	0.44 ± 0.35	8	NS
2% Hydrocortisone cream 32 μg/sq cm/Saran	4	0.14 ± 0.10	71	< .01
1% Hydrocortisone cream 16 μg/sq cm/Saran	4	0.12 ± 0.15	75	< .01

*Number of subjects used to determine mitotic index, with twelve separate determinations for each subject.
†P values determined in comparison with normal skin control; NS indicates not significant.
‡Enhanced mitotic activity.

Table 2.—The Effect of Occlusive Corticosteroid Tapes on Mitotic Activity

Treatment	Dose (μg/sq cm)	n*	Mitotic Index Mean ± SD	% Inhibition	P†
Normal skin control	...	13	0.48 ± 0.46	...	...
Corticoid					
Flurandrenolide	4	8	0.03 ± 0.04	94	< .01
Flurandrenolide	20	4	0.15 ± 0.22	69	< .01
Betamethasone valerate	4	4	0.03 ± 0.04	94	< .01
Betamethasone valerate	20	4	0.03 ± 0.03	94	< .01
Betamethasone	4	4	0.06 ± 0.02	88	< .01
Betamethasone	20	4	0.03 ± 0.05	94	< .01
Fluorometholone	4	4	0.02 ± 0.02	96	< .01
Fluorometholone	20	4	0.02 ± 0.02	96	< .01

*Number of subjects used to determine mitotic index, with twelve separate determinations for each subject.
†P values determined in comparison with normal skin control.

Table 3.—The Effect on Mitotic Activity of Hydrocortisone Tapes With Variable Occlusivity

Dose (μg/sq cm)	n*	Mitotic Index Mean ± SD	% Inhibition	P†
Normal skin control	13	0.48 ± 0.46	...	...
Occlusive tapes				
1	5	0.61 ± 0.40	27‡	NS
4	5	0.34 ± 0.47	29	NS
20	5	0.05 ± 0.03	90	< .01
32	4	0.05 ± 0.04	90	< .01
48	4	0.03 ± 0.02	94	< .01
96	8	0.04 ± 0.07	92	< .01
Partially occlusive tapes				
1	5	0.16 ± 0.06	67	< .01
4	5	0.11 ± 0.05	77	< .01
20	5	0.04 ± 0.03	92	< .01
48	4	0.07 ± 0.05	85	< .01
96	4	0.04 ± 0.06	92	< .01
Nonocclusive tapes				
1	5	0.04 ± 0.03	92	< .01
4	5	0.20 ± 0.15	58	< .01
20	5	0.06 ± 0.09	88	< .01
48	4	0.06 ± 0.05	88	< .01
96	4	0.07 ± 0.07	85	< .01

*Number of subjects used to determine mitotic index, with twelve separate determinations for each subject.
†P values determined in comparison with normal skin control; NS indicates not significant.
‡Enhanced mitotic activity.

Thus, the TEWL from any skin site would be entirely transmitted through a tape with 0% occlusivity. An electrolytic moisture analyzer was used for this investigation. Experimental details of skin TEWL measurements have been described.[5,6]

RESULTS

The mitotic counts that were generated in the present study for normal skin were within the range of those previously reported.[1,2,7,8] The application of an occlusive tape without corticoid increased the mitotic count (Table 1). The nonocclusive tape decreased mitotic activity. The MPF tape (50% occlusive) increased the mitotic count to a degree similar to that of the occlusive tape. The occlusive film without adhesive (Saran) did not alter mitoses.

Fluorinated Corticosteroids in Occlusive Tape

The application of various corticosteroid tapes produced decreases in mitotic activity (Tables 2 and 3). These reductions were statistically significant when compared with untreated control. Flurandrenolide tape at the 4 and 20 μg/sq cm levels dramatically decreased mitotic counts (Table 2). The 20 μg/sq cm level had 60% inhibition compared with 94% inhibition with the 4 μg/sq cm dose. These were not statistically different. Betamethasone valerate tape, at values of 4 and 20 μg/sq cm, was significantly lower than the untreated control but not different from other corticosteroid tapes evaluated. A similar response occurred with betamethasone and fluorometholone, which had at 4 and 20 μg/sq cm.

Hydrocortisone in Occlusive Tape

Hydrocortisone tape at the 1 μg/sq cm level was indistinguishable from untreated control (Table 3). At the 4 μg/sq cm level, it appeared somewhat inhibitory, but not statistically different from control. Increasing the dose from 20 to 96 μg/sq cm in occlusive tapes produced a profound mitotic inhibition similar to that seen with the other more active fluorinated corticosteroids, such as flurandrenolide. Hydrocortisone cream with occlusive plastic film resulted in a lower mitotic count than the control (Table 1).

Hydrocortisone in Semiocclusive Tape

All hydrocortisone tapes were mitotic inhibitors compared with the untreated control (Table 3). Their activity was similar to that of the

potent corticoids. There was no apparent dose-response relationship between the 1 and 96 μg/sq cm doses.

Hydrocortisone in Nonocclusive Tape

All concentrations of hydrocortisone in nonocclusive tape systems demonstrated significant reduction in mitotic activity when compared with the control, but were not different from each other (Table 3). There was no discernible dose-response relationship. An anomaly was the 4 μg/sq cm dose, which showed somewhat higher mitotic counts but which was not statistically significant.

COMMENT

The normal mitotic counts reported in the present study are representative of those published using this method.[1,2,7,8] The occlusive tape increased mitotic counts as noted in a previous publication where the finding is discussed in detail.[1] The nonocclusive tape notably and consistently decreased mitotic counts, confirming the previous publication to this effect.[8] The present study does not define whether these effects were due to specific ingredients or to the tape system as a whole. No previous information is available on partially occlusive tape systems. The semiocclusive tape was, on the basis of TEWL studies, approximately 50% occlusive. This semiocclusive tape did not decrease mitotic counts as did the nonocclusive tape, and semiocclusive tape had a range of increased mitotic activity similar to that of the occlusive tape. The semiocclusive tape, affording 50% occlusion to TEWL, is physiologically closer to the occlusive tape than the nonocclusive tape. The plastic film gave results similar to the untreated control, confirming earlier observations.[8]

Hydrocortisone creams occluded with plastic film were almost as active as the fluorinated corticoids. Although the mitotic counts appear somewhat higher than those obtained with the fluorinated corticoids, this is not statistically different. Previously, 1% hydrocortisone cream without occlusion was shown to have no effect on epidermal mitoses, while the fluorinated corticoids significantly decreased mitoses.[2]

Flurandrenolide in tape at all doses was an extremely potent mitotic inhibitor. Although the individual data points are not given, many biopsy specimens showed no countable mitotic figures. These materials have such a potent mitotic inhibitory effect that we did not go to a low enough dose to show a dose-response, ie, the 4 and 20 μg/sq cm doses were essentially similar. (Note that 4 μg/sq cm of flurandrenolide in tape is marketed as Cordran tape.) The same holds true with betamethasone and the fluorometholone at 4 and 20 μg/sq cm. Tapes containing 4 μg/sq cm of corticoid are approximately equivalent to the clinical use of corresponding 0.25% creams or ointments.[9]

Fluorometholone has been observed to be a less active compound than flurandrenolide.[10] We do not know whether this judgment is correct or whether there is a disassociation of activity between the broad anti-inflammatory activities of corticoids and the mitotic effects noted here. Antimitotic activity would presumably be more relevant for hyperproliferative diseases like psoriasis than for other inflammatory dermatoses that may not be related to hyperproliferation.

The dose-response observed with hydrocortisone in the occlusive tape system was revealing. At the lower doses (1 and 4 μg/sq cm), there were no mitotic effects. Increasing the dose to the 20 to 96 μg/sq cm range produced an antimitotic effect similar to that observed in the potent fluorinated corticoids. Possibly, higher doses of hydrocortisone than ordinarily used clinically might be more effective in psoriasis than they are usually assumed to be. Unfortunately, there are no published efficacy dose-response data that clearly delineate this for hydrocortisone.

With hydrocortisone in the semiocclusive tape, all dose ranges showed activity that suggested that one might obtain a significant pharmacological effect from the drug by using a less occlusive tape, which should produce less tape trauma. The hydrocortisone dose-response data generated with the nonocclusive tapes were most revealing. In this instance, there appears to be an additive effect; the antimitotic effect of hydrocortisone appeared to be potentiated when delivered from the nonocclusive tape system, which, in itself, was antimitotic. Whereas there was no inhibition of mitoses at the 1 and 4 μg/sq cm doses in the occlusive tape, at comparable doses with the nonocclusive tape there was definite inhibition. We cannot explain this apparent discrepancy. However, this important finding suggests that disadvantages of total occlusion, such as maceration, folliculitis, and secondary infection, may be obviated by the use of less occlusive tape systems. This affords new possibilities in dermatopharmacology with tape delivery systems, at least when antimitotic effects are desired.

Although occlusion is undoubtedly an important factor in increasing percutaneous penetration of drugs and obtaining more potent pharmacological effects, it does have limitations, eg, irritation. Nonocclusive tapes produce far less irritation. We believe that the present data suggest that less occlusive systems may be adequate for obtaining certain pharmacological effects. In confirmation of previous work showing a potent antimitotic effect of the nonocclusive tape by itself,[8] we add the observation that this may involve an additive effect with hydrocortisone. We believe these principles deserve careful examination in clinical trials.

References

1. Fisher LB, Maibach HI: Physical occlusion controlling epidermal mitosis. *J Invest Dermatol* 59:106-108, 1972.
2. Fisher LB, Maibach HI: The effect of corticosteroids on human epidermal mitotic activity. *Arch Dermatol* 103:39-44, 1971.
3. Reich H, Samuels BK: The reaction of adrenocortical hormones with 2, 4-dinitrophenylhydrazine. *J Org Chem* 21:65-67, 1956.
4. Sarbach DV: Method of making moisture vapor permeable and water resistant rubbery materials. US Patent 2,826,509. Issued March 11, 1958.
5. Baker H, Kligman AM: Measurement of transepidermal water loss by electrical hygrometry. *Arch Dermatol* 96:441-452, 1967.
6. Spruit D: The water-barrier of stripped and normal skin. *Dermatologica* 141:54-59, 1970.
7. Fisher LB, Maibach HI: Topical antipsoriatic agents and epidermal mitosis in man. *Arch Dermatol* 108:374-377, 1973.
8. Fisher LB, Maibach HI: The effect of occlusive and semipermeable dressings on the mitotic activity of normal and wounded human epidermis. *Br J Dermatol* 86:593-600, 1972.
9. Feldman RJ, Maibach HI: Percutaneous penetration of steroids in man. *J Invest Dermatol* 52:89-94, 1969.
10. Maibach HI Stoughton R: Topical corticosteroids, in Azarnoff D (ed): *Steroid Therapy*. Philadelphia, WB Saunders Co, 1975, p 183.

The editors of the ARCHIVES *agree with the authors that the use of PUVA therapy should be evaluated by controlled analytical procedures. The questions presented by the American Academy of Dermatology Task Forces on Photobiology and Psoriasis* (ARCHIVES 113:1195, 1977) *are of utmost importance and should be addressed before we can consider this a safe, therapeutic modality. In addition, the use of this form of treatment requires knowledgeable physicians and technical personnel to ensure appropriate delivery from both a therapeutic and short-term safety point of view.*—EDS.

Photochemotherapy of Psoriasis (PUVA) Without Specialized Equipment

John W. Petrozzi, MD, Albert M. Kligman, MD, PhD

• High intensity long ultraviolet light (UV-A) systems along with oral methoxsalen (8-methoxypsoralen [8-MOP]) have been dramatically successful in clearing long-standing psoriasis. Since this equipment is beyond the reach of many dermatologists, we have examined alternate ways of achieving the benefits of PUVA photochemotherapy. A total of 24 patients with psoriasis have been treated with ordinary fluorescent blacklights in a conventional Zimmerman cabinet. Fourteen patients' conditions (58%) were cleared completely and the conditions of three (12%) were more than 80% improved. We used higher doses of 8-MOP, starting with 50 mg, and increased the dosage further in 15 cases. In five instances, 80-mg levels were given.

With certain modifications, it may be possible to attain satisfactory therapeutic results with ordinary equipment. Higher doses of 8-MOP may be necessary to compensate for the lower irradiance light source in some instances. However, widespread use of PUVA therapy cannot be recommended at this time until the long-term effects of this treatment become known.

(*Arch Dermatol* 114:387-390, 1978)

One of the most impressive therapeutic advances in the history of dermatology has been the development of PUVA photochemotherapy for psoriasis.[1,2] With 40-mg doses of methoxsalen (8-methoxypsoralen [8-MOP]) and two to three weekly exposures of long ultraviolet light (UV-A) complete clearing can be achieved in approximately 90% of the patients. Recent amendments allow doses up to 60 mg of 8-MOP.

No important adverse effects have been reported to date though there is justifiable worry concerning late actinic damage and skin malignancy.

An extensive cooperative study is underway at a score of university centers that is using sophisticated equipment, the most important component being high-intensity UV-A lamps distributed from top to bottom on all four sides with internal reflecting shields in each lamp bulb. The construction guarantees that all portions of the skin except the soles and scalp will receive relatively equal amounts of radiation with the patient standing in the center of the chamber. Moreover, accurate dosimetry is provided by metering the dose of UV-A in joules per square centimeter. These units are expensive and will not be available until Food and Drug Administration approval is obtained.

Meanwhile, other units have appeared and more dermatologists than expected have begun to evaluate their usefulness in the private practice setting. This is a natural response to the pressures exerted by the multitudes of hopeful patients with psoriasis who do not have access to the treatment centers of which there are less than 20 in the whole of the United States. Although many dermatologists throughout the world have more than a superficial knowledge of the difficulties and benefits of PUVA owing to the many presentations at national meetings along with more cursory reports in the professional news media, it cannot be assumed that all of them have the background to effectively and safely use PUVA. Despite the fact that dermatologists have a long aquaintance with the phototherapy of psoriasis in the form of the Goeckerman tar-ultraviolet light regimen, PUVA therapy presents certain problems of its own and its long-term consequences are still unknown.

In this communication, we describe a form of PUVA therapy that enables most patients' conditions to be cleared using simple, low-intensity, readily available materials. It is not, however, intended to be an endorsement for the proliferation of uncontrolled PUVA systems.

SUBJECTS AND METHODS

Twenty-four patients with chronic, stable psoriasis were treated. Twenty-two had generalized plaque-type psoriasis covering 40% to 75% of the body, one had generalized erythroderma, and one had localized pustular psoriasis. All had a complete blood cell count (CBC), blood chemistry studies using an automated 12-factor analysis system, urinalysis, and ophthalmologic examination done before treatment and at three- to four-month intervals thereafter.

We used a Zimmerman cabinet 210 cm high (internal dimensions, 85 × 70 cm) containing 30 standard 4-foot blacklight fluorescent bulbs (GE F40 BL). The spectral radiation of these bulbs is from 300 to 475 nm, with its peak at 365 nm. They were arranged in the following manner to completely surround the patient: two in each corner, six on the back and sides, and four on the door. Since the bulbs were only 4 ft long, we varied the height so that ten were 15 cm, eight were 45 cm, and 12 were 30 cm from the floor. Bulbs were approximately 2.5 cm apart on the sides, 5 cm apart on the back, and 7.5 cm apart in the corners. Patients with heavy involvement on the legs stood on a 25-cm high stool. The walls were lined with aluminum sheeting. The UV-A intensity in the center of the box at a height of 100 cm averaged 2.8 mW/sq cm as measured by a meter (Black

Accepted for publication Aug 26, 1977.

From the Department of Dermatology (Dr Kligman), University of Pennsylvania School of Medicine, and the Dermatology Section (Dr Petrozzi), Veterans Administration Hospital, Philadelphia.

Reprint requests to Veterans Administration Hospital, Dermatology Service, University and Woodland Avenues, Philadelphia, PA 19104 (Dr Petrozzi).

Fig 1.—Patient prior to therapy.

Fig 2.—Same patient as in Fig 1 after 26 treatments, three times weekly.

Fig 3.—Another patient prior to therapy.

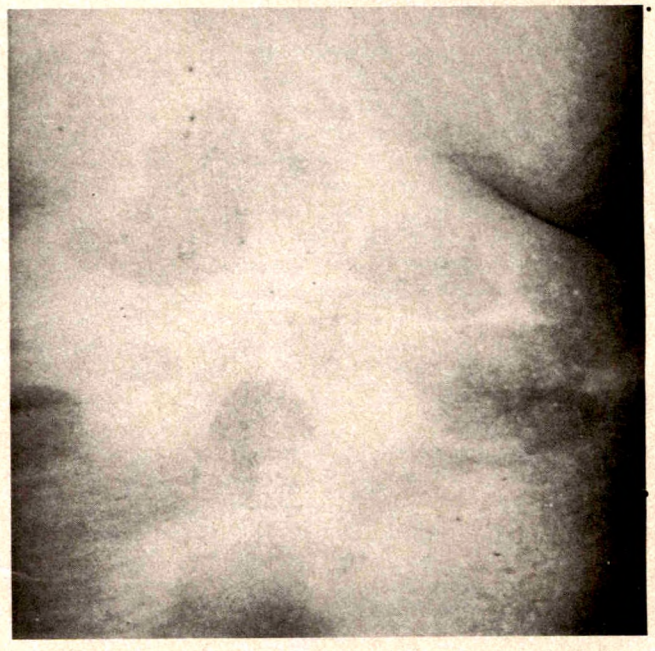

Fig 4.—Same patient as in Fig 2 after 27 treatments, three times weekly.

Ray Ultraviolet Meter, Ultraviolet Products, Inc). The spectral sensitivity of this meter ranges from 300 to 400 nm, with its peak at 365 nm. The intensity decreased to 0.8 mW/sq cm at a height of 150 cm and was 1.0 mW/sq cm 15 cm from the floor. We used a bank of five UV-A bulbs (Sylvania F20 T12 BL) 0.5 cm apart for our patient with localized pustular psoriasis (UV-A intensity of 3.2 mW at 10 cm). In addition, 30% of the energy emitted from this bank is in the sunburn (UV-B) range (Eppley thermopile).

The starting dose of 8-MOP was empirically chosen at 50 mg and was given two hours before irradiation (average patient weight, 80.4 kg). For most patients, when the light dose reached 30 minutes (5.00 joules/sq cm), the 8-MOP dosage was increased to 60 mg and was further raised to 70 and 80 mg when the patients' light dose reached 45 minutes (7.56 joules/sq cm) or when responses were very slow after eight to ten treatments. In general, the light dose was increased by 0.30 to 0.6 joules/sq cm every two to three treatments, using the erythema response of uninvolved skin as a guideline to drug and light dosage. If the skin was noticeably pink, no increase in dosage was given; if very red, no treatment was given. Occasionally, if patients tolerated UV-A well and if response was slow, larger joule increments were given. Twelve patients were treated daily five times a week and 12 three times weekly on Monday, Wednesday, and Friday. A sunscreen that was a mixture of oxybenzone and dioxybenzone (Solbar) was applied to the face prior to exposure. During treatments, the eyes were protected with welder's goggles (Bausch & Lomb Bal-Gard III Shade 5). In addition, on the day of treatment patients used Hazemaster sunglasses (American Optical) while traveling to and from the hospital and while outdoors.

RESULTS

Fourteen of 24 patients had complete resolution of their conditions (Fig 1 through 4) (Table 1) and the conditions of three additional patients were greater than 75% improved. The number of exposures to clearing ranged from 10 to 45. The eight patients treated five times weekly whose conditions cleared required an average of 25.6 exposures and received an average total of 116 joules/sq cm (range, 32.6 to 151.4 joules/sq cm). This was compared with an average of 20.5 treatments for the six patients whose conditions cleared

Table 1.—Patients Treated Five Times Weekly

No. of Treatments	Final Light Dose, Joules/sq cm	Results*	Total No. of Joules/sq cm	8-MOP Dose Start	8-MOP Dose End	Total Exposure Times, min	Comment
30	6.38	+4	129.3	50	60	769.5	...
32	7.56	+4	151.3	50	60	814	...
13	5.04	+4	59.6	50	60	355	...
20	5.04	+3	66.9	50	50	392.5	...
30	5.88	+4	118.4	50	50	631	...
45	8.06	+4	243.8	50	70	1,451	...
10	3.7	+4	32.6	50	50	194	...
67	6.38	+2	316.2	50	70	1,848	Very thick plaque
25	5.04	+4	91.1	50	60	542	...
15	5.04	+1	67.7	50	40	403	Drop out; excess nausea
18	3.7	+3	50.8	50	50	298	...
24	5.3	+4	101	50	50	576	...

* +4 indicates complete clearing of plaques; +3, improvement of all plaques by 75%; +2, improvement of all plaques by 50%; +1, slight improvement of all plaques (less than 50%); and 0, unchanged.

Table 2.—Patients Treated Three Times Weekly

No. of Treatments	Final Light Dose, Joules/sq cm	Results*	Total No. of Joules/sq cm	8-MOP Dose Start	8-MOP Dose End	Total Exposure Times, min	Comment
40	7.73	+2	149	50	70	941	Erythrodermic
40	6.22	+4	62.8	50	50	374	...
52	6.72	+2	271	50	80	1,614	Also failed high-intensity PUVA
34	7.73	+3	163.6	50	60	974	...
26	6.72	+4	137.6	50	70	819	...
27	5.9	+4	119.3	50	80	710	...
30	7.56	+2	177.4	50	80	1,062	Very thick plaque
19	6.72	0	99.5	50	60	520	Acral pustular psoriasis
41	7.73	+2	204.3	50	80	1,188	Very thick plaque
12	4.2	+4	40.3	50	50	240	...
29	10	+4	170.9	50	80	1,017	...
12	5.7	+4	48.9	50	50	290	...

* +4 indicates complete clearing of plaques; +3, improvement of all plaques by 75%; +2, improvement of all plaques by 50%; +1, slight improvement of all plaques (less than 50%); and 0, unchanged.

when treated three times per week and given a total average of 96.6 joules/sq cm (range, 40.3 to 170.9 joules/sq cm) (Table 2). Total exposure times averaged 666.6 minutes for the first group and 575 minutes for the latter. Daily treatments did not, therefore, increase the rate of resolution in the small number of patients studied. Those whose conditions cleared on alternate-day treatment required on the average a lower number of total joules and exposure times.

Three patients with very thick plaques and one with a generalized erythroderma showed less than 50% improvement after an average of 36 treatments. One patient with palmar pustular psoriasis showed no response after 24 treatments and a total of 99.5 joules/sq cm and 520 minutes.

Side effects were minor. Eight complained of pruritus and five experienced nausea. One dropped out because of the severity of the nausea. Results from CBCs, blood chemistry studies using an automated 12-factor analysis system urinalyses, and ophthalmologic examinations remained unchanged from control values during and after treatment.

COMMENT

Our results indicate that the benefits of photochemotherapy can be obtained for most patients using simple low-intensity UV-A equipment and in some instances increased dosage of 8-MOP. Earlier apprehension concerning the hepatotoxic effect of 8-MOP has not been borne out by experience.[3,4]

The starting dose of 8-MOP was 50 mg and was increased according to the rate of response and length of treatment times. Starting light exposures average 2 to 2.5 joules/sq cm (range, 1.6 to 4.2 joules/sq cm). Admittedly, for most patients this represented a conservative undertreatment. Increments of about 0.3 joules/sq cm were made cautiously every two to three treatments. In those who did not seem to be responding satisfactorily after eight treatments, the light dosage was increased every two to three treatments by 0.5 to 0.6 joules/sq cm. Occasionally, larger increments (1 joule) were used in slow responders who tolerated UV-A very well. No patient received more than 10 joules/sq cm per treatment (60 minutes). Of the ten patients who received higher doses (70 and 80 mg), the conditions of four cleared completely and we cannot state with certainty that these would not have cleared with lower doses. Other than psoriatic erythroderma and pustular psoriasis, one could not predict which plaque-type psoriatic condition would respond sluggishly; thick plaques for the most part responded more slowly. A few patients, however, showed remarkably rapid resolution. Psoriasis behaves curiously and we recognize that the number of patients treated in this report was not enormous. One should recall that the initial communication regarding PUVA therapy reported

that the conditions of 21 of 21 patients cleared after 12 to 20 treatments.[1] However, the most recent expanded series now reports that the conditions of only 69% cleared within 30 treatments.[5] Some of our rapid responses must be interpreted within the scope of a study of this size.

Despite the small sample size, it would seem that little is to be gained from daily treatments; the proportion of patients in whom complete clearing was achieved was not significantly greater, and the number of exposures to clearing, total joules, and exposure times were increased. A delayed phototoxic reaction at 48 to 72 hours is a characteristic of 8-MOP. Too frequent exposures with repeated phototoxic effect therefore may be unnecessary and may actually stimulate the disease process, thus counteracting the remedial effects. In addition, the danger of severe burns developing is enhanced. For this reason, we do not advocate daily treatment with PUVA. However, if low UV-A doses are used and are not increased more than every three to four treatments, this risk is diminished.

Our light box is clearly not a very efficient setup in terms of modern technology. We used 4-ft bulbs in a box that was 7 ft (210 cm) high. Even though the lights were staggered, the legs necessarily received lower exposures. Having patients stand on a stool was helpful but not satisfactory. While leg lesions tend to clear more slowly with all forms of treatment, there is little doubt that inadequate exposure to the legs lowered the number of patients whose conditions achieved complete clearing. Indeed, the conditions of three cleared completely on the trunk while the legs showed only partial improvement. A more advantageous arrangement could easily be obtained by placing the 4-ft bulbs at ground level and adding standard 2-ft bulbs above. The number of bulbs could also be expanded to completely fill all wall space of the cabinet. A great deal of heat will be generated by such a light system so that adequate ventilation is essential.

It should be noted that the standard UV-A bulbs used in this study emit small amounts of UV-B as well as visible light. Unlike the high-intensity PUVA program, we made no attempt to eliminate these components. It may well be that the retention of these wavelengths was instrumental in producing our beneficial results using lower total amounts of energy. Although we did not have the equipment to measure the UV-B component of the UV-A bulbs in our cabinet, 30% of the energy emitted from our UV-A bank was in the UV-B range. Photoaugmentation[6] using both UV-B and UV-A should be explored as a mechanism by which the benefit of PUVA might be achieved using a lower total number of joules per square centimeter.

Perhaps the most surprising finding in this study was the lack of side reactions. Only five patients experienced nausea and one refused to go on. The incidence of nausea was not greater in patients receiving 70 to 80 mg of 8-MOP. Our low incidence of nausea may be due to our habit of never mentioning it prior to or during treatment. It was recorded only when patients initiated the complaint. If the initial 50-mg doses did not induce this symptom, higher doses did not do so either, at least not to a distressing degree. Six patients had pruritus that was partially controlled by hydroxyzine hydrochloride (Atarax). In no instance did blistering or a severe phototoxic reaction develop.

Thirteen of the 14 whose conditions cleared completely were followed up to 12 months. Four of the five who received no maintenance relapsed after 2½ to 3 months, whereas the fifth stayed clear for ten months. Eight patients were placed on weekly treatments for maintenance using the last 8-MOP dose and exposure times. Three of eight showed minor recurrences one month later. Increasing the treatments to twice or three times weekly brought about complete resolution, and weekly maintenance was resumed. Three patients remain clear while continuing maintenance treatments. Those in whom maintenance was discontinued relapsed after three to six months.

The 58% rate of complete clearing in our study is significantly lower than the 90% rate achieved with the higher energy UV-A bulbs. However, our results were obtained with 30 bulbs of low intensity compared with the 64-bulb arrangement in the cooperative study. In addition, none of the patients in our cases received exposures of more than 10 joules/sq cm.

The failures in our series had pustular psoriasis,[1] psoriatic erythroderma,[1] or extraordinarily thick plaques.[3] These forms tend to be refractory to all types of treatment, including the high-intensity systems. Two of our failures with thick plaque-type psoriasis did have their conditions clear completely when treated with the high-intensity (Sylvania) system, emphasizing the importance of light dosage. This might not have occurred if our box had been furnished with a maximum number of bulbs from floor to ceiling and if exposures greater than 10 joules/sq cm were used.

In this study, we have attempted to monitor drug and light dosage using as a guide the phototoxic response of uninvolved skin or the worsening or improvement of lesions. The Harvard group has aptly emphasized history of tolerance to sunlight to estimate the initial light dosage.[1] Those who sunburn easily and tan poorly are to be started a good deal more cautiously than those who rarely burn and who tan quickly and intensely. A Celtic (Irish or Scottish) background is another useful criterion of unusual susceptibility to the harmful effects of sunlight.

Clearly, PUVA is not for every patient with psoriasis. The potential long-term side effects are still unknown and chromosome abnormalities have been induced in vitro with 8-MOP and UV-A.[7] However, one cannot help wondering from our successful experience with unsophisticated low-intensity UV-A equipment whether it may be possible to clear the condition of many psoriasis patients with lower UV-A dosages than are currently used. The principles of careful monitoring must always be maintained even with low-intensity light systems to avoid the intense burns that can result from the unskilled, overzealous administration of PUVA. Higher 8-MOP doses as used in this study also make it imperative that patients avoid sun exposure for eight hours after ingestion to avoid painful and severe burns.

References

1. Parrish JA, Fitzpatrick TB, Tanenbaum L, et al: Photochemotherapy of psoriasis with oral methoxsalen and longwave ultraviolet light. *N Engl J Med* 291:1207-1211, 1974.
2. Wolff K, Fitzpatrick TB, Parrish JA, et al: Photochemotherapy for psoriasis with orally administered methoxsalen. *Arch Dermatol* 112:943-950, 1976.
3. Fitzpatrick TB, Imbrie JE, Labby DH: Studies of liver function in subjects receiving 8-methoxypsoralen. *JAMA* 167:1580-1589, 1958.
4. Tucker HH: Clinical and laboratory tolerance studies in volunteers given oral methoxsalen. *J Invest Dermatol* 32:277-280, 1959.
5. Melski JW, Tanenbaum L, Parrish J, et al: Oral methoxsalen photochemotherapy for the treatment of psoriasis: A cooperative clinical trial. *J Invest Dermatol* 68:328-335, 1977.
6. Kaidbey K, Kligman AM: Further studies of photoaugmentation in humans: Phototoxic reactions. *J Invest Dermatol* 65:472-475, 1975.
7. Carter DM, Wolff K, Schnedl W: 8-methoxypsoralen and UVA promote sister-chromatid exchanges. *J Invest Dermatol* 67:548-551, 1976.

Atopic Dermatitis, Impaired Cellular Immunity, and Molluscum Contagiosum

Charles R. Pauly, MD; William M. Artis, PhD; Henry E. Jones, MD

• A substantial elevation in the level of serum IgE (7,000 to 19,000 ng/ml) was noted in a man with atopic dermatitis and chronic molluscum contagiosum. Cell-mediated immunity (CMI) was depressed in vivo (cutaneous anergy), whereas in vitro tests showed normal numbers of "T" rosette-forming lymphocytes, a normal phytohemagglutinin-P-elicited lymphocyte transformation response, and lymphocyte transformation reactivity to the antigens streptokinase-streptodornase and purified protein derivative.

Accumulated evidence suggests that patients with atopic dermatitis may have, associated with an elevated serum IgE level, a functional defect(s) in CMI that is greater in vivo than in vitro. This functional defect may impair host defense and account for the chronic molluscum contagiosum infection present in this patient.

(*Arch Dermatol* 114:391-393, 1978)

Solomon and Telner reported a case of eruptive molluscum contagiosum in a young child with infantile eczema.[1] It has been reported that persons who have atopic dermatitis are predisposed to cutaneous viral infection in the forms of eczema vaccinatum, eczema herpeticum,[2] and chronic dermatophyte[3,4] infection. The reason for this predisposition is not known. It has been suggested that dermatitic skin provides an open portal that facilitates viral colonization. Alternatively, Solomon and Telner have suggested that an abnormality in cutaneous noradrenaline metabolism may predispose to infection.[1]

Accepted for publication July 18, 1977.

From the Department of Dermatology, University of Michigan, Ann Arbor. Drs Artis and Jones are now with Emory University, Atlanta. Dr Pauly is in private practice in Waynesboro, Va.

Reprint requests to Department of Dermatology, Emory University, 215 Woodruff Memorial Bldg, Atlanta, GA 30322 (Dr Artis).

We describe a second patient with atopic dermatitis who is unusually susceptible to molluscum contagiosum and who has an impaired capacity to express cell-mediated immunity (CMI) in his skin. The relationship of the atopic state and the apparent functional impairment of CMI in this patient is discussed.

REPORT OF A CASE

Physical examination showed a young man with an extensive, erythematous, lichenified, and flexurally accentuated dermatitis typical of atopic dermatitis. A diffuse, papular eruption on the arms, neck, and face (Fig 1) was alleged to have been present for longer than five years. These papules were flesh colored, numbered approximately 150, measured 3 to 5mm and, for the most part, were deeply embedded in the cutis. The papular areas showed no evidence of inflammation, and a biopsy specimen showed the lesions to be molluscum contagiosum (Fig 2).

Several lesions were removed by curettage, but this was not tolerated well enough to permit treatment of all lesions. The repeated application of cantharidin slowly reduced the number of lesions.

LABORATORY FINDINGS

Results of the following tests were within normal limits or negative: differential blood count, urinalysis, chemistry panel, and VDRL.

Histopathologic Findings

A biopsy was done on one lesion; the specimen showed a central downward proliferation of epidermis. Many epithelial cells showed glassy, eosinophillic cytoplasma, which is a characteristic of molluscum bodies (Figure 2).

Immunoglobulins

Results of serum protein electrophoresis and quantitative radial immunodiffusion for IgG, IgA, IgM, and IgD were within normal limits. The serum IgE level, which was measured in a radioimmunosorbent test, was 7,000 ng/ml in March 1975 and 19,000 ng/ml in December. Normal IgE values for this laboratory are between 62 and 1,000 ng/ml.

Cell-Mediated Immunity

In vivo assessment included a battery of skin tests for delayed hypersensitivity and allergic contact dermatitis. Intradermal tests with 0.1 ml of mumps skin test antigen (20 complement-forming units per milliliter), purified protein derivative (PPD) of tuberculin (intermediate strength), candidin diluted 1:10), trichophytin CM-107 (10 μg), and streptokinase-streptodornase (SKSD) (400 units SK, 100 units SD per milliliter), plus a patch test using *Rhus* oleoresin (3 to 4 drops), were completed. The results of these tests are presented in Table 1. The finding of delayed cutaneous hypersensitivity anergy to these antigens necessitated an attempt at sensitization using dinitrochlorobenzene (DNCB) (Table 2). The sensitizing dose of DNCB (2,000 μg in 200 μl of acetone) applied topically failed to produce a primary irritant reaction or spontaneous allergic flare. Elicitation with 50 μg of DNCB in 200 μl of acetone 20 days

Fig 1.—Papular eruption of molluscum contagiosum.

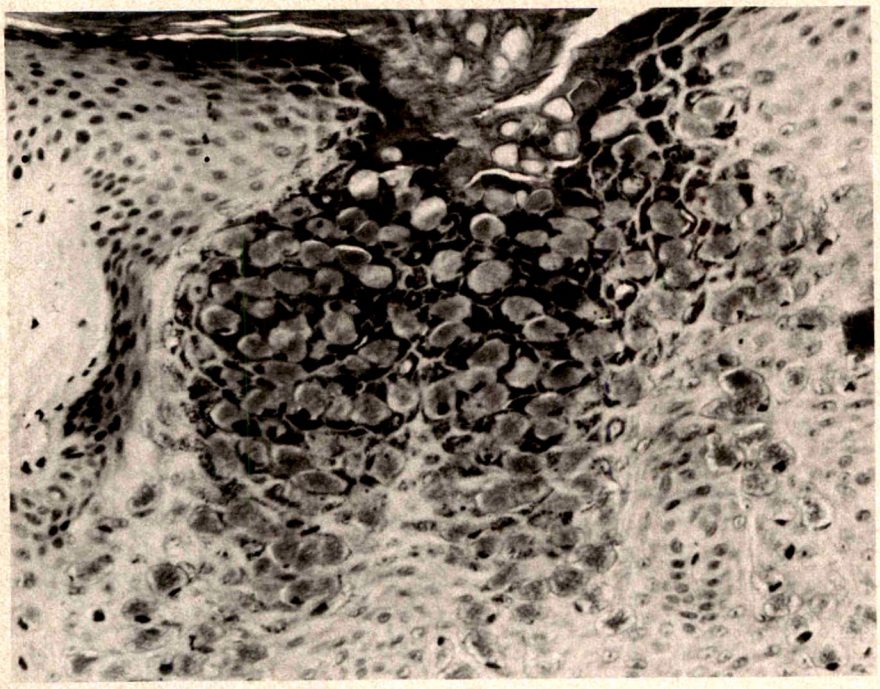

Fig 2.—Histopathologic specimen confirming diagnosis of molluscum contagiosum (hematoxylin-eosin, original magnification ×250).

Table 1.—Patch and Intradermal Testing

Test Material, Concentration and Amount	Results* Immediate, 30 min	Delayed 48 hr	Delayed 7 days
Rhus oleoresin; 3-4 drops	...	Negative	Negative
Candidin; stock diluted 1:10; 0.1 ml	20-mm wheal; 48-mm flare	Negative	Negative
Mumps skin test antigen; 20 complement-fixing units/ml; 0.1 ml	Negative	Negative	Negative
Trichophytin CM-107; 100 μg/ml; 0.1 ml	Negative	Negative	Negative
Purified protein derivative of tuberculin; intermediate strength; 0.1 ml	Negative	Negative	Negative
Streptokinase-streptodornase; 400 units SK, 100 units SD/ml; 0.1 ml	Negative	Negative	Negative

*Negative denotes there was no measureable reaction.

Table 2.—Response to Dinitrochlorobenzene*

Sensitization Day 0 2,000 μg	Elicitation Day 20 50 μg	Elicitation Day 40 50 μg	Reading Day 61
No reaction	No reaction	No reaction	Slight erythema

*Dinitrochlorobenzene at the indicated amount was dissolved in acetone and applied in 200 μl to a 2 cm diameter area of the medial aspect of the forearm. Reactions were read at 24, 48, and 72 hours after application and thereafter, once a week.

later failed to reveal any sensitization. Subsequently, a second elicitation application of 50 μg resulted in a weak erythematous reaction after three weeks. This was interpreted as an allergic contact sensitization to DNCB, although the response was slow and less intense than is normally seen.

In vitro assessment of immunologic competence included enumeration of T cells by the sheep red blood cell (SRBC) rosette method. This test was adapted from the technique of Lay et al.[5] The total number of lymphocytes with three or more adherent SRBCs were counted. Fifty-nine percent of the patient's lymphocytes formed SRBC rosettes, which is within the normal range for this laboratory study (62.1 ± 6.6). Additionally, the percent of lymphocytes stained by polyvalent and monovalent antisera in an immunofluorescent B-cell enumeration technique was reported as normal.

In vitro lymphocyte function was measured in our laboratory by induction of transformation with the mitogen, phytohemagglutinin (PHA)-P, and the antigens, PPD, trichophytin CM-107, candidin, and SKSD.

Heparinized peripheral blood was obtained by vena puncture. The blood was allowed to sediment at 37 C for two hours and the plasma layer was removed. Cells were concentrated by centrifugation, washed three times with Hanks balanced salt solution, resuspended in RPMI-1640 tissue culture medium, supplemented with 10% heat-inactivated AB-positive serum, 4 mM 1-glutamine, and antibiotics, and adjusted to a final concentration of 5×10^5 lymphocytes per milliliter. Two hundred microliters of this preparation were delivered to each well of a 96 well microculture plate. Mitogen and antigen were added in a volume of 10 μl and the plates were incubated at 37 C in an atmosphere adjusted to contain 3.5% CO_2 at a relative humidity approaching 100%. After 68 hours for mitogen and 138 hours for antigens, cultures were pulsed with 0.5 μCi of ^{3}H-thymidine (specific activity, 25 Ci/mM) and terminated four hours later. The DNA from each culture was precipitated on glass filter paper using a multiple assay sample harvester.[6] The precipitated DNA was subjected to liquid scintillation counting. Each experiment had a minimum of four replicate cultures. The data are reported as the ratio of transformation derived from unstimulated control cultures.

A PHA-P dose-response study that consisted of 11 twofold serial dilutions of PHA-P starting from a 1:10 dilution of the preparation was performed. The patients' dose-response curve overlapped the normal control curve for this laboratory. The maximum PHA-P response in the three-day cultures occurred at a dilution of 1:40, which for this laboratory is optimal for normal control subjects. Representative data from a mitogen and antigen study are presented in Table 3.

COMMENT

The mechanism of susceptibility of persons with atopic dermatitis to

Table 3.—Lymphocyte Transformation Studies*

Stimulant,† Concentration	Transformation Ratio After Culture for 3 Days	Transformation Ratio After Culture for 6 Days
Control, RPMI 1640	1; 246 ± 39 CPM	1.0; 429 ± 68 CPM
PHA-P, dilution of stock: 3 days, 1:40; 6 days, 1:10	226‡	37.0‡
Candidin, dilution of stock 1:10	ND	0.9‡
PPD, 10 μg	ND	4.6‡
Trichophytin CM-107, 10 μg	ND	1.0‡
SKSD, 4 unit SK, 1 unit SD	ND	9.1‡

*PHA-P indicates phytohemagglutinin-P; PPD, purified protein derivative; SKSD, streptokinase-streptodornase; CPM, counts per minute; and ND, not done.

†All stimulants are added in 10 μl of the indicated dilution or contain the indicated amount.

‡Ratio can be converted to counts per minute (CPM) by multiplying by control CPM. Counting efficiency is 60%.

cutaneous herpes and vaccinia infections, and in Solomon and Telner's[1] patient, as well as in our patient, to the pox-virus that causes molluscum contagiosum is unknown. The notion that breaks in dermatitic skin provide a portal has been suggested, but it has not been supported.[7-9] Similarly, it is unknown whether the increased production of IgE, which is characteristic of most persons who have atopic dermatitis,[10] is responsible for the defective host defense mechanism(s) or is a result of the defect.

Since CMI correlates directly with host defense in many infectious diseases, impaired CMI could explain the increased susceptibility to viral infection that is associated with atopic dermatitis. Allergic contact dermatitis to DNCB[11] and to *Rhus*,[12] delayed hypersensitivity to bacterial and fungal antigens,[12-14] and lymphocyte transformation to mitogens, bacterial, fungal, and viral antigens[13-15] have all been reported to be depressed to a variable extent in persons with atopic dermatitis. Additional reports of moderately decreased peripheral blood T-cell numbers have appeared.[14,16-18] Despite these reports, the increased susceptibility to cutaneous infection remains unexplained.

Cell-mediated immunity in our patient was grossly intact when it was examined in vitro. This was supported by a normal lymphocyte-transformation response to PHA-P and the finding of normal numbers of peripheral blood T cells. The low transformation ratios to SKSD and PPD, however, may indicate some impaired in vitro antigen reactivity since the ratio in normal individuals who respond to SKSD in our laboratory is usually at least four times greater.

The in vivo findings indicate a general cutaneous CMI anergy since the intradermal tests to SKSD and PPD, which reacted in vitro, and candidin and trichophytin were all negative at 48 hours and seven days. Allergic contact sensitization to DNCB was obtained with great difficulty and was of a reduced intensity. The immunologic findings in this patient are similar to those reported by others[14,18,19] for patients who have moderate to severe atopic dermatitis. The considerable cutaneous CMI anergy, in contrast to the lack of a clear-cut in vitro CMI immunologic deficit in this patient is, in our opinion, a characteristic finding in atopic dermatitis. At times,[19] in very severe cases, the in vitro correlates of immunologic function (PHA-elicited lymphocyte transformation, polymorphonuclear leukocytes, and monocyte chemotaxis), however, can be substantially but variably depressed.

We postulate that, in our patient, cutaneous CMI anergy and possibly the susceptibility to infection are due to a functional abnormality. This postulate is supported by evidence that suggests that pharmacologic mediators, principally histamine, may be antagonistic to T-cell function[3,20-22] and granulocyte chemotaxis.[23] The effect could be caused by the binding of histamine to specific receptors on these cells. Although it is not proven, the interaction of histamine with lymphocytes and other effector cells may, in part, explain the association between elevated levels of IgE, depressed CMI, and defective host resistance that is present in the skin of atopic individuals.

The enumeration of T cells by the SRBC rosette method and the B-cell enumeration technique were performed by the Clinical Immunology Service Laboratory, Department of Pathology, University of Michigan Hospitals.

Antigens were provided by the following: mumps skin test antigen, Lederle; PPD for skin testing, Connaught Chemical Research; PPD for lymphocyte studies, English Department of Fisheries; trichophytin CM-107, Letterman Army Institute for Research; candidin, Hollister-Stier; SKSD, Lederle.

References

1. Solomon LM, Telner R: Eruptive molluscum contagiosum in atopic dermatitis. *Can Med Assoc J* 95:978-979, 1966.

2. Rajka G: *Atopic Dermatitis.* Major Problems in Dermatology. Philadelphia, WB Saunders Co, 1975, vol 3, pp 19-21.

3. Jones HE, Reinhardt JH, Rinaldi MG: Immunologic susceptibility to chronic dermatophytosis. *Arch Dermatol* 110:213-220, 1974.

4. Hanifin JM, Ray LF, Lobitz WC: Immunological reactivity in dermatophytosis. *Br J Dermatol* 90:1-8, 1974.

5. Lay WH, Mendes NF, Bianco C, et al: Binding of sheep red blood cells to a large population of human lymphocytes. *Nature.* 230:531-532, 1971.

6. Hartzman RJ, Bach ML, Bach FH: Precipitation of radioactive labeled samples. *Cell Immunol* 4:182-186, 1974.

7. Mailman CJ, Miranda JL, Spock A: Recurrent eczema herpeticum: Widespread cutaneous herpes simplex in atopic patient without active atopic dermatitis. *Arch Dermatol* 89:815-818, 1964.

8. Copeman PWM, Wallace HJ: Eczema vaccinatum. *Br Med J* 2:906-908, 1964.

9. Burnett JW, Crutcher WA: Viral and rickettsial infections, *in* Moschella SL, Pillsbury DM, Hurley HT (eds): Dermatology. Philadelphia, WB Saunders Co, 1975, p 586.

10. Jones HE, Inouye JC, McGerity JL, et al: Atopic disease and serum immunoglobulin E. *Br J Dermatol* 92:17-25, 1975.

11. Palacios J, Fuller EW, Blaylock WK: Immunological capabilities of patients with atopic dermatitis. *J Invest Dermatol* 47:448-490, 1966.

12. Jones HE, Lewis CW, McMarlin SL: Allergic contact sensitivity in atopic dermatitis. *Arch Dermatol* 107:217-222, 1973.

13. Lobitz WC Jr, Honeyman JF, Winkler NW: Suppressed cell-mediated immunity in two adults with atopic dermatitis. *Br J Dermatol* 86:317-328, 1972.

14. McGeady SJ, Buckley RH: Depression of cell-mediated immunity in atopic eczema. *J Allergy Clin Immunol* 56:393-406, 1975.

15. Hovmark S: An in vivo and in vitro study of cell-mediated immunity in atopic dermatitis. *Acta Derm Venerol* 55:181-186.

16. Gottlieb RR, Hanifin JM: Circulating T cell deficiency in atopic dermatitis. *Clin Res* 22:159A, 1974.

17. Luckasen JR, Sabad A, Goltz RW, et al: T and B Lymphocytes in atopic eczema. *Arch Dermatol* 110:375-378, 1974.

18. Blaylock K: Atopic dermatitis: Diagnosis and pathobiology. *J Allergy Clin Immunol* 57:62-79, 1976.

19. Rogge JL, Hanifin JM: Immunodeficiencies in severe atopic dermatitis. *Arch Dermatol* 112:1391-1396, 1976.

20. Bourne HR, Lichtenstein LM, Melmon KL, et al: Modulation of inflammation & immunity by cyclic AMP. *Science* 184:19-28, 1974.

21. Artis WM, Jones HE: Histamine inhibition of human lymphocyte transformation. *Fed Proc* 34:1002, 1975.

22. Rocklin RE: Modulation of cellular-immune response in vivo and in vitro by histamine receptor-bearing lymphocytes. *J Clin Invest* 57:1051-1058, 1976.

23. Hill HR, Quie PR, Raised serum-IgE levels and defective neutrophil chemotaxis in three children with eczema and recurrent bacterial infections. *Lancet* 1:183-186, 1974.

Lymphangioma Circumscriptum

A Case With Deep Lymphatic Involvement

Louis C. Palmer, MD; William G. Strauch, MD; William A. Welton, MD

• Lymphangioma circumscriptum is a rare disorder that is localized to the skin. To our knowledge, involvement of deeper lymphatic structures has been reported on only two prior occasions. Our patient had typical lymphangioma circumscriptum of her inner thigh, which was associated with deep lymphatic involvement and enlargement of the extremity. We report this case to alert others to this disease entity.

(*Arch Dermatol* 114:394-396, 1978)

Lymphangioma circumscriptum is a rare disorder usually localized to the skin. It was first described in 1879 by Tidbury Fox and Colcott Fox under the name lymphangiectodes.[1] Malcolm Morris coined the term lymphangioma circumscriptum in 1889.[2] Later case reports were published by Noyes and Torok, as well as by others.[3] There have been only two reported instances of deep lymphatic involvement associated with this entity. The first was in an 18-year-old boy who had undergone surgery at age 18 months for a lipoma of the right hip. At age 16 years a cavernous multilocular hemangioma was removed from his upper thigh. Lymphangiograms showed a large lake in the inguinal region. However, it was not clear whether this abnormality was due to the lymphangioma or to the previous surgery.[4] In the second report, Peachey et al[5] refer to a girl who had extensive lymphangioma circumscriptum over the breast, axilla, and anterior part of the chest wall with deep involvement and associated swelling of the arm.[5]

Accepted for publication March 8, 1977.

From the Division of Dermatology, West Virginia University School of Medicine, Morgantown.

Reprints not available.

REPORT OF A CASE

A 13-year-old girl had a lesion on the inner part of the right thigh that had been present for several years. The lesion was asymptomatic but did occasionally leak clear fluid. Clinically, the lesion was a well-circumscribed area composed of a mixture of clear and dark vesicles. Clear fluid exuded from broken vesicles. The patient also commented that her right thigh was larger than her left. On examination, the right thigh measured 50 cm in circumference and the left measured 47.5 cm (Fig 1 and 2). The patient's family history was negative for any similar disorder. She had a normal intravenous pyelogram. A lymphangiogram demonstrated abnormal dilation of the lymphatic channel extending from the femoral region up to the right para-aortic region. Also apparent was an abnormal lymph channel around the right proximal femur that could indicate a backflow phenomena, suggesting evidence of partial obstruction (Fig 3 and 4). Histologic examination disclosed dilated lymph channels compatible with lymphangioma (Fig 5 and 6).

COMMENT

Lymphangiomas are hamartomatous malformations composed of dilated lymph channels lined by normal lymphatic epithelium. They were originally grouped into simple, cavernous, and cystic forms by Wegner in 1877.[6] This classification is still commonly accepted.

Characteristically, lymphangioma circumscriptum consists of small, thin-walled vesicles varying in size, occurring in clusters, and said to resemble "frog spawn." The lesions may be scattered or grouped. The vesicles are translucent and contain fluid that may vary in color from clear to yellow to hemorrhagic. Tiny, blood-filled capillary tufts appear on the vesicle walls. At times, a warty hyperkeratosis may be superimposed over

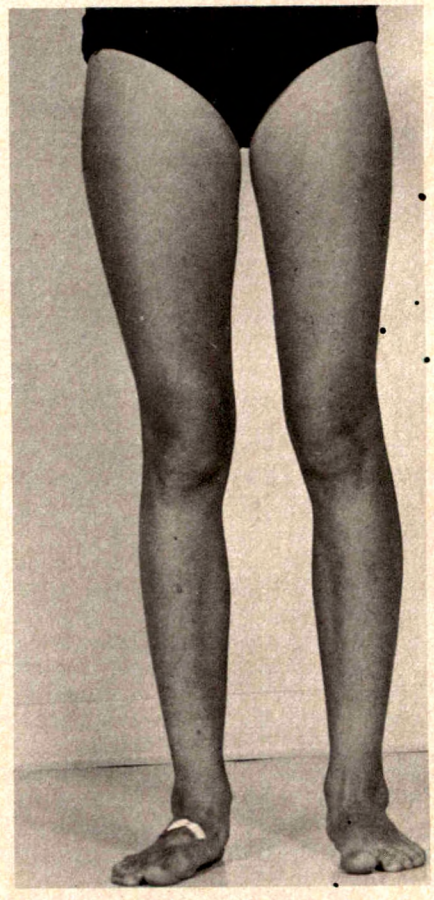

Fig 1.—There is 2.5-cm difference between right and left thighs.

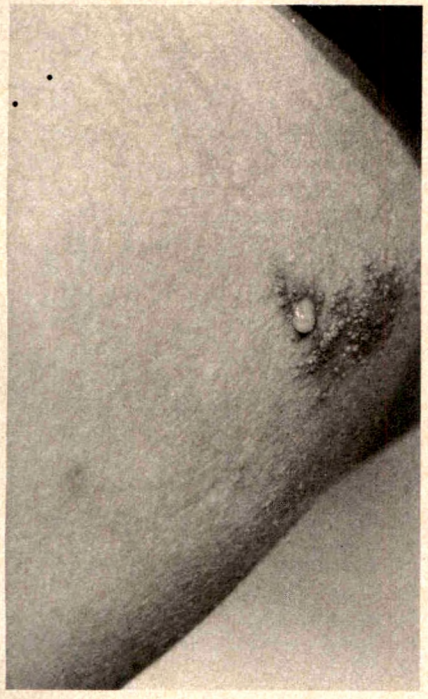

Fig 2.—Close-up of lymphangioma circumscriptum.

Fig 3.—Pooling and ectasia of lymph fluid in pelvic area.

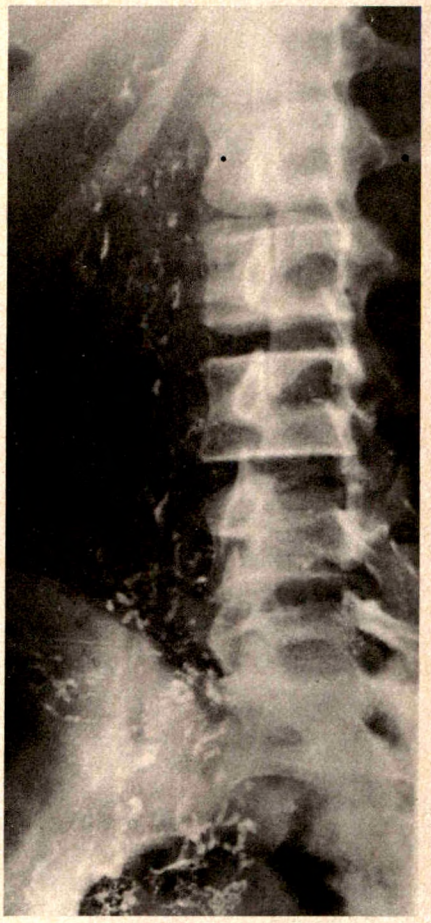

Fig 4.—Dilated lymph channels to periaortic area.

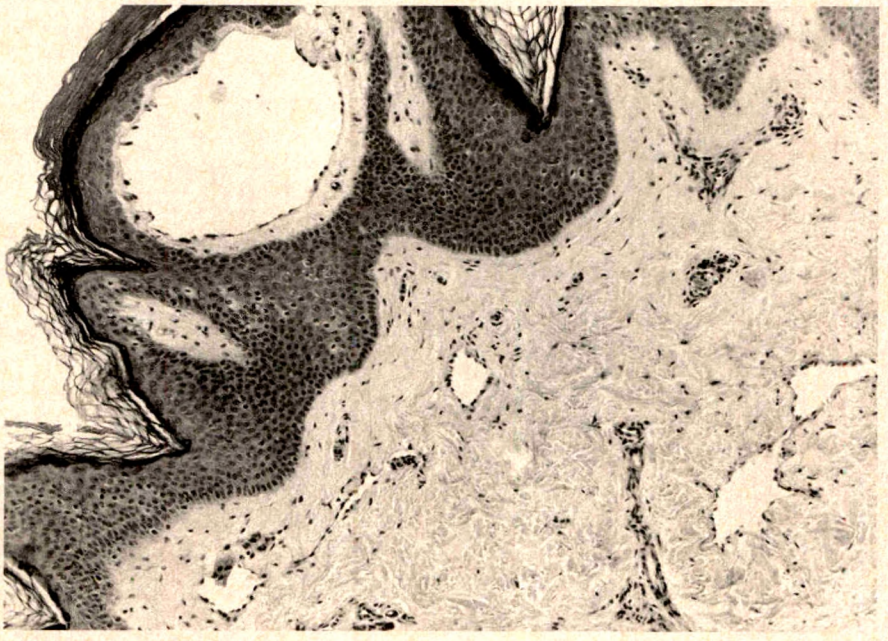

Fig 5.—Dilated endothelial-lined lymph channels (hematoxylin-eosin, original magnification ×100).

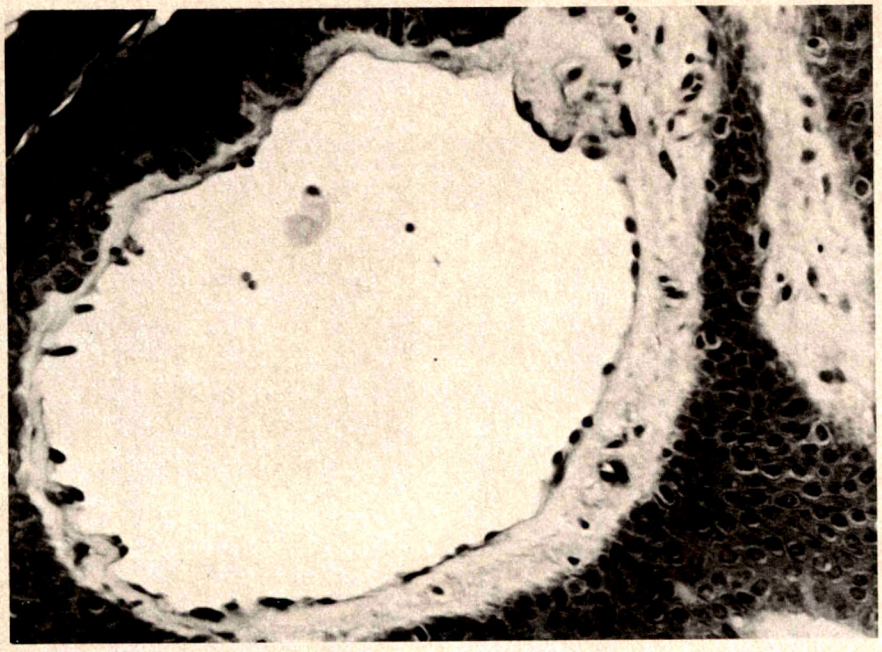

Fig 6.—Close-up of Fig 5 (hematoxylin-eosin, original magnification ×450).

the vesicles. Lymphangioma circumscriptum is usually localized to one region, and the involved areas within that region may range in size from one to several square centimeters. These lesions may remain unchanged for long periods of time and may gradually disappear through absorption of their contents, with new lesions appearing to take their place. The lesions are located superficially, but may sometimes be associated with diffuse swelling in the adjacent subcutaneous tissue or with the enlargement of an entire limb.[5]

Lymphangioma circumscriptum can appear on almost any area of the body, but frequently involves the pectoral and pelvic girdle areas, including the proximal part of the limbs. The tongue, buccal mucosa, and perineum are less often involved. In the great majority of patients, the lesions are either present at birth or appear shortly afterward. It is rare for classical lesions to appear after age 30 years. The disease is reportedly more common in women than in men, but this female preponderance cannot be accurately ascertained because more women than men may seek treatment for cosmetic reasons.[5]

The histology of this entity shows dilated cystic lymph vessels lined with a single layer of endothelium. The principal pathologic changes occur chiefly in the papillary and subpapillary layers of the dermis, causing the epidermis immediately above to bulge upward. The cystic lymph space contains coagulated lymph and, in some cases, red blood cells.

Lymphangiomas may originate from sequestration of primitive lymphatic anlage, congenital absence or blockage, or incompetence of lymphatic vessels or valves. However, it seems likely that a combination of these processes may occur.[7]

Treatment of lymphangioma has included carbon dioxide ice, liquid nitrogen, excisional surgery, electrocautery, x-ray, thorium X, and radium. All these measurements have little or no benefit unless the involved area is very small. Recurrences are common with any treatment modality. These tumors are known to be especially resistant to radiation therapy.

Cavernous lymphangiomas have been treated with various surgical procedures and methods of compression. The Charles procedure, which involves complete resection of the skin with debridement of the subcutaneous tissue and replacement with full-thickness skin grafts, usually has less favorable cosmetic results. Omental transposition also seems to be an unsuitable procedure.[8] Subcutaneous lymphangiectomy has also been performed in these cases. In general, surgery, although not frequently used, is sometimes necessary for functional and cosmetic reasons. Compression dressings are often beneficial to lymphedema of an extremity. Mechanical compression devices are available, but require application for several hours daily. Elevation of the extremity may also be of some benefit.

Complications of this disease include leakage of fluid and recurrent lymphangitis in addition to the cosmetic deformity. No cases of malignant degeneration have been reported to date.[7] The purpose of this report is to emphasize that, although lymphangioma circumscriptum usually occurs as an isolated entity, it may be associated with deep lymphatic disorders. And, if the disease is truly associated with deep lymphatic involvement, the complications may include the impairment of vital organs. This possibility has become evident to us in the case of our 13-year-old patient, who has developed dilated lymph channels to the level of her diaphragm. This development indicates the possibility of eventual ureteral obstruction and the accompanying secondary hydronephrosis.

References

1. Fox T, Fox CT: On a case of lymphangiectodes. *Trans Pathol Soc Lond* 30:470-476, 1879.
2. Morris M: Lymphangioma circumscriptum, in Unna PG, Morris M, Lelois H, et al (eds): *Internationala Attos von seltener Hautkrankheiten*. Leipzig, L Voss, 1889, pp 1-4.
3. Noyes FA, Torok L: Lymphangioma circumscriptum. *Br J Dermatol* 2:359-368, 1890.
4. Russell B, Pridie RB: Lymphangioma circumscriptum with involvement of deep lymphatics. *Br J Dermatol* 79:300, 1967.
5. Peachey RDG, Lim CC, Whimster IW: Lymphangioma of skin. *Br J Dermatol* 83:519-527, 1970.
6. Wegner: Über Lymphangioma. *Arch Klin Chir* 20:641-707, 1877.
7. Deemis DJ, Crouse, Dobson RL, et al: *Clinical Dermatology*. New York, Harper & Row Publishers Inc, 1975, vol 7, p 3.
8. Fonkalsrud EW: Surgical management of congenital malformations of the lymphatic system. *Am J Surg* 128:152-159, 1974.

Mycosis Fungoides Involving the Brain and Optic Nerves

David M. Pariser, MD

• In a patient with long-standing plaque-stage mycosis fungoides, eye pain, a visual field defect, decreased acuity, and a swollen optic disc developed. A lymphomatous infiltrate consistent with mycosis fungoides was found in the brain at craniotomy and in the optic nerves at autopsy. Ten months elapsed between the presenting symptoms and death and during this period the patient's symptoms were controlled with prednisone therapy.

The optic nerves as well as the brain can be involved with mycosis fungoides.
(*Arch Dermatol* 114:397-399, 1978)

Although not commonly recognized by dermatologists, mycosis fungoides can involve the brain. There are several series of autopsies published with brain involvement tabulated.[1-5] Individual cases of CNS invasion by mycosis fungoides are reported[4-15] and there are two cases of intraocular involvement with tumor masses within the globe of the eye.[16,17] Several cases of corneal[18-22] and one case of retinal[23] invasion by mycosis fungoides have also been reported. The patient in a recently reported case of mycosis fungoides had neurologic symptoms and at postmortem examination atypical cells were found in the CSF, both retinae, and in the optic nerve heads. Similar cells were found free-floating in the vitreous humor.

The patient with mycosis fungoides in the current report experienced eye pain, a visual field defect, and a decrease in visual acuity. He was later found to have mycosis fungoides in the brain and optic nerves.

REPORT OF A CASE

A 49-year-old man was seen in January 1971, with widespread infiltrated plaques and some ulcerations typical grossly and microscopically of plaque-type mycosis fungoides. The lesions had slowly progressed for the preceding ten years and had partially responded to therapy with topical nitrogen mustard treatment except for four small ulcerations that were treated with electron beam. No more than 1,500 rads were delivered to any one area. No total body electron beam was administered. After 34 consecutive months of successful treatment with mechlorethamine hydrochloride, the patient reported the development of urticaria in the treated sites immediately after application of the drug. True contact urticaria was documented by open and closed patch testing and by application of mechlorethamine hydrochloride to limited areas of the body. No anaphylactoid symptoms were associated with the contact urticaria.

Although not the type of delayed hypersensitivity that VanScott et al[24] were able to abolish by intravenous infusions of small amounts of the drug, it was decided to attempt desensitization in this case by the same method.[25] Because of the possibility of anaphylaxis, physicians and nurses were in attendance, and monitoring and resuscitation as well as emergency drugs were present at the bedside during all infusions. No symptoms of anaphylaxis occurred during any of the infusions and on the 14th day of the regimen,[25] the patient did not exhibit urticaria when mechlorethamine hydrochloride was applied. He was able to use the drug topically with almost complete suppression of skin lesions until the time of his death.

Results of physical examination during this hospitalization showed a few residual lesions of mycosis fungoides on the skin, but no other abnormalities were detected except for some minimal inguinal and axillary lymphadenopathy. A biopsy done on one of these nodes showed dermatopathic lymphadenopathy.

During the same hospitalization, the patient complained of pain in the left eye, especially on medial motion of the globe. Examination showed vision of 20/25 in the left eye and funduscopic examination showed infiltration of the optic disc. One week later, visual acuity of the left eye had decreased to 20/40 and a neurologic examination was normal except for the eye findings. Spinal fluid was normal. A brain scan showed no space-occupying lesions but did show an abnormality in the distribution of the left internal carotid and left middle cerebral artery. An EEG showed mild diffuse abnormalities. Roentgenographic examination of the skull and optic foramena showed no abnormalities.

One week later, visual acuity had again deteriorated to 20/80 and considerable swelling of the left optic disc with surrounding hemorrhages was noted (Fig 1). A visual defect was observed. The rapid visual loss was thought to represent papillitis or actual infiltration of the optic nerve with mycosis fungoides. A course of prednisone therapy was started beginning at 120 mg daily and tapering over a 14-day course after which it was stopped. Visual acuity in the left eye had returned to 20/20 by the end of the 14-day course and the visual field defect also had returned to near normal.

For the next five months, there was no

Accepted for publication Jan 27, 1977.
From the Department of Dermatology, University of Miami School of Medicine, Miami. Dr Pariser is now in private practice in Norfolk, Va and is also with the Eastern Virginia Medical School, Norfolk.
Reprints not available.

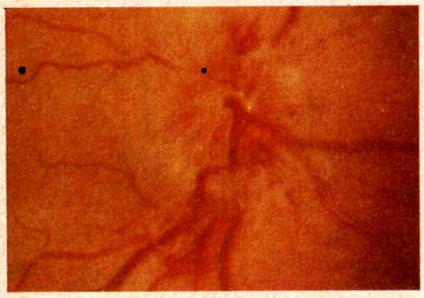

Fig 1.—Left fundus showing swelling of optic disc, blurred disc margins, and retinal hemorrhages.

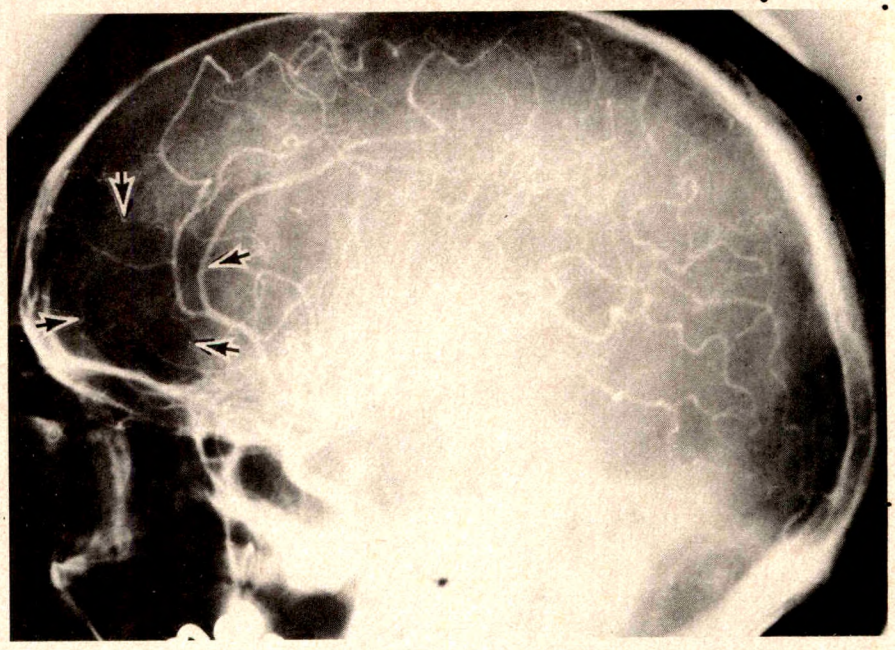

Fig 2.—Carotid angiogram showing mass lesion, indicated by arrows.

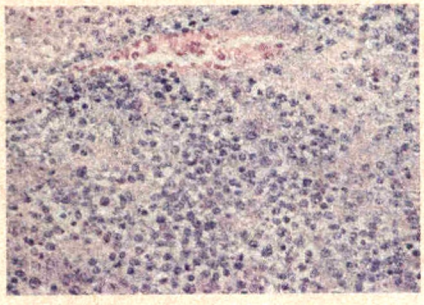

Fig 3.—Brain tissue from frontal lobe removed at craniotomy showing malignant infiltrate of mononuclear cells (×200).

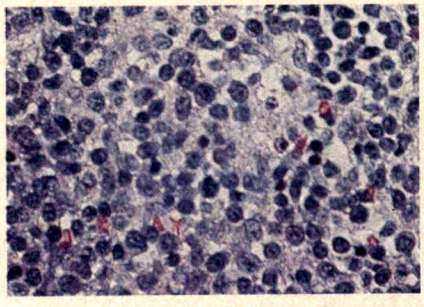

Fig 4.—Abnormal mononuclear cell infiltrate in frontal lobe (×400).

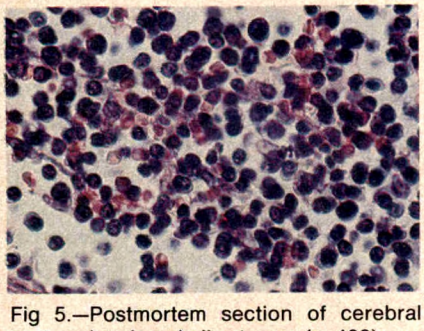

Fig 5.—Postmortem section of cerebral cortex showing similar tumor (×400).

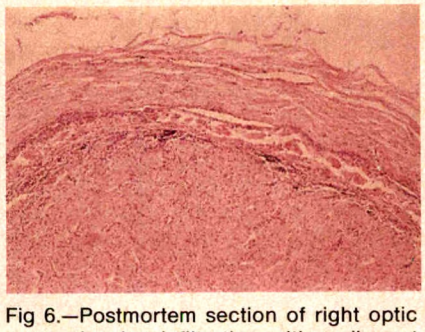

Fig 6.—Postmortem section of right optic nerve showing infiltration with malignant cells (×100).

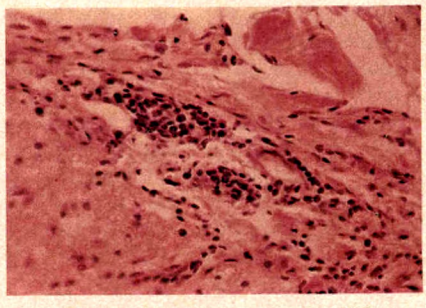

Fig 7.—Optic nerve at autopsy (×400).

recurrence of the eye symptoms, and therapy with topical mechlorethamine hydrochloride was continued until August 1974 when he experienced a sudden decrease in the vision of the right eye that had previously been uninvolved. The visual loss was associated on this occasion with headache and confusion. Examination on Aug 24, 1974, showed him to be lethargic with complete blindness of the right eye. There were no other abnormalities detected by neurologic or general physical examination except for some residual plaques and tumors of mycosis fungoides on the extremities and trunk. Lumbar puncture revealed an opening pressure of 365 mm of water with a protein of 240 mg/100 ml. No RBCs or WBCs were present in the fluid nor were any abnormal cells seen on cytologic examination. A brain scan showed an abnormality in the right frontal region. An echoencephalogram showed a 2.5-mm shift of the midline structures to the right. An EEG was considerably abnormal showing asymmetry with slow wave activity in the right temporal area. Spike wave discharges were also seen in the right temporal area. These findings were interpreted as showing a focal lesion of the right hemisphere. Carotid angiography demonstrated an avascular mass near the corpus callosum (Fig 2).

A craniotomy was performed on Aug 24, 1974, and a firm, meaty, red tumor mass was found on the posterior inferior side of the right frontal lobe within the brain substance. The mass was located immediately above and was compressing the right optic nerve. A yellow cystic mass deep within the parenchyma of the frontal lobe was found adjacent to the meaty mass. Histologic examination of the yellow cystic mass showed hemorrhage and an astrocytic reaction whereas the meaty mass had a malignant infiltrate of mycosis fungiodes (Fig 3 and 4).

Several days after surgery, a subdural hematoma developed requiring a second craniotomy. With the diagnosis of brain involvement, therapy was begun with intravenous cyclophosphamide (Cytoxan) and dexamethasone, but the patient never fully regained consciousness. After four weeks of pneumonia and CNS deterioration, he became an akinetic mute with a left-sided hemiplegia and anisocoria. He died of pneumonia on Oct 4, 1975.

Postmortem examination showed no involvement with mycosis fungoides in the reticuloendothelial system, the liver, or any internal organs except the brain where there was diffuse infiltration of the white matter of the cerebrum. The leptomeninges and dura were also involved. The tumor was grossly hemorrhagic and was composed of pleomorphic cells, many of which showed large irregularly shaped nuclei. Mitoses were frequent among the tumor cells (Fig 5). Reactive astrocytes were also found in areas where the infiltration was less dense. The tumor was present in the hypothalamus, corpus callosum, fornix, and right side of the hippocampus.

Microscopic examination of the eyes and optic nerves showed the globes to be free of disease, but both optic nerves had an infiltrate of large mononuclear cells with hyperchromatic nuclei that were also present in the surrounding meninges (Fig 6 and 7). These cells resembled the infiltrate in the cerebral cortex and are thought to represent infiltration of the optic nerves with mycosis fungoides.

COMMENT

Involvement of the optic nerves with mycosis fungoides is a rare event. Our patient's presenting symptom of internal disease was directly related to the optic nerve and brain involvement. The lymphomatous infiltration in the brain and optic nerves can be called mycosis fungoides or reticulum cell sarcoma. Our patient had long-standing typical mycosis fungoides and died of a lymphomatous infiltration of the brain. This must be considered to be the same disease process. The brain and the eyes should be evaluated along with other internal organs when searching for internal mycosis fungoides.

Westwood Pharmaceutical Inc, Buffalo, NY, provided funds for the printing of the color photographs in this article.

Dr Harvey Blank was the physician in charge of the case; Dr Robert Daroff was the consulting neurologist; and Dr Joel Glaser was the consulting neuro-opthalmologist.

References

1. Block JR, Edgcomb J, Eisen A, et al: Mycosis fungoides; Natural history and aspects of its relationship to other malignant lymphomas. *Am J Med* 34:228-235, 1963.

2. Epstein EH Jr, Levin DL, Croft JD, et al: Mycosis fungoides survival, prognostic features, response to therapy, and autopsy findings. *Medicine* 18:61-72, 1972.

3. Rappaport H, Thomas LB: Mycosis Fungoides: The pathology of extracutaneous involvement. *Cancer* 34:1198-1229, 1974.

4. Moncorps C, Borger C: Mycosis fungoides with mycotic changes in the brain and cerebral nerves. *Virchows Arch Pathol [Anat]* 286:157-166, 1932.

5. Pautrier ML, Hoerner G, Woringer MF: Résultats fornis par l'autopsie du cas de mycosis fongoide avec tumerus presente a la séance de mars dernier. *Bull Soc Fran Derm Syph* 47:8-14, 1940.

6. Cawley EP, Curtis AC, Leach JE: Is mycosis fungoides a reticuloendothelial neoplastic entity? *Arch Dermatol* 64:255-271, 1951.

7. Checinski T, Maldyk E: A case of mycosis fungoides having a feature of malignant proliferation of the reticular cells of the skin and internal organs. *Dermatologica* 124:420-432, 1962.

8. Reed RJ, Cummings CE: Malignant reticulosis and related conditions of the skin. *Cancer* 19:1231-1247, 1966.

9. Bell RF, Brown GR, Gordy PD: Reticulum cell sarcoma of skin and brain: Report of a case. *Arch Dermatol* 93:231-232, 1966.

10. Clinicopathologic conference: Mycosis fungoides with pulmonary and neurologic complications. *Am J Med* 42:129, 1967.

11. Weber MB, McGavran MH: Mycosis fungoides involving the brain. *Arch Neurol* 16:645-650, 1967.

12. Rosai J, Spiro JM: Central nervous system involvement by mycosis fungoides. *Acta Dermatovener* 48:482-488, 1968.

13. Trebin H, Gutjahr L: Mycosis Fungoides mit Beteiligung des Gehirns. *Acta Neuropathol* 13:282-288, 1969.

14. Heintel H, Heintel-Troster U, Worbes C: Mycosis Fungoides mit Beteiligung der Leptomeningen, Hirnnerven, Rukenmarkswurzeln und Spinalganglien "Meningeosis mycoides fungosa." *Dtsch Z Nervenheilk* 196:157-165, 1969.

15. Caldwell I, Dayan AD: Mycosis fungoides and progressive multifocal leukoencephalopathy. *Br J Dermatol* 82:176-181, 1970.

16. Foerster HC: Mycosis fungoides with intraocular involvement. *Trans Am Acad Ophthalmol Otol* 64:308-313, 1960.

17. Giannotti B, Lampis R, Scialdoni D: Micosi fungoide a primitiva localizzazione orbitaria. *Ann d'Ottal Clin Ocul* 89:483-491, 1963.

18. Wolter JR, Leenhouts TM, Hendrix RC: Corneal involvement in mycosis fungoides. *Am J Ophthalmol* 55:317-322, 1963.

19. Herman P: La keratite du mycosis fungoide. *Arch Ophthalmol* 11:39, 1951.

20. Kitchen CK: Mycosis fungoides keratitis. *Am J Ophthalmol* 55:758-761, 1963.

21. Lexow P, Nyquist B: Keratitis in mycosis fungoides with squamous cell carcinoma of the skin. *Acta Ophthalmol* 39:3, 1961.

22. Vogt A: *Lehrbuch u Atlas der Spaltlampenmikroskopie.* Berlin, Springer, 1930 p 177.

23. Franceshette A: Micosi fungoide con manifestazioni oculari. *Ann d'Ottal Clin Ocul* 76:413-420, 1950.

24. VanScott EJ, Kalmanson JD: Complete remission of mycosis fungoides lymphoma induced by topical nitrogen mustard (HN2). *Cancer* 32:18-30, 1973.

25. Lundberg WB, Cadmar EC, Skeel RT: Leptomeningeal mycosis fungoides. *Cancer* 38:2149-2153, 1976.

Reticular Pigmented Anomaly of the Flexures

J. B. Howell, MD, Robert G. Freeman, MD

• Reticular pigmented anomaly of the flexures (Dowling-Degos' anomaly) is a rare, benign, new genodermatosis that has recently evolved from independent observations and studies by several dermatologists. Because of its favorable prognosis, differentiation of this benign disorder from acanthosis nigricans, a cutaneous marker of possible or existing internal malignant disease, is highly important. Careful clinical appraisal of the eruption in correlation with the characteristic microscopic features makes the diagnosis simple and straightforward.

(*Arch Dermatol* 114:400-403, 1978)

In 1974, Wilson-Jones and Grice[1] reported and demonstrated cases of reticular pigmented anomaly of the flexures (Dowling-Degos' anomaly) and clarified this extraordinary epidermal nevoid anomaly; they clearly showed that the syndrome was not to be confused with any type of acanthosis nigricans. Earlier case reports by Dowling and Freudenthal[2] and by Degos and Ossipowski[3] constituted the foundation for this new entity.

REPORT OF A CASE

A healthy 50-year-old man was treated for a lingering acneiform eruption, which had been under treatment since he was a teenager, and for occasional episodes of apocrine gland infection. The patient drew attention to a peculiar pigmentation of his scrotum and flexures. The pigmentation had been present for approximately ten years and had spread very slowly. It was asymptomatic but engendered anxiety and fear since the possibility of associated malignant disease had been derived from medical consultation elsewhere. No other family members had the same or a similar eruption, to the patient's knowledge. However, the family members lived in Europe and were not available for examination.

The pigmentary eruption was symmetric and most striking on the scrotum (Fig 1). The distribution included the natal fold; the perineal, perianal, and crural regions; and the axillae. The lesions consisted of heavily pigmented macules seen as dark dots that were 3 to 5 mm in diameter and stood out conspicuously when the skin was stretched. There was a tendency for grouping or coalescing of some lesions, which gave a lacelike or reticular appearance. The rugae of the folds were not prominent or enlarged.

Results of a biopsy confirmed the diagnosis of reticulate pigmented anomaly of the flexures.

In addition to this pigmentation, our patient had four soft, fingerlike fibromas of the left axilla and two in each groin. There were several 2- to 3-mm, slightly elevated, pigmented epithelial nevi or seborrheic keratoses on the scrotum; small cysts (2 to 3 mm) of the scrotum, back, and axillae; double comedones of the axillae and groin; and a trichilemmal cyst on the back.

PATHOLOGIC FINDINGS

Specimens of skin from the thigh and scrotum revealed similar changes in all lesions. Acanthosis was a prominent feature and was characterized by an irregular elongation of thin, hyperpigmented rete ridges with a concentration of melanin at the tips (Fig 2, top). The elongation of rete ridges and hyperpigmentation involved the follicular infundibulum (Fig 2, bottom), as well as the epider-

Fig 1.—Left and right, Multiple pigmented macules of scrotum.

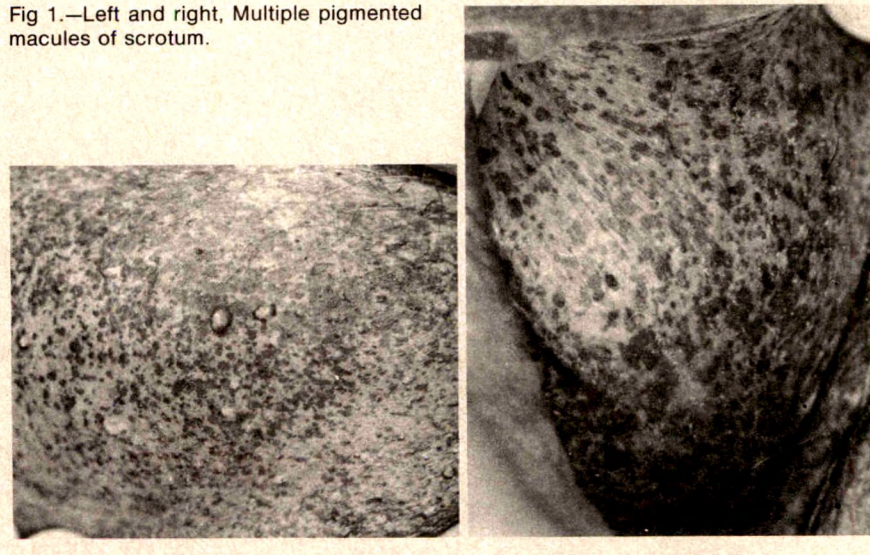

Accepted for publication March 2, 1977.

From the Division of Dermatology, Departments of Internal Medicine (Dr Howell) and Pathology (Dr Freeman), University of Texas Health Science Center, Dallas.

Reprint requests to 862 Wadley Tower, Baylor Medical Plaza, 3600 Gaston Ave, Dallas, TX 75246 (Dr Howell).

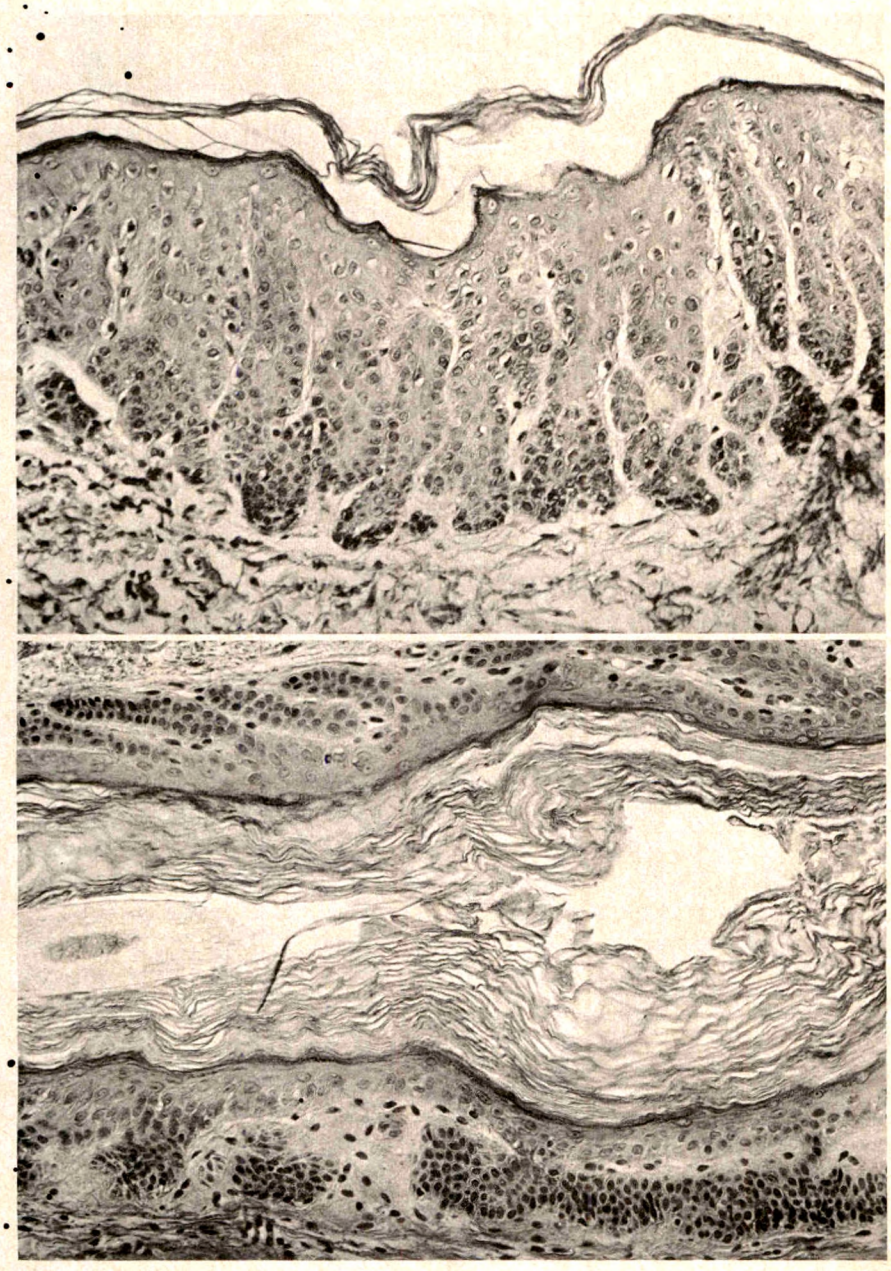

Fig 2.—Top, Characteristic elongated branching of rete ridges with hyperpigmentation. Bottom, Involvement of infundibulum of follicle was distinctive and unique feature (hematoxylin-eosin, ×1,200).

mis, and was sometimes associated with follicular plugging. This follicular involvement was a distinctive feature. Melanocytes were evident in the basal layer but did not appear to be altered in appearance or in number.

Additional sections of skin that were removed from the lesion and from an adjacent normal area were placed immediately in 2M calcium chloride solution for 30 minutes. The epidermis was then separated from the dermis, incubated in 0.1% dihydroxyphenylalanine (dopa) in phosphate buffer at pH 7.4 for two hours at 37 C, and mounted on a microscope slide (Fig 3). The density of melanocytes was determined by counting dopa-positive melanocytes in fifteen 1-sq-mm squares (eyepiece micrometer calibrated with a stage micrometer) for the control and lesional specimens of epidermis. The ranges of melanocyte density were 340 to 580 melanocytes per square millimeter (mean, 423 melanocytes per square millimeter) for control skin and 340 to 670 melanocytes per square millimeter (mean, 491 melanocytes per square millimeter) for lesional skin. The difference between these means was not statistically significant ($P > .9$).

Additionally, on routine hematoxylin-eosin-stained sections, lesional skin contained a mean of 12.5 basal keratinocytes per melanocyte (range, 2 to 48 keratinocytes per melanocyte) based on 100 melanocytes. A normal control specimen was not available for study. This value is similar to that reported by Montagna[4] as the mean for the thigh region (10.2 keratinocytes per melanocyte).

Therefore, the hyperpigmentation was not primarily due to an increase in density of melanocytes or to an alteration of the ratio of melanocytes to keratinocytes. The slightly higher mean value for melanocyte density in lesional skin probably could be accounted for by the greater epidermal-dermal surface area alone. The main concentration of melanin seen histologically was in keratinocytes of the elongated rete ridges, especially near the lower tips. Besides the increase in melanin content of individual cells at this location, there was a much greater surface area of the basal epidermal layer, a greater number of melanin-containing basal cells, and thus, an actual increase in melanin-containing keratinocytes per unit area of skin surface.

In tissue that was fixed in 3.7% neutral buffered formaldehyde solution and later processed for electron microscopy by routine techniques, no abnormality was noted in the melanocytes. Very few melanocytes were present in the material studied. In the keratinocytes, the most notable change was the presence of aggregates of melanin granules in the cytoplasm (Fig 4). These were not in membrane-bound spaces. They were aggregated between tonofibrils and other cell organelles. Some appeared immature or incompletely melanized.

COMMENT

Clinical Description

Multiple melanotic spots that involve the folds are rare. Crowe[5] described axillary freckling as a form of café au lait pigmentation, another diagnostic aid in the early recognition of neurofibromatosis. According to Crowe, persons who have extensive freckling (ephelides) have uninvolved axillary vaults; the pigmentation halts at the anterior and posterior axillary lines. Selmanowitz[6] observed axillary lentigines in the lentiginosis profusa syndrome.

Reticular pigmented anomaly of the flexures, an entirely different entity, initially affects the axillae and groins, sometimes in young persons. How-

ever, the most frequent age at onset has been 30 to 40 years old. Later in life, other areas, including the intergluteal and inframammary folds, neck, trunk, and arms, may be involved. Jacyk and Miklaszewska[7] noted tan-brown reticular pigmentation that involved the neck, wrists, dorsa of hands, fingers, and toes in their patient. Two of Wilson-Jones and Grice's[1] patients were sisters, and the mother of one of the other patients was also affected, which emphasized a genetic trait. Pitted scars and pigmentation below the angles of the mouth were demonstrated in their patients, as well as dark follicular dots on the neck.

The pigmentation consists of numerous small, discrete, round or oval, pigmented macules (approximately 2 to 5 mm in diameter) that resemble freckles. Confluence of lesions toward the vault of the axillae and the center of the genitocrural folds was observed by Smith et al.[8] The pigmentation is symmetric, progressive, often extensive, and asymptomatic; once established, it is thought to be permanent. In our patient, the scrotum was heavily pigmented, but the groins and axillae exhibited less involvement. Individual lesions vary in the degree of pigmentation, depending on the location and the patient. The folds and genitalia are usually more deeply pigmented. In Dowling and Freudenthal's[2] patient, these regions were described as being almost black with lesions so closely aggregated as to be nearly confluent. This confluence may result in a lacelike or reticular pattern with normal intervening skin. Although the lesions have been described as macules, Dowling and Freudenthal[2] noted numerous acuminate, rough, horny lesions on the neck. These seemed to be located about hair follicles and clinically suggested the possibility of Darier's disease. Jacyk and Miklaszewska[7] mentioned that some lesions in their patients' inguinal folds were slightly elevated above the level of the adjacent skin.

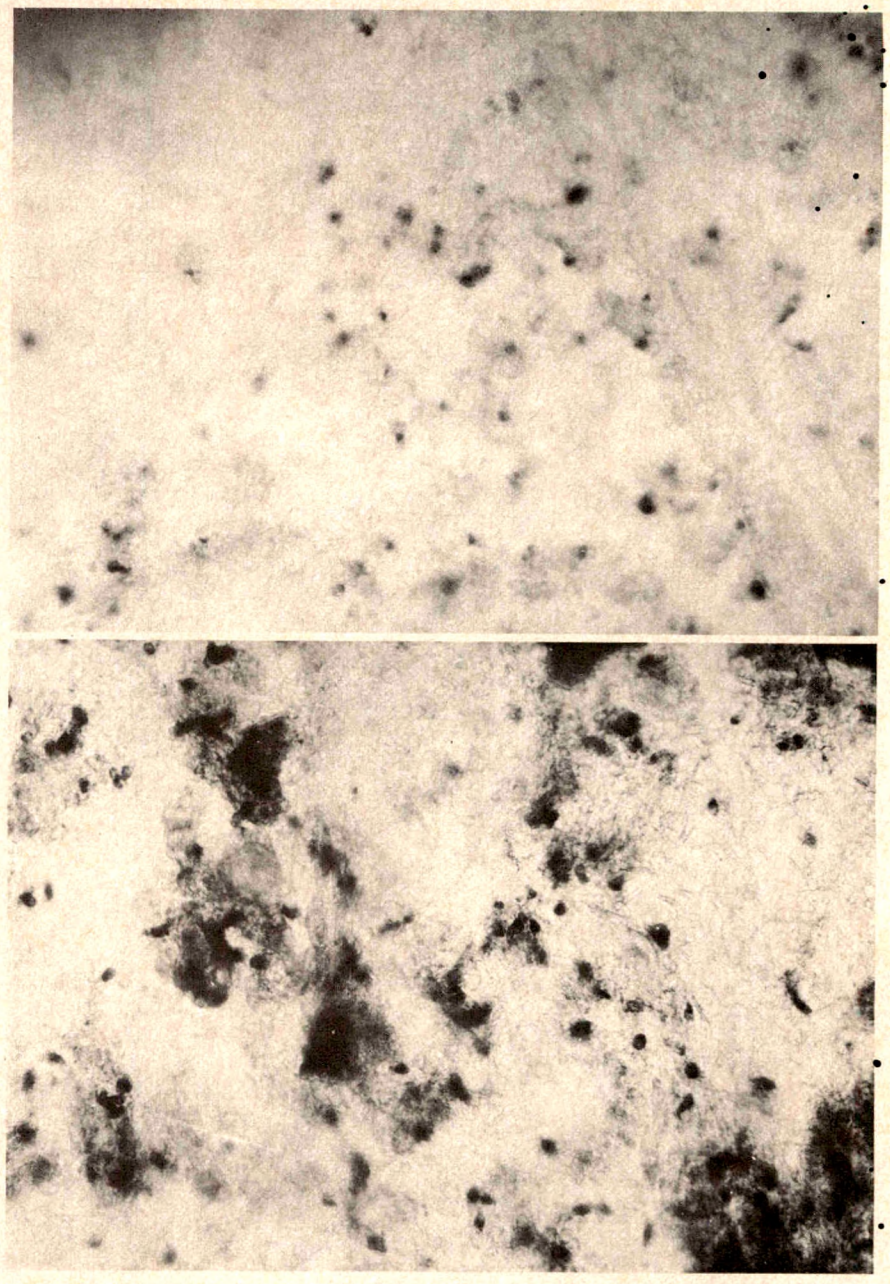

Fig 3.—Melanocytes as shown by dopa reaction. Top, On separated whole normal epidermis, melanocytes appear as dark dots. Bottom, In hyperpigmented lesion, melanocytes appear as dark dots. Larger dark aggregates represent rete ridges of separated whole epidermis (×600).

Review of Literature

According to Wilson-Jones and Grice,[1] there are only a few reports of reticular pigmented anomaly of flexures in the literature. Hamdi and Reschad[9] described a benign form of acanthosis nigricans in an 18-year-old woman whose lesions initially appeared in childhood and involved mainly the neck.

Dowling and Freudenthal[2] described and illustrated epithelial proliferations of the deeper parts of the sweat ducts and noted that a few "buds" were found on one sebaceous duct and one hair root. (Judging from their two microscopical illustrations, one would have thought that the epithelial proliferation arose from the hair follicle system as it did in their case).

In Behdjet's[10] case, described under the name "acanthosis nigricans unassociated with malignancy," the patient was a healthy 24-year-old woman whose eruption was of four years' duration.

Dowling and Freudenthal[2] described a 60-year-old man with a 20-year history of pigmentation of the axillae, intergluteal folds, genital region, and sides of the neck. They thought that their case might be interpreted as a nevus tardus, which histologically, in their view, was an example of acanthosis nigricans associated with trichoepithelioma, a feature hitherto unrecorded in acanthosis nigricans.

Degos and Ossipowski's[3] patient had an identical eruption; they pointed out that the skin was normal between the reticulated and individu-

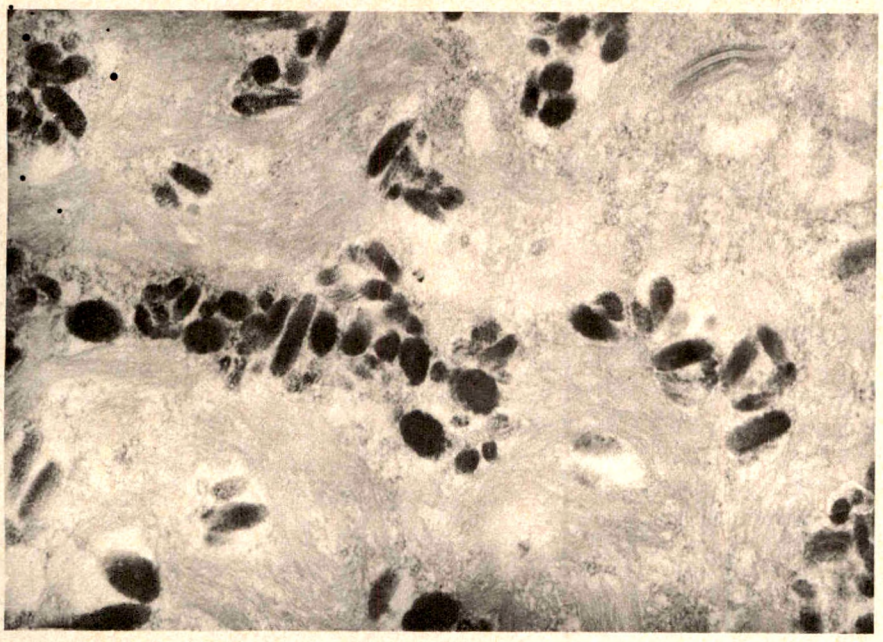

Fig 4.—Electron micrograph of epidermis demonstrating aggregation of melanin granules in cytoplasm of keratinocytes. There is no limiting membrane surrounding aggregates and no abnormality of melanocytes (×35,000).

al pigmented spots. Mucous membranes were not involved, and in their patient, the results of physical examination were normal; the condition could be distinguished from acanthosis nigricans, a position all subsequent reports have accepted.

Smith et al[8] described a healthy 34-year-old woman with a four-year history of darkening of the skin of the groins and axillae.

Recent reports document two additional cases.[7,11] The lesions, although slightly similar, are not seborrheic keratoses. The suggestion by Kaminsky et al[11] to name the entity "patchy (en nappe) seborrheic wart" is inappropriate.

Pathologic Differential Diagnosis

The pathologic changes seen in reticular pigmented anomaly of the flexures resemble those of more common lesions, including lentigo, senile lentigo, seborrheic keratosis, acanthosis nigricans, epidermal nevi, and other nevoid anomalies.

The absence of a melanocytic hyperplasia would rule out the possibility of a lentigo or other similar melanocytic lesion.

Except for the follicular involvement, the pathologic features are suggestive of seborrheic keratosis,[8] particularly of the adenoid type in which narrow cords of basaloid cells are present and are often hyperpigmented. Follicular plugging occasionally resembles horn cysts. However, in the reticular anomaly, there is no anastomotic pattern of basal cords, no papillomatosis, and no solid areas of basal proliferation. Smith et al[8] observed that many of the epithelial tongues showed branched or antler-like configurations. The involvement of the infundibulum of the hair follicle is a unique and distinctive feature of the reticular pigmented anomaly; it is not seen in seborrheic keratosis, epidermal nevi, or any other lesions. The macular configuration and clinical appearance also do not suggest seborrheic keratosis.

The follicular involvement has been compared with trichoepithelioma; however, it does not show the basal pattern that resembles hair matrix, and it does not have an associated connective tissue component suggestive of the connective tissue sheath of the follicle. The hair matrix was not available for study, so we could not determine whether an abnormality was present in this part of the follicle.

Reticular pigmented anomaly of flexures has been mistaken for acanthosis nigricans clinically and could also possibly be mistaken for it microscopically. In acanthosis nigricans, there are two components of epidermal change: (1) a papillomatosis that alters the surface of the epidermis and (2) an elongation of rete ridges with hyperpigmentation that corresponds to recesses in the papillomatosis. In reticular anomaly, there is no papillomatosis, and the elongation of rete ridges does not resemble that of acanthosis nigricans. The follicular anomaly has never been described in acanthosis nigricans.

Reticular pigmented anomaly of the flexures could be mistaken for an epidermal nevus or similar epithelial nevoid condition. In fact, it probably does represent a unique variation of an epithelial nevus or nevoid anomaly. However, it is distinctive and unique, and can readily be separated histologically from the more common linear nevus, nevus verrucosus, or the epidermal changes commonly seen in Jadassohn's nevus sebaceous.

References

1. Wilson-Jones E, Grice K: Reticulate pigmented anomaly of the flexures (Dowling, Degos): A new genodermatosis. *Br J Dermatol* 91(suppl):36, 1974.
2. Dowling GB, Freudenthal W: Acanthosis nigricans. *Br J Dermatol* 50:467-471, 1938.
3. Degos R, Ossipowski B: Dermatose pigmentaire reticulee des plis: (discussion de l'acanthosis nigricans). *Ann Dermatol Syphiligr* 81:147-151, 1954.
4. Montagna W: *The Structure and Function of Skin*, ed 2. New York, Academic Press, 1962, p 79.
5. Crowe FW: Axillary freckling as a diagnostic aid in neurofibromatosis. *Ann Intern Med* 61:1142-1143, 1964.
6. Selmanowitz VJ: Lentiginosis profusa syndrome (multiple lentigines syndrome): II. Histological findings, modified Crowe's sign, and possible relationship to von Recklinghausen's disease. *Acta Derm Venereol* 51:387-393, 1971.
7. Jacyk W, Miklaszewska M: Acquired axillary and inguinal pigmentations. *Dermatologica* 146:262-265, 1973.
8. Smith EL, Dowling GB, Wilson-Jones E: Acquired axillary and inguinal pigmentation: An epidermal nevoid abnormality not to be confused with acanthosis nigricans. *Br J Dermatol* 85:295-296, 1971.
9. Hamdi H, Reschad H: Ueber die Beziehungen der Acanthosis nigricans zu anderswertigen Epithelveränderungen und Teilnahme der Hautdrüsen bei dieser Krankheit. *Virchows Arch Pathol Anat Physiol Klin Med* 263:412-414, 1927.
10. Behdjet H: Deux observations et quelques considérations sur l'"acanthosis nigricans." *Bull Soc Fr Dermatol Syphiligr* 39:192-212, 1932.
11. Kaminsky CA, DeKaminsky AR, Sanguinetti O, et al: Acquired pigmentation of skin folds with the histological picture of seborrhoeic wart. *Br J Dermatol* 93:713-716, 1975.

Mal Perforans and Spina Bifida Occulta

David S. Lockman, MD; Terry M. Jones, MD; Donald C. Abele, MD; Eugenie Obbens, MD

• A 26-year-old man had mal perforans pedis as the principal manifestation of spina bifida occulta with an associated intradural lipoma. Two lumbosacral dimples and a tuft of hair overlying the spina bifida led to the diagnosis.

We include a review of the causes of mal perforans and a review of spina bifida occulta and associated abnormalities.

(*Arch Dermatol* 114:404-405, 1978)

Mal perforans may occur in any neurologic disease in which sensation is impaired while some degree of motor function is still present.

While it is well known that spina bifida occulta with associated abnormalities may cause mal perforans,[1-6] current dermatologic textbooks make no reference to this association.[7-11] We are reporting the following case of spina bifida occulta with an intradural lipoma presenting as mal perforans because the latency of onset of symptoms of mal perforans until adulthood is unusual,[12-14] and because mal perforans may be a cutaneous marker of a remediable lesion.[15]

REPORT OF A CASE

A 26-year-old man was seen for evaluation of a foot ulcer that had been present for 4½ years' duration.

He had stepped on a nail with his right heel 4½ years prior to examination. This injury had been painful. The original injury healed but six months later a small ulcer developed at the site. The ulcer had gradually grown to 2 cm in diameter. The ulcer had never been particularly painful. He had had no symptoms of enuresis, muscle weakness, or gait difficulty. After prolonged sitting or squatting the bottoms of his feet became slightly numb. His mother had adult onset diabetes mellitus and he had been told that he had chemical diabetes. Treatment of the ulcer had included various topical antibiotics and two skin grafts, both of which had sloughed. Results of a physical examination showed an overweight young man in no distress. Pertinent physical findings included an ulcer in the posterior aspect of the right heel. It was 2 cm in diameter and 1 cm deep with a hyperkeratotic border (Fig 1). He had two dimples in the midline of the lower back; one surrounded by a tuft of hair overlying the first sacral vertebra (Fig 2), and the other 2 cm above the anus. Neurologic examination disclosed decreased sensation to pinprick over the right calf, heel, sole, and fourth and fifth toes. Vibratory and position sense were decreased in the right foot. Muscle stretch reflexes were generally decreased, and ankle jerks were absent bilaterally. Perianal sensation was normal, as was anal sphincter tone. Laboratory studies showed normal complete blood cell count and normal findings from automated chemical analyses and urinalysis. Values of the glucose tolerance test were as follows: fasting, 90 mm/100 ml; half hour, 162; one hour, 203; two hours, 155; and three hours, 120. Culture from the ulcer for bacteria, deep fungi, and acid-fact bacilli; showed only coagulase-positive Staphylococcus. A biopsy specimen of the lesion showed hyperkeratosis and mild, nonspecific inflammation. Examination of the CSF showed a glucose level of 59 mg/100 ml; protein, 89 mg/100 ml; and no cells. Roentgenograms of the right foot showed a soft tissue ulcer without bony abnormalities. Cervical spine roentgenograms were normal. Dorsal spine x-ray films showed minimal osteophyte formation. Those of the lumbosacral spine showed a spina bifida occulta throughout the sacrum (Fig 3). There was no evidence of spondylosis or spondylolisthesis. Electromyogram showed normal motor and sensory nerve conduction studies in the right lower extremity. Needle examination disclosed denervation in muscles innervated by sacral roots, worse on the right. It was interpreted as bilateral sacral radiculopathy vs cauda equina lesion, worse on the right. Lumbar

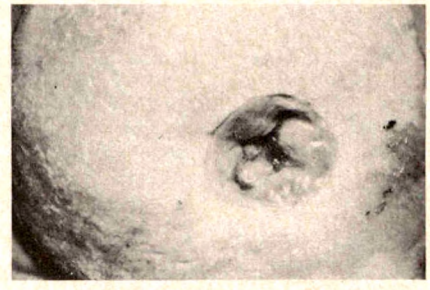

Fig 1.—Mal perforans on posterior aspect of heel.

Fig 2.—Midline lumbosacral dimple surrounded by hair.

Fig 3.—Spina bifida occulta throughout spine.

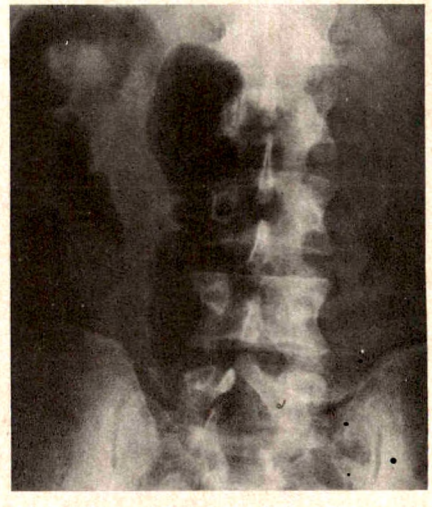

Accepted for publication March 10, 1977.

From the Departments of Dermatology (Drs Lockman, Jones, and Abele) and Neurology (Dr Obbens), Medical College of Georgia, Augusta.

Reprint requests to Department of Dermatology, Medical College of Georgia, Augusta, GA 30902 (Dr Abele).

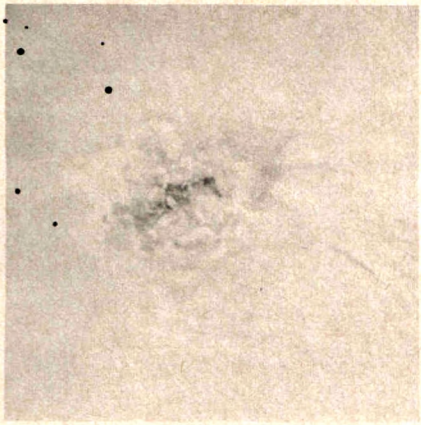

Fig 4.—Ulcer, two weeks postoperatively.

myelogram showed a large, oval, somewhat irregular filling defect in the subarachnoid space at the level of S_1. The mass was attached superiorly to the spinal cord, which extended to the sacral level.

The patient underwent a laminectomy from L_5 to S_2. A lipoma was found extending from the dermal dimple through the upper border of the spina bifida into the subdural space. The lipoma infiltrated the conus medullaris superiorly and the cauda equina roots inferiorly. A subtotal removal of the lipoma was performed. Two weeks postoperatively the ulcer was almost healed and sensation was returning to the sole of the right foot (Fig 4).

COMMENT

Mal perforans (derived from Latin for an evil boring through),[16] also known as neurotrophic ulcer or perforating ulcer, is a chronic ulcer occurring in denervated skin at the site of constant pressure or trauma. Clinically, these ulcers appear crusted and deep while the surrounding skin is hyperkeratotic and anhidrotic.[10] The presence of pain does not rule out the diagnosis of mal perforans because deep sensation or referred pain may be present.[11]

Mal perforans may occur on the face following a vascular insult such as the lateral medullary syndrome of Wallenberg[17] or after surgical procedures resulting in trigeminal anesthesia.[18] These ulcers usually occur at the nasolabial fold but may occur on the forehead and cheek.[19]

However, the most common locations for these ulcers are the hands and feet. Underlying causes of these ulcers include certain peripheral neuropathies such as hereditary sensory neuropathy,[10] Charcot-Marie-Tooth disease,[18] Dejerine-Sottas disease,[10] Hansen's disease,[10] amyloid neuropathy,[10] small-fiber diabetic neuropathy,[10] nutritional neuropathy,[10] or neuropathy due to lesions of named peripheral nerves. Other causes include congenital insensitivity to pain,[10] spinal cord lesions such as tabes dorsalis,[10] syringomyelia,[10] and posttraumatic[17] and myelodysplasia,[3] as in this case.

In a review of 47 cases of mal perforans pedis, Kelly and Coventry[3] found diabetes to be the most common cause, being found in 23 of the 47 cases. The second most common cause (eight cases) was myelodysplasia.

Myelodysplasia (spinal dysraphism) consists of certain variable anomalies that result from embryonic errors during and following closure of the neural tube in the early weeks of gestation. Most frequently, the defect occurs in the lower lumbar region and includes well-marked distortions of the spinal cord or of the cauda equina and meninges, bony elements of the spinal column, and the overlying muscles and skin.[6] The term spina bifida has come to include the bony defect plus associated anomalies. If the defect is severe enough, a fluid-filled sac tends to form that often produces an external swelling (spina bifida cystica). However, there may be no external evidence of any abnormality or there may be a dimple, a sinus, a tuft of hair, or a port wine stain (spina bifida occulta).[20]

The embryology, overlying cutaneous changes, and underlying spinal and meningeal defects in spina bifida occulta were recently reviewed by Harris and Miller.[21]

Several points deserve emphasis. Spina bifida occulta is a common finding in the lumbar or sacral region in the normal population, estimated at 25% by Ingraham and Lowrey.[22] However, spinal and meningeal defects or growths of clinical importance in spina bifida occulta are relatively rare lesions.[21] The spinal cord anomalies (diastematomyelia, hydromyelia, ectopic nerve roots, dermoids, cauda equina compression due to a fibrous band, and intraspinal lipomas) may be present without overlying bony or cutaneous abnormalities.[23,24] Last, symptoms and signs of the associated spinal defects primarily occur in the pediatric population[12-14] but, as pointed out by Harris and Miller's case 3[21] and our case, it may be delayed until the late 20s and early 30s and, in the exceptional case, may be delayed until the 50s.[13]

References

1. Lassman LP, James MCC: Spinal dysraphism. *Arch J Dis Child* 35:315-327, 1960.
2. Lowrey JJ, Ingraham FD: Spina bifida and cranium bifida. *N Engl J Med* 228:745-750, 1943.
3. Kelly PJ, Coventry MB: Neurotrophic ulcers of the feet. *JAMA* 168:388-393, 1958.
4. Shuman AM: Malum perforans in a young girl with spina bifida. *J Am Podiatry Assoc* 60:248-249, 1970.
5. Brickner WM: Spina bifida occulta. *Am J Med Sci* 155:473-502, 1918.
6. Anderson FM: Occult spina dysraphism. *J Pediatr* 73:163-177, 1968.
7. Edwards EA: Cutaneous changes in peripheral vascular disease, in Fitzpatrick TB, Arndt KA, Clark WC, et al (eds): *Dermatology in General Medicine*. New York, McGraw-Hill Book Co Inc., 1971, p 1655.
8. Domonkos AN: *Andrew's Diseases of the Skin*. Philadelphia, WB Saunders Co, 1971, p 73.
9. Eliasson SG, Landau WM: Trophic skin lesions associated with sensory disturbances, in dermis DJ, Dobson RL, McGuire J (eds): *Clinical Dermatology*. Hagerstown, Md, Harper & Row, 1972, vol 4, pp 1-9.
10. Moschella SL, Pillsbury DM, Hurley HJ: *Dermatology*. Philadelphia, WB Saunders Co, 1975, pp 1561-1564.
11. Rook A, Wilkinson DS, Ebling FSG (eds): *Textbook of Dermatology*, ed 2. London, Blackwell Scientific Publications, 1972, pp 1809-1810.
12. Bassett RC: The neurologic deficit associated with lipomas of the cauda equina. *Ann Surg* 131:109-116, 1950.
13. Dubowitz V, Lorber J, Zachary RA: Lipoma of the cauda equina. *Arch J Dis Child* 40:207-213, 1965.
14. Lassman LP, James MCC: Lumbosacral lipomas: Critical survey of 26 cases submitted to laminectomy. *J Neurol Neurosurg Psychiatr* 30:174-181, 1967.
15. Lassman LP, James MCC: Results of treatment of progressive lesions in spina bifida occulta five to ten years after laminectomy. *Lancet* 2:1277-1279, 1967.
16. Leider M, Rosenblum M: *A Dictionary of Dermatological Words, Terms, and Phrases*. New York, McGraw-Hill Book Co Inc, 1968.
17. Barraquer L-F, Barraquer L-B: Trophic disorders of the feet in acquired lesions of the cauda equina *J Nerv Ment Dis* 116:902-911, 1952.
18. Adams RD, Asbury AK: Diseases of the peripheral nervous system, in Wintrobe MM, Thorn GW, Adams RD, et al (ed): *Harrison's Principles of Internal Medicine*, ed 7. New York, McGraw-Hill Book Co Inc, 1974, pp 1717-1730.
19. Karnosk LJ, Scherb RF: Trophic lesions in distribution of the trigeminal nerve. *JAMA* 115:2144-2147, 1940.
20. Moriarty JA, Klingman WO: Congenital and prenatal diseases, in Baker AB (ed): *Clinical Neurology*, ed 2. New York, Hoeber Medical Division, 1962, vol 4, pp 1924-1930.
21. Harris HW, Miller OF: Midline cutaneous and spinal defects. *Arch Dermatol* 112:1724-1728, 1976.
22. Ingraham FD: *Spina Bifida and Cranium Bifida*. Cambridge, Mass, Harvard University Press, 1944.
23. Lichtenstein BW: Spinal dysraphism. *Arch Neurol Psychiatr* 44:792-810, 1940.
24. Lord Brain WR, Walton JN: *Brain's Diseases of the Nervous System*, ed 7. London, Oxford University Press, 1964, pp 672-675.

Varicella-like Infection Due to Herpes Simplex

John C. Long, MD; Clayton E. Wheeler, Jr, MD; Robert A. Briggaman, MD

• Herpes simplex usually presents with fairly characteristic skin lesions that are localized to small area. A less well appreciated presentation for herpes simplex is a varicelliform eruption that may be difficult to differentiate from chickenpox. We treated a patient with such an eruption who had systemic lupus erythematosus and was receiving oral prednisone. We also review seven other cases from the literature of varicella-like herpes simplex and discuss the role played by immunosuppression in herpetic infections.

(*Arch Dermatol* 114:406-409, 1978)

Clinically evident primary or recurrent herpes simplex infections usually remain localized to certain body regions, the most common being the mouth, eye, genital area, and small areas of skin. On rare occasions, the infection disseminates to cause a chickenpox-like or varicelliform eruption. This varicelliform eruption may be of two types. The most common type, called Kaposi's varicelliform eruption, develops in patients who have some type of preexisting skin disease, most often atopic dermatitis, but other dermatoses such as pemphigus and Darier's disease also predispose to this type of disseminated cutaneous infection. A much less common and less well appreciated type of herpetic varicelliform eruption occurs in patients who have no preexisting skin disease. It is this varicella-like herpes simplex infection that is the subject of this report.

We describe a patient with systemic lupus erythematosus (LE) treated with prednisone who developed a primary herpes simplex infection of the penis, followed by a generalized varicelliform eruption. We shall also review briefly other cases that fit out classification of varicella-like herpes simplex infection, of which all but one are immunocompromised. In addition, we shall comment briefly on herpetic infections in immunologically compromised hosts.

REPORT OF A CASE

The history of this 26-year-old man's illness dates back to age 15 when he had an episode of uncontrollable epistasis and was found to have a platelet count of 2,500/cu mm. Results of a bone marrow biopsy at that time disclosed only erythroid hyperplasia. A latex fixation test was positive at 1:640 and three LE preparations were negative. The patient was given oral steroids, which returned the platelet count to normal.

Between the ages of 15 and 27, the patient had multiple episodes of low-grade fever, malaise, sore throat, and cough, followed by spontaneous resolution. He also had an episode of pleuritic chest pain and hematuria in December 1973. In early May 1974 he developed swelling of both wrists with decreased range of motion and pain.

The patient was admitted to the North Carolina Memorial Hospital for the first time in May 1974. At that time he had a temperature of 37.7 C (orally), decreased range of motion in both wrists with effusions, and bilateral knee effusions, Results of a laboratory workup included a Westergren sedimentation rate of 120 mm/hr, a positive LE preparation, a 4+ homogeneous rim-staining antinuclear antibody (ANA) pattern; and a latex fixation of less than 1:20. The serum complement level was 122 mg/100 ml (normal, 90 to 185). The BUN and creatinine levels were normal. A diagnosis of systemic LE, was made and the patient was started on a regimen of salicylates. Due to a poor response, prednisone, 30 mg/day; was added and the patient was discharged with relief of his symptoms.

Between July 7 and 9, 1974, the patient developed a temperature of 40 C orally, chills, diarrhea, and a vesicular rash on his penis. He was noted to have a 0.5 × 0.5-cm superficial ulceration with surrounding vesicles on the penile shaft just proximal to the glans. He had no previous history of herpes simplex infection. A Tzanck smear showed intranuclear inclusion bodies and multinucleated and ballooning giant cells. He was given 1% idoxuridine in dimethylacetamide to apply topically and was sent home. During the next 24 hours multiple vesicles and vesiculopustular lesions, varying from 0.5 to 2.5 mm in diameter appeared on his forehead, cheeks, nose, fingers, forearms, upper part of his arms, chest, and back. These lesions occurred as isolated vesicles or small clusters of vesicles in the regions mentioned (Fig 1 through 4). The patient was readmitted to the North Carolina Memorial Hospital on July 14, 1974.

Laboratory data included the following values: hematocrit, 41%; WBC count, 8,500/cu mm, with 45% neutrophils, 13% band forms, 28% lymphocytes, and 14% monocytes; platelet count, 210,000/cu mm; BUN, 10 mg/100 ml; creatinine, 1.0 mg/100 ml; total bilirubin 0.5 mg/100 ml; SGOT, 361 SF units: SGPT, 531 SF units; lactic dehydrogenase, 995 units/ml; alkaline phosphatase, 8.7 NP units; IgG, 290 mg/100 ml (normal, 700 to 1,500); IgA, 650 mg/100 ml (normal, 150 to 300); IgM, 260 mg/100 ml (normal, 60 to 120); Westergren sedimenta-

Accepted for publication March 29, 1977.

From the Department of Dermatology, North Carolina Memorial Hospital, Chapel Hill. Dr Long is now in private practice in Winston-Salem, NC.

Reprint requests to Department of Dermatology, North Carolina Memorial Hospital, Chapel Hill, NC 27514 (Dr Wheeler).

tion rate, 90 mm/hr; ANA negative; 1+ proteinuria, but urine otherwise normal; normal chest roentgenogram. A mumps skin test showed 4.8 mm of erythema at 48 hours, a streptokinase-streptodornase skin test showed 5.5 mm of induration at 48 hours and an intermediate purified protein derivative was negative.

A Tzanck smear of one of the vesicles on the face showed intranuclear inclusion bodies and multinucleated and ballooning giant cells. Vesicular fluid from the face, mouth, hand, and penis was inoculated on HeLa cells and showed a cytopathic effect consistent with herpes simplex virus, type II. A punch biopsy was done of a vesicular lesion on the patient's right forearm. The center of the biopsy specimen showed a crater containing necrotic cellular debris with complete loss of the epidermis. The ulcerated area also contained old blood, pigment-laden macrophages and occasional balloon cells. In the upper dermis there was a moderate chronic vasculitis of small vessels with lymphocytes and plasma cells surrounding the vessels.

The patient was continued on a regimen of salicylates and prednisone. He developed right-upper-quadrant pain and the scattered vesicular lesions spread to involve most of the back, chest, and lower extremities. During a two-week period the patient's skin lesions began to resolve and his liver function study results returned to normal levels. He was discharged July 27, 1974, on a course of tapering doses of prednisone.

On follow-up in the Dermatology Clinic on Aug 2, 1974, the patient was given prednisone, 17.5 mg every other day. Several small vesicles persisted on the left forearm, of which a Tzanck smear showed intranuclear inclusion bodies and multinucleated and ballooning giant cells. In a telephone conversation with the patient on September 11, 1974, he stated that he was continuing to develop a few scattered vesicles. The patient moved away and was lost to follow-up.

Table 1.—Summary of Herpes Virus Studies

	Tzanck Smear	HeLa Cell Culture	Herpes Neutralizing Antibody Titer*		CF Titers to Herpes
			Type 1	Type 2	
5/21/74	...	...	...	...	1:10
7/15/74	Positive	Herpes simplex, type II from penis, face, neck, mouth, & hand	32-64	32-64	1:320
7/17/74	...	...	128-256	128-256	...
7/19/74	...	...	256-512	256-512	...
7/22/74	...	...	512-1,024	512-1,024	1:640
8/2/74	Positive	...	256-512	256-512	...

*In our laboratory equal neutralizing antibody titers to type 1 and type 2 indicate a serologic response to a type 2 infection.

Fig 1.—Scattered vesiculopustular lesions on dorsum of hand.

Fig 2.—Maculopapular and pustular lesions on palmar surface of hand.

Fig 3.—Scattered and grouped vesiculopustular lesions on chest.

Fig 4.—Discrete vesiculopustular lesions on ankle.

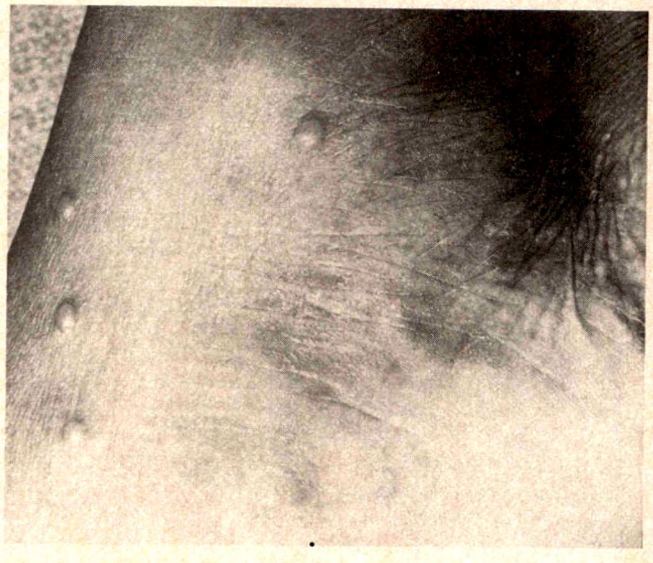

Table 2.—Summary of Eight Cases*

	Age (yr) and Sex	Underlying Disease	Preceding Drugs	1° Site	Areas of Dissemination
Arora et al[1]	34 M	Renal transplant	Azathioprine, prednisone, gentamicin	Suture sites on abdomen	Face, extremities, back
Kipping & Downie[2]	37 M	None	None	5 Vesicles on hands & feet	5-10 lesions on back, feet, & trunk
Mueller et al[3]	37 F	Hodgkin's disease	NS	NS	Face & trunk
Solomon[6]	84 M	Myelogenous Leukemia	None	Abdomen	Extremities, trunk, face, & mouth
Sutton et al[4]	20 F	Thymic dysplasia	Oral contraceptives, ampicillin, penicillin	Probably cervix	Face, neck, upper chest, & cervix
Rendtorff & Fowinkle[5]	23 F	Chronic granulocytic leukemia	NS	Vulva	40-50 lesions over trunk, face, palms, soles, & perineum
Lynfield et al[7]	68 M	Lymphosarcoma	Cyclophosphamide, prednisone	Upper trunk	Trunk, extremities, face, palms, soles, mouth, & nostrils
Long et al	27 M	Systemic lupus erythematosus	Prednisone	Penis	Trunk, extremities, face, & genitalia

*NS indicates not stated.

Neutralizing antibody and complement fixation titers, Tzanck smears, and cultures taken at various intervals during this man's illness are summarized in Table 1.

COMMENT

We have been able to find seven other cases of varicella-like infection due to herpes simplex in the literature. These seven cases plus ours are summarized in Table 2. There appeared to be no predilection for either sex. Six of the eight, including the present case, were individuals younger than 40 years of age.[1-5] Three of the eight, including the present case, represented primary herpetic infections, as documented by viral isolation and a fourfold or more increase in serum antibody titers.[1,2] Although one might suspect that the other five cases were primary infections, they cannot be clearly classified as such or as being recurrent due to incomplete documentation of antibody titers.[3-7]

The initial site of infection was the genital area in three cases. Initial sites of infection in the others were the upper part of the trunk,[7] the abdomen,[6] and an abdominal suture line.[1] The initial site of infection was not stated or was not obvious in two cases,[2,3] and none was thought to have originated from initial infections of the mouth or eye.

Areas to which the virus disseminated varied but in all cases dissemination included the trunk; in seven cases, it included the face; and in six the extremities. All cases apparently had variable numbers of discrete, scattered lesions. Grouping of individual lesions was described in only two cases besides ours.[4,6]

The disseminated cutaneous lesions early in the course of our case were indistinguishable from varicella. Individual lesions showed orderly progression from macules to 2- to 4-mm, umbilicated, vesicles, which became pustular, crusted, and healed, leaving hypopigmented areas or superficial scars. Residual hypopigmentation was also described by Mueller et al.[3] After a few days of the disease there developed a herpetiform distribution of vesicles at some sites. There was a tendency for the first lesion in an area to be a discrete vesicle around which developed a small cluster of vesicles in a few days, as the older, initial lesion was undergoing crusting and healing. This herpetiform behavior is unusual in varicella and serves as a clinical clue that the disease might be due to herpes simplex rather than the zoster-varicella virus. However, there is no way to make an exact clinical distinction from typical or atypical varicella in these cases, and one must rely on laboratory tests for exact diagnosis.

Although the course of varicella-like herpes simplex was poorly described in most cases, it appeared to be variable. When our patient was lost to follow-up, he had been having repeated eruptions of herpes lesions for 2½ months. In the case described by Mueller et al, new lesions developed for at least one year.[3] Another patient developed lesions for three weeks,[6] and in another the duration appeared to be about one week.[5] The patients described by Sutton et al and by Lynfield and co-workers died six days and one month, respectively, after the onset of herpes lesions.[4,7] The duration of the illness could not be ascertained in the other two cases.[1,2] The viral infection was associated with fever in all but one.[3] Muscle aching and/or malaise, which lasted a few days or two or three weeks, was a prominent feature of our case as well as that described by Solomon.[6] Vomiting, diarrhea, and backache were additional features described by Kipping and Downie.[2] Based on the abnormal liver enzyme study results and right-upper-quadrant pain, it is likely that our patient suffered from herpetic hepatitis. One patient in this series of eight died from the herpetic infection, which complicated thymic dysplasia.[4]

Because the skin lesions of varicella and varicella-like herpes simplex due to herpes cannot be distinguished conclusively on clinical grounds, laboratory study is essential for definitive diagnosis. Skin biopsy specimens and Tzanck smears show intraepidermal vesicles, ballooning, viral acantholysis, multinucleated giant cells, and intranuclear inclusions, but these changes are identical for herpes simplex and zoster-varicella infections. The herpes simplex virus grows in a wide variety of animal and human tissue cultures, where it produces a characteristic picture. Herpes simplex virus produces disease in small laboratory animals and the chorioallantoic membrane of the embryonated chicken egg. The zoster-varicella virus is much more fastidious, producing disease in only certain cell cultures of primate origin and failing to induce disease in small laboratory animals or the chorioallantoic membrane. The two viruses can be distinguished by means of serologic techniques such as the neutralization test. In addition, serologic testing is required in herpes simplex infections to determine whether the infection is primary or recurrent; complement fixing and neutralizing tests show a substantial increase of serum antibody titers during primary infections, whereas

titers are high at the onset of recurrent infections and show little change during their course.

Most of the patients with varicella-like infection due to herpes simplex have some underlying disease or condition. Four of the eight patients had either leukemia or lymphoma,[3,5-7] and one of these four was taking immunosuppressive drugs.[7] Another patient was taking immunosuppressive drugs after receiving a renal transplant.[1] Our patient had systemic LE and was taking prednisone. The one patient who died had thymic dysplasia.[4] Only one patient was apparently healthy with no underlying disease or immunosuppressive therapy.[2]

A number of diseases, drugs, or physical agents appear to predispose to the development of bizarre, disseminated, or slowly healing herpes simplex infections. It has long been known that persons with eczema, including individuals with Wiscott-Aldrich syndrome and especially persons with atopic eczema, are susceptible to herpes simplex infections.[8-13] Preceding infections, in particular measles, can predispose to disseminated herpes simplex infections.[14,15] Malnourished patients, for example those with marasmus, kwashiorkor, and severe celiac disease, may exhibit severe and fatal herpes simplex infections from visceral involvement.[15-19] Individuals who have received organ transplants and are receiving immunosuppressive drugs may acquire many types of infection, including extensive, deep, progressive recurrent herpes simplex.[1,20] The fetus, neonates, and premature infants who are not yet immunocompetent and burned patients who probably have an acquired immune defect are known to be susceptible to cutaneous and visceral herpes simplex infections.[21-27] A drug-induced immune defect and/or a defect from malignancy predisposes individuals with lymphomas and hematologic malignancies to herpes simplex infections.[3,5-7,28-32] Pregnancy has recently been implicated in disseminated visceral herpes.[33] The specific reasons why patients with these conditions are susceptible to herpetic infections are not known but immunologic abnormalities appear to be very important in their pathogenesis.

Since this article was completed, Naragi et al reported a case of herpes simplex with features of chicken pox.[34]

Nonproprietary Names and Trademarks of Drugs

Idoxuridine—*Dendrid, Herplex, Stoxil.*
Azathioprine—*Imuran.*

References

1. Arora KK, Karalakulasingam R, Raff MJ, et al: Cutaneous herpesvirus hominis (type 2) infection after renal transplantation. *JAMA* 230:1174-1175, 1974.
2. Kipping RH, Downie AW: Generalized infection with the virus of herpes simplex. *Br Med J* 10:247-249, 1948.
3. Mueller SA, Herrman EC, Winkelmann RK: Herpes simplex infections in hematologic malignancies. *Am J Med* 52:102-114, 1972.
4. Sutton AL, Smithwick EM, Seligman SJ, et al: Fatal disseminated herpesvirus hominis type 2 infection in an adult with associated thymic dysplasia. *Am J Med* 56:545-553, 1974.
5. Rendtorff RC, Fowinkle EW: Herpes simplex skin lesions simulating smallpox. *JAMA* 192:156-158, 1965.
6. Solomon M: Herpes simplex virus from skin lesions of myelogenous leukemia. *Arch Intern Med* 107:100-104, 1961.
7. Lynfield YL, Farhangi M, Runnels JL: Generalized herpes simplex complicating lymphoma. *JAMA* 207:944-945, 1969.
8. Lynch FW, Evans CA, Bolin VS, et al: Kaposi's varicelliform eruption. *Arch Dermatol* 51:129-137, 1945.
9. Wenner HA: Complications of infantile eczema caused by the virus of herpes simplex. *Am J Dis Child* 67:247-264, 1944.
10. St Geme JW Jr, Prince JT, Burke BA, et al: Impaired cellular resistance to herpes simplex virus in Wiskott-Aldrich syndrome. *N Engl J Med* 273:229-234, 1965.
11. St Geme JW Jr, Prince JT, Burke BA, et al: Studies of persistent herpes virus infections in children with the Aldrich syndrome. *J Pediatr* 61:302-303, 1962.
12. Cooper MD, Chase HP, Lowman JT, et al: Wiscott-Aldrich syndrome. *Am J Med* 44:499-513, 1968.
13. Evans DIK, Holzel A: Immune deficiency state in a girl with eczema and low serum IgM. *Arch J Dis Child* 45:527-533, 1970.
14. Kipps A, Becker W: Fatal disseminated herpesvirus infection in children: Epidermiology based on 93 non-neonate cases. *S Afr Med J* 41:647-651, 1967.
15. Becker WB, Kipps A, McKenzie D: Disseminated herpes simplex virus infection. *Am J Dis Child* 115:1-8, 1968.
16. McKenzie D: Disseminated herpes simplex infection. *S Afr Med J* 35:133-135, 1961.
17. McKenzie D, Hansen JDL, Becker W: Herpes simplex virus infection: Dissemination in association with malnutrition. *Arch J Dis Child* 34:250-256, 1959.
18. Becker W, Naude W, Kipps A: Virus studies in disseminated herpes simplex infections. *S Afr Med J* 37:74-81, 1962.
19. Dowling RH, Henry K: Non-responsive celiac disease. *Br Med J* 3:624-631, 1972.
20. Montgomerie JZ, Becroft DMO, Croxson MC, et al: Herpes simplex virus infection after renal transplantation. *Lancet* 2:867-871, 1969.
21. Hanshaw JB: Herpesvirus hominis infections in the fetus and the newborn. *Am J Dis Child* 126:546-555, 1973.
22. Florman AL, Gershon AA, Blackett PR, et al: Intrauterine infection with herpes simplex virus: Resultant congenital malformations. *JAMA* 225:129-132, 1973.
23. Nahmias AJ, Dowdle WR, Josey WE, et al: Newborn infection with herpesvirus hominis type 1 and 2. *J Pediatr* 75:1194-1203, 1969.
24. Bird T, Ennis JE, Wart AJ, et al: Disseminated herpes simplex in newborn infants. *J Clin Pathol* 16:423-431, 1963.
25. Foley FD, Greenawald KA, Nash G, et al: Herpesvirus infection in burned patients. *N Engl J Med* 282:652-656, 1970.
26. Nash G, Foley FD: Herpetic infection of the middle and lower respiratory tract. *Am J Clin Pathol* 54:857-863, 1970.
27. Nash G: Necrotizing tracheobronchitis and bronchopneumonia consistent with herpetic infection. *Hum Pathol* 3:283-291, 1972.
28. Price R, Chernik NL, Horta-Barbosa L, et al: Herpex simplex encephalitis in an anergic patient. *Am J Med* 54:222-228, 1973.
29. Bean SF, Fusaro RM: Atypical cutaneous herpes simplex infection associated with acute myelogenous leukemia. *Acta Derm Venereol* 49:94-96, 1969.
30. Morrison WL: Herpes simplex and herpes zoster in neoplasia. *Lancet* 1:1293, 1974.
31. Casazza AL, Duvall CP, Carbone PP: Infection in lymphoma. *JAMA* 197:710-716, 1966.
32. Cheever AW, Valsamis MP, Rabson AS: Necrotizing toxoplasmic encephalitis and herpetic pneumonia complicating treated Hodgkin's disease. *N Engl J Med* 272:26-29, 1965.
33. Young EJ, Killam AP, Greene JF Jr: Disseminated herpesvirus infection: Association with primary genital herpes in pregnancy. *JAMA* 235:2731-2733, 1976.
34. Naragi S, Jackson GG, Jonasson OM: Viremia with herpes simplex type I in adults. *Ann Intern Med* 85:165-169, 1976.

Lupus Mastitis

Russell B. Harris, MD, R. K. Winkelmann, MD, PhD

• Two patients with long-standing discoid lupus erythematosus developed tender, discrete breast nodules that, on the mammogram, were interpreted as carcinomas. The histologic features, direct immunofluorescence findings, and laboratory data confirmed the diagnosis of lupus mastitis. Antimalarial therapy resulted in the complete resolution of the lesions.

(*Arch Dermatol* 114:410-412, 1978)

Since Kaposi's original description of subcutaneous nodules in a patient with lupus erythematosus (LE) in 1883,[1] and Irgang's introduction of the term "lupus erythematosus profundus" into the English literature in 1940,[2] there has been an increasing awareness of nodular inflammation of the fat in LE. We present the clinical, diagnostic, and therapeutic problems in two well-documented cases of discoid LE (DLE), in which separate, deep, inflammatory lesions of the fat occurred within the breast.

REPORT OF CASES

CASE 1.—A 36-year-old black woman was first seen at the Mayo Clinic in January 1972. In 1956, abnormal findings on a chest roentgenogram and a positive purified protein derivative (PPD) reaction had led to her placement in a sanitarium, where she was treated for tuberculosis with pneumothorax, isoniazid, and streptomycin sulfate. In 1961, DLE had developed on the scalp and upper portion of the left arm; the diagnosis was confirmed by biopsy. From 1962 to 1969, she had been treated with intramuscularly administered steroids. In 1970, a tender lump had developed in the left breast. There was no history of trauma. The lesion developed fluctuation with severe pain. It opened and drained purulent material, and she was treated with antibiotics during the next two years. Although there had been intermittent improvement, the lesion did not heal.

Examination at our clinic revealed scarring and hypertrophic, keratotic, erythematous, telangiectatic, and nodular lesions of the scalp, with alopecia. An indurated, slightly erythematous area was observed at the left breast areola, with a 3-mm fistulous opening. Mammograms were interpreted as carcinoma of the breast (Fig 1). No palpable nodes were observed. The lesion was excised and was found to be consistent with LE panniculitis. Cultures showed *Propionibacterium*, *Streptococcus*, and *Proteus mirabilis* organisms. Acid-fast and fungus cultures were negative. A biopsy specimen of the scalp showed DLE. A study of the breast tissue by direct immunofluorescence revealed positive basement membrane immunofluorescence with IgM. The antinuclear antibody, LE clot test, rheumatoid factor, and VDRL were negative, and results of complement studies were normal. The sedimentation rate (Westergren) was 35 mm/hr. The patient received chloroquine hydrochloride from 1972 to 1974, and the breast lesion healed.

In 1975, the patient returned with disseminated DLE, signs and symptoms of a duodenal ulcer, and an active ulcer of the left breast. Because of the symptoms of duodenal ulcer, all medications, including the antimalarial agents, had been stopped in 1974. After the use of chloroquine had been discontinued, the scalp lesions progressed and the draining ulcer of the left breast recurred. The patient was hospitalized again and was given hydroxychloroquine sulfate (200 mg three times a day). Another mammogram was interpreted as being consistent with carcinoma. The hydroxychloroquine therapy, bed rest, and local use of 0.1% triamcinolone cream, three times a day, improved the patient's skin satisfactorily during her hospital stay. The antinuclear antibody test was positive (1:32 with a speckled pattern). The LE clot, rheumatoid factor, VDRL, and anti-nDNA tests were negative, and the findings from blood chemistry studies and immunoglobulin and cryoglobulin levels were normal. The hemoglobin level was 10.6 gm/100 ml. Upper gastrointestinal roentgenograms revealed duodenal and antral deformities. The patient was dismissed and was to continue treatment. She reported that the breast lesion had healed.

CASE 2.—A 70-year-old white woman had a 37-year history of DLE of the cheeks, forehead, neck, and shoulders, and she had been observed at the Mayo Clinic during most of this time. The diagnosis had been confirmed by a routine biopsy and by direct immunofluorescence, which demonstrated a band-like deposit of immunoglobulins and fibrin. The patient had intermittent anemia, with hemoglobin levels as low as 10.5 gm/100 ml. She had recurrent leukopenia, with a count of 2,600/cu mm. The sedimentation rate generally was more than 50 mm/hr (Westergren), and on one occasion, it was as high as 85 mm/hr. The antinuclear antibody reaction and the LE clot test were negative. Urinalysis showed intermittent urinary sediment associated with a urinary tract infection and positive urine cultures. The patient complained of intermittent fatigue and had an occasional joint swelling, which lasted for a short time. There were no periods of fever, Raynaud's phenomenon, or other systemic signs or symptoms. During a 20-year period the DLE had been completely controlled on numerous occasions by intermittent antimalarial therapy.

In 1969, a routine mammogram was interpreted as normal. In 1972, the patient complained of a tender area in the left breast, and mammography showed a tiny, benign-appearing nodule in the upper portion of the left breast. Palpation could not isolate the nodule, and a biopsy was not done. The lesion gradually disappeared during six months of observation. In March 1974, mammography disclosed an area of increased density in the upper portion of the right breast. The patient complained of

Accepted for publication March 2, 1977.

From the Department of Dermatology, Mayo Clinic and Mayo Foundation, Rochester, Minn.

Reprint requests to Section of Publications, Mayo Clinic, 200 First St SW, Rochester, MN 55901 (Dr Harris).

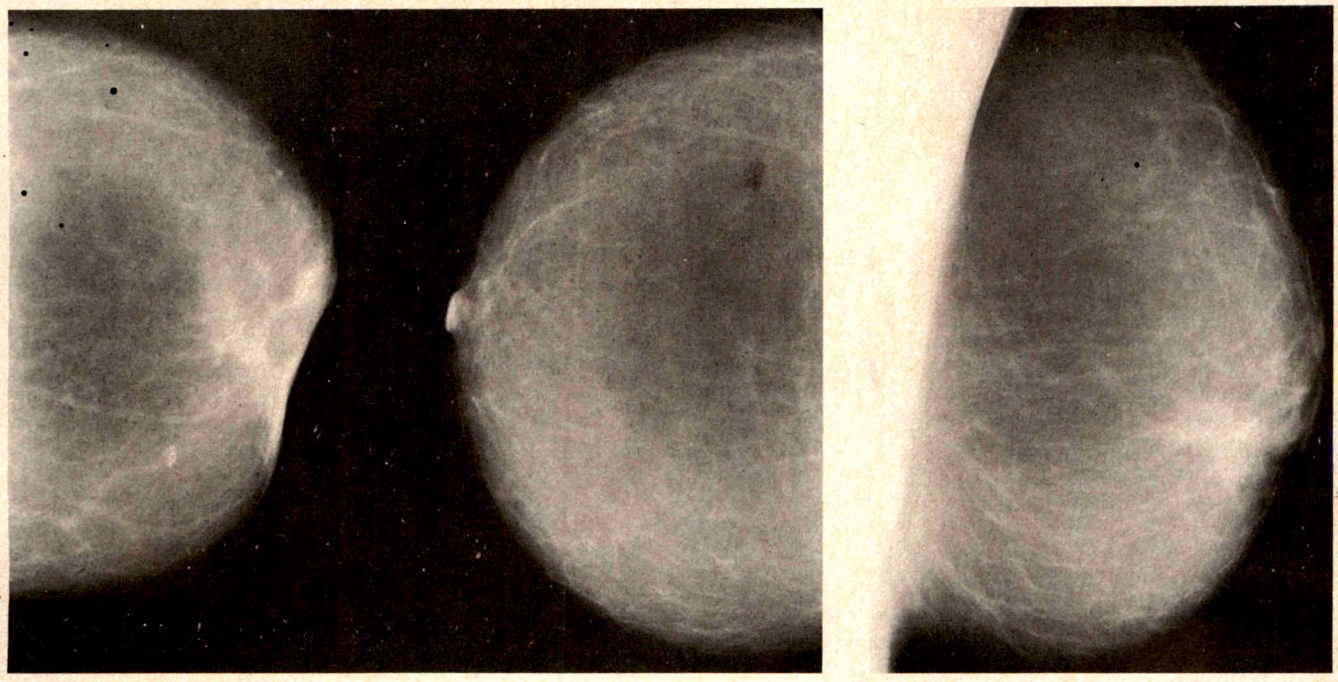

Fig 1.—Mammograms interpreted as carcinoma.

tenderness and discomfort in this region. The nodule was palpated at the most tender area within the deep substance of the breast tissue. At this time, antimalarial therapy was resumed with hydroxychloroquine sulfate (200 mg/day). The tenderness disappeared in one month, the nodule was less well-defined in two months, and the mammogram was normal in three months.

COMMENT

Sharply defined, subcutaneous nodules or swellings that may progress to chronic ulcers and that, when they resolve, may leave unique hyperkeratotic and atrophic scars, have been described by many authors[1-17] as being definite variants of both DLE and systemic lupus erythematosus (SLE). Greater clinical awareness and newer diagnostic aids have resulted in an apparent increase in the number of diagnoses made of LE panniculitis. In two large studies the incidence of patients with panniculitis appearing in either DLE or SLE was approximately 2%. In studies by Tuffanelli[5] of a series of 118 patients with DLE and 110 patients with SLE, six patients were found to have panniculitis; Díaz-Jouanen et al,[3] in a series of 270 patients with SLE, also found six patients with panniculitis.

Lesions of panniculitis can occur before, coincident with, or later than (as in our two case reports) the other lesions of LE, indicating that the pattern of inflammation can remain alone in the fat without SLE or cutaneous LE occurring for some time. In two of the three cases reported by Winkelmann[6] and in three of the six cases reported by Díaz-Jouanen et al[3] the panniculitis was the first sign of SLE. MacDonald and Feiwel[7] emphasized that panniculitis (including Weber-Christian panniculitis) is not nosologically distinct and that a search should be made for its etiologic factors. The patient should be observed for signs of an evolving reaction pattern, such as LE.

Because fat may be the primary site of inflammation in LE, the inflammation can be localized by the use of physical agents, such as heat, trauma, or cold, and by the use of drugs, such as iodides. One then might expect a chronic, lymphocytic, hyalinizing panniculitis in the patient who is likely to develop LE, rather than the polymorphonuclear leukocyte inflammation with necrosis of fat. Tuffanelli[5] noted that four of his six cases were associated with trauma.

Several authors[6,10,11,15] have noted the painful, chronic nature and the absence of the healing response in the ulcers associated with LE panniculitis. Removal of tissue for a biopsy often results in an enlarged, painful ulcer. This feature was well demonstrated in our first case report. Biopsy specimens in these cases of disease can show signs of chronic granulation and granuloma formation,[6] as well as LE panniculitis and DLE in the ulcer margin.

The conditions of both of our patients responded to low-dose, short-term antimalarial therapy, which supports the findings of many authors.[3,5,6,13,14,16,17] Jablonska et al[12] stated that the nodules respond dramatically to antimalarial agents, but not to corticosteroids. Winkelmann[6] described patients whose conditions required both steroids and antimalarial agents for healing.

MacDonald and Feiwel[7] and others[11] have indicated that whole-thickness or pedicle grafts can be used in treating the ulcers of LE panniculitis. Apparently, split-thickness skin grafts have not been successful.[18]

Immune complexes have been demonstrated by direct immunofluorescence in blood vessel walls in the active panniculitis lesions, and a band-like distribution has been found in the dermal-epidermal junction of sun-exposed uninvolved and involved skin.[19,20] The breast tissue from our first case report showed positive basement membrane immunofluorescence with IgM, and in both of our cases, positive skin immunofluorescence supported the clinical diagnosis.

Some authors[4,6] have stated that a microscopic diagnosis of LE panniculitis can be made in the absence of clinical epidermal changes. They believe that the pathologic pattern is unusual enough so that its combination of features would be suggestive of an unusual, chronic, inflammatory syndrome of the fat, such as LE. The inflammation of LE usually consists of lymphocytic foci about the dermal blood vessels, the adnexal structures,

or the fat. Hyalinization of the connective tissue of the dermis and septa of the fat lobules may be observed. This hyalinization can produce the eosinophilic, amorphous, fibrous masses in an edematous, mucoid, and inflammatory stroma, as has been emphasized by Fountain[4] and by Winkelmann.[6] Basophilic elastotic degeneration may be seen in the subcutaneous tissue, and there may be vasculitis involving the entirety of all the vessel walls, or a focal inflammation involving only one segment of the vein and large lymphatic vessel walls. In addition, masses of histiocytes can surround the necrobiosis of collagen, especially at the dermis-panniculus junction or in the fat lobules. These granulomas may show a palisading pattern similar to that seen in necrobiosis lipoidica or in rheumatoid nodules. Foci of calcification may be found in the dermis and in the septa of fat lobules; in one case,[6] the foci involved the hyalinizing vessel walls. If the epidermis is involved, it will show the usual features of hyperkeratosis, atrophy of the Malpighian layer, focal liquefactive necrosis of the basal layer, and features of the pilary complex.[21]

In both of our cases, the mammograms taken to aid in the diagnosis of the tender breast masses were interpreted as carcinoma, which was the reason for the first operation in case 1. There was no suggestion of inflammation. The dense, angular shadows produced by lupus mastitis are clearly part of the differential diagnosis of carcinoma by mammography. The histologic appearance and the response to treatment offer a means of resolving the diagnostic problem raised by mammography.

The diagnosis of lupus mastitis may be suggested by the appearance of a tender nodular breast mass in a patient with LE (either discoid or systemic). Other features to look for in diagnosing lupus mastitis are as follows: (1) a history and findings of LE, (2) a mammogram interpreted as carcinoma, (3) a biopsy showing LE and LE panniculitis, (4) a direct immunofluorescent band, and (5) responsiveness to antimalarial therapy. Laboratory tests, such as the antinuclear antibody test and LE clot test, may provide support for the diagnosis. The biopsy specimen shows a characteristic lymphocytic and hyalinizing panniculitis, and direct immunofluorescence shows immunoglobulins and complement at the dermal-epidermal junction. A biopsy should be avoided if possible, because a painful, chronic, inflammatory ulcerative lesion may result.

Nonproprietary Names and Trademarks of Drugs

Chloroquine hydrochloride—*Aralen Hydrochloride.*

Triamcinolone—*Aristocort Tablets, Kenacort, Aristopak.*

References

1. Kaposi M: Pathologie und Therapie der Hautkrankheiten, in *Vorlesungen für praktische Ärzte und Studirende,* ed 2. Wien, Austria, Urban & Schwarzenberg, 1883, p 642.
2. Irgang S: Lupus erythematosus profundus: Report of an example with clinical resemblance to Darier-Roussy sarcoid. *Arch Dermatol Syphilol* 42:97-108, 1940.
3. Díaz-Jouanen E, DeHoratius RJ, Alarcón-Segovia D, et al: Systemic lupus erythematosus presenting as panniculitis (lupus profundus). *Ann Intern Med* 82:376-379, 1975.
4. Fountain RB: Lupus erythematosus profundus. *Br J Dermatol* 80:571-579, 1968.
5. Tuffanelli DL: Lupus erythematosus panniculitis (profundus): Clinical and immunologic studies. *Arch Dermatol* 103:231-242, 1971.
6. Winkelmann RK: Panniculitis and systemic lupus erythematosus. *JAMA* 211:472-475, 1970.
7. MacDonald A, Feiwel M: A review of the concept of Weber-Christian panniculitis with a report of five cases. *Br J Dermatol* 80:355-361, 1968.
8. Arnold HL Jr: Lupus erythematosus profundus: Commentary and report of four more cases. *Arch Dermatol* 73:15-33, 1956.
9. Zweiman B, Tomar RH, Gross PR: Lupus erythematosus profundus following thrombocytopenic purpura. *Arch Dermatol* 111:347-351, 1975.
10. Klein SA, Tomaro AJ: Lupus erythematosus profundus: Review of the literature and report of a case. *J Oral Surg* 33:454-457, 1975.
11. Lupus erythematosus profundus. Baylor College of Medicine Resident Staff. *Arch Dermatol* 102:345, 1970.
12. Jablonska S, Chorzelski T, Stachow A: Lupus erythematosus profundus, in Pillsbury DM, Livingood CS (eds): *Proceedings of the 12th International Congress of Dermatology.* Excerpta Medica International Congress series 55, Amsterdam, Excerpta Medica Foundation, 1962, pp 698-700.
13. Thurston CS, Curtis AC: Lupus erythematosus profundus (Kaposi-Irgang): Clinical response to hydroxychloroquine sulfate. *Arch Dermatol* 93:577-582, 1966.
14. Cordero AA, Abulafia J, Woscoff A: Lupus eritematoso profundo (Kaposi-Irgang). *Prensa Med Argent* 54:1263-1268, 1967.
15. Epstein MT: Lupus erythematosus panniculitis. *Br J Dermatol* 85:292-294, 1971.
16. Dubois EL: *Lupus Erythematosus,* ed 2. Los Angeles, University of Southern California Press, 1974.
17. Fries JF, Holman HR: Systemic lupus erythematosus: A clinical analysis. *Major Probl Intern Med* 6:1-199, 1975.
18. Allison JH, Bettley FR: Rheumatoid arthritis with chronic leg ulceration. *Lancet* 1:288-290, 1957.
19. Kay DM, Tuffanelli DL: Immunofluorescent techniques in clinical diagnosis of cutaneous disease. *Ann Intern Med* 71:753-762, 1969.
20. Burnham TK, Fine G, Neblett TR: Immunofluorescent "band" test for lupus erythematosus: II. Employing skin lesions. *Arch Dermatol* 102:42-50, 1970.
21. Pinkus H, Mehregan AH: *A Guide to Dermatohistopathology,* ed 2. New York, Appleton-Century-Crofts, 1976.

Febrile Neutrophilic Dermatosis in Acute Myelogenous Leukemia

Sharon Smith Raimer, MD, W. Christopher Duncan, MD

• A 50-year-old woman with acute myelogenous leukemia on two occasions had fever and exquisitely tender, warm, erythematous, indurated to frankly bullous plaques on the face and upper extremities. Histologically, the lesions showed rather dense dermal infiltrates of mature polymorphonuclear leukocytes; special stains for bacteria and fungi were negative, as were all cultures for infectious agents. The lesions did not respond to antibiotics but cleared rapidly with systemic steroid treatment. Febrile neutrophilic dermatosis of acute myelogenous leukemia is believed to be a nonspecific reaction to the underlying malignant disease process. By prompt recognition of this entity, prolonged expensive courses of antibiotics may be avoided.

***(Arch Dermatol* 114:413-414, 1978)**

Acute febrile neutrophilic dermatosis was introduced to the dermatologic literature by Sweet[1] in 1964. Ninety percent of the cases have occurred in middle-aged women. Half of the reported cases have developed soon after a respiratory infection, lending support to the hypothesis that it is a hypersensitivity reaction.[1,2] Until a report by Matta et al[2] describing Sweet's syndrome in two patients subsequently found to have acute (type not specified) leukemia, there were no reports of associated systemic disease.

Recently, Klock and Oken[3] described three patients with acute myelogenous leukemia and adequate granulocyte reserves who developed fever and painful erythematous plaques studded with vesicles, which histologically showed a dense granulocytic infiltrate in the dermis, and who responded dramatically to corticosteroid therapy. Because of the resemblance to Sweet's syndrome,[1] the entity was referred to as "febrile neutrophilic dermatosis in acute myelogenous leukemia." A similar clinical picture in a young woman with acute myelogenous leukemia was described by Costello et al[4]; however, histologic examination disclosed infiltration by myeloblasts. We would like to describe an additional patient with acute myelogenous leukemia and cutaneous lesions resembling those described by Sweet.

REPORT OF A CASE

A 50-year-old woman who had acute myelogenous leukemia, successfully treated with numerous courses of chemotherapy since October 1974, was admitted to Ben Taub General Hospital in November 1975, with fever (40 C) and an exquisitely tender, warm, erythematous, indurated plaque in the right antecubital fossa, which subsequently developed superficial vesicles. She also had an erythematous, tender swelling around the right eye. Complete blood cell count at the time of admission was 2,200/cu mm, with 46% neutrophils, 5% myeloblast forms, and 49% lymphocytes.

A clinical diagnosis of cellulitis was made, and the patient received three weeks of parenteral antibiotic therapy, including penicillin G potassium, cephalothin sodium, carbenicillin, gentamicin sulfate, and nafcillin sodium. Cultures from blood, urine, blister fluid, and a skin biopsy for bacteria, acid-fast organisms, viruses, and fungi were negative. Daily temperatures continued to range from 38.9 to 40 C; the lesion on the arm increased in size and an additional plaque developed on the right side of the neck. A dermatology consultant suggested that the process was noninfectious and probably reactive, although its specific nature was not recognized. Histopathologic examination of a lesion demonstrated edema throughout the dermis, but most prominent in the papillary dermis, with a dense infiltration of mature polymorphonuclear leukocytes (Fig 1 and 2). Blood vessels were mildly dilated and the infiltrate had a slight perivascular predominance. Special stains for bacteria and fungi were negative.

Three weeks after admission, treatment with prednisone, 60 mg/day, was initiated. Twenty-four hours later the patient was afebrile, and five days later all lesions had cleared and the patient was discharged.

The patient had no recurrence of skin lesions until June 1976, when she again developed warm, tender, erythematous indurated plaques on the right hand and the left forearm and wrist (Fig 3 and 4). The plaques were edematous to frankly bullous and purpuric in areas. Nafcillin therapy was begun at the time of admission and continued for one week with worsening of the presenting lesions and development of new lesions on the flexor surface of the right wrist and right arm. Her temperature spiked daily to 40 C, although she felt relatively well.

Complete blood cell count showed a hemoglobin value of 8.8 gm/ml and 15,600 WBCs, with 74% myeloblasts, 20% neutrophils, 5% lymphocytes, and 1% monocytes. Cultures of the blood and vesicular fluid for bacteria were negative and a culture of a biopsy specimen from a skin plaque was also negative for bacteria, acid-fast organisms, and fungi. Histologic findings demonstrated a dense infiltrate of mature polymorphonuclear leukocytes, although a rare immature cell was present.

Prednisone, 60 mg/day, was initiated, with a decrease of her temperature from 40 to 36.3 within 24 hours. Chemotherapy with doxorubicin hydrochloride (Adriamycin), 6-thioguanine, and prednisone was begun at this time and she was discharged much improved one week later. Slightly hypopigmented, atrophic patches remain at the sites of the most severe cutaneous involvment.

COMMENT

The cutaneous lesions of acute myelogenous leukemia may be specific, showing true leukemic infiltrations, or nonspecific, referred to as leukemids. Specific skin lesions are most commonly purplish macules, papules, or tumors that rarely ulcerate or heal spontaneously.[4,5] Nonspecific skin manifestations frequently encountered include prurigo and petechiae, and hemorrhagic phenomena are present in fewer than 20% of patients with acute leukemia.[5]

In 1975, Perry and Winkelmann described three patients with "atypical" superficial bullous pyoderma gangrenosum, all of whom were later shown to have leukemia.[6] Histologically, the lesions showed dense polymorphonuclear leukocyte infiltration with edema and hemorrhage. In one of the three, necrosis of deeper tissues had occurred, although no evidence of blood vessel thrombosis was seen. The

Accepted for publication March 18, 1977.

From the Department of Dermatology, Baylor College of Medicine, Texas Medical Center, Houston. Dr Raimer is now with the Department of Dermatology, University of Texas Medical Branch, Galveston.

Reprint requests to Department of Dermatology, University of Texas Medical Branch, Galveston, TX 77550 (Dr Raimer).

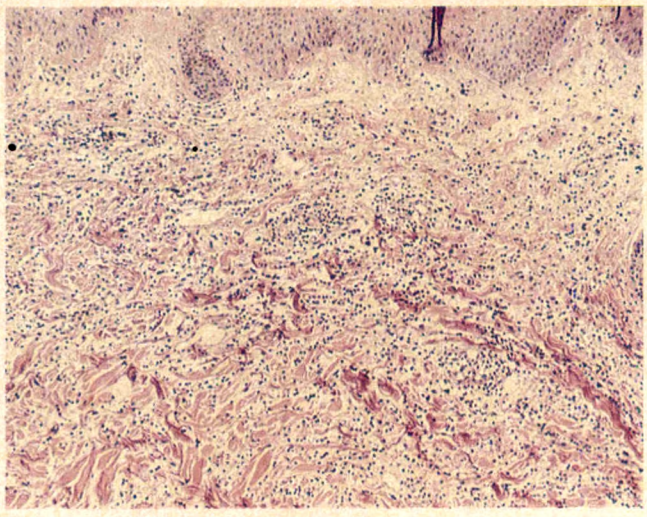

Fig 1.—Dense infiltrate of polymorphonuclear leukocytes throughout dermis (hematoxylin-eosin, original magnification ×86).

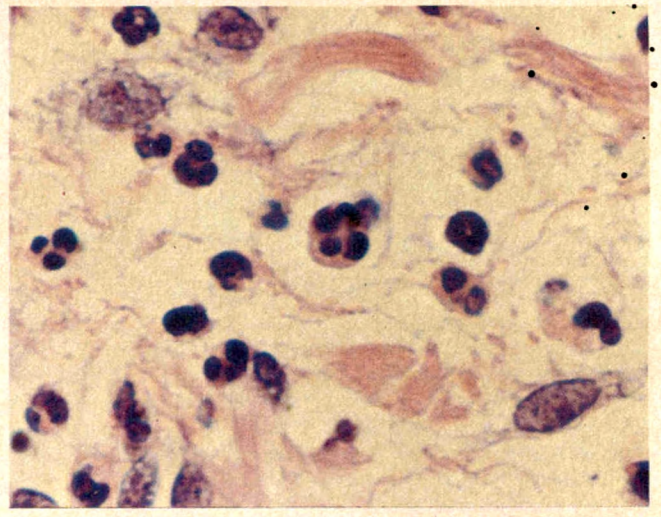

Fig 2.—Edema and infiltration of mature polymorphonuclear leukocytes between collagen bundles (hematoxylin-eosin, original magnification ×1270).

Fig 3.—Erythematous indurated plaque on wrist shortly after admission.

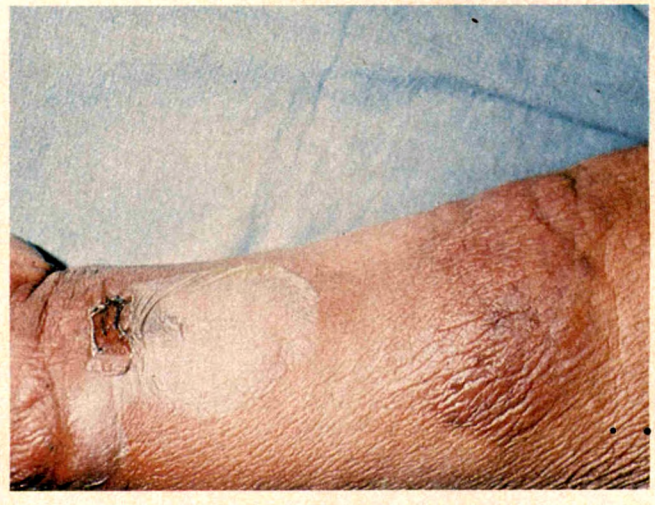

Fig 4.—Residual of large bulla over plaque on wrist and forearm with an adjacent nonbullous lesion.

lesions responded, though not dramatically, to corticosteroids and sulfapyridine.

The lesions of our patient and those reported by Klock and Oken[3] appear to be clinically and histologically identical. Clinically, the lesions are warm, painful, erythematous, indurated plaques that may reach a diameter of many centimeters without a central clearing. Most of the plaques develop vesicles or frankly bullous lesions on the surface. Patients are febrile, and although leukocytosis is not always present, they have adequate granulocyte reserves in spite of their acute myelogenous leukemia. In all four patients (five episodes) response to systemic corticosteroid treatment was dramatic.

Since the skin lesions are so consistent, it seems reasonable to assume that the eruption is a nonspecific reaction to the underlying acute myelogenous leukemia. Only one patient of Klock and Oken and our patient received treatment for acute myelogenous leukemia at some time prior to the appearance of the cutaneous lesions, so that chemotherapy as an etiologic factor can be ruled out. Despite extensive searches for an infectious agent, none was found. An upper-respiratory tract infection did not precede either of our patient's episodes, nor was it a factor in the patients described by Klock and Oken.

Acute neutrophilic dermatosis of acute myelogenous leukemia does appear distinctive enough that early treatment with corticosteroids should be considered to ameliorate the distressing symptoms in the patient in whom infection and specific leukemic infiltration have been ruled out. Biopsy is essential for diagnosis. Needless to say, prolonged, expensive courses of antibiotics may be avoided if this entity is promptly recognized.

References

1. Sweet RD: An acute febrile neutrophilic dermatosis. *Br J Dermatol* 76:349-356, 1964.
2. Matta M, Malak J, Tabet E, et al: Sweet's syndrome: Systemic associations. *Cutis* 12:561-565, 1973.
3. Klock JC, Oken RL: Febrile neutrophilic dermatosis in acute myelogenous leukemia. *Cancer* 37:922-927, 1976.
4. Costello MJ, Canizares O, Montague M III, et al: Cutaneous manifestations of myelogenous leukemia. *Arch Dermatol* 71:605-614, 1955.
5. Braverman IM: *Skin Signs of Systemic Disease*. Philadelphia, WB Saunders Co, 1970.
6. Perry HO, Winkelmann RK: Bullous pyoderma gangrenosum and leukemia. *Arch Dermatol* 106:901-905, 1972.

Cicatricial Pemphigoid and Rheumatoid Arthritis

G. Thomas Spigel, MD, R. K. Winkelmann, MD, PhD

• A review of our experience with cicatricial pemphigoid revealed three patients with cicatricial pemphigoid and rheumatoid arthritis and one patient with ankylosing spondylitis who had a high titer of rheumatoid factor. A comparison of these four patients with patients who had bullous pemphigoid and rheumatoid arthritis shows similarities between cicatricial pemphigoid and bullous pemphigoid in relation to the development of rheumatoid arthritis.

(*Arch Dermatol* 114:415-417, 1978)

Cicatricial pemphigoid is a subepidermal blistering and scarring disease of the mucous membranes and skin whose relationship to the usual bullous pemphigoid has been questioned. Bullous pemphigoid is a subepidermal blistering disease that rarely involves mucous membranes and that possesses circulating basement-membrane antibody. In both diseases, direct immunofluorescence of skin biopsy specimens of bullae may be positive for immunoglobulins and complement at the basement membrane, thus suggesting a pathogenetic similarity between these blistering diseases.

Accepted for publication March 29, 1977.

From the Department of Dermatology, Mayo Clinic and Mayo Foundation, Rochester, Minn.

Reprint requests to Section of Publications, Mayo Clinic, 200 First St SW, Rochester, MN 55901 (Dr Spigel).

Since the report of bullous pemphigoid and rheumatoid arthritis by Salo and Räsänen,[1] we have observed four patients with this association. We have also observed three patients with cicatricial pemphigoid who had rheumatoid arthritis, and one additional patient who had ankylosing spondylitis with a high titer of rheumatoid factor. These latter four cases (Table) provided an opportunity to review the pathogenesis and similarities of cicatricial pemphigoid and bullous pemphigoid associated with rheumatoid arthritis.

REPORT OF CASES

CASE 1.—A 56-year-old man was seen at the Mayo Clinic on June 5, 1950, with arthritis that had started in 1920 with swelling and stiffness and had become worse over the years, eventually involving the feet, ankles, shoulders, elbows, wrists, hands, and knees. He had ankylosis, or severe limitation of motion, as well as deformity of several peripheral joints. Three years before the patient was seen by us, an ulcer had developed in his throat, and two years prior to that an eye irritation had developed. An ophthalmologist had diagnosed "essential shrinkage of the conjunctivae with symblepharon of the right eye, with complete covering of the cornea, permitting only light perception and partial symblepharon of the left eye." An ear, nose, and throat consultation showed a grayish exudate on the posterior pharyngeal region that was initially considered to be a blister. Dermatologic consultation revealed "chronic pemphigus, a disease of the elderly," and a potassium arsenite (Fowler's) solution was recommended as treatment. Roentgenograms of the pelvis, hips, and knees showed evidence of old rheumatoid arthritis. The patient had severe rheumatoid arthritis and spondylitis.

CASE 2.—A 67-year-old woman was seen at our clinic on Aug 29, 1968, with a four-year history of arthritis that began in the right hand and subsequently involved nearly all her joints, except the temporomandibular and hip joints. The knees were most severely affected. Swelling and tenderness were noted at the sternoclavicular, wrist, metacarpophalangeal, proximal phalangeal, knee, and metatarsophalangeal joints. Morning stiffness of 1½ hours' duration was noted. Roentgenograms of the hands and wrists showed no abnormalities, but those of the knees showed degenerative changes with synovitis. The rheumatoid factor was positive at 1:640, the sedimentation rate was 49 mm/hr, and there was mild anemia. The patient had tearing, erythema, and matter in her left eye for five months and friable, bleeding gums for three months. An eye examination disclosed shortening of the conjunctiva, trichiasis, conjunctival injection, and a mucoid discharge compatible with cicatricial pemphigoid. The right eye was not involved. There was no dysphagia. A dermatologic examination showed a bulla on the right side of the hard palate. A biopsy specimen revealed a subepidermal bulla. A Tzanck smear was negative. Direct immunofluorescence performed on a biopsy specimen taken from a bullous lesion on the right side of the soft palate showed an antinuclear pattern (unspecified) in the epidermal cells at 1:80. Her serum antinuclear antibody titer was 1:160 (pattern unspecified). No indirect immunofluorescence was done on this initial visit. Prednisone therapy (40 mg/day) was prescribed for her cicatricial pemphigoid, and she returned to the clinic on Sept 19, 1972.

Four Patients With Cicatricial Pemphigoid and Associated Rheumatoid Arthritis or Spondylitis or Both					
		Mucosal or Skin Lesions			
Case/Sex/Age, yr	Duration of Arthritis, yr	Duration, yr	Location	Rheumatoid Factor	X-ray Films Indicative of Arthritis
1/M/56	30	3	Eyes, pharynx	...	Hips, pelvis, knees
2/F/67	4	5-12	Eyes, palate, gums	1:640, 1968 1:2,560, 1972	Hands, wrists, knees
3/M/80	Approx 2	Approx 1	Eyes	Negative	Hands, wrists
4/M/78	50	4	Eyes, cheeks, mouth, groin, perineum	1:1,280	Hips, pelvis, spine

Initially, she had done fairly well, and the prednisone dosage had been reduced gradually to between 5 and 15 mg/day shortly after she had left the clinic. This dosage was continued during the four-year period. However, she had had progressive involvement of her left eye, and a blepharorrhaphy had been performed elsewhere. Her friable, bleeding gums were unchanged over the years and the bullae on the hard palate had been particularly bothersome. An eye examination disclosed severe scarring of the fornices of the conjunctiva, and the blepharorrhaphy provided reasonable protection. The right eye was not involved.

A biopsy specimen of a palatal bulla showed a subepidermal bulla. Direct immunofluorescence performed on the biopsy specimen was negative for immunoglobulins or complement. The serum antinuclear antibody titer was mixed (not all nuclei in the test tissue show the same pattern) and positive at 1:64, and the rheumatoid factor was positive at 1:2,560. The sedimentation rate was 69 mm/hr. The prednisone dosage at that time was 5 mg in the morning and 2.5 mg in the afternoon. Therapy with azathioprine (100 mg/day) was started. Roentgenograms of the right hand and wrist showed soft-tissue swelling and degenerative changes, but the knees showed only degenerative changes. During the next four years, her arthritis remained stable, except for her knees, which became worse. She continued to have morning stiffness, and a subcutaneous nodule was found above her right elbow.

Case 3.—An 80-year-old man was seen on April 24, 1973, with a six-week history of swollen hands and minimal skin changes. He had a history of kidney cysts, ethanol abuse, carcinoma of the sigmoid colon, and diverticulitis (for which he had an anterior resection in 1970), and a 13-year history of a dermatitis that was considered to be a combination of photoallergic, contact, and irritant dermatitides. Roentgenograms of both hands and wrists showed severe soft-tissue swelling and some evidence of bony erosions that were strongly suggestive of rheumatoid arthritis. Roentgenograms of the shoulder were normal, and no other joints were examined roentgenographically. The rheumatoid factor was negative on two occasions. The patient had arthralgia of his shoulder, wrist, metacarpophalangeal, proximal phalangeal, knee, ankle, and metatarsophalangeal joints for approximately two years. Tenderness, limited mobility, and swelling were noted in these joints. He could not make a fist with either hand, and the right was more affected than the left. Small effusions were noted in both knees. He had sicca symptoms of his eyes and mouth for three years and was considered to have active rheumatoid arthritis, perhaps subclinically for several years, on the basis of bony changes that were seen on the roentgenogram. The sedimentation rate was 95 mm/hr. An eye examination disclosed changes consistent with Sjögren's syndrome, a symblepharon of the lateral canthus on the left eye, and mild trichiasis. Treatment consisted of acetylsalicylic acid and artificial tears. The arthritis remained controlled, but the patient had a one-year history of progressive problems in his left eye consisting of trichiasis (requiring electrolysis at another institution), redness, and irritability. An examination on June 5, 1974, showed minimal symblepharon and trichiasis of the right upper lid and symblepharon and trichiasis of both lids of the left eye, with vascularization of the cornea and a calcific corneal plaque. These findings were compatible with a diagnosis of cicatricial pemphigoid, and the patient underwent blepharoplasty.

Case 4.—A 78-year-old man was hospitalized on June 4, 1976, for investigation of a six-month history of progressive dysphagia and a two-year history of weakness. For the preceding four years, he had had blisters and erosions that had healed with scarring over both cheeks. For two years prior to his hospitalization, he had had oral and perineal erosions, and in 1975, erosions had developed in the right groin region. His history included an approximate 50-year history of rheumatoid spondylitis with involvement of the right hip, the knees, and the entire spinal column, atrial fibrillation, compensated congestive heart failure, adult-onset diabetes mellitus, and an upper gastrointestinal bleeding episode secondary to the use of indomethacin. Roentgenograms of his knees showed evidence of degenerative changes and chondrocalcinosis of the left knee. There was evidence of old rheumatoid arthritis of the right hip, with superimposed degenerative changes. The spinal column showed evidence of old rheumatoid spondylitis with severe, superimposed, degenerative changes and asymmetric involvement of the sacroiliac joints. The rheumatoid factor was positive at 1:1,280. A skin biopsy specimen from the left side of the groin and the face showed a subepidermal bulla. Direct immunofluorescence performed on biopsy specimens taken from the left side of the groin and the face was negative for immunoglobulins or complement. Indirect immunofluorescence showed an intercellular epidermal antibody up to a dilution of 1:40. An esophageal endoscopy was unsuccessful because of extreme strictures and hemorrhaging. Treatment consisted of 25 mg of prednisone orally, four times a day (which was decreased to 15 mg, four times a day), wet dressings, .05% triamcinolone acetonide cream, .05% fluocinonide gel, viscous 2.0% lidocaine hydrochloride, and nystatin oral suspension. The lesions in the mouth and skin healed, but the patient became dehydrated owing to poor oral intake, and suffered nonketotic hyperosmolar hyperglycemia, a urinary tract infection, and right lower lobe pneumonitis. He aspirated, had a cardiopulmonary arrest, and died in the hospital.

COMMENT

The literature that reviews the three largest series of cases involving cicatricial pemphigoid does not mention any presumed association among immunologic diseases.[2-4] An older series of nine cases also does not mention any such association.[5] On the contrary, bullous pemphigoid has been noted with rheumatoid arthritis,[1,6] systemic lupus erythematosus,[7] and polymyositis.[8]

Certain similarities exist between our four cases and the five cases of bullous pemphigoid with rheumatoid arthritis reported by Salo and Räsänen.[1] All five of their patients had arthritis for seven to 25 years before the bullous pemphigoid erupted. Our patients with cicatricial pemphigoid had arthritis from several years to 50 years before their skin diseases became apparent. Two of five patients in Salo and Räsänen's series had positive rheumatoid factor, whereas two of the three patients in our group in whom the determination was made also had positive rheumatoid factor.

It is interesting to speculate on the role of the rheumatoid factor in view of the finding by Salo and Räsänen[1] of a positive rheumatoid factor in five of nine blister fluids in pemphigoid. Unfortunately, the authors did not state whether these patients were the ones who also had arthritis. The obvious question concerns the rela-

tionship of rheumatoid factor to the formation of the basement-membrane antibody found in pemphigoid.

Rheumatoid factors are antibodies with specificity for antigenic determinants on the Fc portion of human or animal IgG.[9,10] They exist in the three major immunoglobulin classes, IgM, IgG, and IgA, but IgM (19S) is the most common.[11] When present in a large amount, this antibody can be detected as a 22S component composed of one molecule of rheumatoid factor and five molecules of IgG.[11] This interaction has all the characteristics of an antigen-antibody reaction, with rheumatoid factor as the antibody and IgG as the antigen.[11] The usual clinical tests for rheumatoid factor are agglutination procedures that utilize the RBCs of sheep sensitized with rabbit antisheep cell antibodies or inert particles (latex or bentonite) with human IgG adsorbed on their surfaces.[12] All of these systems detect the 19S IgM rheumatoid factor primarily because these molecules are very potent agglutinators. IgG rheumatoid factor may be detectable by other more sophisticated methods in the absence of IgM rheumatoid factor.[12] These factors enhance viral neutralization and phagocytosis, fix complement, stimulate chemotaxis, and activate the kinin system.[9] In addition, soluble immune complexes can be converted into complement-fixing aggregates by the addition of IgM or IgG rheumatoid factor.[12] This conversion may render the complexes more susceptible to phagocytosis. All of these properties of rheumatoid factor may have a role in the eventual release of potentially damaging lysosomal enzymes.[12]

Rheumatoid factor and immunoglobulins are found at the site of damage in rheumatoid arthritis, namely, the synovium, as well as in the synovial fluid, in other tissues damaged in the disease, and circulating in the blood.[9-13] Even in a patient with arthritis who had agammaglobulinemia and negative serum rheumatoid factor, minute amounts of rheumatoid factor and immunoglobulins had been found in the synovial fluid.[14] Seropositive rheumatoid arthritis is usually more severe and is associated with lower synovial, total hemolytic complement levels.[9,11,12] All this indicates that rheumatoid factor has some part in the pathogenesis of the disease. The current theory[9,11,12] is that an unknown antigen stimulates the production of IgG from the rheumatoid synovium. This IgG acts as an antigen for the production of rheumatoid factor. Why the IgG, a component of self, should be antigenic is uncertain; it may become antigenic only after reaction with its antigen.

Whether the presence of rheumatoid factor(s) in the serum or in the tissues for prolonged periods has anything to do with the production of antibasement-membrane antibody is speculative and remains unknown at present. An interesting theory is that it reacts with the basement membrane, resulting in an antigenic stimulus for the production of the antibasement-membrane antibody.

The early literature stated that cicatricial pemphigoid could be differentiated from bullous pemphigoid on the basis of negative direct and indirect immunofluorescence.[4,15-18] More recently, there have been reports of positive direct and indirect immunofluorescence studies in cicatricial pemphigoid,[19-29] thus making the complete separation of these two bullous diseases less definite, and the concept of a spectrum of the same disease more plausible. Both diseases may be considered immune-complex blistering diseases of the skin. Another unifying concept, which we believe is reported for the first time, is the association of cicatricial pemphigoid with rheumatoid arthritis. Now both of these subepidermal bullous disorders have been reported in association with the same immunologic disease. In rheumatoid arthritis, the production of immune complexes characterizes the disease process, and with an appropriate stimulus, an immune-complex blistering disease (pemphigoid and cicatricial pemphigoid) can occur.

Nonproprietary Name and Trademark of Drug

Azathioprine—*Imuran.*
Fluocinonide—*Lidex, Topsyn.*

References

1. Salo OP, Räsänen JA: Pemphigoid and rheumatoid arthritis. *Ann Clin Res* 4(suppl 9):173-177, 1972.
2. Lever WF: *Pemphigus and Pemphigoid.* Springfield, Ill Charles C Thomas Publisher, 1965, pp 103-118.
3. Shklar G, McCarthy PL: Oral lesions of mucous membrane pemphigoid: A study of 85 cases. *Arch Otolaryngol* 93:354-364, 1971.
4. Hardy KM, Perry HO, Pingree GC, et al: Benign mucous membrane pemphigoid. *Arch Dermatol* 104:467-475, 1971.
5. Benedict EB, Lever WF: Stenosis of the esophagus in benign mucous membrane pemphigus. *Ann Otol Rhinol Laryngol* 61:1120-1132, 1952.
6. Lillicrap DA: Rheumatoid arthritis and pemphigoid. *Proc R Soc Med* 56:921-922, 1963.
7. Jordon RE, Muller SA, Hale WL, et al: Bullous pemphigoid associated with systemic lupus erythematosus. *Arch Dermatol* 99:17-25, 1969.
8. Peck SM, Lefkovits AM: Bullous pemphigoid with polymyositis and co-existing contact dermatitis, abstracted. *Arch Dermatol* 94:672-674, 1966.
9. Stage DE, Mannik M: Rheumatoid factors in rheumatoid arthritis. *Bull Rheum Dis* 23:720-725, 1973.
10. Luthra HS, McDuffie FC, Hunder GG, et al: Immune complexes in sera and synovial fluids of patients with rheumatoid arthritis: Radioimmunoassay with monoclonal rheumatoid factor. *J Clin Invest* 56:458-466, 1975.
11. Primer on the rheumatic diseases. *JAMA* 224(suppl 5):662-812, 1973.
12. Zvaifler NJ, Robinson CA: Rheumatoid arthritis. *DM* May 1974, pp 2-56.
13. Fish AJ, Michael AF, Gewurz H, et al: Immunopathologic changes in rheumatoid arthritis synovium. *Arthritis Rheum* 9:267-280, 1966.
14. Barnett EV, Winkelstein A, Weinberger HJ: Agammaglobulinemia with polyarthritis and subcutaneous nodules. *Am J Med* 48:40-47, 1970.
15. Jordon RE, Beutner EH, Witebshy E, et al: Basement zone antibodies in bullous pemphigoid. *JAMA* 200:91-96, 1967.
16. Peck SM, Osserman KE, Weiner LB, et al: Studies in bullous diseases: Immunofluorescent serologic tests. *N Engl J Med* 279:951-958, 1968.
17. Jablonska S: Immunopathology of bullous diseases. *Ann Clin Res* 2(suppl 4):7-12, 1970.
18. Beutner EH, Chorzelski TP, Jordon RE: *Autosensitization in Pemphigus and Bullous Pemphigoid.* Springfield, Ill, Charles C Thomas Publisher, 1970.
19. Bean SF, Waisman M, Michel B, et al: Cicatricial pemphigoid: Immunofluorescent studies. *Arch Dermatol* 106:195-199, 1972.
20. Holubar K, Hönigsmann H, Wolff K: Cicatricial pemphigoid: Immunofluorescence investigations. *Arch Dermatol* 108:50-52, 1973.
21. Dantzig P: Circulating antibodies in cicatricial pemphigoid. *Arch Dermatol* 108:264-266, 1973.
22. Hood CI: Essential shrinkage of conjunctiva, chronic cicatrizing conjunctivitis, and benign mucous membrane pemphigoid. *Invest Ophthalmol* 12:308-309, 1973.
23. Bean SF: Cicatricial pemphigoid: Immunofluorescent studies. *Arch Dermatol* 110:552-555, 1974.
24. Bean SF: Cicatricial pemphigoid: A study of 15 cases. *South Med J* 67:1187-1190, 1974.
25. Herron BE: Immunologic aspects of cicatricial pemphigoid. *Am J Ophthalmol* 79:271-278, 1975.
26. Michel B, Thomas CI, Levine M, et al: Cicatricial pemphigoid and its relationship to ocular pemphigus and essential shrinkage of the conjunctiva. *Ann Ophthalmol* 7:11-20, 1975.
27. Dabelsteen E, Ullman S, Thomsen K, et al: Demonstration of basement membrane autoantibodies in patients with benign mucous membrane pemphigoid. *Acta Derm Venereol (Stockh)* 54:189-192, 1974.
28. Tagami H, Imamura S: Benign mucous membrane pemphigoid: Demonstration of circulating and tissue-bound membrane antibodies. *Arch Dermatol* 109:711-713, 1974.
29. Rogers RS III, Perry HO, Bean SF, et al: Immunopathology of cicatricial pemphigoid: Studies of complement deposition. *J Invest Dermatol* 68:39-43, 1977.

Monocytic Leukemia

Clinically Appearing as 'Malignant Reticulosis of the Skin'

Günter Burg, MD; Christian Schmoeckel, MD; Otto Braun-Falco, MD; Helmut H. Wolff, MD

• Enzyme cytochemical (hydrolytic enzymes for cell differentiation), immunocytologic (B and T lymphocyte differentiation), and electron microscopic studies of skin infiltrates facilitate the proper diagnosis of myelomonocytic and lymphoreticular proliferations. With use of these methods, the original clinical diagnosis of malignant reticulosis of the skin was corrected to monocytic leukemia in a 65-year-old woman. Because primary involvement of the skin preceded monocytosis of the blood, it was concluded that the cutaneous infiltrates in our patient resulted from proliferation of tumor cells in the skin rather than from homing of the cells to, or settling of the cells in, the skin.

(*Arch Dermatol* 114:418-420, 1978)

The term "malignant reticulosis of the skin"[1,2] has been used primarily as a clinical term to designate tumorous or plaque-like monomorphous infiltrates of the skin by atypical mononuclear cells.

It is the purpose of this study to show the usefulness of enzyme cytochemical and immunocytologic tests and electron microscopy in the diagnosis and differentiation of myelomonocytic and lymphoreticular proliferations in the skin.

Accepted for publication March 18, 1977.

From Dermatologische Klinik und Poliklinik der Ludwig-Maximilians-Universität München, Munich.

Reprint requests to Frauenlobstrasse 9, 8000 München 2, West Germany (Dr Burg).

REPORT OF A CASE

Over a period of six weeks, a 65-year-old woman developed multiple 2 to 3-cm, dome-shaped cutaneous tumors; the skin over them was taut but not ulcerated (Fig 1). There were no notable changes in the peripheral blood when these lesions appeared; a complete blood cell count showed 3,500/cu mm WBCs, differential cell counts within normal limits, and a hemoglobulin level of 12.9 gm/100 ml. Six months after the appearance of the skin lesions, the patient developed progressive leukopenia (2,000/cu mm) with a 20% monocytosis, yet there were no pathologic findings in the scans of liver and spleen. Results of protein electrophoresis, immunoelectrophoresis, and routine renal and liver function studies were all within normal limits. The bone marrow specimens removed from the iliac crest showed infiltration by polymorphous monocytic cells (Fig 2).

Some of the tumors were excised, and transient remission of other tumors was achieved by x-ray therapy (200) rads five times of soft rays. The patient developed progressive leukopenia and died nine months after the onset of the disease; permission for an autopsy was not granted.

MATERIALS AND METHODS

Biopsy specimens were taken from tumors, from clinically uninvolved skin, from an area where tumors had regressed following x-ray therapy, and from an allergic dinitrochlorbenzene (DNCB) test reaction. Tissue sections from normal persons were taken for control. With use of frozen sections the following enzyme cytochemical studies were performed: nonspecific esterases (α-naphthylacetatesterase and naphthol-AS-D-acetatesterase), naphthol-AS-D-chloracetatesterase, acid and alkaline phosphatase, peroxidase and leucine aminopeptidase. Viable single-cell suspensions were prepared from skin tumors and processed for B and T cell differentiation by means of surface markers and spontaneous rosette formation. Tissue specimens were prepared for electron microscopy. For epicutaneous sensitization and testing a DNCB ointment was used. Details on the methods applied are reported elsewhere.[3-8]

RESULTS

Enzyme Cytochemistry and Immunocytology

In clinically uninvolved skin, α-naphthylacetatesterase and napthol-AS-D-acetatesterase were detectable cytochemically in monocytic cells lying in close topographic connection with the blood vessels (Fig 3).

In lesions that appeared clinically as erythema, nodules, or large tumors, a progressive proliferation of cells throughout the layers of the corium cytomorphologically resembled histiocytes and monocytes; their enzyme cytochemical patterns were characterized by a high content of nonspecific esterases (naphthol-AS-D-acetatesterase, α-naphthylacetatesterase [Fig 4], and acid phosphatase) designating their monocytic character. Peroxidase and napthol-AS-D-chloracetatesterase could not be shown in these cells. However, these enzymes were abundantly present in monocytic cells of the peripheral blood. Surrounding the monocytic infiltrates was an accumulation of fibroblasts, characterized by positive alkaline phosphatase and leucine aminopeptidase reactions.

Neither B nor T lymphocyte surface markers could be detected in the single-cell suspension from homogenized tumors. In lesions where the tumor had regressed following x-ray

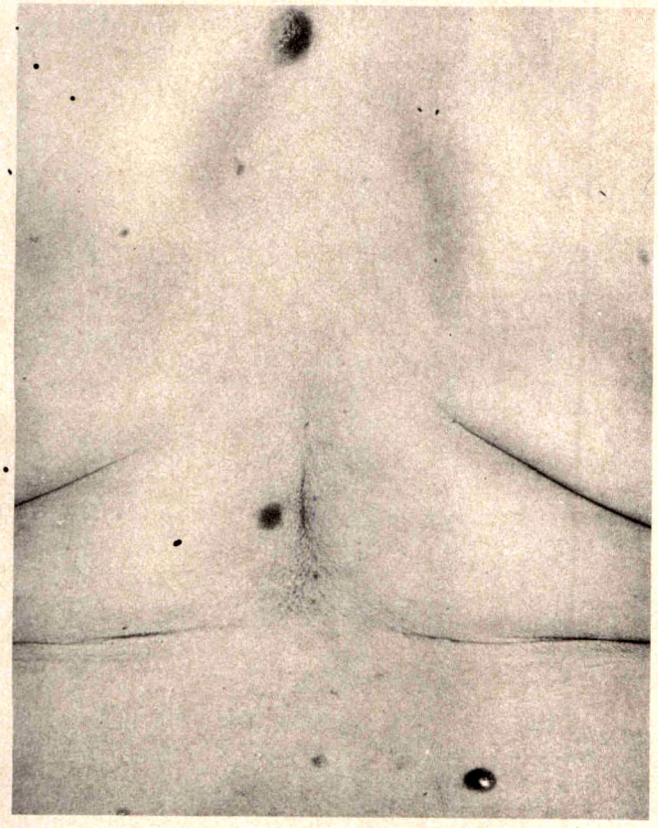

Fig 1.—Monocytic leukemia with specific skin infiltrates producing lesions that clinically resemble "malignant reticulosis."

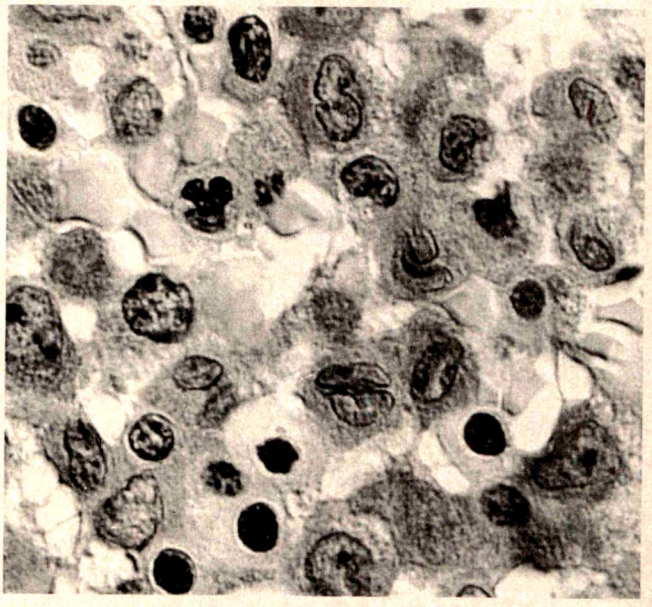

Fig 2.—Monocytic leukemia in bone marrow specimen. Note atypical monocytic cells (Giemsa, ×1,000 interference contrast).

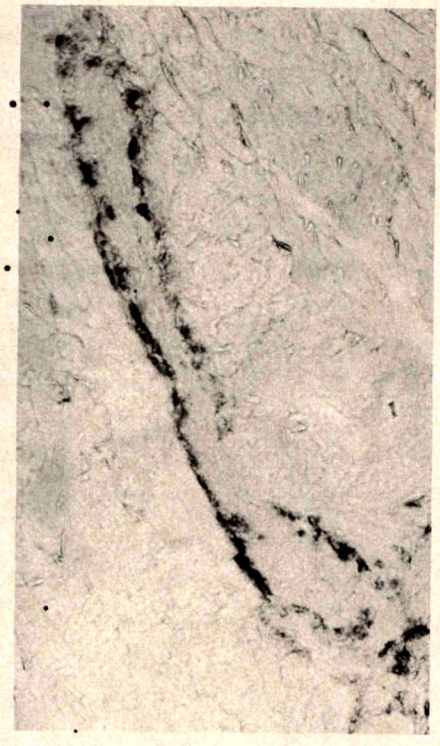

Fig 3.—Monocytic leukemia in clinically uninvolved skin, naphthol-AS-D-acetatesterase staining: positive enzyme reaction in cells near the wall of a blood vessel (×400 interference contrast).

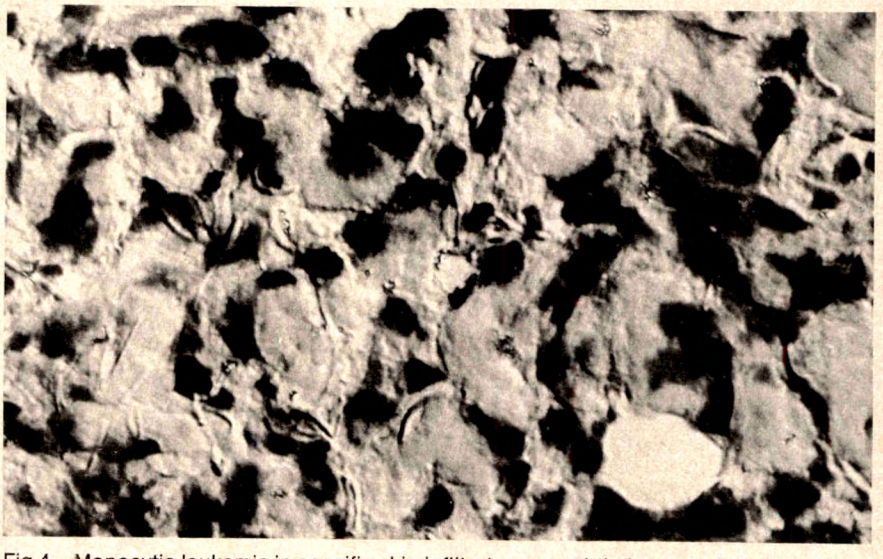

Fig 4.—Monocytic leukemia in specific skin infiltrates, α-naphthylacetatesterase staining: positive cells throughout the corium (×400 interference contrast).

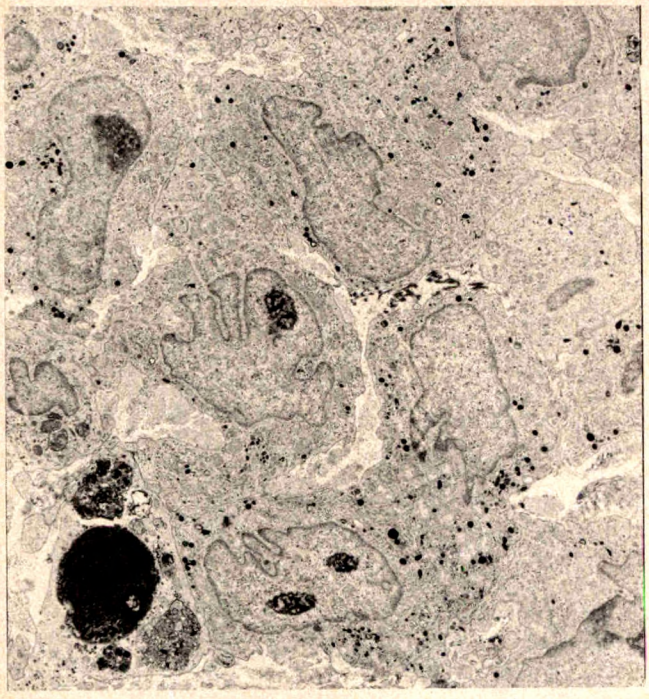

Fig 5.—Monocytic leukemia in tumorous skin infiltrate: monomorphous cells showing dense bodies and large phagosomes (bottom left) (×4,600).

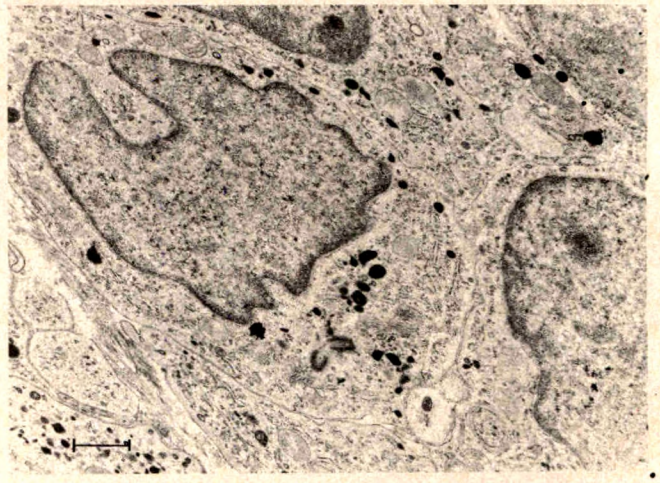

Fig 6.—Monocytic leukemia in tumor cell from skin infiltrate: characteristic granules (dense bodies), well-developed endoplasmatic reticulum with ribosomes, mitochondria, and a few Golgi complexes and centrioles (×9,600).

therapy, however, a few monocytic cells (nonspecific esterase positive) still remained near the blood vessels and adnexal structures.

The biopsy specimen taken from the positive allergic DNCB test reaction site showed typical histologic features[9]: predominantly lymphocytes (enzyme cytochemically negative) and a few monocytes (positive nonspecific esterase reaction). No leukemic infiltrates developed in the test area.

Electron Microscopy

Skin infiltrates showed monomorphous cells with a high cytoplasm-nucleus ratio and irregularly shaped nuclei with cytoplasmatic invaginations and prominent nucleoli. Within the cytoplasm were varying numbers of "dense bodies," as can be found in monocytes. In addition, phagosomes, endoplasmatic reticulum with ribosomes, mitochondria, and occasionally centrioles were found, as well as remarkable autophagosomes or heterophagosomes (Fig 5 and 6).

COMMENT

The clinical picture of lymphomatous skin infiltrates is polymorphous and not characteristic, and offers poor information about the nature and composition of cellular proliferations.[10] In monocytic leukemia, plaque-like infiltrates, nodules, or papules as well as large ulcerating tumors can be found.[11,12] In our patient the infiltrates were similar to those reported as characteristic of the so-called reticulosarcomatosis described by Gottron[13]: deep red tumors with taut glossy overlying skin. Recently, Klein and Ude[12] reported eight patients with myelomonocytic leukemias appearing as "malignant reticulosis or reticulosarcomatosis of the skin." This indicates that enzyme cytochemical, immunocytologic, and electron microscopic studies are important in facilitating the proper diagnosis of myelomonocytic and lymphoreticular proliferations in the skin.

The different enzyme pattern of the monocytic cells in the peripheral blood (peroxidase-positive) and in skin tumors (peroxidase-negative), the presence of tumor cells in the perivascular and periadnexal zones of clinically uninvolved skin, and the onset of skin lesions before the appearance of monocytosis in the peripheral blood provide some evidence that the cutaneous infiltrates in our patient resulted from proliferation of tumor cells rather than from homing of cells to, and settling of cells in, the skin.

Technical assistance was provided by E. Ebmeyer, F. Clauss, and I. Pfab.

E. Beil, MD, and R.H. Burkhardt, MD, Department of Medicine, Bone Marrow Unit, performed the analysis of bone marrow specimens in this patient.

References

1. Degos R, Ossipowsky B, Civatte J, et al: Réticuloses cutanées (Réticuloses histiomonocytaires). *Ann Dermatol Syphiligr* 84:125-152, 1957.

2. Gottron HA: Retikulosen der Haut, Gottron HA, Schönfeld W (eds): in *Dermatologie und Venerologie*. Stuttgart, G. Thieme, 1960, vol 4.

3. Burg G, Rodt H, Grosse-Wilde H, et al: Enzyme cytochemical and immunocytological studies as a basis for the revaluation of the histology of cutaneous B-cell and T-cell lymphomas, in Thierfelder S, Rodt H, Thiel E (eds): *Haematology and Blood Transfusion*. Berlin, Springer-Verlag, 1977, vol 20.

4. Burg G, Braun-Falco O: Morphological and functional differentiation and classification of cutaneous lymphomas. *Bull Cancer* 64:225-240, 1977.

5. Burg G, Braun-Falco O: Fortschritte in der cytochemischen Differenzierung von Infiltratzellen in der Haut. *Hautarzt* 25:1-8, 1974.

6. Burg G, Braun-Falco O: Cutaneous non-Hodgkin lymphoma: Revaluation of the histology using enzyme cytochemical and immunological studies. *Int J Dermatol*, to be published.

7. Wolff HH: Foreign cell acantholysis: Electron microscopic study on the pathodynamics of exocytosis. *Arch Dermatol Forsch* 247:145-160, 1973.

8. Burg G, Braun-Falco O: 1-Chlor-2,4-Dinitrobenzol (DNCB)-Salbe zur Sensibilisierung, Testung und Behandlung von Patienten mit malignem Melanom. *Dtsch Med Wochenschr* 102:210-211, 1977.

9. Braun-Falco O, Burg G: Histochemische und cytochemische Untersuchungen bei der allergischen DNCB-Kontaktdermatitis des Meerschweinchens. *Arch Klin Exp Dermatol* 239:307-322, 1970.

10. Petrozzi JW, Raque CJ, Goldschmidt H: Malignant lymphoma, reticulum cell type. *Arch Dermatol* 104:38-44, 1971.

11. Wohlenberg H, Griss P, Goos M, et al: Zur Zytochemie von Hautinfiltraten myelomonocytärer Leukämien. *Dtsch Med Wochenschr* 95:1439-1443, 1970.

12. Klein UE, Ude P: Monozytenleukämien mit ungewöhnlichem Erkrankungsverlauf. *Med Klin* 70:613-621, 1975.

13. Gottron E: Sogenannte Retikulosarkomatose der Haut. *Hautarzt* 2:42, 1951.

Primary Adenoid Cystic Carcinoma of Skin

John T. Headington, MD; Robert Teears, MD; John E. Niederhuber, MD; Robert P. Slinger, MD

• Two primary adenoid cystic carcinomas of skin were studied histologically and histochemically. Histologically, they closely resemble adenoid cystic carcinoma found in other tissues but in the skin must be distinguised from aggressive basal cell carcinomas. The natural history of these tumors and of those collected from the literature suggest a long indolent and progressive course. Local excision with meticulous histologic control of the surgical margins appears to be an appropriate therapeutic strategy. Thus far lymph node metastases have not been observed.

***(Arch Dermatol* 114:421-424, 1978)**

Adenoid cystic carcinoma is a histologically distinctive neoplasm most familiar to oncologists as arising in the major and minor salivary glands. Originally called cylindroma by Billroth,[1] this generic name was used for almost 100 years until the more specific term, adenoid cystic carcinoma, first used by Spies,[2] was popularized by Foote and Frazell[3] in 1953. Fortunately, this change in nomenclature was obviated dermatopathologic confusion with eccrine dermal cylindroma (turban tumor). Adenoid cystic carcinoma is now generally accepted terminology and is widely used.

Few malignant neoplasms have evolved a more predictable natural history than adenoid cystic carcinoma. Indolent yet relentlessly aggressive, infiltration of bones, fascial planes, and particularly the adventitia of nerves makes macroscopic demarcation of local growth very difficult. Local recurrence is frequently the result after attempted excision, while lymph node metastases are usually a late event. Most common in the major and minor salivary glands, adenoid cystic carcinoma has also been recognized in a number of other glandular tissues including the lacrimal[4] and ceruminous glands,[5] mucosal glands of the upper airway,[6] esophagus,[7] breast,[8] Bartholin glands of vulva,[9] the lower uterine cervix,[10] and prostate gland.[11]

Primary adenoid cystic carcinoma of the skin has been a very rarely reported neoplasm except in the integument of the external ear canal.[5] Only four clearly acceptable single cases in nonaural skin were found in a survey of the literature, including reports by Miller[12] (case 3), Stout and Cooley[13] (case 8), Lennox et al[14] (case 10), and Boggio.[15]

This report details the histology and histochemisty of two new examples of primary adenoid cystic carcinoma of the skin that are closely comparable to those found in other sites.

REPORT OF CASES

CASE 1.—A 60-year-old woman first noticed a pruritic area of the right frontoparietal scalp. Although treated with topical preparations, intermittent bleeding and crusting persisted. A biopsy diagnosis of primary adenoid cystic carcinoma of scalp was made nine years after the onset of local symptoms. She subsequently received two courses of x-ray therapy, but 15 months later the lesion recurred. When she was examined at the University of Michigan Medical Center, a 3 × 2-cm, firm, irregularly defined, relatively immobile, nontender dermal mass was fixed to the underlying tissue. There was some hair loss over the mass but no evidence of epidermal erosion. Regional lymph nodes were clinically normal. Skull roentgenograms and results of a complete examination of ears, nose, and throat were normal. The lesion was widely excised to the calvaria and a full-thickness graft placed in the defect.

The cut surface of the surgical specimen showed a focally thickened dermis with a somewhat discrete, firm, gray-white nodule 0.6 × 0.5 cm expanding the dermis and extending into the subcutis but not penetrating the galea aponeurotica. The patient is alive without evidence of disease six months after the excision.

CASE 2.—A 41-year-old woman first noticed a furuncle-like lesion in the skin of the left axilla that persisted after antibiotic treatment. Another examination done a few months later showed a firm deep-seated lesion in the axilla. Metastatic carcinoma from the breast was considered but results from examination of the breast, mammography, chest roentgenogram, and bone scan examinations were all normal. A biopsy done in another hospital six months after onset indicated an "infiltrative syringoma with adenoid cystic areas." Biopsy was followed by an attempt to surgically remove the tumor, which was found adherent to the brachial plexus and the latissimus dorsi muscle.

The surgical specimen showed a hard, gray-yellow mass 2.5 cm in diameter that extended to the deep margin of resection. Thirteen axillary lymph nodes were negative for metastatic neoplasm. The patient was subsequently treated by x-ray therapy and remains alive without evidence of disease 18 months after diagnosis.

MATERIALS AND METHODS

Specimens from cases 1 and 2 were fixed in a neutral buffered formaldehyde solution and embedded in paraffin. Serial and step-sections were stained with each of the following: hematoxylin-eosin, Wilder's reticulin, and Movat pentachrome.

Acid mucosubstances were studied by using Alcian blue (pH 0.4; 2.5), mucicarmine, colloidal iron, and PAS with and without diastase, hyaluronidase, and sialidase (neuraminidase) digestion.

Portions of the tumor immediately after removal from case 1 were flash frozen in isopentane chilled in liquid nitrogen. Sectioning was done in a cryostat at −15 C. Histochemical demonstrations on cover glasses were done according to standard controlled methods for succinic dehydrogenase, isocitric dehydrogenase, lactate dehydrogenase, phosphorylase brancher, adenosine triphosphatase, glucose-6-phosphate dehydrogenase, glucose-6-phosphatase, β-glucose aminidase, acid phosphatase, β-glucuronidase, nonspecific (indoxyl) esterase, and monoamine oxidase. Glycogen was evaluated by PAS staining with and without diastase digestion. Lipids were demonstrated with oil red O and Sudan black B preparations.

RESULTS

In case 1 the epidermis was thinned with flattening of rete ridges. Infiltrating neoplasm was accompanied by dermal fibrosis with partial loss of the normal structure of the reticular

Accepted for publication April 1, 1977.

From the Departments of Pathology (Drs Headington and Teears), Dermatology (Dr Headington), and General Surgery (Dr Niederhuber), University of Michigan Medical Center, Ann Arbor. Dr Slinger is now with St Joseph's Hospital, London, Ontario.

Reprint requests to Department of Pathology, 1335 E Catherine St, Ann Arbor, MI 48109 (Dr Headington).

Fig 1.—Case 1. Primary adenoid cystic carcinoma. Microcysts containing pale-staining mucin are lined by flattened cuboidal epithelium. There is fibrosis of the papillary dermis (hematoxylin-eosin, ×16).

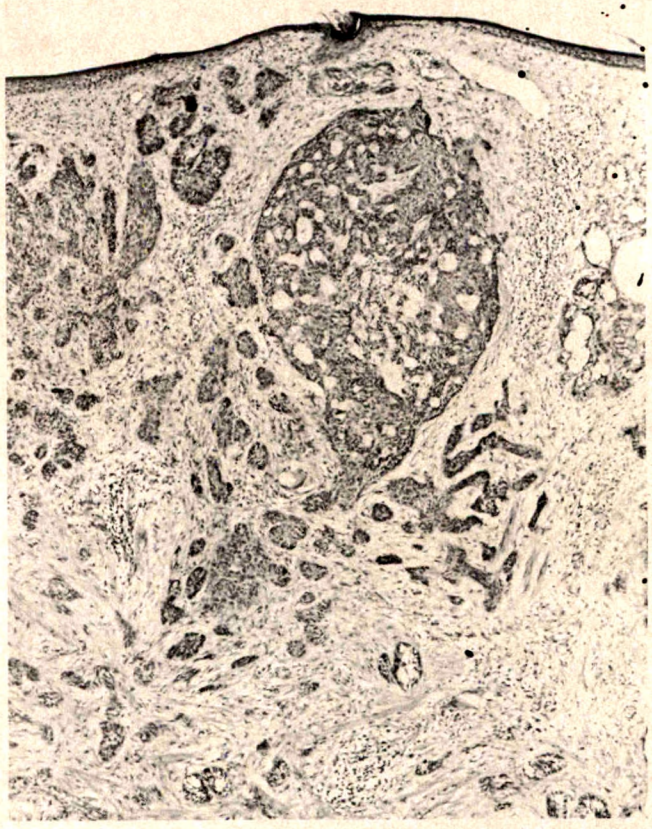

Fig 2.—Case 1. Primary adenoid cystic carcinoma. Another field from the same section shown in Fig 1 illustrates the highly variable histology. A large cribriform mass and many smaller separate epithelial islands simulate basal cell carcinoma (hematoxylin-eosin, ×16).

dermis. Solid and cystic sharply circumscribed round and oval islands of small deeply basophilic epithelial cells formed a diffuse plate-like infiltration of the dermis, except for a large central nodular mass extending into the subcutis (Fig 1, 2). Small cell masses were either solid or reticulated, while larger masses were cribriform or frankly cystic (Fig 3). There was occasional centripetal squamous transformation of small cystic masses with desquamation of loose, flaky keratin. Some epithelial islands were enclosed by very prominent hyalinized PAS-positive basement membranes, suggesting the pattern seen in dermal cylindroma. The extensive perilobular hyaline changes often seen in some adenoid cystic carcinomas in other sites were not observed in either case. Cysts and interstices of cribriform areas contained wispy pale-staining mucin. Coherent groups of tumor cells extensively infiltrated the perineural adventitia (Fig 4). There was a slight to moderate (1 to 2+) patchy lymphocytic infiltrate.

The histologic findings in case 2 were similar to those in case 1, with the exception that there was a deeper extension into the dermis and subcutis of axillary skin.

Cells in solid epithelial islands were cuboidal or low columnar (Fig 5); they became somewhat spindled or stellate when compressed by interstitial mucin. Cell borders were generally indistinct. With iron hematoxylin staining, nuclei showed a pattern of fine stippled chromatin and one or more small distinct nucleoli (Fig 6). Division figures averaged less than one per ten high-power fields. With high-intensity polarization microscopy, some solid cylindroid cellular islands were seen to contain parallel sheaves of birefringent filaments suggestive of tonofilaments.

Mucin histochemistry (Table 1) showed an acidic nonsulfated glycosaminoglycan consistent with hyaluronic acid. Frozen sections showed little mucin staining, but all reactions for mucin were enhanced in formaldehyde solution-fixed paraffin sections. The tumor mucosubstance was moderately carminophilic, colloidal iron-positive, and PAS-positive. It was moderately Alcian blue-positive at pH 2.5 but was negative at pH 0.4. It was resistant to sialidase (neuraminidase) but was readily removed by hyaluronidase digestion.

The results of enzyme histochemistry are shown in Table 2. Preparations for oxidative enzymes were strongly positive (3 to 4+). Only minimal and focal phosphorylase activity and glycogen deposition could be shown. Hydrolytic enzymes were negative or only weakly positive, except for a strongly positive (3+) reaction for acid phosphatase. Alkaline phosphatase was shown in vascular endothelium only. Glucose-6-phosphate dehydrogenase reactions were weakly (1+) positive. Only a small amount of sudanophilic lipid (1+) was found in tumor cell masses.

COMMENT

Morphologic studies have suggested that the intercalated duct of the salivary gland is the origin for adenoid cystic carcinoma in this organ.[16] In these ultrastructural studies of salivary gland tumors, both myoepithelial and secretory cells have been putatively demonstrated.[16,17] In addition, the elaboration of basement membrane material and the formation of tonofilamentous structures similar to

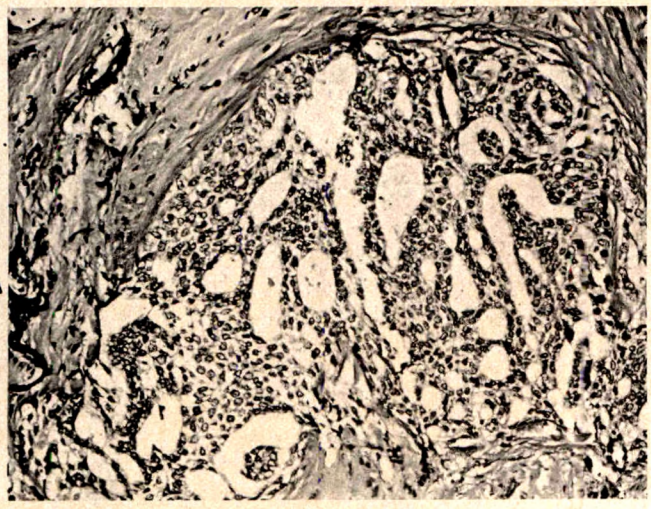

Fig 3.—Case 1. Primary adenoid cystic carcinoma. The cribriform pattern seen in this epithelium is typical for adenoid cystic carcinoma. Such tumor islands may or may not be membrane bound. Mucins do not stain intensely (Movat pentachrome, ×162).

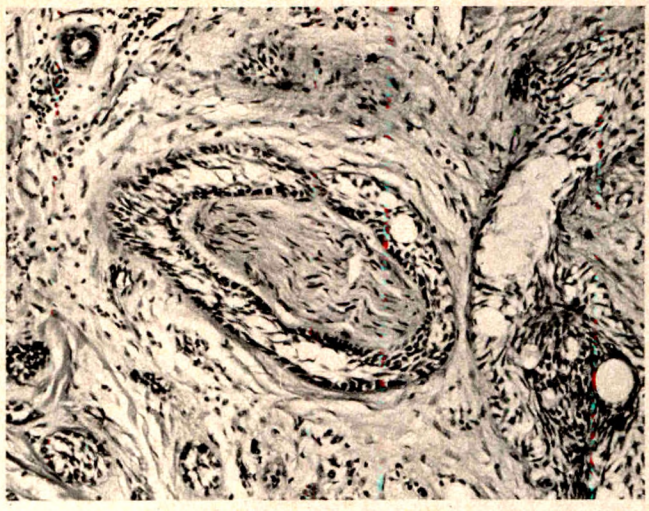

Fig 4.—Case 2. Primary adenoid cystic carcinoma. Adenoid cystic carcinoma characteristically infiltrates the perineural adventitia. Perineural infiltration was widespread in both cases (hematoxylin-eosin, ×162).

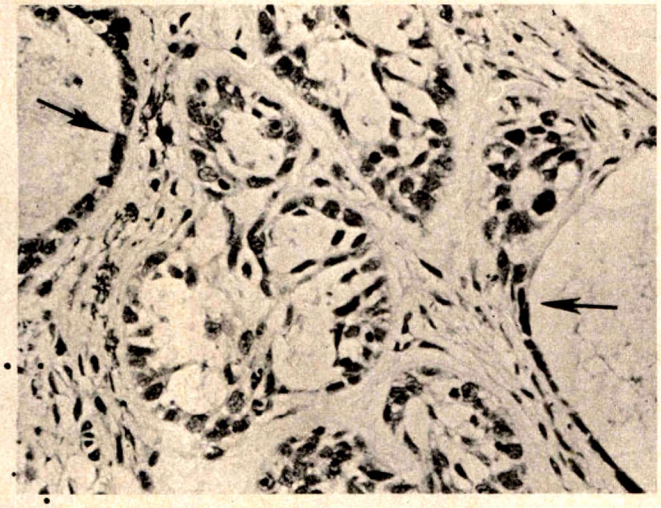

Fig 5.—Case 2. Primary adenoid cystic carcinoma. The accumulation of intercellular mucosubstances separates and compresses cells. This leads to the formation of small cysts (arrows) (Movat pentachrome, ×260).

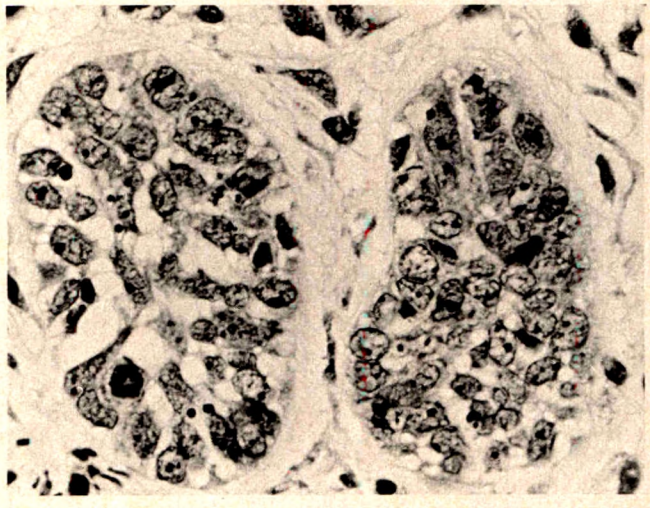

Fig 6.—Case 2. Primary adenoid cystic carcinoma. Cellular details show sharp nuclear outlines, variation in nuclear size, small distinct nucleoli, and indistinct cell borders (Movat pentachrome, ×406).

Table 1.—Primary Adenoid Cystic Carcinoma: Mucin Histochemistry

Preparation	Digestion	Reaction
PAS	...	3+
PAS-diastase	...	3+
Mucicarmine	...	3+
Alcian blue (pH 2.5)	...	2+
Alcian blue (pH 0.4)	...	0
Alcian blue (pH 2.5)	Sialidase	2+
Alcian blue (pH 2.5)	Hyaluronidase	0
Colloidal iron	...	3+

Table 2.—Primary Adenoid Cystic Carcinoma: Enzyme Histochemical Studies

Demonstration	Reaction
Phosphorylase	±
Glucose-6-phosphatase	0
Glucose-6-phosphate dehydrogenase	1+
Nonspecific esterase	0
Acid phosphatase	3+
β-glucose aminidase	±
β-glucuronidase	1+
Alkaline phosphatase	0
Succinic dehydrogenase	3+
Lactate dehydrogenase	2+
Isocitric dehydrogenase	3+
Monoamine oxidase	3+

Table 3.—Primary Adenoid Cystic Carcinoma: Summary of Six Cases

	Age, yr/Sex	Location	Duration
Stout and Cooley[13] (case 8)	52/F	Abdomen	8 yr
Miller[12] (case 3)	66/F	Arm	6 mo
Boggio[15]	66/F	Scalp	14 yr
Lennox et al[14] (case 10)	69/M	Nose	?
Present study (case 1)	60/F	Scalp	9 yr
Present study (case 2)	41/F	Axilla	6 mo

those seen in keratinocytes were found in some secretory-type cells. In the absence of ultrastructural studies of cutaneous neoplasms, it is not possible to delineate the participation of the myoepithelial cell in primary adenoid cystic carcinoma of skin but it is possible to show presumptive basement membrane formation, to document the occurrence of birefringent tonofibrils, and to characterize the epithelial mucin.

Adenoid cystic carcinomas from other sites apparently have in common the ability to form acid mucosubstances that are mostly hyaluronic acid.[18] Hyaluronic acid was also found as the predominant mucosubstance in these two cases. Occurrence of this tumor in the skin of the external ear canal[5,19] has suggested possible origin from modified apocrine glands (ceruminous glands) in this area. By implication, the apocrine glands in other cutaneous areas may be possible sites for origin, but this does not preclude an eccrine ductal contribution. Hyperplastic eccrine epithelium immediately adjacent to tumor lobules was observed by Boggio[15] and was also seen in case 1.

The enzyme histochemical profile of the adenoid cystic carcinoma studied in case 1 does little to clarify the problem of histogenesis. The relative absence of glycolytic enzymes does not enhance the view of possible eccrine ductal origin, but in a single sample it is not possible to know if this is typical for adenoid cystic carcinoma or is a matter of clonal variation. Moreover, for comparison we have not been able to find a report of an enzyme histochemical study of adenoid cystic carcinoma from any other site.

Although the histogenesis is uncertain, the combined histologic and histochemical findings do permit accurate recognition of primary adenoid cystic carcinoma of skin. Clearly separable types of sweat gland carcinomas with specific natural histories are beginning to emerge from the shrouded heterogeneous series and single case reports accumulated during the last two decades. Primary mucinous carcinoma,[20] malignant acrospiroma,[21] apocrine carcinoma,[22] and adenoid cystic carcinoma are four such distinctive neoplasms.

There is an indication from the cumulative series of six cases (Table 3) that a very long and indolent but progressive course may occur: 9 years in our case 1, 14 years in the case reported by Stout and Cooley, and 8 years in the case reported by Boggio. That metastases have not been detected in any of these cases does not suggest that such will not occur. Metastases from noncutaneous adenoid cystic carcinomas at prolonged intervals of 10 to 20 years or more after initial treatment have repeatedly been recorded, including one of Billroth's original cases. Wide local excision with meticulous histologic control of margins of resection is recommended.

Differentiation of adenoid cystic carcinoma from some primary mucinous carcinomas of skin can be difficult in routine preparations. This is particularly true when the epithelial islands of mucinous carcinoma are large and cribriform and when the usual sclerotic trabeculae frequently found in this neoplasm are inconspicuous. Simple mucin histochemistry resolves this problem: adenoid cystic carcinoma is associated with pale-staining hyaluronic acid while mucinous carcinoma forms dense sialomucins. Mucin histochemistry does not, however, separate adenoid cystic carcinoma from adenoid basal cell carcinoma as both these tumors may form pools of hyaluronidase-sensitive mucosubstances. In the latter instance, recognition of adenoid cystic carcinoma is based on the combined observations of lack of continuity with epidermis or hair sheath, some membrane-bound tumor lobules without palisading, and very prominent perineural infiltration. Problems in differential diagnosis may be intensified, however, if the oligomucinogenous, predominantly solid, basaloid and focally necrotic variant of adenoid cystic carcinoma, well known in some other organs, is considered a possibility of skin. The best indication for such a diagnosis might be the finding of a very highly aggressive "basal cell" carcinoma occurring in an unusual location, for example, scalp, axilla, groin, or perineum.

Because of the degree of histologic variation and the natural history of primary adenoid cystic carcinoma of skin are not yet fully determined, it is desirable that other examples of primary adenoid cystic carcinoma of skin be reported.

References

1. Billroth T: Beobactungen über Gerchwülste der Speicheldrüsen. *Virchow Arch Pathol Anat* 17:357-375, 1859.
2. Spies JW: Adenoid cystic carcinoma: Generalized metastases in three cases of basal cell type. *Arch Surg* 21:365-404, 1930.
3. Foote FW Jr, Frazell EL: Tumors of major salivary glands. *Cancer* 6:1065-1133, 1953.
4. Adam YG, Farr HW: Primary orbital tumors. *Am J Surg* 122:726-731, 1971.
5. Pulec JL, Parkhill EM, Devine KJ: Adenoid cystic carcinoma (cylindroma) of the external auditory canal. *Trans Am Acad Ophthalmol Otolaryngol* 67:673-694, 1963.
6. Enterline HT, Schoenberg HW: Carcinoma (cylindroma type) of trachea and bronchi and bronchial adenoma: A comparative study. *Cancer* 7:663-670, 1954.
7. Nelms CD, Luna MA: Primary adenocystic carcinoma (cylindromatous carcinoma) of the esophagus. *Cancer* 29:440-443, 1972.
8. Cavanzo FJ, Taylor HB: Adenoid cystic carcinoma of the breast: An analysis of 21 cases. *Cancer* 24:740-745, 1969.
9. Chamlian DL, Taylor HB: Primary carcinoma of Bartholin's gland. *Obstet Gynecol* 39:489-494, 1972.
10. Gallager HS, Simpson CB, Ayala AG: Adenoid cystic carcinoma of the uterine cervix. *Cancer* 27:1398-1402, 1971.
11. Frankel K, Craig JR: Adenoid cystic carcinoma of the prostate. *Am J Clin Pathol* 62:639-645, 1974.
12. Miller WL: Sweat-gland carcinoma. *Am J Clin Pathol* 47:767-780, 1967.
13. Stout AP, Cooley SGE: Carcinoma of sweat glands. *Cancer* 4:521-536, 1951.
14. Lennox B, Pearse AGE, Richards HGH: Mucin-secreting tumours of the skin: With special reference to the so-called mixed-salivary tumour of the skin and its relation to hidradenoma. *J Pathol Bacteriol* 64:865-880, 1952.
15. Boggio R: Adenoid cystic carcinoma of scalp. *Arch Dermatol* 111:793-794, 1975.
16. Hoshino M, Yamamoto I: Ultrastructure of adenoid cystic carcinoma. *Cancer* 25:186-198, 1970.
17. Hübner G, Kleinsasser O, Klein HJ: Zur Feinstruktur und Genese der Cylindrome der Speicheldrüsen: Weitere Untersuchungen zur Rolle myoepithelial differenzierter zellen der Speicheldrüsengeschwulste. *Virchows Arch* 347:296-315, 1969.
18. Azzopardi JG, Smith OD: Salivary gland tumours and their mucins. *J Pathol Bacteriol* 77:131-140, 1959.
19. Althaus SR, Ross JAT: Cerumen gland neoplasia. *Arch Otolaryngol* 92:40-42, 1970.
20. Mendoza S, Helwig EB: Mucinous (adenocystic) carcinoma of the skin. *Arch Dermatol* 103:68-78, 1971.
21. Johnson BL Jr, Helwig EB: Eccrine acrospiroma: A clinicopathologic study. *Cancer* 23:641-657, 1969.
22. Baes H, Suurmond D: Apocrine sweat gland carcinoma: Report of a case. *Br J Dermatol* 83:483-486, 1970.

Plane Xanthoma and Multiple Myeloma With Lipoprotein–Paraprotein Complexing

James S. Taylor, MD; Lena A. Lewis, PhD; John D. Battle, Jr, MD; Antanas Butkus, PhD; Abel L. Robertson, MD, PhD; Sharad Deodhar, MD, PhD; Henry H. Roenigk, Jr, MD

• Clinicopathologic findings are reported of a woman with generalized plane xanthoma, multiple myeloma (IgG type K), and hyperlipemia with very high levels of serum cholesterol and triglyceride. Complexing of the serum lipoproteins and immunoglobulins had cryoglobulin properties and was separable by ultracentrifugation. Immunofluorescent studies of skin and bone marrow demonstrated deposits of IgG with low density lipoprotein apoprotein and IgG with β-lipoprotein, respectively. Although immunosuppressive therapy resulted in return of serum IgG, lipid, and lipoprotein levels to normal, the patient died from the myeloma. Serum lipoprotein-paraprotein complexes have been demonstrated in at least 20 other cases of cutaneous xanthomatosis and myeloma. This interaction may result in an autoimmune hyperlipemia.

(*Arch Dermatol* 114:425-431, 1978)

The association of xanthomatosis with paraproteinemia, although rare, is now an established clinical entity.[1,2] Most of the xanthomatous lesions are cutaneous with at least two cases of visceral and/or cutaneous xanthomas reported.[3,4] Most of the paraproteinemias have occurred in patients with multiple myeloma, cryoglobulinemia,[2] and secondary or primary benign paraproteinemias, as defined by Michaux and Heremans.[5] The serum lipid levels in multiple myeloma are generally low.[6] Most patients with myeloma with xanthomatosis have been hyperlipemic,[1,2] but at least five[7-10] were normolipemic. Studies of more than 20 cases of multiple myeloma and xanthomatosis make little or no mention of complexing of serum paraproteins and lipoproteins.[11] Hyperviscosity is mentioned only infrequently.

Accepted for publication April 13, 1977.

From the Departments of Dermatology (Drs Taylor and Roenigk), Hematology and Medical Oncology (Dr Battle), Immunopathology (Dr Deodhar), and the Research Division, Cleveland Clinic Foundation and Cleveland Clinic Educational Foundation (Drs Lewis, Butkus, and Robertson). Dr Robertson is now at Case Western Reserve University Medical School, Cleveland.

Read in part before the Section of Dermatology, American Medical Association annual meeting, New York, June 25, 1973.

Reprint requests to Department of Dermatology, Cleveland Clinic Foundation, 9500 Euclid Ave, Cleveland, OH 44106 (Dr Taylor).

The purpose of this discussion is to report the results of studies on a woman with generalized plane xanthoma (GPX), multiple myeloma, and hyperlipoproteinemia who had a "pseudomacroglobulinemia" and hyperviscosity of plasma. Plasma lipoproteins were bound with the abnormal immunoglobulin and they migrated together during electrophoresis to the γ-globulin position. It is postulated that this complexing may be an immune reaction. The treatment of these so-called autoimmune hyperlipidemias is discussed.

Previously reported cases of cutaneous xanthomatosis associated with multiple myeloma, which demonstrate this unique binding, are summarized in Table 1.

REPORT OF A CASE

A 69-year-old white woman was first seen at the Cleveland Clinic in June 1967 due to recent anemia of unknown cause, headaches, fatigue, and nervousness. She also noted a progressive generalized yellow pigmentation of her skin that had begun about four years earlier as yellowing of her palmer creases. System inquiry disclosed moderate dyspnea on exertion, light headedness, and lumbosacral pain.

There was no family history of diabetes mellitus, hyperlipemia, xanthomatosis, carcinoma, or myeloma. Results of serum lipid and lipoprotein studies on her two sisters and brother were normal for their age.

On physical examination the skin was a remarkably diffuse yellowish-orange with conspicuous involvement of the palmar creases. The eruption was maculopapular and was generalized, excluding only her lower legs and feet. There was no jaundice, and the sclerae were white. There were no xanthelasma, tendinous, tuberous, or papuloeruptive xanthomas. There was moderate pallor of the skin and mucosa. The remainder of the physical examination findings were normal.

Initial laboratory values showed the urinalysis to be normal; hemoglobin was 9.5 gm/100 ml; the cell volume was 29; and leukocyte count was 4,000 cu mm, with a normal differential cell count. Rouleaux formation was conspicuous. The platelet count was 220,000 cu mm. Red blood cells appeared normochromic and normocytic. Bone marrow examination showed a substantial increase in plasma cells with many plasmablasts and immature plasma cells. Additional studies disclosed a serum viscosity of 21.6 (normal, 1.5 to 2.0). Serum protein electrophoresis demonstrated a sharp γ-globulin spike and 4.6 gm/100 ml γ-globulin; 1.1 gm/100 ml β; 1.0 gm/100 ml α_2; 0.5 gm/100 ml α_1; and 2.3 gm/100 ml albumin. Cryoglobulins, which precipitated between 18 C and 20 C, were observed.

Serum immunodiffusion and electrophoresis for immunoglobulins showed 2,800 mg/100 ml IgG, 45 mg/100 ml IgA, and 24 mg/100 ml IgM. Typing of the γ-globulin proved it to be IgG type K light chain. Immunofluorescent study of the bone marrow showed scattered plasma cells reacting against IgG and β-lipoprotein antisera. Results from the remaining screening laboratory studies were essentially within normal limits.

A skin biopsy specimen of xanthoma showed the epidermis to be hyperkeratotic with effacement of the epidermal rete ridges. The dermis showed scattered collections of lipid-laden foam cells and a mild perivascular lymphocytic infiltrate. There were a few Touton-type giant cells.

Table 1.—Summary of Cases of Cutaneous Xanthomatosis

Reference	Sex/Age, yr	Myeloma Type	Cholesterol	Triglycerides	Total Lipids
1 Lennard-Jones (1960)[45]	F 65	↑ β-globulin	830	1,000	NS
2 Levin et al (1964)[46]	M 58	↑ γ-globulin	303	1,709	NS
3 Neufield et al (1964)[47]	M 45	↑ β-globulin	1,190	NS	NS
4 Aubert et al (1967)[36]	M 62	IgA	770-1,120	430-1,350	2,580-3,450
5 Kayden et al (1962)[48]	M 40	IgG	↑	NS	↑
6 James & Harland (1968)[43]	F 39	IgA	1,379	1,759	NS
7 Beaumont et al (1965-1967)[37, 49-55]	M 57	IgA	590	260	1,530
8 Heremans (1960)[56]	NS	B2A	480-980	NS	4,500
9 Heremans (1960)[56]	NS	B2A	NS	NS	2,000-2,800
10 Perrault et al (1971)[34]	F 53	IgG	400	NS	NS
11 Beaumont (1968)[37]	M 59	IgA	410-990	170-1,440	NS
12 Beaumont et al (1970)[40]	M 57	IgA anti-Lp PG	770	430	NS
13 Beaumont et al (1970)[40]	M 62	IgA anti-Lp PG	400-900	180-400	NS
14 Beaumont et al (1970)[40] (1969)[57]	F 52	IgG anti-Lp AS	360	400	NS
15 Beaumont et al (1969)[57]	NS	IgG	↑	Normal	NS
16 Beaumont (1969)[57]	NS	IgG	↑	Normal	NS
17 Beaumont (1969)[57]	NS	IgG	↑	↑	NS
18 Beaumont (1969)[57]	NS	IgG	↑	Normal	NS
19 Marien & Smeenk (1975)[20]	F 62	IgG	485	228	1,427
20 Wilson et al (1975)[41]	M 75	IgG	145-155	35-170	Normal
21 Taylor et al (1977)	F 69	IgG	790	1,120	2,145

* Antilipoprotein indicated by anti-Lp; not specified, NS; generalized plane xanthoma, GPX; paper electrophoresis, PE; and ultracentrifugation, UC.
† Oral communication, H. J. Kayden, MD, January 1971.

METHODS AND MATERIALS

Serum Lipoproteins

Lipoproteins were separated from the serum in the preparative ultracentrifuge at a density of 1.063 and 1.21.[12] The concentrate from the top of the ultracentrifuge tube was studied in the analytical ultracentrifuge[12] by paper electrophoresis with albuminated buffer[13] or starch-gel[14] and by immunoelectrophoresis. The cryoglobulin was separated by centrifugation in a refrigerated centrifuge, and repeatedly washed with cold 0.9% NaCl. It was then dissolved by warming to 20 C and subjected to ultracentrifugation at d 1.21 to separate the lipoprotein and immunoglobulins. Lipoprotein concentrate and subnatant fractions were studied by immunoelectrophoretic and ultracentrifugal techniques.

Lipid Composition of Xanthoma and Plasma

Xanthomatous skin was taken by punch biopsy with the patient under anesthesia. It was processed and lipids were extracted and analyzed as previously described.[15,16]

Immunofluorescent Studies With Skin and Cell Cultures

Frozen skin specimens and primary cell cultures of the patient's xanthomatous and normal skin as well as xanthomas from patients without myeloma were studied by direct immunofluorescence with use of antisera to IgG, IgA, low- and high-density lipoproteins, and fibrin. Skin cell cultures were incubated with autologous or homologous sera for three to six hours before testing.[17]

RESULTS

Serum Lipoproteins

Initial analysis showed total serum lipid levels were 2,145 mg/100 ml; total cholesterol, 790 mg/100 ml; and triglycerides, 1,120 mg/100 ml.

The paper electrophoretic pattern

Multiple Myeloma Demonstrating Serum Lipoprotein-Paraprotein Complexing*

Hyperviscosity	Type of Cutaneous Xanthoma	Cryoglobulins	Myeloma Bone Involvement	How Lipoprotein-Paraprotein Complexing Demonstrated	Complex Separated?	Other
NS	GPX	NS	+	PE staining UC	Yes, by UC	...
NS	GPX	NS	0	PE staining immunoelectrophoresis	Yes, by UC; readily separated; complex very weak	Also visceral xanthomatosis
NS but treated	GPX	NS	+	PE staining	NS	Abnormal lipoprotein is produced by plasma cells
+	GPX	None	+	Starch gel electrophoresis	Yes, by agar gel double diffusion	Anti-β-lipoprotein auto-antibody demonstrated
NS	GPX†	NS	NS	Starch zone electrophoresis	Yes, by UC	Recombination of complex in vitro
+	GPX & papuloeruptive	NS	0	"Immunoassay"	No	...
"Serum very viscous"	Tuberous xanthoma, disseminated papules, & xanthelasma	NS	NS	PE staining	Yes	Anti-β-lipoprotein auto-antibody demonstrated
NS	NS	NS	+	PE staining	Yes, by UC	Authors believe that migration of B2A and lipoprotein represented a simple absorption of B2A lipoprotein
NS	NS	NS	+	PE staining	Yes, by UC	See case 8 above
NS	GPX	NS	NS	PE staining immunoelectrophoresis	Yes, by UC	Multiple myeloma diagnosed 5 yr after GPX found
NS	GPX tendinous, tuberous	NS	NS	PE staining; chromatography; ultracentrifugation	Yes?	Multiple myeloma diagnosed 3 yr after high cholesterol-IgA found
NS	NS	NS	+	PE staining; hemagglutination	Yes, by electrophoresis	...
NS	NS	NS	+	PE staining; hemagglutination	Yes, by chromatography	...
NS	NS	NS	+	PE staining; hemagglutination	Yes, by ultracentrifuge	...
NS	GPX	0	NS	NS	NS	Sera studied by details concerning patients not given
NS	GPX	+	NS	NS	NS	Sera studied but details concerning patients not given
NS	NS	0	NS	NS	NS	Sera studied but details concerning patients not given
NS	GPX	0	NS	NS	NS	Sera studied but details concerning patients not given
NS	GPX	0	+	Immunoelectrophoresis	NS	...
0	GPX	+	0	Immunoelectrophoresis; UC	Yes, by UC	...
+	GPX	+	+	PE staining	Yes	...

of serum lipoproteins initially demonstrated a sharply defined lipid-stained band of 4+ intensity in the γ-globulin position, slightly behind that of the usual chylomicron, 2+ β-lipoproteins, and ± pre-β and α-lipoproteins (Fig 1). Normal levels by this grading system are chylomicrons, ±; beta-lipoproteins, 2+ to 3+; pre-β-lipoprotein, ±; and α-lipoprotein, 2+ to 3+.[18]

The initial ultracentrifugal sedimentation pattern of the patient's serum showed 32% 38 S_{20}° and 18% 19 S_{20}° macroglobulins with 9% 7 S_{20}° globulins and 41% 4 S_{20}° albumin and low-molecular-weight globulins.

Ultracentrifugal analysis for serum lipoprotein at 1.21 dynes showed exceptionally high concentrations of very low density lipoproteins (VLDL) similar to pre-β-lipoprotein, and low density lipoproteins (LDL) and a low concentration of α or high density (-S 0-10) lipoproteins: -S 70 to 400 (1,080 mg/100 ml), -S 40 to 70 (260 mg/100 ml), -S 25 to 40 (300 mg/100 ml), -S 1 to 10 (108 mg/100 ml), respectively. The VLDL and LDL proteins were not clearly separated. With ultracentrifugation at high salt concentration of d 1.063 or d 1.21, the complex of lipoprotein-immunoglobulin was broken with

Table 2.—Comparison of Lipid Composition of Xanthoma and Plasma in GPX*

	Lipid Composition of Plane Xanthoma (% of Total)					Palmitic Acid (% of Total FFA)	
	CE	FC	TG	FFA	PL	Xanthoma	Plasma
Normal skin	0.2	0.8	96.3	1.1	1.5	32.1	32.5
Present case	39.4	15.9	21.2	1.9	21.6	17.9	19.6
Kodama et al[19]	82.7	4.2	3.2	2.5	7.4	62.4	40.1
Marien et al[20] Yellow skin	37.0	6.0	43.0	2.0	12.0	NS	NS
Papule	30.0	10.0	39.0	4.0	17.0	NS	NS

* Not specified indicated by NS; cholesterol ester, CE; free cholesterol, FC; triglyceride, TG; free fatty acids, FFA; and phospholipid, PL.

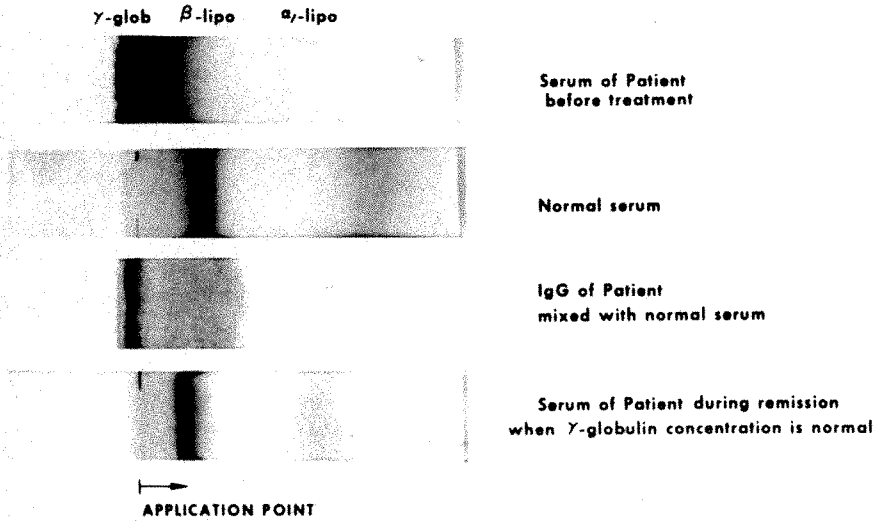

Fig 1.—Interaction of IgG with lipoproteins in present case (serum lipoprotein electrophoresis—oil red O stain).

lipoproteins concentrating in the supernatant and IgG in the subnatant fraction. There were high levels of VLDL and LDL in the supernatant fraction. Isolated lipoprotein and IgG globulin after dialysis against 0.9% NaCl solution recombined readily. Recombination studies were made mixing the isolated IgG and the lipoprotein concentrate from the patient's serum. Two-tenths milliliter of IgG solution (20 mg/ml) were mixed with an equal volume of the lipoprotein solution, which contained the following: 20 mg -S 70-400, 6 mg -S 40-70, 7 mg -S 25-40, and 1.5 mg -S 0-10/ml. After incubation at 37 C for two hours, the mixture was studied by paper electrophoresis for lipoproteins and proteins. Similar incubations were made with use of the same IgG preparation containing 20 mg/ml and adding it to an equal volume of lipoprotein concentrate from serum of a healthy control that contained 1.0 mg -S 70-400, 0.5 mg -S 40-70, 3.5 mg -S 25-40, and 2.0 mg S 0-10/ml. The LDL fraction (d 1.006 to 1.063) containing 2 mg/ml and HDL (d 1.063 to 1.21) containing 1.5 mg/ml from the same serum were also studied. Electrophoresis of the mixtures of lipoprotein with immunoglobulin after incubation when studied by electrophoresis showed that most of the lipoproteins of the patient's serum migrated to the γ-globulin position. Trace amounts of material of α_1 mobility were observed. Similarly, when α- and β-lipoprotein (d 1.21) or β-lipoprotein (d 1.006 to 1.063) of normal serum was incubated with the IgG preparation, most of the lipoproteins migrated to the γ-globulin position. Very little lipid-stainable material was observed in the γ-globulin position when the α-lipoprotein (d 1.063 to d 1.21) was incubated with the IgG. The relative percentage of lipoprotein bound to immunoglobulin from lipoprotein electrophoresis on three occasions in 1969 ranged from 54% to 87%. Total polysaccharide content of the purified immunoglobulin was 5.4%.

Lipid Composition of Xanthoma and Plasma

Chemical analyses showing the lipid and fatty acid composition of the various lipid classes of the xanthoma and of the plasma are shown in Table 2 and Fig 2. Data from two patients with plane xanthoma, hyperlipemia, and IgG monoclonal gammopathies reported by Kodama et al[19] and Marien and Smeenk[20] are also shown for comparison.

Immunofluorescent Studies With Skin and Primary Cell Cultures

In both direct frozen sections and primary cell cultures, considerable amounts of IgG and LDL apoproteins were present in scattered lipid-laden cells in the deep dermis, particularly in the pericapillary and perifollicular regions of the xanthomatous lesions. No evidence of IgA, HDL, or fibrin deposits were found in these lesions. Histologically normal skin from the patient failed to show detectable deposits of immunoglobulins or lipoproteins in such areas. Control studies of similar samples of xanthomatous skin from patients without myelomatosis had consistently shown LDL and HDL deposits not associated with immunoglobulins.

THERAPY

A summary of the patient's treatment and response of serum viscosity, γ-globulin, and lipid levels is shown in Fig 3. Additionally, a short trial of clofibrate (Atromid-S) in August 1969 was poorly tolerated. She also received periodic radiation therapy to several sites of myelomatous lesions of bone.

POSTMORTEM EXAMINATION (EXCLUDING BRAIN AND SPINAL CORD)

Primary findings at autopsy consisted of a severe bilateral bronchopneumonia, acute suppurative bilateral pyelonephritis with necrotizing papillitis, severe generalized atherosclerosis, including the coronary arteries, multiple myeloma with extensive involvement of the vertebral bone marrow, and generalized plane xanthoma. Immediate cause of death was attributed to pneumonia and sepsis.

Notable microscopic findings were infiltration and obliteration of the interlobular arteries of the kidney by foamy histiocytes and a necrotizing vasculitis of the kidney and lung. Most unusual was the finding of a diffuse, band-like infiltrate of neutrophils, many of which were disintegrating, in the subintima and media of the aorta.

COMMENT

The diagnosis of our patient's myeloma was based on classic find-

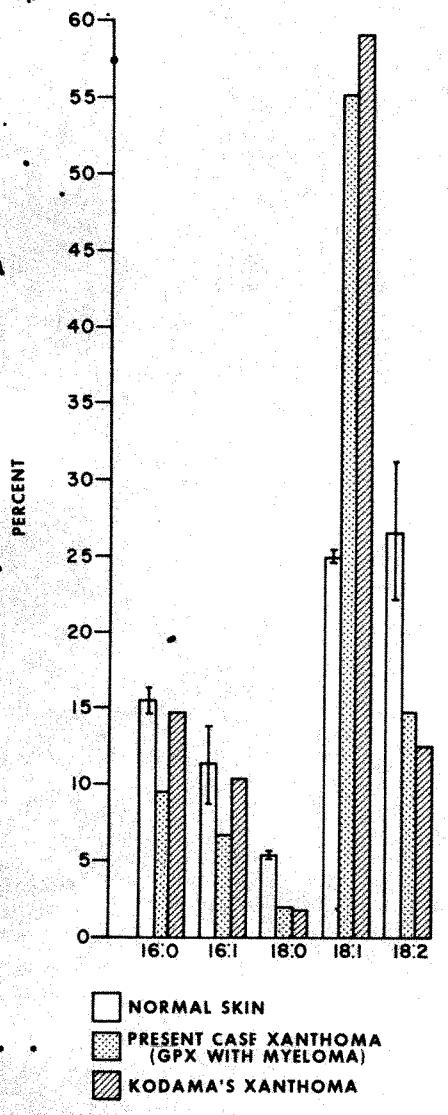

Fig 2.—Xanthoma cholesterol ester fatty acids; comparison of present case with that of Kodama et al[19].

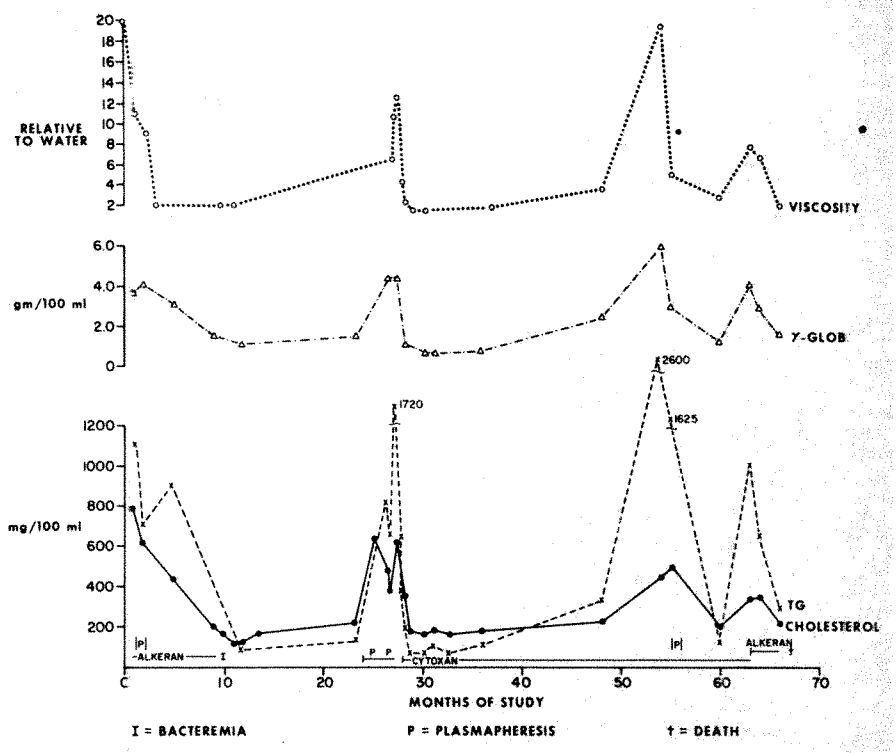

Fig 3.—Changes in serum viscosity, γ-globulin, and lipid levels during treatment in present case.

ings. The xanthoma in our case was a diffuse yellow-orange and the patient was well known to the Cleveland Clinic staff as the "golden lady." A few Touton giant cells were present, but the biopsy specimen did not show the granulomatous quality reported by Winkelmann and Welburn[21] when GPX is associated with paraproteinemia. Although elevated serum carotene levels have been reported in similar cases,[22,23] no association with skin color is postulated. The patient's serum carotene was normal.

Generalized plane xanthoma may be subdivided into two groups.[7,24] The first group, consisting of plane xanthoma occurring with other clinical types of xanthoma is always associated with hyperlipemia, which is either familial or associated with liver disease, usually biliary cirrhosis. In the second group GPX occurs sui generis in a monomorphous pattern; serum lipid levels are usually normal and, if elevated, are not genetically determined nor associated with liver disease. This second group can be subdivided into three others in which xanthomas are associated with reticuloendothelial disease, as in our case, are not associated with any systemic disorder, or are associated with miscellaneous coincidental disease.[24]

Myeloma may occur in association with other clinical types of xanthoma such as the tuberous variety[1,2,5,25] and xanthelasma.[26]

Complexing of serum lipoproteins and paraproteins has been demonstrated in at least 21 cases (including ours) of cutaneous xanthoma associated with multiple myeloma. They are summarized in Table 1; 14 had GPX, 1 had a tuberous xanthoma; in 6 the type was not specified. Twenty cases were hyperlipemic and in 14 cases the lipoprotein-paraprotein complexes were separable by ultracentrifugation at high density. In case 6, the complex was not separable, and in six other cases this point was not specified. In three additional cases of myeloma associated with xanthomatosis, complexing of lipoprotein with immunoglobulin was looked for but no definitive evidence of its occurrence was found.[22,26-28]

However, xanthomatosis is not always present when such complexing occurs[29-33]; most of these were normolipemic. Complexing was also found by Lewis and Page[25] in a patient with secondary paraproteinemia and hyperlipemia without xanthomatosis.

The pathophysiology of the association of myeloma and dyslipidosis has recently been discussed.[34,35] Some arguments favor the dysproteinemia being secondary to the xanthomatosis, but most favor the opposite viewpoint.

It has been shown that the paraprotein secreted by the plasma cell contains a lipid fraction, which is freed at the level of the cutaneous capillaries, and might cross the endothelium and be phagocytized by the dermal histiocytes, resulting in xanthoma formation.[36]

Lynch and Winklemann concluded that GPX was a cutaneous lymphoreticular proliferation with secondary xanthomatization.[24]

Beaumont[37,38] showed that lipoprotein-paraprotein complexing in some patients may be due to an autoantibody activity of the myeloma protein against the serum lipoproteins. He postulates that formation of immune complexes interferes with normal lipoprotein catabolism resulting in hyperlipidemias. Two IgA and one IgG lipoprotein "complexes" were isolated from serum of patients with

myeloma.[39,40] After purification of the immunoglobulins their binding properties with lipoprotein preparations were demonstrated by hemagglutination tests using sheep red blood cells coupled to lipoproteins.

Although these immunochemical data were not obtained in our study, many of the characteristics of our patient's IgG-lipoprotein association were similar to those of the immune reaction present in Beaumont's cases. All of the lipoproteins migrated electrophoretically with the IgG globulin fraction in the γ-globulin position (Fig 1). Separation of the complex was accomplished by ultracentrifugation at a high salt concentration, the lipoprotein floating while the IgG concentrated at the bottom of the tube. The isolated lipoprotein and IgG recombined readily when mixed together and was allowed to stand a few hours. The components migrated as a single, clearly defined band with the mobility of γ-globulin, stainable both with lipid and protein stains. Very little material with the mobility of β-lipoprotein was present. Our patient's IgG also combined with normal lipoprotein, as judged by altered electrophoretic migration of lipoproteins after addition to normal serum of the IgG preparation (Fig 1). Before treatment the patient's serum had a large amount of cryoglobulin consisting chiefly of IgG and lipoproteins. After removal of the lipoproteins by ultracentrifugation the subnatant fraction had no cryoglobulin properties, after adjustment to isotonic salt concentrations.

Changes in serum IgG and viscosity levels, which occurred as a result of therapy, were closely paralleled by a decrease in serum cholesterol and triglyceride levels. When exacerbation occurred and IgG and viscosity increased, cholesterol and triglyceride responded similarly.

Immunofluorescent study of our patient's bone marrow and skin, which showed cells that stained for IgG and β-lipoprotein in the former, and IgG and LDL apoprotein in the latter, is evidence pointing toward a causal relation between the two.

The cause of the vasculitis in the lung and kidneys and the neutrophilic reaction along the aorta may be a reaction to immunologic injury induced by the paraprotein-lipoprotein complex or infection.

In addition to the formation of lipoprotein-paraprotein complexes, another explanation for abnormal lipid transport may be the presence of antiheparin M proteins as reported by Wilson et al.[41] Low total serum complement and an abnormal complement profile were shown in a case reported by Jordan et al.[42]

Distribution of xanthoma lipids in our case and that of Kodama et al[19] differs greatly from that in normal skin (Table 2). Cholesterol esters in both cases made up the largest single component of the xanthoma. The 21.2% of triglycerides in our case as compared to 3.2% in the case of Kodama et al could be due to more complete removal of adhering tissue in the latter. Marien et al[20] (Table 2) demonstrated a high content of triglycerides similar to that in eruptive xanthoma. Cholesterol ester (Fig 2), triglyceride and phospholipid fatty acid xanthoma lipids were similar in ours and that of Kodama et al. However, there was a substantial difference in xanthoma and plasma free fatty acid (FFA) distribution between the two cases that was largely due to palmitic acid.

Free fatty acids make up only 2% of the total lipid in the plane xanthoma of our case and that of Kodama et al.[19] The difference in the xanthoma FFA composition between these two cases may be due in part to differences in their dietary habits, which in turn would be reflected in their plasma FFA. Our patient's plasma had only 19.6% palmitic acid compared to 40.1% of the same acid in the plasma of the case reported by Kodama et al.

Our patient showed no resolution of her cutaneous xanthomas. Partial regression has been noted by others.[9,43]

In another case with xanthomatosis and hyperlipidemia in which the serum lipoproteins and immunoglobulins were tightly bound, Lewis et al[44] found that attempted regulation of serum lipoprotein and lipid levels by means of diet and hypolipidemic agents was ineffective in lowering serum lipids or immunoglobulin levels. The size of the cutaneous xanthomas did, however, decrease. In our case, use of immunosuppressive therapy resulted in the return of serum IgG, lipid, and lipoprotein levels to normal. These findings suggest that in the autoimmune type of hyperlipidemia regulation of immunoglobulin levels may be a more effective way of controlling the hyperlipidemia than using hypolipidemic diet or diet plus hypolipidemic drugs.

References

1. Moschella SL: Plane xanthomatosis associated with myelomatosis. *Arch Dermatol* 101:683-687, 1970.
2. Feiwel M: Xanthomatosis in cryoglobulinaemia and other paraproteinaemias with report of a case. *Br J Dermatol* 80:719-729, 1968.
3. Short MH: Multiple myeloma with xanthoma formation: A report of a case. *Arch Pathol* 77:400-405, 1964.
4. Brehmer W, Lübbers P: Über eine generalixierte Xanthomatose mit Knochenbefall und diffuser Plasmazellwucherung im Knochenmark bei essentieller Hyperlipämie. *Arch Pathol Anat* 318:394-431, 1950.
5. Michaux JL, Heremans JF: Thirty cases of monoclonal immunoglobulin disorders other than myeloma or macroglobulinemia: A classification of diseases associated with the production of monoclonal-type immunoglobulins. *Am J Med* 46:562-579, 1969.
6. Lewis LA, Page IH: Serum proteins and lipoproteins in multiple myelomatosis. *Am J Med* 17:670-673, 1954.
7. Bazex A, Dupré A, Abravanel M: Plasmocytome gamma xanthomateux plan normocholestérolémique. *Ann Dermatol Syphiligr (Paris)* 92:139-150, 1965.
8. Thannhauser SJ: Normocholesteremic xanthomatoses, in *Lipidoses: Diseases of the Intracellular Lipid Metabolism*, ed 3. New York, Grune & Stratton Inc, 1958, p 360.
9. Kint A: Les manifestations cutanée de la maladie de Kahler. *Arch Belg Dermatol Syphiligr* 17:148-160, 1961.
10. Marten RH: Xanthomatosis and myelomatosis. *Proc R Soc Med* 55:318-319, 1962.
11. Potter M: Myeloma proteins (M-components) with antibody-like activity. *N Engl J Med* 284:831-838, 1971.
12. Lewis LA, Green AA, Page IH: Ultracentrifuge lipoprotein patterns of serum of normal, hypertensive and hypothyroid animals. *Am J Physiol* 171:391-400, 1952.
13. Lewis LA: Screening for serum lipoprotein abnormalities: Comparison of ultracentrifugal, paper and thin-layer starch-gel electrophoresis techniques. *Lipids* 4:60-66, 1969.
14. Lewis LA: Thin-layer starch-gel electrophoresis: A simple, accurate method for characterization and quantitation of protein components. *Clin Chem* 12:596-605, 1966.
15. Butkus A, Berrettoni JN: Quantitative and qualitative lipid correlation in experimental endogenous hyperlipemia. *Lipids* 2:212-216, 1967.
16. Butkus A, Robertson AL Jr, Ehrhart LA, et al: Aortic lipids at different stages of canine experimental arteriosclerosis. *Exp Mol Pathol* 16:311-325, 1972.
17. Robertson AL: Selective isolation of cell monolayers from mammalian organ cultures for metabolic studies, abstracted. *In Vitro* 3:174, 1967.
18. Frederickson DS, Levy RI: Familial hyperlipoproteinemia, in Stanbury JB, Wyngaarden JB, Frederickson DS (eds): *The Metabolic Basis of Inherited Disease*, ed 3. New York, McGraw Hill Book Co Inc, 1972, chap 28, pp 545-614.
19. Kodama H, Nakagawa S, Tanioku K: Plane xanthomatosis with antilipoprotein autoantibody. *Arch Dermatol* 105:722-727, 1972.
20. Marien KJC, Smeenk G: Plane xanthomata associated with multiple myeloma and hyperlipoproteinaemia. *Br J Dermatol* 93:407-415, 1975.
21. Winkelmann RK, Welburn WR: Xanthome und Maligne Retikulosen. *Der Hautarzt* 20:550-555, 1969.
22. Cohen L, Blaisdell RK, Djordjevich J, et al: Familial xanthomatosis and hyperlipidemia, and myelomatosis. *Am J Med* 40:299-317, 1966.
23. Moschella SL: Xanthomatosis, associated with multiple myeloma. *Arch Dermatol* 102:121-122, 1970.
24. Lynch PJ, Winkelmann RK: Generalized plan xanthoma and systemic disease. *Arch Dermatol* 93:639-646, 1966.
25. Lewis LA, Page IH: An unusual serum lipoprotein-globulin complex in a patient with

hyperlipemia. *Am J Med* 38:286-297, 1965.

26. Sawkar LA: Familial xanthelasma, hyperlipidemia and multiple myeloma. *J Assoc Phys India* 19:329-334, 1971.

27. Cohen L, Blaisdell RK, Ormiste V, et al: Xanthomatosis, familial hyperlipidemia, and myelomatosis (P). *Circulation* 29 and 30: suppl III-5, 1964.

28. Wilson DE, Sanella JJ, Flowers CM, et al: Hyperlipidemia in multiple myeloma: Response to melphalan therapy, abstracted. *Clin Res* 20:561, 1972.

29. Hill RM, Mulligan RM, Dunlop SG: Plasma cell myeloma associated with high concentration of plasma lipoprotein. *Am J Pathol* 24:688-690, 1948.

30. Sachs BA, Cady P, Ross G: An abnormal lipid-like material and carbohydrate in the sera of patients with multiple myeloma. *Am J Med* 17:662-669, 1954.

31. Magalini SI, Stefanini M, Marin HM: Diagnostic significance of changes in free, esterified, and protein-bound cholesterol, lipo- and glycoproteins in lymphoma and multiple myeloma. *Am J Med Sci* 231:155-164, 1956.

32. Schless GL: Serum cholesterol-globulin complex in multiple myeloma. *Am J Med Sci* 235:562-565, 1958.

33. Noseda G, Bütler R, Schlumpf E, et al: Bindung von Beta-Lipoprotein durch ein IgA-Paraprotein; eine Antigen-Antikörper-Reaktion. *Schweiz Med Wochenschr* 101:893-899, 1971.

34. Perrault M, Duperrat B, Dry J, et al: Xanthomes plans normo-lipidemiques et paraprotemiques. *Ann Med Interne* 122:799-805, 1971.

35. Bazex A, Dupré A, Christol-Jalby B: Xanthomatoses et dysglobulinemies. *Bull Soc Fr Dermatol Syphiligr* 77:607-620, 1970.

36. Aubert L, Arroyo H, Detolle P, et al: Étude clinique et cytologique d'un deuxième cas d'IgA-myélome xanthomateux avec autoanticorps circulant anti-lipoprotéine. *Sem Hop Paris* 43:3014-3021, 1967.

37. Beaumont JL: Hyperlipidemia with circulating anti B lipoprotein auto-antibody in man: Auto-immune hyperlipidemia, its possible role in atherosclerosis. *Prog Biochem Pharmacol* 4:110-121, 1968.

38. Beaumont JL: Auto-immune hyperlipidemia: An atherogenic metabolic disease of immune origin. *Rev Europ Etudes Clin Biol* 15:1037-1041, 1970.

39. Seligmann M, Brouet JC: Antibody activity of human myeloma globulins. *Sem Hematol* 10:163-177, 1973.

40. Beaumont JL, Beaumont V, Antonnucci M, et al: Les auto-anticorps antilipoprotéines de myélome: Étude comparée de deux types: L'Iga anti-Lp P.G. et l'IgG anti-Lp A.S. *Ann Biol Clin* 28:387-399, 1970.

41. Wilson DE, Flowers CM, Hershgold EJ, et al: Multiple myeloma, cryoglobulinemia and xanthomatosis. *Am J Med* 59:721-729, 1975.

42. Jordan RE, McDuffie FC, Good RA, et al: Diffuse normolipaemic plane xanthomatosis. *Clin Exp Immunol* 18:407-415, 1974.

43. James W III, Harland WR: Plasma cell disease and xanthomatosis. *Trans Am Clin Clim Assoc* 79:115-123, 1968.

44. Lewis LA, deWolfe VG, Butkus A, et al: Autoimmune hyperlipidemia in a patient. *Am J Med* 59:208-218, 1975.

45. Lennard-Jones JE: Myelomatosis with lipaemia and xanthomata. *Br Med J* 1:781-783, 1960.

46. Levin WC, Aboumrad MH, Ritzmann SE, et al: γ-Type I myeloma and xanthomatosis. *Arch Intern Med* 114:688-693, 1964.

47. Neufield AH, Morton HS, Halpenny GW: Myelomatosis with xanthomatosis multiforme. *Can Med Assoc J* 91:374-380, 1964.

48. Kayden HJ, Franklin EC, Rosenberg B: Interaction of myeloma gamma globulin with human beta lipoprotein (P), abstracted. *Circulation* 26:659, 1962.

49. Beaumont JL, Jacotot B, Beaumont V, et al: Myélome, hyperlipidémie et xanthomatose. *Nouv Rev Fr Hematol* 5:507-517, 1965.

50. Jacotot B, Nguyen-Trong T, Beaumont JL: Myélome, hyperlipidémie et xanthomatose: II. Recherches complementaires sur l'association entre la paraprotéine et les lipoprotéines légères. *Nouv Rev Fr Hematol* 5:777-779, 1965.

51. Beaumont JL, Jacotot B, Vilain C, et al: Myélome, hyperlipidémie et xanthomatose: III. Un syndrome du a la présence d'un auto-anticorps anti-beta lipoprotéine. *Nouv Rev Fr Hematol* 5:787-792, 1965.

52. Beaumont JL, Jacotot B, Vilain C, et al: Présence d'un auto-anticorps anti-beta-lipoprotéine dans un serum de myélome. *C R Acad Sci [D] (Paris)* 260:5960-5962, 1965.

53. Beaumont JL: Une gamma A-globuline de myélome douée d'une activité spécifique antilipoprotéine: L'auto-anticorps anti-Pg. *C R Acad Sci [D] (Paris)* 263:2046-2049, 1966.

54. Beaumont JL: Une spécificité commune aux alpha et beta-lipoprotéines de serum révélée par un auto-anticorps de myélome: L'antigène Pg. *C R Acad Sci [D] (Paris)* 264:185-188, 1967.

55. Beaumont JL: L'hyperlipidémie par auto-anticorps anti-beta-lipoprotéine: Une nouvelle entité pathologique. *C R Acad Sci [D] (Paris)* 261:4563-4566, 1965.

56. Heremans J: *Les globulines seriques du systeme gamma: Leur nature et leur pathologie (Thèse en vue de l'obtention du grades d'agrege de l'enseignement superieur)*, thesis, Université catholique de Louvain, editions Arscia S.A., Bruxelles, 1960.

57. Beaumont JL: Gamma-globulines et hyperlipidémies: L'hyperlipidémie par auto-anticorps. *Ann Biol Clin* 27:611-635, 1969.

Secondary Cutaneous Mucinosis With Systemic Lupus Erythematosus

A Case Presentation and Review of the Literature

Walter R. Gammon, MD; Ivor Caro, MD; John C. Long, MD; Clayton E. Wheeler, Jr, MD

• A patient had papular and nodular cutaneous deposits of mucin and cutaneous and systemic manifestations of lupus erythematosus (LE). Since many of the mucinous deposits occurred at sites that were clinically free of skin lesions of LE, we considered initially that the patient had both LE and papular mucinosis. However, after a review of the English literature and further study of the patient, it seemed more likely that the papular and nodular deposits of mucin were secondary to LE and not a previously unreported simultaneous occurrence of the two diseases in the same patient.

To our knowledge, this is the third case report of a patient with papular and nodular cutaneous mucinosis secondary to LE. In addition to the case report, this article is concerned with a discussion of cutaneous mucinosis in LE and other "collagen vascular" diseases.

(*Arch Dermatol* 114:432-435, 1978)

It is not widely appreciated that mucin is often present in the cutaneous lesions of discoid and systemic lupus erythematosus (LE). In the majority of LE patients, mucin can be demonstrated by histologic examination performed with special staining techniques, but the mucin is usually not present in large enough amounts to be clinically detectable.

It is uncommon for mucin to be sufficiently abundant to produce gross morphologic changes in otherwise characteristic LE lesions but, rarely, mucin may produce papular and nodular deposits in the cutis without evidence of epidermal change. It is possible that a few patients described as having unusual cases of papular mucinosis before the advent of lupus serology may have had LE with secondary cutaneous mucinosis instead.

We treated a patient with systemic LE who had a spectrum of skin pathology from typical discoid lesions to dermal deposits of mucin without clinically apparent epidermal changes and lesions that seemed to represent transition forms between discoid lesions and dermal mucinous nodules. Careful study to rule out other causes of cutaneous mucinosis left us with the conclusion that the patient's mucinosis was secondary to LE.

Accepted for publication April 8, 1977.

From the Department of Dermatology, University of North Carolina School of Medicine, North Carolina Memorial Hospital, Chapel Hill.

Reprint requests to Department of Dermatology, University of North Carolina School of Medicine, North Carolina Memorial Hospital, Chapel Hill, NC 27514 (Dr Gammon).

REPORT OF A CASE

A 43-year-old man was seen initially in the Dermatology outpatient department at the North Carolina Memorial Hospital in May 1975 because of a progressive eruption on his arms, upper part of the trunk, face, and scalp of approximately ten years' duration. The skin lesions were asymptomatic except for reddening of depigmented areas with prolonged sun exposure. The patient felt generally well and results from a review of systems were normal.

Examination of the skin showed many characteristic lesions of discoid LE distributed over the scalp, face, trunk, arms, upper thighs, and back. The face and scalp showed prominent depigmentation, atrophy, and scarring, especially over the malar areas (Fig 1). Active areas of erythema with telangiectasia, follicular plugging, and scales were present at the borders of most of these lesions. There was scarring alopecia of the scalp, eyebrows, and beard. The arms, upper part of the chest, back, and thighs showed multiple, annular, papular to plaque-like lesions with hyperkeratosis, follicular plugging, and central atrophy; many of these had a firm elevated border of several millimeters. Scaly, hyperpigmented plaques were present over the

dorsum and palmar surfaces of both hands.

In addition to the characteristic lesions of discoid LE, multiple dermal papules and nodules 5 to 15 mm in diameter were present over the upper and middle part of the back, shoulders, and upper arms (Fig 2). These lesions produced a "lumpy" appearance in the skin and were best appreciated with tangential lighting. These infiltrates were firm and nontender with poorly defined borders. The texture and consistency of the skin in these areas were normal.

The epidermis overlying most of these papules and nodules appeared normal but over some there appeared to be a continuum of epidermal involvement from isolated follicular hyperkeratosis and hyperpigmentation to more typical discoid lesions of varying sizes. These lesions appeared to progress from isolated follicular involvement by enlarging centrifugally to produce discoid lesions with hyperpigmentation, atrophy, and follicular plugging.

Laboratory studies on the first visit showed the following values: urinalysis, 4+ proteinuria without cells or casts; Westergren sedimentation rate, 72 mm/hr; antinuclear antibody (ANA), 3+ membranous staining equivalent to a titer of greater than 1:40; double-stranded DNA, negative; one LE preparation, negative; C3, 93 mg/100 ml (normal, 90 to 185); serum protein electrophoresis, IgG–1,941 mg/100 ml (normal, 535 to 1,620), IgA–64/mg/100 ml (normal, 75 to 370), IgM–6 mg/100 ml (normal, 25 to 210). No paraprotein was seen on gel or immunoelectrophoresis.

Skin biopsy specimens were taken from lesions with apparent epidermal involvement typical of discoid LE and from dermal nodules without discernable epidermal change. The former showed epidermal atrophy with follicular plugging, scattered liquefactive degeneration of the basal layer, and perivascular and perifollicular mononuclear cell infiltrates. Specimens of dermal nodules showed no epidermal changes but all specimens showed severe disruption of collagen fibers in all layers of the dermis; Alcian green and colloidal iron stains disclosed heavy deposits of acid mucopolysaccharides between collagen bundles throughout the dermis (Fig 3).

The working diagnoses were systemic LE with discoid skin lesions and possible papular mucinosis. A follow-up appointment was scheduled but the patient failed to return.

In June 1976, following several syncopal episodes and one brief episode of involuntary left-sided movement without loss of consciousness, the patient was admitted to his local hospital. Diagnosis of congestive heart failure and systemic LE were made and the patient was given digitalis and referred to the North Carolina Memorial Hospital.

The patient had stopped working six months prior to admission because of increasing fatigability, weight loss of 9.1 kg, progressive dyspnea on exertion, and mild orthopnea without paroxysmal nocturnal dyspnea. There was no history of chest pain, blood loss, pedal edema, poor appetite, or diarrhea. The patient denied dysphagia, trauma, dysphasia, Raynaud's phenomenon, arthralgias, fever, night sweats, changes in emotional and mental status, or genitourinary symptoms. Drugs taken by the patient included diazepam, digoxin, and salicylates.

On physical examination, pulse rate, temperature, and respiration rate were normal. The blood pressure was 100/60 mm Hg without orthostatic change. The skin showed progressive involvement of discoid LE lesions over the upper arms, back, and thighs. The same unusual, nodular, dermal infiltrates without epidermal changes were observed. It was suspected that enlarging epidermal lesions had developed over the surface of some of the nodular infiltrates.

The remaining positive physical findings included a slightly enlarged heart, coarse inspiratory wheezes at the bases of both lung fields, a fine tremor of both upper extremities, mild generalized weakness, and moderate weakness of the right ankle dorsiflexors.

A summary of pertinent laboratory data is as follows: hematocrit, 37%; hemoglobin, 12.3 gm/100 ml: WBC count, 3,400; differential WBC count, 58% neutrophils, 30% lymphocytes, 11% monocytes, 1% eosinophils; Zeta sedimentation rate, 70 mm/hr; VDRL, negative; routine urinalysis, 3+ protein, 5 to 10 WBC/high-power field, moderate hyaline casts; platelet count, 110,000/ml prothrombin and partial thromboplastin times, normal; total clotting time, 27 seconds (control, 12.4); Ivy bleeding time, 6½ minutes; electrolytes, BUN, creatinine, bilirubin, SGOT, and SGPT, normal. Alkaline phosphatase was 7.2 units/100 ml (normal 2 to 6); cholesterol, 270 mg/100 ml; total serum protein, 8.6 gm/100 ml; albumin, 3 gm/100 ml. Studies for serum paraprotein were negative; serum immunoelectrophoresis, IgG–2,125 mg/100 ml, IgA–577 mg/100 ml, IgM–6 mg/100 ml; 24-hour urine collections for Bence-Jones protein, negative; creatinine clearance, 55 ml/min; three 24-hour urine collections for protein, 1.4, 2.9, and 2.4 gm/24 hr, respectively. Three lupus erythematosus preparations were negative; cryoglobulins, negative; antibodies to double-stranded DNA, negative; T_3 and T_4, normal; ANA, +1:120 dilution in a homogeneous pattern; C3, 81 mg/100 ml. The results of a spinal tap and CSF analysis showed a normal pressure, cell count of 11, with 100% lymphocytes, protein, 87 gm/100 ml, and normal glucose level.

Chest roentgenogram showed a slightly enlarged heart, increased interstitial markings, but normal pulmonary vasculature. Results of an intravenous pyelogram were normal. A cardiac ultrasound study showed moderate left ventricular enlargement and a small pericardial effusion. Nerve conduction studies demonstrated mild sensory and motor conduction defects in both lower extremities. Brain scan and EEG were normal or nonspecific. Results of a percutaneous kidney biopsy showed a mild focal mesangioproliferative glomerulonephritis.

Direct immunofluorescence of kidney tissue showed a mixed linear and granular deposition of IgG and complement components C3 and C4 in the mesangium and glomerular basement membrane (Fig 4). Immunofluorescence of skin biopsy specimens showed granular deposits of IgG at the dermal-epidermal junction and within the walls of small upper dermal vessels. The same pattern was present in clinically uninvolved skin taken from sun-exposed areas. No specific immunoglobulin staining was seen in the dermal collagen.

The patient's hospital course was complicated by a sudden left hemiparesis, which was believed to be secondary to a cerebrovascular accident or lupus cerebritis. The patient was given prednisone, 90 mg/day which improved his hemiparesis; when discharged, he was able to ambulate with a walker. Discharge diagnoses were systemic LE with secondary cutaneous mucinosis, congestive heart failure, and resolving left hemiparesis.

When seen at follow-up three months after discharge, improvement was noted in the skin lesions and left hemiparesis. The discoid lesions were much less active, no new lesions had developed, and the dermal mucinosis was less apparent.

COMMENT

Beyond the recognized presence of mucinous material in characteristic skin lesions, little is known about the extent or distribution of mucin in the skin of patients with systemic and discoid LE. Through the years, many investigators have observed and commented on the presence of abnormal polysaccharide deposits in the dermis of LE skin lesions but a systematic search for these substances in clinically uninvolved skin has not been made.

Increased deposits of "ground-substance" in the dermis of LE lesions have been noted since the classic descriptions of LE histopathology in the 1930s and 1940s by Goeckerman and Montgomery[1] and Klemperer et al[2] but it has been only within the last decade that LE has been unequivocally established as a cause of secondary cutaneous mucinosis.[3-5]

In 1950, Stoughton and Wells studied skin lesions from 26 cases of acute and chronic LE and found dermal PAS-positive deposits in 22.[6] The same year Asboe-Hansen, using differential histochemical techniques, reported hyaluronidase-positive mucin deposits in the corium of LE skin lesions.[7] The deposits of mucin were seen in clumps, strands, and in a diffuse pattern. He noted that mucin deposition was more prominent in the early lesions.

In 1956, Cawley et al investigated the presence and distribution of acid mucopolysaccharides in the clinically involved skin of patients with a

Fig 1.—Hypopigmentation and scarring (with alopecia) on face, ears, and scalp. Hyperpigmented and hyperkeratotic lesions are seen on left shoulder.

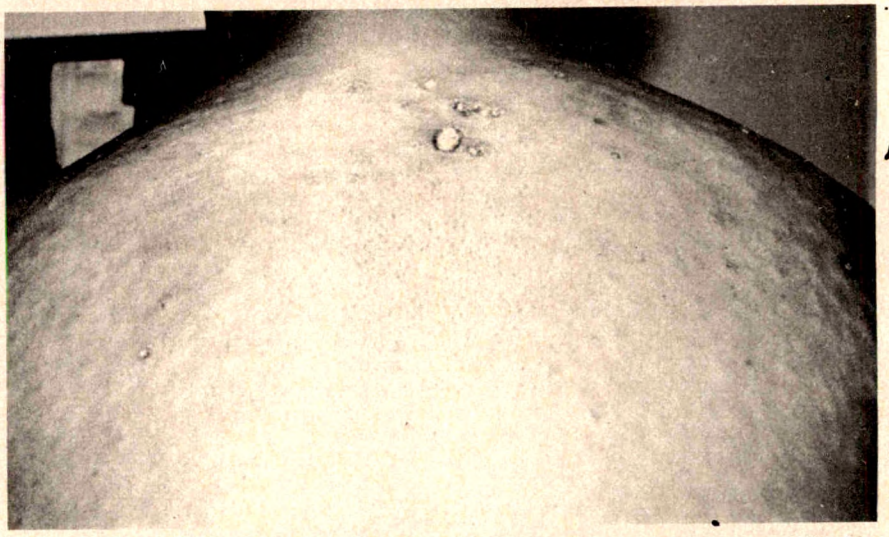

Fig 2.—Patient's upper and middle parts of back showing dermal nodules, follicular hyperkeratosis, and several lesions of discoid lupus erythematosus.

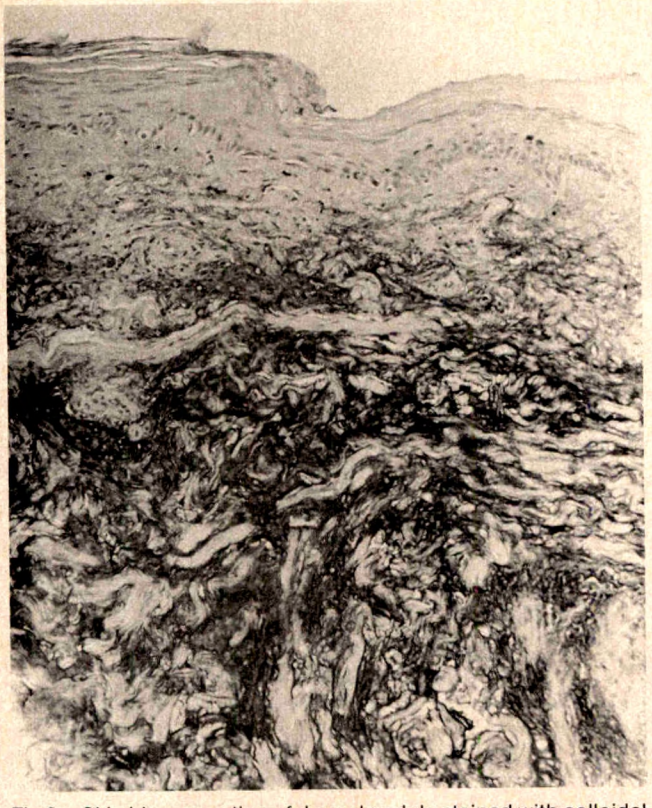

Fig 3.—Skin biopsy section of dermal nodule stained with colloidal iron showing extensive deposits of mucinous material interspersed among collagen bundles of middle and lower dermis (original magnification ×250).

Fig 4.—Fluorescent microscopy of glomerulus obtained by percutaneous renal biopsy stained with fluorescein-labeled anti-IgG and C4. Note mixed granular and linear staining pattern (original magnification ×400).

variety of collagen-vascular diseases including discoid and systemic LE, dermatomyositis, and polyarteritis nodosa.[8] Using an alcian blue stain for mucin, they noted small quantities of mucin in the upper dermis of discoid lesions and abundant deposits in the upper and middle dermis of patients with systemic LE and dermatomyositis. In 1963, Johnson and Helwig observed increased ground substance dispersed among collagen bundles in acute LE[3] and in 1966 they listed LE as a cause of cutaneous mucinosis.[4]

In 1968, Janis and Winklemann, in a histologic review of 55 cases of dermatomyositis, noted mucin in 8 of 18 nonspecific skin biopsy specimens taken over muscle biopsy sites.[9] These investigators stressed the point that mucin staining in an otherwise nonspecific biopsy section should make one suspect dermatomyositis, and noted the similarity to LE. It was not apparent from their study whether mucin had been observed in the clinically normal skin of patients with LE.

In an excellent review of the subject in 1973, Reed et al[5] stressed LE as a cause of diffuse or disseminated cutaneous mucinosis along with generalized myxedema, pretibial myxedema, papular mucinosis, "collagen diseases," cutaneous infarcts (Degos' disease), and sclerodermoid plaques of the mucopolysaccharidoses. The presence of mucinous deposits in clinically uninvolved skin of LE has not been substantiated by a review of the literature, and with rare exceptions, the effect of dermal deposits of mucin on the gross clinical morphology of LE skin lesions has not been reported. It might be inferred from the literature, however, that the presence of mucin usually produces no clinically detectable alteration of the skin in patients with this disease.

Subcutaneous or dermal changes with normal overlying epidermis have been described in the skin of patients with LE. In addition to vasculitis, these include lupus profundus or panniculitis[10,11] and rheumatoid nodule-like lesions.[12] Mucin deposits in those lesions have not been described.

In 1954 Gold[13] described two very unusual patients with systemic LE who had, in addition to typical discoid skin lesions, subepidermal deposits of mucin clinically apparent as approximately 1-cm, poorly defined, nodular deposits distributed over the upper part of the back and trunk. The lesions were described as skin-colored and were best observed with tangential lighting. Biopsy specimens of the unusual lesions from both patients showed mild thinning epidermis in one and no epidermal change in the other. Both showed abundant mucin deposition between collagen bundles in the dermis. The lesions were observed to wax and wane with the activity of the LE in both patients. Gold included pictures of lesions from the back of one of his patients. These were very similar to those seen in our patient.

A few patients whose conditions were diagnosed as papular mucinosis have been described with skin lesions and mucin deposits similar to those in our patient. Though none of these cases was diagnosed as LE, these reports preceded the time when sensitive serologic tests were available to aid in that diagnosis. One such patient was described in 1953[14,15] and another in 1960.[16] Both had cutaneous and systemic manifestations of a disease characterized by discoid lupus-like skin lesions overlying mucin deposits and prominent neurologic abnormalities. Both patients eventually succumbed to their disease. These investigators realized that the skin lesions were atypical for papular mucinosis and suggested that they might fit better into a subcategory of papular mucinosis. In many ways these two patients were clinically indistinguishable from our patient and the two patients described by Gold.

Dermal immunoglobulin staining in and around collagen bundles has been described in papular mucinosis and the majority of such patients have a cathodal paraprotein in their serum. Neither of these findings was present in our patient who was studied twice in one year. Furthermore, the dermal papulonodular appearance of mucin deposits in this patient are unlike those seen in most patients with papular mucinosis. Until the pathogenesis of mucin deposits in these two diseases are better understood, little more can be said about their similarities and differences.

References

1. Goeckerman WH, Montgomery H: Lupus erythematosus. *Arch Dermatol Syphilol* 25:304-314, 1932.
2. Klemperer P, Pollack AD, Baehr G: Pathology of disseminated lupus erythematosus. *Arch Pathol* 32:569-631, 1941.
3. Johnson WC, Helwig EB: Histochemistry of the acid mucopolysaccharidoses of skin in normal and in certain pathologic conditions. *Am J Clin Pathol* 40:123-131, 1963.
4. Johnson WC, Helwig EB: Cutaneous focal mucinosis. *Arch Dermatol* 93:13-20, 1966.
5. Reed RJ, Clark WH, Mihm MC: The cutaneous mucinoses. *Hum Pathol* 4:201-205, 1973.
6. Stoughton R, Wells G: A histochemical study on polysaccharides in normal and diseased skin. *J Invest Dermatol* 14:37-50, 1950.
7. Asboe-Hansen G: A survey of the normal and pathologic occurrence of mucinous substances and mast cells in the dermal connective tissue in man. *Acta Dermatol Venereol* 30:338-346, 1950.
8. Cawley EP, McManus JFA, Lupton CH, et al: An examination of skin from patients with collagen disease utilizing the combined alcian blue-periodic acid Schiff stain. *J Invest Dermatol* 27:389-392, 1956.
9. Janis JF, Winklemann RK: Histopathology of the skin in dermatomyositis: A histopathologic study of 55 cases. *Arch Dermatol* 97:640-650, 1968.
10. Fountain RB: Lupus erythematosus profundus. *Br J Dermatol* 80:571-579, 1968.
11. Tuffanelli DL: Lupus erythematosus panniculitis (profundus). *Arch Dermatol* 103:231-242, 1971.
12. Hahn BH, Yardley JH, Stevens MB: "Rheumatoid" nodules in systemic lupus erythematosus. *Ann Intern Med* 72:49-58, 1970.
13. Gold SC: An unusual papular eruption associated with lupus erythematosus. *Br J Dermatol* 66:429-433, 1954.
14. Montgomery H, Underwood LJ: Lichen myxedematosus (Differentiation from cutaneous myxodermas or mucoid states). *J Invest Dermatol* 20:213-233, 1953.
15. McCuistion CH, Schoch EP Jr: Autopsy findings in lichen myxedematosus. *Arch Dermatol* 74:259-262, 1956.
16. Perry HO, Montgomery H, Stickney JM: Further observations on lichen myxedematosus. *Ann Int Med* 53:955-969, 1960.

Inflammatory Linear Verrucose Epidermal Nevus

Steven J. Hodge, MD; James M. Barr, MD; Lafayette G. Owen, MD

• We treated three patients with inflammatory linear verrucose epidermal nevus. The lesions were either verrucose or psoriasiform and all had an inflammatory component. Histologic features included psoriasiform acanthosis with spongiosis and parakeratosis. Features that distinguish this entity and the differential diagnoses are discussed.

(*Arch Dermatol* 114:436-438, 1978)

Inflammatory linear verrucose epidermal nevus (ILVEN) was first described as such by Altman and Mehregan in their report of 25 cases in 1971.[1] They considered it to be a distinct variety of linear verrucose epidermal nevus that appeared inflammatory or psoriasiform. Prior to their report there had been occasional case reports of linear verrucose lesions that were inflammatory and pruritic, which had been confused with linear psoriasis or lichen simplex chronicus.[2-5]

Histologically, the features of ILVEN are characteristic, although not pathognomonic. The histologic appearance is distinctively inflammatory and psoriasiform, and typically discloses the following features: (1) moderate acanthosis and papillomatous thickening of the epidermis; (2) an even elongation of the rete ridges and the dermal papillae; and (3) multiple small areas of spongiotic edema and exocytosis within the thin suprapapillary epidermis leading to spotty areas of parakeratosis (at times small Munro-type microabscesses may be formed). There may also occur a more pronounced degree of parakeratosis appearing in broad areas associated with complete loss of the granular layer. There is usually a mild perivascular lymphocytic infiltrate is the upper dermis.

Accepted for publication April 26, 1977.

From the Department of Dermatology, University of Louisville School of Medicine.

Reprint requests to Department of Dermatology, University of Louisville School of Medicine, 323 E Chestnut St, Louisville, KY 40202 (Dr Hodge).

REPORT OF CASES

Case 1.—A 29-year-old woman, was first seen on Dec 3, 1975. She had the appearance of a hyperpigmented papule in the left groin region for one year's duration. The lesion had since spread in a linear fashion laterally. Examination disclosed several well-demarcated, mildly hyperpigmented, slightly scaly patches in a linear fashion in the left groin.

A 3-mm punch biopsy specimen was taken for histologic examination. The patient's general health was excellent and she had no personal or family history of psoriasis. She was given betamethasone dipropionate (Diprosone) 0.05% cream to apply three times daily. The lesions responded within one week with an approximately 50% reduction in pruritus, scaling, and erythema. However, continued treatment failed to produce any further improvement. Recent follow-up showed that the patient's lesions disappeared in February 1976, leaving some mild residual manifestation of hypopigmentation.

Case 2.—A 7-year-old girl who was first seen on Sept 30, 1975, had developed a very pruritic papular eruption on the left side of her abdomen at 1 year of age (Fig 1 and 2). The eruption had been very persistent with periodic flares of itching interspersed between periods of quiescence during which the lesions would subside to the point of being barely noticeable. Her general health was good and there was no personal or family history of psoriasis. Examination showed a 4- to 5-cm cluster of mildly erythematous and slightly hyperpigmented papules in the midabdominal region to the left of the midline. A 2-mm punch biopsy specimen was taken for histologic examination.

The eruption has been treated with fluocinonide (Lidex), 0.05%, which decreased the erythema and pruritus but did not completely clear the lesions. After discontinuing the cream the lesions quickly become prominant and pruritic.

Case 3.—A 19-month-old girl was first seen in October 1974 for a pruritic eruption on the left medial thigh that had been present since birth. Examination disclosed grouped, erythematous, excoriated, scaly psoriasiform papules on an inflammatory base distributed about the upper left thigh, anteriorly, medially, and posteriorly (Fig 3). A 2-mm punch biopsy specimen was taken. The patient was treated with desonide 0.05% cream (Tridesilon) during the day and tretinoin 0.05% cream nightly.

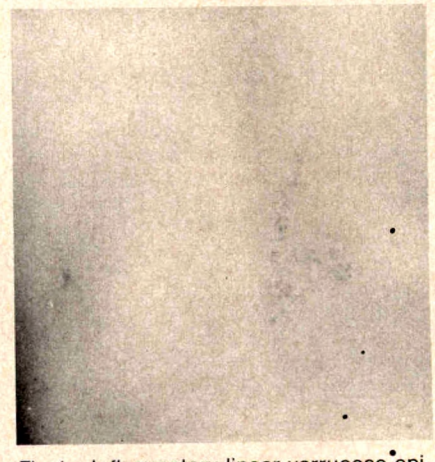

Fig 1.—Inflammatory linear verrucose epidermal nevus, left abdomen.

The itching was not relieved and the patient was changed to a regimen of halcinonide 0.1% cream (Halog). The pruritus persisted, the area became secondarily infected, and use of the halcinonide cream was discontinued. Since the clearing of the infection she has been treated with nothing other than a cream containing a mixture of zinc oxide and cod liver oil (Desitin) and the eruption has persisted with no substantial change.

HISTOPATHOLOGY

All three biopsy specimens showed similar features, with an overall pattern consistent with psoriasiform chronic dermatitis (Fig 4 and 5). A thick parakeratotic scale covered an epidermis demonstrating mild papillomatosis in some areas, with absence of the granular layer, acanthosis, and marked spongiosis. No Munro's microabscesses were seen. There was some psoriasiform flattening of the rete ridges. The upper dermis showed

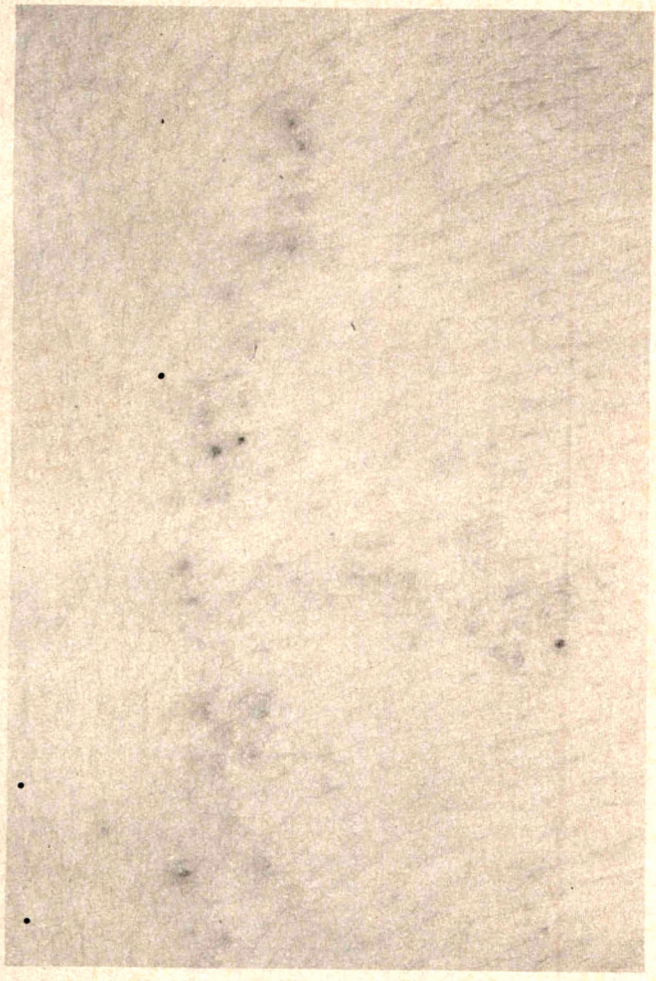

Fig 2.—Linear cluster of excoriated erythematous papules.

Fig 3.—Papulosquamous psoriasiform lesion, upper part of left thigh and groin.

Fig 4.—Inflammatory linear verrucose epidermal nevus. Thick parakeratotic scale covers psoriasiform acanthotic epidermis. There is mild perivascular and periappendageal inflammatory infiltrate in the dermis (hematoxylin-eosin, original magnification, ×40).

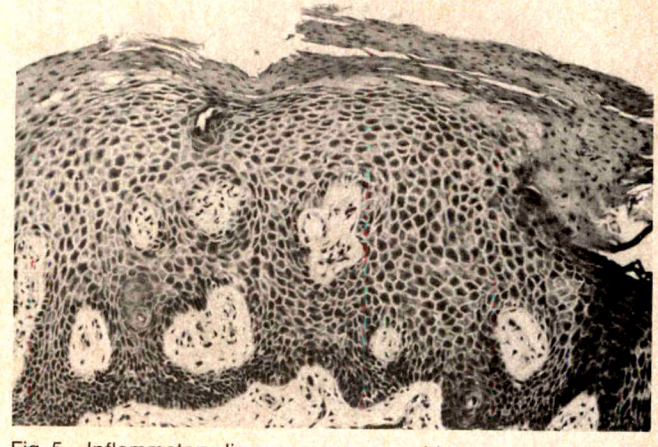

Fig 5.—Inflammatory linear verrucose epidermal nevus. Higher power demonstrates parakeratosis, spongiosis, and acanthosis of epidermis (hematoxylin-eosin, original magnification ×100).

a mild, nonspecific capillary dilation and proliferation with a perivascular and periappendageal infiltrate of lymphocytes and histiocytes.

COMMENT

Inflammatory linear verrucose epidermal nevus, as described by Altman and Mehregan,[1] has the following characteristic features: (1) early age of onset; (2) 4:1 predominance in females; (3) frequent involvement of the left side of the body, especially the left lower extremity; (4) pruritus; (5) persistent lesions showing great refractoriness to treatment; and (6) distinctive inflammatory and psoriatic histologic appearance. All three of the cases in this report were females who had involvement of the left side of the body with persistent, pruritic lesions that were refractory to treatment. Two of the three patients had developed lesions early in life; the patient in case 2 at 1 year of age, and that in case 3 at birth. Eighteen of the 25 cases (75%) of Altman and Mehregan had noted an onset of lesions prior to age 5 years, 12 of them observing onset prior to age 6 months. Lesions were present at birth in four patients. Six patients developed the eruption between ages 10 and 20, and in one patient lesions first appeared at age 49.

The differential diagnosis primarily includes, linear psoriasis and linear localized neurodermatitis. Linear Darier's disease, lichen striatus, and linear lichen planus may also be included.

Linear psoriasis, as pointed out by Beek and Jantzen,[6] is almost always associated with more typical lesions of psoriasis elsewhere on the body. Linear psoriasis existing as an isolated lesion unassociated with psoriatic lesions elsewhere on the body must be exceedingly rare, and several authors[1,5,7] tend to reject the existence of true linear psoriasis. Morphologically, the lesions in two of our cases are more verrucose than psoriasiform. Histologically, in all three cases there were no Munro microabscesses and no epidermal transmigration or exocytosis of polymorphonuclear leukocytes.

Linear localized neurodermatitis seldom, if ever, occurs in childhood, and is most common in middle-aged and elderly adults. Morphologically, the most striking feature is lichenification. The lesions will usually respond promptly to treatment with topical corticosteroids, as opposed to ILVEN.

Linear Darier's disease and linear lichen planus may be distinguished histopathologically. The acantholytic and dyskeratotic changes seen in Darier's disease are not seen in these cases. The band-like subepidermal infiltrate, destruction of the basal layer, hypergranulosis, and orthokeratotic scale of lichen planus are not seen microscopically.

Lichen striatus does occur primarily in children and usually appears on an extremity. However, it is composed of small, lichenoid papules that do not itch, and it usually involutes within a year. Histologically, there is less acanthosis, with a patchy papillary dermal lymphohistiocytic infiltrate and some exocytosis of erythrocytes.

Russell[5] stated that "some cases of linear psoriasis (Clar, 1922; Woringer, 1936; Camano, 1943) seem to be a psoriatic type of linear nevus. Such nevi may otherwise have pigmentary, acneiform, lichenoid, hypertrichotic, or warty characteristics. Although it is possible that an underlying psoriatic diathesis is responsible for the development of these lesions, in most cases there is no supporting evidence in the form of a family history or past history of psoriasis to suggest this."

Bennett et al[8] reported a patient with widespread epidermal nevus present since childhood who developed recent-onset typical psoriasis on the elbows, scalp, and nails, as well as verrucose psoriatic lesions within, and overlapping, portions of the epidermal nevus. They supported the concept that psoriasiform inflammatory changes in linear epidermal nevi represent a Koebner phenomenon, and that epidermal nevi provide excellent psoriagenic foci in persons predisposed to psoriasis. Histologic sections showed typical psoriasis in these nevi, in contrast to our biopsy findings and most of the cases of Altman and Mehregan.

Torbio and Quinones[9] recently reported a case in ILVEN with electron microscopic findings that were inconclusive with regard to a relation with psoriasis. The histologic pattern was consistent with psoriasis.

We believe that these cases probably represent instances of the entity that Altman and Mehregan have called inflammatory linear verrucose epidermal nevus. We feel that this condition is a distinct and not uncommon entity, and that it should be recognized as such.

References

1. Altman J, Mehregan AH: Inflammatory linear verrucose epidermal nevus. *Arch Dermatol* 104:385-389, 1971.
2. May SB: Epithelial nevus with marked pruritus. *Arch Dermatol* 83:340-341, 1961.
3. Gethner PJ: Case for diagnosis, linear psoriasis? *Arch Dermatol* 83:341-342, 1961.
4. Obermayer ME, Dockweiler JES: Epidermal nevus, psoriasiform, of vulva? *Arch Dermatol* 93:145-146, 1966.
5. Russell B: Psoriasis zosteriformis. *Br J Dermatol* 62:314-315, 1950.
6. Beek CH, Jantzen T: An acute linear dermatoses. *Acto Dermatovener* 35:318-326, 1955.
7. Leslie G: Linear psoriasis. *Br J Dermatol* 63:262-263, 1951.
8. Bennett RG, Burns L, Wood MG: Systematized epidermal nevus (a determinant for the localization of psoriasis). *Arch Dermatol* 108:705-707, 1973.
9. Torbio J, Quinones PA: Inflammatory linear verrucose epidermal nevus. *Dermatologica* 150:65-69, 1975.

Uveitis, Poliosis, Hypomelanosis, and Alopecia in a Patient With Malignant Melanoma

Arthur J. Sober, MD, Harley A. Haynes, MD

• Bilateral uveitis, poliosis, hypomelanosis, and alopecia (Vogt-Koyanagi-Harada syndrome) developed spontaneously in a 57-year-old woman following operation for metastatic malignant melanoma. She has been disease-free for 8½ years in spite of a highly unfavorable prognosis. Within the framework of current concepts of cell-mediated and humoral immunity in patients with malignant melanoma, activity of the host's immune system is postulated for the destruction of normal melanocytes in the skin, hair follicle, and uveal tract, as well as for the favorable outcome.

(*Arch Dermatol* 114:439-441, 1978)

Clinical observations abound in the melanoma literature that suggest that melanocyte destruction by the host can occur. Spontaneous regression of the primary tumor, long latency period following removal of the primary tumor to appearance of metastasis, and the halo of leukoderma centrifugum aquisitum about the primary tumor are just a few examples.[1] Two cases of uveitis and vitiligo following bacillus Calmette-Guerin (BCG) administration in melanoma patients have been reported.[2] The authors suggest that immune stimulation by BCG might in some way be responsible for this occurrence. The present report was motivated by the observation of a patient in whom poliosis and nonscarring alopecia, in addition to hypomelanosis and uveitis, developed following surgical excision of metastatic malignant melanoma without the use of immunotherapy. This patient has now been free of melanoma for 8½ years.

REPORT OF A CASE

A 57-year-old woman was admitted to the Massachusetts General Hospital in August 1968 for examination of a right axillary mass that on biopsy proved to be metastatic malignant melanoma. A black mole over the right scapula had been removed by fulguration five months prior to this admission. A right axillary lymph node dissection was performed to remove the metastatic disease. Nine months later (May 1969), the patient developed blurred vision. Acute bilateral anterior uveitis was diagnosed. This problem was treated with topically applied dexamethasone and cleared during a two-month period. Fourteen months postoperatively (October 1969), several discrete areas of hypopigmentation clinically consistent with vitiligo had developed in areas near the surgical site of the primary and the metastatic tumor (right axilla, Fig 1) and in other scattered areas as well (neck, Fig 2). In addition, scattered poliosis (Fig 3) and two small discrete circular patches of nonscarring alopecia clinically consistent with alopecia areata had developed on the vertex scalp. At no time during the active phases of this illness did the patient experience auditory or other CNS symptoms. Detailed otologic examination was not performed. At last follow-up (February 1977), the hypomelanotic lesions were less prominent, the alopecia had disappeared completely without evidence of a scarred scalp, and the areas of poliosis had increased somewhat. Follow-up ophthalmologic examination at this time disclosed no signs of active uveitis. The presence of pigment cells dispersed on the anterior lens capsule was interpreted as residual evidence reflecting the past uveitis. She has been followed up at least semiannually in the Pigmented Lesion Clinic at the Massachusetts General Hospital and has had no recurrences of her melanoma during this 8½ year period. Epidermal sections from a

Accepted for publication April 13, 1977.

From the Departments of Dermatology, Harvard Medical School (Drs Sober and Haynes) and Massachusetts General Hospital (Dr Sober); Melanoma Clinical Cooperative Group (Dr Sober); and Division of Dermatology, Department of Medicine, Peter Bent Brigham Hospital, Boston (Dr Haynes).

Reprint requests to Melanoma Registry, Warren 5, Massachusetts General Hospital, Boston, MA 02114 (Dr Sober).

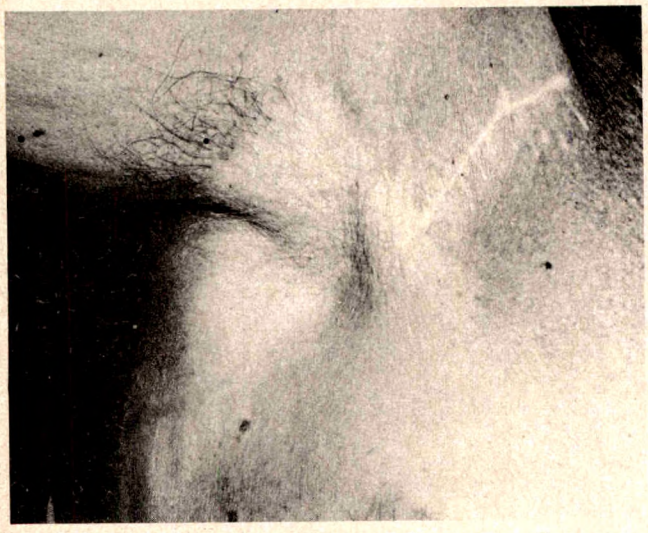

Fig 1.—Hypomelanotic area in right axilla (region of previous nodal surgery) photographed under long wave ultraviolet light.

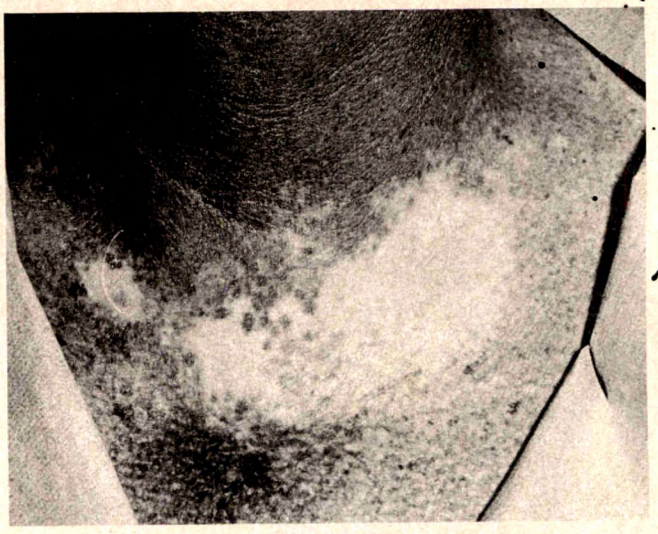

Fig 2.—Hypomelanotic area on neck and upper part of chest photographed under long wave ultraviolet light.

Fig 3.—Poliosis photographed under long wave ultraviolet light.

hypomelanotic lesion on the left arm (October 1976) incubated with dihydroxyphenylalanine (DOPA) disclosed a sharp decrease in the number of melanocytes compared to a normally pigmented area. In addition, the melanocytes in the hypomelanotic area were much larger and had more prominent dendrites than those in the normal control area. These large melanocytes were mophologically normal, however. Melanocytes were totally absent from the sections prepared for the electron microscope, reflecting the problem of sampling when melanocyte density is severely reduced.

COMMENT

The immune system plays an important role in the natural history of malignant melanoma.[1] Both cellular[3,4] and humoral[4,5] factors directed against melanoma cells have been detected in the laboratory. The depigmentation noted in areas of regression of malignant melanoma and in the halos of depigmentation about melanomas and halo nevi also seem to have an immunologic basis in that the mononuclear cells infiltrate the areas in which melanocytes are being destroyed.[6] Many melanoma patients as well as individuals with halo nevi have circulating mononuclear cells that are cytotoxic to cultured melanoma cells.[3,4,7] Hypomelanotic macules (depigmentation away from the primary lesion) have also been observed in cases of malignant melanoma.[8-11] However, true vitiligo at the time of diagnosis of malignant melanoma was found in only 11 patients in 834 followed up by the Melanoma Clinical Cooperative Group (Harvard, New York University, Temple University, and University of California at San Francisco; written communication, July 1976), which would not differ in prevalence from the normal population.[12] Melanocytes are absent in well-developed areas of true vitiligo. The finding of large, well-arborized multidendritic melanocytes in decreased number within a hypomelanotic macule in this patient, while quite interesting, provides a challenge in the interpretation. Without the dihydroxyphenylalanine findings, the electronic microscopic study would have led to the false conclusion that there was complete absence of melanocytes in the hypomelanotic macule consistent with classical vitiligo. A biopsy being a static observation gives information about only one point in the

evolution of a process. Future biopsies will be helpful to interpret whether the observation of diminished melanocyte number is representative of the true state of the hypomelanotic areas in the Vogt-Koyanagi-Harada syndrome or is merely a phase on the curve of melanocyte recovery or total destruction.

Vitiligo may be an immunologically mediated melanocyte destruction. Circulating antibodies to the melanocyte have been found in some patients with vitiligo.[13] In patients with melanoma, vitiligo may occur spontaneously[8,9] or follow immunostimulation with BCG[2] or vaccinia.[11] It is presently thought that BCG and melanoma cells may share a common antigen, so that a response mounted to the BCG will also be directed against the melanoma cells.[14] In the syndrome of Vogt-Koyanagi-Harada,[15,16] in which one observes a prodrome of fever, CNS symptoms (encephalitis or meningitis), depigmentation of hair (poliosis, 80%), vitiligo (60%), uveitis, deafness or tinnitus (50%), and alopecia, an immunologically mediated pathogenesis in which the target cell is the melanocyte[17,18] has also been postulated. Parallels have been proposed between the uveitis of Vogt-Koyanagi-Harada and the uveitis of sympathetic ophthalmia, in which lymphocytes from affected patients but not from normal subjects transform on exposure to uveal pigment.[19] In the present patient, the Vogt-Koyanagi-Harada syndrome developed following excision of metastatic malignant melanoma. In spite of a very high risk of recurrent disease in patients with nodal metastases (24%; five-year survival in patients with therapeutic nodal dissection), this patient has been free of detectable melanoma for 8½ years, suggesting either complete surgical removal or excellent host resistance. Unfortunately, immunologic testing with use of current techniques was not performed at the time of onset of uveitis and depigmentation. Since cytotoxicity has been observed by several authors to occur in normal patients,[20,21] results in a single patient would have been difficult to interpret regardless of the outcome. In the patient who developed vitiligo following vaccinia therapy, a search for serum cytotoxic factors (antibody) was negative even though histologic evidence demonstrating destruction of normal melanocytes was found.[11]

Several studies have attempted to relate the presence or absence of humoral (antibody) and/or cellular reactivity to melanoma cells with stage and/or prognosis of disease. Lewis et al[5] have correlated the presence of antibody with good patient prognosis and the disappearance of antibody with progression of disease and usually death. Similar attempts have been made to correlate lymphocyte cytotoxicity with clinical measurements such as tumor load, activity, and extent of disease. In most reports, cytotoxicity was present irrespective of the clinical status of the patient.[22,23] In some studies, however, more vigorous cytotoxicity was demonstrated in patients with inactive or localized disease than in patients with progressing and disseminated disease.[24,25]

In the Vogt-Koyanagi-Harada syndrome, the uveitis typically precedes the vitiligo.[15] In the two patients who developed vitiligo and uveitis after BCG therapy of melanoma, the vitiligo was noted after six to eight months.[2] In both patients the vitiligo preceded the uveitis. In our patient, the uveitis developed nine months and the vitiligo 14 months following surgical removal of the metastatic melanoma. An immunologic hypothesis is very tempting, relating the development of the Vogt-Koyanagi-Harada syndrome in this patient to the development of immune responsiveness directed at normal melanin-containing tissues as well as malignant melanoma. Even if the development of the Vogt-Koyanagi-Harada syndrome in this patient had been fortuitous, it may be contributing to the favorable course in this patient.

Thomas B. Fitzpatrick, MD, reviewed the manuscript; Masaaki Takahashi, MD, performed the split epidermis-dihydroxyphenylalanine preparation; Daniel Albert, MD, did the follow-up ophthalmologic examination; Lawrence Cherkas provided the photographs; and Gayle Fahey provided technical assistance in the manuscript preparation.

References

1. Sober AJ: Immunology and cutaneous malignant melanoma. *Int J Dermatol* 15:1-18, 1976.
2. Donaldson RC, Canaan SA, McLean RB, et al: Uveitis and vitiligo associated with BCG treatment for malignant melanoma. *Surgery* 76:771-778, 1974.
3. Hellström I, Sjogren HO, Warner G, et al: Blocking of cell-mediated tumor immunity by sera from patients with growing neoplasms. *Int J Cancer* 7:226-237, 1971.
4. Nairn RC, Nind AP, Guli EOG, et al: Antitumor immunoreactivity in patients with malignant melanoma. *Med J Aust* 1:397-403, 1972.
5. Lewis MG, Ikonopisov RL, Nairn RC, et al: Tumor-specific antibodies in human malignant melanoma and their relationship to the extent of disease. *Br Med J* 3:547-552, 1969.
6. Epstein WL, et al: Halo nevi and melanoma. *JAMA* 225:373-377, 1973.
7. Krebs JA: Halo nevus, competent surveillance of potential melanoma? Read before the 33d annual meeting of the American Academy of Dermatology, Chicago, 1974.
8. Frenk E: Dépigmentations vitiligineuses chez des patients atteints de mélanomes malins. *Dermatologica* 139:84-91, 1969.
9. Fodor J, Bodrogi I: Vitiligo and malignant melanoma. *Neoplasma* 22:445-448, 1975.
10. Kärcher KH: Systematisierte Depigmentierung bei strahlenbehandelten Melanomen. *Dermatologica* 120:255-263, 1960.
11. Burdick KH, Hawk W: Vitiligo in a case of vaccinia virus-treated melanoma. *Cancer* 17:708-712, 1964.
12. Grunnet I, et al: Vitiligo and pernicious anemia. *Arch Dermatol* 101:82-85, 1970.
13. Langhof H, Feuerstein M, Schabinski G: Melaninantikörperbildung bei vitiligo. *Hautartz* 16:209-212, 1965.
14. Minden P, Sharpton TR, McClatchy JK: Shared antigens between human malignant melanoma cells and *Mycobacterium bovis* (BCG). *J Immunol* 116:1407-1414, 1976.
15. Ebling FJ, Rook A: Disorders of skin color, in Rook A et al (eds): *Textbook of Dermatology*. Oxford, England, Blackwell Scientific Publications, 1972, p 1278.
16. Howsden SM, Herndon JH, Freeman RG: Vogt-Koyanagi-Harada syndrome and psoriasis. *Arch Dermatol* 108:395-398, 1973.
17. Woods AC, Little MF: Uveal pigment: Hypersensitivity and therapeusis. *Arch Ophthalmol* 9:209-226, 1933.
18. Bruno MG, McPherson SD: Harada's disease. *Am J Ophthalmol* 32:513-522, 1949.
19. Hammer H: Lymphocyte transformation test in sympathetic ophthalmitis and the VKH syndrome. *Br J Ophthalmol* 55:850-852, 1972.
20. Hellström I, Hellström KE, Sjogren H, et al: Destruction of cultivated melanoma cells by lymphocytes from healthy black (North American Negro) donors. *Int J Cancer* 11:116-122, 1973.
21. Morton DL, Malmgren RA, Holmes EC, et al: Demonstration of antibodies against human malignant melanoma by immunofluorescence. *Surgery* 64:233-240, 1968.
22. Mavligit G, Gutlerman JU, McBride C, et al: Tumor-directed immune reactivity and immunotherapy in malignant melanoma. *Prog Exp Tumor Res* 19:222-252, 1974.
23. Currie GA, Lejeune F, Hamilton-Fairley G: Immunization with irradiated tumor cells and specific lymphocyte cytotoxicity in malignant melanoma. *Br Med J* 2:305-310, 1971.
24. Hellström I, Hellström KE: Some recent studies on cellular immunity to human melanomas. *Fed Proc* 32:156-159, 1973.
25. Heppner GH, Stolbach L, Byrne M, et al: Cell-mediated and serum blocking reactivity to tumor antigens in patients with malignant melanoma. *Int J Cancer* 11:245-260, 1973.

Contact Dermatitis to Homomenthyl Salicylate

Maj Robert L. Rietschel, MC, USA, Col Charles W. Lewis, MC, USA

• Two patients with follicular dermatitis were found to have a contact sensitivity to homomenthyl salicylate, a sunscreening chemical present in a commercially available suntan lotion. One patient did not use the product, but her boyfriend did, and contact between the two individuals resulted in a follicular dermatitis developing in her. A second patient with contact dermatitis to homomenthyl salicylate also had a follicular eruption. Both patients appear to represent true allergic sensitivities.

(*Arch Dermatol* 114:442-443, 1978)

Follicular patterns of contact dermatitis have been reported for formaldehyde,[1] nickel, chrome, copper, and fluoride.[2] In the atopic patient, follicular patch tests can be caused by human dander,[3] and similar-appearing periporal reactions have been caused by neomycin.[4] We recently studied a patient with follicular dermatitis that mimicked recurrent disseminate infundibulo-folliculitis[5,6] but proved to be due to homomenthyl salicylate (HMS). A second case of follicular dermatitis to HMS, less puzzling in presentation, is also reported.

REPORT OF CASES

CASE 1.—A 24-year-old nurse was seen at the Brooke Army Medical Center (Fort Sam Houston, Tex) Dermatology Clinic in late April 1975. An eruption of four days' duration that involved the chest, abdomen, upper extremities, and buttocks (Fig 1) had begun approximately 24 hours after a swimming pool party. The lesions were 1- to 2-mm erythematous, follicular papules that were not restricted to sun-exposed areas nor were their numbers increased in areas covered by clothing. Treatment for an irritant dermatitis of unknown origin was initiated with 1% hydrocortisone, 3% salicylic acid, and 20% urea in a water-soluble base. The eruption persisted for three weeks at which time a biopsy was performed and the patient given a 0.1% triamcinolone acetonide cream. Microscopic examination showed infundibular spongiosis and an inflammatory infiltrate, which also involved the surrounding dermis, composed of lymphocytes, histiocytes, and extravasated RBCs (Fig 2). At this point, a diagnosis of infundibulofolliculitis was made. Although her pruritus improved somewhat, the eruption persisted and intensified after weekends at the beach.

After 10 weeks, the patient was given 6 mg of a mixture of betamethasone sodium phosphate and betamethasone acetate suspension (Celestone) intramuscularly and the condition cleared completely in two days. At the same time, the patient's boyfriend moved to another city, but when he returned six weeks later so did the eruption. Once again they had gone to the beach. At this time, questioning revealed that the only product used topically by the patient's boyfriend was a lotion containing homomenthyl salicylate (Coppertone lotion). Patch testing with the Coppertone produced erythema, edema, and vesiculation at 48 hours, which displayed a more prominent follicular pattern at 72 hours. Additional history revealed that contact with the patient's boyfriend accounted for the distribution of the lesions. The ten ingredients in Coppertone (coded) were supplied for patch testing. The patient reacted to only one substance which proved to be HMS. While the concentration of this agent is 8% (w/w) of the commercial product, after evaporation of the water, the sunscreen reaches a concentration of 32% (J. M. Clayton, PhD, written communication, Dec 8, 1975). The ingredients were supplied at their maximum use concentration in mineral oil. Since Fisher[7] recommends testing with a 2% concentration of salicylates, the patch test was repeated at this dilution and was again found to be positive.

CASE 2.—A 57-year-old woman was first seen in late May 1976. She had an erythematous, follicular eruption on the thighs and lower legs confined to the area in which she had applied Coppertone lotion one week before being seen and again three days before her clinic visit. Patch tests were performed with the same ten coded ingredients provided for testing in the first case, with the addition of the 2% HMS. At 48 hours, all patches were negative but both the 2% and 32% HMS patches became positive at four days mimicking the clinical dermatitis. A biopsy specimen from the patch test site showed the identical histopathological changes seen in Fig 2 which is from the first patient's dermatitis. Because of the delayed positive patch tests, the patient was retested with the 2% and 32% HMS. One set of patches were removed at 48 hours and immediately covered with black cardboard to prevent exposure to light. The other set were removed at 24 hours and exposed to 30 seconds of light from a hot quartz lamp through window glass, then left open. At 72 hours, the black cardboard was removed and the reaction intensities were found to be equal. At no time did the light-exposed patches exceed the intensity of the photoprotected patches.

The patient was further patch tested to the following sunscreens with negative results: 3% octyldimethyl-p-aminobenzoic acid, a 3% mixture padimate A and aminobenzoate glyceryl (Eclipse); 2.5% padimate A (Pabafilm gel); and a mixture of 4% cinoxate and 5% menthyl anthranilate (Maxafil cream); and 25% Peruvian balsam.

The dermatitis of both patients resolved on discontinuance of Coppertone lotion.

COMMENT

Contact dermatitis to HMS is rare. We were unable to find any similar reports and the company has no similar complaints on file (J. M. Clayton, PhD, oral communication, March 1976). Our first case was initially misdiagnosed as recurrent disseminate infundibulo-folliculitis. However, most of the reported cases of infundibulo-folliculitis have been in black patients who were refractory to treatment.[6] Since our patient was white and appeared to respond to steroids administered for systemic effect, we continued to seek another possible explanation for her dermatitis. Eventually, the relationship of the boyfriend's presence came to light and the diagnosis of contact dermatitis to HMS was made.

While follicular reaction patterns are generally thought to represent an irritant phenomenon, we believe that

Accepted for publication May 20, 1977.

From the Dermatology Service (Dr Rietschel), Department of Medicine (Dr Lewis), Brooke Army Medical Center, Fort Sam Houston, Tex.

Presented in part at the Patch Test Clinic, American Academy of Dermatology, Chicago, Dec 7, 1976.

Reprint requests to Dermatology Service, Brooke Army Medical Center, Fort Sam Houston, TX 78234 (Dr Rietschel).



Fig 1.—Follicular eruption on abdomen also involved chest, upper extremities, and buttocks.

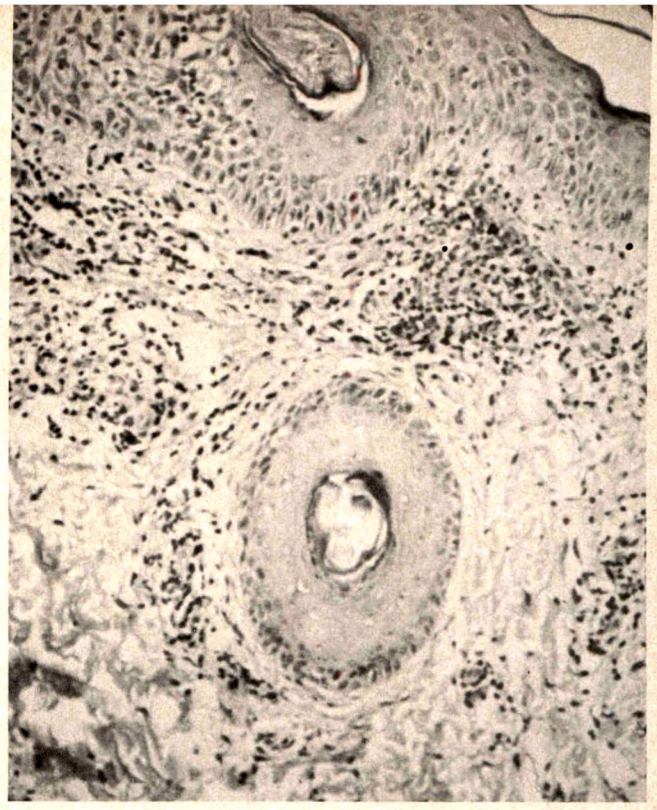

Fig 2.—Infundibular spongiosis and inflammatory infiltrate confined to superficial perifollicular dermis (hematoxylin-eosin section, original magnification ×430).

Fig 3.—Chemical structure of three sunscreens.

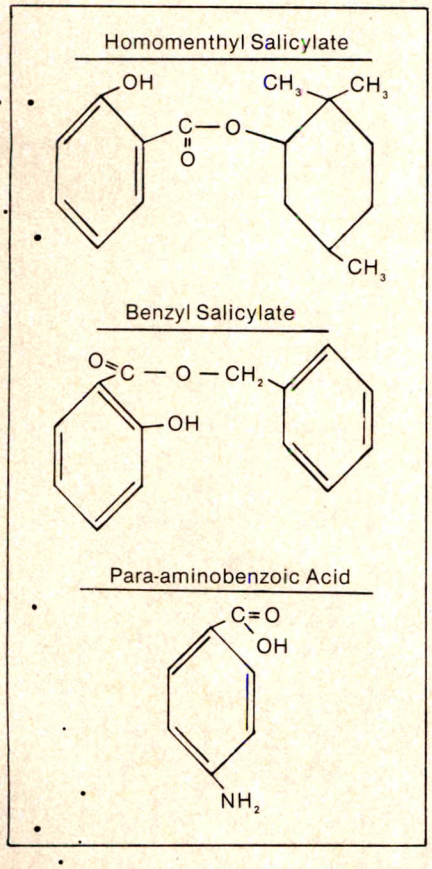

our two patients represent a true allergic contact dermatitis. Our first patient was so sensitive to HMS that her dermatitis was produced by the small amount of material transferred from her boyfriend's skin to her own. These exposures at weekly intervals led to a persistent eruption. The delayed positive patch test in the second patient argues against irritancy. Finally, we tested four normal individuals with both the 2% and 32% concentrations of HMS with negative results.

Benzyl salicylate was the first cosmetic sunscreen used in the United States, and contact sensitivity to benzyl salicylate has been reported.[8,9] Figure 3 demonstrates the chemical structure of HMS, benzyl salicylate, and para-aminobenzoic acid. Our second patient was still available for patch testing, and no cross-reactivity was found with other sunscreens (although benzyl salicylate was not tested). Peruvian balsam cross-reacts with benzyl salicylate,[8] but a patch test to Peruvian balsam was negative.

Why the follicular pattern? Neither of our patients had a history of asthma, hay fever, or eczema. Perhaps HMS is penetrating the stratum corneum via the pilosebaceous apparatus, or perhaps hapten conjugation is occurring to a substance present only in the infundibular region. Regardless, the follicular pattern of both contact dermatitis and patch tests was noted with HMS.

This investigation was funded in part by the Clinical Investigation Service, Brooke Army Medical Center, Fort Sam Houston, Tex.

Plough, Inc supplied the ten ingredients in Coppertone lotion that were used for patch testing.

Nonproprietary Names and Trademarks of Drugs

Triamcinolone acetonide—*Aristocort cream, Kenacort, Kenalog cream.*

Padimate A—*Escalol 506, Paba film, Block Out.*

References

1. Epstein E, Maibach HI: Formaldehyde allergy: Incidence and patch test problems. *Arch Dermatol* 94:186-190, 1966.

2. Becker SW, O'Brien MP: Value of patch tests in dermatology: Special study of follicular reactions. *Arch Dermatol* 79:569-577, 1959.

3. Uehara M, Ofuji S: Patch test reaction to human dander in atopic dermatitis. *Arch Dermatol* 112:951-954, 1976.

4. Jillson OF, Curwen WL, Alexander BR: Problems of contact dermatitis in the atopic individual with reference to neomycin and ragweed oil sensitivity. *Ann Allergy* 17:215-223, 1959.

5. Hitch JM, Lund HZ: Disseminate and recurrent infundibulo-folliculitis: Report of a case. *Arch Dermatol* 97:432-435, 1968.

6. Hitch J, Lund HZ: Disseminate and recurrent infundibulo-folliculitis. *Arch Dermatol* 105:580-583, 1972.

7. Fisher AA: *Contact Dermatitis.* Philadelphia, Lea & Febiger, 1973, pp 211, 406.

8. Rothenborg HW, Hjorth N: Allergy to perfumes from toilet soaps and detergents in patients with dermatitis. *Arch Dermatol* 97:417-421, 1968.

9. Kahn G: Intensified contact sensitization to benzyl salicylate: Phototoxic effect of psoralen therapy. *Arch Dermatol* 103:497-500, 1971.

Clark Wylie Finnerud, MD

1895-1977

Clark Wylie Finnerud, MD, died on Oct 10, 1977, in his home in the heart of the Wisconsin Northwoods. He was 82 years old—one month my junior. He had been incapacitated in recent years by the sequelae of encephalitis. But despite his handicaps, he lived contentedly in the midst of his beloved animals, flowers, and trees, constantly warmed by the devotion of his cherished wife, Gertrude, the loyal companion of his life. He is survived, also, by two daughters, Ann Finnerud Moyer and Mary Finnerud Lewis.

Gertrude told me that Clark had expressed the wish that I write this tribute to his memory. I suppose he selected me, not because I knew him best, but because he recognized that among the thousands who loved him, I was second to none in my affection.

I had few opportunities to observe directly Clark's professional activities. I knew him as a generous and courageous man, a loyal friend, a good companion with a keen sense of humor. I felt that these qualities (of which I shall say more later) plus his exceptional medical capabilities surely helped him to become one of our country's most successful practitioners of dermatology, a physician trusted and loved by his innumerable patients. He was superb in his knowledge and teaching of practical medicine—a star of the first magnitude in the galaxy of distinguished Chicago dermatologists like Pusey, Ormsby, and Rothman.

Finnerud published more than 40 articles and chapters in textbooks, on

Clark Wylie Finnerud, MD

such diversified subjects as skin diseases of children, surgery of the skin, histopathology, many kinds of skin cancers, and syphilis. His publications include a study of the life and work of Ferdinand von Hebra and a study of the Vienna School of Dermatology. (In 1924 and 1925 Clark had taken graduate training in Vienna as well as in Paris and London.) One of his major contributions was his coauthorship and then complete revision of consecutive editions of Oliver S. Ormsby's authoritative textbook, *Diseases of the Skin*. In 1938, I was privileged to be associated with Dr Finnerud on one publication: *Industrial Dermatitis: Definitions and Criteria for Diagnosis*, and it was a joy to collaborate with him.

Clark Finnerud's accomplishments were recognized and honored. He was president and director of many local societies, including the Chicago Dermatological Society (President, 1927); the Chicago Medical Society, and the Illinois Medical Society. In addition, he was a corresponding member of the Viennese, Austrian, and Swedish Dermatological societies, and a fraternity brother of Nu Sigma Mu, Chi Psi, and Sigma Sigma. He was chairman of the section on dermatology of the American Medical Association (1935 to 1938). He served first as a director and subsequently as vice-president of the American Academy of Dermatology (1940), and also as chairman of the academy's scientific exhibit (1940). He was vice-president of the Society for Investigative Dermatology (1941 to 1942); a member of the Subcommittee on Medical Food Requirements of the National Research Council (1943 to 1946); and he represented the United States as a delegate to the International Congress of Dermatology in Stockholm (1957). He was an honorary member and president of the American Dermatological Association (1957 to 1958).

These are not all the positions of honor and responsibility held by Dr Finnerud; a complete list would necessitate a great deal more space. And, a list of his distinguished awards does not give a picture of the man.

Clark Finnerud was a philanthropist, both in the usual sense of the word and in its literal meaning, ie, he was a lover of mankind. His gifts to the causes he believed in were generous and many, including the gift from himself and Gertrude to the University of Wisconsin of a 300-acre tract of land with a large stand of virgin white and Norway pines which was named

by the University "The Finnerud Forest," and valued at over $1,200,000. The gift stipulates that the forest, its flora and its fauna, are to be preserved in their natural state and used for scientific research. By a gift of $50,000 to the Dermatology Foundation, he endowed the Clark Finnerud Award, which is given each year to an outstanding practitioner of dermatology. And he donated a fund to his alma mater, Rush-Presbyterian Medical College, to establish a scholarship that bears his name. In addition, he made a gift to the University of Chicago toward a professorship in Norwegian studies, gifts to Duke University's Department of Dermatology, and gifts to the Howard Young Medical Center in Wisconsin, and to other such institutions.

My opening paragraph implies Clark Finnerud was a lover of nature, an outdoorsman. The Finnerud Forest testifies to the fact that he and Gertrude were longtime conservationists. Among Clark's dominant interests were fishing, hunting, and exploring unspoiled woods. One of his hobbies was a search for the wild terrestrial orchids of Wisconsin and Michigan. He found and photographed all 52 varieties known to grow in Wisconsin.

In somewhat remarkable contrast to Clark's affinity for the wide, wild open spaces was his collection of antique Persian, Caucasian, and Turkish rugs, a hobby in which he was very much interested. Between 1948 and 1956, he donated half of his collection (valued at more than $150,000) of magnificent rugs to the Art Institute of Chicago and half to Augustana College of Rock Island, Ill.

But these recountings of philanthropy, of hobbies, and of medical and other accomplishments do not capture the essence of Clark Finnerud as I knew him. His sensitivity and humor, his generosity and courage became more evident to me at each successive meeting with him.

My first meetings with Clark and Gertrude Finnerud were in 1929 and 1930 when I accompanied Josef Jadassohn and his son, Werner, on a lecture tour across the United States and then traveled with Bruno Bloch on a similar voyage. On both trips we had been showered, from one end of the land to the other, with attention and hospitality beyond description. But nothing equaled the kindness with which Clark Finnerud included me, a raw novice, in every one of the scientific sessions and drew me into the discussions. And nothing compared with the warmth and kindness with which Clark and Gertrude welcomed me at the gala dinners they gave for the distinguished lecturers.

In 1935, when I attended my first meeting of the American Dermatological Association, I was somewhat overawed, greatly frightened, and terribly lonely. This was in the days before wives were welcome, before there were receptions for new members, before there were gatherings to which all members were invited. Who paid attention to me? Who spoke to me? Who made me feel I belonged? Clark Finnerud and Bedford Shelmire, Sr, were among the few.

I could recount many such stories that reveal the unusual considerateness, sensitivity, and kindness that the Finneruds went out of their way to bestow on me and my family. And so could many other of their friends and colleagues recount such stories.

Honors and success like his can easily make a lesser man than Dr Finnerud standoffish, a "stuffed shirt." But Clark remained informal and congenial, at home with men and women of every rank and station. His quick and delightful sense of humor never left him.

In 1959, I was the William Alan Pusey Memorial Lecturer, and Dr Finnerud was my host at the University Club in Chicago. After lunch, he took me to the place of my lecture. As we mounted the broad stone steps of the building, he handed me a long, white, official-looking, sealed envelope with my name on it, saying "Marion, stick this in your pocket and don't open it until after your lecture." I followed his wishes. After my talk, as Clark and I descended the stairs, he said, "Why don't you open the envelope now?" I did so, took out its sole content—a slip of paper on which Clark had written, "Marion, that was the best goldarned lecture I ever heard." This was a typical Finnerudian prank: kind and humorous, the sort for which Clark and his life-long friend, Bedford Shelmire, Sr, were both well-known.

I have not done justice to the many sides of Clark Finnerud's extraordinary character, career, and contributions. But I hope that these few broad strokes and small anecdotes will convey some inkling of how much the life and works of Clark Wylie Finnerud have enriched medicine and dermatology, patients and acquaintances, colleagues, friends, and family. For Clark was indeed an unusual human being; he was a true friend to humanity and to all living things.

MARION B. SULZBERGER, MD
San Francisco

Letters to the Editor

Readers are advised that in view of The Copyright Revision Act of 1976, *all Letters to the Editor submitted for publication must contain on the transmittal letter the following language: "The person(s) undersigned hereby grant the American Medical Association permission to publish this Letter and in addition, hereby assigns all copyright ownership therein to the AMA."*

Contact Dermatitis Due to Clindamycin

To the Editor.—Oral doses of clindamycin hydrochloride capsules (150 to 300 mg daily) are effective in the treatment of acne vulgaris.[1,2] However, since ingestion of this drug can cause severe colitis, it probably should not be used as the drug of choice to treat acne vulgaris. Recently, clindamycin phosphate, which is used for intramuscular and intravenous use, has been used topically in a 1% solution for acne with good results.[3,4] Clindamycin has also been applied topically for acne. I describe a case of contact dermatitis that was due to 1% clindamycin hydrochloride solution.

Report of a Case.—A 33-year-old woman was seen on March 7, 1977, because of excoriated, pruritic acne lesions that involved her face. She had previously taken tetracycline hydrochloride by mouth and used benzoyl peroxide topically. Because these agents had not been helpful, her physician changed her therapy to 1% clindamycin hydrochloride diluted in alcohol. She had used this preparation for two weeks. I suggested that she continue with it and take erythromycin (250 mg) twice daily by mouth.

When seen on March 21, 1977, she complained of itching of her face. She only had evidence of multiple excoriations. I suggested that she apply the clindamycin in a water-washable base (Cetaphil lotion) and take hydroxyzine (Atarax) hydrochloride by mouth.

The patient returned on April 4, 1977. She still had pruritus of her face and had multiple excoriations. She then was treated with minocycline hydrochloride (100 mg/day). In addition, I advised her to patch test herself to the clindamycin in the water-washable lotion and to the lotion itself. When she returned on April 18, 1977, she had a 2+ reaction to the clindamycin in the lotion, but not to the lotion itself. A diagnosis of contact dermatitis due to the clindamycin was made, and this therapy was discontinued.

On June 6, 1977, she was patch tested to a 1% aqueous clindamycin hydrochloride, as well as the other constituents of the capsule, which include lactose, talc, and cornstarch. These agents were applied in a 1% aqueous suspension. The patch tests were read on June 8, 1977. At that time, there was a 2+ reaction to the 1% clindamycin hydrochloride. The other tests were negative.

To rule out the possibility of the positive patch tests being primary irritant reactions, closed patch tests to 1% clindamycin hydrochloride in Cetaphil lotion and also in water were applied to five normal subjects. They were negative in each individual.

Comment.—A number of adverse side effects of systemic clindamycin have been reported. However, no reports of contact dermatitis caused by clindamycin are mentioned in the *Physicians' Desk Reference,*[5] and the Upjohn Company has not received reports of this type of reaction. Topical clindamycin is being used more and more by dermatologists to treat acne, and if a patient should develop dermatitis and/or itching after topical use of this agent, the possible complication of contact dermatitis should be considered.

RALPH J. COSKEY, MD
Detroit

Clyde R. Howse provided the constituent ingredients of clindamycin hydrochloride powder.

Nonproprietary Names and Trademarks of Drugs

Benzoyl peroxide—*Benoxyl, Oxy-5, Persadox, Vanoxide.*
Clindamycin hydrochloride—*Cleocin.*

1. Poulos ET, Tedesco FJ: Acne vulgaris: Double-blind trial comparing tetracycline and clindamycin. *Arch Dermatol* 112:974-976, 1976.
2. Dantzig PI: The safety of long-term clindamycin therapy for acne. *Arch Dermatol* 112:53-54, 1976.
3. Resh W, Stoughton RB: Topically applied antibiotics in acne vulgaris: Clinical response and suppression of *Cornyebacterium acnes* in open comedones. *Arch Dermatol* 112:182-184, 1976.
4. Stoughton RB, Resh W: Topical clindamycin in the control of acne vulgaris. *Cutis* 17:551-554, 1976.
5. *Physicians' Desk Reference.* Oradell, NJ, Medical Economics Inc, 1977, pp 1614-1615.

Unilateral Nevoid Telangiectasia

To the Editor.—In the ARCHIVES (113:486-488, 1977), Wilkin described three patients with unilateral nevoid telangiectasia and reviewed 12 cases previously reported. Recently, we have had occasion to observe a case akin to those mentioned in that article.

Report of a Case.—A 36-year-old woman has suffered since puberty from telangiectasia on the superior right limb, and that also involves the right shoulder, the right scapular area, and the right breast. The palm of the hand is affected. These lesions are strictly unilateral and do not go beyond the mediosternal line, nor behind the line of the spine. These telangiectasias, which fade away totally with vitropression, are asymptomatic. There is no similar history in her family. The lesions remained stable from puberty until the age of 36 years. At this age, the patient had measles, which was confirmed serologically. Following this febrile, infectious episode, numerous telangiectasias continued to appear, always in the cutaneous area defined previously, in an eruptive manner. The number of cutaneous lesions approximately doubled during the attack of measles.

No anomalies were found on auscultation of the vascular system. The blood pressure is symmetric in the two superior limbs. Roentgenologic examination showed no bone anomalies. The overall biological evaluation, including in particular the hepatic tests, was normal.

A cutaneous biopsy specimen showed the number of dermal capillaries to be more numerous than normal, in particular at the level of the superficial dermis, but there were no signs of angioblastic proliferation. These vessels had a thickened wall, layered, and impregnated with a PAS-positive

substance. Their endothelium was slightly turgescent and some mononuclear perivascular infiltrates were present. Orcein stain showed alteration in the elastic fibers, which were rarefied in the superficial dermis, and pock-marked and fragmented in the mid-dermis.

Comment.—This observation leads to two points. First, Wilkin, suggests that estrogens play a role in the pathogenesis of this disorder. In our case, as in those mentioned by Wilkin the lesions appeared at puberty. Since the age of 30 years, our patient has been under gynecological supervision for mastosis. Her menstruation is normal and regular. She did not notice any change in her cutaneous lesions during a previous pregnancy, nor during birth control treatment she followed for a year. Second, the total urinary estrogens were titrated at the moment of the quasi-eruptive appearance of the new telangiectasias. Their level (17 μg/24 hr) was within normal limits (15 to 50 μg/24 hr).

The coincidence between the measles and the eruption of new telangiectasia deserves emphasis. However, we have no satisfactory pathogenic hypothesis to explain this phenomenon.

JEAN-PAUL ORTONNE, MD
GÉRARD GUILLET, MD
HENRI PERROT, MD
Lyon, France

Ulcerative Sarcoidosis

To the Editor.—Ulcerative sarcoidosis is an unusual phenomenon, as Schiffner and Sharma[1] indicated in their recent report. We would like to report another case of a patient with sarcoidosis in whom localized ulcerations developed.

Report of a Case.—A 32-year-old woman was seen in the dermatology clinic of Cook County Hospital, Chicago, in January 1974, with complaints of skin lesions that had appeared on her face. After performing appropriate workup and biopsy, a diagnosis of sarcoidosis was made. At this time, the patient was referred to the eye clinic for evaluation. Investigations in the eye clinic revealed uveitis, and therapy with 50 mg of prednisone, daily, was begun. Systemic steroid therapy was continued in various doses for almost three years and was finally stopped in December 1976, with no evidence of active uveitis.

The patient returned to the dermatology clinic again in February 1977, after about two months without systemic corticosteroid therapy. She then had multiple 1- to 2-cm "punched out" ulcerations (Fig 1) in the pretibial areas bilaterally that were extremely painful. At that time, these unusual lesions prompted us to consider diseases such as collagen vascular disease or cryoglobulinemia as part of the differential diagnosis. Laboratory investigations, including cryoglobulins, antinuclear antibodies, rheumatoid factor, hepatitis-associated antigen, rapid plasma reagin, and direct and indirect immunofluorescence were all negative. The initial skin biopsy specimen, taken from the margin of an active ulcer, failed to show a granulomatous process. A second biopsy specimen of a healing area revealed a noncaseating granuloma (Fig 2).

Comment.—We began therapy with topical corticosteroids and soaks of aluminum subacetate in an attempt to resolve the process without resorting to systemic steroid therapy. James[2] found cutaneous sarcoidal lesions quite resistant to topical therapy, with resolution of the lesions occurring only when systemic therapy was added. Our experience was similar, wherein the ulcers showed almost no tendency toward healing after a two-week trial of topical therapy. Sharma[3] contends, and rightfully so, that skin lesions are not an absolute indication for systemic corticosteroid therapy. However, the pain and disfigurement in this case prompted us to give, at first, 50 mg of prednisone per day. This was rapidly tapered over a period of two weeks to 25 mg per day. At that time, there was slight resolution of the lesions but continued therapy at that dosage eventually resulted in a flare of the ulcerative process. The dose of prednisone was increased, and because we felt the patient would be on long-term therapy, an alternate day dosage of 50 mg per day was begun. After ten days on this regimen all ulcers were either healed or healing. At this writing, the steroid dosage was gradually tapered to 35 mg every other day, and no new ulcerations have been noted.

MARK MEYERS, MD
SIDNEY BARSKY, MD
Chicago

1. Schiffner J, Sharma OM: Ulcerative sarcoidosis: Report of an unusual case. *Arch Dermatol* 113:676-677, 1977.
2. James GD: Dermatological aspects of sarcoidosis. *Q J Med* 28:109, 1959.
3. Sharma OP: Cutaneous sarcoidosis: Clinical features and management. *Chest* 61:320, 1972.

Fig 1.—Ulcerations in pretibial area.

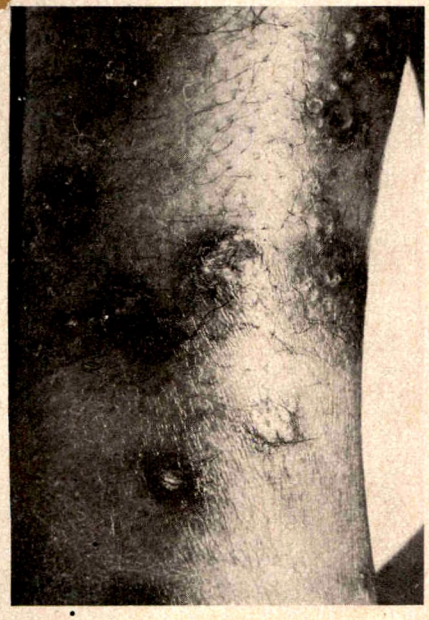

Fig 2.—Biopsy specimen with noncaseating granuloma (hematoxylin-eosin, ×400).

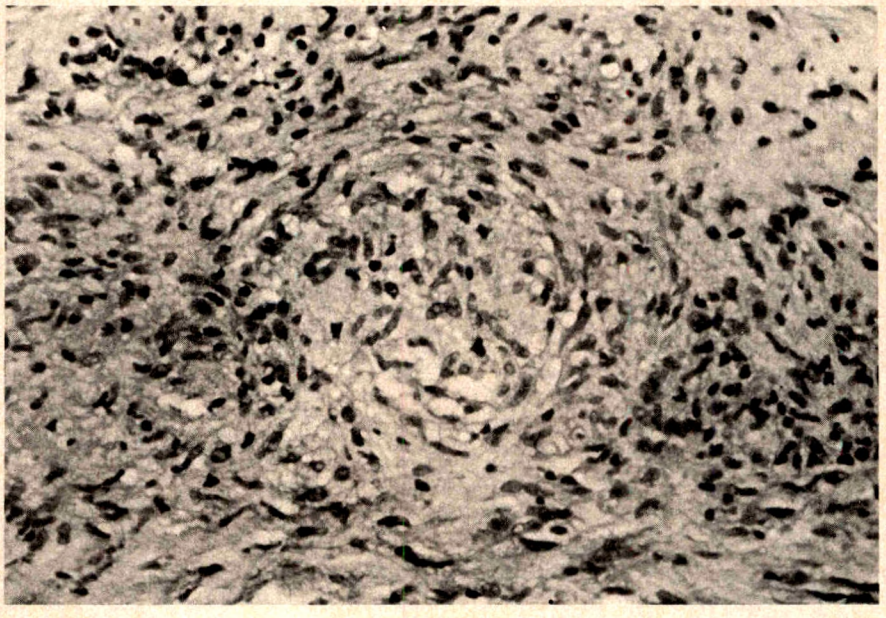

Photo-Onycholysis Secondary to Psoralen Use

To the Editor.—To our knowledge, there are no reports in the medical literature of photo-onycholysis secondary to psoralen use. We report such a case.

Report of a Case.—During the summer of 1976, a healthy 35-year-old woman, who weighed 50 kg, took methoxsalen by mouth on approximately ten occasions (20 to 40 mg/dose). The patient experienced no untoward effects. She was taking no other medication.

In early September, she took 60 mg of methoxsalen, and one to two hours later, she lay out in the late afternoon sun for two hours, face down, hands extended in front of her, dorsa upward. Two to three days later, soreness of all ten fingernails developed. Physical examination revealed onycholysis of the central and proximal portions of all fingernails.

Two months later, transverse depressions were noted on several nails, 2 to 3 mm proximal to the onycholysis.

Comment.—Photo-onycholysis secondary to the tetracyclines is well recognized.[1-3] Onycholysis is also seen associated with nail hardeners,[4] topical use of 5-fluorouracil,[5] enzyme detergent use,[6] thyroid disease, Raynaud's phenomenon, trauma, psoriasis, eczema, lichen planus, and nail infections. Since psoralens are known to be potent photosensitizers, and onycholysis is a recognized result of phototoxicity, the association of psoralen use and onycholysis seems to be a logical one. To our knowledge, however, no such association has been reported. In light of the extensive use of psoralens in the past and the recent well-monitored studies of psoralen photochemotherapy of psoriasis, it is surprising that this association has not previously been noted. Although the association that we report could be fortuitous, we feel the evidence is sufficient to establish probable cause and effect. The horizontal depression found in the nail plate proximal to the area of onycholysis could be the result of a phototoxic insult to the nail matrix.

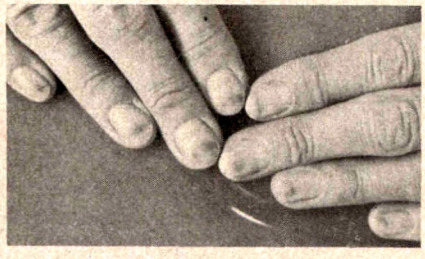

Fig 1.—Onycholytic nails three months after psoralen ingestion and sun exposure.

Fig 2.—Fingernails 4½ months after phototoxic insult. Onycholysis has almost completely resolved. Transverse depressions are present in nail plates at index and middle fingers.

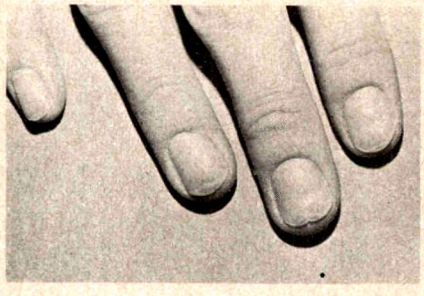

ROBERT C. RAU, MD
FRANKLIN P. FLOWERS, MD
JAMES L. BARRETT, MD
Columbus, Ohio

1. Orentreich N, Harber LC, Tromovitch TA: Photosensitivity and photo-onycholysis due to demethylchlortetracycline. *Arch Dermatol* 83:730-737, 1961.

2. Bettley F, Samman P: Photo-onycholysis. *Proc R Soc Med* 67:28, 1974.

3. Frank SB, Cohen HJ, Minkin W: Photo-onycholysis due to tetracycline hydrochloride and doxycycline. *Arch Dermatol* 103:520-521, 1971.

4. Donsky H: Onycholysis due to nail hardener. *Can Med Assoc J* 96:1375-1376, 1967.

5. Shelley W: Onycholysis due to topical 5-fluorouracil. *Acta Derm Venereol* 52:320-322, 1972.

6. Hodgson G, Mayon-White R: Acute onychia and onycholysis due to an enzyme detergent. *Br Med J* 3:352, 1971.

Herpes Gestationis

To the Editor.—Since the report by Provost and Tomasi[1] in 1973 of complement deposition along the basement membrane in skin of patients with herpes gestationis (HG), there have been a number of reports of immunofluorescence studies in this disease. We recently studied two patients with HG, in which results of immunofluorescence studies were helpful in confirming the diagnosis.

Report of Cases.—CASE 1.—A 30-year-old woman developed a highly pruritic generalized eruption at 18 weeks' gestation during her third pregnancy. Her first pregnancy had been normal. During her second pregnancy in 1974, she experienced a similar problem that persisted from the fifth month of gestation to the third postpartum day. On examination, her condition demonstrated grouped vesicles on an erythematous base and large, gyrate erythematous plaques with peripheral bullae, which measured up to 2 cm in diameter in a generalized distribution that spared only the scalp, face, palms, soles, and mucous membranes. The WBC count was 11,800/cu mm, with 14% eosinophils. A skin biopsy specimen showed a subepidermal vesicle with an intense papillary infiltrate of neutrophiles and eosinophils. Initial treatment with oral pyridoxine hydrochloride (300 mg/day) resulted in a partial remission; however, a severe exacerbation at 30 weeks' gestation necessitated the use of oral corticosteroids. A rapid clearing of lesions was associated with prednisone (30 mg/day). This was tapered gradually, and she was delivered of a normal 2,522-gm male infant at 35 weeks' gestation. A postpartum flare of skin lesions responded to reinstitution of prednisone (30 mg/day), and by two months postpartum, her skin was normal without steroid therapy.

Direct immunofluorescence of involved skin showed C3 and IgM at the basement membrane zone. Indirect immunofluorescence studies of her serum were negative for antibasement zone antibodies and circulating HG factor.

CASE 2.—A 29-year-old woman developed a pruritic vesicular rash on her knees at 14 weeks' gestation of her second pregnancy. Her first pregnancy had been entirely normal. By 18 weeks' gestation, she had a generalized vesiculobullous eruption with grouped 0.3- to 2-cm vesicles on an erythematous base on the neck, back, scapulae, extensor surfaces of extremities, and periumbilical regions. The WBC count was 8,400/cu mm, with 5% eosinophils. A skin biopsy specimen showed a subepidermal vesicle with a neutrophilic papillary infiltrate. She was treated with oral pyridoxine hydrochloride (400 mg/day) throughout the second and third trimesters. Improvement was noted at the end of the third trimester. She was delivered of a normal 3,080-gm female infant at 44 weeks' gestation.

Direct immunofluorescence studies of involved skin showed C3 and IgG at the basement membrane zone. Indirect immunofluorescence studies of her serum were negative for circulating antibasement membrane zone antibodies and HG factor.

Comment.—Our direct immunofluorescence findings are in agreement with the studies that described immunoglobulin and C3 deposition at the basement zone in patients with HG. In both of our patients, no circulating antibasement membrane antibodies or an HG factor were found with the use of standard indirect immunofluorescence techniques.[2,3]

JUDITH H. SCHIFFNER, MD
THOMAS H. REA, MD
FRANCISCO P. QUISMORIO, MD
Los Angeles

1. Provost TT, Tomasi TB Jr: Complement activation via the alternate pathway in skin disease: I. Herpes gestationis, systemic lupus erythematosus and bullous pemphigoid. *J Clin Invest* 52:1779-1787, 1973.

2. Jordon RE, Heine KG, Tappeiner G, et al: The immunopathology of herpes gestationis: Immunofluorescence studies and characterization of "HG factor." *J Clin Invest* 57:1426-1433, 1976.

3. Katz SI, Hertz KC, Yaoita H: Herpes gestationis: Immunopathology and characterization of the HG factor. *J Clin Invest* 57:1434-1441, 1976.

Your input on Rural Health Issues is needed at the 31st National Conference on Rural Health

Regency Hotel/Denver, Colorado
April 5-7, 1978

Building Local Alliances for Rural Health is the theme of this year's Rural Health Conference. Sponsored by the American Medical Association, the goals of the Conference are to:

- Develop and refine skills in utilizing current health resources
- Discuss issues impacting on health care delivery in rural areas
- Provide technical assistance in community organization and problem-solving
- Provide continuing education directly related to the rural practitioner

The Conference will feature major discussions in: Health Manpower; Financing Health Care; Access to Health Care; and Rural Health Care Facilities.

For further information, please send in the coupon.

American Medical Association
Dept. of Meeting Services
535 N. Dearborn
Chicago, IL 60610

Please send me information on the 1978 National Conference on Rural Health.

Name _____

Address _____

City _____

State/Zip _____ S/J

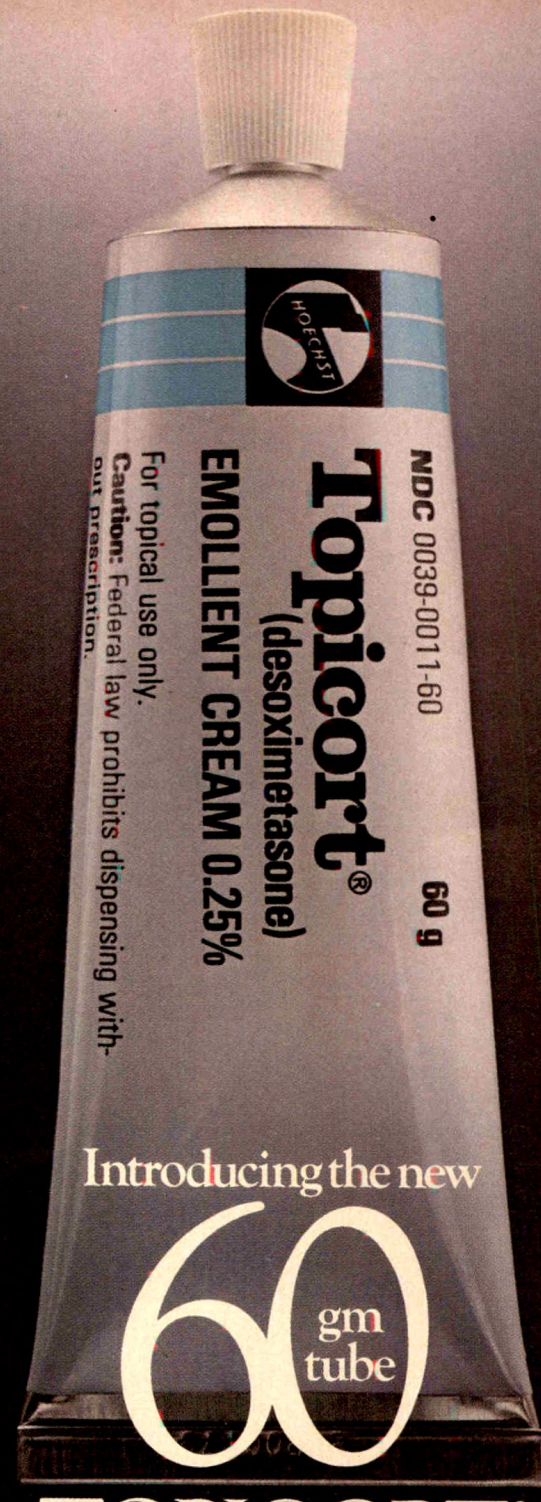

TOPICORT®
(DESOXIMETASONE)
EMOLLIENT CREAM 0.25%

For greater convenience and economy.

HOECHST-ROUSSEL
PHARMACEUTICALS INCORPORATED
SOMERVILLE, NEW JERSEY 08876

This is not an oil bath, but it will be in 15 minutes...

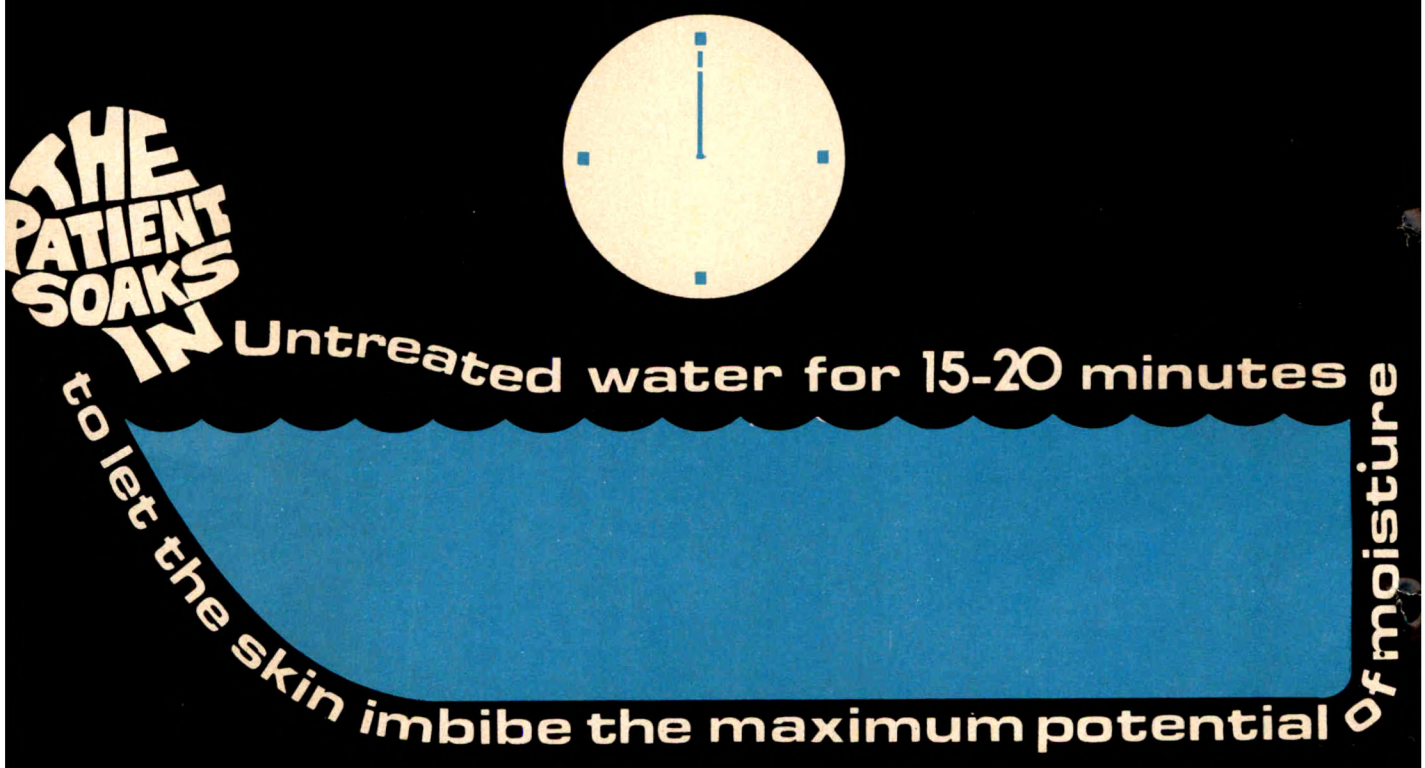

Water, alone, will penetrate the stratum corneum for thorough hydration after a 15 minute soak.

New two-step procedure for the oil bath increases moisturization of dry skin

Rationale:

The missing ingredient in dry skin is water, as Blank[1] pointed out in his pioneering work. Having the patient soak in a tub of pure water for 15 to 20 minutes, *without bath oil of any kind,* will replenish skin moisture effectively. **The use of bath oil at this stage, particularly one miscible in the water, may actually impede absorption of water by occluding the stratum corneum before it has been thoroughly hydrated.**

Procedure 1:

Patient soaks in a tub of comfortably warm water for 15 to 20 minutes to allow the skin to absorb a maximum amount of water in this time.

*Diagrammatic representation of moisturizing the stratum corneum and holding moisture in with an occlusive barrier of oils.

1. Blank, I.H.: Factors which influence the water content of the stratum corneum. *J. Invest. Dermat.*, **18**, 433-40, 1952
2. Blank, I.H.: Cosmetics versus topical therapeutic agents. *J. Soc. Cos. Chem.*, **14**, 433-41, 1963

...after the skin is fully hydrated.





Then is the time to provide the occlusive barrier supplied by SURFOL.*

Rationale:

As Blank later indicated, "Water, alone, almost immediately relieves a sensation of dryness, but this relief is short-lived if the water is allowed to evaporate."[2] Therefore, an occlusive substance should be applied, and the logical time to administer it is *after* the stratum corneum is thoroughly hydrated.

Procedure 2:

Pour one or two capfuls of SURFOL® Post Immersion Bath Oil into the bath *after soaking*. Swish SURFOL through the water; SURFOL spreads quickly in a thin film of *pure, undiluted, unemulsified oils*. Patient soaks an additional five minutes and leaves the bath fully covered with a protective coat of occlusive oils, sealing in essential moisture. Skin not only feels soft and satiny, but is actually more thoroughly hydrated.

The new SURFOL bath method increases hydration of the stratum corneum and provide a better occlusive barrier to seal in essential moisture.

New **surfol**®

Post Immersion Bath Oil

STIEFEL
Logical Dermatologicals
Stiefel Laboratories, Inc.
Oak Hill, N.Y. 12460

The 7 best ways to keep up on what's happening in the practice of medicine...

They're all in American Medical News!

New health care legislation. New federal regulations. New state laws. New delivery systems. Every day there's a lot happening in the world of medicine that could affect the way you practice medicine now and in the future.

What's the best way you have to keep yourself up to date on the latest developments? *American Medical News!* No other publication can match it in providing you with timely, comprehensive coverage of the news in medicine. Here's why:

1 WASHINGTON'S WEEK
Written by a veteran Washington reporter, this weekly column gives you insight into what's happened and what's likely to happen in Congress and the federal regulatory agencies.

2 MEDICINE'S WEEK
Who and what made the news on the national and international medical scene? You'll find all the highlights neatly capsuled in this weekly section.

3 EDITORIALS
Here's where organized medicine speaks out, expressing its views on the issues of concern to the profession, on the practice of medicine, and on the health care of the American people.

4 MY OPINION ARTICLES
In this weekly department, medical leaders and other health care experts share with you their own frank and independent views on topical subjects.

5 FEATURE ARTICLES
Each week, you'll find articles featuring in-depth reporting on subjects of vital interest to you, such as health care legislation before Congress, federal medical and drug regulations, and court actions.

6 IMPACT
This monthly section puts the news of medicine into focus through a thoughtful, in-depth examination of the social forces affecting medicine. In their provocative articles, a wide range of health care authorities seek to explain what is happening in the doctor's world, what forces are shaping your life and practice, and what is likely to come.

7 LETTER PAGE
Here's where you and your colleagues can step up and express your likes and dislikes on what's happening in medicine.

Give *American Medical News* just 30 minutes a week; it will give you all the news you need to know about what's happening in the practice of medicine.

American Medical
NEWS

Keeping your finger on the pulse of medicine

SOLBAR®

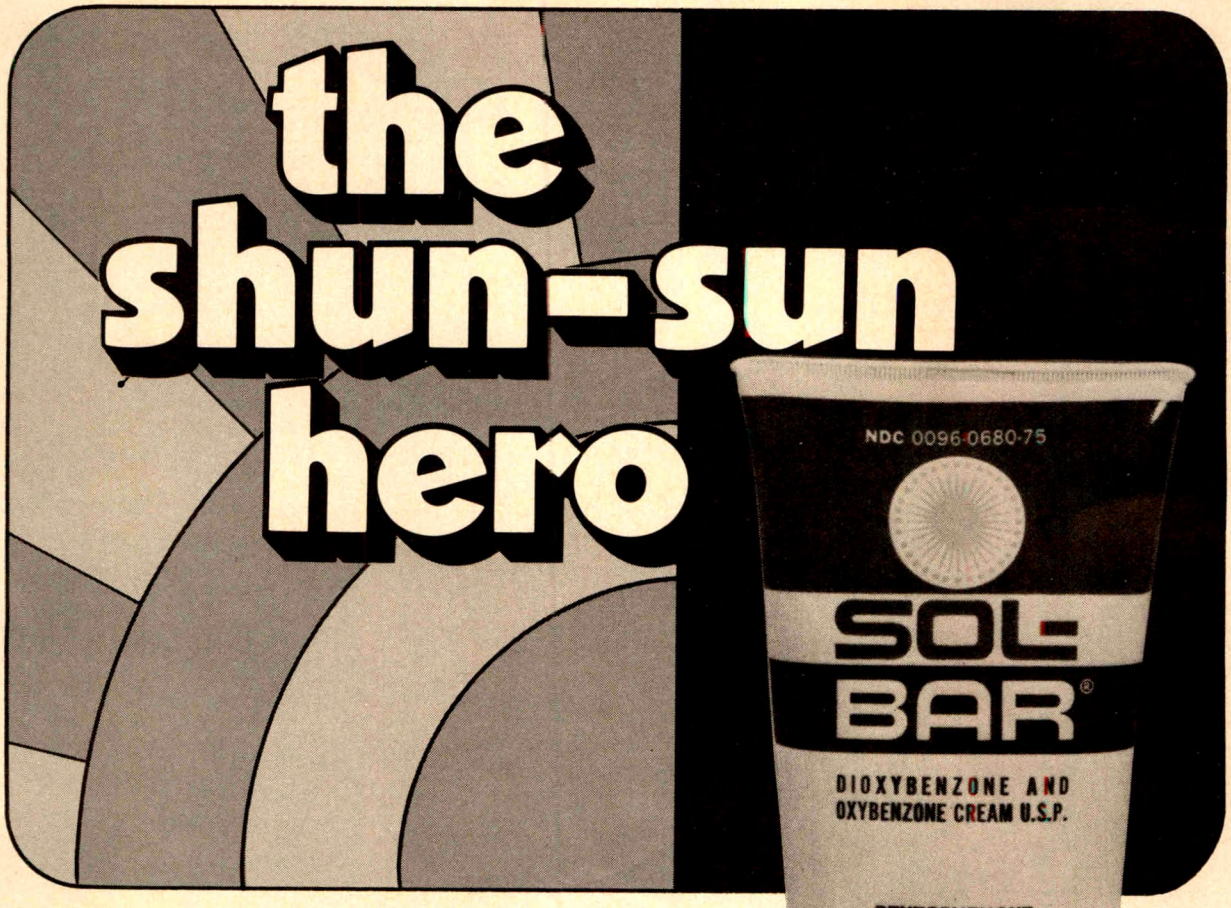

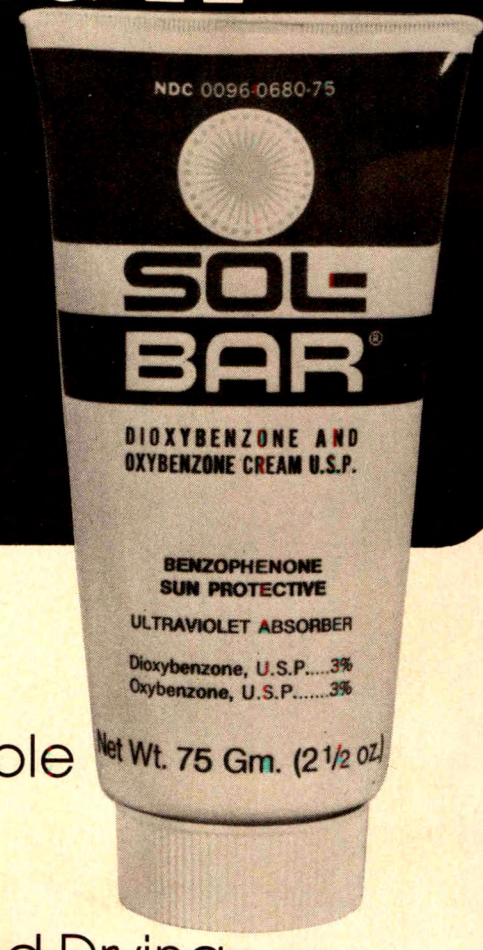

Shuns UVB and UVA —

SOLBAR®

Contains Water Insoluble Benzophenones.

Aids in Preventing Wrinkling, Freckling and Drying due to overexposure to the sun.

PERSŌN & COVEY INC.
GLENDALE, CALIF. 91201

Two volumes of the series

Modern Problems in Paediatrics

Series Editors: F. Falkner, Yellow Springs, Ohio; N. Kretchmer, Bethesda, Md., and E. Rossi, Bern

The first practical guide relating skin diseases to systemic manifestations

Vol. 20

Pediatric Dermatology: Internal and External Medicine

Proceedings of the 2nd International Congress of Pediatric Dermatology, Mexico 1976, selected papers

Editor: R. Ruiz-Maldonado, Mexico
VI + 180 p., 65 fig., 24 tab., 1978
SFr./DM 98.– / approx. US $ 43.75
ISBN 3–8055–2703–9

Just off the press

This is the first work relating the most important skin diseases to systemic manifestations in the pediatric patient. Its contents, which include descriptions of new as well as classic diseases, provide an up-to-date review oriented toward practical needs. The volume's authority derives from the reputation of its authors, contributors who will be recognized as among the most experienced workers in pediatric dermatology.
Subjects, such as the skin and heart in inherited disease and the cutaneous and visceral manifestations of systemic necrotizing vasculitis, carry importance for a large number of specialists in various fields. Other topics are designed to acquaint the reader with the most recently described syndromes, such as the new progeroid syndrome with Fabry-like changes in the heart, great vessels and kidneys. 'HLA antigens in atopic disease' is among those subjects offering new insight into enduring problems. On the whole, the book is an informed and thorough review which every specialist dealing with children or adolescents can use as a practical, up-to-the-minute guide.

Previous Congress on Pediatric Dermatology

Vol. 17

Pediatric Dermatology

Proceedings of the 1st International Symposium on Pediatric Dermatology, Mexico, October 1973

Editor: R. Ruiz-Maldonado, Mexico
VIII + 282 p., 155 fig., 29 tab., 1975
Special price: SFr./DM 73.– / US $ 32.50
ISBN 3–8055–2108–1

Main Headings: Genetics in Pediatric Dermatology · Neonatal Dermatology · Atopic Dermatitis · Acne Juvenile · Systemic Diseases and the Skin in Children · Benign and Malignant Proliferations and Tumors in Children · Bacterial Mycotic and Parasitic Diseases in Children · Lichen sclerosus et atrophicus in Children · Iatrogenic and Factitial Dermatoses in Children.

From a book review
'This book contains important information on topics of interest to microbiologists. It is handsomely printed on glossy paper with excellent halftones. ...Papers on many noninfectious diseases with dermatological manifestations make up most of this volume, including genetic, congenital, allergic, neoplastic, and metabolic disorders.' American Society for Microbiology

S. Karger · Basel · München · Paris · London · New York · Sydney

Order Form
Modern Problems in Paediatrics

__ copy/ies of **Vol. 20: Pediatric Dermatology: Internal and External Medicine**
ISBN 3–8055–2703–9

__ copy/ies of **Vol. 17: Pediatric Dermatology** at the special price of SFr./DM 73.– / US $ 32.50
ISBN 3–8055–2108–1

☐ Prospectus **New Karger Titles in Pediatrics**

☐ Check enclosed
☐ Please invoice

Name _____
Address _____
_____
City/Postal code _____
Country _____
Signature _____

Please send this order form to your bookseller or to:

USA: Albert J. Phiebig Inc., P.O. Box 352, White Plains, NY 10602 (USA)

Europe and all other countries: S. Karger AG, Arnold-Böcklin-Strasse 25, CH–4011 Basel (Switzerland)

wash it. dry it. peel it.

Fostex,® the flexible therapeutic acne wash that degreases, dries, and peels. Easily integrated with all topical or systemic therapy for acne Grades I, II, and III. Convenient and economical Fostex Liquid and Cream are also effective anti-seborrheic shampoos for oily scalps associated with acne. Available as Fostex Cream in 4½ oz. jars, Fostex Cake in 3¾ oz. bars, and Fostex Liquid in 5 oz. plastic bottles.

Fostril,® the flesh-tinted drying and peeling lotion that conceals as it heals. Adaptable to Grades I, II, or III acne, Fostril is available in 1 oz. plastic tubes.

Transact,® the transparent medicated acne gel. A thin film of Transact will dry the oiliest of skin and is ideal for acne on chest, shoulders, and back. Greaseless, nonstaining, with a fresh clean fragrance. In 1 oz. plastic tubes.

WESTWOOD
PHARMACEUTICALS INC.
Buffalo, New York 14213
In Canada, Belleville, Ontario K8N 1E2

Multiple Actinic Keratoses...

the conservative medical approach?

Fluoroplex.® A medical alternative to urgery. The only topical 5-FU available in ow 1% dosage forms...Cream and Solution both paraben free).

The treatment of choice for facial lesions.

Just as effective as higher dosage for Reveals preclinical lesions.[1]

1. Simmonds, W.L. Read before the North American Clinical Dermatologic Soci Athens, Greece, 1975, quoted in Skin and Allergy News 6:3 (Aug) 1975.

Herbert Laboratories
Dermatology Division o
Allergan Pharmaceutica
Irvine, California 92713

UOROPLEX® (fluorouracil) 1% Topical Solution and 1% Topical Cream. **DESCRIPTION:** Fluoroplex® (fluorouracil) 1% Topical Cream is a stable, standardized cream formulation of fluo an emulsion base with the following formula: fluorouracil...1.0%, with: benzyl alcohol (0.5%), ethoxylated stearyl alcohol, mineral oil, isopropyl myristate, sodium hydroxide, and purifie uoroplex (fluorouracil) 1% Topical Solution is a stable, standardized solution of fluorouracil in a clear propylene glycol base with the following formula: fluorouracil...1.0%, with: propylen dium hydroxide-hydrochloric acid to adjust to pH9, and purified water. Fluorouracil is a modified pyrimidine similar to uracil and thymine, with whose metabolism it competes. It is a wh line substance with a melting point of 283±2°C., an empirical formula of $C_4H_3FN_2O_2$ and a molecular weight of 130.08. It has a characteristic ultraviolet absorption maximum of 266 crons in 0.1N HCl. **INDICATIONS:** Fluoroplex (fluorouracil) 1% Topical Solution and Fluoroplex (fluorouracil) 1% Topical Cream are indicated for the topical treatment of multiple actin ratoses. **CONTRAINDICATIONS:** Should not be used in patients with known hypersensitivity to any of the components of the drug. **WARNINGS:** 1) If an occlusive dressing is used, th an increase in the incidence of inflammatory reactions to the adjacent normal skin. 2) The patient should avoid prolonged exposure to sunlight or other forms of ultraviolet irradiatio eatment with Fluoroplex as the intensity of the reaction may be increased. **Use in Pregnancy:** Safety for use in pregnancy has not been established. **PRECAUTIONS:** The medication s plied with care near the eyes, nose and mouth. Excessive reaction in these areas may occur due to irritation from accumulation of drug. To rule out the presence of a frank neoplasm, ould be made of those areas failing to respond to treatment or recurring after treatment. **ADVERSE REACTIONS:** Pain, pruritus, burning, irritation, inflammation, dermatitis and telan ve been reported. Occasionally, hyperpigmentation and scarring have also been reported. **DOSAGE AND ADMINISTRATION:** The patient should be instructed to apply sufficient medi ver the entire face or other affected areas. Apply medication twice daily with non-metallic applicator or fingertips and wash hands afterwards. A treatment period of 2-6 weeks is usually r creasing frequency of application and a longer period of administration with Fluoroplex® may be required on areas other than the head and neck. When Fluoroplex is applied to keratoti sponse occurs with the following sequence: erythema, usually followed by scaling, tenderness, erosion, ulceration, necrosis and re-epithelization. When the inflammatory reaction reaches n, necrosis and ulceration stage, the use of the drug should be terminated. Responses may sometimes occur in areas which appear clinically normal. These may be sites of subclinical actini ratoses which the medication is affecting. **HOW SUPPLIED:** Fluoroplex (fluorouracil) 1% Topical Solution is available in 30 ml plastic dropper bottles. On prescription only. Fluoroplex (flu Topical Cream is available in 30 gm tubes. On prescription only. Avoid freezing. Store at controlled room temperature (59°-86°F).

Short Reports

Kindler's Syndrome

Joseph C. Alper, MD; Howard P. Baden, MD; Lowell A. Goldsmith, MD

In 1954, Kindler described a 14-year-old girl who had cutaneous manifestations of both epidermolysis bullosa and poikiloderma congenitale associated with an extreme photosensitivity.[1] A recent review of the literature does not reveal another case report of this precise association of manifestations.

Report of a Case

A 50-year-old man was noted to have wrinkled skin, particularly of the hands, elbows, and face, at birth. During infancy and childhood, extreme photosensitivity and blistering with slight trauma were noted. A decreased urinary stream became manifest at the age of 12 years.

The patient was inducted into the armed services at the age of 18 years but was ultimately discharged because of severe blistering of the feet while marching. At discharge, he was noted to have wrinkled skin, blisters on the dorsal hands and buccal and labial mucosa, dystrophic teeth and fingernails, and soft, easily bleeding gums.

At the age of 24 years, in 1949, the decrease in urinary stream was severe enough to require urethral dilation. This was performed intermittently until 1963 when a urethroplasty was performed for urethral stricture.

In 1967, esophageal bougienage was required because of dysphagia secondary to esophageal stricture.

In 1969, bilateral cicatricial ectropion was noted. The severity of the left lower lid defect necessitated surgical repair with a skin graft in 1970.

Microscopic hematuria was first noted in late 1974. Evaluation in early 1975 revealed a papillary transitional cell carcinoma, grade 2, of the posterior bladder wall. This was treated by fulguration.

In 1974, results of routine laboratory examinations, including urine for uroporphyrins, coproporphyrins, and RBC porphyrins, were all within normal limits. Esophagoscopy revealed a web-like structure (24 cm) from the gingiva, and urethrography showed a urethral stricture. Four-millimeter punch biopsy specimens of the thigh and foot, which were stained with hematoxylin-eosin, revealed epidermal atrophy, basal vacuolization, and telangiectasia with occasional loose, lamellar fibrosis in the superficial dermis consistent with poikiloderma.

Family history did not show any evidence of cutaneous disease, cancer, or diabetes.

Physical Examination

Abnormal findings were limited to the skin. The skin appeared to be almost universally atrophic, including the palms and soles, as manifested by wrinkling, thinness, and loss of normal cutaneous markings. There were widespread areas of poikiloderma on the extremities and trunk. The changes were accentuated on the extensor aspects of the extremities within which some scaling was present. Several healing erosions were noted over the fingers, but there were no blisters or milia. The nails were present but showed longitudinal ridges and horizontal grooves. There was some ectropion of the lower lids and scarring of the lower lip. The patient was edentulous but had no mucosal lesions.

Comment

The present case shows the following identical features to those of the 14-year-old girl who was described by Kindler[1]: traumatic bulla formation from birth to early adulthood, a reticulated eruption of the trunk and extremities, and extreme photosensitivity.

The question arises now, as it did in 1954, whether this constellation of findings is a distinct entity or the chance occurrence of two rare syndromes. We think that this question cannot be answered with absolute certainty until one of three criteria is met: (1) the basic pathomechanism of the two syndromes under question is discovered; (2) a large number of cases that demonstrate the association of poikiloderma and traumatic bulla formation are observed and reported, thus making chance occurrence of two rare syndromes unlikely; or (3) the discovery of multiple members of several families showing the combination of poikiloderma and traumatic bulla formation, thus defining a distinct genetic syndrome. Thus far, none of these criteria have been met.

On the basis of the clinical manifestations alone, however, Kindler's syndrome seems to be a distinct entity. In a recent review of the poikiloderma syndromes by Weary et al,[2] only the Mendes Da Costa syndrome shows features of bulla formation and poikiloderma similar to those of Kindler's syndrome. However, Mendes Da Costa syndrome is X-linked (Kindler's original case was a girl), the bulla are not related to trauma, and are generalized rather than acral. The associated findings of microcephaly, dwarfism, short fingers, and nail dystrophy are not present in Kindler's syndrome.[1,3] A review of the English literature from 1971 to the present does not reveal any further cases of traumatic bulla formation and poikiloderma.

The possibility that Kindler's syndrome represents a rare form of epidermolysis bullosa associated with poikiloderma exists. Both syndromes have in common involvement of the mucosae of the gastrointestinal and genitourinary tracts and conjunctiva.[4,5] However, if Kindler's syndrome is eventually proved to have a genetic origin and the poikiloderma is always associated with the traumatic bullae in each family, then it is still an entity distinct from the presently well-described genetic forms of epidermolysis bullosa.

Finally, we raise the possibility that Kindler's syndrome may be associated with a predisposition to malignancy. Our patient has had two independent malignant neoplasms: a squamous cell carcinoma of the lower lip and a transitional cell carcinoma of the bladder. Although the squamous cell carcinoma can be explained purely on the basis of sun exposure in lightly pigmented skin, the bladder carcinoma cannot. Perhaps the long-term erosion and regeneration of mucosal surfaces predisposes these regions to the development of a mitotic process. Therefore, we suggest that patients with Kindler's syndrome should be followed up carefully for the development of malignant neoplasms, particularly of the sun-exposed areas and the mucosal areas of the body.

From the Sub-Section of Dermatology, Brown University and Division of Dermatology, Department of Medicine, Roger Williams General Hospital, Providence, RI (Dr Alper), the Department of Dermatology, Harvard Medical School, Massachusetts General Hospital, Boston (Dr Baden), and the Department of Dermatology, Duke University, Durham, NC (Dr Goldsmith).

Reprints not available.

References

1. Kindler T: Congenital poikiloderma with traumatic bulla formation and progressive cutaneous atrophy. *Br J Dermatol* 66:104-111, 1954.

2. Weary PE, Manley WF, Graham GF: Hereditary acrokeratotic poikiloderma. *Arch Dermatol* 103:409-422, 1971.

3. Pegum JS, Ramsay CA: X-linked epidermolysis bullosa (Mendes Da Costa), poikiloderma, retarded growth. *Proc R Soc Med* 66:234-235, 1973.

4. Yakya MB: Esophageal involvement in epidermolysis bullosa. *Am J Gastroenterol* 62:145-147, 1974.

5. Kretkowski RC: Urinary tract involvement in epidermolysis bullosa. *Pediatrics* 51:938-941, 1973.

Bromoderma

Stephen Z. Smith, MD, S. Randolph Scheen, MD

Despite the withdrawal of bromide from the prescription pharmacopoeia, some proprietary products contain substantial amounts of bromide salts.[1] Therefore, potentially toxic amounts of bromide are readily available over the counter. We report this case of bromoderma to emphasize the presence of bromide in the pharmacopoeia and the importance of surveillance for its clinical presentation.

Report of a Case

A 41-year-old woman had a six-month history of an erythematous pustular eruption that involved primarily the lower legs. The thighs, upper extremities, and face were less affected. Four months after the onset of this eruption, larger bullous lesions that were filled with purulent material developed. Some of these lesions subsequently developed deep crater, ecthymatiform ulcers. In the month prior to seeking medical attention, strikingly large vegetative (fungoid) plaques with elevated papillomatous borders developed (Fig 1).

The central portion of the plaques on her legs was studded with small pustules. Slight pressure on these lesions discharged a thick purulent exudate. A few lesions had bullae that contained a seropurulent material. Scattered erythematous pustules intervened between these plaques. No tenderness, pain, or limitation of movement was present.

A biopsy specimen of a representative lesion at its border is shown in Fig 2. Marked papillomatosis and pseudocarcinomatous hyperplasia is present. Intraepidermal and numerous dermal abscesses that contained neutrophils, eosinophils, monocytes, and desquamated squamous cells are present.

Culture of the purulent and biopsy material for bacteria, fungi, acid-fast bacilli, atypical acid-fast bacilli, and leishmania at 32 and 37 C failed to reveal organisms.

The patient had been taking a mixture of sodium bromide, potassium bromide, ammonium bromide, niacinamide, and thiamine (Nervine) as a sedative several weeks prior to the onset and continuous with the development of her skin lesions. No quantitative history could be ascertained. The sedative effect apparently became increasingly impotent, which necessitated increasing her daily intake. She became increasingly anxious and used the drug during the day, as well.

A serum bromide level of 68 mEq/liter (normal, 0 to 5 mEq/liter) with a serum sodium level of 141 mEq/liter, a serum chloride level of 102 mEq/liter, a serum potassium level of 4.1 mEq/liter, and a serum carbon dioxide content of 24 mEq/liter was found on admission. The blood toxology levels for other drugs were negative.

She was treated with Burow's 1:20 wet dressings and betamethasone (Valisone Spray) valerate until the lesions began to dry. Within two to three days, only betamethasone (Valisone Cream) was required. By the fifth hospital day, her serum bromide level was 50.4 mEq/liter, and after three weeks, it was 1.7 mEq/liter. Hyperpigmentation marked the previously involved sites on the legs, and no scarring resulted. The patient no longer takes bromides and has had no recurrence.

Comment

Acute bromide intoxication is unlikely as gastrointestinal (GI) irritation and vomiting follow substantial ingestion. Usually, the user will take bromides in recommended amounts initially in the hopes of achieving the desired effect. The habit of "feeding at the bromide bottle" is often developed. Unfortunately, the bromide ion is slowly excreted. Long-term ingestion and sluggish excretion combine to permit dangerous accumulation of bromide in the body.

Bromide intoxication affects the nervous[2] and GI[3] systems. The skin responds to the bromides with hyperpigmentation, photosensitivity, and macular eruptions[4]; it also responds with large fungoid tumefactions, erythematous papules, yellowish exudative plaques, and necrotic ulcers.[5]

The sudden onset of severe, erythematous pustular and cystic acne complicated by small ulcerations is included in the differential diagnosis of acneform eruptions. However, the most familiar cutaneous lesion is the pustular plaque, particularly on the legs, which follows rapidly after an initial erythematous papule. This lesion can be confused with deep fungal infection, particularly blastomycosis and chromoblastomycosis, pyoderma gangrenosum, mycosis fungoides, atypical mycobacteria, or pemphigus vegetans. Histologically, the presence of intraepidermal abscesses, papillomatosis, and eosinophils must be differentiated from deep fungal infection, pemphigus vegetans, and pyoderma gangrenosum.

Various treatments for bromism have been used,[6] including the administration of sodium and ammonium chloride, ethacrynic acid (Edecrin) and mannitol, and thiazides. The rapid resolution of our patient's lesions and stabilization of her mental status were accomplished with topical therapy alone. This was remarkable in view of the slow decline in her bromide level.

Fig 1.—Multiple vegetative and ulcerating lesions with elevated papillomatous borders.

Fig 2.—Intraepidermal abscess containing desquamated epidermal cells and mixed infiltrate (hematoxylin-eosin, original magnification ×150).

Steven Hodge, MD, prepared the photomicrographs; Sandra McCauley assisted in this study.

References

1. Ewing JA, Grant WJ: The bromide hazard. *South Med J* 58:148-152, 1965.
2. Carney MWP: Five cases of bromism. *Lancet* 2:523-525, 1971.

From the Department of Dermatology, University of Louisville School of Medicine, Kentucky.

Reprints not available.

3. Emery AW, Richards AG: Bromide poisoning over the counter. *Can Med Assoc J* 89:354-355, 1963.
4. Sutton RL, Sutton RL Jr: *Diseases of the Skin*, ed 9. St Louis, CV Mosby Co, 1935, pp 442-443.
5. Tollman M: Bromoderma. *Arch Dermatol* 90:236-237, 1964.
6. Adamson JS, Flanigan WJ, Ackerman GL: Treatment of bromide intoxication with ethacrynic acid and mannitol diuresis. *Ann Intern Med* 65:749-752, 1966.

Cysticercus cellulosae Cutis

Lt Comdr David Schlossberg, MC, USNR, Lt Comdr Jon T. Mader, MC, USNR

Human infections with *Taenia solium*, the pork tapeworm, are rare in the United States. We recently encountered a patient infected with both the adult worm and the larval stage of *T solium*. The clinical presentation was that of a subcutaneous nodule, representing cysticercosis of the skin, known as *Cysticercus cellulosae* cutis.

Report of a Case

A 20-year-old Filipino woman had a nodule in her left calf. At the age of 15, she had had a similar mass removed from her left thigh. Although the current lesion had been present for two years, it had become more painful during the last six months. The patient also complained of abdominal cramping and a 9-kg weight loss. She readily admitted to having eaten raw pork frequently.

On physical examination, a 1 × 2-cm subcutaneous nodule was evident on the left calf. Laboratory evaluation of several stool samples demonstrated the eggs of *Taenia*, *Ascaris*, *Trichuris*, and hookworm. Liver and renal functions were normal. The creatinine phosphokinase value was less than 2 units/ml. X-ray films of the chest, skull, pelvis, and thighs were normal. Specifically, no calcified lesions were noted. Electroencephalogram and ECG were normal. The nodule was excised, and histologic findings were compatible with the larval stage of *T solium* (Figure).

The patient first received quinacrine hydrochloride and antiemetics, and then she received mebendazole (Vermox) for her *Ascaris*, *Trichuris*, and hookworm infections. Since her hospitalization, she has done well. Repeated examinations of the stool for ova and parasites have been negative, and she has regained her lost weight.

COMMENT

This patient had both intestinal infection with *T solium* (taeniasis) and infection with the larval stage of the tapeworm (cysticercosis). Man acquires *T solium* by eating infected pork that has not been cooked thoroughly. The encysted larvae then excyst, and the organism develops in the jejunum into an egg-producing adult. The pig, which is the usual intermediate host, then ingests the excreted eggs. In the pig, the larvae hatch from the eggs and spread via the bloodstream to striated muscles, causing cysticercosis, and the cycle begins again. If man happens to ingest the eggs, he may develop cysticercosis also. This occurs either by fecal-oral contamination or by autoinfection, the latter via regurgitation of eggs into the stomach in a patient with intestinal infection. Then, just as in the usual intermediate host, the larvae may become bloodborne to striated muscle or to brain, skin, eye, liver, heart, lung, and peritoneum.[1]

The parasite is widespread, particularly in Central and South America, Africa, India, and China. Its rarity in man in the United States results from safeguards against hogs' feeding on human feces. However, increasing world travel has made such organisms accessible to an unprecedented number of individuals not living in endemic areas. The subcutaneous lesions, *Cysticercus cellulosae* cutis, are firm, elastic, round, painless nodules that histologically resemble lesions that may be found in other parts of the body. These subcutaneous lesions may caseate and calcify and thus are visible occasionally on x-ray films.[2] Other than biopsy, serologic testing may be helpful. The indirect hemagglutination (IHA) is probably the most effective test, but false-negative results are encountered, and false-positive results may be seen with hydatid disease, *T saginata*, and *Coenurus* infection. It appears that the sensitivity of the IHA is related to the degree of infection.[3]

The treatment of cysticercosis is surgical removal, although certain localization, eg, intracerebral, obviates a surgical approach. However, intestinal infection with the adult tapeworm is amenable to medical therapy, and treatment may be undertaken with either niclosamide (Yomesan) or quinacrine (Atabrine). An objection to the use of niclosamide,

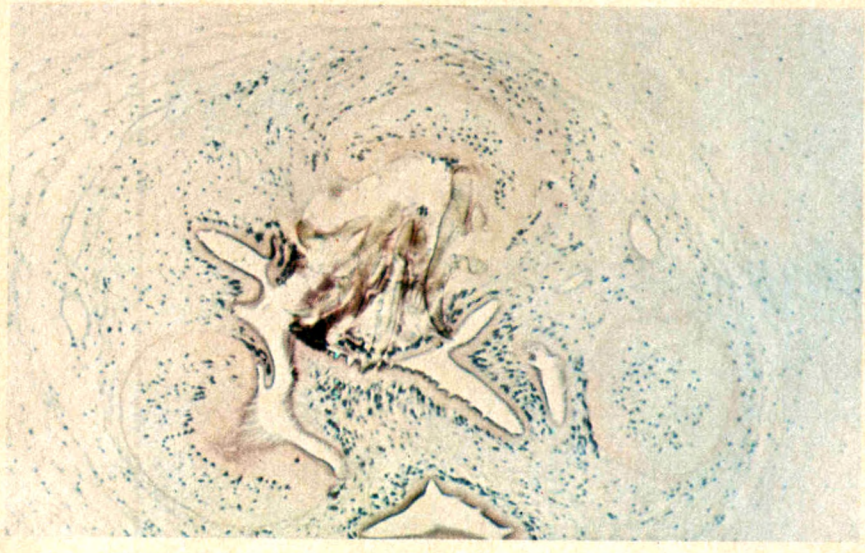

Biopsy section shows scolex with both suckers and hooks visible.

From the Infectious Disease Branch, Internal Medicine Service, Naval Regional Medical Center; Portsmouth, Va. Lt Comdr Mader is now at the University of Texas Medical Branch, Galveston.

The opinions or assertions contained herein are those of the authors and are not to be construed as official or reflecting the views of the Department of the Navy or the Department of Defense.

Reprint request to Infectious Disease Branch, Internal Medicine Service, Naval Regional Medical Center, Portsmouth, VA 23708 (Lt Comdr Schlossberg).

which is used in other tapeworm infections, is that large numbers of eggs may be released in the intestine as the adult tapeworm is macerated, and some believe that these eggs may penetrate the mucosa, circulate to other tissues, and cause cysticercosis. Some authorities consider this possibility more theoretical than real, but others prefer to treat this infection with quinacrine instead.[4]

Although *T solium* infections are rare in the United States, the peripatetic habits of modern Americans, coupled with the steady influx of potential patients from endemic areas, makes an awareness of this infection incumbent upon the American physician.

The Figure was obtained through the Medical Photography Department of the Naval Regional Medical Center.

References

1. Brown HW: *Basic Clinical Parasitology*. New York, Appleton-Century-Crofts, 1975.
2. Moschella, SL: *Dermatology*. Moschella, Pillsbury, Hurley. Philadelphia, WB Saunders Co, 1975.
3. Lennete EH, Spaulding EH, Truant JP (eds): *Manual of Clinical Microbiology*. Washington, DC, American Society for Microbiology, 1974.
4. Most H: Treatment of common parasitic infections on man encountered in the United States. *N Engl J Med* 287:495-498, 1972.

Perianal Basal Cell Carcinoma

Capt Eric W. Kraus, MC, USA

The reports of basal cell carcinoma (BCC) of the perianal and anal area are very infrequent in the dermatologic literature. It is important to distinguish this relatively benign carcinoma from other more aggressive anal carcinomas that may be strikingly similar histologically.

REPORT OF A CASE

An 82-year-old woman who was hospitalized on the gastrointestinal service for a large gastric ulcer was referred to the dermatology clinic in February 1977 with a large posterior perianal ulcer. It was mildly pruritic and had been present for an unknown period of time. She denied any previous roentgenographic therapy to the area.

On physical examination a 3- × 4-cm, sharply marginated "kissing" lesion with a firm white border and ulcerated erythematous center was noted just posterior to the anus; it involved the posterior perianal skin and extended onto the medial buttock bilaterally (Fig 1). Anoscopy and a rectal digital examination were normal. An esophagogastroduodenoscopy revealed a 1.2- × 2.4-cm benign gastric ulcer.

A biopsy specimen of the perianal lesion (Fig 2) showed multiple foci of medium-sized, irregularly shaped basophilic cells with moderately pleomorphic nuclei that demonstrated marginal nuclear palisading and with a small amount of mucin in the stroma between the cells within the superficial dermis. Some foci arising from the overlying epidermis demonstrated focal squamous differentiation. The foci were surrounded by a dense infiltrate of chronic inflammatory cells and consisted mainly of plasma cells. These histological features were most consistent with BCC; however, because of the location of this lesion, basaloid (cloacogenic) carcinoma of the anus was considered.

Results of routine laboratory examination and liver function studies and a chest roentgenogram were normal.

The patient was referred to the plastic surgery service for local excision and a Limberg rotation flap.

COMMENT

Carcinoma of the anus may arise from any portion of the anal canal epithelium. At the proximal end, a simple columnar mucosa can give rise to an adenocarcinoma, while the transitional or stratified columnar epithelium causes basaloid (cloacogenic) carcinoma. The stratified squamous epithelium of the distal anal canal and the adjoining perianal skin can give rise to BCC and squamous cell carcinoma (SCC).

The clinical differential diagnosis of perianal and anal lesions include Bowen's disease, extramammary Paget's disease, BCC, SCC, basaloid (cloacogenic) carcinoma, and infectious ulcers ranging from *Candida* to cutaneous amebiasis.

About 100 cases of BCC of the distal anal canal and perianal skin have been reported, mainly in the surgical literature.[1-7] These lesions all responded to local excision with excellent five-year survival rates.[1-7] Several cases that were originally believed to be BCC of the anal canal with metastasis were, in reality, basaloid (cloacogenic) carcinomas.[1,2] Histologically, basaloid (cloacogenic) carcinomas have features of both squamous and BCC, but their aggressiveness equals that of a

Fig 1.—Posterior perianal ulcer.

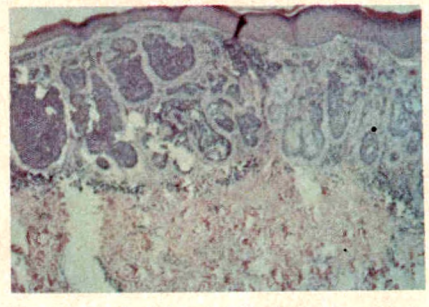

Fig 2.—Foci of basophilic tumor nests in superficial dermis (hematoxylin-eosin, original magnification ×40).

From the Division of Dermatology, Department of Medicine, Brooke Army Medical Center, Fort Sam Houston.

Read in part before the Southern Medical Association Dermatology Section, Dallas, Nov 8, 1977.

The opinions expressed herein are those of the author and are not necessarily those of the US Army.

Reprints not available.

SCC of the anal canal with combined abdominoperineal resection as the treatment of choice.[6-7] Basaloid (cloacogenic) carcinoma is a malignancy of the anal canal with the possibility of extension onto perianal skin, while BCC involves mainly the perianal skin with extension into the distal anal canal.

This case clinically began on perianal skin with no involvement of the anal canal and histologically was most consistent with BCC. Simple excision was therefore the treatment of choice.

Funds for color reproductions were donated by Westwood Pharmaceuticals, Incorporated.

References

1. Armitage G, Smith I: Rodent ulcer of anus. *Br J Surg* 42:395-398, 1955.
2. Matt JG, Dilger JT: Basal cell carcinoma of the anus. *Am Surg* 22:886-893, 1956.
3. Wittoesch JH, Woolner LB, Jackman RJ: Basal cell epithelioma and basaloid lesions of the anus. *Surg Gynecol Obstet* 104:75-80, 1957.
4. Bunstock WH: Basal cell carcinoma of the anus. *Am J Surg* 95:822-825, 1958.
5. Rosenthal D: Basal cell carcinoma of the anus: Report of two cases. *Dis Colon Rectum* 10:397-400, 1967.
6. Möller C, Saksela E: Cancer of the anus and anal canal. *Acta Chir Scand* 136:340-348, 1970.
7. Beahrs OH, Wilson SM: Carcinoma of the anus. *Am Surg* 184:422-428, 1976.

Breast Carcinoma Metastatic to the Eyelids

Virginia M. Weimar, MD; Roger I. Ceilley, MD; C. Norman Hurwitz, MD

Metastatic tumors to the eyelids are rare and metastasis in the absence of an overt primary tumor is even more uncommon. About 30 cases of breast carcinoma metastatic to the eyelids have been reported in the American literature, mainly by ophthalmologists or pathologists. The purpose of this paper is to alert dermatologists to this unusual problem by reporting a patient who had eyelid metastases prior to the recognition of her primary breast carcinoma.

REPORT OF A CASE

A 61-year-old woman was first examined in August 1975 for erythema and edema of the right eyelids of five months' duration and similar involvement of the skin surrounding the left medial canthus of two weeks' duration. She denied excessive lacrimation, itching, or pain in the eyes, and denied contact with nail polish, eye drops, false eyelashes, or eye cosmetics. The right eyelids, right periorbital tissues, and skin surrounding the left medial canthus were erythematous, edematous, and slightly indurated (Figure). Tenderness and increased warmth were absent and the lacrimal canaliculi drained freely. There were no other skin lesions, breast masses, or enlarged lymph nodes.

A punch biopsy specimen from the right upper eyelid showed metastatic, poorly differentiated adenocarcinoma that was believed to be consistent with a primary tumor in the breast. Results of the following laboratory studies were within normal limits: complete blood count, thyroid function tests, and blood chemistries. An ECG, EEG, chest and sinus roentgenograms, excretory urogram, barium enema, upper gastrointestinal series, sigmoidoscopy, and scans of the liver, spleen, brain, and bones were also normal. Xero-mammography showed several lymph nodes up to 2 cm in diameter in the right axilla, but the breasts were interpreted as normal.

A surgeon palpated a prominent right axillary fat pad and found a nodule in the right breast. A biopsy specimen of this nodule and a right axillary node showed infiltrating ductal carcinoma. The patient was then treated with radiotherapy to the eyelids that resulted in regression of the metastases. She received no further treatment to the right breast but underwent palliative bilateral adrenalectomy, at which time a liver biopsy specimen and an incidental splenectomy showed widely disseminated metastases in both adrenals, the liver, and the spleen. She has been clinically stable on a regimen of chemotherapy and has had no recurrence of the eyelid lesions to the present time.

COMMENT

Eyelid metastases have been reported with carcinoma of the gastrointestinal tract, breast, and kidneys.[1] According to Riley, 40% of the eyelid metastases were associated with breast carcinoma, 40% with malignant melanoma, and the remainder with carcinoma of the stomach (15%) or lung (6%).[2] Eyelid metastases from breast cancer usually occur after the primary lesion has been diagnosed.[2,3] Rarely, as in our patient, the eyelid metastases present before the primary breast cancer manifests itself.

The clinical appearance of breast carcinoma metastatic to the eyelids may be either a solitary, painless, noninflamed nodule, or a diffuse, painless, red or dusky induration.[2,3] Most of the lesions are unilateral. Solitary nodules can be confused with chalazion.[3,4] The differential diagnosis of the diffuse lesions includes myxedema, sarcoidosis, foreign body reaction, periorbital cellulitis, amyloidosis, papillomas, dermatomyositis, trichinosis, and allergic contact dermatitis.

Metastatic breast carcinoma should be added to the list of causes of eyelid edema. Although most of the cases occur in patients already known to have breast carcinoma, occasionally a patient will have eyelid lesions prior to the diagnosis of the primary neoplasm, and in these cases, an eyelid biopsy can be very helpful.

Swelling and erythema of eyelids caused by metastatic breast carcinoma. Suture in right upper lid indicates biopsy site.

Jack R. Scherer, MD, Columbus, Ind, supplied the clinical photographs. Westwood Pharmaceuticals, Inc, Buffalo, NY, financed the cost of the color reproductions.

References

1. Hogan MJ, Zimmerman LE: *Ophthalmic Pathology: An Atlas and Textbook*, ed 2. Philadelphia, WB Saunders Co, 1962.
2. Riley FC: Metastatic tumors of the eyelids. *Am J Ophthalmol* 69:259-264, 1970.
3. Hood CI, Font RL, Zimmerman LE: Metastatic mammary carcinoma in the eyelid with histiocytoid appearance. *Cancer* 31:793-800, 1973.
4. Weinstein GW, Goldman JN: Metastatic adenocarcinoma of the breast masquerading as chalazion. *Am J Ophthalmol* 56:960-963, 1963.

From the Departments of Dermatology (Drs Weimar and Ceilley) and Pathology (Dr Hurwitz), University of Iowa Hospitals and Clinics, Iowa City.

Reprints not available.

New measures of response in psoriasis patients

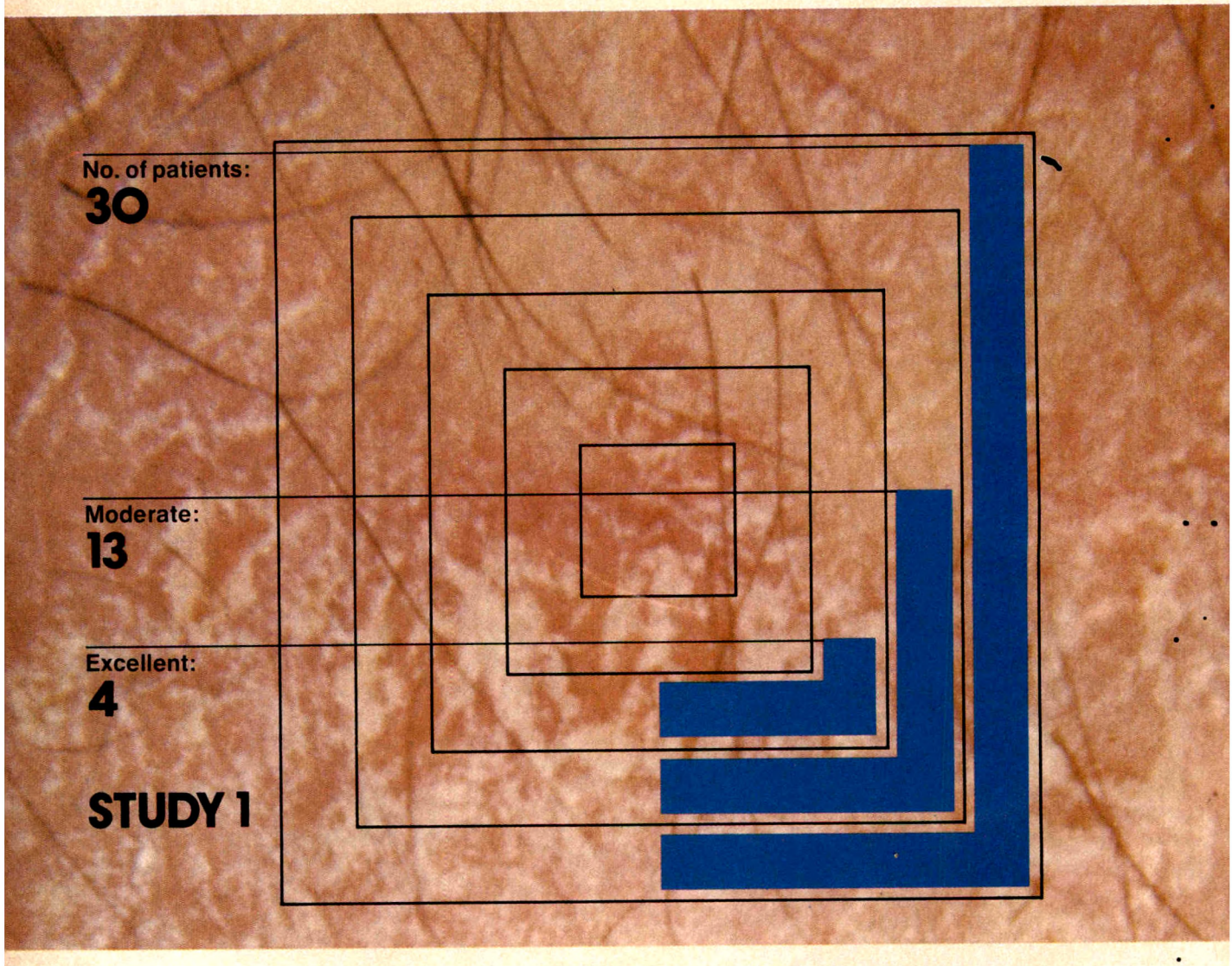

ARISTOCORT-A (Triamcinolone Acetonide 0.1%) Cream was applied t.i.d. without occlusion for 14 days, by a total of 60 patients with psoriasis, in 2 similar studies.*

The % of moderate or excellent response was 57% in Study 1 and 50% in Study 2. A combined overall response rate of 90% was achieved if 22 patients showing slight response are included.*

■ Overall patient acceptance of the Cream in both these studies was high, when evaluated against 10 criteria.

*Data on file, Lederle Laboratories, Dept. of Medical Research

New studies show 50-57% moderate or excellent response in 14 days

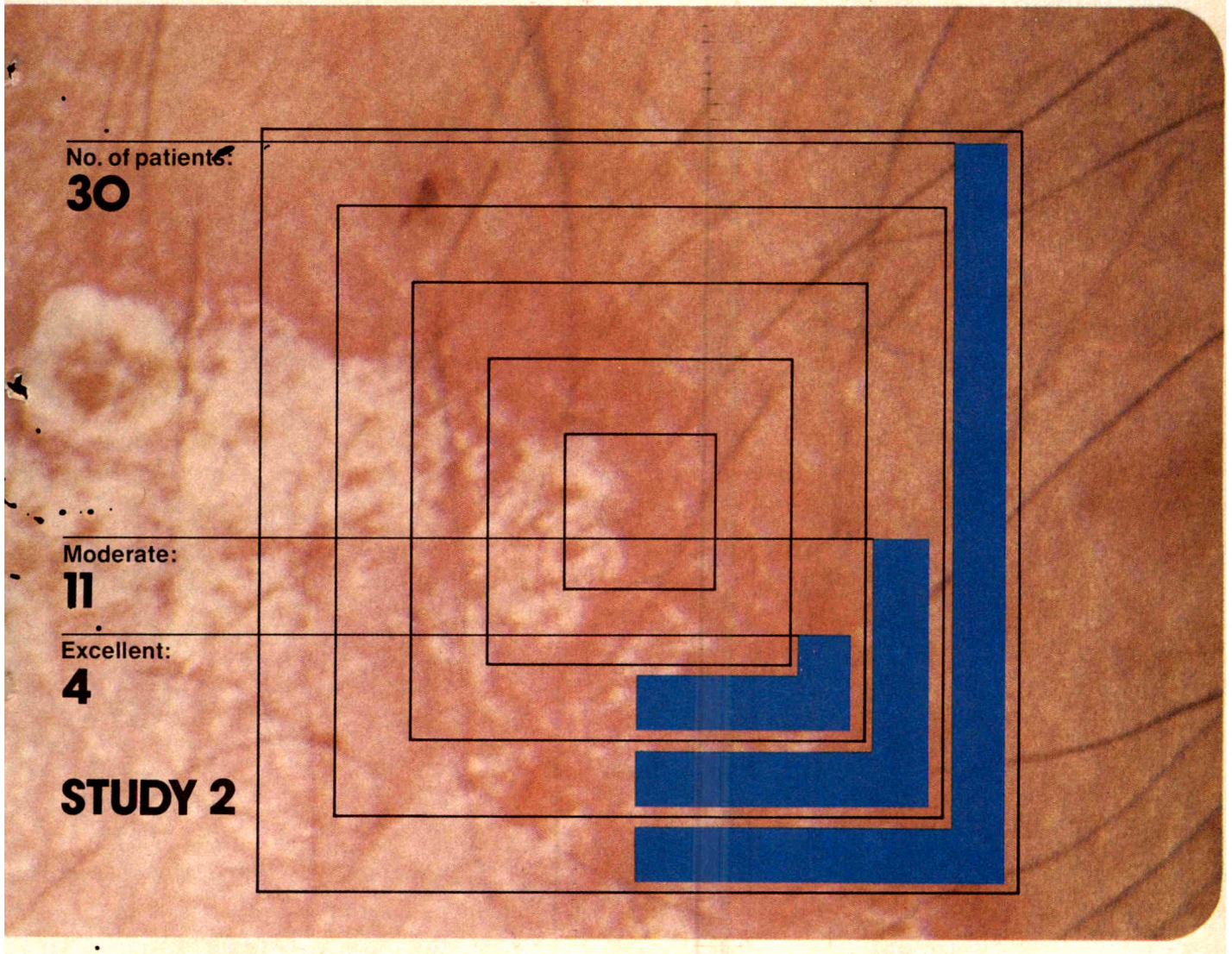

Aristocort®-A

TRIAMCINOLONE ACETONIDE

with AQUATAIN™ Hydrophilic Base

0.1% Cream

See following page for prescribing information.

Measures of Economy

Large size packages
save money when treating chronic and/or extensive dermatoses

CREAM 0.025%
(Quarter Strength)
75 Gm. tubes

OINTMENT 0.1%
(Regular Potency)
75 Gm. tubes

Also available: 15 Gm. tubes of ARISTOCORT A Cream—0.025%, 0.1% and 0.5%—and ARISTOCORT A Ointment, 0.1% and 0.5%.



CREAM 0.1%
(Regular Potency)
75 Gm. tubes
240 Gm. jars

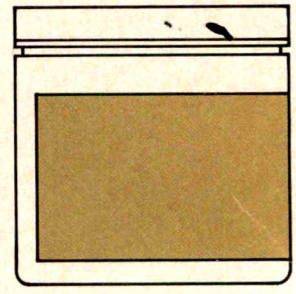

CREAM 0.5%
(High Potency)
240 Gm. jars

INDICATIONS: For relief of inflammatory manifestations of corticosteroid-responsive dermatoses.

CONTRAINDICATIONS: Viral skin diseases, such as varicella and vaccinia; hypersensitivity to any component (not for ophthalmic use); when circulation is markedly impaired.

WARNINGS: Safety of use in pregnancy has not been absolutely established. Do not use extensively, in large amounts, or for prolonged periods of time in pregnant patients.

PRECAUTIONS: If irritation develops, discontinue use and institute appropriate therapy. In infections, use appropriate antifungal or antibacterial agents; if a favorable response does not occur promptly, discontinue the corticosteroid until the infection is adequately controlled. If extensive areas are treated or the occlusive technique is used, increased systemic absorption of the corticosteroid may occur; take suitable precautions.

ADVERSE REACTIONS: (local) Burning sensations, itching, irritation, dryness, folliculitis, secondary infection, skin atrophy, striae, hypertrichosis, acneform eruption and hypopigmentation.

ARISTOCORT A CREAM: Each gram of ARISTOCORT A contains 0.25 mg. (0.025%), 1 mg. (0.1%) or 5 mg. (0.5%) of the highly active steroid, Triamcinolone Acetonide (a derivative of triamcinolone) in AQUATAIN, a specially formulated base composed of emulsifying wax NF, isopropyl palmitate, glycerin USP, sorbitol solution USP, lactic acid, 2% benzyl alcohol and purified water. AQUATAIN is non-staining, water-washable, paraben-free, spermaceti-free and has a light texture and consistency.

ARISTOCORT A OINTMENT: Each gram of ARISTOCORT A Ointment contains 1 mg. (0.1%) or 5 mg. (0.5%) of the highly active steroid, Triamcinolone Acetonide (a derivative of triamcinolone) in a specially formulated base composed of emulsifying wax NF, white petrolatum, and propylene glycol. In addition, the 0.1% Ointment contains Tenox II and lactic acid.

Lederle

LEDERLE LABORATORIES,
A Division of American Cyanamid Company
Pearl River, New York 10965

066-7R

Aristocort®-A
TRIAMCINOLONE ACETONIDE with AQUATAIN™ Hydrophilic Base
0.1% Cream

A free measure for lesions
Ask your Lederle Representative for a complimentary supply.

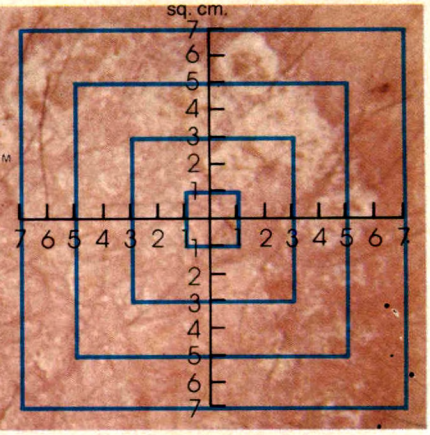

News and Notes

Annual Meeting.—The annual meeting of the Society for Investigative Dermatology, Inc (SID), will be held Monday through Wednesday, May 1-3, 1978, at the St Francis Hotel in San Francisco immediately following the meeting of the American Federation for Clinical Research (AFCR). Beginning with this meeting, a registration fee of $50 will be required of all nonmembers of the SID and AFCR. Admission to the meeting rooms will be by name badge only. To speed registration, members will receive registration forms at the time of the mailing of the annual program. Nonmembers are requested to preregister by writing the secretary-treasurer and enclosing the registration fee. Send forms and fees to W. Mitchell Sams, Jr, MD, secretary-treasurer, Department of Dermatology, N. C. Memorial Hospital, Chapel Hill, NC 27514.

Skin Pathology.—A Dermatopathology Foundation course in gross and microscopic pathology of the skin will be held June 12-16, 1978, under the auspices of Tufts University Department of Continuing Education. The five-day intensive course will be held at the Howard Johnson Motor Lodge in Boston. Instructors are Milton R. Okun, MD, Leon M. Edelstein, MD, and Walter F. Lever, MD, and lectures will be accompanied by simultaneous projection of gross and microscopic color 35-mm slides. The course is good for 40-hour credit in the American Medical Association category 1a. For details and applications contact R. P. Patel, PhD, Dermatopathology Foundation, PO Box 377, Canton, MA 02021.

Anglo-American Symposium on Issues in Research With Human Subjects.—The Anglo-American Symposium on Issues in Research With Human Subjects will be held March 20-21, 1978, at the Masur Auditorium, National Institutes of Health, Bethesda, Md. This meeting is one of a series that is jointly sponsored by the Royal Society of Medicine and the National Institutes of Health; the meetings are designed to exchange information or experiences in areas of biomedicine that are of mutual interest to health scientists of the United States and the United Kingdom.

At this meeting, information will be exchanged on topics such as clinical research on children, compensation of research subjects for adverse effects, role of the public in monitoring research with human subjects, government and industry relationships, and the need for international standards for clinical research.

Notification of planned attendance is required. Persons attending are responsible for their own travel costs and other expenses. Requests for additional information or the program, or notification of attendance should be addressed to: Mrs Toby P. Levin, Fogarty International Center, National Institutes of Health, Bldg 31, Room 2C15, Bethesda, MD 20014, telephone (301)496-2516.

Allergy Seminar.—A seminar entitled, "Food and Chemical Sensitivities in Human Disease," sponsored by the University of Miami School of Medicine, Department of Pediatrics, and the Miller Foundation Inc, will be held May 20-23, 1978, at the Holiday Inn on Airport Blvd, Mobile, Ala. This seminar will present new diagnostic and therapeutic procedures for entities now known to be often of immunologic origin, including migraine, vertigo, allergic rhinitis, asthma, atopic dermatitis, chronic urticaria, aphthous stomatitis, irritable colon syndromes, generalized cyclic edema, and behavioral syndromes related to focal cerebral edema. The seminar is approved for 28 hours of Category 1 Continuing Medical Education credit.

For further information, write to the Miller Foundation Inc, Three Office Park, Mobile, AL 36609. Please make hotel reservations directly with the hotel (phone: 205/342-3220, or toll-free central Holiday Inn reservation number: 1-800-238-8000).

Skin Disease Symposium.—An international symposium on dermatopathology entitled, "Histological Differential Diagnosis of Skin Diseases," which was organized by the Department of Dermatology of the University of Munich, Germany, and the Departments of Dermatology and Pathology of New York University School of Medicine, will be held in Munich on Friday, Saturday, and Sunday, June 16, 17, and 18, 1978. The chairmen of the symposium will be Otto Braun-Falco, MD, University of Munich, and A. Bernard Ackerman MD, New York University School of Medicine. The symposium will be conducted in English, will have an international faculty, and will focus on 45 difficult problems in histologic differential diagnosis of cutaneous diseases. Special emphasis will be given to histologic patterns that are diagnostically distinctive of inflammatory skin diseases and to current concepts of cutaneous and systemic malignant lymphomas.

A special group flight at considerable savings for registrants in the symposium has been arranged. For additional information write to: A. Bernard Ackerman, MD, PC, Dermatopathology Section, New York University Medical Center, 562 First Ave, New York, NY 10016, or to: Helmut H. Wolff, MD, Dermatologische Klinik, Frauenlobstrasse 9, 8000 Munchen, West Germany.

Iranian Dermatology Congress.—The fifth Iranian Congress of Dermatology will be held May 30-June 1, 1978, in the Razi Hospital of the Razi Medical School, Tehran University, Tehran, Iran. The topics will be "Dermatology in the Middle East" and "Therapeutic Problems in Dermatology." If you would like to give a 15-minute presentation of a paper at the congress, please send an abstract (not more than 200 words) to Dr B. V. Seyedi, congress director, before March 31, 1978. Official languages of the congress will be Persian, English, and French.

For further information write to: Dr B. V. Seyedi, Director, Fifth Iranian Congress of Dermatology, Razi Hospital, Shahpour Ave, Tehran, Iran.

Addition to 'Basic Sciences in Dermatology' Announced.—"Immunofluorescence in Dermatologic Diagnosis," by Thomas K. Burnham, MB, Department of Dermatology, Henry Ford Hospital, Detroit, is the fifth in the series "Basic Sciences in Dermatology" produced by the Institute for Dermatologic Communication and Education (IDCE), according to Marion B. Sulzberger, MD, president of IDCE, and Roberta Z. Sulzberger, executive producer.

The new program consists of 80 color slides in a carousel tray, synchronized sound on a cassette tape electronically cued for automatic advance

or with audible tone manual advance, and a script.

In the collection, photomicrographs and artwork created at the fluorescence microscope reveal nuclear patterns, bands, and intercellular fluorescence characteristic of systemic and discoid lupus erythematosus, certain connective tissue disorders, and various bullous diseases. Direct and indirect techniques to demonstrate immunofluorescence are shown.

The program is priced at $85 (Illinois residents add 5% sales tax, outside the United States and Canada, add $6). Remittance must accompany order. Please indicate automatic or manual signal for cassette. Orders may be sent to Department of Education Services, American Academy of Dermatology, PO Box 552, Evanston, IL 60204.

Congress of American College of Allergists.—The 34th Annual Congress of the American College of Allergists will be held April 1-6, 1978, at the Las Vegas Hilton Hotel, Las Vegas, Nev. A comprehensive review will be made, relevant to the needs of the physician in practice, on immunologic and allergic diseases. The 5½-day program will focus on physician/registrant participation.

Thirty hours credit (AMA-Continuing Medical Education, category 1) is available. The registration fee is $75 for members and $190 for nonmembers; there is no fee for residents, interns, nurses, and technicians who are from teaching hospitals and who present letters from department heads.

For further information contact Frances P. White, Executive Secretary and Treasurer, American College of Allergists, 2141 Fourteenth St, Boulder, CO 80302 (Phone: 303/447-8111).

Search Committee for Directorship.—A search committee has been appointed by Arthur C. Upton, MD, Director National Cancer Program, to advise in the selection of candidates for the directorship of the division of cancer cause and prevention of the National Cancer Institute (NCI). This division's activities encompass several major program areas: field studies and statistics, the virus cancer program, the carcinogenesis research program, and the carcinogenesis testing program. Because the division's activities deal with both scientific and public issues of considerable importance and visibility, the division's directorship is one of the most difficult and responsible positions in the Institute.

Dr Vincent T. DeVita, Director of Division of Cancer Treatment, NCI, will serve as chairman of the search committee, and Elizabeth Stroud, Chief of the Personnel Management Branch, NCI, will serve as executive secretary. In addition to Dr DeVita and Mrs Stroud, the following persons have been appointed to serve on the Committee: Mr Calvin B. Baldwin, Jr, Associate Director for Administrative Management, NCI; Dr Eula Bingham, Administrator, Occupational Safety and Health Administration, US Department of Labor; Mr Douglas Costle, Administrator, Environmental Protection Agency; Dr Diane J. Fink, Director, Division of Cancer Control and Rehabilitation, NCI; Dr Donald Kennedy, Commissioner, Food and Drug Administration; Dr Thomas J. King, Director, Division of Cancer Research Resources and Centers, NCI; Dr Ruth L. Kirschstein, Director, National Institute of General Medical Sciences; Dr David P. Rall, Director, National Institute of Environmental Health Sciences; and Dr DeWitt Stetten, Jr, Deputy Director for Science National Institutes of Health.

In the interest of securing appropriate input from the community at large, the committee will consult freely with intramural as well as extramural advisers. The committee will be grateful for any comments in support of its mission. Communications may be directed to the chairman of the committee, to the executive secretary, or to individual members of the committee.

The NCI is an equal opportunity employer.

Sixth Annual Consultant's Course.—The sixth annual consultant's course in dermatology will be held March 28-31, 1978. This program will be an intensive course directed to problems in dermatology as seen in practices that have a substantial number of consultant-type patients. The program will be held at the University of California, San Francisco, and is approved for Category 1 credit of the Physician's Recognition Award of the AMA and the certification program of the California Medical Association. For further information, please write to: Extended Programs in Medical Education, University of California, Room 569-U, San Francisco, CA 94143, or call 415/666-4251.

SYNALAR
(fluocinolone acetonide)
CREAM 0.025%
CREAM 0.01%
OINTMENT 0.025%
SOLUTION 0.01%

Description Synalar (fluocinolone acetonide) has the chemical name 6α, 9α-difluoro-16α-hydroxyprednisolone-16, 17-acetonide.

The cream contains fluocinolone acetonide 0.25 mg./g. or 0.1 mg./g. in a water-washable aqueous base of stearic acid, propylene glycol, sorbitan monostearate and monooleate, polysorbate 60, purified water and citric acid with methylparaben and propylparaben as preservatives.

The ointment contains fluocinolone acetonide 0.25 mg./g. in a white petrolatum U.S.P. vehicle.

The solution contains fluocinolone acetonide 0.1 mg./g. in a water-washable base of propylene glycol with citric acid.

Indications For relief of the inflammatory manifestations of corticosteroid-responsive dermatoses.

Contraindications Topical steroids are contraindicated in vaccinia and varicella.

Topical steroids are contraindicated in those patients with a history of hypersensitivity to any of the components of the preparation.

Precautions If irritation develops, the product should be discontinued and appropriate therapy instituted.

In the presence of an infection the use of an appropriate antifungal or antibacterial agent should be instituted. If a favorable response does not occur promptly, the corticosteroid should be discontinued until the infection has been adequately controlled.

If extensive areas are treated or if the occlusive technique is used, the possibility exists of increased systemic absorption of the corticosteroid and suitable precautions should be taken.

Although topical steroids have not been reported to have an adverse effect on pregnancy, the safety of their use in pregnant females has not absolutely been established. Therefore, they should not be used extensively on pregnant patients, in large amounts, or for prolonged periods of time.

Synalar products are not for ophthalmic use.

Adverse reactions The following local adverse reactions have been reported with topical corticosteroids: burning, itching, irritation, dryness, folliculitis, hypertrichosis, acneform eruptions, hypopigmentation.

The following may occur more frequently with occlusive dressings than without such therapy: maceration of the skin, secondary infection, skin atrophy, striae, miliaria.

How Supplied
Synalar (fluocinolone acetonide)
Cream 0.025% — 15 and 60g. tubes and 120 and 425g. jars.
Cream 0.01% — 15, 45 and 60g. tubes and 120 and 425g. jars.
Ointment 0.025% — 15 and 60g. tubes and 425g. jars.
Solution 0.01% — 20cc. and 60cc. plastic squeeze bottles.

Also Available
Synalar-HP® (fluocinolone acetonide) Cream 0.2% 5g. and 12g. tubes.

SYNTEX
SYNTEX LABORATORIES, INC.
PALO ALTO, CALIFORNIA 94304

USEFUL TODAY AS THE
Y IT WAS INTRODUCED

SYNALAR

(FLUOCINOLONE ACETONIDE)

See preceding page for summ
of prescribing information

Vectrin® Capsules

(minocycline hydrochloride capsules, USP)

50 and 100 mg

effective adjunctive treatment in severe acne

Before Treatment | **After Treatment**

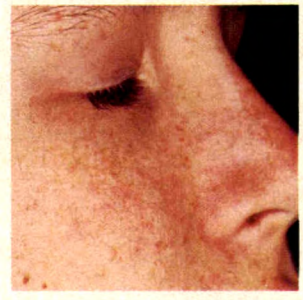

84 DAYS
Vectrin, 50 mg, twice daily

91 DAYS
Vectrin, 50 mg, twice daily

40 DAYS
Vectrin, 100 mg, once daily

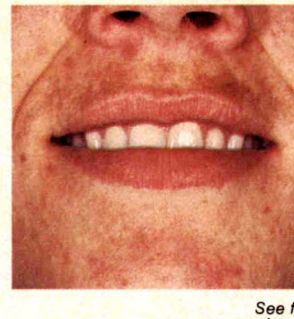

84 DAYS
Vectrin, 100 mg, once daily

PARKE-DAVIS

See following page for brief summary of prescribing information.

VECTRIN Capsules, 50 and 100 mg
(minocycline HCl capsules, USP)
Brief Summary of Prescribing Information

Indicated in severe acne as adjunctive therapy. Consult package insert for complete prescribing information.

Contraindication: Hypersensitivity to any tetracycline.

Warnings: When need for intensive treatment outweighs potential dangers, perform renal and liver function tests before and during therapy; also follow serum concentrations. In renal impairment, usual doses may lead to excessive accumulation and liver toxicity. Under such conditions, use lower total doses, and, in prolonged therapy, determine serum levels. The use of tetracyclines during tooth development (last half of pregnancy, infancy, and childhood to the age of 8 years) may cause permanent discoloration of the teeth (yellow-gray-brown). This is more common during long-term use but has been observed following repeated short-term courses. Enamel hypoplasia has also been reported. Tetracyclines, therefore, should not be used in this age group unless other drugs are not likely to be effective or are contraindicated. Photosensitivity manifested by an exaggerated sunburn reaction has been observed in some individuals taking tetracyclines. Advise patients apt to be exposed to direct sunlight or ultraviolet light that such reaction can occur, and discontinue treatment at first evidence of skin erythema. Studies with minocycline HCl indicated that photosensitivity did not occur. However, reports have been received. In patients with significantly impaired renal function, the antianabolic action of tetracycline may cause an increase in BUN leading to azotemia, hyperphosphatemia, and acidosis. **CNS side effects:** (light-headedness, dizziness, vertigo) have been reported, may disappear during therapy, and always disappear rapidly when drug is discontinued. Caution patients who experience these symptoms about driving vehicles or using hazardous machinery while taking this drug. **Pregnancy:** In animal studies, tetracyclines cross the placenta, are found in fetal tissues, and can have toxic effects on the developing fetus (often related to retardation of skeletal development). Embryotoxicity has been noted in animals treated early in pregnancy. The safety of minocycline HCl for use during pregnancy has not been established. **Newborns, infants, and children:** All tetracyclines form a stable calcium complex in any bone-forming tissue. Prematures, given oral doses of 25 mg/kg every six hours, demonstrated a decrease in fibula growth rate, reversible when drug was discontinued. Tetracyclines are present in the milk of lactating women who are taking a drug in this class.

Precautions: Use may result in overgrowth of nonsusceptible organisms, including fungi. If superinfection occurs, antibiotics should be discontinued and appropriate therapy instituted. In venereal diseases when coexistent syphilis is suspected, darkfield examination should be done before treatment is started and blood serology repeated monthly for at least four months. Patients on anticoagulant therapy may require downward adjustment of such dosage. Test for organ system dysfunction (eg, renal, hepatic, and hemopoietic) in long-term use. Treat all group A beta-hemolytic streptococcal infections for at least 10 days. Avoid giving tetracycline in conjunction with penicillin.

Adverse Reactions: GI: Anorexia, nausea, vomiting, diarrhea, glossitis, dysphagia, enterocolitis, inflammatory lesions (with monilial overgrowth) in anogenital region. **Skin:** Maculopapular and erythematous rashes. Exfoliative dermatitis (uncommon). Photosensitivity is discussed above. (See Warnings.) **Renal toxicity:** Rise in BUN, dose-related. (See Warnings.) **Hypersensitivity reactions:** Urticaria, angioneurotic edema, anaphylaxis, anaphylactoid purpura, pericarditis, exacerbation of systemic lupus erythematosus. In young infants, bulging fontanels have been reported following full therapeutic dosage, disappearing rapidly when drug was discontinued. **Blood:** Hemolytic anemia, thrombocytopenia, neutropenia, eosinophilia. **CNS:** (See Warnings.) When given over prolonged periods, tetracyclines may produce brown-black microscopic discoloration of thyroid glands; no abnormalities of thyroid function studies are known to occur.

NOTE: Concomitant therapy: Antacids containing aluminum, calcium, or magnesium impair absorption; do not give to patients taking oral tetracycline. Studies to date indicate that absorption of VECTRIN (minocycline hydrochloride) is not notably influenced by foods and dairy products.

Full prescribing information available upon request.

PARKE, DAVIS & COMPANY
Detroit, MI 48232

PD-JA-2378-1-P (2-78)

Books

Readers are advised that in view of The Copyright Revision Act of 1976, *all Book Reviews submitted for publication must contain on the transmittal letter the following language: "The person(s) undersigned hereby grant the American Medical Association permission to publish this Book Review and in addition hereby assigns all copyright ownership therein to the AMA."*

Psychosomatic Aspects of Allergy, by Claude A. Frazier, 252 pp, with illus, $14.95, New York, Van Nostrand Reinhold Publishing Co, 1977.

Dr Frazier has explained in some detail his perspective of the psychosomatic aspects of allergy. Unfortunately, this type of book is more a personal reflection than a scientific documentation; it reads like a diary of the day's events with case references and anecdotes. To construct the psychosomatic framework Dr Frazier uses a foundation of anxiety, personality, and psychophysiology. Quickly colds, skin problems, gastrointestinal turmoil, and nervous system maladies are inserted in hopes of keeping the structure together. Even re-reading individual segments of the book leaves one convinced only of Dr Frazier's consummate clinical skills and not of the scientific basis for his conclusions.

Perhaps this book is meant for the friendly bookstore shelf, where legions of allergy sufferers can extract pertinent information. The reader who is a physician, however, will not be convinced that Dr Frazier's experience in practice is relevant to explaining the vagaries of allergy. Confronted with the case history of the allergy patient, the clinician who reads this book will find little refuge in its pages, and neither will he or she find any plethora of therapeutic pearls. The appendix is appropriately named, ie, it is an addition that seems to be without a relationship to the body of the book.

In conclusion, this book is not meant to be a rigorous scientific contribution. Rather, it bears the ruminations and practices of a fine allergist.

STEPHEN Z. SMITH, MD
Louisville

Advances in Modern Toxicology, Vol 4, Dermatotoxicology and Pharmacology, edited by Francis N. Marzulli & Howard Maibach, 567 pp, with illus, $37.50, New York, Halsted Press, 1977.

Many aspects of dermatotoxicology have received inadequate attention or study in the past, and the editors of this volume are to be congratulated for their in-depth focus on this subject. There are 21 chapters in the book and nine of these chapters deal exhaustively with the subject of skin irritation and contact sensitivity. Comprehensive reviews on sebaceou glands, cutaneous metabolism, pe meability theory, and immunologi aspects of contact sensitivity provid an excellent background for much c the other material presented in thi volume. Two chapters on photocontac allergy are authoritative and wel written, as are chapters on contac urticaria and cutaneous granuloma: A few contributions, such as those o cutaneous carcinogenesis and pigmer tary effects of topically applie agents, are unduly abbreviated, how ever. Conversely, some of the author have dealt with experimental method ology in too much detail. This review er's main concern is with the balanc of subject matter and the omission c important topics. Reactions of th skin to systemic agents (especiall medications), systemic toxicity fror percutaneous absorption, the chem istry and toxicology of cosmetic: cutaneous vascular toxicity, and th subject of cutaneous inflammatio have all been omitted. The majo emphasis has been placed on dermato toxicology; the "pharmacology" of th title has been de-emphasized.

Despite the fact that this is a mult authored book with some inevitabl duplication, it is eminently readabl throughout and is graced with exter sive bibliographies. The book is als well-indexed and well-produced. T continue to protest the ever-escalat ing costs of medical books seems hope less; for $37.50, however, the reader i entitled to a far better quality of blac and white photographs and photom crographs than the publisher ha provided.

Overall, this is a useful referenc volume for investigators interested i various aspects of dermatotoxicology For teachers, students, and practi tioners of dermatology, several chap ters provide excellent presentations o selected subjects. Admittedly, th fields of interest reflected in this boo are much too broad for comprehensiv inclusion in a single volume. Hope fully, the editors will make addition contributions to this continuing serie that will review and expand ou knowledge of basic aspects of derma totoxicology and pharmacology in der matologic science and practice.

FREDERICK D. MALKINSON, MI
Chicago

WHEN DERMATOSES TAKE SHAPE

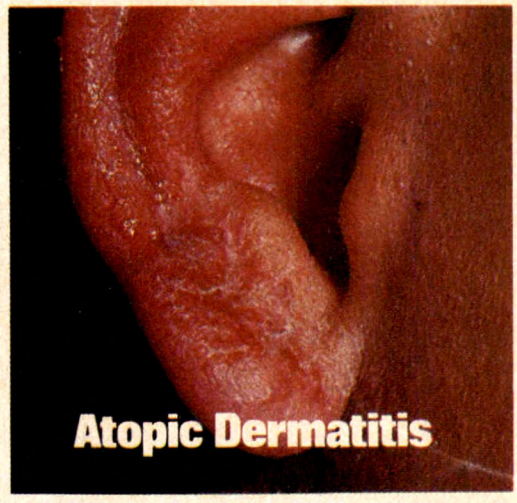

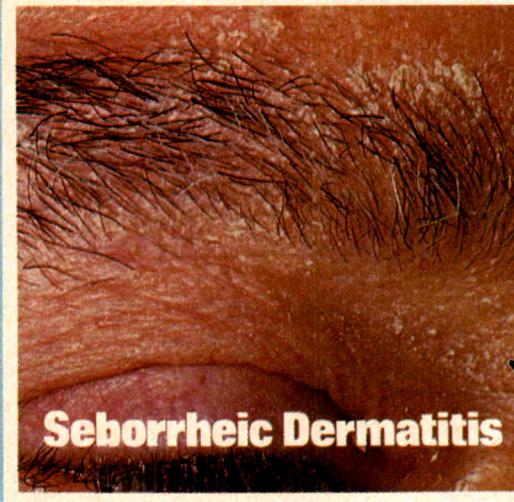

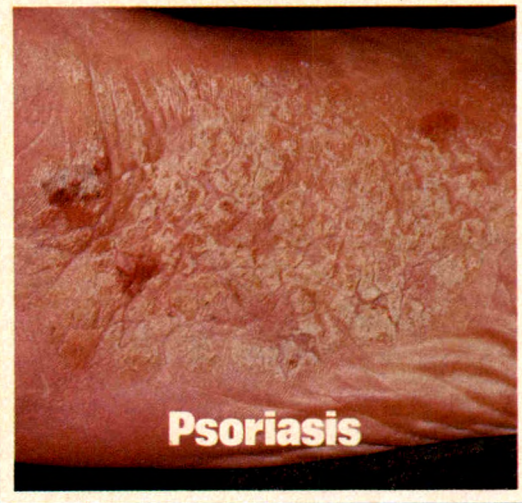

COPYRIGHT © 1977, SCHERING CORPORATION. ALL RIGHTS RESERVED. SLS-866

When treating tar-responsive dermatoses...

You'll have to tell your patients it's tar.

NEW

estar™

Therapeutic Tar Gel

The odor won't.

For full product information, see PDR.

WESTWOOD
PHARMACEUTICALS INC.
Buffalo, New York 14213

©1976, W.P. Inc.

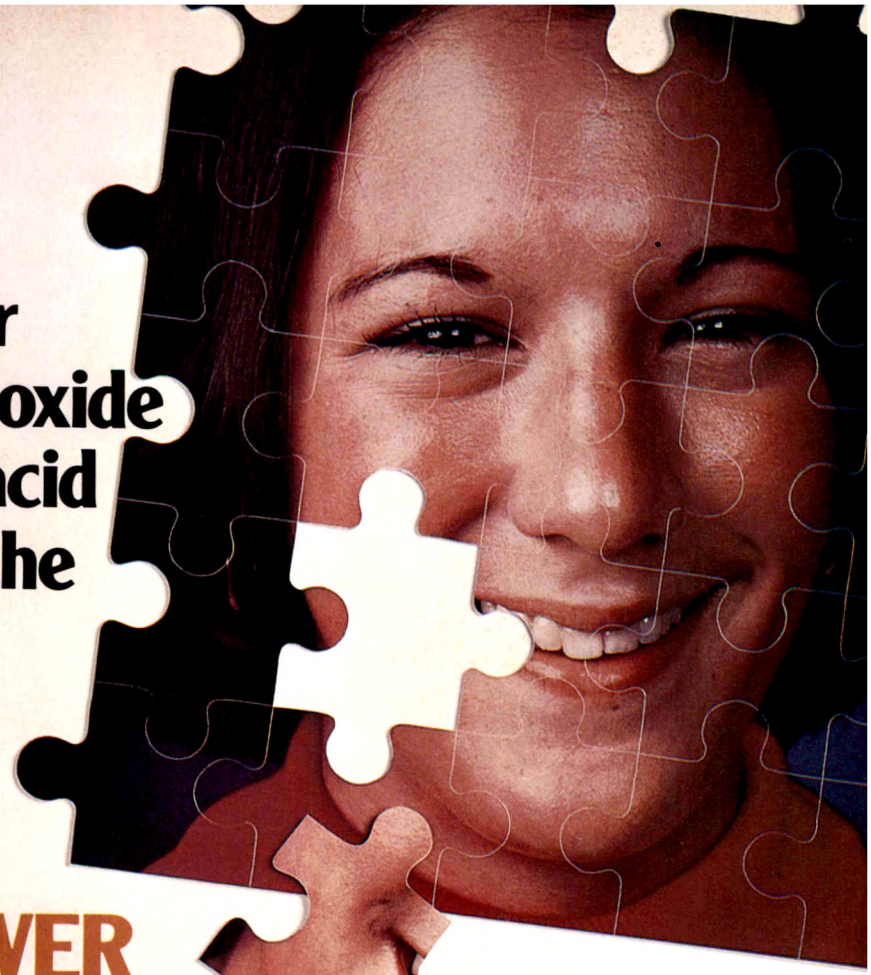

When either benzoyl peroxide or retinoic acid can't solve the puzzle of pustular acne...

THE ANSWER COULD BE SULFACET-R®

(10% sodium sulfacetamide, 5% sulfur)

- **Exerts** broad spectrum antibacterial activity
- **Controls** pustular stages of acne and seborrhea quickly, safely...without unsightly desquamation
- **Safety record**...A low incidence of sensitivity has been observed in thousands of patients during the past two decades
- **Provides** instant "Social Confidence" with the exclusive Dermik Color Blender™ customized tinting to match individual patient skin tones

SULFACET-R® LOTION

DESCRIPTION—Sulfacet-R® Acne Lotion contains (as dispensed) sodium sulfacetamide 10% and sulfur 5% in a flesh-tinted lotion of purified water, alkyl-aryl sulfonic acid salts, hydroxyethylcellulose, propylene glycol, xanthan gum, lauric myristic diethanolamide, polyoxyethylene laurate, cyclohexanediamine tetraacetic acid, butylparaben, methylparaben, silicone emulsion, talc, zinc oxide, titanium dioxide, attapulgite, iron oxides, pH buffers and 2-bromo-2-nitropropane-1, 3-diol.

ACTIONS—Provides keratolytic, peeling, drying and antiseborrheic action.

INDICATIONS—An aid in the treatment of acne vulgaris, acne rosacea and seborrheic dermatitis.

CONTRAINDICATIONS—This product is contraindicated for use by patients having known hypersensitivity to sulfonamides, sulfur or any other component of this preparation. Not to be used by patients with kidney disease.

PRECAUTIONS—For external use only. Keep away from eyes. If irritation develops, discontinue use and consult physician. Sensitivity to sodium sulfacetamide may occur. Therefore, caution and careful supervision should be observed when prescribing this drug for patients who may be prone to hypersensitivity to topical sulfonamides. Particular caution should be employed if areas of denuded or abraded skin are involved. Patients should be carefully observed for possible local irritation or sensitization during long term therapy. Occasionally, certain individuals may be sensitive to one or more components of this preparation. The object of this therapy is to achieve desquamation without irritation, but sodium sulfacetamide and sulfur can cause reddening and scaling of the epidermis. These side effects are not unusual in the treatment of acne vulgaris, but patients should be cautioned about the possibility. Keep out of the reach of children.

ADVERSE REACTIONS—Previous toxic reactions such as agranulocytosis, acute hemolytic anemia, purpura hemorrhagica, drug fever, jaundice and contact dermatitis indicates hypersensitivity to sulfonamides.

DIRECTIONS—Shake well before using. Apply a thin film 1 to 3 times daily with light massaging to blend in each application in accordance with the physician's directions. Each package contains a "Dermik Color Blender" which enables the patient to alter the basic shade of the lotion so that is matches the skin color exactly.

[Important to the Pharmacist—At the time of dispensing, add contents of vial* to the bottle. Shake well and/or stir with a glass rod to insure a uniform dispersion. Place expiration date of four (4) months on bottle label.]

*"Sulfa-Pak" vial contains 2.4 grams of sodium sulfacetamide.

HOW SUPPLIED—Bottle, 1 oz.

CAUTION—Federal law prohibits dispensing without prescription.

Dermik

Dermik Laboratories, Inc.
Fort Washington, Pa., U.S.A. 19034

Please see Cl

DIPROSONE®
brand of betamethasone dipropionate
Cream 0.05%, Ointment 0.05%, Lotion 0.05% w/w, Aerosol 0.1% w/w
(Potency expressed as betamethasone)
For Dermatologic Use Only

ACTIONS: DIPROSONE **Cream, Ointment, Lotion,** and **Aerosol** are primarily effective because of their anti-inflammatory, antipruritic, and vasoconstrictive actions.

INDICATIONS: DIPROSONE **Cream, Ointment,** and **Lotion** are indicated for the relief of the inflammatory manifestations of corticosteroid-responsive dermatoses.

DIPROSONE **Aerosol** is indicated solely for the adjunctive topical management for the relief of inflammatory manifestations of acute contact dermatitis.

DIPROSONE **Aerosol** has not been shown to be effective in any steroid-responsive dermatosis other than contact dermatitis.

CONTRAINDICATIONS: DIPROSONE **Cream, Ointment, Lotion,** and **Aerosol** are contraindicated in vaccinia and varicella. Topical steroids are contraindicated in those patients with a history of hypersensitivity to any of the components of such preparations.

DIPROSONE **Aerosol** is also contraindicated for use under occlusive dressings.

WARNINGS FOR DIPROSONE AEROSOL: Keep DIPROSONE **Aerosol** away from eyes or other mucous membranes. Use only as directed; intentional misuse by deliberately concentrating or inhaling the contents can be harmful or fatal. Avoid freezing of the tissue by not spraying for more than three seconds, at a distance of not less than six inches. Contents under pressure. Do not puncture. Do not use or store near heat or open flame. Exposure to temperatures above 120° Farenheit may cause bursting. Never throw container into fire or incinerator. Keep DIPROSONE **Aerosol** out of reach of children.

PRECAUTIONS: If irritation develops with the use of DIPROSONE products, treatment should be discontinued and appropriate therapy instituted. In the presence of an infection, the use of an appropriate antifungal or antibacterial agent should be instituted. If a favorable response does not occur promptly, the corticosteroid should be discontinued until the infection has been adequately controlled.

If extensive areas are treated or if the occlusive technique is used, the possibility exists of increased systemic absorption of the corticosteroid and suitable precautions should be taken. Although topical steroids have not been reported to have an adverse effect on pregnancy, the safety of their use in pregnant females has not been absolutely established. Therefore, they should not be used extensively in pregnant patients, in large amounts or for prolonged periods of time. DIPROSONE products are not for ophthalmic use.

ADVERSE REACTIONS: The following local adverse reactions have been reported with topical corticosteroids: burning; itching; irritation; dryness; folliculitis; hypertrichosis; acneiform eruptions; hypopigmentation. Additionally, the following may occur with DIPROSONE **Aerosol** and also may occur more frequently with occlusive dressings than without such therapy: maceration of the skin; secondary infection; skin atrophy; striae; miliaria.

DOSAGE AND ADMINISTRATION: DIPROSONE **Cream** and **Ointment** are applied as a thin film over the affected skin areas twice daily, in the morning and at night. Clinical studies of DIPROSONE have indicated that applications twice a day are generally adequate.

Apply a few drops of DIPROSONE **Lotion** to the affected areas and massage lightly until it disappears. Apply twice daily, in the morning and at night. For the most effective and economical use, apply nozzle to affected area and gently squeeze bottle.

DIPROSONE **Aerosol** may be held upright or inverted during use. The spray should be directed onto the affected area from a distance of not less than six inches and applied for only three seconds. Apply DIPROSONE **Aerosol** sparingly to the affected skin area three times a day.

Aerosol packaged by Aerosol Techniques, Inc., Armstrong Laboratories Division, West Roxbury, MA. 02132.

For more complete details, consult package insert or Schering literature available from your Schering Representative or Professional Services Department, Schering Corporation, Kenilworth, New Jersey 07033.
DECEMBER 1977

INDEX TO ADVERT

A

Abbott Laboratories 312-313

B

Barnes-Hind Pharmaceuticals 361

C

Columbia University
College of Physicians & Surgeons 348
Cooper Laboratories, Inc. 362

D

Dermik Laboratories ..... 331, 3rd Cover
Dista Products Company 309
Doak Pharmacal Company 338
Dome Laboratories 315, 356-357
Dorsey Laboratories 343-344

G

General Medical Company 342

H

Herbert, G.S., Laboratories, Division of
Allergan Pharmaceuticals 345, 456
Hoechst-Roussel Pharmaceuticals 322-324, 449

I

Ingram Pharmaceutical Company 367
International Light Inc. 348

K

Karger, S., AG 454

L

Lederle Laboratories, Division of
American Cyanamid Company .. 332-333, 359-360, 462-464

N

Neutrogena Corporation 348

O

Owen Laboratories, Inc. 311

P

Parke-Davis & Company 320-321, 468-469
Person & Covey, Inc. 453
Pharmacia Diagnostics 327
Procter & Gamble Company 342A-342F, 353, 358, 456A
Purdue Frederick Company 339

R

Riker Laboratories Inc. 330, 352
Roche Laboratories, Division of
Hoffmann-LaRoche, Inc. 349-351
Roerig, J.B., Company
Division of Pfizer, Inc. 346-347

S

Schering Corporation 336-337, 363, 470-472
Smith Kline & French Laboratories 354-355
Squibb, E.R., & Sons, Inc. 364-366
Stiefel Laboratories, Inc. 319, 450-451
Stuart Pharmaceuticals
Div. of ICI Americas Inc. 317
Syntex Laboratories, Inc. 328-330, 340-342, 466-467

W

Westwood Pharmaceuticals, Inc. ..... 2nd Cover, 318, 325-326, 334-335, 368, 455, 4th Cover

While every precaution is taken to insure accuracy, we cannot guarantee against the possibility of an occasional change or omission in the preparation of this index.

Schering

DIPROSONE® TAKES CHARGE!

BRAND OF
BETAMETHASONE
DIPROPIONATE

Prompt and Effective Topical Action for Everyday Steroid-Responsive Dermatoses

- Rapid onset of response
- Economy and convenience of b.i.d. dosage
- Occlusive dressings rarely needed
- Sensitivity is unusual



Available for prescribing flexibility in cream, ointment, and lotion.
Also available in aerosol, which is indicated for contact dermatitis only.

nical Considerations section which follows...

Published by the American Medical Association

April 197
Volume 114, Number

17.7.78

archives of Dermatology

Continuing Medical Education ..... W. M. Sams, Jr 527

Reviewers for 1977 ..... J. H. Epstein, K. Fukuyama, D. L. Tuffanelli 529

Dermatologic Manifestations of the Hypereosinophilic Syndrome ..... J. A. Kazmierowski, M. J. Chusid, J. E. Parrillo, A. S. Fauci, S. M. Wolff 531

Epidermal Nucleolar IgG Deposition in Clinically Normal Skin ..... S. D. Prystowsky, J. N. Gilliam, D. L. Tuffanelli 536

Experimental Cutaneous Candidiasis in Rodents ..... T. L. Ray, K. D. Wuepper 539

Neutrophil Chemotaxis in Patients With Atopic Dermatitis Without Infection ..... M. V. Dahl, K. L. Cates, P. G. Quie 544

Phototoxicity to a Sunscreen Ingredient ..... K. H. Kaidbey, A. M. Kligman 547

Migraine and Systemic Scleroderma ..... N. C. Goldberg, S. C. Duncan, R. K. Winkelmann 550

Fetal and Maternal Risk Factors in Herpes Gestationis ..... T. J. Lawley, G. Stingl, S. I. Katz 552

The Shulman Syndrome ..... S. W. Shewmake, D. A. Lopez, J. C. McGlamory 556

Skin Lesions in Paroxysmal Nocturnal Hemoglobinuria ..... R. L. Rietschel, C. W. Lewis, R. A. Simmons, R. L. Phyliky 560

Papulonecrotic Tuberculid Secondary to *Mycobacterium bovis* ..... D. L. Iden, R. S. Rogers III, A. L. Schroeter 564

Primary Inoculation Tuberculosis of the Skin ..... D. K. Goette, K. W. Jacobson, R. D. Doty 567

Carcinoid in an Umbilical Nodule ..... H. J. Brody, W. P. Stallings, R. M. Fine, A. Someren 570

Cutaneous Signs of Spinal Dysraphism ..... V. Tavafoghi, A. Ghandchi, G. W. Hambrick, Jr, G. B. Udverhelyi 573

Atypical Purpura Fulminans With Benign Monoclonal Gammopathy ..... W. R. Friedenberg, M. West, D. J. Miech, J. J. Mazza 578

Necrotizing Fasciitis ..... G. G. Koehn 581

Multiple Cutaneous Metastases of a Scapular Chondrosarcoma ..... D. T. King, A. W. Gurevitch, F. M. Hirose 584

Aneurysm of the Superficial Temporal Artery ..... E. C. Lewis II, E. G. Southwick 587

Aspiration Metastases From Basal Cell Carcinoma ..... R. A. Guillan, R. P. Johnson 589

Hereditary Painful Callosities ..... W. Roth, N. S. Penneys, N. Fawcett 591

Human Infection With *Dirofilaria* ..... H. M. Payan 593

Histoplasmosis Due to *Histoplasma capsulatum* var *duboisii* in a Canadian Immigrant ..... J. R. Nethercott, R. K. Schachter, K. F. Givan, D. E. Ryder 595

Dermatofibrosarcoma Protuberans With Lymph Node and Pulmonary Metastases ..... L. B. Kahn, N. Saxe, W. Gordon 599

Nasopharyngeal Carcinoma Associated With Long-Term Arsenic Ingestion S. D. Prystowsky, G. J. Elfenbein, S. I. Lamberg 602

AMA AMERICAN MEDICAL ASSOCIATION

When dehydrated stratum corneum and pruritus pose a problem...

Applehead art, hand-carved from an apple and dehydrated in stages. Apple carving is a 250 year old art in this country.

© 1978, W.P. Inc.

WESTWOOD
PHARMACEUTICALS INC
Buffalo, New York 14213
In Canada, Belleville, Ontario K8N 5E9

Recommend our therapeutic moisture system.

PREDICTION:

There will be 3 Eclipses in 1978.

INTRODUCING NEW ECLIPSE® GEL:

Non-comedogenic, it provides superior protection from sun damage for your patients with acne or oily skin.

INTRODUCING NEW ECLIPSE® LIP AND FACE PROTECTANT:

Convenient stick form moisturizes while it protects against burning, chapping and drying effects of sun, wind and cold.

ORIGINAL ECLIPSE® LOTION:

Combines the superior efficacy of two PABA esters with the moisturizing Aquacare® base to protect your patients with dry to normal skin.

Herbert Laboratories, Dermatology Division of Allergan Pharmaceuticals, Inc., Irvine, CA 92713, U.S.A.

THE ECLIPSE® FAMILY OF SUNSCREENS:

- Provide maximum skin protection. Absorb more than 99% of burning rays.
- Lotion and Gel contain 6% PABA esters . . . superior to 5% PABA formulations.
- Continue to protect after swimming with superior wash-off resistance.
- Do not develop unsightly and uncomfortable peeling of formulation.
- Protect immediately upon application. Patient does not have to wait before exposure.
- Are formulated to protect every patient skin type in every type of weather.

Archives of DERMATOLOGY

Copyright © 1978 by the AMERICAN MEDICAL ASSOCIATION

VOL 114, NO. 4 APRIL 1978

EDITORIALS

Continuing Medical Education
W. Mitchell Sams, Jr, MD, Chapel Hill, NC 527

Reviewers for 1977
John H. Epstein, MD; Kimie Fukuyama, MD, Denny L. Tuffanelli, MD, San Francisco 529

ORIGINAL CONTRIBUTIONS

Dermatologic Manifestations of the Hypereosinophilic Syndrome
John A. Kazmierowski, MD; Michael J. Chusid, MD; Joseph E. Parrillo, MD; Anthony S. Fauci, MD; Sheldon M. Wolff, MD, Bethesda, Md 531

Epidermal Nucleolar IgG Deposition in Clinically Normal Skin
Stephen D. Prystowsky, MD, San Francisco; James N. Gilliam, MD, Dallas; Denny L. Tuffanelli, MD, San Francisco 536

Experimental Cutaneous Candidiasis in Rodents
Thomas L. Ray, MD, Kirk D. Wuepper, MD, Portland, Ore 539

Neutrophil Chemotaxis in Patients With Atopic Dermatitis Without Infection
Mark V. Dahl, MD; K. Lynn Cates, MD; Paul G. Quie, MD, Minneapolis 544

Phototoxicity to a Sunscreen Ingredient
Kays H. Kaidbey, MD, Albert M. Kligman, MD, PhD, Philadelphia 547

Migraine and Systemic Scleroderma
Norman C. Goldberg, MD; Scott C. Duncan, MD; R. K. Winkelmann, MD, PhD, Rochester, Minn 550

Fetal and Maternal Risk Factors in Herpes Gestationis
Thomas J. Lawley, MD; Georg Stingl, MD; Stephen I. Katz, MD, PhD, Bethesda, Md 552

CASE REPORTS

The Shulman Syndrome
Lt Comdr Stephen W. Shewmake, MC, USN; Capt D. A. Lopez, MC, USN; Comdr James C. McGlamory, MC, USN, San Diego 556

Skin Lesions in Paroxysmal Nocturnal Hemoglobinuria
Robert L. Rietschel, MD; Charles W. Lewis, MD; Robert A. Simmons, MD; Robert L. Phyliky, MD, Fort Sam Houston, Tex 560

Papulonecrotic Tuberculid Secondary to *Mycobacterium bovis*
Donald L. Iden, MD; Roy S. Rogers III, MD; Arnold L. Schroeter, MD, Rochester, Minn 564

Primary Inoculation Tuberculosis of the Skin
Lt Comdr D. Klaus Goette, MC, USA; Capt Kraig W. Jacobson, MC, USA; Maj Richard D. Doty, MC, USA, Presidio of San Francisco, Calif 567

Carcinoid in an Umbilical Nodule
Harold J. Brody, MD; William P. Stallings, MD; Robert M. Fine, MD; Ayten Someren, MD, Atlanta 570

Cutaneous Signs of Spinal Dysraphism
Vida Tavafoghi, MD; Amir Ghandchi, MD; George W. Hambrick, Jr, MD; George B. Udverhelyi, MD, Baltimore 573

Atypical Purpura Fulminans With Benign Monoclonal Gammopathy
William R. Friedenberg, MD; Michael West, MD; Donald J. Miech, MD; Joseph J. Mazza, MD, Marshfield, Wis 578

Necrotizing Fasciitis
Gerard G. Koehn, MD, Denver 581

Multiple Cutaneous Metastases of a Scapular Chondrosarcoma
Donald T. King, MD; Arnold W. Gurevitch, MD; Frank M. Hirose, MD, Torrance, Calif 584

(Continued on page 476)

EDITORIAL BOARD

Chief Editor
John H. Epstein, MD
450 Sutter Street
San Francisco 94108

Assistant Chief Editor
Kimie Fukuyama, MD
San Francisco

Assistant Chief Editor
Denny L. Tuffanelli, MD
San Francisco

Donald C. Abele, MD
Augusta, Ga

Harry L. Arnold, Jr, MD
Honolulu

Walter C. Lobitz, Jr, MD
Portland, Ore

Frederick D. Malkinson, MD
Chicago

Sigfrid A. Muller, MD
Rochester, Minn

W. Mitchell Sams, Jr, MD
Chapel Hill, NC

John S. Strauss, MD
Iowa City

Gerald D. Weinstein, MD
Miami

THREE-IN-ONE THERAPY AGAINST TOPICAL INFECTION

Neosporin® Ointment

(Polymyxin B-Bacitracin-Neomycin)

This potent broad-spectrum antibacterial provides overlapping action to help combat infection caused by common susceptible pathogens (including staph and strep). The petrolatum base is gently occlusive, protective and enhances spreading.

Neomycin

Staphylococcus
Haemophilus
Klebsiella
Aerobacter
Escherichia
Proteus
Corynebacterium
Streptococcus
Pneumococcus

Bacitracin

Staphylococcus
Corynebacterium
Streptococcus
Pneumococcus

Polymyxin B

Pseudomonas
Haemophilus
Klebsiella
Aerobacter
Escherichia

In vitro overlapping antibacterial action of Neosporin® Ointment (polymyxin B-bacitracin-neomycin).

COLLEGE OF MEDICINE · U.P. · UNIVERSITY LIBRARY

Wellcome

Burroughs Wellcome Co.
Research Triangle Park
North Carolina 27709

Neosporin® Ointment

(Polymyxin B-Bacitracin-Neomycin)

Each gram contains: Aerosporin® brand Polymyxin B Sulfate 5,000 units; zinc bacitracin 400 units; neomycin sulfate 5 mg (equivalent to 3.5 mg neomycin base); special white petrolatum qs; in tubes of 1 oz and 1/2 oz and 1/32 oz (approx.) foil packets.

WARNING: Because of the potential hazard of nephrotoxicity and ototoxicity due to neomycin, care should be exercised when using this product in treating extensive burns, trophic ulceration and other extensive conditions where absorption of neomycin is possible. In burns where more than 20 percent of the body surface is affected, especially if the patient has impaired renal function or is receiving other aminoglycoside antibiotics concurrently, not more than one application a day is recommended.

When using neomycin-containing products to control secondary infection in the chronic dermatoses, it should be borne in mind that the skin is more liable to become sensitized to many substances, including neomycin. The manifestation of sensitization to neomycin is usually a low grade reddening with swelling, dry scaling and itching; it may be manifest simply as failure to heal. During long-term use of neomycin-containing products, periodic examination for such signs is advisable and the patient should be told to discontinue the product if they are observed. These symptoms regress quickly on withdrawing the medication. Neomycin-containing applications should be avoided for that patient thereafter.

PRECAUTIONS: As with other antibacterial preparations, prolonged use may result in overgrowth of nonsusceptible organisms, including fungi. Appropriate measures should be taken if this occurs.

ADVERSE REACTIONS: Neomycin is a not uncommon cutaneous sensitizer. Articles in the current literature indicate an increase in the prevalence of persons allergic to neomycin. Ototoxicity and nephrotoxicity have been reported (see Warning section).

Complete literature available on request from Professional Services Dept. PML.

CONTENTS—Continued

Aneurysm of the Superficial Temporal Artery
Edward C. Lewis II, MD, Edward G. Southwick, MD, Salt Lake City 587

Aspiration Metastases From Basal Cell Carcinoma
Ramon A. Guillan, MD, Richard P. Johnson, MD, Topeka, Kan 589

Hereditary Painful Callosities
• *William Roth, MD; Neal S. Penneys, MD, PhD; Nancy Fawcett, MD, Miami* 591

Human Infection With *Dirofilaria*
Hushang M. Payan, MD, Ishpeming, Mich 593

Histoplasmosis Due to *Histoplasma capsulatum* var *duboisii* in a Canadian Immigrant
James R. Nethercott, MD; R. Kanee Schachter, MD; Kathleen F. Givan, MD; Donald E. Ryder, MD, Toronto 595

Dermatofibrosarcoma Protuberans With Lymph Node and Pulmonary Metastases
Leonard B. Kahn, MBBCh, MMed, MRCPath; Norma Saxe, MBChB, FFDerm (SA); Walter Gordon, MD, FRCP (Edin), Cape Town, South Africa 599

Nasopharyngeal Carcinoma Associated With Long-Term Arsenic Ingestion
Stephen D. Prystowsky, MD; Gerald J. Elfenbein, MD; Stanford I. Lamberg, MD, Baltimore 602

REGULAR DEPARTMENTS

Short Reports 611

Mycosis Fungoides With Blast Cell Transformation Christine I. Harrington, MB, ChB, MRCP, David N. Slater, B Med Sci, MB, ChB, Sheffield, England . . . **Twenty-Nail Dystrophy** Richard K. Scher, MD; Robert Fischbein, MD; A. Bernard Ackerman, MD, New York . . . **The Coexistence of Two Types of Porphyria in One Family** Joel Levine, MD; Capt W. Taylor Johnson, MC, USN; Donald P. Tschudy, MD, Bethesda, Md

Books 620

Letters to the Editor 623

Tape Treatment for Fiberglass Splinters James H. Deeken, MD, Kansas City, Mo . . . **Dermatitis and Sézary's Cells** Scott C. Duncan, MD, R. K. Winkelmann, MD, PhD, Rochester, Minn . . . **Studies on Betamethasone Valerate vs Fluocinonide** D. Stephen Robins, MD, Palo Alto, Calif . . . **Suppression of Corticosteroid-Induced Atrophy and Telangiectasia With Vitamin A** Tovio Rist, MD, Knoxville, Tenn; Maj Charles W. Ruggles, MC, USAF; Maj Michael E. Ryan, MC, USAF; Lt Col Raymond L. Garcia, MC, USAF; Capt Donald Osborne, BSC, USAF, San Antonio, Tex . . . **Sweet's Disease** Lois Y. Matsuoka, MD, William Storino, MD, Chicago . . . **Cutis Punctata Linearis Colli** Hermann Pinkus, MD, Monroe, Mich, Thomas Butterworth, MD, Reading, Pa . . . **Including All Possible Sources** J. Delescluse, MD, Brussels, Belgium . . . **Stevens-Johnson Syndrome** Joseph J. Chanda, MD, Ann Arbor, Mich, Jeffrey P. Callen, MD, Louisville . . . **Pedunculated Malignant Melanoma** Raphael Shafir, MD; Rafaele David, MD; Sam Slutzki, MB, BS, Tel-Aviv, Israel . . . **Role of Race in Scabies Infestation** A. Melvin Alexander, MD, Silver Spring, Md . . . **Pemphigus Vegetans of Hallopeau** Louis Forman, MD, London, Christopher G. Nelson, MD, St Petersburg, Fla . . . **Depigmentation of Normal Skin to Treat Patients With Melanomas** Aaron B. Lerner, MD, James J. Nordlund, MD, New Haven, Conn

News and Notes 631

Index to Advertisers 638

Instructions for Authors 480

SUBSCRIPTION RATES: The yearly rate of the ARCHIVES OF DERMATOLOGY is as follows: United States and US Possessions, one year, $18; two years, $28; all other countries, one year, $28; two years, $38. Special yearly price to residents, interns and medical students in the United States and US Possessions, $9.

THE ARCHIVES OF DERMATOLOGY is published monthly by the American Medical Association, 535 N Dearborn St, Chicago, IL 60610, and is an official publication of the Association. Second-class postage paid at Chicago and at additional mailing office.

IMPROVED

SELSUN® ℞

(SELENIUM SULFIDE LOTION, U.S.P.)

- **Nicer fragrance**
- **Lighter color**
- **Richer sudsing**
- **Same efficacy and safety**

as the formula proved in millions of cases for over a quarter century

BRIEF SUMMARY

Contains: Selenium sulfide, 2½%, w/v; bentonite; lauric diethanolamide; ethylene glycol monostearate; titanium dioxide; amphoteric—2; sodium lauryl sulfate; sodium phosphate (monobasic); glyceryl monoricinoleate; citric acid; captan; perfume; and water.

Indications: For the treatment of dandruff and seborrheic dermatitis of the scalp.

Contraindications: Should not be used by patients allergic to any of its components.

Warnings: Safety for use on infants has not been established.

Precautions: Cutaneous sensitization of the scalp or adjacent areas has been reported; if sensitivity reactions should occur, discontinue use. Chemical conjunctivitis may result if product enters the eyes. Do not use when acute inflammation or exudation is present as an increase in absorption may occur.

Adverse Reactions: As with other shampoos, oiliness or dryness of the hair and scalp may occur following use; there have been occasional reports of an increase in the amount of normal hair loss. Hair discoloration may occur; can be avoided or minimized by thorough rinsing.

8033233

ABBOTT

Archives of Dermatology

James H. Sammons, MD
Executive Vice-President

Thomas F. Hannon
Group Vice-President,
Publishing Operations

William R. Barclay, MD
Group Vice-President,
Scientific Publications

Norman D. Richey
Director, Publication
Production Division

John T. Baker
Director, Marketing Division

Helen R. Mazur
Director, Circulation-Fulfillment

John T. Baker, General Sales Manager; **Robert Corcoran,** Eastern Sales Manager; **Fred Bauman, Richard M. Johnson,** Eastern Sales Representatives; **Alice Harvey, William J. Healy,** Midwest Sales Representatives; **Thomas J. Carroll,** West Coast/Northern Sales Representative

PUBLICATION STAFF

Offices: 535 N Dearborn St
Chicago, IL 60610

Robert W. Mayo
Executive Editor and Director,
Scientific Publications Division

Sandra Williamson
Administrative Assistant

Marlene M. Hinsch, Production Manager

Diana A. Morgan, Editorial Processing Manager

Copy Editing: Rosanne Schulenberg (Supervisor), Patti Narret, Kathy Swartz

Proofreading: Lorraine L. Kruse (Supervisor), Verna Coffman, Patricia Coyne, Elizabeth Petrikenas, Patricia Poznanski, Mary Kay Tinerella, Dorothy Troy

Production Supervisors: Julia Bero (Layout), Thomas J. Handrigan (Illustrations), Marlene M. Hinsch (Editorial), James P. Bagniewski (Advertising)

Art and Senior Production Assistants: Betty Frigerio, Floriana Hayes, Shirley Latronica, Donna Pender, Nancy Keyes, Marilyn Moroney, Susan Routhier, JoAnne Weiskopf

Production Assistants: Karen Branham, E. Linda Eisenberg, Anna Goins, Lucille Kuznicki, Elaine Starks

Manuscript Records: Denise Henderson

Indexing: Phyllis H. O'Donnell (Supervisor), Jane P. Mauldin, Helen F. Topel

Please address communications concerning accepted or published communications to: AMA Specialty Journals, 535 N Dearborn St, Chicago, IL 60610.

Conditions for Acceptance of Color Illustrations

Illustrations in full color are accepted for publication in ARCHIVES OF DERMATOLOGY if the editor believes that color will add significantly to the published manuscript.

When color illustrations are accepted, the American Medical Association will pay part of the expense of reproduction and printing, the remainder to be borne by the author or the institution with which he is affiliated. After deducting AMA's contribution, the author's share is $275 for up to six square finished illustrations. Additional illustrations and special effects, such as outlining, opaquing, or surprinting, will be billed to the author at cost.

Color transparencies must be submitted for evaluation. Do not send color prints unless accompanied by original transparencies. If transparencies are mounted in frames or glass, the material should be carefully packed in gauze and sent with the manuscript in a separate container or between two pieces of pressboard.

Advertising and Subscription Information

ADVERTISING OFFICES: 535 N Dearborn St, Chicago, IL 60610, Area Code 312, 751-6000; and 600 Third Ave, New York, NY 10016, Area Code 212-867-6640.

ADVERTISING PRINCIPLES: Each advertisement in this issue has been reviewed and complies with the principles governing advertising in AMA scientific publications. A copy of these principles is available on request.

CHANGE OF ADDRESS: Please notify the publisher at least six weeks in advance, including both old and new address, and a mailing label taken from the most recent copy. Include your new zip code number.

Cleansing & Moisturizing

New Keri Facial Cleanser is formulated to slow moisture loss from the skin, emulsify oil, and remove dirt and debris as it leaves skin softer and smoother.

Cleansing without drying is a Keri tradition.

Patients who routinely use Alpha Keri® Bath Oil and Alpha Keri® Soap should welcome this new addition to the fine line of Keri skin care products.

New Keri® Facial Cleanser

In 4 oz. plastic bottles. Promoted to physicians only.

WESTWOOD
PHARMACEUTICALS INC.
Buffalo, New York 14213

1977 W.P. Inc.

Instructions for Authors

• Send manuscripts by first-class mail to the Chief Editor, John H. Epstein, MD, 450 Sutter St, San Francisco, CA 94108. Manuscripts are received with the understanding that they are not under simultaneous consideration by another publication. Accepted manuscripts become the permanent property of the ARCHIVES and may not be published elsewhere without permission from the publisher (AMA).

In addition, in view of *The Copyright Revision Act of 1976*, effective Jan 1, 1978, transmittal letters to the editor should contain the following language: "In consideration of the American Medical Association taking action in reviewing and editing my submission, the author(s) undersigned hereby transfers, assigns, or otherwise conveys all copyright ownership to the AMA in the event that such work is published by the AMA." We regret that transmittal letters not containing the foregoing language signed by all authors of the submission will necessitate delay in review of the manuscript.

Author Responsibility.—All accepted manuscripts are subject to copy editing. The author will receive an edited typescript rather than galley proofs for approval. The author is responsible for all statements in his work, including changes made by the copy editor.

Designate one author as correspondent and provide his address and telephone number. Order reprints at the time the typescript is returned after editorial processing. Specify address to which requests for reprints should be sent.

Manuscript Preparation.—Submit an original typescript and two high-quality copies of the entire manuscript. All copy (including references, legends, and tables) must be typed double-spaced on 22 × 28-cm (8½ × 11-inch), heavy-duty white bond paper. Ample margins should be provided.

Refer to patients by number (or, in anecdotal reports, by fictitious given names). Real names or initials should not be used in the text, tables, or illustrations.

Titles.—Titles should be short, specific, and clear. They should not exceed 42 characters per line, including punctuation and spaces, and be limited to two lines, if possible. The title page should include the full names and academic affiliations of all authors, the address to which requests for reprints should be sent, and, if the manuscript was presented at a meeting, the name of the organization, place, and date on which it was read.

Style of Writing.—The style of writing should conform to acceptable English usage and syntax. Slang, medical jargon, obscure abbreviations, and abbreviated phrasing are to be avoided.

Informed Consent.—Manuscripts reporting the results of experimental investigations of human subjects must include a statement to the effect that informed consent was obtained after the nature of the procedure(s) had been fully explained.

Abstract.—Provide an abstract (135-word maximum) of the article, including statements of the problem, method of study, results, and conclusions. The abstract replaces the summary.

References.—List references in consecutive numerical order (not alphabetically). Once a reference is cited, all subsequent citations should be to the original number. All references must be cited in the text or tables. Unpublished data and personal communications should not be listed as references. References to journal articles should include (1) author(s), (2) title, (3) journal name (as abbreviated in *Index Medicus*), (4) volume number, (5) inclusive page numbers, and (6) year, in that order. References to books should include (1) author(s), (2) chapter title (if any), (3) editor (if any), (4) title of book, (5) city of publication, (6) publisher, and (7) year. Volume and edition numbers, specific pages, and name of translator should be included when appropriate. The author is responsible for the accuracy and completeness of the references and for their correct text citation.

Metrication.—All measurements must be in metric units. English units may also be given parenthetically if the measurements were originally done in English units.

Illustrations.—Use only those illustrations that clarify and augment the text. Submit illustrations in duplicate, unmounted and untrimmed. Do not send original artwork. Send high-contrast glossy prints (not photocopies). Figure number, name of senior author, and arrow indicating "top" should be typed on a gummed label and affixed to the back of each illustration. All lettering must be legible after reduction to column size. Artwork submitted for publication may be relettered to achieve uniformity of lettering style throughout the journal. Magnification and stain should be provided when pertinent. Illustrations should preferably be in a proportion of 12.5 × 18 cm (5 × 7 inches).

An experienced medical illustrator should be employed whenever possible for the preparation of all artwork. Template lettering or preset type is preferred to hand-lettered labels. If halftone artwork with labels is submitted, affix type and leaders to a clear acetate overlay registered to the base drawing. Labels and leaders should be applied directly to the drawing board surface if the artwork consists only of line ink technique.

Illustrations in full color are accepted for publication if the editors believe that color will add significantly to the published manuscript. The ARCHIVES will pay part of the expense of reproduction and printing color illustrations, the remainder to be borne by the author or his sponsor. After deducting the ARCHIVES contribution, the author's share is $275.00 for up to six square-finished illustrations that can be arranged on a one-page layout. Any additional illustrations or special effects will be billed to the author at cost. Positive color transparencies (35 mm preferred) must be submitted for an evaluation. Do not send color prints unless accompanied by original transparencies. All transparencies should be carefully packed and sent with the manuscript.

Legends.—Legends should be typed double-spaced, beginning on a separate sheet of paper. Length should be limited to a maximum of 40 words.

Photographic Consents.—A letter of consent must accompany all photographs of patients in which a possibility of identification exists. It is not sufficient to cover the eyes to mask identity.

Acknowledgments.—Illustrations from other publications must be acknowledged. Include the following when applicable: author(s), title of article, title of journal or book, volume number, page(s), month, and year. The publisher's permission to reprint should be submitted to the ARCHIVES after the manuscript has been formally accepted.

Statistical Review.—Manuscripts containing statistical evaluations should include the name and affiliation of the statistical reviewer.

Tables.—Each table should be typed double-spaced, including all headings, on a separate sheet of 22 × 28-cm (8½ × 11-inch) paper. Do not use larger size paper. If a table must be continued, use a second sheet and repeat all heads and stubs. Each table must have a title.

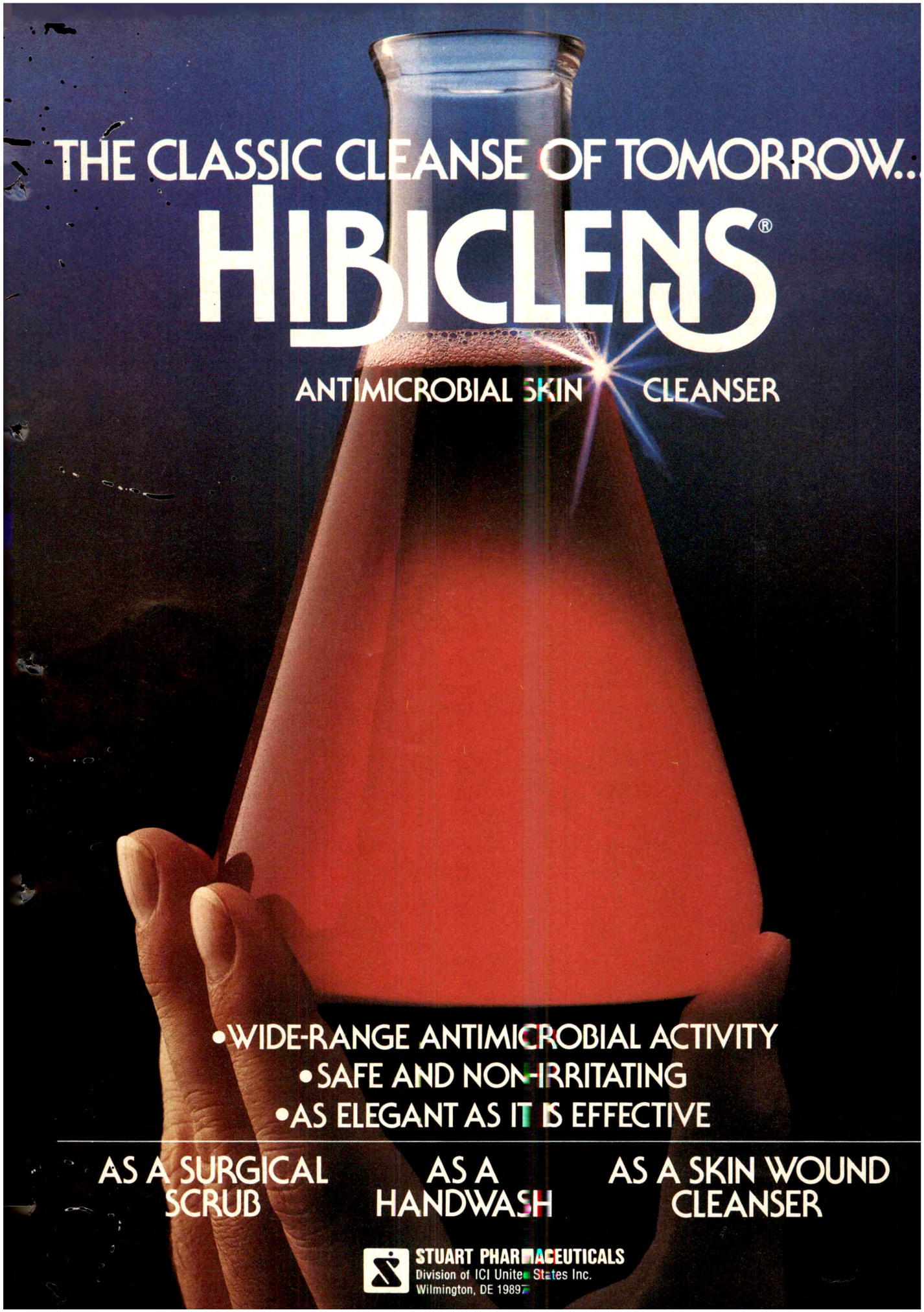
THE CLASSIC CLEANSE OF TOMORROW...
HIBICLENS®
ANTIMICROBIAL SKIN CLEANSER
•WIDE-RANGE ANTIMICROBIAL ACTIVITY
•SAFE AND NON-IRRITATING
•AS ELEGANT AS IT IS EFFECTIVE
AS A SURGICAL SCRUB
AS A HANDWASH
AS A SKIN WOUND CLEANSER
STUART PHARMACEUTICALS
Division of ICI United States Inc.
Wilmington, DE 19897



Hymenoptera Allergy

Phadebas RAST provides an accurate means of documenting IgE mediated allergic sensitivity to stinging insects.

Phadebas RAST®

the *in vitro* alternative

Pharmacia Diagnostics AB
Uppsala, Sweden

Pharmacia Diagnostic

Argentina Laboratorios Dr. Gador y Cia., S.A.C.I. Casilla de Correo 4041 1006 BUENOS AIRES. **Australia** Pharmacia (South Seas) Pty. Ltd. P.O. Box 175 4 Byfield Street NORTH RYI N.S.W. 2113. **Austria** Pharmacia Gesellschaft m.b.H. Rathausplatz 4 A-1010 WIEN. **Belgium** N.V. Pharmacia Belga S.A. Bld. Gen. Jacqueslaan 26 B-1050 BRUSSELS. **Brazil** Empre Medimex Importação e Comércio Ltda. Rua Cardoso Marinho, 40 Caixa Postal 33-ZC-00 RIO DE JANEIRO. **Canada** Pharmacia (Canada) Ltd. 2044 boul. St. Régis Blvd. DORVAL, Québ H9P 1H6. **Denmark** Pharmacia AS, Herredsvejen DK-3400 HILLERÖD. **Finland** Pharmacia OY Norrskensvägen 6, SF-02100 ESBO. **France** Pharmacia France S.A. Rue de Marly Parl F-78150 LE CHESNAY. **German Federal Rebublic** Deutsche Pharmacia G.m.b.H. Munzinger Strasse 9 Postfach 5480 D-7800 FREIBURG. **Great Britain** Pharmacia (G.B.) Ltd. Paramo House 75 Uxbridge Road LONDON W5 5SS. **Greece** G.A. Kambanis Imports-Exports-Representations 3 Iridanou Street ATHENS 612. **Italy** Importex Chimici Farmaceutici S.p.A. P.O. Box Via Flavia 122/124 I-34100 TRIESTE. **Mexico** Internacional Cientifica S.A. Apartado Postal 2-807 Angel del Campo 17-A MEXICO 12 D.F. **The Netherlands** Gist-Brocades N.V. Diagnost Dept. P.O. Box 324 Frijdastraat 7–9 RIJSWIJK (Z H) 2109. **Norway** Norsk Pharmacia A/S Postboks 2005 Grünerløkka OSLO 5. **Portugal** J.A. Baptista D'Almeida Lda. Apartado 1339 LISBOA **Spain** Atom, Paseo del Monte 34 BARCELONA 12. **Sweden** Pharmacia Norden AB Diagnostics Dept. Box 159 751 04 UPPSALA 1. **Switzerland** Pharmacia -pdf- (Schweiz) A.G. 214 Seefe strasse CH-8034 ZUERICH. **USA** Pharmacia Diagnostics Division of Pharmacia Inc. 800 Centennial Avenue PISCATAWAY New Jersey 08854. **Other countries** Pharmacia Diagnostics Box 17 S-751 03 UPPSALA 1 Sweden.

Maximized Moisturization and Emolliency

A natural humectant which occurs in normal healthy skin:

Sodium pyrrolidone carboxylate (NaPCA):
Proven superior to the most commonly-used humectants in water-holding capability and restoration of extensibility.[1] NaPCA is extremely hygroscopic, imbibing 60% of its weight in water at a humidity of 58%.[2]

A superior humectant which *locks* moisture into the stratum corneum:

Lactic Acid:
Lactic acid has the unique ability to be adsorbed onto the cells of the stratum corneum and to be retained there even after rinsing with water for 30 minutes long after "the effect of other humectants was lost."[1]

An occlusive lipid barrier to help retard evaporation:

Special emulsion base is highly concentrated and helps reduce water loss from the stratum corneum.

Formula: Lactic Acid USP 5.0%
Na-PCA 2.5%
in an oil-in-water lotion base containing: purified water, mineral oil, isopropyl palmitate, coceth-6, sodium hydroxide, glyceryl stearate, myristyl lactate, cetyl alcohol, carbomer-940, imidazolidinyl urea, fragrance, dehydroacetic acid.

Please see LactiCare File Card for full prescribing information.

LactiCare® Lotion

How Supplied: In 8 Oz. Polyethylene Bottles With Flip-Top Dispenser Caps

STIEFEL
Logical Dermatologicals
Stiefel Laboratories, Inc., Oak Hill, N.Y. 12460

1. Middleton, J.D.: Development of a skin cream designed to reduce dry and flaky skin. *J. Soc. Cosm. Chem.*, **25**, 519-534.

2. Laden, Karl: Natural moisturizing factors in skin. *American Perfumer and Cosmetics*, **82**, 77-79, Oct. 1967.

Still the only oral antipruritic with q12h convenience

Before prescribing, see complete prescribing information in SK&F literature or *PDR*. The following is a brief summary.

* **Indications**

Based on a review of this drug by the National Academy of Sciences—National Research Council and/or other information, FDA has classified the indications as follows:

Effective: For symptomatic relief of pruritic symptoms in urticaria.

Possibly effective: For relief of pruritic symptoms in neurodermatitis, allergic dermatitis, contact dermatitis, atopic dermatitis, chickenpox, pruritus ani and vulvae.

Final classification of the less-than-effective indications requires further investigation.

Contraindications: Comatose patients; presence of large amounts of C.N.S. depressants; bone marrow depression; idiosyncrasy or hypersensitivity to this drug or other phenothiazines; in newborn or premature children; in nursing mothers; in acutely ill and/or dehydrated children.

Warnings: May impair mental and/or physical ability required for potentially hazardous tasks (driving vehicles, operating machinery); may impair mental alertness in children. Concomitant use with alcohol or other C.N.S. depressants may have additive effect. Warn patients accordingly.

Use with extreme caution in patients with asthmatic attack, narrow-angle glaucoma, prostatic hypertrophy, stenosing peptic ulcer, pyloroduodenal obstruction, bladder neck obstruction, patients receiving MAO inhibitors.

Do not use in women of childbearing potential. There are reported instances of jaundice and prolonged extrapyramidal symptoms in infants whose mothers received phenothiazines during pregnancy.

Use with caution in children, as administration may result in excitation; overdosage may produce hallucinations, convulsions, sudden death.

Elderly patients (60 or older) are more prone to develop the following phenothiazine side effects: hypotension, syncope, toxic confusional states, extrapyramidal symptoms (especially parkinsonism), excessive sedation.

Precautions: May increase, prolong or intensify sedative action of C.N.S. depressants (when administered concomitantly, narcotic or barbiturate dosage should be reduced to ¼ or ½); lead to restlessness and motor hyperactivity in patient with pain being treated with narcotics; block or reverse the pressor effect of epinephrine. Use cautiously in persons (particularly children) with acute or chronic respiratory impairment, as it may suppress cough reflex; in persons with cardiovascular disease, liver function impairment, or history of ulcer discase. The drug's slight antiemetic action may obscure signs of intestinal obstruction, brain tumor, toxic drug overdose.

Adverse Reactions: (Note: May produce adverse reactions attributable to both phenothiazines and antihistamines, although not all the following have

Controls the itching* promptl
...while you treat the cause

Temaril® Spansule®

Each 'Spansule' capsule contains trimeprazine tartrate equivalent to 5 mg. of trimeprazine.

brand of sustained release capsules

been reported with 'Temaril'. There have been occasional reports of sudden death in patients receiving phenothiazine derivatives chronically. Drowsiness, extrapyramidal reactions (opisthotonos, dystonia, akathisia, dyskinesia, parkinsonism), particularly with high doses, hyperreflexia in newborn (when used during pregnancy), dizziness, headache, lassitude, tinnitus, incoordination, fatigue, blurred vision, euphoria, diplopia, nervousness, insomnia tremors and grand mal seizures, excitation, catatonic-like states, neuritis and hysteria, oculogyric crises, disturbing dreams/nightmares, pseudoschizophrenia, intensification and prolongation of action of C.N.S. depressants, atropine, heat, organophosphorus insecticides.

Also postural hypotension, reflex tachycardia, bradycardia, faintness, cardiac arrest, ECG changes, anorexia, nausea, vomiting, epigastric distress, diarrhea, constipation, dry mouth, increased appetite and weight gain, urinary frequency and dysuria, urinary retention, early menses, induced lactation, gynecomastia, decreased libido, inhibition of ejaculation, false positive pregnancy tests, thickening of bronchial secretions, tightness of chest, wheezing, nasal stuffiness, urticaria, dermatitis, asthma, laryngeal edema, angioneurotic edema, photosensitivity, lupus erythematosus-like syndrome, anaphylactoid reactions, leukopenia, agranulocytosis, pancytopenia, hemolytic anemia, elevation of plasma cholesterol levels, thrombocytopenic purpura, jaundice, erythema, peripheral edema, stomatitis, high or prolonged glucose tolerance curves, glycosuria, elevated spinal fluid proteins, reversed epinephrine effects.

After prolonged phenothiazine administration at high dosage, the following have occurred: skin pigmentation, ocular changes (the appearance of lenticular and corneal opacities, epithelial keratopathies, pigmentary retinopathy). Vision may be impaired.

Drug Interactions: MAO inhibitors and thiazide diuretics prolong and intensify anticholinergic effects. Combined use of MAO inhibitors and phenothiazines may result in hypertension and extrapyramidal reactions. Phenothiazines potentiate C.N.S. depressant and analgesic effects of narcotics. Phenothiazine effects may be potentiated by oral contraceptives, progesterone, reserpine, nylidrin HCl.

Supplied: 'Spansule' capsules — in bottles of 50. Syrup — Each 5 ml. teaspoonful contains trimeprazine tartrate equivalent to 2.5 mg. of trimeprazine and alcohol 5.7%, in 4 fl. oz. bottles. Tablets — Each tablet contains trimeprazine tartrate equivalent to 2.5 mg. of trimeprazine, in bottles of 100 and 1000. Tablets and 'Spansule' capsules also available in Single Unit Package (SUP) of 100, intended for institutional use only.

Smith Kline & French Laboratories
Division of SmithKline Corporation
Philadelphia, Pa.

SK&F
a SmithKline company

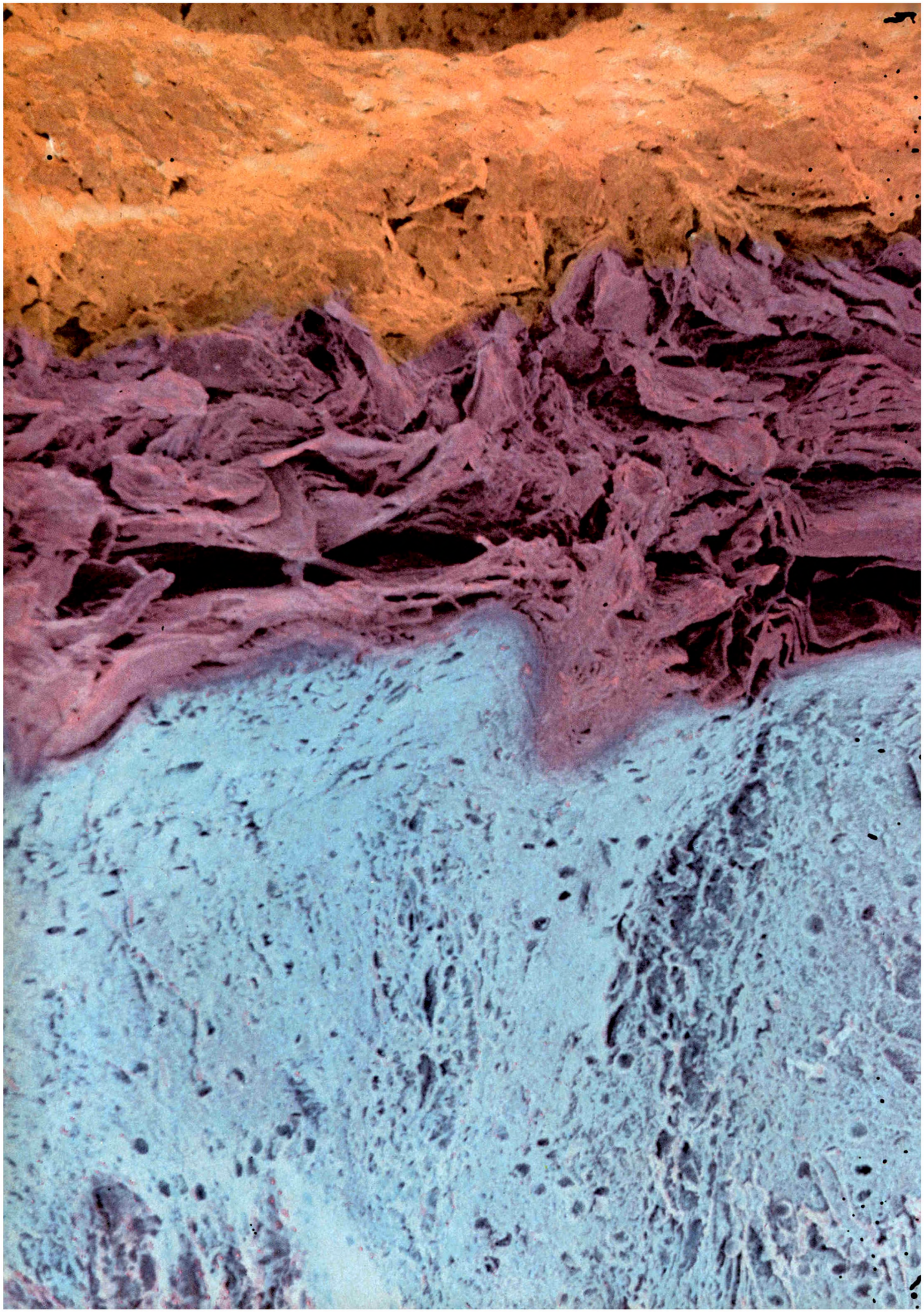

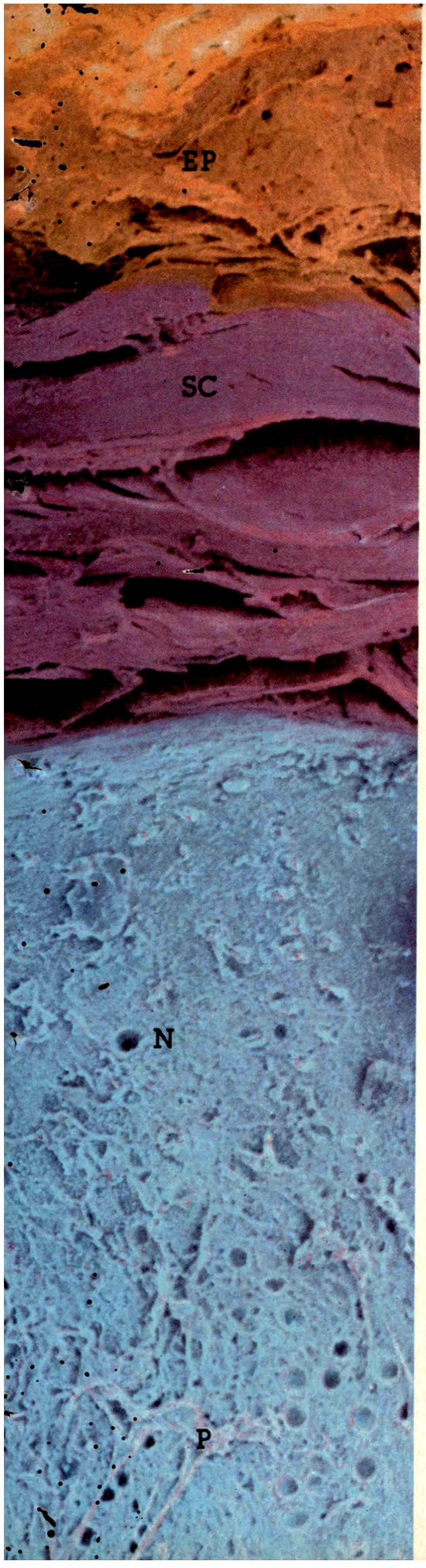

Potency in psoriasis

Potency — A singularly important criterion in selecting a topical steroid for psoriasis as well as all other acute inflammator steroid-responsive conditions.

Fluocinonide — A steroid that is 100% dissolved in the Lidex base for optimal lesion penetration. Anti-inflammatory, vasoconstrictive, antipruritic actions, backed by a proven record of performance.

Available in a form that's right for the case at hand — cream, ointment, or Topsyn® (fluocinonide) Gel, 0.05%.

Lidex®

(fluocinonide 0.05%

See following page for summary of prescribing information.

Cryofractured section of psoriatic epidermis photographed en face. Epidermis (EP) is thickened and stratum corneum (SC) is both thickened and highly disorganized. Dark oval depressions are nuclei (N). Stringy adherent material is exuded serum protein (P).

Color imposed on black-and-white photomicrograph magnified 209X.

SYNTEX
SYNTEX LABORATORIES, INC.
PALO ALTO, CALIFORNIA 94304

LIDEX® (fluocinonide)
Cream and Ointment 0.05%

TOPSYN® (fluocinonide)
Gel 0.05%

Summary of prescribing information

Description

LIDEX cream 0.05%, LIDEX ointment 0.05% and TOPSYN gel 0.05% contain the active compound fluocinonide. Fluocinonide, which is the 21-acetate ester of fluocinolone acetonide, has the chemical formula 6α, 9α -difluoro-11β, 16α, 17α, 21-tetrahydroxypregna-1,4-diene-3, 20-dione, cyclic 16, 17-acetal with acetone 21-acetate. LIDEX cream contains fluocinonide in FAPG® cream, a specially formulated cream base consisting of stearyl alcohol, polyethylene glycol 6000, propylene glycol, 1, 2, 6-hexanetriol and citric acid. This white cream vehicle is greaseless, non-staining, anhydrous and completely water miscible. The base provides emollient and hydrophilic properties. In this formulation, the active ingredient is totally in solution.

LIDEX ointment contains fluocinonide in a specially formulated ointment base consisting of Amerchol CAB (mixture of sterols and higher alcohols), white petrolatum, propylene carbonate and propylene glycol. It provides the occlusive and emollient effects desirable in an ointment. In this formulation the active ingredient is totally in solution.

TOPSYN gel contains fluocinonide in a specially formulated gel base consisting of propylene glycol, propyl gallate, disodium edetate, and Carbopol 940 (carboxypolymethylene) with NaOH and/or HCL added to adjust the pH. This clear, colorless, thixotropic vehicle is greaseless, non-staining and completely water miscible. In this formulation, the active ingredient is totally in solution.

Indications

LIDEX cream and ointment and TOPSYN gel are intended for the relief of inflammatory manifestations of corticosteroid responsive dermatoses.

Contraindications

Topical steroids are contraindicated in vaccinia and varicella. Topical steroids are contraindicated in those patients with a history of hypersensitivity to any of the components of the preparation.

Precautions

If irritation develops, the cream, ointment or gel should be discontinued and appropriate therapy instituted. In the presence of an infection the use of an appropriate antifungal or antibacterial agent should be instituted.

If a favorable response does not occur promptly, the corticosteroid cream, ointment or gel should be discontinued until the infection has been adequately controlled.

If extensive areas are treated, the possibility exists of increased systemic absorption and suitable precautions should be taken.

Although topical steroids have not been reported to have an adverse effect on pregnancy, the safety of their use in pregnant females has not absolutely been established. Therefore, they should not be used extensively on pregnant patients, in large amounts or for prolonged periods of time.

LIDEX® (fluocinonide) cream and ointment and TOPSYN® (fluocinonide) gel are not for ophthalmic use.

Adverse reactions

The following local adverse reactions have been reported with topical corticosteroids:

burning	folliculitis
itching	acneform eruptions
irritation	hypopigmentation
dryness	striae
secondary infection	skin atrophy

Dosage and administration

A small amount should be gently massaged into the affected area three or four times daily, as needed.

How supplied

LIDEX Cream 0.05% – 15 g 30 g and 60 g tubes.
LIDEX Ointment 0.05% – 15 g 30 g and 60 g tubes.
TOPSYN Gel 0.05% 15 g and 60 g tubes.

SYNTEX
SYNTEX LABORATORIES, INC.
PALO ALTO, CALIFORNIA 94304

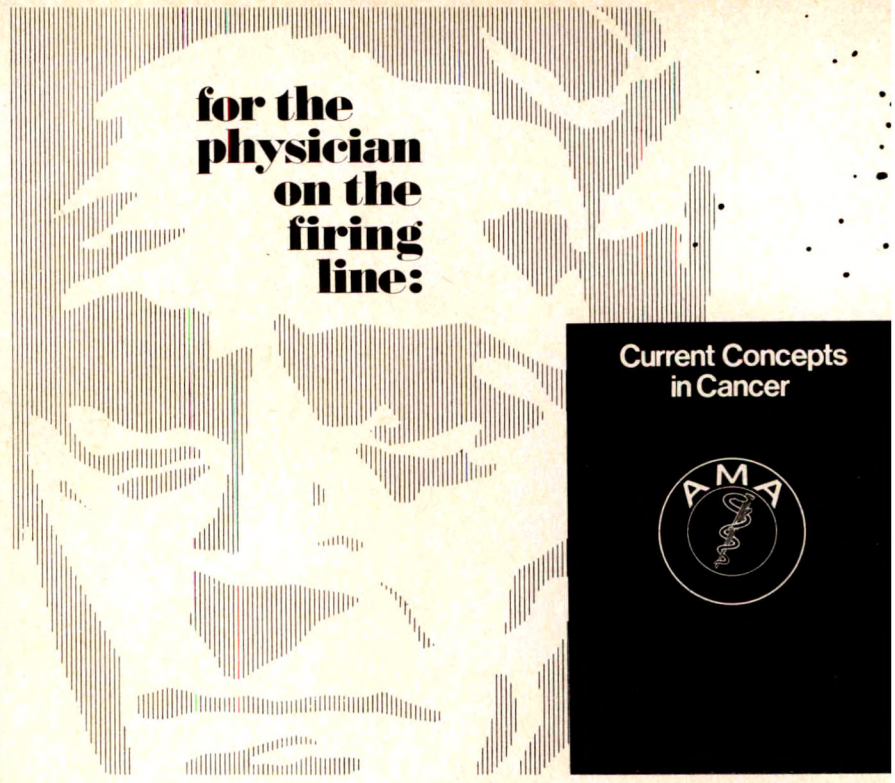

A valuable guide to diagnostic and therapeutic procedure for the cancer patient

Current Concepts in Cancer

While national attention focuses on cancer through specialized canc centers, physicians are aware that the majority of cancer patien are treated in office practices. For most practicing physicians, ca cer treatment is not a research objective, but a very practical pro lem in patient management.

Current Concepts in Cancer, a compilation of articles original published in the *Journal of the American Medical Association,* designed to be a guide for the practitioner in the choice of diagnost and therapeutic procedures for many types of malignancies. It pr sents an objective interdisciplinary view by MDs outstanding in the respective fields, emphasizing principles of diagnosis and surgic radiotherapeutic, and chemotherapeutic treatment.

Make this important resource a part of your reference file. Ord your copy today.

American Medical Association S/J
535 North Dearborn Street
Chicago, Illinois 60610

Please send me _____ copy(ies) of **Current Concepts in Cancer** (OP-281). Price is $10 per copy. Please enclose your remittance with order.

Please Print

Name _____

Address _____

City _____ State _____ Zip _____

There are two faces of severe acne vulgaris

Right profile of patient with Grade IV acne after 6 weeks of tetracycline therapy.

BEFORE adjunctive

MINOCIN®

MINOCYCLINE HCl

CAPSULES 50 mg and 100 mg
SYRUP 50 mg/5 ml

200 mg initially, 100 mg *b.i.d.* or
100 or 200 mg initially, 50 mg *q.i.d.*

MINOCIN Minocycline HCl
Oral and Intravenous Brief Summary

Contraindications: Hypersensitivity to any tetracycline.

Warnings: Intravenous use, particularly in pregnancy, in daily doses exceeding 2 grams has been associated with deaths through liver failure. When need for intensive treatment outweighs potential dangers, perform renal and liver function tests before and during therapy; also follow serum concentrations. In renal impairment, usual doses may lead to excessive accumulation and liver toxicity. Under such conditions, use lower total doses, and, in prolonged therapy, determine serum levels. This hazard is of particular importance in I.V. use in pregnant or postpartum patients with pyelonephritis. In such cases, the blood level should not exceed 15 mcgm/ml, and liver function tests should be made at frequent intervals. Do not prescribe other potentially hepatotoxic drugs concomitantly. The use of tetracyclines during tooth development (last half of pregnancy, infancy and childhood to the age of 8 years) may cause permanent discoloration of the teeth (yellow-gray-brown). This is more common during long-term use but has been observed following repeated short-term courses. Enamel hypoplasia has also been reported. Tetracyclines, therefore, should not be used in this age group unless other drugs are not likely to be effective or are contraindicated. Photosensitivity manifested by an exaggerated sunburn reaction has been observed in some individuals taking tetracyclines. Advise patients apt to be exposed to direct sunlight or ultraviolet light that such reaction can occur, and discontinue treatment at first evidence of skin erythema. Studies to date indicate that photosensitivity is rarely reported with MINOCIN *Minocycline HCl*. In patients with significantly impaired renal function, the antianabolic action of tetracycline may cause an increase in BUN leading to azotemia, hyperphosphatemia, and acidosis. CNS side effects (lightheadedness, dizziness, vertigo) have been reported, may disappear during therapy, and always disappear rapidly when drug is discontinued. Caution patients who experience these symptoms about driving vehicles or using hazardous machinery while taking this drug. **Pregnancy:** In animal studies, tetracyclines cross the placenta, are found in fetal tissues, and can have toxic effects on the developing fetus (often related to retardation of skeletal development). Embryotoxicity has been noted in animals treated early in pregnancy. **Newborns, infants and children:** All tetracyclines form a stable calcium complex in any bone-forming tissue. Prematures, given oral doses of 25 mg./kg. every 6 hours, demonstrated a decrease in fibula growth rate, reversible when drug was discontinued. Tetracyclines are present in the milk of lactating women who are taking a drug in this class.

(cont'd)

There are two faces of severe acne vulgaris

Right profile of patient with acne vulgaris clearing after 6 weeks of MINOCIN therapy.

AFTER adjunctive MINOCIN® MINOCYCLINE HCl

CAPSULES 50 mg and 100 mg
SYRUP 50 mg/5 ml

200 mg initially, 100 mg *b.i.d.* or
100 or 200 mg initially, 50 mg *q.i.d.*

MINOCIN Minocycline HCl
Oral and Intravenous Brief Summary (continued)

Precautions: Use may result in overgrowth of nonsusceptible organisms, including fungi. If superinfection occurs, institute appropriate therapy. In veneral diseases when coexistent syphilis is suspected, darkfield examination should be done before treatment is started and blood serology repeated monthly for at least four months. Patients on anticoagulant therapy may require downward adjustment of such dosage. Test for organ system dysfunction (*e.g.*, renal, hepatic and hemopoietic) in long-term use. Treat all group A beta-hemolytic streptococcal infections for at least 10 days. Avoid giving tetracycline in conjunction with penicillin.

Adverse Reactions: GI: (with both oral and parenteral use): anorexia, nausea, vomiting, diarrhea, glossitis, dysphagia, enterocolitis, inflammatory lesions (with monilial overgrowth) in anogenital region. **Skin:** maculopapular and erythematous rashes. Exfoliative dermatitis (uncommon). Photosensitivity is discussed above ("Warnings"). **Renal toxicity:** rise in BUN, dose-related (see "Warnings"). **Hypersensitivity reactions:** urticaria, angioneurotic edema, anaphylaxis, anaphylactoid purpura, pericarditis, exacerbation of systemic lupus erythematosus. In young infants, bulging fontanels have been reported following full therapeutic dosage, disappearing rapidly when drug was discontinued. **Blood:** hemolytic anemia, thrombocytopenia, neutropenia, eosinophilia. **CNS:** (see "Warnings"). When given in high doses, tetracyclines may produce brown-black microscopic discoloration of thyroid glands: no abnormalities of thyroid function studies are known to occur.

NOTE: Concomitant therapy: Antacids containing aluminum, calcium, or magnesium impair absorption; do not give to patients taking oral minocycline. Studies to date indicate that absorption of MINOCIN *Minocycline HCl* is not notably influenced by foods and dairy products.

CNS side effects including light-headedness, dizziness, or vertigo have been reported with MINOCIN. Patients who experience these symptoms should be cautioned about driving vehicles or using hazardous machinery while on minocycline therapy.

Lederle

LEDERLE LABORATORIES
A Division of American Cyanamid Comp
Pearl River, N.Y. 10965

Printed in U.S.A.

November 1977

41

AVEENO®
Colloidal Oatmeal
bath for sensitive skin

When you treat inflammatory diseases, such as wet dermatitis (including allergic, atopic and contact), intertrigo or wet pruritus, a colloidal oatmeal bath may prove valuable, adjunctive therapy.

Soak Away The Discomfort With AVEENO COLLOIDAL OATMEAL.

- **Cleans naturally**—a soap-free way to absorb dirt and excess oil.
- **Comforts gently**—soothingly soaks hard-to-reach and widespread problem areas.
- **Long-lasting protection**—colloidal oatmeal film continues to protect after bathing.
- **Helps restore normal skin pH.**

Available in 1 lb. and 4 lbs. boxes.

Cooper Laboratories, Inc., Wayne, N.J. 07470 Cooper

WHEN DERMATOSES TAKE SHAPE

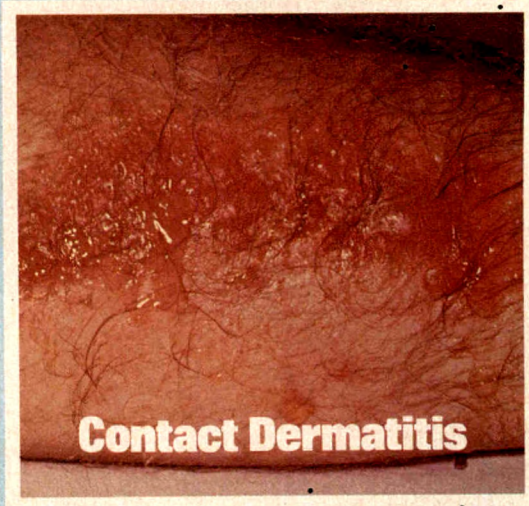

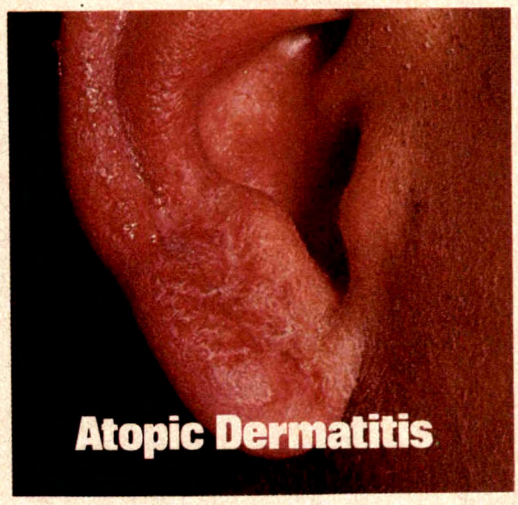

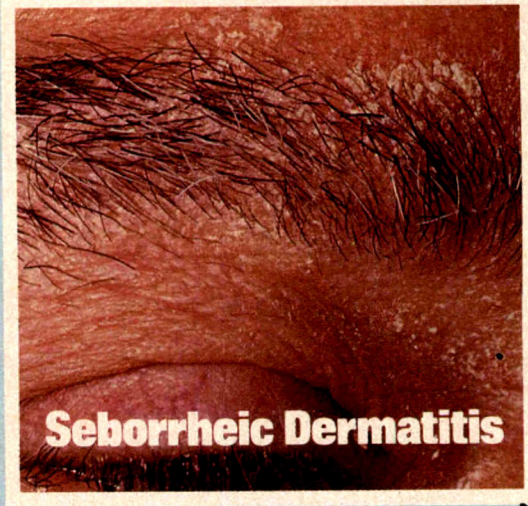

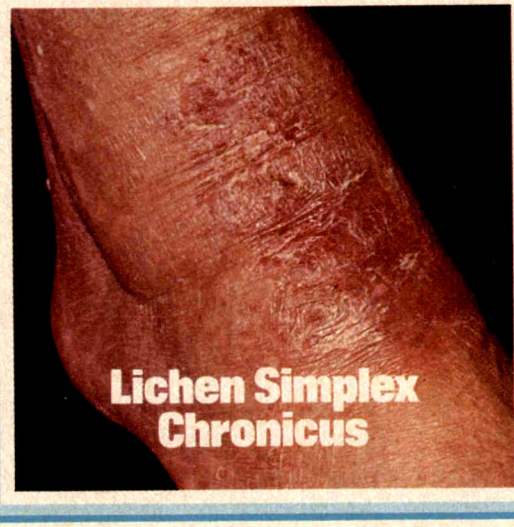

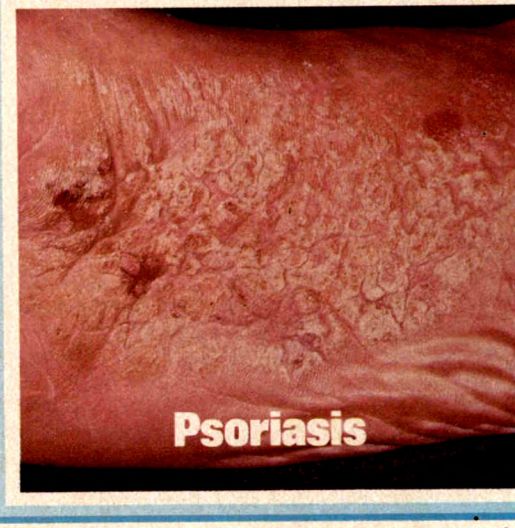

COPYRIGHT © 1977, SCHERING CORPORATION. ALL RIGHTS RESERVED. SLS-866

Schering

DIPROSONE® TAKES CHARGE!

BRAND OF
BETAMETHASONE
DIPROPIONATE

Prompt and Effective Topical Action for Everyday Steroid-Responsive Dermatoses

- Rapid onset of response
- Economy and convenience of b.i.d. dosage
- Occlusive dressings rarely needed
- Sensitivity is unusual



Available for prescribing flexibility in cream, ointment, and lotion.
Also available in aerosol, which is indicated for contact dermatitis only

Please see Clinical Considerations section which follows...

DIPROSONE®
brand of betamethasone dipropionate
Cream 0.05%, Ointment 0.05%, Lotion 0.05% w/w, Aerosol 0.1% w/w
(Potency expressed as betamethasone)
For Dermatologic Use Only

ACTIONS: DIPROSONE **Cream, Ointment, Lotion,** and **Aerosol** are primarily effective because of their anti-inflammatory, antipruritic, and vasoconstrictive actions.

INDICATIONS: DIPROSONE **Cream, Ointment,** and **Lotion** are indicated for the relief of the inflammatory manifestations of corticosteroid-responsive dermatoses.

DIPROSONE **Aerosol** is indicated solely for the adjunctive topical management for the relief of inflammatory manifestations of acute contact dermatitis.

DIPROSONE **Aerosol** has not been shown to be effective in any steroid-responsive dermatosis other than contact dermatitis.

CONTRAINDICATIONS: DIPROSONE **Cream, Ointment, Lotion,** and **Aerosol** are contraindicated in vaccinia and varicella. Topical steroids are contraindicated in those patients with a history of hypersensitivity to any of the components of such preparations.

DIPROSONE **Aerosol** is also contraindicated for use under occlusive dressings.

WARNINGS FOR DIPROSONE AEROSOL: Keep DIPROSONE **Aerosol** away from eyes or other mucous membranes. Use only as directed; intentional misuse by deliberately concentrating or inhaling the contents can be harmful or fatal. Avoid freezing of the tissue by not spraying for more than three seconds, at a distance of not less than six inches. Contents under pressure. Do not puncture. Do not use or store near heat or open flame. Exposure to temperatures above 120° Farenheit may cause bursting. Never throw container into fire or incinerator. Keep DIPROSONE **Aerosol** out of reach of children.

PRECAUTIONS: If irritation develops with the use of DIPROSONE products, treatment should be discontinued and appropriate therapy instituted. In the presence of an infection, the use of an appropriate antifungal or antibacterial agent should be instituted. If a favorable response does not occur promptly, the corticosteroid should be discontinued until the infection has been adequately controlled.

If extensive areas are treated or if the occlusive technique is used, the possibility exists of increased systemic absorption of the corticosteroid and suitable precautions should be taken. Although topical steroids have not been reported to have an adverse effect on pregnancy, the safety of their use in pregnant females has not been absolutely established. Therefore, they should not be used extensively in pregnant patients, in large amounts or for prolonged periods of time. DIPROSONE products are not for ophthalmic use.

ADVERSE REACTIONS: The following local adverse reactions have been reported with topical corticosteroids: burning; itching; irritation; dryness; folliculitis; hypertrichosis; acneiform eruptions; hypopigmentation. Additionally, the following may occur with DIPROSONE **Aerosol** and also may occur more frequently with occlusive dressings than without such therapy: maceration of the skin; secondary infection; skin atrophy; striae; miliaria.

DOSAGE AND ADMINISTRATION: DIPROSONE **Cream** and **Ointment** are applied as a thin film over the affected skin areas twice daily, in the morning and at night. Clinical studies of DIPROSONE have indicated that applications twice a day are generally adequate.

Apply a few drops of DIPROSONE **Lotion** to the affected areas and massage lightly until it disappears. Apply twice daily, in the morning and at night. For the most effective and economical use, apply nozzle to affected area and gently squeeze bottle.

DIPROSONE **Aerosol** may be held upright or inverted during use. The spray should be directed onto the affected area from a distance of not less than six inches and applied for only three seconds. Apply DIPROSONE **Aerosol** sparingly to the affected skin area three times a day.

Aerosol packaged by Aerosol Techniques, Inc., Armstrong Laboratories Division, West Roxbury, MA. 02132.

For more complete details, consult package insert or Schering literature available from your Schering Representative or Professional Services Department, Schering Corporation, Kenilworth, New Jersey 07033.

DECEMBER 1977

DERMATOLOGISTS
PLASTIC/ENT SURGEONS

We are a multi-office group expanding in California. There are now 10 associates including 3 Board Certified surgeons (ENT or Plastic) and Board Certified or Qualified Dermatologists. The opportunities are for full or part-time.

If you are Board Certified or Eligible, we have the capability of enhancing your present skills with additional training, if needed. We do maintain a strict division of services according to training. Remuneration and opportunity for ownership participation are excellent.

We advertise our services in good taste. We are dedicated to provide high quality medical services. We invite your personal inspection of our facilities. If you have further interests, please send your curriculum vitae to my personal attention. E. Frankel, M.D., 4322 Wilshire Blvd. L.A., CA 90010 (213) 938-2191.

For the part-time occupational physician...



An invaluable quick reference guide to occupational dermatoses

The AMA's new guide, *Occupational Dermatoses* is an invaluable aid for physicians working part-time in occupational health programs.

It provides a ready reference for specific information on the causes, diagnosis, prevention, and treatment of occupational skin diseases. It also discusses management of prolonged and recurrent dermatoses, medico-legal aspects, and provides extensive references.

To order your copy ($1 ea.) of *Occupational Dermatoses, OP-108,* write: Order Dept., American Medical Association, 535 N. Dearborn St., Chicago, Ill. 60610.

Multiple Actinic Keratoses...

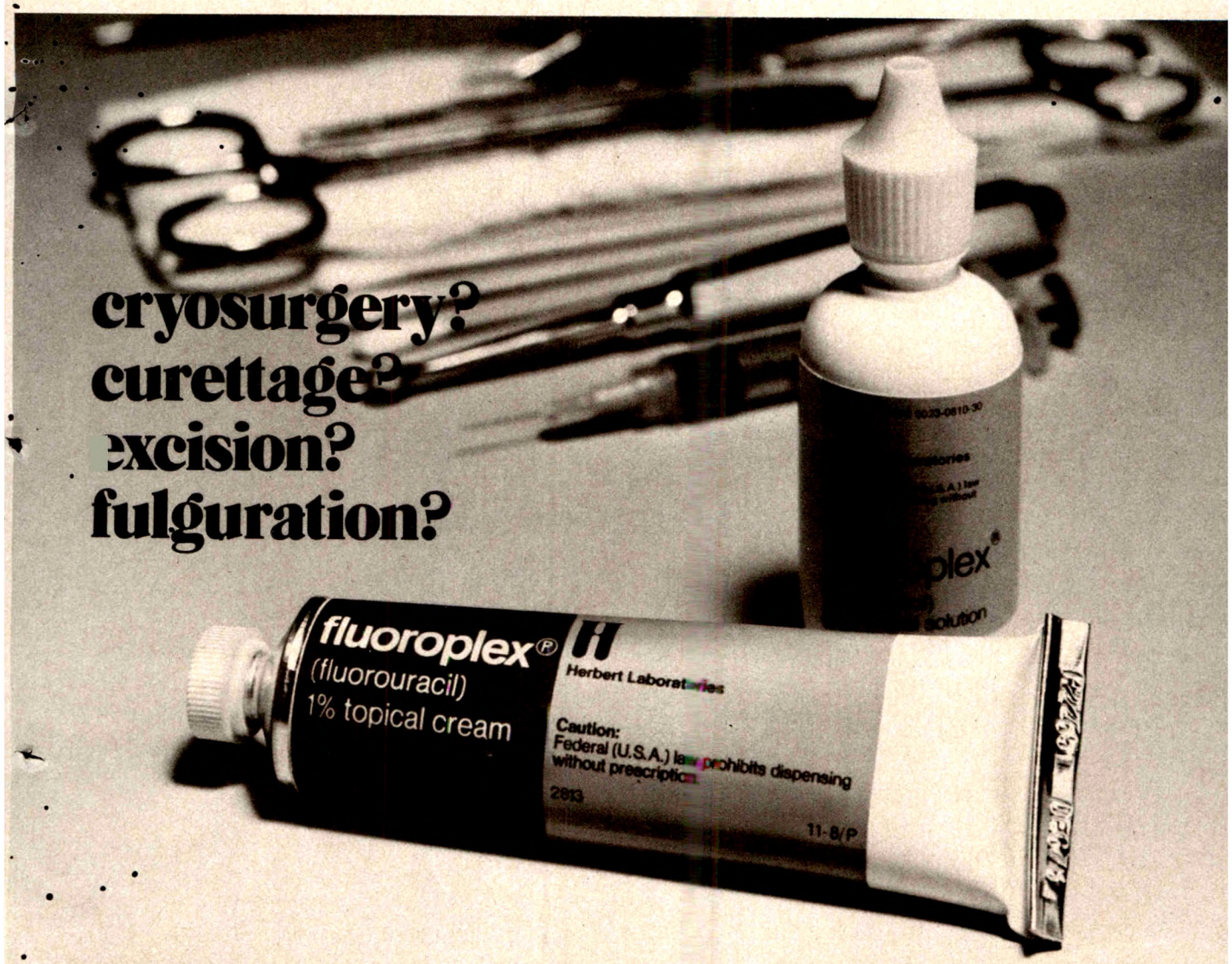

C · the conservative medical approach?

Fluoroplex.® A medical alternative to surgery. The only topical 5-FU available in low 1% dosage forms...Cream and Solution (both paraben free).

The treatment of choice for facial lesions.

Just as effective as higher dosage fo
Reveals preclinical lesions.[1]

1. Simmonds, W.L. Read before the North American Clinical Dermatologic S
Athens, Greece, 1975, quoted in Skin and Allergy News 6:3 (Aug) 1975.

Herbert Laboratories
Dermatology Divisior
Allergan Pharmaceuti
Irvine, California 927

FLUOROPLEX® (fluorouracil) 1% Topical Solution and 1% Topical Cream. **DESCRIPTION:** Fluoropl (fluorouracil) 1% Topical Cream is a stable, standardized cream formulation of fl n an emulsion base with the following formula: fluorouracil...1.0%, with: benzyl alcohol (0.5%), ethoxylated stearyl alcohol, mineral oil, isopropyl myristate, sodium hydroxide, and puri Fluoroplex (fluorouracil) 1% Topical Solution is a stable, standardized solution of fluorouracil in a clear propylene glycol base with the following formula: fluorouracil...1.0%, with: propyl sodium hydroxide-hydrochloric acid to adjust to pH9, and purified water. Fluorouracil is a modified pyrimidine similar to uracil and thymine, with whose metabolism it competes. It is a v alline substance with a melting point of 283±2°C., an empirical formula of $C_4H_3FN_2O_2$ and a molecular weight of 130.08. It has a characteristic ultraviolet absorption maximum of 26 microns in 0.1N HCl. **INDICATIONS:** Fluoroplex (fluorouracil) 1% Topical Solution and Fluoroplex (fluorouracil) 1% Topical Cream are indicated for the topical treatment of multiple acti keratoses. **CONTRAINDICATIONS:** Should not be used in patients with known hypersensitivity to any of the components of the drug. **WARNINGS:** 1) If an occlusive dressing is used, e an increase in the incidence of inflammatory reactions to the adjacent normal skin. 2) The patient should avoid prolonged exposure to sunlight or other forms of ultraviolet irradiati treatment with Fluoroplex as the intensity of the reaction may be increased. **Use in Pregnancy:** Safety for use in pregnancy has not been established. **PRECAUTIONS:** The medication pplied with care near the eyes, nose and mouth. Excessive reaction in these areas may occur due to irritation from accumulation of drug. To rule out the presence of a frank neoplasm should be made of those areas failing to respond to treatment or recurring after treatment. **ADVERSE REACTIONS:** Pain, pruritus, burning, irritation, inflammation, dermatitis and tela have been reported. Occasionally, hyperpigmentation and scarring have also been reported. **DOSAGE AND ADMINISTRATION:** The patient should be instructed to apply sufficient me cover the entire face or other affected areas. Apply medication twice daily with non-metallic applicator or fingertips and wash hands afterwards. A treatment period of 2-6 weeks is usually Increasing frequency of application and a longer period of administration with Fluoroplex® may be required on areas other than the head and neck. When Fluoroplex is applied to kerato response occurs with the following sequence: erythema, usually followed by scaling, tenderness, erosion, ulceration, necrosis and re-epithelization. When the inflammatory reaction reach sion, necrosis and ulceration stage, the use of the drug should be terminated. Responses may sometimes occur in areas which appear clinically normal. These may be sites of subclinical acti keratoses which the medication is affecting. **HOW SUPPLIED:** Fluoroplex (fluorouracil) 1% Topical Solution is available in 30 ml plastic dropper bottles. On prescription only. Fluoroplex (flu 1% Topical Cream is available in 30 gm tubes. On prescription only. Avoid freezing. Store at controlled room temperature (59°-86°F).

Superior to the most widely used brand of topical steroid in psoriasis and atopic dermatitis.

Based on the evidence.

In double-blind, parallel studies,* Topicort® (desoximetasone) Emollient Cream 0.25% demonstrated greater efficacy than betamethasone valerate cream 0.1% in the two most common corticosteroid-responsive dermatoses.

		NO. OF PATIENTS	Overall Evaluation: EXCELLENT & GOOD	Overall Evaluation: EXCELLENT (CLEARANCE OF DISEASE)
ATOPIC DERMATITIS	TOPICORT	39	100%	77%
	BETAMETHASONE VALERATE	41	90%	54%
PSORIASIS	TOPICORT	61	84%	43%
	BETAMETHASONE VALERATE	56	63%	21%

These recently conducted U.S. studies confirm the outstanding worldwide acceptance of Topicort in more than 30 countries for up to 4 years.

*Data on file and available upon request from Hoechst-Roussel Pharmaceuticals Inc., Somerville, New Jersey 08876.

Less than 1% incidence of side effects.
Of 488 patients in the clinical trials, side effects were seen in only 4 (0.8%).* And in 2 of the 4 patients, the relationship of side effects to the drug was uncertain.

The convenience of b.i.d. dosage. And the uniqueness of a preservative-free, emollient cream base.
The specially developed, preservative-free Topicort base combines the emollience of an ointment with the cosmetic acceptability of a cream in a water-in-oil emulsion. This makes Topicort (desoximetasone) especially useful in psoriatic and other dry, scaly dermatoses.

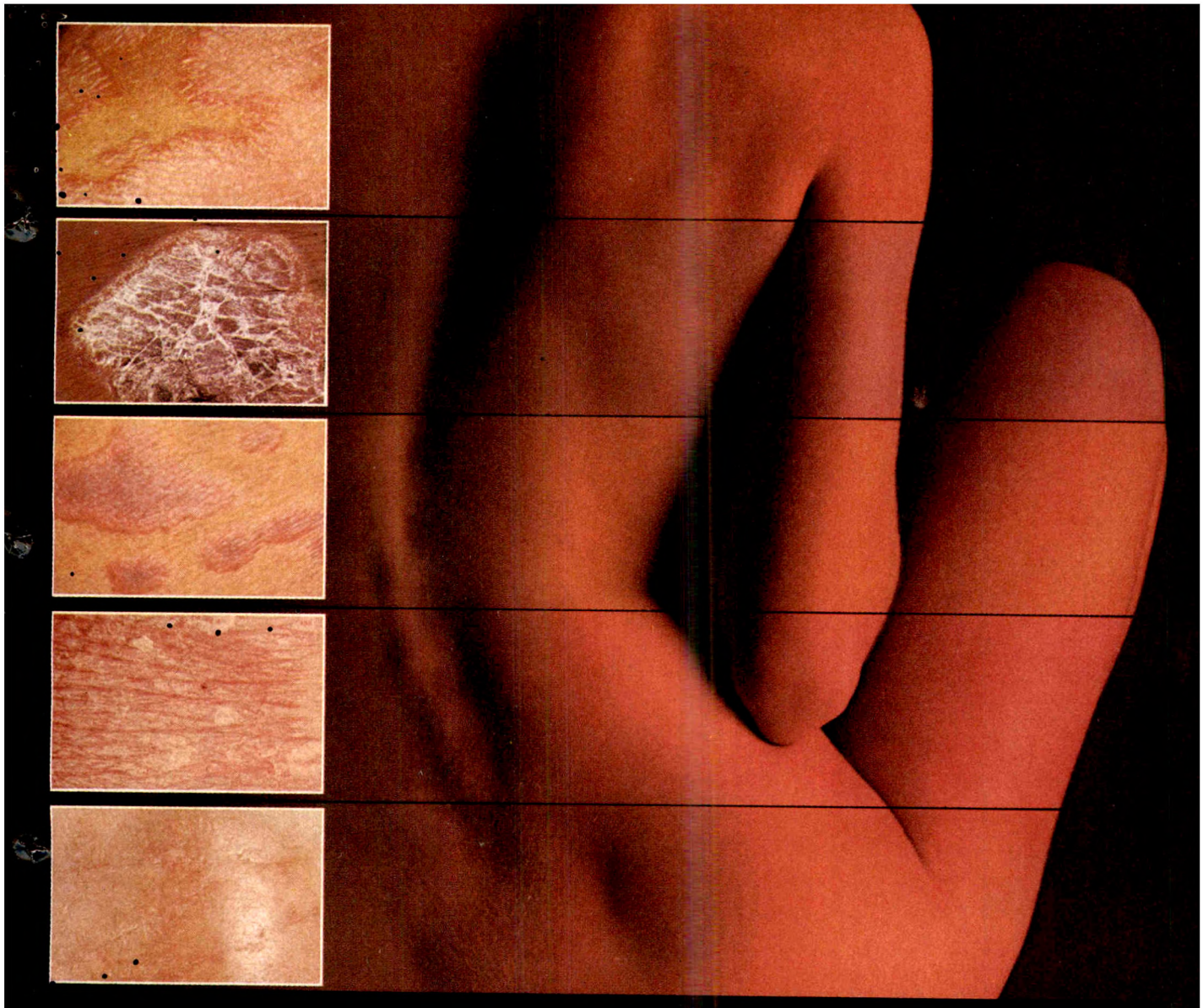

TOPICORT®
(DESOXIMETASONE)
EMOLLIENT CREAM 0.25%

An important innovation from the research laboratories of
Hoechst-Roussel Pharmaceuticals Inc.

Please consult full prescribing information on following page.

EDITION

TOPICORT® (desoximetasone) EMOLLIENT CREAM 0.25%

Description: Topicort® (desoximetasone) Emollient Cream 0.25% contains the active synthetic corticosteroid desoximetasone. The chemical name of desoximetasone is 9α - fluoro - 11β, 21 - dihydroxy - 16α - methylpregna - 1,4 - diene-3,20-dione. The chemical structure is:

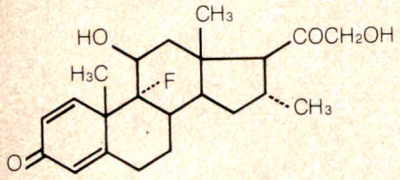

Each gram of Topicort® (desoximetasone) Emollient Cream 0.25% contains 2.5 mg desoximetasone in an emollient cream consisting of isopropyl myristate, cetylstearyl alcohol, white petrolatum, mineral oil, lanolin alcohol and purified water.

Actions: Topicort® (desoximetasone) Emollient Cream is primarily effective because of its anti-inflammatory, antipruritic and vasoconstrictive actions.

Indications: Topicort® (desoximetasone) Emollient Cream is indicated for the relief of inflammatory manifestations of corticosteroid-responsive dermatoses.

Contraindications: Topical steroids are contraindicated in vaccinia, varicella and in those patients with a history of hypersensitivity to any of the components of the preparation. This preparation is not for ophthalmic use.

Precautions: If local infection exists, suitable concomitant antimicrobial or antifungal therapy should be administered. If a favorable response does not occur promptly, application of the corticosteroid should be discontinued until the infection is adequately controlled.

Although systemic side effects associated with absorption of topical corticosteroid preparations are rare, their possible occurrence must be kept in mind when these preparations are used over large areas or for an extended period of time, or if occlusive technique is used.

If irritation or sensitization develops, the preparation should be discontinued and appropriate therapy instituted.

Although topical steroids have not been reported to have an adverse effect on pregnancy, the safety of their use during pregnancy has not been absolutely established; therefore, they should not be used extensively on pregnant patients, in large amounts, or for prolonged periods of time.

Adverse Reactions: The following local adverse reactions have been reported with topical corticosteroids: burning, itching, irritation, striae, skin atrophy, secondary infection, dryness, folliculitis, hypertrichosis, acneform eruptions and hypopigmentation. The following may occur more frequently with occlusive dressings: maceration of the skin, secondary infection, skin atrophy, striae, and miliaria.

Dosage and Administration: Apply a thin film of Topicort® (desoximetasone) Emollient Cream 0.25% to the affected skin areas twice daily. Rub in gently.

How Supplied: Topicort® (desoximetasone) Emollient Cream 0.25% is supplied in 15-gram tubes.

HOECHST-ROUSSEL
PHARMACEUTICALS INCORPORATED
SOMERVILLE, NEW JERSEY 08876

Send us this coupon today and we'll send you a way to slash your claims reporting costs and time

S/J

Return Order Blank To:
American Medical Association
535 North Dearborn
Chicago, Illinois 60610
(312) 751-6000

Type of form		Quantity—in orders of:	Price Including Handling and Postage
☐ Single Form (One page pads of a hundred)	OP-407	1,000 ☐	$ 18.50
		5,000 ☐	78.00
		10,000 ☐	138.00
☐ Two Forms (Original and one carbon)	OP-408	1,000 ☐	28.00
		5,000 ☐	112.00
		10,000 ☐	210.00
☐ Continuous Form (Original and one carbon) (For Computer Printers)	OP-409	1,000 ☐	28.00
		5,000 ☐	112.00
		10,000 ☐	210.00

TOTAL _____

Name _____

Street Address _____

City _____ State _____ Zip _____

Check or money order must accompany this order and be made payable to the American Medical Association.

The Official AMA Uniform Health Insurance Claim Form

Accepted by Medicare, Commercial Carriers, many Blue Shield Plans, and many states for Medicaid.

Developed by the AMA in cooperation with carriers, government agencies, and other groups, this form is the most current and most widely used claim reporting form available. It significantly reduces the time and cost of claims reporting. **Note:** A number of private firms are marketing an outdated, more expensive version of this form. To be certain you are using the most current and acceptable form to third party insurers, we encourage you to use the official AMA form. Order today.

what's best for the care of dr
or premature aging
or wrinkled skin...
DUE TO EPIDERMA
DEHYDRATION?

SUPPLIED: 2 OZ. TUBES

WRITE FOR SAMPLES

DOAK PHARMACAL CO., INC. WESTBURY, N.Y. 11

DISTRIBUTOR IN CANADA
TRANS-CANADA DERMAPEUTICS LTD., MONTREAL 23, QUE

IN SKIN INFECTIONS, WHERE CLEANLINESS REQUIRES MORE THAN SOAP

BETADINE® Skin Cleanser

Degerms as it cleanses

Patients can use BETADINE Skin Cleanser to degerm and cleanse face, hands and body, gently and thoroughly—particularly when it is essential to prevent autoinoculation of new sites, as may be the case in infected acne pimpl

BETADINE Skin Cleanser, with its rich, golden lather, provides these advantages:

- Prompt, broad-spectrum microbicidal action—kills both gram-positive and gram-negative bacteria (including antibiotic-resistant strains), fungi, viruses, protozoa and yeasts.
- Maintains microbicidal activity in the presence of blood, pus and serum.
- Virtually nonirritating to skin and mucosa.*
- Nonstaining to skin and natural fabrics.

Supplied: 4 fl. oz. plastic bottles.

*In the rare instance of local irritation or sensitivity, discontinue use by the individual.

Purdue Frederick © COPYRIGHT 1976, THE PURDUE FREDERICK COMPANY

NORWALK, CONN. 06856 A8196 172076

OBJECTIVE: TO SEEK OUT AND DESTROY SOLAR KERATOSES

BEFORE

2/6/75—Diffuse hyperplastic solar keratoses over the dorsa of both hands were present at the start of treatment with twice daily applications of Efudex® (fluorouracil) 5% Cream.

DURING

2/21/75—After slightly more than two weeks of therapy, lesions had become inflamed and excoriated, and subclinical lesions not visible before treatment had become inflamed. Treatment was terminated on 2/27/75 and healing was complete within 2 to 3 weeks.

AFTER

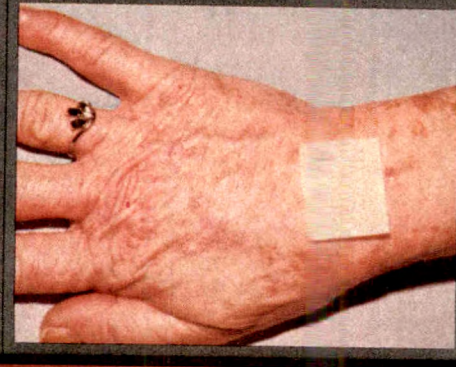

8/4/77—There was no evidence of recurrence at follow-up visit 30 months later. (Note: The redness seen in this photograph is the result of insect bites and is unrelated to the course of therapy.)

Please consult summary of product information on third page of this advertisement.

■ AN EFFECTIVE TOPICAL ALTERNATIVE TO SURGERY FOR MULTIPLE LESIONS AND DIFFICULT TREATMENT SITES.

■ COSMETICALLY GRATIFYING RESULTS, WITH MINIMAL OR NO SCARRING.

■ HIGH DEGREE OF SAFETY...SYSTEMIC TOXICITY RARE.

■ CONVENIENT, ECONOMICAL B.I.D. APPLICATION. APPLY WITH CARE NEAR EYES, NOSE AND MOUTH.

AN EXCLUSIVE ROCHE FORMULATION

Efudex® 5% Cream

fluorouracil/Roche

Solar Keratosis—a premalignant lesion

Among any light-skinned population, extended exposure to the sun may lead to solar keratoses, which commonly occur as multiple lesions on exposed portions of the skin. Because they are the most common types of lesions that progress from minor alteration to cancer,[1] they should be treated. Efudex is a proven cytotoxic agent, with a marked effect on more rapidly growing cells.

1. Pinkus H: The border line between cancer and noncancer, in *Year Book of Dermatology*, edited by Kopf AW, Andrade R, Chicago, p. 16. Copyright© 1967 by Year Book Medical Publishers, Inc. Used by permission.

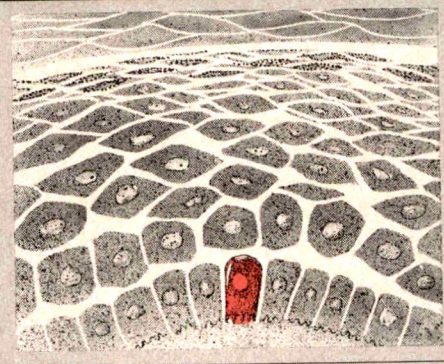

The development of a precancerous epidermal lesion from a germinal basal cell*

This mother cell, with a slightly higher mitotic rate, produces more dysplastic basal cells and also prickle cells.

When these prickle cells reach the surface, a visible clinical lesion results.

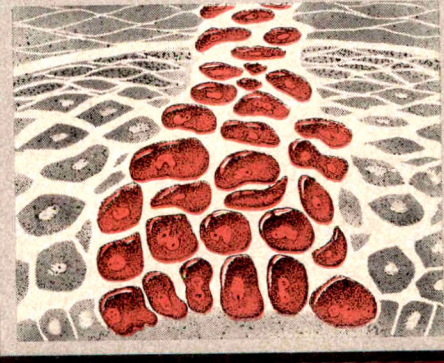

These cells undergo parakeratosis and form a scale. The heavy outline denotes dysplastic cell.

*Adapted from Pinkus H: The border line between cancer and noncancer, in *Year Book of Dermatology*, edited by Kopf AW, Andrade R, Chicago, p. 17. Copyright© 1967 by Year Book Medical Publishers, Inc. Used by permission.

INDICATED FOR SUPERFICIAL BASAL CELL CARCINOMA

Management of superficial basal cell carcinoma is often complicated by multiple lesions which may extend over large areas of the body. Conventional treatments such as surgical or radiation therapy are still preferred for single lesions or those in easily accessible locations. However, topical chemotherapy with Efudex (fluorouracil) 5% can be used for the treatment of multiple superficial lesions over large areas of the body as well as difficult treatment sites. Although during treatment with Efudex (fluorouracil) the lesions and some of the surrounding skin may become inflamed and blistered temporarily, final results are cosmetically gratifying

AN EXCLUSIVE ROCHE FORMULATION

Efudex® 5% Cream
fluorouracil/Roche

Before prescribing, please consult complete product information, a summary of which follows:

Indications: Multiple actinic or solar keratoses. In 5% strength, superficial basal cell carcinoma when conventional methods are impractical, such as with multiple lesions or difficult treatment sites. Establish diagnosis before treating, as this method has not been proven effective in other types of basal cell carcinomas. Conventional techniques preferred for isolated, easily accessible lesions, as success rate is nearly 100%. Success rate with Efudex is about 93%.

Contraindications: Patients with known hypersensitivity to any of its components.

Warnings: If occlusive dressing is used, may increase inflammatory reactions in adjacent normal skin. Avoid prolonged exposure to ultraviolet rays. Safe use in pregnancy not established.

Precautions: If applied with fingers, wash hands immediately. Apply with care near eyes, nose and mouth. Solar keratoses failing to respond should be biopsied. Warn patients that treated area may be unsightly during therapy and sometimes for several weeks after. Perform follow-up biopsies in superficial basal cell carcinoma.

Adverse Reactions: Local—pain, pruritus, hyperpigmentation and burning at application site most frequent; also dermatitis, scarring, soreness, tenderness, suppuration, scaling and swelling. Also reported—insomnia, stomatitis, irritability, medicinal taste, photosensitivity, lacrimation, telangiectasia, leukocytosis, thrombocytopenia, toxic granulation and eosinophilia.

Dosage and Administration: When Efudex is applied erythema occurs, then vesiculation, erosion, ulceration, necrosis, epithelization. *Actinic or solar keratosis*—apply sufficient quantity to cover lesions, twice daily. Usual length of therapy is 2 to 4 weeks. *Superficial basal cell carcinomas*—apply sufficient quantity **(only 5% strength recommended)** to cover lesions, twice daily. Continue treatment for at least 3 to 6 weeks, but possibly as long as 10 to 12.

How Supplied: Solution, 10-ml drop dispensers containing 2% or 5% fluorouracil on a weight/weight basis. Cream, 25-Gm tubes containing 5% fluorouracil in a vanishing cream base.

ROCHE

Roche Laboratories
Division of Hoffmann-La Roche Inc.
Nutley, New Jersey 07110

Atopic dermatitis o
hand and wrist
36 year old male

Added versatility in dermatology

new Lidex®-E (fluocinonide) 0.05%

The established potency of fluocinonide, in a soothing emollient base.

Less drying than a cream, with the lubricating qualities of an ointment–cosmetically acceptable to patients.

Especially useful wherever a soothing topical steroid is indicated, as in atopic dermatitis.

Available in 15g and 60g tubes.

SYNTEX

Please see following page for summary of prescribing information

new Lidex® E (fluocinonide) Cream·0.05%

Prescribing Information

Description LIDEX-E cream 0.05% contains the active compound fluocinonide. Fluocinonide, which is the 21-acetate ester of fluocinolone acetonide, has the chemical formula 6α, 9-difluoro-11β, 16α, 17, 21-tetrahydroxypregna-1, 4-diene-3, 20-dione, cyclic 16, 17-acetal with acetone, 21-acetate.

The cream contains fluocinonide 0.5 mg./g. in a water-washable aqueous emollient base of stearyl alcohol, cetyl alcohol, mineral oil, propylene glycol, sorbitan monostearate, polysorbate 60, citric acid and purified water.

Actions Topical steroids are primarily effective because of their anti-inflammatory, antipruritic and vasoconstrictive actions.

Indications For relief of the inflammatory manifestations of corticosteroid-responsive dermatoses.

Contraindications Topical steroids are contraindicated in vaccinia and varicella.

Topical steroids are contraindicated in those patients with a history of hypersensitivity to any of the components of the preparation.

Precautions If irritation develops, the cream should be discontinued and appropriate therapy instituted.

In the presence of an infection, the use of an appropriate antifungal or antibacterial agent should be instituted. If a favorable response does not occur promptly, the corticosteroid cream should be discontinued until the infection has been adequately controlled.

If extensive areas are treated, the possibility exists of increased systemic absorption and suitable precautions should be taken.

Although topical steroids have not been reported to have an adverse effect on pregnancy, the safety of their use in pregnant females has not absolutely been established. Therefore, they should not be used extensively on pregnant patients, in large amounts or for prolonged periods of time.

This product is not for ophthalmic use.

Adverse reactions The following local adverse reactions have been reported with topical corticosteroids: burning sensations, itching, irritation, dryness, secondary infection, folliculitis, acneform eruptions, hypopigmentation, striae, skin atrophy.

Dosage and Administration A small amount should be gently massaged into the affected area three or four times daily, as needed.

How Supplied LIDEX®-E (fluocinonide) cream 0.05% — 15g. and 60g. tubes.

SYNTEX
SYNTEX LABORATORIES, INC
PALO ALTO, CALIFORNIA 94304

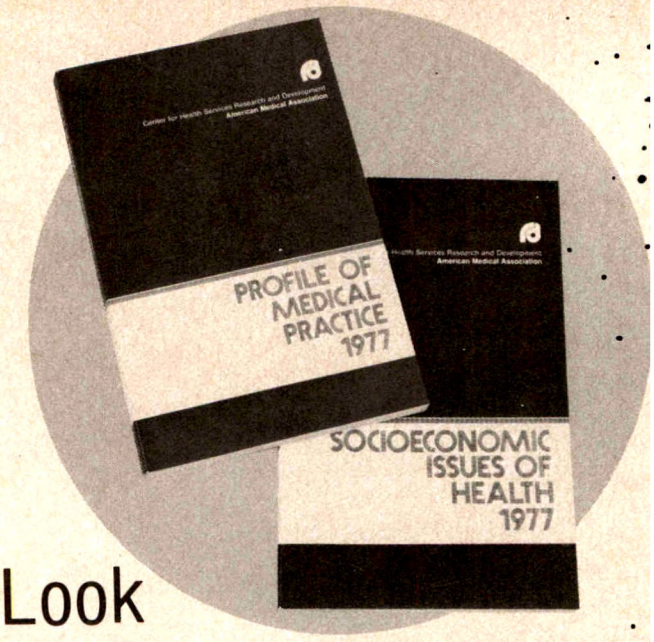

A New Look for the 1977 Red and Blue Books

Those familiar **Red and Blue Books,** published by the American Medical Association's Center for Health Services Research and Development, now have new size. . .new format. . .new data. As a result, you will find them more useful and convenient than ever. Here's a closer look at the 6th annual edition of these authoritative volumes:

Profile of Medical Practice 1977 (Red Book)
The focus is on characteristics of medical practice such as physicians' work patterns, professional expenses, and net income from medical practice. Among the topics covered in short articles are: physician productivity, rural group practice, and hospital utilization by physicians.

Socioeconomic Issues of Health 1977 (Blue Book)
Current data on medical education, medical manpower in the U.S., and financial characteristics of the health services delivery system are featured. Also included are essays on such issues as national health insurance, second surgical opinion programs, and the physician's role in cost accountability.

Quantities are limited, so order today!

S/J

Order Dept.
American Medical Association
535 N. Dearborn
Chicago, IL 60610

_____Profile of Medical Practice (OP-6) $4.50
_____Socioeconomic Issues of Health (OP-5) $4.50

Enclosed is my check for $_____, payable to the American Medical Association.

Name_____

Address_____

City/State/Zip_____

the procedure that benefits millions

Remove 97% of the caffein from 100% pure coffee, and you've got SANKA® Brand Decaffeinated Coffee – the ideal coffee for so many of your patients. SANKA® Brand contains only 3-5 mg of caffein per 6-oz cup (compared to about 50-100 mg in an equivalent cup of regular coffee).

Cardiac patients and hypertensives...insomniacs and anxious patients...patients with caffein-aggravated symptoms of a dermatologic condition...or the housewife overstimulated by caffein – they're just some of the patients who may benefit from your recommendation of SANKA® Brand. It's available in food stores everywhere...in instant, freeze-dried and ground-roast forms. And at restaurants, in convenient single-service packages.

Sanka®
BRAND
97% CAFFEIN-FREE COFFEE
Recommended by more physicians than all other brands of coffee combined

For a FREE Patient Sample Kit, please complete return the coupon.

GF GENERAL FOODS
Maxwell House Division
General Foods Corporation
Box #3143
Kankakee, Illinois 60901

Please send me a FREE kit with patient samples, an informative booklet, "The No-Coffee Edict," and a special coupon for a FREE SANKA® Brand Freeze-Dried Decaffeinated Coffee.

PHYSICIAN'S NAME _____
(please print)

SPECIALTY: ☐ GP/FP ☐ IM ☐ Surg ☐ DO ☐ OBG ☐ Card ☐ ☐ Psych ☐ Other (please specify) _____

STREET _____
(please print)

CITY _____ STATE _____ ZIP _____

PHYSICIAN'S SIGNATURE _____

omplete an continuous
er ge r t r-re n e
dermatoses encourages
full patient co-operation
24 hours a day.

estar® Gel is transparent and virtually odor-free for inconspicuous daytime therapy.

A Balnetar® bath in the evening helps relieve irritating symptoms throughout the night.

Elegant Sebutone® extends tar therapy to the scalp in psoriasis, seborrhea, itchy scalp.

Westwood® Tar products contain the first chemically and biologically standardized tar, bioassayed to insure uniform therapeutic activity. Westwood® Tar is anti-pruritic, keratoplastic, and anti-eczematous.

Therapeutic Tar Gel, 3 oz. Plastic Tube. Equivalent to 5% Coal Tar USP

Therapeutic Emollient Tar Bath, 8 fl. oz. Plastic Bottles. Equivalent to 2.5% Coal Tar USP

Antiseborrheic Liquid Tar Shampoo, 4 and 8 oz. Plastic Bottles. Equivalent to 0.5% Coal Tar USP

estar®

Therapeutic Tar Gel. 3 oz. Plastic Tube.

CAUTION: AFTER USING, TREATED AREAS SHOULD BE PROTECTED FROM SUNLIGHT, ESPECIALLY IF ESTAR HAS BEEN USED ON THE FACE. THIS PRECAUTION SHOULD BE TAKEN FOR AT LEAST 24 HOURS AFTER APPLICATION, UNLESS OTHERWISE DIRECTED. ESTAR SHOULD NOT BE USED ON HIGHLY INFLAMED OR BROKEN SKIN. If used on the scalp temporary discoloration of blond, bleached, or tinted hair may occur. If undue irritation develops or increases, the usage schedule should be changed or ESTAR discontinued. Contact with the eyes should be avoided. In case of contact, flush eyes with water.

Slight staining of clothing may occur. Standard laundry procedures will usually remove stains. For external use only.

Balnetar®

Therapeutic Emollient Tar Bath.
8 fl. oz. Plastic Bottle.

CAUTION: If irritation persists, discontinue use. In rare instances temporary discoloration of blond, bleached or tinted hair may occur. In rare cases BALNETAR may cause allergic irritation attributable to coal tar.

PRECAUTION: After use of BALNETAR, patient should avoid exposure to direct sunlight unless sunlight is being used therapeutically in a supervised, modified Goeckerman regimen. Contact with eyes should be avoided. Patient should be cautioned against slipping when BALNETAR is used in bathtub. Also advise patient that use in a plastic or fiberglass tub may cause staining of the tub.

Sebutone®

Antiseborrheic Liquid Tar Shampoo.
4 oz. and 8 oz. Plastic Bottles.

CAUTION: If undue skin irritation develops or increases, discontinue use. In rare instances, temporary discoloration of blond, bleached or tinted hair may occur.

PRECAUTION: Contact with the eyes is to be avoided. In case of contact flush eyes with water.

WESTWOOD
PHARMACEUTICALS INC.
Buffalo, New York 14213
In Canada, Belleville, Ontario K8N 5E9

Clinically proven.
Cosmetically superior.
Conveniently packaged and economically priced.

© 1978, W.P. Inc.

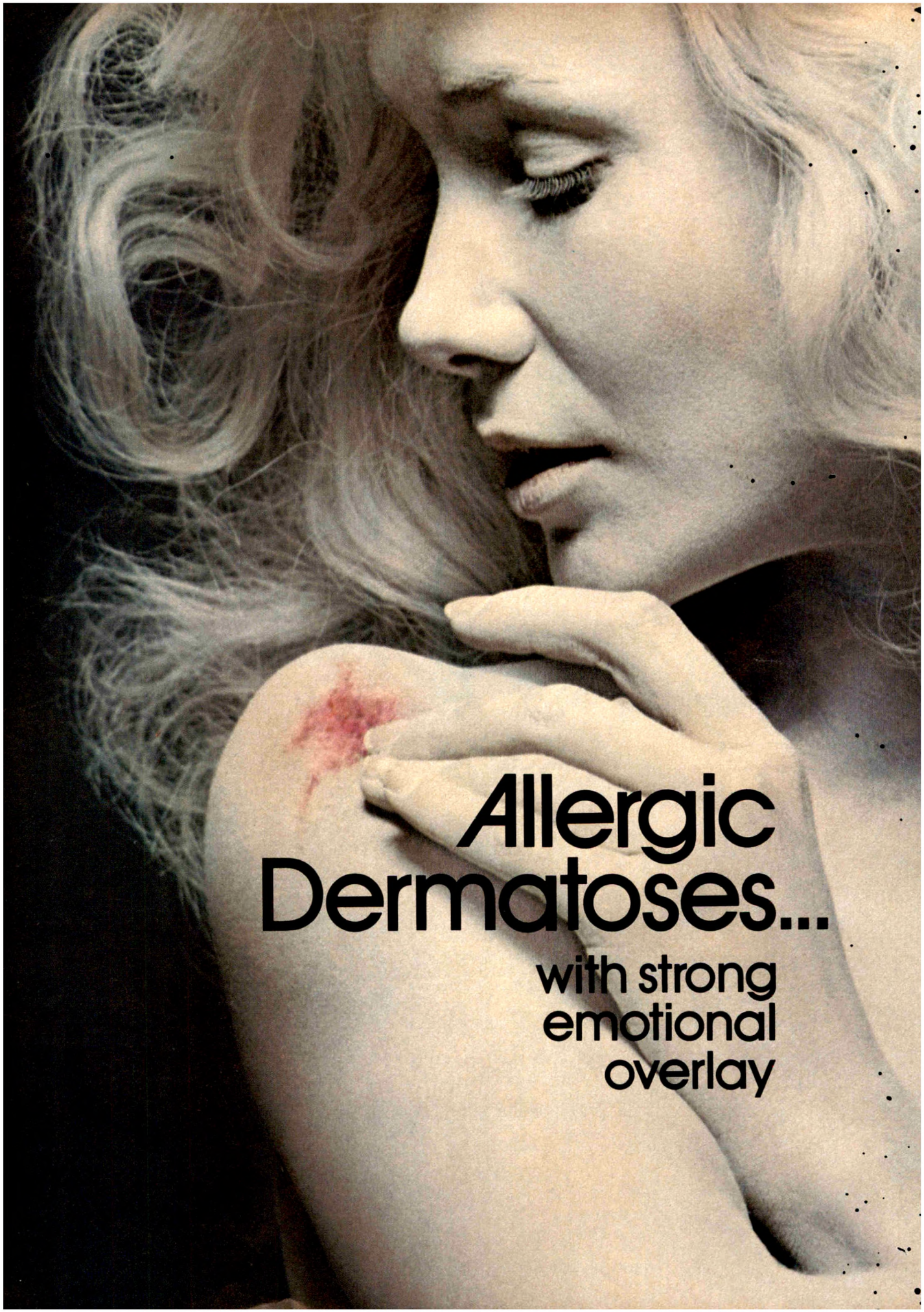
Allergic
Dermatoses...
with strong
emotional
overlay

Contraindications: Hypersensitivity to hydroxyzine. Hydroxyzine, when administered to the pregnant mouse, rat, and rabbit, induced fetal abnormalities in the rat at doses substantially above the human therapeutic range. Clinical data in human beings are inadequate to establish safety in early pregnancy. Until such data are available, hydroxyzine is contraindicated in early pregnancy.

Precautions: Hydroxyzine may potentiate the action of central nervous system depressants such as meperidine and barbiturates. In conjunctive use, dosage for these drugs should be reduced. Because drowsiness may occur, patients should be cautioned against driving a car or operating dangerous machinery.

Adverse Reactions: Drowsiness may occur; if so, it is usually transitory and may disappear in a few days of continued therapy or upon dosage reduction. Dryness of the mouth may occur with higher doses. Involuntary motor activity, including rare instances of tremor and convulsions, has been reported, usually with higher than recommended dosage.

Supply: Tablets, containing 10 mg hydroxyzine hydrochloride, 100's and 500's; Tablets, containing 25 mg or 50 mg, 100's, 500's, and Unit Dose (10 x 10's); Tablets, containing 100 mg, 100's and Unit Dose (10 x 10's); Syrup, containing 10 mg per teaspoonful (5 ml) and ethyl alcohol 0.5% v/v, pint bottles.

Before prescribing or administering, see package circular.

ROERIG Pfizer
A division of Pfizer Pharmaceuticals
New York, New York 10017

as adjunctive therapy

Atarax®
(hydroxyzine HCl)

TABLETS: 10 mg, 25 mg, 50 mg, and 100 mg SYRUP: 10 mg per 5 ml, ethyl alcohol 0.5% v/v

- rapid antianxiety action
- demonstrated antihistaminic/antipruritic activity

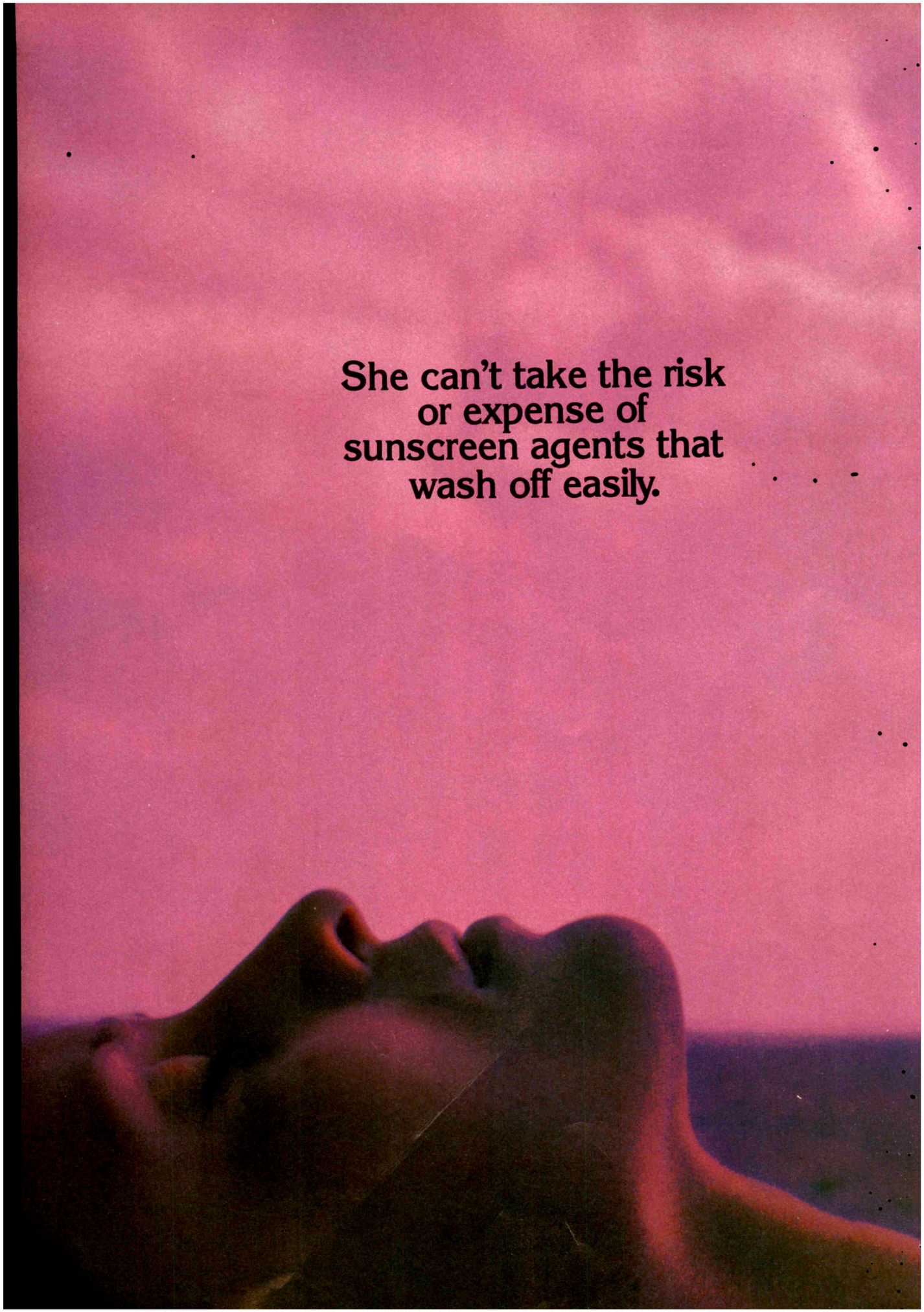
She can't take the risk
or expense of
sunscreen agents that
wash off easily.

Dome

SunGard® Lotion

Effective yet economical because its excellent durability means fewer applications.

SUNGARD provides more durable protection on the skin than PABA 5% or octyl dimethyl PABA 3.3%* (amount of sunscreen agent remaining on skin after water-wash procedure).

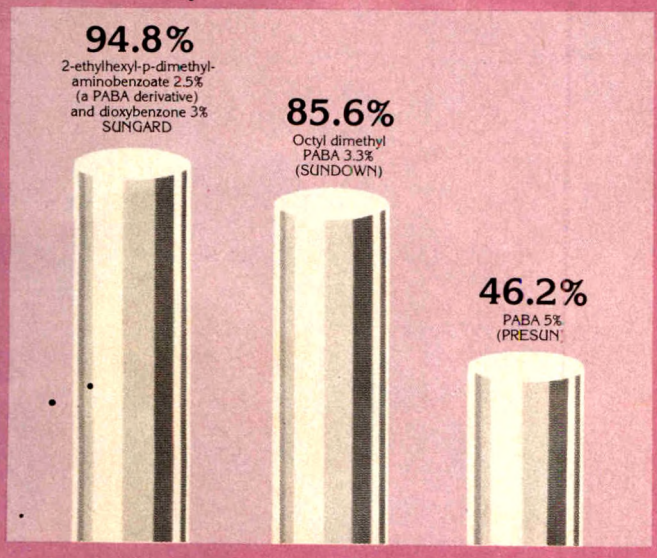

*Data on file at Dome Laboratories.

Broad-range effectiveness
SUNGARD protects against more than just the sunburn (UVB) spectrum—it provides some protection in the photosensitivity (UVA) range as well.

Greater economy from greater substantivity
The more sunscreen remaining on the skin, the better the protection and the fewer applications required to maintain effective protection. As with other sunscreen agents, however, caution your patients about the importance of maintaining continuous protection by reapplying SUNGARD every 3 to 4 hours.

SPF (Sun Protection Factor) 6.3
SUNGARD Lotion is an extra-protection sunscreen product. It allows patients to stay in the sun 6 times as long as before without burning provided there is no heavy perspiration or prolonged swimming.

Yet SUNGARD permits tanning
With SUNGARD, sun-sensitive patients enjoy protection in the erythema range and moderate protection in the photosensitivity range. This permits gradual, natural tanning with repeated exposure to the sun.

SUNGARD...from the company that is a leader in skin-care products.

Dome Laboratories
Division Miles Laboratories Inc MILES
West Haven Connecticut 06516 USA

© 1978 DOME LABORATORIES, DIVISION MILES LABORATORIES, INC. ALL RIGHTS RESERVED. DOM-1694

The good news. The bad news.

American Medical News reports all the news you need to know!

Some of the news about medicine these days is pretty encouraging; some of it is frankly discouraging.

American Medical News prints both kinds of news—good and bad— because you need to know about those developments that could affect the way you practice medicine.

If you want to read just good news and praises of the profession, *American Medical News* isn't your kind of paper. It is a professional newspaper, not a house organ. The AMA Board of Trustees has ordered it to operate that way. That means that *American Medical News* prints both sides of a controversy; it prints what other people say about doctors; it asks discomforting questions; it prints a vast array of stimulating opinions from readers.

Give *American Medical News* just 30 minutes a week; it will give you all the news you need to know about what's happening in the practice of medicine.

Keeping your finger on the pulse of medicine

American Medical **NEWS**

An Informed Membership Is Our Greatest Strength

JANUARY 30, 1978

Carter's '79 budget: More aid for children, less money for schools

President Carter's budget for 1979 contains big increases in funding for child health, and Medicare and Medicaid programs, with substantial cuts in capitation grants for medical education. The increase in the total funding of the National Institutes of Health has been limited to 1.5%, which will not keep up with the rate of inflation in 1979, expected to be approximately 6%.

The Carter budget proposed for fiscal year 1979 (Oct. 1, 1978 to Sept. 30, 1979) contains these proposals:

- A $118-million increase in Medicaid for low-income pregnant women to provide pre-natal care and related ser- ... ...ded child health assess- ... ...3 million. The ... for health services for adolescents, with emphasis on prevention of unwanted pregnancy.
- A $34-million increase in funding for professional standards review organizations.

PSRO funding at $174 million for 1979 will be sufficient to blanket the country and review all Medicaid, Medicare, and child health procedures. HEW officials say, instead, greater use of sampling techniques will allow the program to pick target areas, for review. Surgery will likely be the first target.

- A one-third reduction in capitation assistance to medical, osteopathic, and dental schools. Schools of public health will be funded at the 1978 level. Support for most nursing programs will end. HEW officials say the net effect will be ... medical school tuition and fun- ... the national health service corps and related scholarship programs.

The biggest money item in the health budget is Medicare and Medicaid, which together make up 23% of HEW's budget. This is a significant rise from 1973 when the two programs made up 18% of HEW's budget. Medicare hospital insurance payments will rise 15.3% in 1979 and Medicaid payments to physicians (not including the new programs in child health) will rise about 11%.

The Office of Management and Budget anticipates total outlays for these two programs to be $41.5 billion in 1979, if the Administration's hospital cost containment legislation is enacted by July 1.

"If these proposals are not enacted, the 1979 estimate will be $1.1 billion higher," say Health Care Financing Administration officials.

A modest increase was proposed in funding for health maintenance organizations. HEW proposed $5.3 million for 70 new HMO feasibility grants. HEW wants 172 HMOs operating by 1982, and anticipates there will be 5 million people enrolled in these plans by that time.

Funding for health planning agencies will basically keep pace with inflation. A $9-million increase will bring the planning budget to $152 million.

No major changes in the level of health services in the Veterans Administration were proposed. The VA's health budget will increase about 7% to cope with inflation.

Funds for clinical research in 1979 will be tighter. NIH's budget has leveled off and is shrinking slightly due to inflation. The only exception to this is the National Institute of Child Health and

(See Budget . . . . p. 13)

...rikes a possibility ... hospitals

For the soap-assaulted skins...

AVEENO® BAR

Uncomplicated soap-free adjunctive therapy.

In treating atopic and contact dermatitis, primary therapy can be hindered by continued use of alkaline soaps...conversely, adjunctive therapy can enhance treatment and reduce complications. AVEENO® BAR is your logical uncomplicator.

- **Soothing action** from 50% (by weight) colloidal oatmeal.
- **Gentle cleansing** — 100% soap-free.
- **Helps restore normal skin pH** — AVEENO® BAR is non-alkaline.

Available in 3.2 oz. and 4.4 oz. bars.

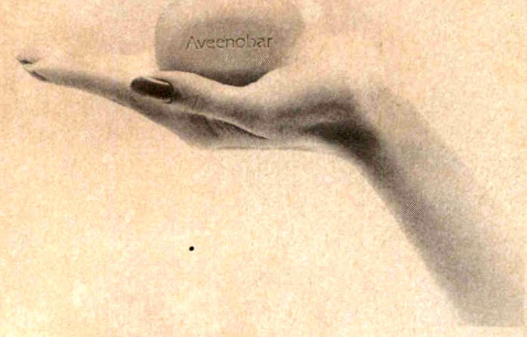

Cooper Cooper Laboratories, Inc., Wayne, New Jersey 07470

THE ONLY WAY TO END THE EPIDEMIC IS OVER HER DEAD BODY.

Kill the female itch mite (*sarcoptes scabiei*) and you've stopped the current scabies epidemic. Because when she burrows deep into the stratum corneum, she defies diagnosis and resists removal by surface-acting medications and cleansers. Her success has been making headlines around the country—with reports of scabies outbreaks in rural and suburban areas as well as in the cities.

A quick and simple diagnosis. Scabies can mimic a number of dermatological conditions,[1-3] such as urticaria, furunculosis and dermatitis—as well as syphilis with which it may coexist. But there's an almost foolproof way to recognize it. Even in the absence of the fierce nocturnal itching[3] and the lesion distribution characteristic of the disease (hands, wrists and elbows in 9 out of 10 cases),[1] a quick microscopic look can confirm your scabies diagnosis.

To demonstrate the itch mite, look for an unscratched, inhabited burrow (wherever the patient says he itches at that very moment is a likely spot). Use a strong light, a magnifying glass and a surgical blade to which a drop of mineral oil is added. Scrape several sites. Transfer the material to a slide, cover and examine under low power magnification.[1,3,4] (If you don't spot any parasites in egg, larvae or adult stages, look for their red fecal compactions. They can be just as diagnostic.)

Kwell: penetrating action to kill mites, their eggs and larvae. Once you've found scabies, there's a positive way to eradicate it. Kwell (1% gamma benzene hexachloride) Lotion or Cream. It penetrates to reach the scabietic burrows, kills the female mites and, of course, the less tenacious males, as well as their eggs and any larvae that may have hatched. In fact, Kwell works so consistently and well against scabies that it has been the most widely prescribed scabicide for three decades.

Nearly 100% effective. The clinical record of Kwell has never been surpassed by any other pediculicide. It is "nearly 100% effective,"[1] and often works with a single application (a second or third application may be made at weekly intervals, if needed). Your patients will appreciate the low risk of sensitization and irritation.[5,6] And you will appreciate that Kwell works so predictably that it serves to confirm your diagnosis of scabies. Not many pharmaceutical preparations can match *that* record of dependability.

Contraindications: Kwell is contraindicated in individuals who develop hypersensitivity to the product or to any of its components.

Precautions: If accidental ingestion occurs, prompt institution of gastric lavage will rid the body of large amounts of the toxicant. However, since oils favor absorption, saline cathartics for intestinal evacuation should be given rather than oil laxatives.

Central nervous system manifestations can be antagonized by the administration of pentobarbital or phenobarbital in sufficiently large doses to the limit of their therapeutic effectiveness. It is not desirable to depress the patient to the point of hypnosis. However, persons poisoned with stimulants may tolerate large doses of barbiturate without undue depression and with great benefit. Intravenous calcium gluconate may be used in conjunction with the barbiturates. Epinephrine should not be used because ventricular fibrillation may result.

If accidental contact with eyes occurs, flush with water. If irritation or sensitization occurs, discontinue the product and consult physician.

Adverse Reactions: Eczematous eruptions due to sensitization of this product have been reported.

Available on prescription as Kwell Lotion in 2 and 16 fl. oz. bottles and as Kwell Cream in 2 oz. and 1 lb. jars. See package insert for complete prescribing information.

References: 1. *Patient Care 7*:94, Nov. 1, 1973. 2. Stankler, L.: *Practitioner 210*:803, June 1973. 3. Domonkos, A.N. (ed.): Andrews' Diseases of the Skin: Clinical Dermatology, ed. 6, Philadelphia, W. B. Saunders Company, 1971, pp. 511-513. 4. Muller, G., *et al: Arch. Dermatol. 107*:70, Jan. 1973. 5. James, B.H.E.: *Br. Med. J. 1*:178, Jan. 15, 1972. 6. Sollman, T.: A Manual of Pharmacology, ed. 8, Philadelphia, W. B. Saunders Company, 1957, p. 178.

SEM Courtesy of J. M. Rower, M.D., Columbus, Ohio.

Reed & Carnrick / Kenilworth, New Jersey 07033

Cream/Lotion

KWELL® gamma benzene hexachloride

THE SCABICIDE OF CHOICE.

An unsurpassed standard of therapy

Vectrin® Capsules

(minocycline hydrochloride capsules, USP)

50 and 100 mg

effective adjunctive treatment in severe acne

Before Treatment

After Treatment

84 DAYS
Vectrin, 50 mg, twice daily

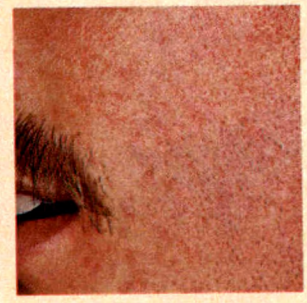

91 DAYS
Vectrin, 50 mg, twice daily

40 DAYS
Vectrin, 100 mg, once daily

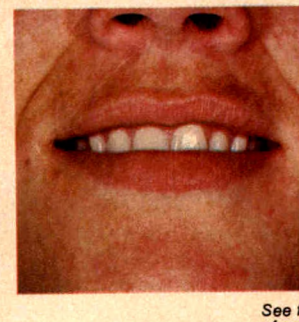

84 DAYS
Vectrin, 100 mg, once daily

PARKE-DAVIS

See following page for brief summary of prescribing information.

VECTRIN Capsules, 50 and 100 mg
(minocycline HCl capsules, USP)
Brief Summary of Prescribing Information

Indicated in severe acne as adjunctive therapy. Consult package insert for complete prescribing information.

Contraindication: Hypersensitivity to any tetracycline.

Warnings: When need for intensive treatment outweighs potential dangers, perform renal and liver function tests before and during therapy; also follow serum concentrations. In renal impairment, usual doses may lead to excessive accumulation and liver toxicity. Under such conditions, use lower total doses, and, in prolonged therapy, determine serum levels. The use of tetracyclines during tooth development (last half of pregnancy, infancy, and childhood to the age of 8 years) may cause permanent discoloration of the teeth (yellow-gray-brown). This is more common during long-term use but has been observed following repeated short-term courses. Enamel hypoplasia has also been reported. Tetracyclines, therefore, should not be used in this age group unless other drugs are not likely to be effective or are contraindicated. Photosensitivity manifested by an exaggerated sunburn reaction has been observed in some individuals taking tetracyclines. Advise patients apt to be exposed to direct sunlight or ultraviolet light that such reaction can occur, and discontinue treatment at first evidence of skin erythema. Studies with minocycline HCl indicated that photosensitivity did not occur. However, reports have been received. In patients with significantly impaired renal function, the antianabolic action of tetracycline may cause an increase in BUN leading to azotemia, hyperphosphatemia, and acidosis. **CNS side effects:** (light-headedness, dizziness, vertigo) have been reported, may disappear during therapy, and always disappear rapidly when drug is discontinued. Caution patients who experience these symptoms about driving vehicles or using hazardous machinery while taking this drug. **Pregnancy:** In animal studies, tetracyclines cross the placenta, are found in fetal tissues, and can have toxic effects on the developing fetus (often related to retardation of skeletal development). Embryotoxicity has been noted in animals treated early in pregnancy. The safety of minocycline HCl for use during pregnancy has not been established. **Newborns, infants, and children:** All tetracyclines form a stable calcium complex in any bone-forming tissue. Prematures, given oral doses of 25 mg/kg every six hours, demonstrated a decrease in fibula growth rate, reversible when drug was discontinued. Tetracyclines are present in the milk of lactating women who are taking a drug in this class.

Precautions: Use may result in overgrowth of nonsusceptible organisms, including fungi. If superinfection occurs, antibiotics should be discontinued and appropriate therapy instituted. In venereal diseases when coexistent syphilis is suspected, darkfield examination should be done before treatment is started and blood serology repeated monthly for at least four months. Patients on anticoagulant therapy may require downward adjustment of such dosage. Test for organ system dysfunction (eg, renal, hepatic, and hemopoietic) in long-term use. Treat all group A beta-hemolytic streptococcal infections for at least 10 days. Avoid giving tetracycline in conjunction with penicillin.

Adverse Reactions: GI: Anorexia, nausea, vomiting, diarrhea, glossitis, dysphagia, enterocolitis, inflammatory lesions (with monilial overgrowth) in anogenital region. **Skin:** Maculopapular and erythematous rashes. Exfoliative dermatitis (uncommon). Photosensitivity is discussed above. (See Warnings.) **Renal toxicity:** Rise in BUN, dose-related. (See Warnings.) **Hypersensitivity reactions:** Urticaria, angioneurotic edema, anaphylaxis, anaphylactoid purpura, pericarditis, exacerbation of systemic lupus erythematosus. In young infants, bulging fontanels have been reported following full therapeutic dosage, disappearing rapidly when drug was discontinued. **Blood:** Hemolytic anemia, thrombocytopenia, neutropenia, eosinophilia. **CNS:** (See Warnings.) When given over prolonged periods, tetracyclines may produce brown-black microscopic discoloration of thyroid glands; no abnormalities of thyroid function studies are known to occur.

NOTE: Concomitant therapy: Antacids containing aluminum, calcium, or magnesium impair absorption; do not give to patients taking oral tetracycline. Studies to date indicate that absorption of VECTRIN (minocycline hydrochloride) is not notably influenced by foods and dairy products.

Full prescribing information available upon request.

PARKE, DAVIS & COMPANY
Detroit, MI 48232

PD-JA-2378-1-P (2-78)



A safe, economical method of permanent hair removal– from face, legs, body

To save valuable office time, you can confidently recommend Perma Tweez to your patients for their home use.

- Battery-operated instrument self-sterilizes when current flows.
- Patented self-correcting needle.
- No-puncture safety feature helps prevent infection.
- Proved clinically safe (report on request).

FOR PHYSICIAN ORDERING

GENERAL MEDICAL CO., Dept D-96
1935 Armacost Ave.
West Los Angeles, CA 90025
30 DAY FREE TRIAL EXAMINATION.
(May be returned with no obligation.)

☐ PERMA TWEEZ $19.95
☐ ATTACHMENT $3.00
(for treating others)
☐ INVOICE AFTER 30 DAYS
☐ CHECK ENCLOSED

DR_____

STREET_____

C/S_____ ZIP_____

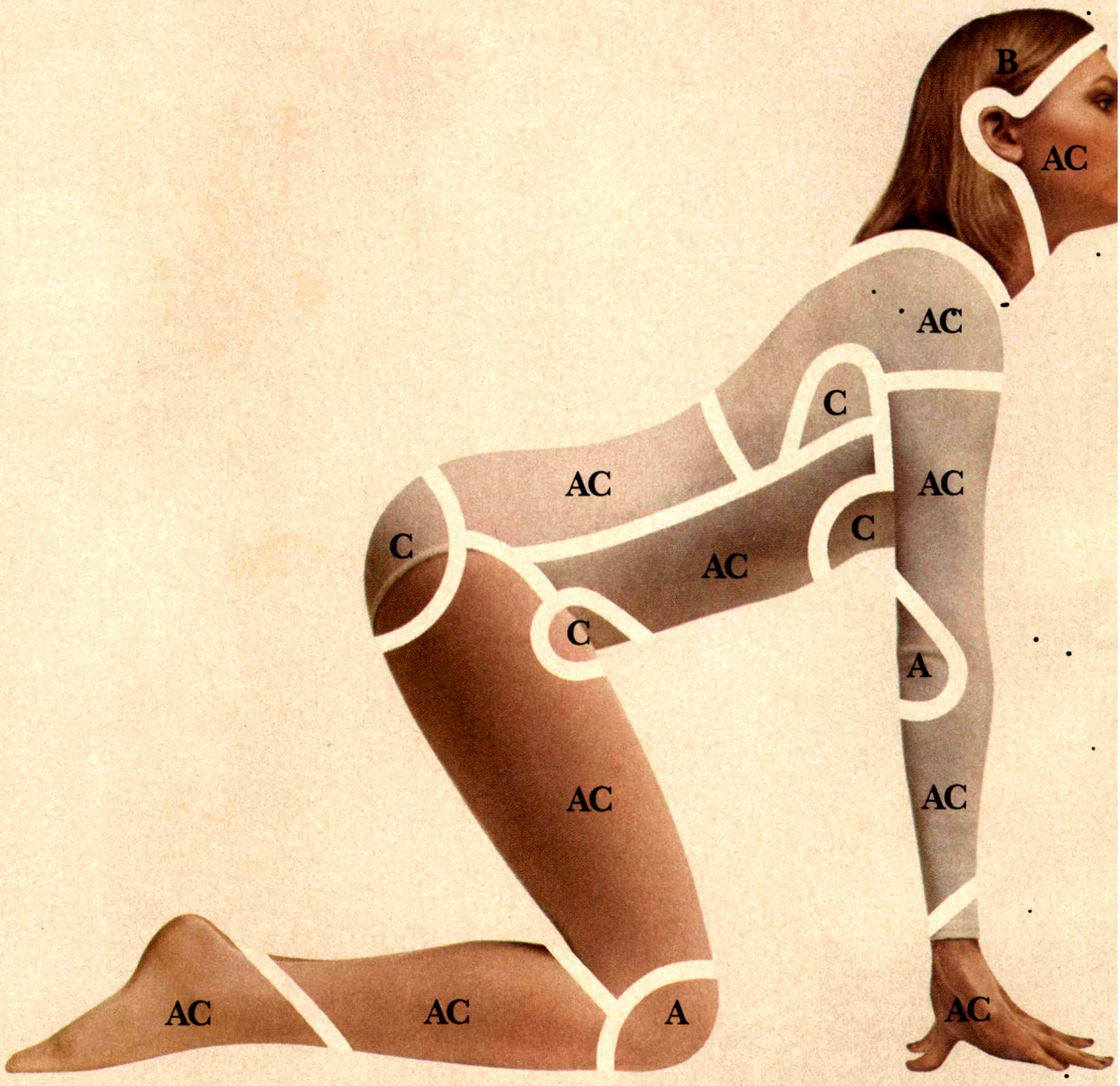

FOR THE ZONES OF DERMATOSES

For dry areas/lesions

A New Halog® Ointment 0.1%

Halcinonide Ointment 0.1%

For scalp lesions

B New Halog® Solution 0.1%

Halcinonide Solution 0.1%

For moist areas/lesions

Full-strength

C Halog® Cream 0.1%

Halcinonide Cream 0.1%

'Maintenance formula'

Quarter-strength

New Halog® Cream 0.025%

Halcinonide Cream 0.025%

Clinical experience

A total of 984 psoriatic patients in US clinical studies were treated with either the Solution, the Creams, or the Ointment. After 2 weeks' therapy,* 151 (78%) of 194 patients improved with Halog Solution, 407 (92.5%) of 440 patients improved with full-strength (0.1%) Halog Cream, 132 (72%) of 184 patients improved with quarter-strength (0.025%) Halog Cream, and 145 (87%) of 166 patients improved with Halog Ointment.

In general, the preferred topical formulations for lesions in specific areas are: solutions for scalp lesions, creams for moist areas/lesions, and ointments for dry areas/lesions. The studies cited above, however, were not limited to lesions in these specific areas.

*Majority of patients evaluated after 2 weeks' therapy. Data on file at Squibb Institute for Medical Research.

See next page for brief summary.

©1977 E.R. Squibb & Sons, Inc. 357-508

HALOG®

HALCINONIDE

SQUIBB®

HALOG® (Halcinonide)
Cream/Ointment/Solution
Halog Cream 0.025% (Halcinonide Cream 0.025%) and Halog Cream 0.1% (Halcinonide Cream 0.1%) contain 0.25 mg. and 1 mg. halcinonide per gram, respectively, in a specially formulated cream base. Halog Ointment (Halcinonide Ointment 0.1%) contains 1 mg. halcinonide (0.1%) per gram in Plastibase® (Plasticized Hydrocarbon Gel), a polyethylene and mineral oil gel base. Halog Solution (Halcinonide Solution 0.1%) contains 1 mg. halcinonide (0.1%) per ml.
CONTRAINDICATIONS: Topical steroids are contraindicated in vaccinia, varicella, and in those patients with a history of hypersensitivity to any of the components of the preparations. These preparations are not for ophthalmic use.
PRECAUTIONS: *General*—If local infection exists, suitable concomitant antimicrobial or antifungal therapy should be administered. If a favorable response does not occur promptly, application of the corticosteroid should be discontinued until the infection is adequately controlled. If extensive areas are treated or if the occlusive technique is used, the possibility exists of increased systemic absorption of the corticosteroid and suitable precautions should be taken. If irritation or sensitization develops, the preparation should be discontinued and appropriate therapy instituted. Although topical steroids have not been reported to have an adverse effect on pregnancy, the safety of their use during pregnancy has not been absolutely established; therefore, they should not be used extensively on pregnant patients, in large amounts, or for prolonged periods of time.
Occlusive Dressing Technique—The use of occlusive dressing increases the percutaneous absorption of corticosteroids; their extensive use increases the possibility of systemic effects. For patients with extensive lesions it may be preferable to use a sequential approach, occluding one portion of the body at a time. The patient should be kept under close observation if treated with the occlusive technique over large areas and over a considerable period of time. Occasionally, a patient who has been on prolonged therapy, especially occlusive therapy, may develop symptoms of steroid withdrawal when the medication is stopped. Thermal homeostasis may be impaired if large areas of the body are covered. Use of the occlusive dressing should be discontinued if elevation of the body temperature occurs. Occasionally, a patient may develop a sensitivity reaction to a particular occlusive dressing material or adhesive and a substitute material may be necessary. If infection develops, discontinue the use of the occlusive dressing and institute appropriate antimicrobial therapy.
ADVERSE REACTIONS: The following local adverse reactions have been reported with topical corticosteroids: burning, itching, irritation, striae, skin atrophy, secondary infection, dryness, folliculitis, hypertrichosis, acneform eruptions, and hypopigmentation. The following may occur more frequently with occlusive dressings: maceration of the skin, secondary infection, skin atrophy, striae, and miliaria. Contact sensitivity to a particular dressing material or adhesive may occur occasionally (see PRECAUTIONS).
For full prescribing information, consult package insert.
HOW SUPPLIED: The 0.025% and 0.1% Cream and the 0.1% Ointment are supplied in tubes of 15 g. and 60 g., and in jars of 240 g. (8 oz.). The 0.1% Solution is supplied in plastic squeeze bottles of 20 ml. and 60 ml.

SQUIBB®

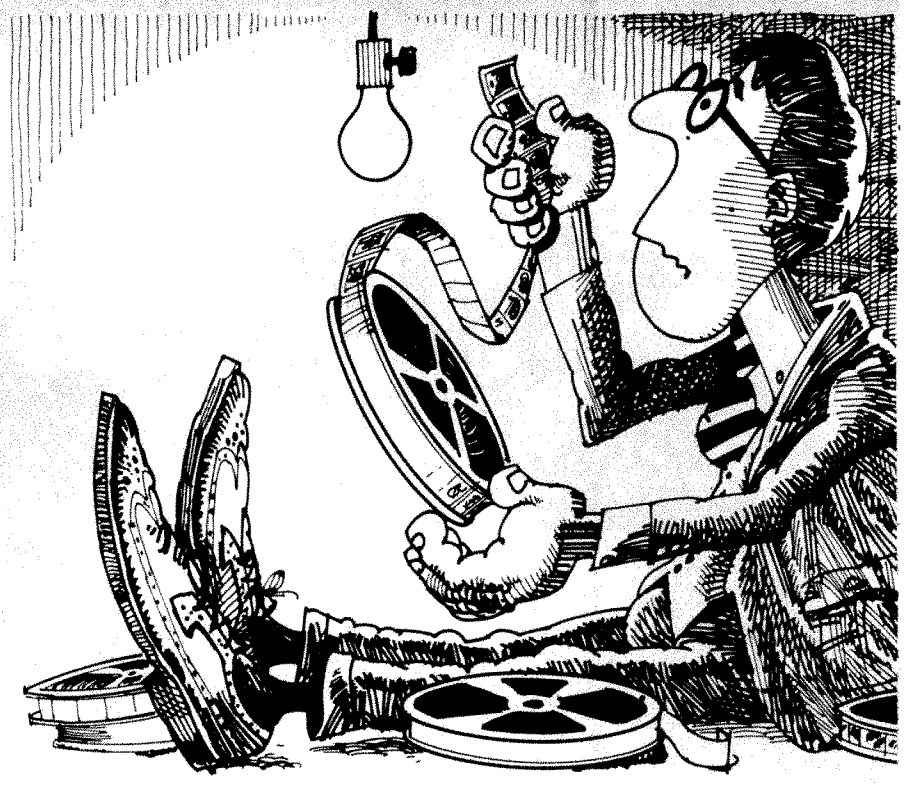

a quick reference to the AMA's large collection of medical films

and its yours free with the coupon below

You'll find nearly 100 pages of medical motion picture titles and descriptions in this new catalog—well over 300 titles and many of them brand new! All are available on loan basis for a slight service charge.



American Medical Association S/J
535 N. Dearborn St.
Chicago, Ill. 60610
ATTN: Dept. of Audio Visual
Self Learning Programs.

Please send me your catalog:
AMA Medical Health Film Library 1976

Name _____
Title _____
Organization _____
Address _____
City _____
State/Zip _____

When the fluorinated steroid is gone–

Problems such as striae, or dermal atrophy leading to telangiectasia and fragility, especially on the face, in the groin, anal or axillary areas may be the result.

Consider Starting with Hytone® 2.5% (hydrocortisone)

For rapid control of the majority of inflammatory dermatitides seen in office practice.

Followed by–Hytone® 1% or 0.5%

for maintenance therapy and ultimate control–especially on the face or in children.

Hytone®–the conservative but effective approach

HYTONE® CREAM (hydrocortisone)

DESCRIPTION: Hydrocortisone 2½%, 1% and ½% in a water-washable cream containing purified water, propylene glycol, isopropyl myristate, cholesterol and related sterols, cetyl alcohol, sorbic acid, glyceryl monostearate, polysorbate 60, sorbitan monostearate and polyoxyl 40 stearate. ACTIONS: Topical corticosteroids are effective primarily because of their anti-inflammatory, antipruritic, and vasoconstrictive actions. INDICATIONS: For relief of the inflammatory manifestations of corticosteroid-responsive dermatoses. CONTRAINDICATIONS: In viral diseases of the skin such as varicella and vaccinia and in patients with a history of hypersensitivity to any component. Not for ophthalmic use. Topical steroids should not be used when circulation is markedly impaired. WARNING: Should not be used extensively, in large amounts, or for prolonged periods in pregnancy. PRECAUTIONS: If irritation develops, the product should be discontinued and appropriate therapy instituted. In the presence of an infection, the use of appropriate antifungal or antibacterial agents should be instituted. If a favorable response does not occur promptly, the corticosteroid should be discontinued until the infection has been adequately controlled. If extensive areas are treated or if the occlusive technique is used, the possibility exists of increased systemic absorption of the corticosteroid and suitable precautions should be taken. ADVERSE REACTIONS: The following local adverse reactions have been reported with topical corticosteroids, either with or without occlusive dressings: burning sensations, itching, irritation, dryness, folliculitis, secondary infection, skin atrophy, striae, hypertrichosis, acneform eruption and hypopigmentation. DOSAGE AND ADMINISTRATION: Apply to affected areas 3 or 4 times daily. HOW SUPPLIED: Cream 2½%—Tubes ½ oz. and 1 oz. Cream 1% and ½%—Tube 1 oz. and Jar 4 oz. CAUTION: Federal law prohibits dispensing without prescription.

Dermik

Dermik Laboratories, Inc.
Fort Washington, Pa. 19034

You've made PreSun® (5% PABA) number one*

Now, a major clinical sunscreen study confirms PreSun's premier sunscreen position.

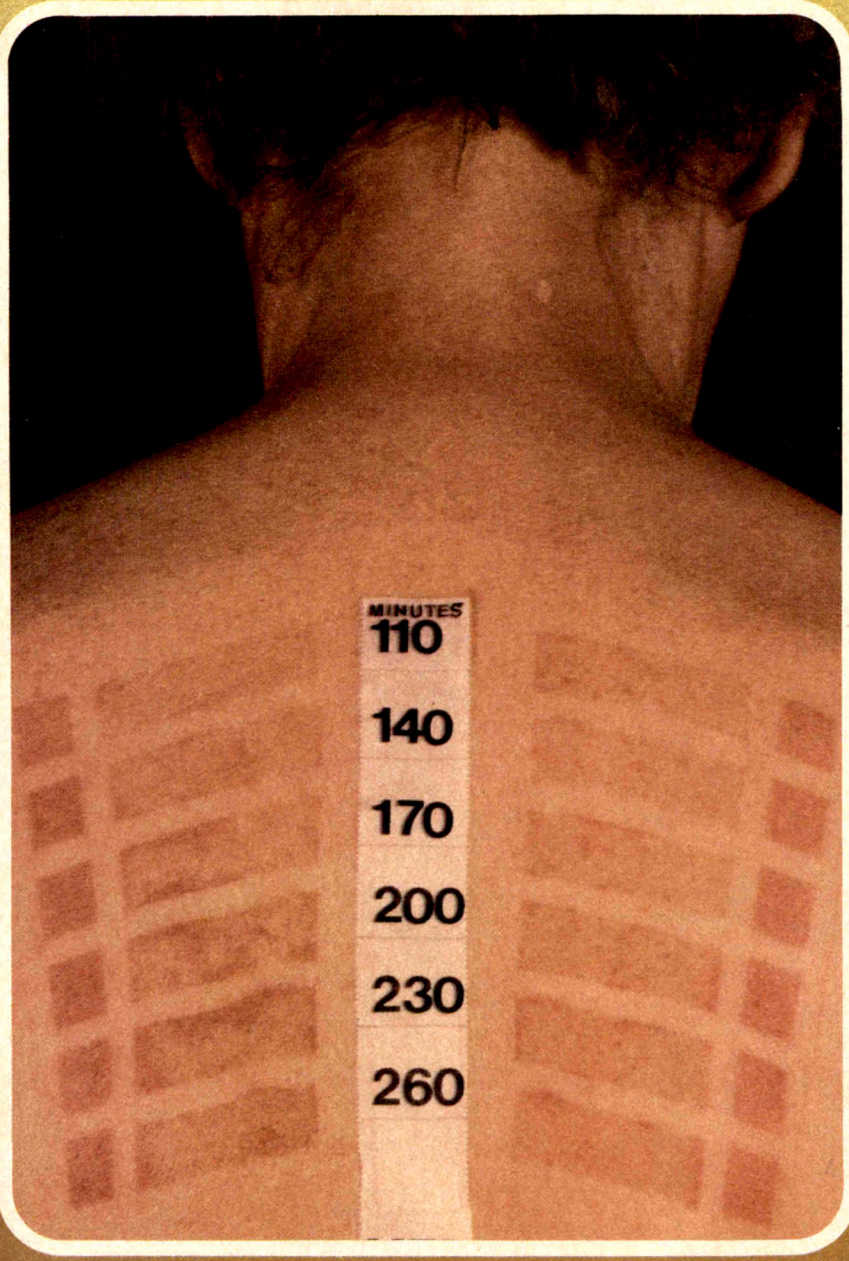

Unretouched photo of subject's back, PreSun® applied (right) and another sunscreen product (left).

Westwood designed its most rigidly controlled sunscreen study to date; 68 sun-sensitive volunteers were exposed to increasing amounts of southern California sunlight up to 4 hours. This complex investigation demonstrated important differences between the degree of protection that sunscreen products afford. PreSun® was shown to afford maximum sunscreen protection. On an average, PreSun allowed the sun-sensitive individual to withstand the sun *over eight times longer* before acquiring a slight, painless reddening, than he could unprotected.** PRESUN CONTINUES TO SET THE SUNSCREEN STANDARD. DON'T JEOPARDIZE THE SKIN OF YOUR SUN-SENSITIVE PATIENTS WITH JUST ANY FORMULA.

PreSun® may also help prevent premature aging and skin cancer caused by the sun.

*Based on retail sales of ethically promoted sunscreens.

**Information on file at Westwood Pharmaceuticals

WESTWOOD PHARMACEUTICALS INC.
Buffalo, New York 14213
In Canada, Belleville, Ontario K8N 5E

©1978, W.P. Inc.

Continuing Medical Education

Albatross or Challenge?

For many centuries physicians have been at the cutting edge of scientific curiosity and self-education, but only in recent years have we become subject to a massive proliferation of courses, symposia, workshops, and forums all ostensibly designed to make us "better" physicians. The American Academy of Dermatology (AAD) has been the undisputed world leader in education designed specifically for purveyors of the cutaneous healing arts. And, year after year, an astonishing 70% to 80% of those physicians whose practice or training is limited to skin disease flock to the annual fount of knowledge. And, as these professional consumers have become more sophisticated and the teachers more effective, there has been a dramatic rise in the number and excellence of learning experiences (in 1977 there were 15 courses, 26 symposia, 39 forums, and 71 seminars in depth; in 1967 there were eight courses, 21 symposia, no forums, and no seminars in depth). Since the founding of the AAD in 1938, dermatologists have come voluntarily to the annual meeting and have returned home secure in the knowledge that they would each be able to deliver better, more effective, and more efficient care to their patients.

MANDATORY ATTENDANCE

But, because of pressure from governmental as well as professional medical organizations, attendance at future medical meetings is no longer voluntary, but mandatory. Currently, 22 states require evidence of continuing medical education (CME) for relicensure and 17 for medical society membership; these figures are certain to increase even by the time this editorial is published. Professional organizations and the government have been the recipients of considerable pressure to develop CME requirements; this pressure has originated from several sources, including consumer movements for accountability; increasing malpractice litigation, an unparalleled rise in health care costs, and a heightened interest in peer review. The consequences of failure to meet the requirements of CME vary widely, but may be tied to continued membership in a professional society or even to state licensure to practice. The specifics of the requirements also vary widely between different specialties and different states, but the most common figure quoted is 50 hours per year of approved forms of learning experiences. With this figure has come a new term for a very old concept, "continuing medical education," known in all circles now as CME. And with the requirement and with the new term have come a proliferation of bureaucracy to design CME programs (professional medical societies, committees, and medical school assistant deans), groups to monitor compliance and issue awards (medical society executive personnel), complete with prepunched computer evaluation and attendance cards, an "Institute for Continuing Education," and a new publication that compiles all CME courses in the United States. The extent of administrative involvement boggles the mind.

WHAT 50 HOURS OF CME WILL MEAN

But how much thought has been given to what 50 hours of CME may mean to the practitioners and to the teachers?

Practitioner

Consider the practitioner first. No conscientious physician would ever disagree with the concept that, to deliver the best possible care to his patients, he must stay current with the latest of diagnostic and therapeutic knowledge. But will it help him either diagnose or treat atopic dermatitis to know that those patients have a defective monocyte chemotaxis or that a soluble fragment of C5 is a potent chemoattractant? Has the practitioner, ten years out of residency training in diagnosis and management of difficult problems, forgotten the clinical characteristics of erythropoietic protoporphyria? Should he know that liver disease that could be fatal may develop in these patients? Or should he know that porphyria cutanea tarda is due to an inherited enzyme defect and that family members should be examined? Should he even be concerned with these thoughts when his waiting room is chock-full of acne, wart, and eczema patients? One can say that the practitioner should have knowledge of uncommon diseases just for the intellectual satisfaction of knowledge for knowledge's sake and maybe some day it will help him treat the conditions of his patients. But knowledge for knowledge's sake is not what CME is all about; it is, to repeat, so we can "provide better and more efficient care for our patients."

No study nor omnipotent physician has established as fact that 50 hours are ideal or the minimum necessary to provide excellent care. Some physicians may provide that type of care with only five hours, while others may take several times 50. And, anyway, how do we define "better care"? The 50 hours, of course, can be divided into several categories to include home study as well as attendance at meetings. But what about the patient-care physician man-hours lost while the physician is getting his CME? Attendance is one aspect, travel time to and from local, regional, or national meetings is another. Does the total time invested to learn better patient care offset the time lost in patient care? Proponents of CME are committed to that assumption but others, including Laur et al (ARCHIVES 113:524, 1977), have doubts. For instance, the dermatologic physician man-hours not devoted to patient care at each annual AAD meeting approaches 150,000, which is about 600,000 patient visits for that week out of the office. There has also been no built-in mechanism to demonstrate that learning actually took place, although some groups, such as the AAD, have begun pretests and posttests, but the argument is offered that since the posttest is given immediately after the end of the course, it

does not measure retention back to the examining table at home. However, it must be remembered that these tests were not developed to be recriminatory but are to be used as a learning experience, ie, as reinforcement for specific important points. If a learner is unsure of an answer in the pretest, he is far more likely to listen to try to find that answer.

Teacher

Second, consider the teacher. Who is he, how experienced need he be, who determines what he will teach, and how shall he be compensated? These are not easy questions to answer but they must be considered.

Who is he? Traditionally, he is a member of a medical school faculty, on either a part-time or full-time basis and not the physician who is in total private practice. However, the AAD, as a result of a program developed more out of enthusiasm than by actual design, has, for many years, used the very real talents of many of our practitioners. Nevertheless, when regional program committees make speaker selections, academic persons will be seen on the guest faculty list far more often than practitioners. It is essential to note that the academician is not necessarily a better teacher simply by virtue of his being an academician—more experienced, yes; better, not necessarily. But how do these academic teachers who have become more and more burdened with increasing governmental legislation and medical school administrative problems react? Simple multiplication reveals that the total number of student hours per year for AAD-sponsored category-1 time must average 40,000 (10 hr/yr × 4,000 dermatologists) and that the total category-1 time required is 120,000 hr/yr. Can the academician shoulder all of that responsibility? He can, but there is no reason why he should.

How much time is actually required to prepare a 30-minute lecture? Obviously, this varies greatly from speaker to speaker; it may be a few minutes minimum to toss a few slides in a carousel to several hours for a new lecture requiring a literature review. And, because of new program design, that may be only a beginning. Now participants, particularly those paying for a course, demand handouts from all speakers. Preparing a good handout may be almost as time consuming as writing a full manuscript. And teachers are now asked to develop questions for pretests and posttests. It is not surprising that the Council on the National Annual Meeting (Program Committee) is receiving an increasing number of verbal and written complaints related to the time burden. It is true that many lectures have been used before and will be used again for different audiences. But, from my personal experience, initial preparation of a new 30-minute lecture with handout and questions requires 20 to 25 hours of my time, and four to five hours of secretarial time. If this is cost accounted and added to the cost of preparing 20 slides, the total is a minimum of $800.

CURRICULUM

Who determines what the teacher should teach? In the case of the AAD, course, symposium, forum, and workshop topics and directors are chosen by the Council on the National Annual Meeting. Each topic and director is evaluated by a number of mechanisms that determine whether either the topic or the director remain in that position for periods of tenure running from three to five years. Because of the sheer size of the AAD meeting, virtually every facet of dermatologic basic science, diagnosis, and care is covered each year. In the case of local and regional programs, one or more topics and speakers are chosen less for the need of the members to be brought up to date on an area of common weakness, but more for the professional reputation of the speaker. This leads to a hit-and-miss type of CME at a time when the CME hours per year required mean that a good proportion of these hours must be obtained somewhere in addition to the annual meeting of the AAD. What can be done? A great deal, I believe, can be accomplished by basing education on a core curriculum and delivering both what practitioners want to know and what they should know in easily digestible and practical fashion. With this conceptualization, Peyton Weary and I organized the Southeastern Consortium for Dermatologic CME and held the first meeting in September 1977 in Chapel Hill, NC. It is based on a core curriculum developed by an AAD Committee chaired by Richard Caplan. The meetings are to be usually eight hours in length and associated with one of the abundant clinical meetings held in the Southeastern United States. The long-range plan is to cover the core in five to six years and then recycle. By attending every meeting, a dermatologist should be exposed to all he needs to know to practice at a very high level of clinical competence. The faculty was chosen not only from academicians but also from full-time practitioners, and full-time practitioners were equally represented on the organizing committee. To save travel money, the faculty was drawn only from the represented states of Georgia, South Carolina, North Carolina, Virginia, Maryland, and the District of Columbia. Additionally, and this is the key element, a curriculum for each of two half days was chosen first, followed by specific topics within the broad curriculum and only then were faculty picked. Where there were topics for which the region had no recognized expert, a person known to be an effective teacher (whether academician or practitioner) was selected and asked to prepare a lecture on that topic. The attendance and enthusiasm far exceeded our expectations; thus, the next meeting is scheduled for the fall of 1978 in Atlanta and, after that, we hope to meet twice yearly.

DERMATOLOGIC UPDATE FOR GENERAL AND FAMILY PRACTITIONERS

But there is another group for whom dermatologic CME is also essential—the general practitioner and family practitioner whose practice may be 10% to 15% cutaneous problems. To whom should he turn for his dermatologic update? Should this become another burden on the already overtaxed time resources of the academician? To some extent it should, but not entirely. Many clinicians are very effective teachers, often more effective than they themselves believe, and they are often better and more credible than their academic counterparts. In North Carolina, we have initiated a series of "Practical Dermatology for the Non-Dermatologist" courses that are held at varying places in the state two to three times per year. And, at each place, we call on the expertise of dermatologists who are practicing in that region. The visceral reaction is that these courses might decrease patient flow to the dermatologist, but that concern has not been borne out in practice. The exposure increases the visibility of the dermatologist and he then receives increased referrals, which are often the more difficult clinical problems that he had been trained to manage. But the dermatologic practitioner should not wait for an invitation from his regional academic center to participate in a program. He can, and should, become part of the CME activities within his own medical community. And, pragmatically, he receives

CME credit hours for his teaching efforts.

BEST METHOD FOR DELIVERING CME

Another question that is only recently being approached is determination of the best method for delivering CME. From the teacher's standpoint, the larger the audience, the more efficient is the dissemination of knowledge. But how much knowledge is really disseminated and what is the half-life of its retention by the individual minds of the audience? The pretests and posttests that were administered at all courses, forums, and seminars at the AAD in 1977 begin to put a handle on the knowledge differential between the beginning and the end of the respective course. But how much is actually remembered two or six or 12 months later when that patient walks into the office? Is the quantity of retention from the learning experience of a small group, such as a seminar, greater than that from a full lecture hall? Many people believe so, but there is no supporting data. Certainly repetition is a key element of retention, thus emphasizing the continuing part of CME. Continuing medical education cannot be a once-a-year experience but must take place on a regular basis through journals, home study, and local meetings. The latter provides a particularly rich source, especially those meetings that are centered around patient presentation because of the probability of greater retention. However, in my experience, even many of these meetings could profit by innovative ideas for improvement.

EXPECTATIONS

How much learning should be expected of the consumers? Should the CME for someone 30 years out of residency be the same as for the physician who just completed his training? This question, although it has been asked previously, has not been considered when CME programs were designed. Certainly, if we are to teach immunodermatology to the recent residency graduate who learned basic immunology in medical school and was exposed to an immunology course during his training, he should be far ahead of the practitioner who graduated in the era when an enlarged thymus was only something to be irradiated.

COST

Who should pay for the CME? By any rational mind, the consumer must be willing to support the travel, expenses, and time of the speakers and also support the organizational time invested by salaried members of a dermatologic department via some form of compensation back to that department. Departmental expenses, like all others, are increasing yearly and government legislation is restricting many sources of former funds. Thus, the time of faculty members that was formerly spent in fund raising and is now being spent in CME activities must be appropriately compensated.

CONCLUSIONS

Thus, like it or not, required CME is upon us and is likely to remain for a long time. Its avowed aim is noble, but I doubt that even time will allow us to accurately assess whether dermatologic care delivered in 1980 is better than that in 1970 relative to knowledge available in those years. Although the practical and theoretical aspects of CME are complex and their consideration raises many unanswered questions, the challenge wins easily over the albatross. The challenge varies depending on ones' position: for the organizer, it is to develop an innovative and enlightened program; for the teacher, it is to reach the peak of his teaching potential; and for the consumer, it is to learn as much as he can in order to deliver the best possible care. Personally, I like to think that the intangible rewards resulting from intellectual curiosity will be stimulus enough so that each of us will attend CME sessions with enthusiasm to learn and a willingness to contribute our own time and talents to improve the quality of each learning experience. And, if you really want to learn a subject well, accept the challenge to prepare a lecture where you discuss that topic with clarity to an audience of your peers. This may require taking a risk, but the rewards of self-fulfillment can be profound.

W. Mitchell Sams, Jr, MD
Chapel Hill, NC

Reviewers for 1977

The editors of the Archives would like to take this opportunity to thank, on behalf of themselves and the readership, the large number of dedicated persons who have reviewed articles for the journal in 1977. As you may or may not know, every submitted paper is examined by at least two referees, as well as by the editors. Though this procedure may delay publication, it is essential for the maintenance of accuracy and quality of material published.

The following is a compilation of the names of these reviewers who have so generously given their time and expertise on behalf of the Archives. If any name is misspelled or not included, we apologize in advance. Please let us know and we will include the information as a correction in a future issue.

John H. Epstein, MD
Kimie Fukuyama, MD
Denny L. Tuffanelli, MD
San Francisco

Elizabeth A. Abel
Donald C. Abele
A. Bernard Ackerman
William A. Akers
Alfred M. Allen
Burton Allyn
Joseph C. Alper
Jules Altman
Raza Aly
Philip C. Anderson
Kenneth A. Arndt
Harry L. Arnold, Jr
Faye D. Arundell
Robert Auerbach
Samuel Ayres III
Daniel L. Azarnoff
Howard P. Baden
Rudolf L. Baer
Malcolm A. Bagshaw
William B. Baker
Robert R. Baumann
Samuel F. Bean
James H. Bennett
Wilma Fowler Bergfeld
Ernst H. Beutner
Irvin H. Blank
W. Kenneth Blaylock
Eric Bleumink

M. Scott Blois
Irwin M. Braverman
Algie Curry Brown
Martin H. Brownstein
Kenneth H. Burdick
Kelmar M. Burge
Carroll F. Burgoon, Jr
Thomas K. Burnham
Melodie M. Buxman
Vera S. Byers
Jean-Claude Bystryn
Philip Calanchini
Russell B. Caldwell
Richard M. Caplan
William A. Caro
Thomas E. Carson
D. Martin Carter
Fred F. Castrow II
Ronald R. Chappler
Herbert B. Christianson
Thomas M. Christie
William E. Clendenning
Marcus A. Conant
Victor S. Constantine
Alvin J. Cox, Jr
William R. Crain
David L. Cram
Peggy Crawford
Derek J. Cripps
Robert G. Crounse
Roger Crumley
Mark V. Dahl
Paul I. Dantzig
Steve A. Davis
P. Joseph Demis
Vincent J. Derbes
Charles H. Dicken
Richard L. Dobson
Hendrik M. G. Doeglas
Richard D. Doty
David J. Drutz
Howard V. Dubin
Edmund L. Dubois
André Dupre
Frank R. Dutra
William H. Eaglstein
Peter M. Elias
Edward A. Emmett
Marvin L. Engel
Ernst Epstein
Ervin H. Epstein
Ervin H. Epstein, Jr
Wallace V. Epstein
William L. Epstein
Nancy B. Esterly
Mark Allen Everett
Eugene M. Farber
Paul Fasal
Robert M. Fine
Alexander A. Fisher
David G. Fisher
Thomas B. Fitzpatrick
Raul Fleischmajer
P. Donald Forbes
Samuel B. Frank
Irwin M. Freedberg
Robert B. Freeman
David F. Fretzin
Phillip Frost
Nancy L. Furey
Gerald A. Gellin
William C. Gentry, Jr
Paul J. Gethner
Barbara A. Gilchrest
James N. Gilliam
Richard G. Glogau
Detlef K. Goette
Herbert Goldschmidt
Lowell Alan Goldsmith
Loren E. Golitz
Robert W. Goltz
Richard S. Goodman
Bernard I. Gordon
Robert Gorlin
Bernard Gottlieb
William M. Gould
Joseph H. Greenberg
John S. Greenspan
Kenneth E. Greer
David A. Grekin
Inta A. Grots
James R. Groundwater
Arnold W. Gurevitch
Adeline J. Hackett
Carlyn J. Halde
George W. Hambrick, Jr
Jon M. Hanifin
Leonard C. Harber
Kent M. Hardy
David R. Harris
Ken Hashimoto
John T. Headington
Elson B. Helwig
William J. Hennessy
Felix J. Hernandez
Layne Hersh
R. Jeffrey Herten
Paul Hirsch
Axel W. Hoke
H. Spencer Holmes
Richard T. Hoppe
Chung-Hong Hu
Funan Hu
Seiichi Izaki
James D. Jacobitz
Alvin H. Jacobs
Kent F. Jacobs
Paul H. Jacobs
G. Thomas Jansen
Michael T. Jarratt
R. Thomas Jessen
Waine C. Johnson
Henry W. Jolly, Jr
Frank J. Jonelis
Henry E. Jones
William P. Jordan, Jr
Robert E. Jordon
Dennis Juranek
Marvin A. Karasek
Stephen I. Katz
Donald M. Kay
Robert E. Kellum
John A. Kenney, Jr
Robert Kim
Samuel J. Kimura
Frederick A. J. Kingery
Sidney N. Klaus
Albert M. Kligman
John M. Knox
Dennis D. Knutson
Alfred W. Kopf
Lawrence S. Krain
Gerald G. Krueger
Edward A. Krull
Joseph W. Landau
Robert LaPerriere
Walter G. Larsen
Robert M. Lavker
Gerald S. Lazarus
Roy W. Leeper
Aaron B. Lerner
Walter F. Lever
S. William Levy
James J. Leyden
Walter C. Lobitz, Jr
Reed Lockwood
Albert E. Long
D. Anthony Lopez
Edmund D. Lowney
Lee R. Lumpkin
Marvin A. Lutzner
Peter J. Lynch
Chamel Macaron
Charles W. Mahart
Lisa Mahoney
Howard I. Maibach
John C. Maize
Frederick D. Malkinson
William Margaretten
Arthur W. Mayo
Amir H. Mehregan
Max G. Menefee
Herbert Mescon
Beno Michel
Ellis N. Mitchell
Eugene W. Monroe
Vera Morhenn
Samuel L. Moschella
Sigfrid A. Muller
Dowling D. Munro
Charles J. McDonald
James McGinley
John D. McGrae, Jr
Joseph S. McGuire
Lexie Nall
Douglas N. Naversen
Kenneth H. Neldner
Carl T. Nelson
Leslie Nicholas
Peter O'Brien
Richard B. Odom
Milton R. Okun
Sean O'Loughlin
Milton Orkin
Donald W. Owens
Frank Parker
Lawrence Charles Parish
John A. Parrish
David Paslin
Franklin Pass
Roger W. Pearson
Gary L. Peck
Magali Pena
Neal S. Penneys
Harold O. Perry
John R. Person
Lawrence D. Petz
Hermann Pinkus
Sheldon R. Pinnel
Gerd Plewig
Peter E. Pochi
Maureen B. Poh-Fitzpatrick
Vera H. Price
Thomas T. Provost
Stephen D. Prystowsky
Walter C. Quevedo
James E. Rasmussen
Thomas H. Rea
Rees B. Rees
John R. T. Reeves
Ron M. Reisner
Curt A. Ries
Edward J. Ringrose
John W. Rippon
Orlando G. Rodman
Gerald P. Rodnan
Henry H. Roenigk, Jr
Roy S. Rogers III
Robert W. Romero
Stanley A. Rosenthal
Jane M. Rosenzweig
Harry L. Roth
Andrew H. Rudolph
Arkadi M. Rywlin
Richard W. Sagebiel
W. Mitchell Sams, Jr
Willis C. Schaupp
Robert Scheuplin
Perry L. Scholnick
William F. Schorr
Donald S. Schuster
Jerral S. Seibert
Victor J. Selmanowitz
Alan R. Shalita
Howard Shapiro
Om P. Sharma
Gordon Sharp
Walter B. Shelley
Lawrence E. Shulman
Robert C. Siegel
Inga Silberberg-Sinakin
Stephen Z. Smith
Edward A. Smuckler
Arthur J. Sober
Lawrence M. Solomon
Nicholas A. Soter
William H. Spencer
Lynn E. Spitler
Willard D. Steck
Samuel J. Stegman
John D. Stobo
Bernard Stone
Stephen P. Stone
Frances J. Storrs
Richard B. Stoughton
John S. Strauss
Marion B. Sulzberger
Frederick J. Szymanski
Lewis Tanenbaum
David Taplin
William B. Taylor
E. George Thorne
Theodore A. Tromovitch
Hideo Uno
Frederick Urbach
Eugene J. Van Scott
Peter Viksnins
Ralph O. Wallerstein
George Waring
Raphael L. Warkel
William Watson
Peyton E. Weary
Gerald D. Weinstein
William L. Weston
Victor Wheatley
Clayton E. Wheeler, Jr
Laurens P. White
Mary L. Williams
Harvey E. Williams
Isaac Willis
Edward Wilson-Jones
Richard K. Winkelmann
Peter L. Winters
John E. Wolf, Jr
Kirk D. Wuepper
Herschel S. Zackheim
Nardo Zaias
Alvin S. Zelickson

Dermatologic Manifestations of the Hypereosinophilic Syndrome

John A. Kazmierowski, MD; Michael J. Chusid, MD; Joseph E. Parrillo, MD; Anthony S. Fauci, MD; Sheldon M. Wolff, MD

• We report the histopathologic and dermatologic manifestations of eight patients with hypereosinophilic syndrome (HES). Skin lesions occurred in eight patients (53%) in a group of 15 patients with HES, and were generally of two types: (1) erythematous pruritic papules and nodules, or (2) urticaria and angioedema. As HES was treated with appropriate therapy, the skin lesions improved. Skin eruption may be the only manifestation of disease in otherwise asymptomatic patients with HES.

(*Arch Dermatol* 114:531-535, 1978)

An increased number of peripheral blood eosinophils is often associated with a variety of disorders, including hypersensitivity,[1] drug reactions,[2] parasitic infestations,[3,4] malignant tumors,[5,6] and autoimmune[7,8] and infectious diseases.[9,10] Occasionally, however, no cause for the eosinophilia is found. Some patients with severe blood eosinophilia have a systemic disorder, characterized by diffuse infiltration of the organs with eosinophils, that is associated with hepatosplenomegaly, as well as cardiovascular, pulmonary, neurologic, and dermatologic abnormalities.[11,12] Hypereosinophilic syndrome (HES) appears to exist as a continuum of disease, with eosinophilic leukemia at one end, and asymptomatic patients with skin lesions and heart disease at the other.

Fifteen patients with HES have been evaluated at the National Institutes of Health (NIH) Clinical Center. Their cases have been reviewed previously.[1,2] Half of these patients were noted to have skin lesions. We report here the nature and pathology of these lesions, and emphasize their frequent occurrence in HES.

Accepted for publication June 20, 1977.

From the Laboratory of Clinical Investigation, the National Institute of Allergy and Infectious Diseases, National Institutes of Health, Bethesda, Md. Dr Kazmierowski is now with the Department of Dermatology, University of Oregon Health Sciences Center, Portland. Dr Chusid is now with the Department of Pediatrics, the Medical College of Wisconsin, Milwaukee.

Reprint requests to Laboratory of Clinical Investigation, National Institute of Allergy and Infectious Diseases, National Institutes of Health, Bethesda, MD 20014 (Dr Fauci).

SUBJECTS AND METHODS

Clinical Data

The eight patients with HES and skin lesions are listed in Table 1. These patients were part of an overall study group of 15 patients originally referred to the NIH Clinical Center for evaluation of eosinophilia. The male-to-female ratio of this subpopulation was 7:1, with a mean age of disease onset at 40.6 years (range, 5 to 66 years). The duration of the disease ranged from two to 23 years, and the patients had clinical manifestations covering the entire disease spectrum of HES. Two patients with eosinophilic leukemia, four patients with documented multiple organ involvement, and two patients with skin lesions and abnormal echocardiograms are included in the study.

Diagnostic Criteria and Evaluation

Patients in this report fulfilled the following criteria for the diagnosis of HES: (1) persistent eosinophilia of greater than 1,500 eosinophils per cubic millimeter for longer than six months, or death associated with the signs and symptoms of HES before six months; (2) a lack of evidence for parasitic, allergic, or other known causes of eosinophilia; and (3) presumptive signs and symptoms of parenchymal organ involvement.

The usual evaluation included the following: a complete history and physical examination, a chest x-ray film, complete blood cell and total eosinophil counts, a stool screen for ova and parasites, a bone marrow aspiration and biopsy, serum B_{12} and folate levels, leukocyte alkaline phosphatase level, chromosomal evaluation, quantitative immunoglobulin levels, serum IgE level, a urinalysis, an ECG, and an echocardiogram. Skin biopsies were performed on patients with cutaneous lesions. The biopsy material was stained with hematoxylin-eosin and evaluated by the

NIH pathology service. The activity of the disease determined whether patients were seen for inpatient follow-up evaluations at intervals of six and 12 months or followed as outpatients on a regular basis.

RESULTS

Descriptions of the cutaneous lesions and histopathologic findings in patients with HES are listed in Table 2. Both patients with eosinophilic leukemia (patients 1 and 2) had skin lesions that became manifest when their disease was in relapse. Shown in Fig 1 are the hyperpigmented, erythematous, maculopapular lesions on the hands and forearms of patient 1 when his eosinophilic leukemia was under poor control. The histologic features of one of these lesions is shown in Fig 2. The dermis contains an infiltrate of eosinophils, polymorphonuclear leukocytes, and mononuclear cells that surround and invade vessel walls. The intimal proliferation and vessel occlusion (Fig 2, right) are compatible with the diagnosis of vasculitis. Patient 2, who also had eosinophilic leukemia, had somewhat different skin lesions. Pruritic, erythematous, ulcerated nodules and vesicles were noted on the buttocks and lower extremities of this patient when his leukemia relapsed. The histopathologic features of an early lesion (Fig 3) shows generalized inflammatory cell infiltration of the connective tissue, necrosis, and a vesicle containing large numbers of eosinophils and proteinaceous material. A higher power view of the dermis (Fig 3, right) shows an infiltrate composed of eosinophils, lymphocytes, and histiocytes, as well as pronounced endothelial thickening of the small arteries.

Four patients (patients 3 through 6) had peripheral blood eosinophilia and skin lesions, and biopsy specimens gave evidence of multiple organ infiltration by eosinophils. Frequently, there were associated constitutional symptoms, including fatigue, weakness, and episodic fevers, but the relatively benign clinical course of these patients contrasted sharply with the rapidly progressive deterioration seen in the patients with eosinophilic leukemia. Skin lesions seen in this form of HES were either erythematous papular lesions, or angioedema and urticaria. The erythematous papules were usually found in a patchy distribution on the trunk and extremities. They often were pruritic, and were usually responsive to therapy. Figure 4 shows an example of the confluent erythematous papules seen in one patient with this form of the disease. Figure 5 shows the dermal perivascular infiltration, primarily of eosinophils, seen in these lesions. Episodes of urticaria and angioedema, primarily of the face and trunk, were seen in two patients (patients 4 and 5). These lesions appeared in an episodic manner, and were often associated with noticeable constitutional symptoms and fever. These two patients with angioedema had greatly increased IgE levels, but three other patients, who had HES with skin lesions other than angioedema, also had IgE levels in the same range. The histologic features of a typical urticarial lesion is shown in Fig 6. The dermis is somewhat edematous, and a dermal infiltrate, primarily of eosinophils, is notable.

Two patients in this study (patients 7 and 8) had only peripheral blood eosinophilia and skin lesions at the time of referral. Both of these patients had intermittently occurring erythematous papular skin lesions over the trunk and extremities that were similar in appearance and histologic features to those seen on patients 3, 4, and 6. Further evalua-

Table 1.—Patients With Hypereosinophilic Syndrome and Skin Lesions

Patient/Sex/ Age of Onset, yr	Highest Total Eosinophil Count/cu mm	Other Clinical Manifestations of HES
1/M/40	240,000	Eosinophilic leukemia; constitutional symptoms; diarrhea; cardiomegaly; abnormal echocardiogram
2/M/42	67,200	Eosinophilic leukemia; constitutional symptoms; endomyocardial fibrosis; pulmonary fibrosis; eosinophilic infiltration of liver and lymph nodes
3/M/35	29,400	Constitutional symptoms; cardiomegaly; mitral insufficiency; abnormal echocardiogram
4/M/66	17,350	Constitutional symptoms; mitral insufficiency; abnormal echocardiogram; interstitial pulmonary infiltrates; diarrhea
5/M/7	44,650	Episodic fever and diarrhea; interstitial pulmonary infiltrates; eosinophilic infiltration of liver, lymph nodes, and muscle
6/F/34	13,400	Constitutional symptoms; eosinophilic infiltration of muscle
7/M/57	18,750	Abnormal echocardiogram
8/M/44	6,100	Abnormal echocardiogram

Table 2.—Histopathology of Skin Lesions in HES

Patient	Skin Lesion	Histopathology
1	Pruritic, hyperpigmented erythematous macules and papules on hands and forearms	Dense focal and perivascular infiltrate of eosinophils, PMNs,* and monocytes in dermis
2	Pruritic, erythematous, ulcerated nodules and vesicles on buttocks and lower extremities	Dense infiltration around dermal arteries and veins with eosinophils, histiocytes, and lymphocytes; epidermal vesicle formation
3	Erythematous papules on lower extremities	Infiltrate of eosinophils, lymphocytes and plasma cells around and within dermal vessel walls
4	Angioedema of face and neck, erythematous, pruritic papules on neck and back	Eosinophilic and PMN infiltrate in edematous dermis; perivascular eosinophilic dermal infiltrate
5	Angioedema of face and extremities	Perivascular eosinophilic infiltrate in edematous dermis
6	Pruritic, perifollicular erythematous papules and moderate hyperkeratosis of trunk, neck, and extremities	Dermal perivascular infiltrate of eosinophils, mononuclear cells and PMNs
7	Pruritic erythematous papules on trunk and extremities	Dermal perivascular infiltrate of eosinophils and mononuclear cells
8	Erythematous papules on trunk and extremities	Dermal perivascular infiltrate of eosinophils and mononuclear cells

*Polymorphonuclear leukocytes.

Table 3.—Response of HES Skin Lesions to Therapy

Patient	Drugs	Clinical Response and Follow-up Observations
1	Alternate-day prednisone; vincristine sulfate; methotrexate sodium; hydroxyurea	Complete remission of leukemia; skin lesions healed with hyperpigmentation and scarring; continues on hydroxyurea alone
2	Daily prednisone; azathioprine; busulfan	No response; skin lesions persisted; died with marrow aplasia
3	Cyclophosphamide; alternate-day prednisone	No response; skin lesions persisted; died
4	Alternate-day prednisone	Complete remission; skin lesions healed; continues on treatment
5	Alternate-day prednisone; intermittent daily prednisone	Decreased number of attacks; less angioedema and fever with attack
6	Alternate-day prednisone	Skin lesions resolve while on steroids, but recur when treatment stopped
7	Topical triamcinolone acetonide	Skin lesions moderately improved, decreased pruritis
8	None	Skin lesions occur intermittently

tion of these patients revealed abnormal echocardiographic examinations, identical to those seen in patients with more pronounced symptoms. The abnormalities included an increase in mass of the left ventricular muscle, which is associated with left ventricular free-wall and intraventricular septal thickening.[13] The echocardiographic findings were similar in both patients with HES without evidence of cardiac dysfunction and those with obvious symptomatic heart disease.

The clinical response of the eight patients with HES and dermatologic lesions to various treatment modalities is shown in Table 3. The patients with eosinophilic leukemia (patients 1 and 2) received several chemotherapeutic agents. The most effective therapy for patient 1 was a combination of vincristine sulfate and hydroxyurea. His skin lesions had healed with hyperpigmentation and scarring, and no new lesions recurred while he was receiving hydroxyurea therapy.[14] Patient 2 was seen in an advanced stage of his disease and died despite aggressive therapy with prednisone, azathioprine, and busulfan. Chemotherapy had little effect on his skin lesions. The four patients with urticarial or erythematous papular skin lesions (patients 3 through 6) were treated with alternate-day prednisone, and in most cases a resolution of both types of lesions was seen. Patient 3 was treated with cyclophosphamide, in addition to prednisone, and showed no improvement. Patient 4 had a complete resolution of his angioedema while he was receiving alternate-day prednisone, whereas patient 5 required daily prednisone therapy intermittently for his occasional attacks of angioedema. The skin lesions of patient 6 resolved, and his constitutional symptoms disappeared while he was receiving alternate-day prednisone. The skin lesions of patient 7, who had eosinophilia with episodic skin eruptions as the only manifestations of his disease, were treated with topical triamcinolone acetonide; moderate improvement occurred. One patient was symptom free and required no therapy of his skin lesions.

COMMENT

This report is the first detailed study of the histopathologic features and the clinical course of skin lesions in a group of patients with HES. Dermatologic abnormalities were often seen in association with the HES, occurring in 53% of our patient population. The skin lesions, which are not pathognomonic of HES, are generally of one or two varieties: erythematous, pruritic patches of maculopapules distributed over the trunk and extremities, or urticaria and angioedema of the face and extremities. Skin lesions occur across the entire spectrum of disease in HES, and may be the only clinical evidence of disease in an otherwise asymptomatic patient. Although the therapy for HES differs depending on the extent of disease (Table 3), the response of the skin lesions usually parallels the rest of the disease.

It should be emphasized that HES is composed of several closely related disease entities. The syndrome is characterized by persistent and prolonged eosinophilia, with primarily hematologic, cardiac, neurologic, and dermatologic abnormalities. The etiology of HES is unknown, but the majority of patients appear to have a hypersensitivity reaction of some type. Some patients are likely to b suffering from a form of leukemi with a rapidly fatal course, which i characterized by extensive tissue in filtration, as evidenced by one of ou patients who died. However, the diag nosis of HES is often compatible wit long survival; several of our patient have been followed up for many year without deterioration in their condi tions.

A recent review[12] noted that skin lesions were described in 27% o previously reported patients with th HES, as compared with 53% of th patients in our group. The high inci dence of skin lesions in our series o patients with HES may reflect th inclusion of patients with minima symptoms who would not be include in earlier studies. Skin lesions have been described in several case reports of HES or eosinophilic leukemia. Evans and Nesbit[15] described a 53-year-old woman with eosinophilic leukemia and pruritic erythematous nodules in a generalized distribution. A biopsy specimen of the lesions showed a perivascular dermal infiltration with eosinophils. Engfeldt and Zetterstrom[16] reported a 10-year-old boy with HES and skin manifestations of two types: an erythematous, hyperkeratotic, scaling eruption and episodic angioedema. Both types of lesions were distributed over the face, arms, and legs and histologic examination disclosed eosinophilic infiltration of the dermis, which is often localized around hair follicles and vessels. The patient's skin lesions and eosinophilia improved for a time with regular long-acting corticotropin injections. Bentley et al[17] described an erythematous, serpiginous eruption on the chest and extremities, in addition to subcutaneous nodules on the scalp of a 5-year-old boy with eosinophilic leukemia. Both types of lesions persisted despite prednisone, busulfan, and mercaptopurine therapy. Histologic features of the nodular lesion showed an extensive infiltration of the dermis and subcutaneous tissue with lymphocytes and eosinophils. Pierce et al[18] described an edematous, erythematous, scaly, pruritic eruption in a 58-year-old man with HES. A skin biopsy specimen showed a dermal infiltrate of polymorphonuclear leukocytes, lymphocytes, and plasma cells, which was accompanied by areas of vasculitis. Initial treatment with oral prednisone and corticotropin injections induced a remission of the disease and clearing of the skin lesions, but a relapse occured within five months. Yam et

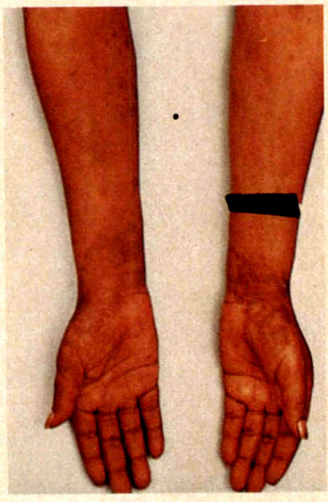

Fig 1.—Patient 1. Skin lesions on hands and forearms before treatment, showing hyperpigmented, erythematous maculopapules.

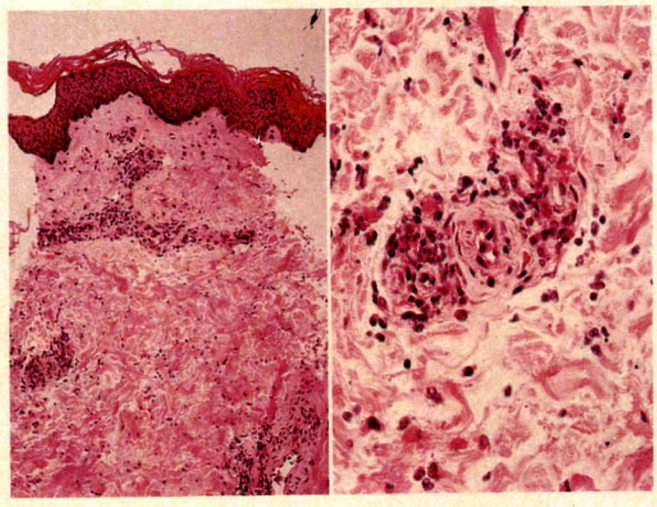

Fig 2.—Patient 1. Left, Punch biopsy specimen showing infiltrate of eosinophils, polymorphonuclear leukocytes, and mononuclear cells surrounding and involving vessel walls (hematoxylin-eosin, original magnification ×140. Right, Higher power view showing intimal proliferation and vascular occlusion (hematoxylin-eosin, original magnification ×475).

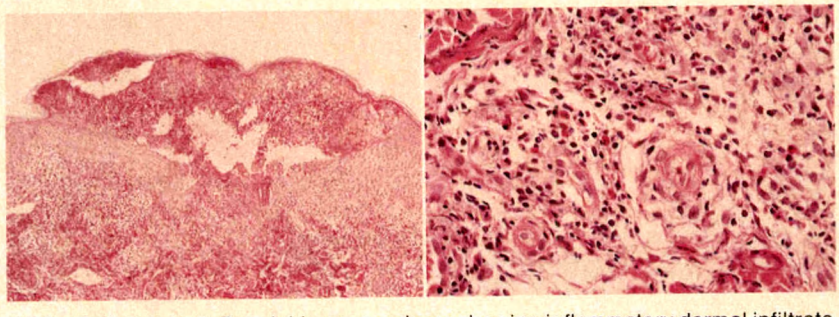

Fig 3.—Patient 2. Left, Punch biopsy specimen showing inflammatory dermal infiltrate and vesicle formation (hematoxylin-eosin, original magnification ×160). Right, Higher power view showing endothelial thickening and infiltrate of eosinophils, lymphocytes, and histiocytes (hematoxylin-eosin, original magnification ×350).

Fig 4.—Patient 6. Skin lesions on chest and extremities showing perifollicular distribution of erythematous papules.

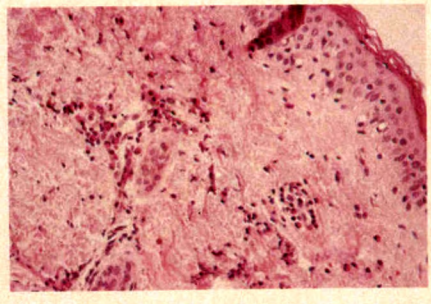

Fig 5.—Patient 6. Punch biopsy specimen of skin lesion demonstrating perivascular infiltrate of eosinophils (hematoxylin-eosin, original magnification ×160).

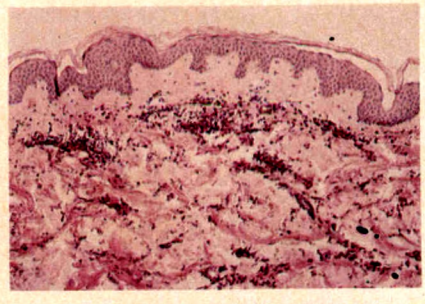

Fig 6.—Patient 4. Punch biopsy specimen of urticarial skin lesion showing edematous dermis and dermal infiltrate primarily of eosinophils (hematoxylin-eosin, original magnification ×90).

al[19] reported a petechial eruption in a 12-year-old boy with eosinophilic leukemia. A biopsy specimen of the lesion showed perivascular cuffing by mononuclear cells and eosinophils in the dermis. The patient's disease did not respond to prednisone and busulfan therapy.

Other skin disorders associated with peripheral blood eosinophilia have been described. Eosinophilic lymphfolliculosis of the skin (Kimura's disease), another condition which chiefly affects male subjects, as does HES, has eosinophilic furunculosis associated with granulomatous and hyperplastic changes in adjacent lymphatic tissue.[20,21] The lesions usually are located on the face or the axillary and inguinal regions. The disease has been treated with local irradiation and systemic corticosteroids, and usually runs a chronic, benign course. A related condition has been referred to as subcutaneous angiolymphoid hyperplasia with eosinophilia.[22] This disease is characterized by persistent subcutaneous nodules on the head and neck with distinctive histologic features of dermal infiltration with eosinophils and lymphoid cells, and the proliferation of capillary vessels. Modest blood eosinophilia is a frequent accompaniment and there are no systemic manifestations. The lesions respond to irradiation therapy. Hypereosinophilic syndrome differs from both of these disorders in histologic features and in clinical presentation, and likely has no relationship to them.

The finding of several patients with skin lesions and normal cardiac examinations, but abnormal echocardiograms, was of interest. The heart appears to be a major target organ in HES, and the clinical manifestations can vary somewhat, and may include signs of congestive failure, murmurs of mitral or aortic insufficiency, and conduction defects.[13] Autopsy data have shown that a thickened endocardium with mural thrombi and biventricular hypertrophy are common postmortem findings in HES, and can account for the progressive, restrictive cardiac disease seen terminally.[23] The long-term follow-up of patients with HES[23] has demonstrated that eosinophilia can persist for many years before cardiac symptoms appear, and that heart disease is a major cause of debility and death. The echocardiogram provides an important means for following patients with the endomyocardiopathy associated with HES, and may identify pathologic features in patients in whom there is no suggestion of or evidence for cardiac disease prior to study. All patients in whom the diagnosis of HES is suggested should be evaluated with this test.

Although the etiology of HES is unknown, recent experimental studies have provided some information that may partially explain the migration and infiltration of eosinophils into various tissue sites in this disease. Products of complement activation (C3a and C5a) appear to attract eosinophils and polymorphonuclear leukocytes,[24,25] and thus may account for the mixed cell populations seen on biopsy specimens. An eosinophilic chemotactic precursor substance that is elaborated by antigen-stimulated lymphocytes may stimulate the migration of eosinophils to areas of injury mediated by cellular immune processes. Marked eosinophilia results from the reaction of the antigen and antibody fixed to the surface of mast cells or basophils; moreover, chemical mediators released from these cells are chemotactic for eosinophils, ie, eosinophil chemotactic factor of anaphylaxis[26] and histamine.[27] Recent preliminary studies have suggested that eosinophils may be involved in the modulation of histamine release[28] or in reparative processes within damaged connective tissue.[29]

Nonproprietary Names and Trademarks of Drugs

Azathioprine—*Imuran.*
Corticotropin—*Acthar, Cortrophin.*
Hydroxyurea—*Hydrea.*
Vincristine sulfate—*Oncovin.*

References

1. Chafee PH, Ross JR, Gunn HG: Eosinophilia in fatal asthma: Studies of bone marrow and myocardium. *Ann Intern Med* 17:45-59, 1942.
2. Jacob HS, Sidd JJ, Greenberg BH, et al: Extreme eosinophilia with iodide hypersensitivity. *N Engl J Med* 271:1138-40, 1964.
3. Beaver PC, Snyder CH, Carrera GM, et al: Chronic eosinophilia due to visceral larva migrans. *Pediatrics* 9:7-19, 1952.
4. Della Vida BL, Dyhe SC: The blood picture in trichinosis. *Lancet* 2:69-71, 1941.
5. Viola MV, Chung EM, Mukhopadhyay MG: Eosinophilia and metastatic carcinoma. *Med Ann DC* 41:1-3, 1972.
6. Liao KT, Rosai J, Dameshek R: Malignant histiocytosis with cutaneous involvement and eosinophilia. *Am J Clin Pathol* 57:438-448, 1972.
7. Blackburn CR: Periarteritis nodosa simulating eosinophilic leukemia. *Am J Med Sci* 220:313-315, 1950.
8. Panush RS, Franco AE, Schur PH: Rheumatoid arthritis associated with eosinophilia. *Ann Intern Med* 75:199-205, 1971.
9. Elson KA, Ingelfinger FJ: Eosinophilia and pneumonitis in chronic brucellosis. *Ann Intern Med* 16:995-1002, 1942.
10. Friedman S: Eosinophilia in scarlet fever. *Am J Dis Child* 49:933-938, 1935.
11. Hardy WR, Anderson RE: The hypereosinophilic syndromes. *Ann Intern Med* 68:1220-1228, 1968.
12. Chusid MJ, Dale DC, West BC, et al: The hypereosinophilic syndrome: Analysis of fourteen cases with review of the literature. *Medicine* 54:1-27, 1975.
13. Borer J, Henry W, Dale D, et al: Eosinophilia and the heart. Abstract #19. Presented at the 55th Annual Session of American College of Physicians, New York, April 1974.
14. Chusid MJ, Dale DC: Eosinophilic leukemia: Remission with vincristine and hydroxyurea. *Am J Med* 59:297-300, 1975.
15. Evans TS, Nesbit RR: Eosinophilic leukemia. *Blood* 4:603-613, 1949.
16. Engfeldt B, Zetterstrom R: Disseminated eosinophilic "collagen disease." *Acta Med Scand* 153:337-353, 1956.
17. Bentley HP, Reardon AE, Knoedler JP, et al: Eosinophilic leukemia. *Am J Med* 30:310-322, 1961.
18. Pierce L, Hossenian AH, Constantine AB: Disseminated eosinophilic collagen disease. *Blood* 29:540-549, 1967.
19. Yam LT, Li CY, Necheles TF, et al: Pseudoesoinophilia, eosinophilic endocarditis, and eosinophilic leukemia. *Am J Med* 53:193-202, 1972.
20. Kimura T, Yoshimura S, Ishikawa E: Unusual granulation combined with hyperplastic changes of lymphatic tissue. *Trans Soc Pathol Jpn* 37:179-184, 1948.
21. Kawada AK, Takahoshi H, Auzai T: Eosinophilic folliculosis of the skin (Kimura's disease). *Jpn J Dermatol* 73:61-72, 1966.
22. Wells GC, Whimster IW: Subcutaneous angiolymphoid hyperplasia with eosinophilia. *Br J Dermatol* 81:1-15, 1969.
23. Solley GD, Maldonado JE, Gleich GJ, et al: Endomyocardiopathy with eosinophilia. *Mayo Clin Proc* 51:697-707, 1976.
24. Kay AB: Studies on eosinophil leukocyte migration: II. Factors specifically chemotactic for eosinophils and neutrophils generated from guinea-pig serum by antigen-antibody complexes. *Clin Exp Immunol* 7:732-737, 1970.
25. Ward PA: Chemotaxis of human eosinophils. *Am J Pathol* 54:121-128, 1969.
26. Kay AB, Stechshulte DJ, Austen KF: An eosinophil leukocyte chemotactic factor of anaphylaxis. *J Exp Med* 133:602-619, 1971.
27. Clark RA, Gallin JI, Kaplan AP: The selective eosinophil chemotactic activity of histamine. *J Exp Med* 142:1462-1476, 1975.
28. Hubscher T, Eisen AH: An eosinophil derived inhibitor (EDI) of histamine release. *J Allergy Clin Immunol* 51:83-84, 1973.
29. Samter M: Intolerance to asprin. *Hosp Pract* 8:85-90, 1973.

Epidermal Nucleolar IgG Deposition in Clinically Normal Skin

Clinical and Serologic Features of Eight Patients

Stephen D. Prystowsky, MD; James N. Gilliam, MD; Denny L. Tuffanelli, MD

• Epidermal nucleolar IgG deposition in clinically normal skin reflects high serum concentrations of antibody to nucleolar antigen. This immunopathologic finding occurred in six patients with scleroderma and in two patients with a scleroderma-systemic lupus erythematosus overlap syndrome.

(*Arch Dermatol* 114:536-538, 1978)

Direct immunofluorescence on biopsy specimens of normal skin is a useful test for the evaluation of patients with systemic lupus erythematosus (SLE).[1-4] Epidermal nuclear IgG deposition in a speckled (particulate) pattern on clinically normal skin appears to correlate with high titer serum antibody to extractable nuclear antigen (ENA).[5-8] One of us (J.N.G.) recently reported on two patients with scleroderma who demonstrated nucleolar staining in epidermal nuclei.[6] During the past five years, we have examined 3,453 skin biopsy specimens by a standard direct fluorescent antibody technique described elsewhere.[3,9] The purpose of this report is to describe the eight patients (0.2%) that had epidermal nuclear IgG deposition in a nucleolar staining pattern. This finding usually reflects high serum concentrations of antibody to nucleolar antigen and is most commonly seen in patients with scleroderma or a rheumatic disease with scleroderma-like features.

Accepted for publication Sept 9, 1977.

From the Department of Dermatology, University of California Medical School, San Francisco (Drs Prystowsky and Tuffanelli); and the Department of Internal Medicine, University of Texas Southwestern Medical School, Dallas (Dr Gilliam).

Reprint requests to Department of Dermatology, University of California, San Francisco, CA 94143 (Dr Prystowsky).

REPORT OF CASES

CASE 1.—A 27-year-old woman had periorbital edema, evanescent polyarthritis, and Raynaud's phenomenon. Physical examination showed diffuse hyperpigmentation of the hands with depigmentation over the knuckles and periungual telangiectasia. There was no cutaneous sclerosis or sclerodactyly.

The antinuclear antibody (ANA) test was positive at 1:2,560 with a nucleolar pattern. Antibodies to DNA and ENA were negative. Direct immunofluorescence of normal skin from the medial aspect of the volar forearm showed nucleolar staining of epidermal cells (Fig 1). There was no immunoglobulin deposited along the dermal-epidermal junction.

Two years later, the patient developed cutaneous sclerosis extending above the elbows and involving the face and upper part of the chest. The skin was shiny and tight over the hands and distal area of the upper extremities. There was accentuation of the depigmented areas over the knuckles, elbows, and periungual region. Telangiectatic mats were present on the hands. Abnormal laboratory findings at that time were a strongly positive ANA at a serum dilution of 1:81,920 with a nucleolar staining pattern; crythrocyte sedimentation rate (ESR), 28 mm/hr; hypergammaglobulinemia, 2.49 gm/100 ml; and a defect in carbon monoxide pulmonary gas diffusion (DLCO) of 43% predicted. The following laboratory studies were normal or negative: rheumatoid factor, LE preparation, cryoglobulin, total hemolytic complement (CH_{50}), antibodies to native DNA (anti-nDNA), anti-ENA, complete blood cell count, and serum creatinine. During the next few months, the disease rapidly progressed until she was unable to work. High titer ANAs (from 1:5,120 to 1:81,920) in a nucleolar staining pattern have persisted. A second immunofluorescence skin biopsy specimen again showed nucleolar epidermal and dermal nuclear staining. This patient's clinical and laboratory findings are typical of progressive systemic sclerosis.

CASE 2.—A 48-year-old woman had a nine-year history of Raynaud's phenomenon. Other pertinent positive clinical features included mild sclerodactyly with swollen fingers, periungual telangiectasia, telangiectatic mats of the face and tongue, diffuse nonscarring alopecia, hypopigmentation, and hyperpigmentation. She has no signs or symptoms of arthritis or arthralgia, myositis, adenopathy, serositis, keratoconjunctivitis, sicca syndrome, vascular headaches, CNS disease, or renal disease.

Immunofluorescence of normal, exposed skin disclosed nucleolar epidermal nuclear IgG deposition. There were no subepidermal immunoglobulin deposits. The ANA test was positive in low titer with a nucleolar staining pattern. The ESR was 32 mm/hr. The following tests were normal or negative: antibodies ENA (anti-ENA), rheumatoid factor (RF), LE preparation, CH_{50}, cryoglobulins, VDRL, hemoglobin, WBC, chest roentgenogram, BUN, and serum creatinine. The clinical impression was mild scleroderma.

CASE 3.—A 24-year-old woman had an eight-month history of widespread progressive cutaneous sclerosis. Additional clinical features included scarring alopecia, hyperpigmentation, hypopigmentation, sclerodactyly, periungual telangiectasia, atrophic papules over the knuckles (Gottron's papules), arthralgia, Raynaud's phenomenon, thrombophlebitis, and dysphagia. There were no signs or symptoms of myositis, adenopathy, serositis, vascular headaches, CNS disease, renal disease, or keratoconjunctivitis sicca.

Direct immunofluorescence of normal, exposed, and unexposed skin revealed nucleolar epidermal nuclear IgG deposition (Fig 2). The lupus band test (immunoglobulin at the dermal-epidermal junction) of normal exposed and unexposed skin was negative. The serum ANA was positive in high titer with a nucleolar pattern. The ESR was 50 mm/hr. The following tests were normal or negative: anti-ENA, anti-nDNA, CH_{50}, LE preparation, RF, VDRL, hemoglobin and WBC count.

These clinical and laboratory features are typical of scleroderma.

CASE 4.—A 62-year-old woman had a three-year history of cutaneous sclerosis of the face and hands. Additional positive findings included telangiectatic mats on the hands and gangrene of the fingers thought to be secondary to severe athero-

sclerotic peripheral vascular disease. She had a history of myocardial infarction and a cerebrovascular accident. Carotid arteriograms showed atheromatous plaques in both carotid arteries. There were no signs or symptoms of Raynaud's phenomenon, arthritis or arthralgia, myositis, serositis, adenopathy, vascular headaches, renal disease, CNS disease, keratoconjunctivitis sicca syndrome, or dysphagia.

Direct immunofluorescent staining of a biopsy specimen from normal sun-exposed skin disclosed nucleolar epidermal nuclear IgG deposition. The lupus band test was negative. The light microscopic findings were compatible with scleroderma. Barium examination showed esophageal dysmotility. Wide-neck pseudosacculations on the gastrointestinal series were additional roentgenographic findings compatible with scleroderma. The ANA was positive in low titer with a homogeneous pattern. Values for the following were normal or negative: anti-ENA, serum protein electrophoresis, immunoelectrophoresis, ESR, LE preparation, CH_{50}, anti-nDNA, VDRL, cryoglobulins, hemoglobin, WBC count, chest roentgenogram, and serum cholesterol.

The above clinical and laboratory findings are compatible with mild derma.

Case 5.—A 49-year-old woman ha mentation of the knuckles and up of the chest and back and edem periorbital region. A few months developed Raynaud's phenomenon dactyly, dysphagia, weight loss, a imal muscle weakness.

Abnormal laboratory test res cluded the following: hemoglobin, 100 ml; creatine phosphokinase (C IU; hypergammaglobulinemia, 2.5 ml; a restrictive defect on pulmona tion studies; and esophageal dysm

Direct immunofluorescence of skin from the volar forearm epidermal nuclear IgG depositi nucleolar pattern. There was no dermal immunoglobulin. The seru test was positive at 1:40,000 nucleolar staining pattern.

Values for the following were n negative: serum creatinine, ESR, sis, blood gases, electromyogra ENA, and anti-nDNA.

These clinical and laboratory are compatible with the diagnosis roderma with mild myositis.

Case 6.—A 24-year-old woman h neous sclerosis (confirmed by biop Raynaud's phenomenon. Addition neous findings included depigment the knuckles, hyperpigmentation dactyly, periungual telangiectas telangiectatic mats of the lip and

Direct immunofluorescence of normal skin from the volar forearm epidermal nuclear IgG staining of In addition, IgM was present dermal-epidermal junction. Seru was positive at a dilution of 1:5,12 nucleolar pattern. The anti-nDN was mildly elevated. She had pe hypocomplementemia and a pul

Fig 1.—Epidermal nucleolar IgG deposition (case 1).

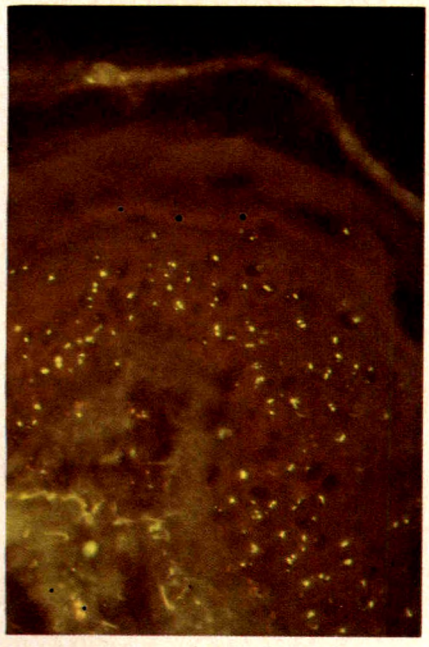

Fig 2.—Epidermal nucleolar IgG deposition (case 3).

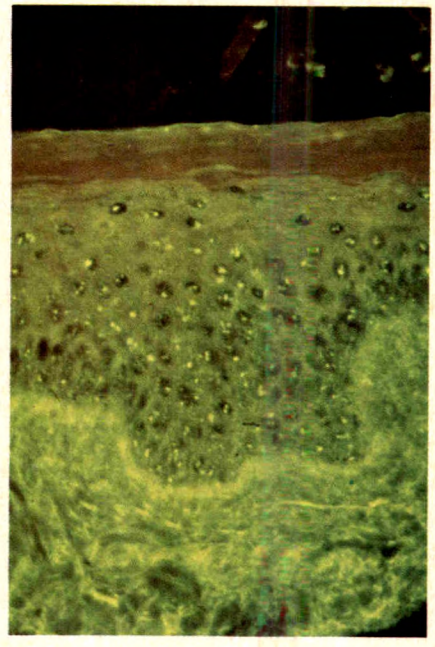

Clinical and Serologic Features of Eight Patients With Epidermal Nucleolar IgG Deposition*

Case No.	Clinical Features	ANA	anti-nDNA	anti-ENA	CH_{50}
1	Cutaneous sclerosis; Raynaud's phenomenon; arthritis; dyspigmentation; & pulmonary diffusion defect	Nucleolar 1:81,920	—	—	—
2	Sclerodactyly; Raynaud's phenomenon; alopecia; & dyspigmentation	Nucleolar 2+	ND	—	—
3	Cutaneous sclerosis; Raynaud's phenomenon; alopecia; arthralgia; dysphagia; & dyspigmentation	Nucleolar 4+	—	—	—
4	Cutaneous sclerosis & esophageal dysmotility	Homogeneous 1+	—	—	—
5	Sclerodactyly; Raynaud's phenomenon; myositis; dysphagia; restrictive pulmonary defect; & dyspigmentation	Nucleolar 1:40,000	—	—	—
6	Cutaneous sclerosis; Raynaud's phenomenon; dyspigmentation; pericarditis; & pulmonary diffusion defect	Nucleolar 1:5,120 Particulate 1:5,120	+	+ ("Sm" specificity)	+
7	Sclerodactyly; myositis; Raynaud's phenomenon; alopecia; & dyspigmentation	Nucleolar 1:5,120	—	—	ND
8	Sclerodactyly; Raynaud's phenomenon; chronic cutaneous LE; diffuse telangiectasia; splenomegaly; arthritis; & mucosal ulcers	Nucleolar 1:2,560	+	—	—

*Normal or negative indicated by —; abnormal or positive, +; and not done, ND. ANA indicated antinuclear antibody; anti-nDNA, antibodies DNA; anti-ENA, antibodies to extractable nuclear antigen; CH_{50}, total hemolytic complement, LBT, lupus band test; and LE, lupus erythematous

diffusion defect with a DLCO of 48% predicted.

Seven months later, she developed pericarditis, proteinuria, and weakness. An electromyogram was suggestive of a peripheral neuropathy. Direct immunofluorescence of normal skin at that time showed epidermal nuclear staining in a speckled (particulate) pattern. Serum antibody to a ribonuclease (RNase)-resistant ENA (anti-Sm) was present in high titer. Subepidermal deposits of IgM were again detected. Her DNA antibody (of IgM specificity by the *Crithidia lucillae* assay) remained elevated and the hypocomplementemia persisted. The LE preparations were consistently negative.

The clinical features and laboratory determinations found in this case suggest a scleroderma/SLE overlap syndrome. The absence of antibody to the RNase-sensitive ENA precludes the diagnosis of mixed connective tissue disease. It is of interest that the ANA staining pattern changed from nucleolar to particulate (speckled) and was reflected by a change in the immunofluorescence staining pattern of the skin to particulate (speckled).

Case 7.—A 27-year-old woman had depigmentation and myositis. She later developed sclerodactyly, weight loss, Raynaud's phenomenon, and diffuse nonscarring alopecia. She had no signs or symptoms of arthritis, adenopathy, serositis, keratoconjunctivitis sicca syndrome, dysphagia, vascular headaches, CNS disease, or renal disease.

Direct immunofluorescence of normal skin from the volar forearm showed epidermal nuclear IgG deposition in a nucleolar pattern. There was no subepidermal immunoglobulin. The light microscopic findings were typical of scleroderma. The serum ANA test was positive at 1:5,120 with a nucleolar staining pattern. Additional abnormal laboratory test results included a CPK of 140 IU and hypergammaglobulinemia of 2.14 gm/100 ml. The following determinations were normal or negative: anti-ENA, anti-nDNA, ESR, urinalysis, chest roentgenogram, and complete blood cell count.

These clinical and laboratory features are compatible with scleroderma.

Case 8.—A 57-year-old woman had chronic cutaneous LE. She later developed Raynaud's phenomenon, arthritis, mucous membrane ulceration, sclerodactyly, splenomegaly, and diffuse telangiectasia. She had no signs or symptoms of serositis, adenopathy, keratoconjunctivitis sicca syndrome, CNS disease, or renal disease.

Direct immunofluorescence of normal skin from the volar forearm disclosed epidermal nuclear IgG deposition in a nucleolar pattern. In addition, IgG was present at the dermal-epidermal junction. The serum ANA test was positive at 1:2,560 with a nucleolar staining pattern. Antibodies to native DNA were mildly elevated. Values for the following were normal or negative: anti-ENA, CH_{50}, BUN, serum creatinine, CPK, SGOT, and complete blood cell count.

The clinical features and laboratory determinations found in this patient suggest a scleroderma/SLE overlap syndrome.

COMMENT

Scleroderma is usually an easy clinical diagnosis because of the characteristic cutaneous sclerosis, which is readily detectable.[10] High titer nucleolar ANAs are present most commonly in patients with scleroderma[11,12] and are rarely found in patients with LE.[13,14] The present findings indicate that nucleolar IgG deposition on direct immunofluorescence of clinically normal skin usually correlates with high titer serum ANA when both tests are performed simultaneously. Ritchie observed in his scleroderma patients that very high titer ANAs were all of the IgG variety.[12]

The clinical and serologic features of these eight patients are summarized in the Table. The immunopathologic finding does not appear to distinguish a clinical subset of scleroderma in these few patients. This finding is consistent with previous studies that showed no correlation between ANAs and the natural history of scleroderma.[15,16] Six patients had scleroderma and two had a scleroderma/SLE overlap syndrome.

Serum ANA immunofluorescent staining patterns of our eight patients were nucleolar in high titer in six, nucleolar in low titer in one, and homogeneous in low titer in one. The diffuse or homogeneous staining may have obscured a nucleolar pattern or the nucleolar ANA may have become negative when the test was performed.[8] The ANA and direct immunofluorescent tests were not performed simultaneously in the two patients with low titers.

Epidermal nuclear staining appears to be an in vitro phenomenon.[5] High concentrations of easily diffusible ANAs in the dermis may bind to epidermal nuclear antigens when the tissue is prepared for direct immunofluorescence.[6] The process of freezing and thawing may destroy membrane integrity, allowing dermal antibody to bind to nuclear constituents.[6]

Nucleolar epidermal nuclear IgG deposition is found most often in patients with scleroderma or connective tissue disease with scleroderma-like features. However, this finding occurred in only eight of 50 (16%) such patients. The low prevalence of nucleolar epidermal IgG deposition reflects the low prevalence of high-titered nucleolar ANA in scleroderma.[11,12]

This investigation was supported in part by a grant from the Dermatology Foundation and by Public Health Service research grant AMO5154. Dr Gilliam is the recipient of Public Health Service research career development award AMO0278. The cost for printing the color photographs was supported, in part, by Westwood Pharmaceuticals, Inc. Elaine Vander-Beugle, Linda Franke, and Paula Crawford provided technical assistance.

References

1. Burnham TK, Fine G: The immunofluorescent "band test" for lupus erythematosus: III. Employing clinically normal skin. *Arch Dermatol* 103:24-32, 1971.

2. Tuffanelli DL: Lupus erythematosus. *Arch Dermatol* 106:553-566, 1972.

3. Gilliam JN, Cheatum DN, Hurd ER, et al: Immunoglobulin in clinically uninvolved skin in systemic lupus erythematosus: Association with renal disease. *J Clin Invest* 53:1434-1440, 1974.

4. Schrager MA, Rothfield NF: Clinical significance of serum properidin levels and properidin deposition in the dermal-epidermal junction in systemic lupus erythematosus. *J Clin Invest* 57:212-221, 1976.

5. Gilliam JN, Smiley JD, Ziff M: Correlation between serum antibody to extractable nuclear antigen and immunoglobulin localization in epidermal nuclei. *Clin Res* 22:611A, 1974.

6. Gilliam JN: The significance of cutaneous immunoglobulin deposits in lupus erythematosus and NZB/NZW F_1 hybrid mice. *J Invest Dermatol* 65:154-161, 1975.

7. Gilliam JN, Prystowsky SD: Mixed connective tissue disease syndrome: The cutaneous manifestations of patients with high titer serum antibody to RNase sensitive extractable nuclear antigen (ENA). *Arch Dermatol* 113:583-587, 1977.

8. Prystowsky SD, Tuffanelli DL: Speckled (particulate) epidermal nuclear IgG deposition in normal skin: Correlation of clinical features and laboratory findings in 46 patients with a subset connective tissue disease characterized by antibody to extractable nuclear antigen (ENA). *Arch Dermatol*, to be published.

9. Kay DM, Tuffanelli DL: Immunofluorescent technique in clinical diagnosis of cutaneous disease. *Ann Intern Med* 71:753-762, 1969.

10. Tuffanelli DL, Winkelmann RK: Systemic scleroderma: A clinical study of 727 cases. *Arch Dermatol* 84:49-64, 1961.

11. Burnham TK, Bank PW: Antinuclear antibodies: I. Patterns of nuclear immunofluorescence. *J Invest Dermatol* 62:526-534, 1974.

12. Ritchie RF: Antinucleolar antibodies: Their frequency and diagnostic association. *N Engl J Med* 282:1174-1178, 1970.

13. Burnham TK: Antinuclear antibodies: II. The prognostic significance of nuclear immunofluorescent patterns in lupus erythematosus. *Arch Dermatol* 111:203-207, 1975.

14. Prystowsky SD, Gilliam JN: Antinuclear antibody studies in chronic cutaneous discoid lupus erythematosus. *Arch Dermatol* 113:183-186, 1977.

15. Medsger TA, Masi AT, Rodnan GP, et al: Survival with systemic sclerosis (scleroderma). *Ann Intern Med* 75:369-376, 1971.

16. Jordon RE, Deheer D, Schroeter A, et al: Antinuclear antibodies: Their significance in scleroderma. *Mayo Clin Proc* 46:111-113, 1971.

Experimental Cutaneous Candidiasis in Rodents

II. Role of the Stratum Corneum Barrier and Serum Complement as a Mediator of a Protective Inflammatory Response

Thomas L. Ray, MD, Kirk D. Wuepper, MD

• Of six species of *Candida* applied epicutaneously to rodents, only *C albicans* and *C stellatoidea* penetrate the stratum corneum and produce inflammation. The role of the stratum corneum in experimental murine *Candida* infections was studied, therefore, by intraepidermal injection of blastospores in mice that received a prior injection of staphylococcal epidermolysin. All six species caused accumulation of neutrophils if placed within an intraepidermal cleft in contact with viable epidermis.

The role of serum complement in cutaneous candidiasis was also studied in vivo in rodents depleted of complement with cobra venom factor or deficient in the fifth component of complement. These animals failed to develop neutrophilic inflammatory responses to the six *Candida* species tested in contrast to control animals. *Candida albicans, C stellatoidea,* and *C tropicalis* developed extensive hyphal proliferation with invasion of the entire cutis and subcutis in these animals.

The stratum corneum provides an effective barrier to some, but not all *Candida* species. When this barrier is penetrated, complement mediates an acute neutrophilic pustular response that restricts *Candida* proliferation and prevents deep invasion of tissue.

(Arch Dermatol 114:539-543, 1978)

Human cutaneous candidiasis is a pustular dermatosis characterized by visible and microscopic abscesses that are composed predominantly of polymorphonuclear leukocytes. Experimental models of this disease in rodents,[1,2] guinea pigs,[3,4] and man,[5,6] have reproduced these lesions. The epicutaneous application of *Candida* blastospores under occlusion for 24 hours in rodents results in intraepidermal microabscesses and subcorneal pustules at sites of hyphal invasion. Only *Candida albicans* and *C stellatoidea* penetrate the stratum corneum and induce lesions; remaining species tested fail to evoke an inflammatory pustular response.[1]

The pathologic mechanism responsible for this neutrophilic cellular migration may be related to the generation of chemotactic stimuli. Studies performed in vitro have shown migration of human po phonuclear leukocytes in respor *albicans*. This response is indep of the organism's viability, but dent upon a heat-labile seru tor.[7,8] We have shown that complement is activated v alternative (properdin) path viable or heat-killed *Candida* well as via extracted, soluble polysaccharides, mannans.[9] Ac of complement is known to chemotactically active fra C3a, C5a, and C567 that directed migration of polym clear leukocytes.[10]

Since only two *Candida* evoke pustular reactions, and ment participates in *Candida* leukocyte migration in vitro, ied whether all species of *Ca* capable of activating com Next, we designed experime the role of the stratum co rodents in vivo.

To exclude the stratum c a barrier in mice, we used purified staphylococcal toxi molysin, to cause a su intraepidermal cleft[11] into v *dida* species were injected.

Finally, to test the dep the pustular reaction on co we studied infections in m

Accepted for publication July 27, 1977.

From the Department of Dermatology, School of Medicine, University of Oregon Health Sciences Center, Portland, Ore.

Read in part before the annual meeting of the Society for Investigative Dermatology, Atlantic City, NJ, May 1, 1976.

Reprint requests to Department of Dermatology, University of Oregon Health Sciences Center, 3181 SW Sam Jackson Park Rd, Portland, OR 97201 (Dr Wuepper).

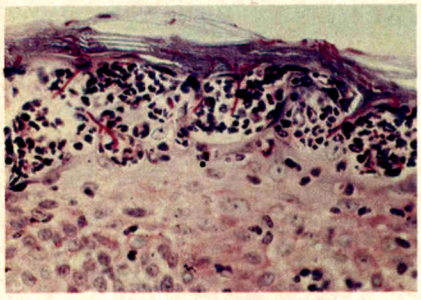

Fig 1.—Polymorphonuclear pustular inflammatory response to epicutaneously applied *C albicans*. PAS-positive hyphal elements have penetrated the stratum corneum and are invading the stratum malpighii where they are surrounded by inflammatory cells forming microabscesses (PAS, original magnification ×640).

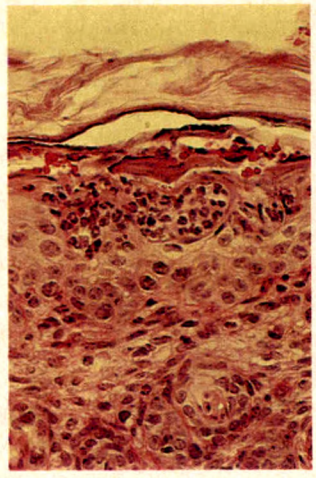

Fig 3.—Zymosan particles within epidermolysin-induced cleft with focal inflammatory microabscesses (PAS, original magnification ×640).

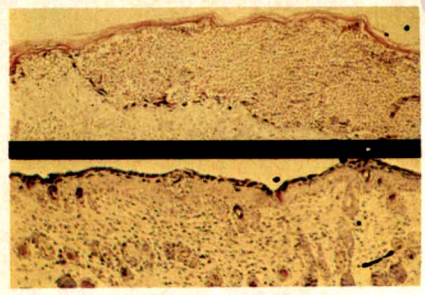

Fig 5.—Top, Rat skin following saline with epicutaneously applied *C albicans*. Note extensive pustular reaction. Bottom, CoF-treated rat with epicutaneously applied *C albicans*. Note paucity and small size of pustular reaction (hematoxylin-eosin, original magnification ×44).

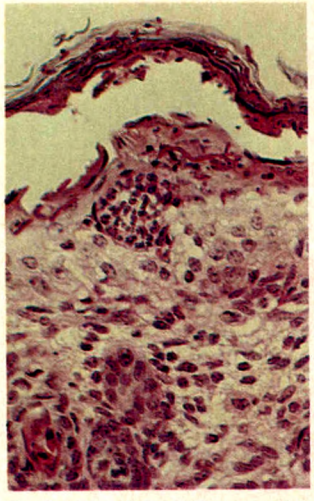

Fig 2.—*Candida albicans* within an epidermolysin-induced cleft with invasion of the stratum corneum and stratum malpighii and with an acute pustular inflammatory response (PAS, original magnification ×640).

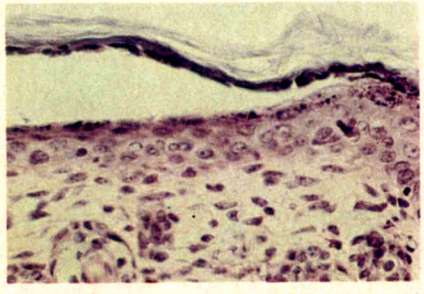

Fig 4.—Epidermolysin-induced epidermal cleft injected with saline alone. Note level of epidermal separation and absence of inflammation (hematoxylin-eosin, original magnification ×640).

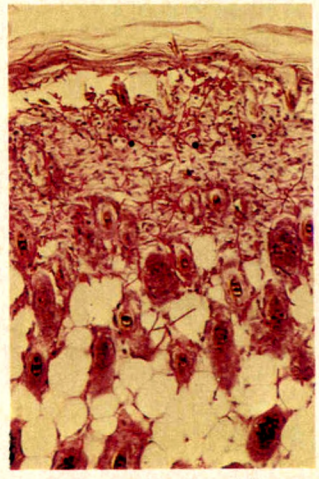

Fig 6.—Extensive *Candida* invasion of entire cutis in a C5 deficient mouse. Note paucity of inflammatory cells and depth of penetration (PAS, original magnification ×160).

Table 1.—Comparison of Epicutaneous Application and Intraepidermal Injection of *Candida* Hyphal Penetration and Inflammation

	Epicutaneous Application			Intraepidermal Injection		
Organism Applied	Stratum Corneum	Stratum Malpighii	Inflammation	Stratum Corneum	Stratum Malpighii	Inflammation
C albicans	6/6*	6/6	6/6	4/4	4/4	4/4
C stellatoidea	6/6	6/6	6/6	4/4	4/4	4/4
C tropicalis	0/6	0/6	0/6	0/4	4/4	4/4
C paropsilosis	0/6	0/6	0/6	0/6	0/6	6/6
C krusei	0/6	0/6	0/6	0/6	0/6	6/6
C guilliermondi	0/6	0/6	0/6	0/6	0/6	6/6
Heat-killed blastospores (*C albicans*)	0/6	0/6	0/6	0/4	0/4	4/4
Zymosan	ND†	ND	ND	0/4	0/4	4/4

*Number of animals showing penetration of inflammation/number of animals tested.
†ND, not done.

cally deficient in the fifth component of complement (C5)[12] and rodents depleted of complement by the action of cobra venom factor (CoF).[13]

METHODS

Animals

Simonson albino rats, Webster Swiss mice, and two congeneric strains of mice, one genetically deficient in C5, $B_{10}D_2/0$, and the other with intact complement, $B_{10}D_2/N$ were purchased from their suppliers. All animals were newborns, 1 to 4 days old, and were separated from their mothers during the experimental period.

Candida Species

Candida albicans, C stellatoidea, C tropicalis, C paropsilosis, C krusei, and *C guil-*

liermondi were isolated from human sources, identified by sugar assimilation and fermentation,[14] and maintained in Sabouraud broth media or on agar slants at room temperature. Boiled yeast cell walls from *Saccharomyces cerevisiae*, supplied as zymosan, were commercially obtained.

Complement Activation

Evidence of activation of complement was measured by the immunoelectrophoretic conversion of the third component of complement (C3) and properdin factor B, as described.[8]

Complement Depletion and Assay

Intraperitoneal injections of 1 unit of CoF per gram of animal weight were given 24 hours before administration of *Candida* organisms. This led to marked depletion of serum complement, which was monitored by double immunodiffusion in agar against monospecific antisera to C3 or C5, raised by injection of $B_{10}D_2/N$ serum in C5 deficient mice. C3 and C5 were greatly depleted at 24 hours and remained low for longer than 48 hours.

CoF, at a concentration of 1 unit/ml media, did not inhibit the proliferation of *C albicans* as determined by culture counts or viability measured by trypan blue dye exclusive in vitro. Hyphae differentiated normally when blastospores were incubated in 10% normal human or mouse serum.

Application of *Candida* Organisms

Candida blastospores were introduced in rodents by epicutaneous application under occlusion as described previously[1] or by intraepidermal injection. The latter method was accomplished by means of a staphylococcal exotoxin, epidermolysin, which was purified by the method of Dimond and Wuepper[15] from coagulase-positive *S aureus* strain EV, phage group 2, type 55/71. Two micrograms in 20 μl of phosphate-buffered saline pH 7.3 were injected subcutaneously into the backs of newborn mice. After 60 minutes, a subgranular, intraepidermal cleft was formed by gently rubbing the skin so as to leave the overlying skin intact. *Candida* blastospores, 1×10^6, or 0.1 mg of zymosan in 10 μl of normal saline were injected into the space. Normal saline was used as control.

Following a 24-hour incubation period the animals were killed. Tissue was obtained for histologic study and blood was collected in heparinized micropipettes from the heart for immunodiffusion assay of C3 and C5.

Histologic Methods

Tissue was fixed in formaldehyde, embedded in paraffin, and stained by conventional methods with either hematoxylin-eosin or the PAS reaction. Serial sections totaling approximately 100 cuts, were examined for (1) the presence and depth of hyphal penetration in the tissue and (2) an inflammatory response of leukocytes about hyphae or within the epidermal cleft.

RESULTS

The activation of the alternative pathway of serum complement by *C albicans* was previously described[8] and independently confirmed by fluorescent antibody and immunoelectrophoretic studies.[16] Extending this finding, all six species of *Candida* tested in this study converted C3 and properdin factor B when incubated with normal human serum.

The results of epicutaneous infections in normal mice or rats are summarized in Table 1. When *C albicans* or *C stellatoidea* were applied epicutaneously, they penetrated the stratum corneum and evoked pustular inflammatory reactions (Fig 1). The remaining species, including *C tropicalis*, failed to penetrate the stratum corneum and no inflammatory response was recognized (Table 1). Intraepidermal infections in normal mice are also summarized in Table 1.

Candida albicans and *C stellatoidea* hyphae invaded the overlying stratum corneum and the underlying stratum malpighii. *Candida tropicalis* did not penetrate the stratum corneum but did invade the stratum malpighii. The remaining species did not penetrate the stratum corneum or the stratum malpighii. All six species evoked an inflammatory response of leukocytes within the epidermis, or the cleft, or both. Only *C albicans, C stellatoidea*, and *C tropicalis* elicited intraepidermal microabscesses of neutrophils about hyphae that penetrated the viable epidermis (Fig 2).

Zymosan, a particulate substance known to activate complement,[17] produced focal accumulation of polymorphonuclear cells in the epidermis when introduced within the epidermal cleft (Fig 3). Epidermolysin alone or followed by intraepidermal normal saline injections produced no inflammatory reactions within 24 hours (Fig 4). Since rats are insensitive to epidermolysin, intraepidermal infections were not studied in this species.

The results of *C albicans* infections in complement-depleted rodents are summarized in Table 2. In general, the inflammatory response was greatly suppressed, but not completely abolished, when compared with control animals injected with saline (Fig 5).

Intraepidermal injections of each *Candida* sp in CoF treated Webster Swiss mice, $B_{10}D_2/N$, and $B_{10}D_2/0$ mice were studied and compared with saline-treated controls. The results are given in Table 3. Note tha *albicans* and *C stellatoidea* a penetrated the stratum corne while *C tropicalis* did not. Howe all three species exhibited con erable penetration and prolifera throughout the entire cutis, reacl the depths of the subcutaneous within 24 hours (Fig 6). Only mini inflammation and leukocyte accu lation were noted. The remai species failed to penetrate beyond cleft, and virtually no inflamma developed.

Infections in C5-deficient ($B_{10}D$ animals behaved in a manner iden to normal mice treated with (Treatment of C5-deficient mice CoF did not enhance or alter nature of infection when comp with untreated C5-deficient anin CoF alone evoked no cutan changes in either mice or rats.

COMMENT

The stratum corneum is a dyn cally regenerating physical bar between the viable epidermis and environment. This thin, keratin layer retards transcutaneous w loss, protects underlying tissue f physical and chemical agents, excludes many overt and oppo nistic pathogens that colonize skin. The epidermolysin-tre mouse is a unique in vivo model evaluating the barrier function of stratum corneum. Subgranular cl age of the epidermis without killing by epidermolysin selecti separates the stratum corneum granular layers from the stra malpighii, allowing access to vi epidermis. To our knowledge, study represents the first applica of epidermolysin to functional stu of the stratum corneum in infecti

Applied epicutaneously or intra dermally, *C albicans* and *C st toidea* invade both the stratum neum and stratum malpighii. *Can tropicalis* fails to penetrate the s tum corneum barrier when app epicutaneously. However, when in duced below the stratum corneu does invade the stratum malpigh an extent comparable to *C albi* and *C stellatoidea*. The remai species do not invade the stra corneum or the stratum malpi when placed intraepidermally or cutaneously. In this model the stra corneum is impervious to many, not all, *Candida* species and prov a barrier against potential pa gens.

Epidermal invasion by some *Ca*

Table 2.—Inflammatory Response After Epicutaneous Application of *Candida albicans* in Cobra Venom Factor Treated Rodents

Severity of Pustular Response	Rats		Mice	
	Saline Treated	CoF Treated	Saline Treated	CoF Treated
Extensive	6/6*	0/6	4/6	0/6
Moderate	0/6	0/6	2/6	0/6
Minimal	0/6	4/6	0/6	5/6
None	0/6	2/6	0/6	1/6

*Number of animals responding/number of animals tested.

Table 3.—Intraepidermal Injection of *Candida* Species: Penetration of *Candida* Species in States of Complement Depletion or Deficiency*

Organism Applied	Mice		$B_{10}D_2$/N Mice		$B_{10}D_2$/0 Mice	
	Saline Treated	CoF Treated	Saline Treated	CoF Treated	Saline Treated	CoF Treated
C albicans	1-2†	1-5	1-2	1-5	1-5	1-5
C stellatoidea	1-2	1-5	1-2	1-5	1-5	1-5
C tropicalis	2	2-5	2	2-5	2-5	2-5
C paropsilosis	0	0	0	0	ND‡	ND
C krusei	0	0	0	0	ND	ND
C guilliermondi	0	0	0	0	ND	ND

*Data accumulated from 4 to 6 test animals in each group and heading.
†Level of invasion: 0, no invasion; 1, stratum corneum; 2, stratum malpighii and basale; 3, superficial dermis; 4, dermis; 5, subcutaneous fat.
‡ND, not done.

da species occurs by an unexplained mechanism requiring at least two steps, stratum corneum penetration and penetration of the deeper, viable layers. *Candida albicans* and *C stellatoidea* have both capabilities, while *C tropicalis* possesses only the latter. The other species tested are incapable of penetrating either epidermal layer. Specific enzymatic digestion of epidermal structures is a conceivable mechanism of entry and may vary with *Candida* species and strains. *Candida albicans* is said to be capable of utilizing keratinized cells as a source of nitrogen,[18] which may facilitate epidermal invasion. However, the factors responsible for breaching the stratum corneum barrier must still be elucidated.

Those *Candida* species that are capable of traversing the stratum corneum elicit subcorneal and intraepidermal neutrophilic pustules. Such lesions characterize a variety of dermatologic disorders,[19] yet the mechanism of leukocyte migration from dermal blood vessels into the epidermis is poorly understood. Neutrophil chemoattractants, either exogenous in origin or generated from host inflammatory mediators, offered attractive hypotheses.

In vitro studies of *Candida*-induced neutrophil chemotaxis and complement activation[8] support the interaction of *Candida* with host inflammatory mediators. Since all species of *Candida* studied activate complement, they should evoke a neutrophilic inflammatory reaction upon contact with the extracellular fluid bathing the viable epidermis. Our studies show that inflammation does not occur until hyphae penetrate the stratum corneum and support this concept. Even heat-killed, washed blastospores, or zymosan elicits neutrophilic responses, which further supports an endogenous mediation system.

Administration of CoF in rodents leads to unregulated complement consumption, with depletion of C3 and C5. In both the epicutaneous and intraepidermal studies (Tables 2 and 3), the pustular inflammatory response to *Candida* is suppressed by pretreating the animals with CoF.

The C5-deficient mice and congeneric C5-intact mice differ only in this single serum protein. C5-intact animals form neutrophilic microabscesses identical to Webster Swiss mice, and hyphal proliferation is confined to the epidermis. Only infrequently we observed superficial dermal invasion (Table 3). However, C5-deficient mice develop no inflammatory response and permit those *Candida* species capable of cutaneous invasion to proliferate into the subcutaneous fat. C5-deficient mice, CoF-treated C5-intact mice, and CoF-treated Webster Swiss mice behave similarly, allowing extensive *Candida* growth and invasion, unchallenged by an inflammatory response. These data further support serum complement as an essential mediator of inflammation in vivo in cutaneous candidiasis.

Neutrophils, in response to complement-generated chemoattractants, form an inflammatory buttress of cells beneath the *Candida*, confining the infection to the superficial skin. Although chemoattractants are released from C3 and C5, the fragment C5a is 1,000-fold more potent than C3a.[20] In these studies, C5 alone is essential for normal neutrophil accumulation. Since complement components through C3 are present in C5-deficient mice, the participation of C3a must be minor in this inflammatory reaction. Sequential assembly of later components (C6 through C9) is also impaired by complement depletion with CoF or deficiency of C5, and their role cannot be assessed fully.

Studies of experimental systemic candidiasis in mice, induced by intravenous injection of *C albicans*, indicate that complement intact mice survive significantly longer than complement deficient mice. It is speculated that longer survival is achieved through greater and earlier mobilization of phagocytic cells.[21]

The predominance of *C albicans* in clinical disease is not explained by these studies. Its potential for cutaneous invasion and complement activation is not unique and does not differentiate it from the less common *C stellatoidea*. The ability of these two species to penetrate the stratum corneum is important however, and their ability to invade stratum malpighii is shared only with *C tropicalis*. These invasive characteristics may contribute to the higher incidence of these three species in clinical disease when compared with the others.

Cutaneous defense against acute *Candida* infections in rodents is dependent on at least three factors. First, an intact stratum corneum provides a physical barrier that excludes many *Candida* species, even under occlusive conditions. In the absence of intact stratum corneum, or in the case of invasive *C albicans* and *C stellatoidea*, complement-derived inflammatory mediators are essential both in vitro and in vivo for mobilizing the phagocytic cells that compose the acute neutrophilic reaction. Finally, competent neutrophils, responding to

chemotactic stimuli, are needed to confine the invading organisms.

Several clinical disease states illustrate the potential importance of these mechanisms in cutaneous defense against *Candida*. Following maceration, thermal burns, or indwelling catheters, a compromised or disrupted stratum corneum allows entry of *Candida* and other organisms due to impaired barrier function.

In a recent report, human C5 deficiency was associated with recurrent candidiasis, particularly of mucous membranes.[22] An immunofluorescence study of mucocutaneous candidiasis demonstrated the deposition of properdin and C3 but not immunoglobulin or C4 in the skin, further supporting alternative pathway complement mediation in this disease.[16] A boy with *Candida* endocrinopathy syndrome and membranoproliferative glomerulonephritis had low serum C3 but normal C4 levels. A renal biopsy showed glomerular and tubular deposits of IgG, C3, and *Candida* antigen, but not C4.[23] Low total hemolytic complement levels were also reported in several family members with mucocutaneous candidiasis.[24]

Finally, some conditions characterized by impaired neutrophil chemotaxis have been associated with *Candida* infections, including the hypergammaglobulinemia E syndromes[25,26] and acrodermatitis enteropathica.[27,28]

The stratum corneum, serum complement, and polymorphonuclear leukocytes form an integrated defense against cutaneous *Candida* infections. Impairment of any factor precisposes the host to cutaneous candidiasis. More work will be required to explain the mechanism of stratum corneum penetration by *C albicans* and *C stellatoidea*. Also, the mechanism whereby neutrophils limit the proliferation of hyphal elements must be explained.

This investigation was supported in part by Public Health Service grants 5T01 AM 05300 and 1T32 AM 07153.

Dr Ray is the recipient of the Nelson Paul Anderson award of the Pacific Dermatologic Association, Honolulu, Hawaii.

Dr Wuepper was the recipient of Public Health Service research career development award 5K04 AM 40086.

Diane Baker, MD, provided purified staphylococcal epidermolysin. Cinda Lobitz, Steven Howe, and Margaret Wattman provided technical assistance.

References

1. Ray TL, Wuepper KD: Experimental cutaneous candidiasis in rodents. *J Invest Dermatol* 66:29-33, 1976.

2. Ray TL, Baker DH, Wuepper KD: Experimental cutaneous candidiasis: Role of the stratum corneum. *Clin Res* 24:495A, 1976.

3. Van Cutsem J, Thienpont D: Experimental cutaneous *Candida albicans* infections in guinea pigs. *Sabouraudia* 9:17-20, 1971.

4. Sohnle PG, Frank MM, Kirkpatrick CH: Mechanisms involved in elimination of organisms from experimental cutaneous *Candida albicans* infections in guinea pigs. *J Immunol* 117:523-530, 1976.

5. Maibach HI, Kligman AM: The biology of experimental human cutaneous moniliasis (*Candida albicans*). *Arch Dermatol* 85:233-254, 1962.

6. Robora A, Marples RR, Kligman AM: Experimental infection with *Candida albicans*. *Arch Dermatol* 108:69-73, 1973.

7. Denning TJV, Davies RR: *Candida albicans* and the chemotaxis of polymorphonuclear neutrophils. *Sabouraudia* 11:210-221, 1973.

8. Ray TL, Wuepper KD: Activation of the alternative (properdin) pathway of complement by *Candida albicans* and related species. *J Invest Dermatol* 67:700-703, 1976.

9. Ray TL, Hanson A, Ray LF, et al: Purification of a polymannan from *Candida albicans* which activates serum complement. *Clin Res* 25:100A, 1977.

10. Ward PA, Cochrane CG, Müller-Eberhard HJ: The role of serum complement in chemotaxis of leukocytes in vitro. *J Exp Med* 122:327-346, 1965.

11. Wuepper KD, Dimond RL, Knutson DD: Studies on the mechanisms of epidermal injury by a staphylococcal epidermolytic toxin. *J Invest Dermatol* 65:191-200, 1975.

12. Nilsson UR, Müller-Eberhard HJ: Deficiency of the fifth component of complement in mice with an inherited complement defect. *J Exp Med* 125:1-16, 1967.

13. Cochrane CG, Müller-Eberhard HJ, Aikin BS: Depletion of serum complement *in vivo* by a protein of cobra venom: Its effect on various immunologic reactions. *J Immunol* 105:55-69, 1970.

14. Silva-Hutner M: Yeast, in Blair JE, Lennette EH, Truant JP (eds): *Manual of Clinical Microbiology*. Baltimore, Md, Williams & Wilkins, 1970.

15. Dimond RL, Wuepper KD: Purification and characterization of a staphylococcal epidermolytic toxin. *Infect Immun* 13:627-633, 1976.

16. Sohnle PG, Frank MM, Kirkpatrick CH: Deposition of complement in the cutaneous lesions of chronic mucocutaneous candidiasis. *Clin Immunol Immunopathol* 5:340-350, 1976.

17. Pillemer L, Blum L, Lepow IH, et al: The properdin system and immunity: I. Demonstration and isolation of a new serum protein, properdin, and its role in immune phenomena. *Science* 120:279-285, 1954.

18. Kapica L, Blank F: Growth of *Candida albicans* on keratin as a sole source of nitrogen. *Dermatologica* 115:81-105, 1957.

19. Wilkinson DS: Pustular dermatoses. *Br J Dermatol* 81(suppl 3):38-45, 1969.

20. Müller-Eberhard HJ: The serum complement system, in Miescher PA, Müller-Eberhard (eds): *Textbook of Immunopathology*, ed 2. New York, Grune & Stratton, 1976, vol 1, p 45.

21. Morelli R, Rosenberg LT: Role of complement during experimental *Candida* infection in mice. *Infect Immun* 3:521-523, 1971.

22. Rosenfeld SI, Kelly ME, Leddy JP: Hereditary deficiency of the fifth component of complement in man: I. Clinical, immunochemical and family studies. *J Clin Invest* 57:1626-1634, 1976.

23. Chesney RW, O'Regan S, Guyda HJ, et al: *Candida* endocrinopathy syndrome with membranoproliferative glomerulonephritis: Demonstration of glomerular *Candida* antigen. *Clin Nephrology* 5:232-238, 1976.

24. Drew JH: Chronic mucocutaneous candidiasis with abnormal function of serum complement. *Med J Aust* 2:77-79, 1973.

25. Dahl MV, Greene WH, Quie PG: Infection, dermatitis, increased IgE, and impaired neutrophil chemotaxis. *Arch Dermatol* 112:1387-1390, 1976.

26. Van Scoy RE, Hill HR, Ritts RE, et al: Familial neutrophil chemotaxis defect, recurrent bacterial infections, mucocutaneous candidiasis, and hypergammaglobulinemia E. *Ann Intern Med* 82:766-771, 1975.

27. Huff JC, Weston WL, Neldner KH, et al: Defective monocyte chemotaxis and zinc deficiency in acrodermatitis enteropathica. *Clin Res* 23:229A, 1975.

28. Weston WL: Disorders of phagocyte function. *Arch Dermatol* 112:1589, 1976.

Neutrophil Chemotaxis in Patients With Atopic Dermatitis Without Infection

Mark V. Dahl, MD; K. Lynn Cates, MD; Paul G. Quie, MD

• Atopic dermatitis has been associated with recurrent infection and impaired neutrophil chemotaxis in some patients. In order to determine if dermatitis per se could decrease polymorphonuclear leukocyte (PMN) chemotaxis, we investigated chemotaxis in 13 patients with atopic dermatitis and no clinical or historical evidence of recurrent or severe infections. Most patients had extensive, but mild, disease. Leukocyte chemotaxis was measured by the Boyden chamber and agarose techniques. There was no difference between patient and control neutrophil chemotactic activity. These findings suggest that atopic dermatitis is not ordinarily associated with impaired PMN chemotaxis in the absence of generalized erythroderma or increased susceptibility to infection.

(*Arch Dermatol* 114:544-546, 1978)

Atopic dermatitis has been associated with recurrent infection and, in some patients, with impaired neutrophil chemotaxis.[1-13] The relationships among dermatitis, infection, and decreased chemotaxis are unclear. While impairment of neutrophil chemotaxis might allow lodgment of bacteria and subsequent clinical infection,[14] it is also possible that impaired neutrophil chemotaxis is a secondary manifestation of skin disease and infection.

In order to investigate if dermatitis per se, in the absence of infection, suppresses neutrophil motility, we studied leukocyte chemotaxis in 13 uninfected patients with atopic dermatitis.

SUBJECTS

Chemotaxis was studied prospectively in 13 consecutive adult patients with atopic dermatitis and no history of severe or recurrent infections. All patients had a chronic or chronically relapsing, severely pruritic dermatitis with flexural lichenification and carried a clinical diagnosis of atopic dermatitis.[15] Most had elevated serum levels of immunoglobulin E. Clinical data are presented in the Table.

With the exception of patient 12 who had active atopic erythroderma, the dermatitis was fairly well controlled at the time chemotaxis was evaluated. All patients were receiving topical medications, including corticosteroids, and two (11 and 13) were being treated empirically with antibiotics although they had no overt infection. No patient was receiving corticosteroids systemically or other medications known to influence neutrophil chemotactic responsiveness. One patient (3) had had a single episode of pneumonia 20 years prior to the study.

Control subjects were healthy adult volunteers taking no medications and without skin disease or increased susceptibility to infection.

METHODS

Chemotactic Factors

A bacterial chemotactic factor was produced by the overnight growth of *Escherichia coli* on liquid medium 199 at 37 C. The culture broth was passed through a 0.22 μ-pore size filter and the filtrate stored at −70 C in 1-ml ampules. The same batch of bacteria-derived chemotactic factor was used for both the modified Boyden chamber and agarose assays. Bacterial factor was used undiluted in the agarose assay, and diluted 1/20 in Hanks balanced salt solution (HBSS) in the Boyden assay.

A complement-derived chemotactic factor was produced by activation of 5 ml of normal human serum with 125 mg zymosan. Zymosan-activated serum was used only in the agarose technique.

Preparation of Polymorphonuclear Leukocytes

For the Boyden method, polymorphonuclear leukocytes (PMN) were separated from heparinized whole blood (10 units of heparin sodium per milliliter of blood) by gravity sedimentation. The PMNs were removed from leukocyte-rich plasma by centrifugation. They were washed twice in HBSS, and resuspended in 10% autologous plasma in HBSS to a concentration of 2.0×10^6 PMNs/per milliliter.

For the agarose method, a more purified population of PMNs was obtained by a modification of Boyum's method.[16] Red blood cells were removed from heparinized blood by centrifugation at 400 g. Plasma was centrifuged at 1,000 g for five minutes to remove additional platelets. The buffy coat was mixed with this platelet-free plasma and allowed to settle at 37 C. Leukocyte-rich plasma was removed, centrifuged at 400 g for ten minutes, and resuspended in 8 ml of minimum essential media (MEM) supplemented with glutamine (2 mM), penicillin (100 units/ml), and streptomycin (100 μg/ml). Leukocytes in MEM were layered over lymphocyte separation medium and centrifuged at 400 g for 45 minutes. The PMNs were recovered from the bottom of the tube. Preparations were at least 97% pure. Remaining RBCs in PMN suspensions were lysed by mixing the pellet with 6 ml of sterile distilled water.[17] After 25 seconds, isotonicity was restored by addition of 2 ml 3.5% sodium chloride to the cell mixture. Isolated cell suspensions were washed twice with 8 ml of MEM and centrifuged at 400 g for ten minutes. Cells thus prepared were at least 90% viable as determined by exclusion of trypan blue dye.

Assay of Chemotaxis by the Boyden Method

Neutrophil chemotaxis was evaluated using a modification of the method originally described by Boyden.[18,19] Leukocyte suspension, 0.4 ml, was added to the upper compartment of the chemotaxis modified Boyden chamber. A 5-μ-pore size filter separated the cell suspension from the standard chemoattractant, bacterial factor, in the lower compartment of the chamber. After a two-hour incubation at 37 C, the filters were removed, fixed, and stained. Chemotactic activity was the number of PMNs adhering to the chemoattractant side of the filter (ie, cells that had come completely through the filter) inside a 5 × 5-mm reticule in ten randomly selected high-power fields. Results expressed are the averages of triplicate determinations. Parallel control chambers contained HBSS in the lower compartment. Normal values using this technique in our laboratory are 35 to 100.

Assay of Chemotaxis by Agarose Method

Chemotaxis under agarose was performed by a modification of the method of Nelson and co-workers.[20,21] This method measures distance transversed by the leading front of PMNs under agarose gel.

Agarose was dissolved in sterile, distilled water at 100 C to make a final concentration of 1.3% agarose. The solution was cooled to 48 C and mixed with an equal volume of prewarmed 2× MEM containing

Accepted for publication Nov 18, 1977.

From the Departments of Dermatology and Pediatrics, University of Minnesota Medical School, Minneapolis.

Reprint requests to Department of Dermatology, Box 98 University Hospitals, 420 Delaware St SE, Minneapolis, MN 55455 (Dr Dahl).

Patient Data														
					Subjective†		Objective‡			Boyden‖		Agarose‖	
Patient/Age, yr/Sex	Duration, yr	Asthma*	Hay Fever*	Hives*	Rash	Itch	Extent	Severity	IgE§, (1,000 Units)	P	C	P	C
1/28/F	28	—	+	+	1+	1+	4+	1+	12.7	99	133	ND	ND
2/38/F	38	+	—	+	2+	2+	4+	2+	8.4	64	48	2.3	1.9
3/28/M	20	—	+	—	2+	2+	4+	1+	5.7	67	39	2.8	2.4
4/33/F	33	+	+	—	2+	2+	4+	1+	1.4	82	48	3.0	4.0
5/18/F	1	—	—	—	1+	1+	3+	2+	0.3	76	69	3.0	4.1
6/25/M	11	+	+	—	2+	2+	3+	1+	4.1	41	64	3.1	3.2
7/27/F	27	+	—	—	2+	2+	2+	1+	2.6	128	68	2.9	3.3
8/35/F	34	—	+	+	1+	1+	2+	1+	0.0	35	69	4.1	4.3
9/26/M	26	—	+	+	1+	2+	3+	2+	0.2	92	35	3.4	3.4
10/35/M	11	—	—	—	2+	2+	3+	2+	7.2	62	87	3.4	3.2
11/66/F	66	+	+	+	4+	4+	4+	4+	0.8	87	91	4.6	3.8
12/54/M	54	+	—	—	1+	1+	2+	1+	3.2	36	85	3.7	2.7
13/27/M	25	+	—	—	2+	2+	4+	2+	20.3	91	150	3.7	3.1

* +, history present, —, absent.
†Patient evaluated severity of symptoms at time of study.
‡Physician evaluated extent and severity of dermatitis at time of study. Extent indicates percentage of body involved with dermatitis; severity, percentage of body involved with erythema (1+ = 0 to 24%, 2+ = 25% to 49%, 3+ = 50% to 74%, 4+ = 75% to 100%).
§Normal values 30 to 600 IU/ml.
‖P indicates patients; C, controls; ND, not done. Respective chemotaxis at three hours were 4.9 and 4.2.

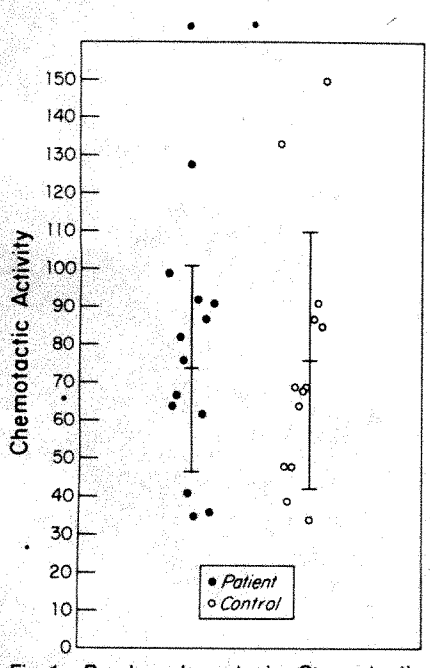

Fig 1.—Boyden chemotaxis. Chemotactic activity of neutrophils from 13 patients and 13 control subjects. Bars represent mean ± 1 SD.

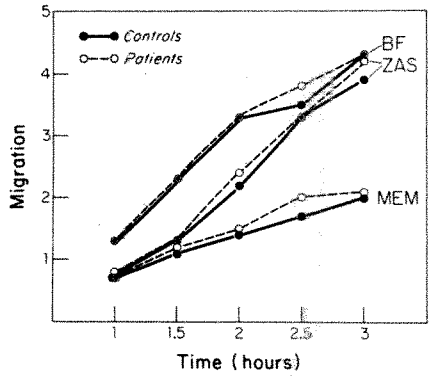

Fig 2.—Chemotaxis under agarose. Mean migration under agarose of PMNs from 13 patients and 13 control subjects after incubation for specified time intervals. Minimal essential medium (MEM) was used for measuring random migration. Bacterial factor (BF) and zymosan-activated serum (ZAS) were the chemoattractants used to evaluate directed migration.

25% pooled human serum and 750 μg/ml sodium bicarbonate. Five milliliters of the resulting agarose solution were delivered to 60 × 15-mm tissue culture dishes (Falcon 3002) and allowed to harden. Six series of three circular wells, 2.4 mm in diameter, were cut in each plate and agarose plugs were removed by suction. Six replicate assays were performed for each incubation time and chemotactic factor on each patient and compared with control values assayed on the same day.

Ten microliters of PMN suspension (2.5×10^5 cells) in MEM were delivered to the center well of each six-well series. The outer well was filled with 10 μl of chemotactic factor and the inner well with 10 μl of MEM. Plates were incubated at 37 C for 1, 1.5, 2.5, and 3 hours. Migration was terminated by fixation with absolute methanol for 30 minutes, followed by buffered formaldehyde solution for 30 minutes. The gel was removed intact, cells stained with Wright's stain, and plates allowed to dry. Migration patterns were projected under standardized conditions, and migration quantitated in arbitrary units by measurement of linear distance from the margin of the well to the leading front of cells. The standard deviation of replicate assays using this method is 11% of the mean for chemotaxis of normal PMNs toward bacterial factor and is similar for patient PMNs. Normal values at two hours' incubation for bacterial factor (uncorrected for random migration) are 2.3 to 4.5 and for zymosan-activated serum are 1.3 to 2.8. Random migration was assayed by placing MEM in both outer and inner wells of separate plates in each experiment. Normal values for random migration after two hours' incubation are 1.0 to 2.1.

Serum IgE

Concentrations of IgE were measured by the radioimmune absorbant assay. The concentration of IgE in patient sera is evaluated by its binding capacity to compete with a fixed amount of labeled IgE for binding sites on anti-IgE. Normal values are 30 to 600 IU/ml for adults.

RESULTS

Patient and control PMN chemotactic activity was comparable when measured by both the Boyden and the agarose techniques. Mean Boyden chemotactic activity using bacterial factor as the chemoattractant was 74 in patients and 76 in controls (Fig 1). Medians were 76 and 69, respectively.

Random migration and chemotaxis was assessed by the agarose technique after 1, 1.5, 2, 2.5, and 3 hours' incubation (Fig 2). Kinetics of random migration were comparable for patients and controls. Chemotactic activity of patient and control neutrophils was comparable when either bacterial factor or zymosan-activated serum was used as the chemoattractant. For example, mean chemotactic activity after two hours' incubation was 3.2 and 2.4 in patients, and 3.3 and 2.2 in controls with the two chemoattractants, respectively. Corresponding medians were 3.1 and 2.3 for patients and 3.2 and 2.0 for controls.

As is shown in the Table, patients and controls with low normal or elevated chemotaxis by one assay were invariably well within the normal range when assayed by the other technique. Some difference in results between the two assays can be expected since chemotactic activity measured by the Boyden assay reflects the number of cells having migrated a given distance (ie, the filter width); whereas, the agarose technique reflects the distance travelled by a leading front of cells. The reasons for low agarose chemotaxis in control 2 and elevated Boyden chemotaxis in patient 7 and controls 1 and 13 are unknown.

As can be seen in the Table, serum IgE levels were elevated in ten of the 13 patients.

COMMENT

In 1974, Hill and Quie described three patients with skin disease resembling atopic dermatitis, recurrent severe staphylococcal infections, elevated serum IgE levels, and greatly depressed neutrophil chemotaxis.[2] Subsequently, impaired chemotaxis has been reported in many patients with atopic dermatitis, most of whom have had increased susceptibility to infection.[1-13] These reports suggest that a relationship may exist between atopic dermatitis and impaired neutrophil chemotaxis.

While describing a family with impaired neutrophil chemotaxis and associated asthma, eczema, and infection, Jacobs and Norman[8] noted normal chemotactic responsiveness of neutrophils from eight "control" children with atopic dermatitis. Rogge and Hanifin evaluated neutrophil chemotaxis in 11 patients with atopic dermatitis.[4] Neutrophil chemotactic response was decreased in all eight patients with extensive severe dermatitis but normal in three patients with milder disease. Only one of these 11 patients was not clinically infected, and leukocyte chemotaxis of that patient was normal. Subsequently, Hanifin and Rogge found impairment of neutrophil chemotaxis in patients with atopic dermatitis.[5] Most of these patients had severe and recalcitrant dermatitis. All had infection consisting mostly of superficial staphylococcal pustules. Snyderman and colleagues found decreased neutrophil chemotaxis in three of ten patients with atopic dermatitis.[22] Depressed chemotaxis was not related to severity of the skin disease or the presence of infection.

Impaired chemotaxis could predispose patients to severe infection. Experimental evidence suggests that delayed influx of leukocytes for only a few hours increases the severity of bacterial infections.[14] However, it is also possible that infection might impair chemotactic responsiveness among certain atopic patients. The improvement of chemotactic activity with remission of dermatitis observed by Rogge and Hanifin[4] and Fontan et al[6] was accompanied also by resolution of infection.

Most patients reported to have decreased neutrophil chemotaxis and atopic dermatitis have recurrent infections.[1-13] In order to determine if dermatitis alone could decrease leukocyte motility, we studied 13 patients with atopic dermatitis but no infection. We found normal chemotaxis in all patients. These results suggest that atopic dermatitis by itself may not affect neutrophil mobility.

Our patients had extensive but less severe dermatitis than that of most patients described by others.[4,5,22] In order to clarify further the relationship of neutrophil chemotaxis to dermatitis and infection, patients with severe, uncontrolled, atopic dermatitis but no infection should be studied. In addition, longitudinal studies of individual patients throughout periods of infection and exacerbations and remissions of dermatitis should also be performed.

William Lindroos and Casann E. Ray provided technical assistance.

References

1. Buckley RH, Wray BB, Belmaker EZ: Extreme hyperimmunoglobulinemia E and undue susceptibility to infection. *Pediatrics* 49:59-70, 1972.
2. Hill HR, Quie PG: Raised serum IgE levels and defective neutrophil chemotaxis in three children with eczema and recurrent bacterial infections. *Lancet* 1:183-187, 1974.
3. Dahl MV, Greene WH Jr, Quie PG: Infection, dermatitis, increased IgE, and impaired neutrophil chemotaxis: A possible relationship. *Arch Dermatol* 112:1387-1390, 1976.
4. Rogge JL, Hanifin JM: Immunodeficiencies in severe atopic dermatitis. *Arch Dermatol* 112:1391-1396, 1976.
5. Hanifin JM, Rogge JL: The character of staphylococcal infections in patients with atopic dermatitis. *Arch Dermatol* 113:1383-1386, 1977.
6. Fontan G, Lorente F, Garcia-Rodriguez MC, et al: Defective neutrophil chemotaxis and hyperimmunoglobulinemia E: A reversible defect? *Acta Pediatr Scand* 65:509-511, 1976.
7. Blum R, Geller G, Fish LA: Recurrent severe staphylococcal infections, eczematoid rash, extreme elevations of IgE, eosinophilia, and divergent chemotactic responses in two generations. *J Pediatr* 90:607-609, 1977.
8. Jacobs JC, Norman ME: A familial defect of neutrophil chemotaxis with asthma, eczema, and recurrent skin infections. *Pediatr Res* 11:732-736, 1977.
9. Van Scoy RE, Hill HR, Ritts RE, et al: Familial neutrophil chemotaxis defect, recurrent bacterial infections, mucocutaneous candidiasis, and hyperimmunoglobulinemia E. *Ann Int Med* 82:766-771, 1975.
10. Hill HR, Ochs HD, Quie PG, et al: Defect in neutrophil granulocyte chemotaxis in Job's syndrome of recurrent "cold" staphylococcal abscesses. *Lancet* 2:617-619, 1974.
11. Paslin D, Norman ME: Atopic dermatitis and impaired neutrophil chemotaxis in Job's syndrome. *Arch Dermatol* 113:801-805, 1977.
12. Hill HR, Quie PG: Defective neutrophil chemotaxis associated with hyperimmunoglobulinemia E, in Bellanti JA, Dayton DH (eds): *The Phagocytic Cell in Host Resistance*. New York, Raven Press, 1975.
13. Dahl MV: Dermatologic manifestations of immunodeficiency diseases. *Prog Dermatol* 10:9-12, 1976.
14. Miles AA, Miles EM, Burke J: The value and duration of defense reactions of the skin to the primary lodgement of bacteria. *Br J Exp Pathol* 38:79-96, 1957.
15. Hanifin JM, Lobitz WC: Newer concepts of atopic dermatitis. *Arch Dermatol* 113:663-670, 1977.
16. Boyum A: Isolation of mononuclear cells and granulocytes from human blood. *Scand J Clin Lab Invest* 21(suppl 97):77-89, 1968.
17. Nelken D, Gilboa-Garber N, Gurevitch J: A method for the simultaneous separation of human thrombocytes and leukocytes. *J Clin Pathol* 13:266, 1960.
18. Boyden S: The chemotactic effect of mixtures of antibody and antigens on polymorphonuclear leukocytes. *J Exp Med* 115:453-466, 1962.
19. Cates KL, Ray CE, Quie PG: Modified Boyden chamber method of measuring polymorphonuclear leukocyte chemotaxis, in Gallin JI, Quie PG (eds): *Leukocyte Chemotaxis*. New York, Raven Press, 1978.
20. Nelson RD, Quie PG, Simmons RL: Chemotaxis under agarose: A new and simple method for measuring chemotaxis and spontaneous migration of human polymorphonuclear leukocytes and monocytes. *J Immunol* 115:1650-1656, 1975.
21. Nelson RD, McCormack RT, Simmons RL, et al: Chemotaxis under agarose: Identification of several factors which influence spontaneous migration and chemotaxis of human leukocytes under agarose. *J Lab Clin Med*, to be published.
22. Snyderman R, Rogers E, Buckley RH: Abnormalities of leukotaxis in atopic dermatitis. *J Allergy Clin Immunol* 60:121-126, 1977.

Phototoxicity to a Sunscreen Ingredient

Padimate A

Kays H. Kaidbey, MD, Albert M. Kligman, MD, PhD

• Para-aminobenzoic acid and certain of its esters are widely used in sunscreens. We found that one of these, amyl paradimethylaminobenzoate (padimate A) was capable of provoking phototoxic reactions. With ultraviolet A (UV-A) dosages of about 30 joules/sq cm, a reaction grossly resembling sunburn developed in most subjects. The dominant histological feature was vacuolar degeneration of the epidermis without sunburn cells.

Proprietary sunscreens containing padimate A were also shown to produce a similar reaction.

Our explanation for the paradox of a sunscreen that promotes "sunburn" is that, as affected users have concluded, the product was ineffective. The similarity between sunburn and a phototoxic response has delayed recognition of this adverse effect until now.

(*Arch Dermatol* 114:547-549, 1978)

Agents that are capable of provoking phototoxic reactions have become increasingly common in the environment. They have been found in a variety of topical products to which exposure is often frequent and long, viz, cosmetics, soaps, toiletries, and drugs.[1,2] An adequate method for laboratory screening would probably have excluded phototoxic substances for topical formulations before their introduction into commerce. We have recently examined a new human assay that overcomes a serious limitation of previously described techniques, including one from our own laboratory,[3] viz, lack of sensitivity. Some known photosensitizers were not detected (K. H. Kaidbey, MD, and A. M. Kligman, MD, PhD, unpublished observations, 1976).

It was important to show that the new procedure possessed specificity as well as sensitivity; hence we tested a variety of familiar products that we felt certain were nonphotosensitizing. To our astonishment, we obtained phototoxic responses to a popular proprietary sunscreen. Since it was scarcely believable that a product designed to prevent sunburn could produce a phototoxic reaction, we rigorously examined alternatives that might explain the unexpected finding.

After extensive study, we established to our satisfaction that padimate A (Escalol 506) was indeed genuinely capable of producing a phototoxic reaction.

Accepted for publication Oct 26, 1977.

From the Department of Dermatology, Duhring Laboratories, University of Pennsylvania, Philadelphia.

Reprint requests to Department of Dermatology, Duhring Laboratories, Suite 203, 3500 Market St, Philadelphia, PA 19104 (Dr Kaidbey).

MATERIALS AND METHODS

Subjects

The subjects were healthy white college students between the ages of 18 and 25 years. The untanned midportion of the back was used for testing. Informed consent was obtained.

Light Source

Long ultraviolet (UV) radiation (UV-A) was obtained from a 150 watt xenon solar simulator with the Schott WG 345 to eliminate erythematous radiation. The output from this source falls sharply in the region between 360 nm and 400 nm because of filtration through a colored filter (Corning 9863), which absorbs UV-A as well as visible light.[4] In order to intensify the UV-A and visible light components, the colored filter was removed. Intensity measurements at skin level were made by a calibrated thermopile (Eppley). The total flux was 118 mW/sq cm; UV-A irradiance, 36 mW/sq cm; visible light, 31 mW/sq cm; infrared, 51 mW/sq cm.

Test Agents

Para-aminobenzoic Acid and Its Esters.—The following were obtained from a commercial source: para-aminobenzoic acid (PABA), glyceryl para-aminobenzoate (Escalol 106), padimate A (Escalol 506), and padimate O (octyl dimethylPABA [Escalol 507]). These were dissolved in 95% ethanol.

Isomers of Amyl Dimethylaminobenzoate.—Two isomeric forms were obtained from a commercial source: amyl orthodimethylaminobenzoate (O-506) and amyl paradimethylaminobenzoate (padimate A). These materials were alleged to be pure and were dissolved in 95% ethanol.

Proprietary Sunscreens.—These were Pre-Sun (PABA), Bain de Soleil (padimate A), Block Out (padimate A), Sea-and-Ski suntan lotion (glyceryl para-aminobenzoate), Sundown (padimate O), and Uval (sulisobenzone). Additionally we tested "old" and "new" Eclipse; the former contains padimate A and the latter, padimate O.

Procedure

Twenty microliters of the test agents were delivered by micropipettes to 2-cm squares of skin outlined by white adhesive tape; this provided a dosage of 5 μl/sq cm. The sites were covered by square patches of nonwoven cotton cloth (Webril) and fastened to the skin by overlapping strips of clear occlusive tape (Blenderm). Six hours later, the sites were uncovered and irradiated with UV-A and visible light. Control areas consisted of unirradiated, drug-treated sites and irradiated vehicle-treated sites. Responses were evaluated 24 hours later.

Action Spectrum

To the backs of five subjects, a dosage of 5 μl/sq cm of 5% padimate A in 95% ethanol was applied. After occlusion for six hours, one site was exposed for 14 minutes to UV-A and visible light and the second to visible light only by the use of the Schott GG 495 filter, which cuts off all UV radiation. Control sites received radiation without drug pretreatment. These studies were repeated with the ortho-isomer of amyl dimethylaminobenzoate in another five subjects, except that the exposure times were halved (seven minutes).

Histopathology

Three 4-mm punch biopsy specimens were secured from each of three subjects. These were obtained 24 hours after 14 minutes of irradiation to sites that were treated with 5% ethanolic solutions of padimate A and padimate O and ethanol alone.

RESULTS

PABA and Its Esters.—There were no abnormal responses except in sites treated with padimate A (Table 1). The reaction resembled sunburn in that it showed modest to intense erythema and slight edema in 12 of 17 subjects 24 hours after exposure to 14 minutes of irradiation (30 joules/sq

Table 1.—Topical Phototoxicity of Para-aminobenzoic Acid and Its Esters*

Test Agent, 5% in Ethanol	No. of Positive Responders	No. of Subjects Tested
PABA	0	15
Glyceryl ester of PABA	0	14
Padimate A	12	17
Padimate O	0	12

*Exposure time was 14 minutes (30 joules/sq cm of UV-A). PABA indicates para-aminobenzoic acid.

Table 2.—Comparative Phototoxicity of Ortho- and Para-isomers of Amyl Dimethylaminobenzoate*

Test Agent, 5% in Ethanol	No. of Positive Responders
Ortho-isomer	10/10
Para-isomer, padimate A	2/10

*Exposure time was seven minutes (15 joules/sq cm of UV-A). Ratios represent number of positive responders over the number of subjects tested.

Table 3.—Phototoxicity of Proprietary Sunscreens*

Sunscreen	No. of Positive Responders	No. of Subjects Tested
PreSun, PABA	0	10
Bain de Soleil, padimate A	9	13
Sea-and-Ski suntan lotion, glyceryl ester of PABA	0	11
Block Out, padimate A	4	9
Sundown, padimate O	0	10
"Old" Eclipse, glyceryl ester of PABA and padimate A	6	10
"New" Eclipse, glyceryl ester of PABA and padimate O	0	8
Uval, sulisobenzone	0	10

*Exposure time was 14 minutes (30 joules/sq cm of UV-A). PABA indicates para-aminobenzoic acid.

Phototoxicity reaction to padimate A showing pronounced vacuolar degeneration of basal cells and intracellular edema of keratinocytes (hematoxylin-eosin, original magnification ×250).

cm of UV-A). The inflammatory response peaked at 24 hours and faded during the next few days, leaving some hyperpigmentation. Irradiated control sites showed only minimal pigmentation.

Comparison of Para- and Ortho-Isomers of Amyl Dimethylaminobenzoate.—The ortho-isomer of amyl dimethylaminobenzoate was a far more potent photosensitizer (Table 2). Intense, deep erythema and edema were present in each of the ten subjects 24 hours after seven minutes of irradiation (15 joules/sq cm of UV-A). In addition, mild erythema and a flare appeared immediately after exposure and faded in 20 to 30 minutes. Four subjects also complained of moderate stinging. These immediate reactions were not accompanied by wheals. By contrast, only two of these ten subjects gave a phototoxic reaction to the para derivative after seven minutes of irradiation. In each case the reactions were much milder and consisted only of minimal erythema. None were preceded by an immediate response. The irradiated control sites showed no phototoxic reaction.

Proprietary Sunscreens.—Three proprietary sunscreens, Block Out, Bain de Soleil, and "old" Eclipse, produced phototoxic reactions (Table 3). These were the only products that contained padimate A. The reactions were similar to those obtained with padimate A itself. It is noteworthy that "new" Eclipse, which contains padimate O, did not produce a phototoxic reaction.

Histopathology

Prominent epidermal changes were present in specimens taken from sites that were treated with padimate A. These consisted of intracellular edema of the Malpighian cells with vacuolar degeneration of the basal cells (Figure). The outlines of cells in the upper epidermis were hazy and the cytoplasm showed homogeneous eosinophilic staining. The dermal reaction was slight; there was a mild perivascular mononuclear cell infiltrate, but the blood vessels seemed normal. Sections from sites treated with padimate O were normal and indistinguishable from the control sites.

Action Spectrum

The phototoxic response to both isomers of amyl dimethylaminobenzoate was elicited only by radiation containing both UV-A and visible light. No reactions occurred with visible light alone.

COMMENT

Para-aminobenzoic acid and its esters have gained prominence in the marketplace as chemical sunscreens. Despite extensive use, side effects have been few. There are several reports of allergic contact dermatitis to PABA and its glyceryl ester.[5] It has also been claimed that glyceryl para-aminobenzoate is capable of inducing photoallergic reactions.[6,7] A transient but rather severe stinging occurs on the face of some persons after applying preparations containing padimate A, especially on sweating skin.[8,9] To this comparatively unimportant subjective side reaction, we must now bring forward the information that this substance can also produce phototoxic reactions. We hasten to add that padimate A is a weak photosensitizer when compared with potent chemicals such as methoxsalen and coal tar.

Were this not so, this side effect would have come to light much earlier. Tanenbaum et al, for example, found that the mean minimum phototoxic dosage for 5% crude coal tar was 7.8 joules/sq cm.[10] Because relatively large dosages of UV-A (30 joules/sq cm) were necessary to elicit reactions, it could be argued that our findings are purely academic and have no importance in the real world. However, one could easily sustain such a dosage in an afternoon of pleasure under the sun. The UV-A component of sunlight at noon in midsummer in Boston ranges from 2.3 to 4.7 mW/sq cm (about 8 to 16 joules/sq cm in one hour).[11] After three hours, a sunbather could be exposed to 24 to 48 joules/sq cm of UV-A, which is easily within the experimental range. Then, too, we used occlusive applications that enhance penetration. However, swimmers often reapply sunscreens several times during the day. Swimming also hydrates the skin and this, too, results in increased absorption.

A question that inevitably comes to mind is why padimate A has not been identified previously as a photosensitizer? Millions of units of sunscreens containing it have been sold annually for years. The literature is completely silent regarding phototoxic reactions. This seems a colossal paradox. How can potentially harmful agents continue to be used on such a wide scale? Actually, we believe that phototoxicity to padimate A does occur but is not recognized. Patients are not trained diagnosticians and even the keenest professionals are likely to be fooled in this situation. Suspicion is the first step in recognition; in this case, everything conspires to submerge suspicion. After all, certain phototoxic reactions may be clinically indistinguishable from sunburn. The customary description of a phototoxic response is an exaggerated sunburn. Both ordinarily produce redness and edema that peak in 24 hours. Severer reactions can be accompanied by blistering but, in view of the weak phototoxicity of padimate A, it is doubtful that blistering would be frequent. Even so, sunburn itself produces blisters in sensitive persons.

Our explanation for the paradox of a sunscreen that actually induces "sunburn" is that persons who experience a phototoxic reaction will conclude that the preparation was simply ineffective. They will turn to another product that gives promise of greater effectiveness. Consumers are used to inflated claims and will quickly switch when they are disappointed. One must emphasize that only a small proportion of users would experience an adverse effect severe enough to seek medical attention. We have since encountered several persons whose story is consistent with a probable phototoxic reaction to a sunscreen containing padimate A.

Unknown to us, Emmett et al in 1975 investigated an eruption in workers who were engaged in the manufacture of UV-cured inks; these workers were exposed to various chemicals, including UV absorbers.[12] The latter comprised preparations containing mixed isomers of amyl dimethylaminobenzoate. Some were aware that their dermatitis was exacerbated by sunlight. Emmett et al conducted photopatch tests with the mixed isomers on affected workers and unaffected volunteers. In both groups, erythema and edema, which were associated with burning and stinging, developed during exposure to 25 to 35 minutes of noon summer sunlight and were followed a few hours later by erythema that persisted for two to five days. In addition, a phototoxic reaction also developed in one of the four tested volunteers to purified padimate A. Prior application of a 10% sulisobenzone sunscreen (broad spectrum, absorbing UV-A) completely suppressed the phototoxic response. Para-aminobenzoic acid, a UV-B absorber, provided only partial protection. However, with the same exposure, these investigators failed to elicit phototoxicity to a 5% concentration of padimate A.

Forbes et al[13] exposed hairless mice to UV-A from fluorescent blacklights after the animals were pretreated with the ortho- and para-isomers of amyl dimethylaminobenzoate. They found the ortho-isomer to be a strong photosensitizer, but they did not obtain abnormal responses with the para-isomer.

As is the case with the great majority of photosensitizing chemicals, the action spectrum of padimate A lies in the UV-A region. Like other PABA esters, padimate A has maximal absorption in the UV-B range, although some absorption does occur within the 320- to 340-nm range. Furthermore, in the living tissue, the absorption curve of the drug may be altered as a result of metabolic degradation or the formation of complexes with tissue constituents.

Histologically, the damage was primarily in the epidermis and consisted of vacuolar degeneration of keratinocytes. A similar type of dominantly epidermal injury occurs with other well-known photosensitizers, such as methoxsalen and coal tar.[14,15] The severe smarting and whealing that develop immediately after UV-A exposure of tar-treated skin are not features of padimate A phototoxicity, although erythema developed with the ortho-isomer.

Our findings underscore the importance of testing topical materials for phototoxicity. Sensitive laboratory techniques are now at hand that should enable such appraisals to be made. Phototoxicity screening should become an integral part of the overall safety evaluation of new products.

Nonproprietary Names and Trademarks of Drugs

Padimate A—*Block Out, Escalol 506, Pabafilm.*

Padimate O—*Escalol 507.*

Sulisobenzone—*Cyasorb UN 284, Spectra-Sorb UV 284, Uval, Uvinul MS-40.*

References

1. Harber LC, Levine GM: Photosensitivity dermatitis from household products. *Gen Practitioner* 39:95-101, 1969.
2. Epstein JH: Adverse cutaneous reactions to the sun, in Malkinson FD, Pearson RW (eds): *The Yearbook of Dermatology 1971.* Chicago, Year Book Medical Publishers Inc, 1971, pp 5-43.
3. Kligman AM, Breit R: The identification of phototoxic drugs by human assay. *J Invest Dermatol* 51:90-99, 1968.
4. Berger DS: Specification and design of solar ultraviolet simulators. *J Invest Dermatol* 53:192-199, 1969.
5. Fisher AA: Sunscreen dermatitis due to glyceryl PABA: Significance of cross-reactions to this PABA ester. *Cutis* 18:495-500, 1976.
6. Satulsky EM: Photosensitization induced by monoglycerol paraaminobenzoate: A case report. *Arch Dermatol* 62:711-713, 1950.
7. Goldman GC, Epstein E Jr: Contact photosensitivity dermatitis from sun-protective agent. *Arch Dermatol* 100:447-449, 1969.
8. Katz SI: Relative effectiveness of selected sunscreens. *Arch Dermatol* 101:466-468, 1970.
9. Parrish JA, Pathak MA, Fitzpatrick TB: Facial irritation due to sunscreen products. *Arch Dermatol* 111:525, 1975.
10. Tanenbaum L, Parrish JA, Pathak MA, et al: Tar phototoxicity and phototherapy for psoriasis. *Arch Dermatol* 111:467-470, 1975.
11. Parrish JA, White HAD, Kingsbury T, et al: Photochemotherapy of psoriasis using methoxsalen and sunlight: A controlled study. *Arch Dermatol,* 113:1529-1532, 1977.
12. Emmett EA, Taphorn BR, Kominsky JR: Phototoxicity occurring during the manufacture of ultraviolet-cured ink. *Arch Dermatol* 113:770-775, 1977.
13. Forbes PD, Davies RE, Urbach F: Photobiologic effects of two isomeric amyl dimethylaminobenzoates. Presented at the Fifth Annual Meeting of the American Society for Photobiology, May 1977.
14. Kaidbey KH, Kligman AM: Further studies of photoaugmentation in humans: Phototoxic reactions. *J Invest Dermatol* 65:472-475, 1975.
15. Kaidbey KH, Kligman AM: Clinical and histological study of coal tar phototoxicity in humans. *Arch Dermatol* 113:592-595, 1977.

Migraine and Systemic Scleroderma

Norman C. Goldberg, MD; Scott C. Duncan, MD; R. K. Winkelmann, MD, PhD

• Scleroderma with typical migraine headaches occurred in 16 well-documented cases observed over a 25-year period. Although the number of cases is within the expected range of coincidence of both diseases, in 13 of the 16 patients the scleroderma developed after 15 years or more of therapy with ergot or methysergide preparations. Eleven of the 13 patients had Raynaud's vasospastic phenomenon as part of their systemic scleroderma. The vascular pathology of scleroderma, Raynaud's phenomenon, and ergotism is similar enough to suggest caution in the administration of these drugs to patients with migraine and extra caution in observing for signs of Raynaud's phenomenon or early vascular scleroderma.

(*Arch Dermatol* 114:550-551, 1978)

Migraine is a frequent general symptom, occurring in 5% to 10% of the population.[1] Thus, it is not surprising to find an occasional patient who has both systemic scleroderma and migraine. To date, none of the large reviews or monographs on scleroderma has emphasized the presence of migraine symptoms, and the literature on headaches and migraine problems has only recently, in case report form, begun to question a possible coincidence with connective tissue disease. We have recently become impressed with the simultaneous occurrence of these two vasospastic syndromes, ie, Raynaud's phenomenon-vascular scleroderma and migraine, and we wish to report on the frequency and nature of their occurrence together. It seems that migraine occurs early in life and that scleroderma may follow after years of ergot therapy, a relationship that seems to deserve emphasis.

METHOD

A retrospective survey was made of Mayo Clinic patients seen between the years 1950 and 1975 who had diagnoses of both scleroderma and migraine headaches. During this period, more than 22,000 patients seen at the Mayo Clinic had the diagnosis of migraine headache, and 2,700 patients with the diagnosis of scleroderma were seen. Twenty-three patients were found with the diagnoses of both scleroderma and migraine headache. In 16 of these cases, both diagnoses were well documented. The diagnosis of migraine was limited to patients with characteristic severe, episodic headaches associated with visual or neurosensory phenomena and diagnosed as migraine headache by consultants in neurology at the Mayo Clinic. Scleroderma was described and diagnosed by consultants in dermatology at the Mayo Clinic. The seven other cases were discarded from this series only because of lack of complete documentation. This coincidence is not outside the range expected by chance. However, in a retrospective study such numbers are conservative.

Accepted for publication Sept 20, 1977.

From the Mayo Clinic and Mayo Foundation, Rochester, Minn.

Reprint requests to Section of Publications, Mayo Clinic, 200 First St SW, Rochester, MN 55901 (Dr Goldberg).

RESULTS

Fifteen of the 16 patients with both scleroderma and migraine headaches were female. Thirteen of the 16 patients were diagnosed as having stage I or II vascular scleroderma, two had a localized type, and one patient had a more advanced systemic form of the disease (stage III, Winkelmann staging procedure[2]). It is also interesting that the only male in the series is the only patient with a more severe form of scleroderma, which included pleural and myocardial involvement. Nine of the 16 patients had ocular signs or symptoms (for example, blurred vision, diplopia, or "light flashes") as part of the migraine prodrome (Table).

In all of these patients, definite histories of long-term treatment with multiple analgesics and ergot derivatives or methysergide drugs or both were noted. In none of the cases did the diagnosis of scleroderma precede the diagnosis of migraine; on the contrary, we found that in 13 of the 16 patients, the onset of migraine headaches preceded the onset of scleroderma by 15 years or more. Two of the three patients whose migraine symptoms did not substantially antedate the onset of scleroderma were the two patients in the series with the localized form of scleroderma. Interestingly, one of these patients had a localized linear scleroderma of the right side of the scalp that was associated with the onset of recurrent, right-sided migraine headaches.

Eleven of the 16 patients had Raynaud's phenomenon of the hands or feet or both as a presenting symptom of the scleroderma, and two other patients gave histories of cold intolerance of the hands and feet and acrocyanosis.

COMMENT

The patients studied were, in all but one case, women in whom migraine headaches had developed in early adult life and in whom, after a generally lengthy intervening period, Raynaud's phenomenon and stage I or II vascular scleroderma had also developed. These patients shared the common factor of use of ergot preparation or methysergide. It has long been known that ergot preparations can induce severe vasospasm and gangrene of arteries and arterioles.[3,4] Ergot appears to have a vasoconstrictor action on the vessel wall. Roentgenographically, this is seen as multiarterial occlusions with small, tortuous collateral vessels.[5] As initially shown by Yater and Cahill,[5] extensive intimal thickening and folding of small arteries, as well as thrombus development, are early histopathological characteristics in ergotism and must contribute to the ischemic effect induced by the vasospasm. A recent report showed severe vasospasm and gangrene occurring in a patient with Raynaud's phenomenon who was inadvertently treated with ergot.[6]

Methysergide has also been associated with vasospastic symptoms in approximately 7% of the patients to whom it has been administered. This effect has been shown with small doses and its cause is unknown.[3] The histopathological changes that develop with the toxic effects of methysergide have not been studied, but it is recognized that retroperitoneal and other fibroses can be caused by this drug.

The vasospastic and vasodilatory phases of Raynaud's phenomenon resemble the two vasoactive phases of migraine. It seems that both phenomena could occur because of vascular hyperreactivity to a mediator such as serotonin or prostaglandin or because of hyperactivity of the vessel receptors. Certain associated clinical events tend to vessel receptors. Certain associated clinical events tend to indicate that serotonin receptor sensitivity may be important in vascular scleroderma. The isolated vascular smooth muscle from subcutaneous arterioles can show a hyperresponsiveness to serotonin,[7] and skin sensitivity to serotonin has been reported in scleroderma.[8] The intra-arterial injection of serotonin mimics the vascular response in Raynaud's phenomenon.[9] Sclerosis of the skin occurs in carcinoid syndrome with its elevated serotonin levels.[10] Carcinoma of the lung is the most frequent cancer found with scleroderma and it is associated with serotonemia.[11-13]

Patients With Concurrent Migraine and Scleroderma

Patient/Age, yr/Sex	Migraine: Age at Onset, yr	Migraine: Ocular Signs	Raynaud's Phenomenon Age at Onset, yr	Scleroderma: Age at Onset, yr	Scleroderma: Stage	Associated Symptoms
Systemic Scleroderma						
1/51/M	14	+	46	46	III	Pleural effusion, myocardial disease
2/71/F	11	+	Acrocyanosis	69	I	...
3/70/F	30	+	51	51	I	Sjögren's syndrome
4/69/F	48	–	65	65	I	...
5/52/F	27	–	51	51	I	...
6/52/F	20	+	44	44	I	...
7/35/F	34	–	34	34	I	...
8/53/F	10	+	Acrocyanosis	53	I	...
9/60/F	32	–	54	54	II	Benign gammopathy
10/29/F	15	–	...	29	I	Schizophrenia, died at age 29
11/52/F	...	–	51	51	I	...
12/48/F	23	+	48	48	I	...
13/69/F	20	+	None	68	II	...
14/44/F	10	+	37	42	II	...
Localized Scleroderma						
15/37/F	35	–	None	35	En coup de sabre	...
16/46/F	10	+	44	45	Linear scleroderma	...

Scleroderma is a disease complex of vascular changes, fibrosis, and inflammation that involves the skin and visceral organs to varying degrees. The most common form of scleroderma is that of cutaneous and systemic vascular fibrosis. Raynaud's phenomenon is a major indicator of this vascular fibrosis and occurs in 80% to 90% of the patients with scleroderma.[14] There is a high female predominance in this disease. The primary vascular lesion is a noninflammatory fibromucinous endothelial proliferation in the small vessels of the skin and viscera seen characteristically in the small arterioles.[2] Roentgenographically, widespread occlusive and stenotic arteriolar lesions with collateral development are typical of lesions in scleroderma.[15] It is not known whether the vascular change is a primary cause of the disease process, but it is thought that the abnormalities of the vessel wall along with sympathetic nervous dysfunction produce Raynaud's phenomenon. In addition, several studies have demonstrated occlusion in small and medium-sized arteries in patients with severe Raynaud's phenomenon and with scleroderma.[16,17]

Thus, the histological changes seen in the vessels of patients with scleroderma and ergotism are very similar, and similar changes are thought to have an important role in the pathogenesis of Raynaud's phenomenon. In our patients, the use of ergot preparations or methysergide was followed by the occurrence of Raynaud's phenomenon and scleroderma. Previous work has shown a significant association between localized scleroderma and migraine headache (46 of 223 cases),[18] as well as concurrence of mesenchymal scleroderma (mixed connective tissue disease) and migraine headache.[19,20] Whether the use of ergot preparations or methysergide can be etiologically related to the vascular sclerosis of Raynaud's phenomenon in these patients is open to conjecture. However, with the evidence presented in this communication, we suggest that a prospective study of patients given these drugs for migraine headaches should be initiated. In addition, we believe that the present evidence is substantial enough that patients for whom administration of these drugs is considered should be closely questioned, examined, and followed up for evidence of scleroderma and of vasospastic disease. Indeed, a history of these diseases may prove to be a contraindication to the use of the drugs, and these drugs may prove to be causally related in the actual occurrence of Raynaud's phenomenon and scleroderma in susceptible individuals.

References

1. Gilroy J, Meyer JS: *Medical Neurology*, ed 2. New York, Macmillan Publishing Co, 1975, p 304.
2. Winkelmann RK: Pathogenesis and staging of scleroderma. *Acta Derm Venereol (Stockh)* 56:83-92, 1976.
3. Coffman JD, Davies WT: Vasospastic diseases: A review. *Prog Cardiovasc Dis* 18:123-146, 1975.
4. Fatherree TJ, Hines EA Jr: Symmetrical gangrene of the extremities associated with purpura: Report of a case in which ergotism was suspected. *Am Heart J* 12:235-240, 1936.
5. Yater WM, Cahill JA: Bilateral gangrene of feet due to ergotamine tartrate used for prurit of jaundice: Report of a case studied arteri graphically and pathologically. *JAMA* 106:162 1631, 1936.
6. Robb LG: Severe vasospasm following erg administration. *West J Med* 123:231-235, 1975.
7. Winkelmann RK, Goldyne ME, Linsche RL: Hypersensitivity of scleroderma cutaneo vascular smooth muscle to 5-hydroxytryptamin *Br J Dermatol* 95:51-56, 1976.
8. Scherbel AL, Harrison JW: Response serotonin and its antagonists in patients wi rheumatoid arthritis and related diseases. *Ang ology* 10:29-33, 1959.
9. Halpern A, Kuhn PH, Shaftel HE, et a Raynaud's disease, Raynaud's phenomenon, ar serotonin. *Angiology* 11:151-167, 1960.
10. Fries JF, Lindgren JA, Bull JM: Sclerode ma-like lesions and the carcinoid syndrome. *Ar Intern Med* 131:550-553, 1973.
11. Monti M: La sclérose systémique progre sive (sclérodermie) associée au cancer pulmo aire: Présentation de quatre nouveaux ca *Schweiz Med Wochenschr* 103:1023-1030, 1973.
12. Bulygina AV: The serotonin content i blood of patients with pulmonary cancer. *Vop Onkol* 19(8):42-44, 1973.
13. Horai T, Nishihara H, Tateishi R, et a Oat-cell carcinoma of the lung simultaneousl producing ACTH and serotonin. *J Clin End crinol Metab* 37:212-219, 1973.
14. Tuffanelli DL, Winkelmann RK: Systemi scleroderma: A clinical study of 727 cases. *Arc Dermatol* 84:359-371, 1961.
15. Dabich L, Bookstein JJ, Zweifler A, et a Digital arteries in patients with scleroderm Arteriographic and plethysmographic study *Arch Intern Med* 130:708-714, 1972.
16. Lewis T: The pathological changes in th arteries supplying the fingers in warm-hande people and in cases of so-called Raynaud' disease. *Clin Sci* 3:287-319, 1938.
17. Norton WL, Nardo JM: Vascular disease i progressive systemic sclerosis (scleroderma) *Ann Intern Med* 73:317-324, 1970.
18. Christianson HB, Dorsey CS, O'Leary PA et al: Localized scleroderma: A clinical study o 235 cases. *Arch Dermatol* 74:629-639, 1956.
19. Prystowsky SD, Tuffanelli DL: Epiderma nuclear IgG deposition: Correlation of clinica features and laboratory findings in 32 patients abstracted. *J Invest Dermatol* 67:562, 1976.
20. Atkinson RR, Appenzeller O: Connectiv tissue disease and migraine, abstracted. *Head ache* 16:79, 1976.

Fetal and Maternal Risk Factors in Herpes Gestationis

Thomas J. Lawley, MD; Georg Stingl, MD; Stephen I. Katz, MD, PhD

• Forty-one cases of immunologically proved herpes gestationis (HG) are reviewed and there appears to be an increased risk of fetal morbidity and mortality. The onset of HG is most frequent in the second and third trimesters of pregnancy although postpartum onset or exacerbation is common. The presence of high-titer, antibasement membrane zone antibody seems to correlate with a severe clinical disease. Systemic treatment with corticosteroids is frequently necessary in order to control maternal signs and symptoms of HG.

(*Arch Dermatol* 114:552-555, 1978)

Herpes gestationis (HG) is an uncommon blistering disease of pregnancy and the puerperium.[1] Classically, it presents as an intensely pruritic erythematous vesiculobullous eruption that is often widespread and recurs in subsequent pregnancies. Though the clinical picture, histopathological findings, and the course of the disease may suggest the diagnosis of HG, it is sometimes difficult to differentiate this entity from dermatitis herpetiformis, erythema multiforme, bullous drug eruptions, bullous pemphigoid, and other dermatoses of pregnancy.[2] The application of immunological techniques as additional diagnostic criteria has proved to be very useful in precisely delineating HG and separating it from other bullous diseases.[3-5] Immunofluorescent (IF) investigations of perilesional and of normal appearing skin reveal the presence of the third component of complement (C3), with or without IgG, in a linear band-like distribution along the basement membrane zone (BMZ). A circulating factor in the serum of these patients, termed the herpes gestationis factor (HGF), can deposit C3 in the same region, as shown by an in vitro complement binding technique, using normal human skin as a substrate. The HGF has recently been shown to be an IgG.[4,5]

The question of whether HG is associated with significant maternal and fetal morbidity has been addressed by Kolodny.[1] His review of the literature indicated that maternal and fetal morbidity was not increased. However, his study was performed prior to the delineation of immunologic abnormalities in this disease, hence the diagnosis in his cases was based only on clinical and histopathological criteria and was therefore not definitive. We have reviewed our own cases of immunologically proved HG, as well as those immunologically verified cases in the literature and a number of other immunologically proved cases available to us, in an attempt to define the spectrum of this disease, with particular regard to fetal and maternal risk factors.

Criteria for inclusion in this review consisted of a compatible clinical presentation occurring in pregnancy or immediately postpartum and the presence of C3 along the BMZ of perilesional skin as demonstrated by immunofluorescence.

RESULTS

Forty-one cases have been reviewed. The essential clinical and IF findings are presented in Table 1. Direct IF studies of perilesional skin demonstrated the presence of C3 along the BMZ in all patients and the presence of IgG in 19 of 41 cases.

Other immunoreactants occasionally deposited along the BMZ included IgA, IgE, Clq, C4, C5, C9, properdin, and fibrinogen. Indirect IF revealed circulating antibasement membrane antibody of the IgG class in the sera of seven of 34 patients (five with an antibody titer of 1:40 or greater), while the HGF was found in 14 of 19 patients in whom it was sought.

Though the complete clinical details of mother and offspring were not available in all cases, the following statements concerning the course of disease in mother and offspring can be made:

Maternal Disease

The maternal age at the time of onset of HG ranged from 20 to 39 years and the onset of the skin eruption from the first month of gestation to the fifth day postpartum. In eight cases the disease started in the first

Accepted for publication Dec 14, 1977.

From the Dermatology Branch, National Cancer Institute, National Institutes of Health, Bethesda, Md.

Reprint requests to Bldg 10, Room 12N238, National Institutes of Health, Bethesda, MD 20014 (Dr Lawley).

Table 1.—Summary of Patient Data

Case/Age, yr	Source	Gravida/Para/Abortus	Onset of HG	Previous History	Delivery*	Child†/Sex	Immunofluorescence‡ Direct	Immunofluorescence‡ Indirect
1/33	Katz et al[5]	g2/p1/ab1	4th mo	Yes	Section	P/F	C3,Clq,C4,C5,P,B,G	G, HGF
2/37		g4/p4	2 days postpartum	...	N	H/F	C3,Clq,C4,P,B,G	HGF
3/28		g2/p2	5th mo	Yes	N	H/F	C3,C5,P,B,G	HGF
4/34		g2/p0/ab2	4th mo	Yes	Sp ab	...	C3,C5	HGF
5/27		g1/p1	9th mo	...	N	H/F	C3,G	...
6/34	Katz & Lawley	g3/p3	4th mo	...	N	H/F	C3	...
7/27		g2/p1/ab1	7th mo	...	Section	P/F	C3,P,G	G, HGF
8/39	Katz et al[6]	g8/p5/ab3	3rd mo	Yes	N	L/M	C3	HGF
9/26	Reid & Sams[7]	g4/p	7th mo	...	N	H/M	C3,C4,B	...
10/24	Bushkell et al[8]	g1/p0	6th mo	...	...	Stillborn	C3,Clq,P,G	G, HGF
11/29	Graulau et al§	g2/p2	1 day postpartum	...	N	L/F	C3,C4,C5,C8,C9,P	G, HGF
12/36	Schultz et al§	g1/p1	7th mo	...	N	H/F	C3,C4,P,G	G, HGF
13/35	Provost & Tomasi[3]	g2/p2	6th mo	...	N	H/M	C3	HGF
14/28	Maize§	g2/p2	4th mo	...	N	H/F	C3	...
15/20	Carruthers et al[9]	g1/p1	5th mo	...	N	H/M	C3,G,A	...
16/33		g9/p9	3rd mo	...	N	H/M	C3	HGF
17/33		g3/p3	3rd mo	Yes	N	H/M	C3	HGF
18/33		g3/p3	3rd mo	Yes	N	...	C3,G	HGF
19/24	Davis§	g4/p2/ab2	1 day postpartum	...	Section	H/F	C3,G	...
20/28		g5/p3/ab2	4th mo	...	Section	H/M	C3	...
21/27	Kark§	g2/p2	8th mo	...	N	H/F	C3,G	...
22/24		g1/p1	8th mo	...	Section	H/M	C3	...
23/29	Jablonska et al[10]	g6/p4/ab?	7th mo	...	N	P/macerated	C3,Clq,C4,C5,P,G	G
24/24		g1/p1	8th mo	...	N	H/...	C3,C4,C5,P	...
25/27		g1/p1	8th mo	...	N	P/...	C3,C5,P	...
26/34		g5/p4	5th mo	...	...	...	C3,C4	...
27/31		g6/p2/ab?	5th mo	...	N	H/...	C3,C4,C5,G	...
28/22	Jablonska et al[10,11]	g1/p1	5th mo	...	N	L/...	C3,C4,P	...
29/34	Kocsis et al[12]	g10/p2/ab8	6th mo	...	N	P/F	C3,G	...
30/22		g1/p1	5 days postpartum	...	N	H/F	C3,G	...
31/35		g4	3 days postpartum	...	N	H/F	C3,G,A,M	...
32/26		...	1 day postpartum	...	N	H/F	C3,G	...
33/26	Hönigsmann et al[13]	g1/p1	9th mo	...	N	H/M	C3,G	G
34/...	Pehamberger et al§	g5/p4/ab1	4th mo	...	N	H/M	C3,G	ND
35/23	Schöpf et al[14]	g2/p1/ab1	7th mo	...	N	P,L/F	C3,C5,C9	HGF
36/27	Michel§	g3/p2/ab1	4th mo	...	Section	P/F	C3	...
37/29		g4/p1/ab3	2nd mo	Yes	Section	P/M	C3	...
38/38	Martin, Goltz, & Dahl§	g8/p8	1st mo	Yes	N	H/M	C3	ND
39/31	Grammens, Mandel, & Dahl§	g3/p3	8th mo	...	N	H/M	C3	...
40/32	Kaczmarek & Uhlin§	g3/p3	3rd mo	Yes	Section	P/F	C3	...
41/37	Tabatai§	g5/p3/ab2	3rd mo	...	...	Stillborn	C3	ND

*Section indicates cesarean section; N, normal vaginal delivery, Sp ab, spontaneous abortion.
†P indicates premature; H, healthy full-term infant; L, infant with lesions of HG.
‡C indicates complement component; P, properdin; B, factor B; G,A,M,E, immunoglobulins.
§Written communication, 1977.

trimester (five of whom had a history of HG in a prior pregnancy), in 15 cases in the second trimester, in 12 cases in the third trimester, and in six patients the eruption began postpartum.

Gravida, Para, Abortus Status.—Ten patients were primiparas and 29 were multiparas. A definite history of at least one abortion was found in 12 of the 29 multiparas. Nine of 29 multiparas had a history of an eruption in a prior pregnancy that was compatible with HG. Three of these nine had terminated with spontaneous abortions.

Course of Maternal Disease.—Of 41 patients with HG, almost all had severe pruritus associated with their cutaneous eruption. Postpartum exacerbations of HG occurred in 17 cases, not including those six cases that began in the postpartum period. Five patients experienced recurrence of itching and lesions with their menstrual periods, including four of the 17 who had developed a postpartum flare. Three patients also suffered exacerbations when they took birth control pills, including two of the 17

Table 2.—Treatment of HG Antepartum

Mode	No. of Cases*	No. of Uncomplicated‡ Live Births
None	2†	1
Conservative	1	1
Topical corticosteroids	8	4
Systemic corticosteroids	23	12

*Seven cases could not be included because of postpartum onset or lack of information.
†Fetal outcome not reported.
‡Full-term infant delivered vaginally without skin lesions.

Table 3.—Patients With High Titer Anti-BMZ Antibody

Case	IIF: IgG*	Total Eosinophils/ cu mm	Treatment	Fetal Outcome
7	1:160	3,007	Prednisone 180 mg each day	Premature
10	1:320	13,500	Prednisone 80 mg each day	Stillborn
11	1:160	5,848	Prednisone 100 mg every other day, azathioprine 100 mg each day	Child with lesions
23	1:80	Not recorded	Topical corticosteroids	Stillborn
33	1:40	1,767	Prednisone 100 mg and azathioprine 150 mg each day	Normal

*IFF indicates indirect immunofluorescence.

who had experienced a postpartum flare.

There were 11 cases in which significant (> 570/cu mm or > 10%) peripheral blood eosinophilic leukocytosis was noted. However, complete blood cell counts were available only in 21 patients. This was accompanied in some cases by a leukocytosis resulting in total eosinophil counts of up to 13,500/cu mm.

Treatment.—Although the eruption was controlled by topical applications of corticosteroids alone in eight patients, it was the experience of most physicians that topical therapy was usually inadequate to control the disease.

Twenty-nine patients (23 antepartum, 6 postpartum) were treated systemically with corticosteroids ranging from 20 mg to 180 mg of prednisone per day (Table 2). In three of these cases, azathioprine was also used postpartum. In most cases the response to systemic corticosteroid administration (20 to 40 mg/day) was prompt, with symptomatic improvement within 48 hours followed rapidly by clinical signs of improvement. The five cases that had high titers of circulating anti-BMZ antibodies may represent an important subgroup (Table 3). Although one case is difficult to evaluate, four of them had very severe clinical manifestations of HG, requiring very high systemic doses of corticosteroids, with or without azathioprine, in order to control the eruption.

Fetal Complications.—Of 40 cases of HG, there were nine premature deliveries, three stillbirths, and one spontaneous abortion at 4½ months gestation. One of the nine premature deliveries resulted in a stillbirth. Of the 36 live births, four of the infants were born with lesions resembling HG. The skin of two was examined by immunofluorescence. One was found to have C3 along the BMZ and the other had C3, C4, and C5 in this area. Indirect IF with the sera of three of the infants showed that two had HGF and one of these had circulating anti-BMZ antibody of the IgG class.

COMMENT

Herpes gestationis is a rare disease and most medical centers have only a limited experience with it. We have had the opportunity to treat and observe seven cases and consult and study several others in the past few years, have sought to accumulate data on as many more immunologically proved cases as possible in an attempt to draw conclusions as to fetal and maternal risk as well as to the efficacy of various modes of therapy.

In this series 77% of patients were multiparas and 23% were primiparas at the time of diagnosis of HG. If one takes history into account, then 67% were multiparas and 33% were primiparas at the time of onset of the first episode of HG. The time of onset is variable, although it is much more common to begin in the second or third trimester than in the first. It is interesting that six (15%) of the cases began one to five days postpartum. In those patients who had a history compatible with HG and for whom complete information was available, six of seven had the onset earlier in subsequent pregnancies than in the first affected pregnancy.

A history of at least one abortion was present in at least 12 of the patients, although only three women had had a prior abortion associated with an eruption compatible with HG.

Although HG is well known to undergo "spontaneous" resolution after delivery, the immediate postpartum period may be a time of peril. Twenty-three of 38 (61%) patients had either the onset of disease (six patients) or underwent significant exacerbations (17 patients) shortly after delivery. Whether or not postpartum exacerbations can be abrogated by providing increased systemic treatment with corticosteroids at the time of and shortly after delivery is not clear. However, one of us (S.I.K.) has done this in two patients who had a history of postpartum exacerbations in their prior pregnancies, and they did not experience postpartum flares of their disease when the dosage was increased at the time of delivery. The cause of postpartum exacerbations is unknown, but this is a time of great physiologic flux and a number of other diseases are known to be particularly labile at this time. In addition, five patients (12%) had recurrence of HG associated with their menses. Three patients suffered exacerbations of HG associated with oral contraceptives, but the total number of patients who took oral contraceptives is unknown.

The severity of maternal disease may, to some extent, be correlated with the presence of high titers of anti-BMZ antibody and/or peripheral blood eosinophilic leukocytosis (Table 3). In the five patients in whom high titers of anti-BMZ antibody were detected, four needed high-dose systemic corticosteroid therapy, with azathioprine added postpartum in two. The fifth patient was treated only with topically applied corticosteroids, but treatment response was not reported and the fetus was macerated. Four of the five patients also had substantial peripheral blood eosinophilic leukocytosis.

There appears to be a considerable

incidence of fetal morbidity and mortality associated with HG. Information was available in 39 cases, and in 15 there were fetal complications. Death of the fetus occurred in four cases—three stillbirths and one spontaneous abortion at 4½ months gestation. Thus, the rate of stillbirths in these patients is 7.7%, which is higher than the 1.3% stillbirth rate for the general population.[15] However, the estimated incidence of spontaneous abortions occurring in all pregnancies is 10% to 15%[16]; therefore, in this series there is not an abnormally high rate.

Of 35 live births, eight infants (23%) were born prematurely. This is much higher than the 5% to 10% rate of premature deliveries that occurs in pregnancies in the general population.[17] Five of the premature infants were delivered by cesarean section, two because of premature rupture of membranes, one because of rupture of a marginal sinus of the placenta, one because of a history of three spontaneous abortions in the mother, and the last for unknown reasons. Four infants were also born with skin lesions compatible with HG; one of these was premature. Therefore, fetal morbidity or mortality occurred in 15 of 39 (38%) cases in which adequate information was available. This contrasts with the study of Kolodny in which he stated that the fetal prognosis is good in HG. However, definitive diagnosis of HG was not possible at the time of his review and, therefore, it may have included cases that were not truly HG.

Treatment modalities varied in this series of cases (Table 2). Most patients did not show significant clinical improvement with topical corticosteroid therapy. On the other hand, patients treated systemically with corticosteroids usually showed prompt clinical improvement, but many required therapy throughout pregnancy and into the postpartum period. However, the crucial question is how therapy affects maternal and fetal prognosis. In those cases in which information was available, there was no significant difference in the rate of uncomplicated live deliveries in the group of patients treated systemically with corticosteroids compared with the group treated topically with corticosteroids. However, it may be that those patients needing systemic therapy with corticosteroids represent a group that not only has more severe maternal disease but that the increased severity serves to place the fetus at greater risk. Therefore, the possibility exists that without systemic corticosteroid therapy, there might have been an even higher rate of fetal morbidity and mortality. Alternatively, it may be argued that systemic corticosteroid therapy in the pregnant woman may place the fetus at risk in and of itself. Pregnant animals treated with large doses of corticosteroids have an increased incidence of placental insufficiency, fetal death, and congenital malformations in their offspring.[18-20] Although the data in humans are not unequivocal, they clearly differ considerably from that found in animals. Warrell and Taylor,[21] in a study of pregnant women with severe asthma who were treated systemically with corticosteroids before conception and throughout their pregnancies, found an increased rate of stillbirths. Bongiovanni and McPadden,[22] in a review of the world literature, found 260 pregnancies in which pharmacologic doses of corticosteroid had been administered for various maternal diseases. They concluded that the "human fetus is rarely injured by maternal treatment with corticoids." Two other studies have similarly concluded that systemic corticosteroid therapy does not place the fetus at increased risk.[23,24]

In summary, HG appears to be a disease that carries with it not only significant maternal morbidity but also fetal morbidity and mortality. Therapy should be tailored to the individual case. The question as to whether therapy of maternal disease can abrogate the apparent inherent risk to the fetus is, at this time, unanswerable.

Ralph Sperrazza, MD, assisted with the preparation of the manuscript, and many physicians kindly provided detailed information about their patients.

Nonproprietary Name and Trademark of Drug

Azathioprine—*Imuran*.

References

1. Kolodny RC: Herpes gestationis. *Am J Obstet Gynecol* 104:39-45, 1969.
2. Hertz KC, Katz SI, Maize J, et al: Herpes gestationis: A clinicopathologic study. *Arch Dermatol* 112:1543-1548, 1976.
3. Provost TT, Tomasi TB: Evidence for complement activation via the alternate pathway in skin diseases. *J Clin Invest* 52:1779-1787, 1973.
4. Jordon RE, Heine KG, Tappeiner G, et al: The immunopathology of herpes gestationis: Immunofluorescence studies and characterization of "HG factor." *J Clin Invest* 57:1426-1433, 1976.
5. Katz SI, Hertz KC, Yaoita H: Herpes gestationis: Immunopathology and characterization of the HG factor. *J Clin Invest* 57:1434-1441, 1976.
6. Katz A, Minta JO, Toole JWP, et al: Immunopathologic study of herpes gestationis in mother and infant. *Arch Dermatol* 113:1069-1072, 1977.
7. Reid LH, Sams WM: Herpes gestationis. *Arch Dermatol* 112:882, 1976.
8. Bushkell LL, Jordon RE, Goltz RW: Herpes gestationis. *Arch Dermatol* 110:65-69, 1974.
9. Carruthers JA, Black MM, Ramnarain N: Immunopathological studies in herpes gestationis. *Br J Dermatol* 96:35-43, 1977.
10. Jablonska S, Chorzelski TP, Maciejowska E, et al: Immunologic phenomena in herpes gestationis, their pathogenic and diagnostic significance. *J Dermatol* 2:149-158, 1975.
11. Chorzelski TP, Jablonska S, Beutner EH, et al: Herpes gestationis with identical lesions in the newborn. *Arch Dermatol* 112:1129-1131, 1976.
12. Kocsis M, Eeg TL, Husby G, et al: Immunofluorescence studies in herpes gestationis. *Acta Derm Venereol* 55:25-29, 1975.
13. Hönigsmann H, Stingl G, Haubar K, et al: Herpes gestationis: Fine structural pattern of immunoglobulin deposits in the skin in vivo. *J Invest Dermatol* 66:389-392, 1976.
14. Schöpf E, Seelig HP, Clorius R, et al: Herpes gestationis: Immunopathologische Untersuchungen bei Mutter und Kind. *Hautarzt* 27:481-487, 1976.
15. Danforth DN (ed): *Obstetrics and Gynecology*, ed 3. Hagerstown, Md, Harper & Row, 1977, p 212.
16. Pritchard JA, MacDonald PC (eds): *Williams Obstetrics*, ed 15. New York, Appleton-Century-Crofts Inc, 1976, p 484.
17. Greenhill JP, Friedman EA: *Biological Principles and Modern Practice of Obstetrics*, ed 13. Philadelphia, WB Saunders Co, 1974, p 697.
18. Fraser FC, Kalter H, Walker BE, et al: The experimental production of cleft palate with cortisone and other hormones. *J Cell Comp Physiol* 43(suppl 1):237-259, 1954.
19. Fainstat T: Cortisone induced congenital cleft palate in rabbits. *Endocrinology* 55:502-508, 1954.
20. Blackburn WR, Kaplan HS, McKay DG: Morphologic changes in the developing rat placenta following prednisolone administration. *Am J Obstet Gynecol* 92:234-246, 1965.
21. Warrell DW, Taylor R: Outcome for the fetus of mother receiving prednisolone during pregnancy. *Lancet* 1:117-118, 1968.
22. Bongiovanni AM, McPadden AJ: Steroids during pregnancy and possible fetal consequences. *Fertil Steril* 2:181-186, 1960.
23. Williams DA: Asthma and pregnancy. *Acta Allergol* 22:311-323, 1967.
24. Schatz M, Patterson R, Zeitz S, et al: Corticosteroid therapy for the pregnant asthmatic patient. *JAMA* 233:804-807, 1975.

The Shulman Syndrome

Lt Comdr Stephen W. Shewmake, MC, USN; Capt D. A. Lopez, MC, USN; Comdr James C. McGlamory, MC, USN

• The Shulman syndrome is a symptom complex recently described in the rheumatology literature that is characterized by eosinophilia, hypergammaglobulinemia, and a diffuse scleroderma-like process of the extremities. The onset of illness has been associated with a period of unusual physical exertion. The condition seems to respond to corticosteroid therapy for systemic effect.

(*Arch Dermatol* 114:556-559, 1978)

In 1974 Shulman[1] described two male patients, 19 and 53 years old, with an unusual scleroderma-like symptom complex previously undescribed in the medical literature. These patients had eosinophilia, hypergammaglobulinemia, and pain and swelling of the extremities resulting from inflammation and diffuse thickening of the fascia between the subcutaneous tissue and underlying muscle. The involved extremities later assumed a scleroderma-like appearance with firm, taut skin tightly bound down to the underlying tissues. The hands and feet were spared in one patient. Neither patient demonstrated evidence of myositis, Raynaud's phenomenon, or the visceral manifestations of systemic sclerosis. In each case, unusual physical exertion antedated the onset of illness. Both patients had a rapid progression of their disease with the development of contractures of their knees and elbows. Steroid therapy induced clinical improvement and reversed the abnormal laboratory findings in both patients, including a full remission in one that lasted for five years.

This condition has since been expanded on and recognized by rheumatologists as a distinct entity.[2-6] This present article describes our experience with a patient who has the Shulman syndrome. To our knowledge, this represents the 20th reported case of this unusual symptom complex and the first described in the dermatological literature.

REPORT OF A CASE

A 36-year-old male naval officer was well until January 1975 when he noted the gradual development of scattered, firm, tender subcutaneous nodules with overlying hyperpigmentation on his right upper arm and on the anterior aspect of his right thigh (Fig 1). These lesions developed approximately six weeks after the patient had completed a four-month program of jogging and weight lifting. In August 1975, the patient was seen in the Dermatology Clinic, Naval Regional Medical Center, San Diego, where a biopsy of one of the lesions on the right thigh was interpreted as compatible with scleroderma.

In mid-September 1975, systemic symptoms consisting of continual malaise, generalized weakness, and a sensation of tightness in the muscles began to develop. These symptoms developed approximately two weeks after a camping trip to the mountains during which the patient hiked extensively. By October 1975, he was experiencing daily fevers with temperatures up to 38.1 C, shaking chills, and generalized myalgias with associated restriction of motion of his mouth, shoulders, wrists, and knees. An outpatient evaluation in November 1975 revealed the aforementioned physical findings and the following laboratory values: WBC count, 10,100/cu mm, with 32% eosinophils; ESR, 4 mm/hr; a positive tube latex fixation test for rheumatoid factor (titer, 1:80); and a negative antinuclear antibody (ANA) test. In early December 1975, two weeks before admission, considerable swelling of his lower legs and ankles accompanied by slight swelling of his arms developed.

The patient was admitted to the Naval Regional Medical Center, San Diego, on Dec 15, 1975, for further evaluation. Results of physical examination of the upper extremities on admission revealed sausage-like swelling of all ten fingers and tightening of the skin over the wrists, dorsa of the hands, and forearms. The lower extremities demonstrated moderate pitting edema of the skin from the ankles to the knees. On all of the edematous areas the skin appeared shiny, and there was tenderness to both palpation and compression of the skin and underlying musculature. Examination of the anterior aspect of the right thigh revealed several discrete and confluent, slightly tender subcutaneous nodules 2 to 4 cm in size (Fig 1). These were moderately indurated, and the overlying skin was slightly hyperpigmented. Opening the mouth and moving the shoulders, wrists, knees, and ankles were moderately limited. The patient was able to grasp objects but was unable to make a clenched fist with either hand. The remainder of the results of the physical examination was within normal limits with no evidence of telangiectasia, Raynaud's phenomenon, or calcium deposits.

FINDINGS

Histopathologic Findings

Three separate skin biopsy specimens, two from the right anterior thigh and one from the right calf, revealed nearly identical findings. The epidermis appeared to be essen-

Accepted for publication Nov 19, 1976.

From the Departments of Dermatology (Drs Shewmake and Lopez) and Internal Medicine (Dr McGlamory), and the Clinical Investigation Center, Naval Regional Medical Center, San Diego.

The opinions and assertions contained herein are those of the authors and are not to be construed as official or as reflecting the views of the Navy Department or the naval services at large.

Reprint requests to Department of Dermatology, Naval Regional Medical Center, San Diego, CA 92134 (Dr Shewmake).

tially within normal limits except for mild effacement of the rete ridges. Occasional follicular keratotic plugs were evident. The subepidermal papillary zone was moderately edematous. The cutaneous appendages appeared normal in the biopsy specimen taken in August 1975 but were less numerous and partially destroyed in the December 1975 specimen. The collagen in the upper two thirds of the dermis was normal except in areas surrounding blood vessels where it appeared looser and somewhat granular. Capillary endothelial proliferation with prominent stasis of RBCs was evident. Scattered areas of mild to moderate tissue hemorrhage were noted. There was a discrete focal perivascular inflammatory response, predominantly lymphohistiocytic in nature but also containing scattered plasma cells and eosinophils.

The inflammatory process was more prominent in the subcutaneous fat where it remained predominantly perivascular but also extended along the collagenous septa, adjacent panniculus, and fascial planes. Occasional vessels within the subcutaneous fat showed destruction of the vascular wall by the inflammatory process. No fibrinoid necrosis was noted. Eosinophils and hemorrhage were more common here than in the dermis. There was a striking widening of the collagenous septa surrounding the fat lobules, and the lower third of the dermis assumed a thickened, band-like configuration (Fig 2). In both areas the collagen had a ground-glass appearance, and the individual collagen fibers were broadened (Fig 3). The ground substance was basophilic and granular with a mucinous-like appearance. This was more prominent within and around the cellular infiltrate, between collagen fibers, and around blood vessels and appendages. The specimens were further studied with special stains, including Masson's trichrome, PAS with and without diastase, alcian blue, orcein-Giemsa, and elastica. The mucosubstance stained well for mesenchymal mucin and was easily removed by bovine testicular hyaluronidase, suggesting that it was hyaluronic acid.

A biopsy specimen of the gastrocnemius muscle revealed throughout the specimen a fascial and perivascular infiltrate of lymphocytes, plasma cells, and scattered eosinophils within a loose mucinous ground substance similar to that observed in the skin (Fig 4). The muscle fibers appeared normal, although interfibrillar edema was evident. Again, occasional blood vessels revealed destruction of their walls by the inflammatory process with no evidence of fibrinoid degeneration or necrosis. Mild hemorrhage was noted in these areas.

Direct immunofluorescence studies on a skin biopsy specimen, including subcutaneous tissue, from the right thigh using monospecific conjugate antiserum to IgG, IgM, and IgA were negative.

Laboratory Findings

On admission, the hematocrit reading was 37.6%; the hemoglobin level was 12.5 gm/100 ml; the WBC count was 10,600/cu mm, with 24% eosinophils; and the ESR (Wintrobe) was 13 mm/hr. The results from the following laboratory studies were normal: platelet count, prothrombin time, partial thromboplastin time, serum electrolytes, liver function tests (serum bilirubin, SGOT, SGPT, lactic dehydrogenase, and serum alkaline phosphatase), serum calcium, serum phosphorus, fasting glucose, serum cholesterol, serum triglycerides, serum urate, serum creatinine, and BUN. Urinalysis showed a trace of protein but was otherwise within normal limits. Twenty-four-hour urine protein was 286 mg (normal, 10 to 150 mg).

In addition, the following laboratory values were determined: serum iron, 28 μg/100 ml (low); total iron binding capacity, 207 μg/100 ml (low); serum folate, 3.6 ng/ml; serum lipase, 1.0 Sigma Trietz units; serum amylase, 42 amylase units %, creatinine phosphokinase, 20 mU/ml; aldolase, 12 IU; VDRL test, nonreactive; antistreptolysin O titer, 166 Todd units; mono spot test for mononucleosis, negative; hepatitis B antigen (HBag) test, nonreactive; cryoglobulins, negative; febrile agglutinins negative; lupus erythematosus cell preparation, negative; ANA test, negative; anti-DNA test, 4.2% (normal); anti-SM and anti-RNP tests, negative; complement panel, all components within normal limits; and two repeated tube latex fixation tests for rheumatoid factor, negative. The total serum protein was 6.0 gm/100 ml. A serum protein electrophoresis demonstrated a moderately decreased albumin level with no evidence of a monoclonal gammopathy, and quantitative immunoglobulins G, A, M, and E were normal.

An infectious disease workup revealed no evidence of bacterial or viral diseases, tuberculosis, coccidioidomycosis, histoplasmosis, amoebiasis, toxoplasmosis, or intestinal parasitosis.

The patient had positive *Trichophyton* and *Candida* skin tests indicating grossly normal cell-mediated immunity.

A chest x-ray film, and upper gastrointestinal tract examination, a barium enema study, and a liver spleen scan were all normal. A bone marrow aspiration revealed a slightly hypercellular marrow with moderate eosinophilia and a mildly increased normoblastic erythropoiesis. An electromyogram of selected left upper limb muscles revealed increased muscle membrane instability and increased resistance to movement of the needle electrode. Pulmonary function tests were within normal limits and specifically revealed no restrictive defect or defect in carbon monoxide diffusion capacity.

During hospitalization, repeated WBC counts ranged from 9,300 to 10,600/cu mm, with eosinophilia from 15% to 48%, and repeated ESRs ranged from 13% to 41%.

Course

During the first month of hospitalization, the patient's edema of all four extremities gradually subsided. The skin over the involved areas became extremely tight, assuming a shiny "hide-bound" appearance (Fig 5). This tightening of the skin made the superficial vasculature in the involved areas very prominent, and exaggerated deep grooves were produced when these vessels were collapsed by elevation of an extremity (Fig 5, left and right). The patient continued to complain of pain and tenderness in the involved areas as well as restriction of motion.

In mid-January 1976, after a review of all of the patient's available laboratory data and biopsy specimens, a presumptive diagnosis of the Shulman syndrome was made. The patient was subsequently begun on treatment with oral prednisone, 60 mg/day, and discharged from the hospital. The swelling in the fingers subsided within one week of starting steroid therapy. In February 1976, the patient reported subjective improvement in energy level and range of motion of involved joints with concomitant decrease in pain on movement. Objectively, there was increased motion of the extremities but no change in the character of the hide-bound skin. The WBC count was 10,200/cu mm, with only 2% eosinophils. During the next six weeks, the patient's steroid dosage was gradually tapered, but when a decrement to 35 mg/day was reached, a mild exacerbation in symptoms was

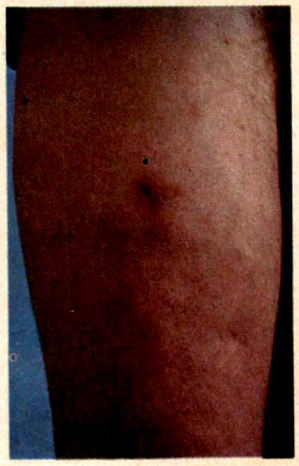

Fig 1.—Scattered subcutaneous nodules with overlying hyperpigmentation on anterior aspect of right thigh.

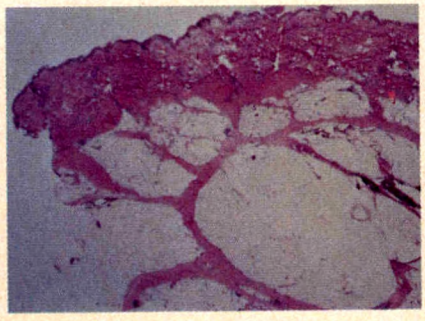

Fig 2.—Scanning view of tissue from right thigh showing thickened, band-like configuration of lower dermis and considerable widening of subcutaneous septa (hematoxylin-eosin, original magnification ×2).

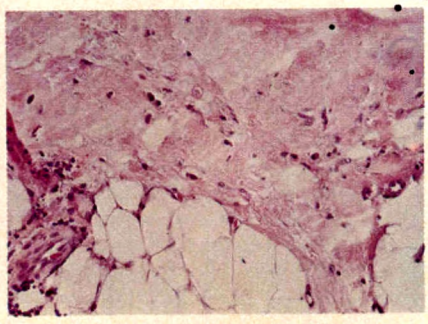

Fig 3.—Higher magnification of Fig 2 showing ground-glass appearance of thickened collagenous septa surrounding fat lobules (hematoxylin-eosin, original magnification ×25).

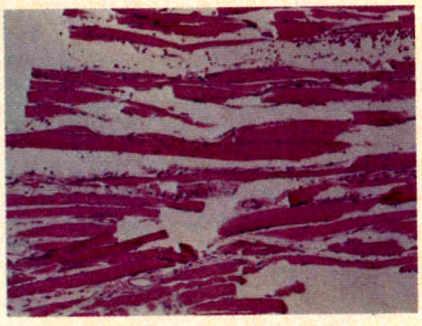

Fig 4.—Low-power view of tissue from right gastrocnemius muscle showing fascial and perivascular inflammatory infiltrate (hematoxylin-eosin, original magnification ×10).

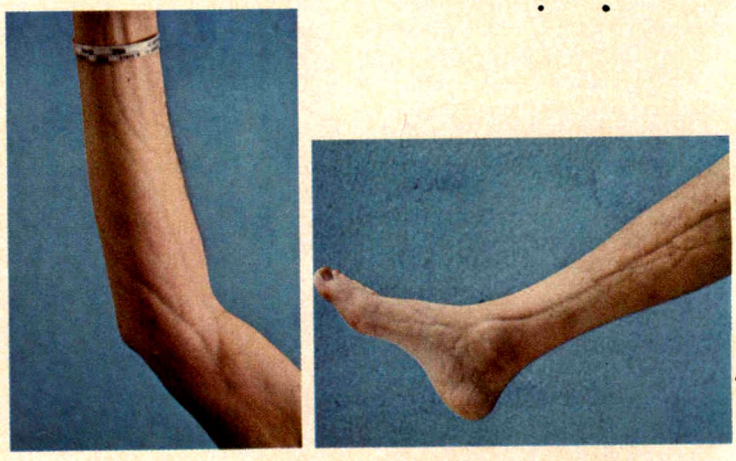

Fig 5.—Left and right, "Hide-bound" appearance of skin over involved areas with production of exaggerated deep grooves over superficial vasculature on elevation of extremities.

noted. The dose, therefore, was boosted to 40 mg of prednisone per day.

By April 1976, the patient's symptoms had subsided, and his WBC count was 6,700/cu mm with 0% eosinophils. The patient's prednisone dosage was decreased to 30 mg daily and subsequently tapered by 2.5 to 5.0 mg every three weeks. By June 1976, the patient was taking 12.5 mg of prednisone daily, and his skin showed signs of improvement. Specifically, over the forearm the skin could be pinched up whereas before this was not possible. Blood studies at that time revealed a hematocrit reading of 47%, a WBC count of 8,200/cu mm, with 0% eosinophils, and an ESR of 2 mm/hr. In September 1976, the patient's steroid therapy was discontinued without any evidence of relapse. The patient remained essentially asymptomatic, but results of physical examination continued to reveal moderately tight, somewhat hide-bound skin over the dorsa of the hands, wrists, forearms, and lower extremities from the knees to the ankles. The fingers, toes, and feet were not involved.

COMMENT

In the two years since Shulman's original article, 17 similar patients, ranging in age from 4 to 60 years, have been described in the medical literature. Caperton ahd Hathaway[2] described five patients and proposed the eponym the "Shulman syndrome" for this unusual steroid-responsive variant of scleroderma. Their patients, two females and three males, had, in addition to those features described by Shulman, plaques of morphea on the trunk, biopsy specimen evidence of myositis of superficial muscle bundles, and deposits of IgM along the dermal-epidermal junction on direct immunofluorescence. Rheumatoid arthritis factor was present in two patients, and in another, the ANA test was positive. These authors also reported, in some instances, dramatic improvement after corticosteroid therapy.

In 1975 Rodnan et al[3] reported their experience with six similar cases, four men and two women, seen over a three-year period. All had hypergammaglobulinemia, consisting predominantly of IgG, and blood eosinophil counts ranging from 416 to 2,725 cells/cu mm. Biopsy specimens revealed

inflammation and fibrosis of the panniculus and deep fascia, with the latter being greatly thickened and heavily infiltrated by lymphocytes, plasma cells, histiocytes, and eosinophils. Immunofluorescence studies on two cases disclosed deposits of IgG and C3 in the deep fascia and septa of the underlying muscle. Five patients improved with prednisone therapy and a sixth had a spontaneous remission develop.

Shulman[4] has updated his original report by describing two additional cases. Undue physical exertion such as jogging, heavy lifting, and resistive cycling antedated closely the onset of illness in three of his four cases. Shulman expressed the view that this disorder represents a "new" connective tissue disease distinct from previously determined entities and possibly precipitated by unusual exertion.

Schumacher[5] recently reported a case similar to ours in a 28-year-old man whose onset of illness was antedated by a two-week period of unusual exertion consisting of painting on a ladder 15 hours a day. This patient demonstrated both muscle inflammation on biopsy specimen and an abnormal electromyogram that showed increased polyphasic potentials and decreased mean action potential durations, indicating a myogenic disturbance. Improvement of clinical and laboratory findings was again coincident with prednisone therapy. The question of whether steroid therapy was instrumental in altering the disease process or in merely alleviating symptoms until the pathologic process spontaneously subsided was not answered.

In 1976 Caperton et al[6] did a follow-up study of their original five patients and reported three additional cases, each demonstrating major differences from those cited in the original reports. After two years, the original group of patients showed a number of variations from previously described cases, including recurrence of the entire syndrome months after withdrawal of steroid therapy following an "apparent cure." Spontaneous resolution of the hypergammaglobulinemia and marked eosinophilia and persistence of the diffuse morphea-like changes despite initial improvement with steroid therapy were also noted. Two of the new patients lacked one or more of the main features of the Shulman syndrome such as morphea or fasciitis. Another patient had systemic sclerosis in addition to all of the features of the syndrome and demonstrated a poor response to steroid therapy. These authors concluded from these findings that there is a wider spectrum to this complex entity than previously appreciated.[6]

The case reported in this article fulfills most of the criteria for the Shulman syndrome, including onset of illness related to unusual physical exertion, constitutional symptoms, eosinophilia, a scleroderma-like disease of the extremities with diffuse fasciitis and myositis, absence of Raynaud's phenomenon, absence of the visceral manifestations of progressive systemic sclerosis, and responsiveness to corticosteroid therapy. In addition, as in several of the previously reported cases, our patient demonstrated lesions of the plaque type of morphea, normal muscle enzyme studies, negative ANA and direct immunofluorescence tests, and an abnormal electromyogram. Unlike previous reports, no evidence of hypergammaglobulinemia was found in our patient. Perhaps a previously present hypergammaglobulinemia had spontaneously resolved as recently reported by Caperton et al.[6]

Skin and muscle biopsy specimens from our patient revealed histopathologic findings similar to those described elsewhere for the Shulman syndrome and, in addition, illustrated the involvement of the subcutaneous tissue with a septitis akin to th deeper fasciitis. Fleischmajer et al[7] have emphasized the role of the subcu taneous tissue in generalized morphe and systemic scleroderma, with th initial event being an inflammator reaction affecting the adipose tissu around the eccrine sweat glands an the upper layer of the subcutaneou tissue. As the disease progresses, th inflammatory reaction subsides, an there is progressive massive depos tion of hyalinized connective tissue i the trabeculae between adipocyte All of these changes were observed i the skin biopsy specimens from ou patient. A muscle biopsy specime revealed a mild to moderate fasciiti with no evidence of myositis, finding stressed by Shulman in both of hi reports.[1,4]

The etiology of this syndrome i unknown. A period of strenuous phys ical exertion that induces a mil degree of muscle injury has bee proposed as the initiating factor i several cases.[1,4,5,9] The demonstratio of IgG and C3 in the deep fascia an muscle septa by Rodnan et al[3] and o IgM along the dermal-epidermal junc tion by Caperton and Hathaway raises the possibility of an immunologic mechanism. These findings have not been consistently found in skin and muscle biopsy specimens from patients with the Shulman syndrome, including ours.

Early recognition of this syndrome permits one to take advantage of its high degree of responsiveness to corticosteroid therapy and to prevent the development of disabling contractures. Unfortunately, a recent follow-up study suggests this response to steroids may only be temporary and that the diffuse morphea-like changes may persist despite adequate steroid therapy as demonstrated in this case report.[6]

Westwood Pharmaceuticals Inc. supported the publication of the color photographs in this article.

References

1. Shulman LE: Diffuse fasciitis with hypergammaglobulinemia and eosinophilia: A new syndrome? abstracted. *J Rheumatol 1* (suppl 1):46, 1974.

2. Caperton EM, Hathaway DE: Scleroderma with eosinophilia and hypergammaglobulinemia: The Shulman syndrome, abstracted. *Arthritis Rheum* 18:391, 1975.

3. Rodnan GP, DiBartolomeo A, Medsger TA, et al: Eosinophilic fasciitis: Report of six cases of a newly recognized scleroderma-like syndrome, abstracted. *Clin Res* 23:443, 1975.

4. Shulman LE: Diffuse fasciitis with eosinophilia: A new syndrome? abstracted. *Clin Res* 23:443, 1975.

5. Schumacher HR: A scleroderma-like syndrome with fasciitis, myositis, and eosinophilia. *Ann Intern Med* 84:49-50, 1976.

6. Caperton EM, Hathaway DE, Dehner LP: Morphea, fasciitis, scleroderma with eosinophilia: broad spectrum of disease. Presented at 40th annual meeting of the American Rheumatism Association, June 9-11, 1976, Chicago.

7. Fleischmajer R, Nedwich A: Generalized morphea: I. Histology of the dermis and subcutaneous tissue. *Arch Dermatol* 106:509-524, 1972.

8. Fleischmajer R, Damiano V, Nedwich A: Alteration of subcutaneous tissue in systemic scleroderma. *Arch Dermatol* 105:59-66, 1972.

9. Shulman LE: Diffuse fasciitis with eosinophilia: A new syndrome. *Trans Assoc Am Physicians* 88:70-86, 1975.

Skin Lesions in Paroxysmal Nocturnal Hemoglobinuria

Robert L. Rietschel, MD; Charles W. Lewis, MD; Robert A. Simmons, MD; Robert L. Phyliky, MD

• Paroxysmal nocturnal hemoglobinuria (PNH) is an uncommon hemolytic anemia that rarely manifests skin lesions. Leg ulcers and purpura similar to the manifestation of thrombotic thrombocytopenic purpura (TTP), disseminated intravascular coagulation, and Henoch-Schönlein purpura do occur. This is the second known case report of PNH with histopathologic features of TTP. Clinically, our patient's condition resembled TTP with disseminated intravascular platelet aggregation, and she followed a nonfulminant course. She improved on a regimen of systemic steroids, dipyridamole, and cessation of antibiotics.

(*Arch Dermatol* 114:560-563, 1978)

Paroxysmal nocturnal hemoglobinuria (PNH) is a rare hemolytic anemia characterized by chronic intravascular hemolysis exacerbated during sleep and resulting in hemoglobinuria. The major cause of morbidity and mortality in PNH is the generalized thrombotic tendency that results in venous occlusion of major organ systems.[1] Skin lesions have been reported in PNH but they are uncommon.[2-8] Recently, a patient with PNH and skin lesions brought this association to our attention, and we wish to introduce this rare anemia with occasional cutaneous manifestations to the dermatologic literature.

Accepted for publication Feb 18, 1977.

From the Department of Medicine, Brooke Army Medical Center, Fort Sam Houston, Texas. Dr Phyliky is now at the Mayo Clinic, Rochester, Minn.

Reprint requests to Dermatology Service, Brooke Army Medical Center, Fort Sam Houston, TX 78234 (Dr Rietschel).

REPORT OF A CASE

A 28-year-old woman was diagnosed as having PNH in early February 1975. At that time she had dark urine intermittently, easy fatigability, and back pain. Laboratory tests disclosed the following abnormal values: hematocrit, 25%; WBC count, 2,900/cu mm; lactic dehydrogenase (LDH), 2,000 mU/ml; total bilirubin, 2.8 mg/100 ml; urine positive for occult blood; and a positive acid hemolysis test. Significant normal test results were direct Coombs, antinuclear antibody, and sickle cell preparation.

In late February 1975, she developed nausea, vomiting, pain in the lower part of the abdomen, a temperature of 38.8 C (102 F), and she was hospitalized. Since the patient had been treated for pelvic inflammatory disease twice in 1974, and a left adnexal mass was palpable on physical examination, a culdocentesis was performed. The 10 ml of serosanguineous fluid obtained was cultured and ampicillin sodium and clindamycin therapy was begun prior to her transfer to Brooke Army Medical Center, Fort Sam Houston, Tex.

At the time of her transfer she had been receiving antibiotics for 36 hours. Significant physical findings were temperature, 39.4 C; pulse, 100 beats per minute; a 5 × 6-cm ill-defined fullness in the left adnexa; and several skin lesions. The cutaneous lesions were erythematous papules, 1 to 2 cm in diameter, with a dusky purple center. There were two such lesions on the abdomen (Fig 1) and one each on the upper part of the right, arm, the lower part of the right leg, and the back. The lesions appeared shortly after the institution of antibiotics.

The following laboratory test results were abnormal on admission: hematocrit, 20.5%; WBC count, 3,500/cu mm; reticulocyte count, 9%; platelet count, 126,000; dark urine with 2 to 5 RBCs per high-power field; SGOT, 125 mU/ml (normal, 7 to 40 mU/ml); LDH, 2,890 mU/ml (normal, 100 to 225 mU/ml); total protein, 5.9 gm/100 ml (normal 6.0 to 8.0 gm/100 ml); albumin, 2.7 gm/100 ml (normal, 3.5 to 5.0 gm/100 ml); calcium, 6.6 mg/100 ml (normal, 8.5 to 10.5 mg/100 ml); serum iron, 51 mg/100 ml with total iron-binding capacity, 285 mg/100 ml; serum folate, 2.7 ng/ml; serum haptoglobin, 20 mg/100 ml; urine positive for hemosiderin; urine hemoglobin, 1.4 mg/100 ml; positive acid hemolysis test; positive sucrose hemolysis test; and positive inulin test. Significant negative or normal laboratory tests included prothrombin time, partial thromboplastin time, electrolyte studies, VDRL, human chorionic gonadotropin test, direct Coombs, and total bilirubin evaluation. A skin biopsy specimen was taken from the abdominal lesion (Fig 1), and half of the specimen was cultured aerobically and anaerobically. A tentative diagnosis of ecthyma gangrenosum led to institution of intravenous gentamycin sulfate, therapy and intravenous penicillin G sodium was given for possible pelvic inflammatory disease.

The skin biopsy specimen (Fig 2) showed thrombi in all dermal blood vessels, extravasated RBCs, small amounts of nuclear dust, but no true vasculitis. Tissue Gram stain was negative.

The patient was transfused with 2 units of frozen, packed RBCs and the hematocrit reading increased to 26%. Folate and iron therapy were instituted. The patient continued febrile, and large geographic plaques, especially prominent on the right flank (Fig 3) and the front of the lower part of both legs (Fig 4), appeared on the third day of hospitalization. The center of these lesions became necrotic and was surrounded by an erythematous halo, which in turn was surrounded by a nonerythematous, edematous border. The plantar surfaces, toes, tip of the nose, and both ears were similarly involved. Hemorrhagic bullae developed within 12 hours in the larger lesions. Initially, the lesions were painless, but pain developed in all lesions coincident with the bullae. The clinical picture suggested purpura fulminans; however,

Fig 1.—Skin lesions on right side of abdomen present on admission. Note the erythematous border with dusky center.

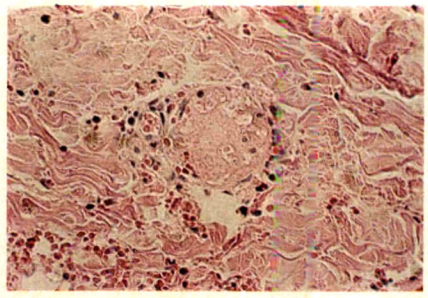

Fig 2.—Biopsy specimen of lesion seen in Fig 1 showing upper dermal vessel occluded with thrombus, extravasated RBCs, some nuclear dust, but no vasculitis (hematoxylin-eosin, original magnification ×200).

Fig 3.—Appearance of right flank on third hospital day. Large geographic plaques with edematous halo surrounding erythematous halo, in turn surrounding central necrosis.

Fig 4.—Appearance of right ankle on third hospital day with large bullae on necrotic region and surrounding erythematous halo.

Fig 5.—Appearance of right flank two weeks after Fig 3. Eschar required surgical debridement and skin grafting.

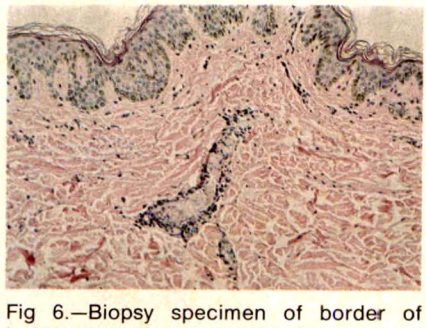

Fig 6.—Biopsy specimen of border of lesion taken shortly after Fig 3. Thrombus is prominent with scattered inflammatory cells now migrating perivascularly (hematoxylin-eosin, original magnification ×100).

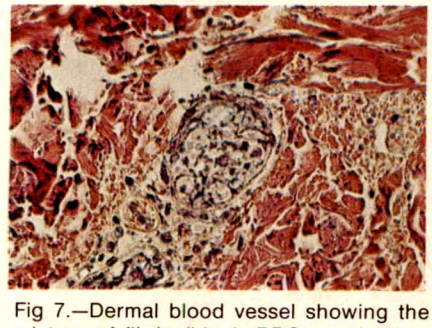

Fig 7.—Dermal blood vessel showing the mixture of fibrin (blue), RBCs, and platelets (PTAH, original magnification ×200).

Summary of Reported Skin Lesions in PNH

Source	Age, yr/Sex	Location of Lesions	Clinical Description
Hartmann & Auditore[4]	33/M	Pretibial	Ulcerations without varicosities or large vessel disease
Hartmann & Auditore[4]	56/M	Right thigh & internal malleolus	Hemorrhagic bullae, healed with scarring
Perkins et al[5]	49/M	Pretibial	Ulceration, superficial venous thromboses present
Mancester[5]	30/M	Left leg	Superficial ulceration, responded to Unna boot
Ellenhorn et al[6]	17/M	Chest & front of arms	Brown, vesicular lesions thought to be similar to Henoch-Schönlein purpura
Pierce & Aldrich[7]	5/M	Abdomen	Petechiae, ecchymosis, thought to be idiopathic thrombocytopenic purpura
Hansen & Killmann[2]	81/F	Legs	Ulceration; developed gangrene and underwent amputation
Hansen & Killmann[2]	40/F	Generalized	Reddish-blue "spots," biopsy specimen suggested thrombotic thrombocytopenic purpura

the patient repeatedly stated that she felt fine except for her skin lesions. Additional laboratory studies at this time showed normal prothrombin time, normal partial thromboplastin time, normal thromin time, negative cryoglobulins, and slightly elevated fibrin split products. Multiple cultures of blood, skin, nose, throat, and urine failed to detect pathogenic organisms. The culdocentesis fluid cultured at her original hospital grew only a *Candida* sp. Antibiotics were stopped and prednisone (20 mg every eight hours) along with dipyridamole (50 mg every six hours) therapy was instituted. The fever lysed, new skin lesions ceased, but the platelet count dropped from 126,000 to 26,000/cu mm. The skin lesions developed a thick eschar requiring surgical debridement (Fig 5).

A second skin biopsy specimen was taken one day after prednisone therapy was begun. Again thrombi were observed occluding the dermal vessels, but no significant vasculitis was seen (Fig 6). Direct immunofluorescence on this specimen was negative for complement, fibrinogen, IgG, IgM, IgA, and IgE.

The patient continued to improve, with platelet and LDH levels returning to normal. The hematocrit reading increased to 38% following additional transfusions. However, the skin lesions developed into full-thickness defects requiring multiple skin grafts. Prednisone therapy was slowly tapered off. A subsequent urinary tract infection with *Escherichia coli* occurred, and the patient again became febrile with a drop in the hematocrit reading and platelet count. Grafted skin lesions were not affected and no new skin lesions appeared. The infection was treated with sulfisoxazole and the prednisone dosage was increased to 20 mg every eight hours. Additional washed, packed RBCs were given and the patient's condition improved without further complications. The adnexal mass decreased in size and was believed to be a resolved tubal ovarian abscess or possible ovarian cyst. The patient was discharged on May 30, 1975, on a regimen of 20 mg of prednisone per day and tapered off medication as an outpatient.

SKIN LESIONS IN OTHER REPORTS

The Table summarizes the previously described skin lesions associated with PNH. Leg ulceration, hemorrhagic bullae, reddish-blue "spots," petechiae, ecchymosis, and brown vesicular lesions have been reported. Diagnostic considerations have included idiopathic thrombocytopenic purpura, Henoch-Schönlein purpura, and thrombotic thrombocytopenic purpura (TTP). The 40-year-old woman described by Hansen and Killmann[2] was most analogous to our own case. Their patient was thought to have an infectious disease, and was treated with ampicillin with subsequent development of skin lesions. The cutaneous histopathology suggested TTP, but there was no renal or neurologic abnormality. The patient was treated successfully with prednisone.

HISTOPATHOLOGY

The only previously reported case of PNH with skin lesions that underwent biopsy was the 40-year-old woman described by Hansen and Killmann.[2] They demonstrated thromboses in the capillaries and arterioles "suggestive of thrombotic thrombocytopenic purpura." Our case appears identical. Both the superficial and deep dermal vessels were occluded with thrombi. There were occasional mononuclear cells and polymorphonuclear leukocytes located perivascularly, but not within vessel walls. There were extravasated RBCs and some nuclear dust but no extravascular deposits of fibrin. The primary process was thrombotic rather than vasculitic. These pathologic changes are similar to those reported in disseminated intravascular coagulation (DIC).[9] The same changes have been reported in TTP.[10] The phosphotungstic-acid hematoxylin (PTAH) stain has been used to identify fibrin within occluded vessels.[10] A PTAH stain on our patient's tissue showed scattered fibrin strands, with platelets and RBCs occupying the bulk of the lumen (Fig 7). This is compatible with disseminated platelet aggregation as has been reported with TTP.[10]

COMMENT

The diagnosis of PNH in our patient was well established by both clinical and laboratory factors. We believe that her skin lesions were a manifestation of her PNH. Although our patient was initially thought to have an infectious process, no microbiologic support for such a process was found. The patient's condition did not improve until antibiotics were discontinued. The diagnosis of DIC could not be supported due to a normal prothrombin time, activated partial thromboplastin time, thrombin time, and lack of bleeding diathesis. The slight elevation of fibrin split products may have been due to massive skin necrosis. Thrombotic thrombocytopenic purpura has a similar histopathologic picture, but lack of renal failure, neurologic signs, and microangiopathic hemolytic anemia make this diagnosis untenable.

Neame et al suggested disseminated intravascular platelet aggregation (DIPA) as the major pathophysiologic event in TTP.[10] The coagulopathy of DIPA is characterized by thrombocytopenia and normal clotting studies, as in our patient. Viral infections have been proposed as a possible cause for DIPA,[10] and our patient may have had an undetected viral disease. However, increased platelet adhesiveness and platelet associated clotting occur in PNH.[1]

Skin lesions are uncommon in PNH, yet thrombocytopenia is frequently observed.[3] Instead of purpura or hemorrhagic manifestations, PNH usually has thrombotic lesions. Crosby noted that peripheral lesions of the arms and legs in PNH were usually painless, and patients with peripheral thrombosis rarely developed abdominal or cerebral infarcts.[3] Leg ulcers are common in sickle cell anemia and other hemolytic diseases, yet they are

apparently rare in PNH. The case reported here and that of Hansen and Killmann suggests that the skin lesions are a direct result of the thrombotic tendency of these patients.

The evolution of PNH skin lesions clinically follows that of a necrotizing purpura. An erythematous, edematous plaque develops in which the center becomes dusky and then deep purple. Hemorrhagic bullae may develop. In our patient lesions with bullae were full-thickness injuries and healed with scarring. Those lesions without bullae generally healed with only postinflammatory hyperpigmentation. Some lesions became large, geographic plaques, developed a full-thickness eschar, and required debridement and skin grafting. At its zenith the large geographic lesions were surrounded by a halo of edema that became erythematous, then purple as one progressed from the periphery to the center of the lesion. Since fever and abdominal pain frequently accompany acute PNH, the differential diagnosis includes ecthyma gangrenosum, TTP, Henoch-Schönlein purpura, and DIC.

The cause of thromboses in PNH is unclear. Primary erythrocyte defects, mechanical occlusion of vessels by RBCs, increased platelet adhesiveness, and C3-activator system generation of platelet-associated clotting have all been suggested.[1] Platelet counts apparently do not correlate with thrombosis as high, low, and normal values have all been reported.[1]

Treatment of the thrombotic complications is difficult and controversial. Dicumarol has been used with occasional success, but heparin sodium has a biphasic effect stimulating hemolysis when given in low concentrations, and preventing hemolysis in higher concentrations.[1] In our patient, prednisone and dipyridamole were used, but their effect on the course of the disease is uncertain. The efficacy of systemic steroids in PNH is generally unclear, but recent reports suggest that steroid-responsive cases do exist.[12,13] The use of adrenocortical steroids and dipyridamole in conditions with platelet thrombus formation (TTP, hemolytic-uremic syndrome, vasculitis syndromes) has been advocated.[14]

Elimination of the causes of acute exacerbation of PNH seems indicated. Transfusion, other than with washed RBCs, should be avoided. Crosby lists the following as inducers of crises: arsphenamine, Evans blue dye, nitrogen mustard, ascorbic acid, intramuscular liver extract, nicotinic acid, riboflavin, peptone, iron salts, typhoid vaccine, oral iron, sodium bicarbonate, ammonium chloride, potassium nitrate, aspirin, sodium benzoate, fish ingestion, infections, physical injury, fatigue, and intense emotion.[3] Interestingly, our patient and the patient described by Hansen and Killmann both received ampicillin prior to their skin eruption. In an attempt to clarify the role of ampicillin, the patient's lymphocytes were challenged in vitro but were found to undergo blast transformation in the presence of clindamycin rather than ampicillin. While we failed to find complement or immunoglobulin deposition in blood vessels by direct immunofluorescence, it must be noted that the patient had been receiving prednisone for one day prior to this biopsy.

It appears that the general thrombotic tendency of PNH can occasionally effect the skin. The resulting lesions clinically suggest thrombotic thrombocytopenia purpura with intravascular platelet aggregation.

This investigation was supported in part by the Clinical Investigation Service, Brooke Army Medical Center.

Cost of color reproduction was assumed by Westwood Pharmaceuticals, Inc.

Nonproprietary Names and Trademarks of Drugs

Clindamycin—*Cleocin*.
Dipyridamole—*Persantine*.

References

1. Peytremann R, Rhodes RS, Hartmann RC: Thrombosis in paroxysmal nocturnal hemoglobinuria (PNH) with particular reference to progressive, diffuse hepatic venous thrombosis. *Ser Haematol* 3:115-136, 1972.

2. Hansen NE, Killmann SA: Paroxysmal nocturnal hemoglobinuria: A clinical study. *Acta Med Scand* 184:525-541, 1968.

3. Crosby WH: Paroxysmal nocturnal hemoglobinuria: Relation of the clinical manifestations to underlying pathogenic mechanisms. *Blood* 8:769-812, 1953.

4. Hartmann RC, Auditore JV: Paroxysmal nocturnal hemoglobinuria I: Clinical studies. *Am J Med* 27:389-400, 1959.

5. Manchester RC: Chronic hemolytic anemia with paroxysmal nocturnal hemoglobinuria. *Ann Intern Med* 23:935-944, 1945.

6. Ellenhorn MJ, Feigenbaum LZ, Plumhof C, et al: Paroxysmal nocturnal hemoglobinuria with chronic hemolytic anemia. *Arch Intern Med* 87:868-878, 1951.

7. Pierce PP, Aldrich CA: Chronic hemolytic anemia with paroxysmal nocturnal hemoglobinuria (Marchiafava-Micheli syndrome). *J Pediatr* 22:30-42, 1943.

8. Perkins HA, Boulware JM, Feichtmeir TV, et al: Paroxysmal nocturnal hemoglobinuria: Report of four cases with observations on treatment with 3,3'-methylenebis 4-hydroxycoumarin) (dicumarol). *Ann Intern Med* 43:1218-1229, 1955.

9. Robboy SJ, Mihm MC, Colman RW, et al: The skin in disseminated intravascular coagulation. *Br J Dermatol* 88:221-229, 1973.

10. Neame PB, Lechago J, Ling ET, Koral A: Thrombotic thrombocytopenia purpura: Report of a case with disseminated intravascular platelet aggregation. *Blood* 42:805-814, 1973.

11. Dacie JV: *The Haemolytic Anaemias Congenital and Acquired*. New York, Grune & Stratton Inc, 1967, vol 4, pp 1226-1227.

12. Hartmann RC, Kolhouse JF: Viewpoints on the management of paroxysmal nocturnal hemoglobinuria. *Ser Hematol* 3:42-60, 1972.

13. Firkin F, Goldberg H, Firkin BG: Glucocorticoid management of paroxysmal nocturnal haemoglobinuria. *Aust Ann Med* 17:127-134, 1968.

14. Harker LA, Slichter SJ: Platelet and fibrinogen consumption in man. *N Engl J Med* 287:999-1005, 1972.

Papulonecrotic Tuberculid Secondary to *Mycobacterium bovis*

Donald L. Iden, MD; Roy S. Rogers III, MD; Arnold L. Schroeter, MD

• A patient with papulonecrotic tuberculid had a pruritic papular eruption associated with constitutional symptoms. The eruption flared whenever the patient received low doses of prednisone to control symptoms of temporal arteritis. A cervical lymph node biopsy specimen demonstrated acid-fast bacilli, and *Mycobacterium bovis* grew on the cultures. The eruption cleared completely with antituberculous therapy. This case demonstrated the clinicopathologic findings compatible with a diagnosis of papulonecrotic tuberculid. Skepticism regarding the existence of papulonecrotic tuberculid is probably a result of the current decreased prevalence of untreated tuberculosis, and the subsequently increased rarity of this entity.

(*Arch Dermatol* 114:564-566, 1978)

Today, the existence of papulonecrotic tuberculid as a rare cutaneous reaction to the *Mycobacterium* bacillus is questioned.[1,2] Case reports of this clinicopathologic entity, which were well known in the past,[3,4] have all but disappeared from the literature.

Papulonecrotic tuberculid is, however, a real entity in underdeveloped countries where tuberculosis is more common. Accordingly, in 1974 Morrison and Fourie[5] reported 91 cases from South Africa that were seen over a 17-year period. As they correctly point out, the skepticism regarding the existence of papulonecrotic tuberculid most likely results from the sharp decline in the prevalence of active tuberculosis in developed countries of the world.

We report a case of papulonecrotic tuberculid secondary to *M bovis* that developed in a patient who had been receiving intermittent prednisone therapy for biopsy-proved temporal (giant cell) arteritis. The patient's eruption would flare on low-dose steroid therapy, only to remit when high doses of steroid were used.

REPORT OF A CASE

A 71-year-old woman was admitted to our hospital in September 1975 with a pruritic papular rash, cervical lymphadenopathy, generalized myalgia, malaise, and a history of intermittent fever. She had received intermittent prednisone therapy since June 1971 for symptomatic treatment of biopsy-proved temporal (giant cell) arteritis. Cutaneous symptoms of papulonecrotic tuberculid appeared in March 1973, while the patient was convalescing from arthroplasty of the right hip that was performed for aseptic necrosis of the femoral head. The eruption was pruritic, papular, symmetric, and confined to the extensor surfaces on both elbows and wrists.

Low-dose steroid therapy was begun (prednisone, 10 mg daily); however, her rash gradually extended to cover the extensor surfaces of the upper and lower extremities. Two punch biopsy specimens were submitted by her local physician to our surgical pathology laboratories in April 1973. Each biopsy specimen contained predominantly a lymphocytic perivascular infiltrate. One also had a necrotizing granuloma suggestive of a hypersensitivity vasculitis. (The importance of this observation was not clear until the diagnosis of papulonecrotic tuberculid was made two years later). Findings from an extensive examination at the Mayo Clinic in May 1973, including chest roentgenograms, were essentially normal. The only abnormal findings were an elevated ESR of 31 mm/hr (Westergren) and a skin biopsy specimen compatible with granulomatous vasculitis.

During the next two years, each attempt to lower the prednisone dosage below 16 mg daily led to a flare-up of her cutaneous eruption. Not until April 1975 did she undergo a spontaneous resolution that led to the discontinuation of prednisone therapy.

The patient had an elective vaginal hysterectomy in July 1975 for which she received cortisone acetate intramuscularly. Immediately after surgery an eruption that was confined to the same sites as her previous eruption developed. Her local physician reinstituted low-dose prednisone therapy, but there was a gradual extension of the eruption to her lower portion of her back and buttocks and a worsening of the lesions of the extensor surfaces of the arms and legs. During the next month additional new lesions developed on her palms and soles, as well as on her oral, nasal, and vaginal mucosae. Intermittently, her temperature increased to between 37.7 and 38.3 C, accompanied by myalgia and cervical lymphadenopathy. The patient concluded that the low doses of prednisone were making her skin eruption worse, so she discontinued it. Within weeks her palmar, plantar, and mucosal lesions involuted. However, the eruption persisted on the extensor surfaces of the arms and legs, as well as on the lower trunk and buttocks. The worsening of her cervical lymphadenopathy prompted her return to our clinic.

She was an elderly woman in moderate discomfort from a severely pruritic, erythematous, papular eruption. Each papule measured 2 to 5 mm in diameter and was surmounted by a small excavation, appearing as if a tiny vesicle had been excoriated. The lesions were grouped and confined to the lower trunk, buttocks (Fig 1), and extensor regions of the arms and legs. No palmar, plantar, or mucosal lesions were detected, except for a few 2- to 3-mm erosions of the nasal mucosa that were healing. The patient was afebrile. Large tender lymph nodes, 2 to 4 cm in diameter, were present in the submandibular and the anterior and posterior cervical chains. Findings from the remainder of the physical examination were normal. Past medications could not be implicated as a cause of her skin eruption. The clinical diagnosis was dermatitis herpetiformis or some form of vasculitis.

Her chest roentgenogram showed a Ghon complex that was not present on previous roentgenograms taken at our institution. An intermediate (5 TU) purified protein derivative skin test was strongly positive at 48 hours, showing 20 mm of induration, and eventually resulting in a large bulla (Fig 2). Tissue from a cervical lymph node biopsy specimen contained caseating granulomas, and sections stained by Ziehl-Neelsen carbolfuchsin had numerous acid-fast positive bacilli.

She had a leukocyte count of 2,200 to 3,500, with a normal differential cell count. She was anemic (hemoglobin level, 10.9 gm/100 ml; hematocrit value, 32.6%). The serum iron level was decreased to 42 μg/100 ml, but iron-binding capacity was normal. In bone marrow, no organisms were found on acid-fast smear or by culture. The fixed section of bone marrow was interpreted as consistent with an evolving myeloproliferative disorder.

The following test results were either normal or negative: platelet count, lupus erythematosus clot test, antinuclear antibody, rheumatoid factor, cryoglobulins, direct Coombs' test, total complement, C3, C4, IgG, IgA, and IgM, serum protein electrophoresis, serum glucose, uric acid, electrolytes, creatinine phosphokinase, alkaline phosphatase, direct and indirect bilirubin, SGOT, SGPT, serum lactic dehydrogenase, Australia antigen, serum creatinine, BUN, VDRL, fungal serology for histoplasmosis, coccidioidomycosis, blastomycosis, and cryptococcosis, urinalysis, stool for occult blood, sputum for acid-fast

Accepted for publication May 25, 1977.
From the Department of Dermatology, Mayo Clinic and Mayo Foundation, Rochester, Minn.
Reprints not available.

Fig 1.—Grouped papular lesions on buttocks.

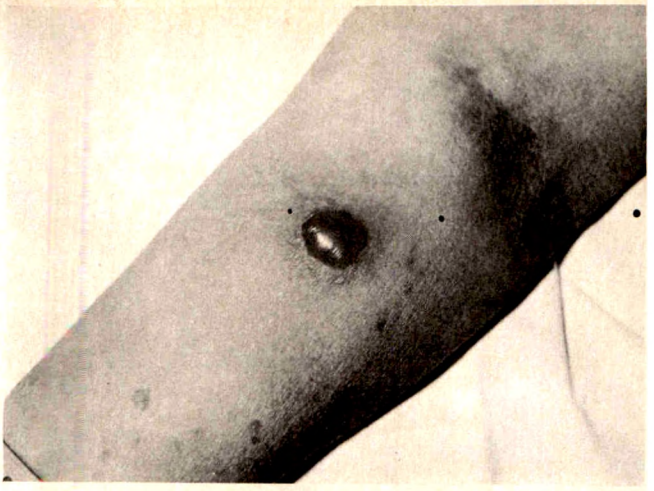

Fig 2.—Intermediate purified protein derivative skin test (5 TU) strongly positive at 48 hours.

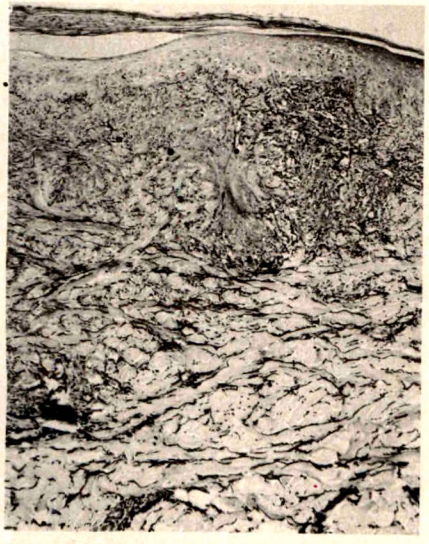

Fig 3.—Necrosis extending into deep dermis with base of wedge at epidermis (hematoxylin-eosin, ×80).

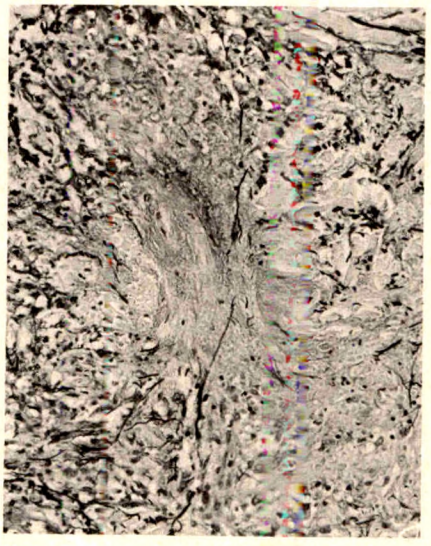

Fig 4.—High-power view demonstrating necrobiosis (elastic Giemsa, ×250).

Fig 5.—Lymphohistiocytic infiltrate with granuloma formation around vessels (arrows) (elastic Giemsa, ×250).

bacilli smear and culture, direct immunofluorescence test of the perilesional skin of the lower back, and indirect immunofluorescence test of serum.

Unfortunately, skin biopsy specimens for culture and guinea pig inoculation were not obtained before her dismissal in October 1975, at which time she was on a regimen of isoniazid (300 mg/day) and ethambutol hydrochloride (25 mg/kg/day).

Seven weeks after dismissal she returned for an examination. The cutaneous lesions were clear, except for three small erosions of the right labum majora. Biopsy specimens were not obtained, at the request of the patient.

Her cervical lymph node specimens eventually cultured mycobacteria that were identified unequivocally as *M bovis*. The patient could give no history that was helpful in identifying the source of her infection.

A follow-up examination at six months showed that all of her lesions has resolved, except for residual pruritus vulvae. Results of a dermatologic examination 12 months after antituberculous therapy were normal.

DERMATOPATHOLOGIC FINDINGS

The punch biopsy specimens from the right wrist and right elbow submitted in April 1973, shortly after the process began, showed a perivascular lymphocytic vasculitis. In addition, there was a necrotizing granuloma on one slide, adjacent to a thrombosed small vein. This vasculitis was compared with the temporal (giant cell) arteritis detected in 1971, and was believed to be a separate process.

During her most recent hospitalization, a 4-mm punch biopsy specimen was taken from the lower portion of the back. The elastic Giemsa stain was particularly useful in demonstrating a wedge-shaped area of necrosis of the primary or necrobiotic type that was almost advanced enough to be categorized as caseation necrosis. The necrosis extended into the deep portion of the dermis, with the base of the wedge at the epidermis (Fig 3).

Higher-power views (Fig 4 and 5) demonstrated necrobiosis and secondary granuloma formation. The elastic Giemsa stain also demonstrated the preservation of elastic fibers in the areas of necrosis and their destruction in areas of granuloma formation. About the vessels there was a lymphohistiocytic infiltrate with epithelioid cell formation. No evidence of giant cell tubercle formation or leukocytoclasis could be detected. The biopsy specimen was interpreted as showing granulomatous vasculitis, and the possibility of the existence of Churg-Strauss vasculitis was raised.

Multiple sections were taken for Ziehl-Neelsen carbol fuchsin, Fite, and Nite blue stains, all of which were negative. The fluorescent auramine-rhodamine technique failed to demonstrate *Mycobacterium* in this biopsy

specimen and all previous biopsy specimens.

COMMENT

Wilkinson[6] defines papulonecrotic tuberculid as an eruption of necrotizing papules affecting the extremities symmetrically and occurring in crops. Each lesion lasts only a few weeks, but continuously successive crops can make the eruption active for months or years. The lesions are usually asymptomatic and can undergo spontaneous exacerbations and remissions. Sites of involvement include the dorsum of the hands and feet, the elbows, the knees, the palms, the soles, the buttocks, and the perineum. The tuberculin test is often strongly positive, and bacilli are almost never found on biopsy. A clinical focus of tuberculosis often is present. Proof of the diagnosis rests on the unequivocal response to antituberculous drugs. Our case fulfills these clinical requirements.

In the 91 patients with papulonecrotic tuberculid reported by Morrison and Fourie[5] from South Africa, two thirds were younger than 30 years of age, and in one third a deep focus of tuberculosis, most commonly cervical lymphadenopathy, was found. Lupus vulgaris developed in four of their patients, and nine patients had erythema induratum. These findings are not unlike those of Irgang,[7] who described papulonecrotic tuberculid in the American black. He, too, found coexistence of erythema induratum, as well as the visceral manifestations of tuberculosis.

The primary lesion of papulonecrotic tuberculid is the papule, which may be pink, red, or flesh colored. It is common to find a brown to black discoloration in a slightly eccentric position, representing a vesicle or pustule. This punctum may be removed, leaving a tiny excavation.[7]

Because the entire histologic spectrum of necrosis may occur, the morphologic gamut runs from that of papule through vesicle to pustule. With minimal epidermal necrosis, the lesions may resemble secondary syphilis. More advanced necrosis may give lesions similar to pityriasis lichenoides et varioliformis acuta. Finally, if vesiculation is pronounced, papulonecrotic tuberculid could be mistaken for varicella or dermatitis herpetiformis.

Necrosis of the central punctum in localized papulonecrotic tuberculid gave rise to now obsolete terms. These included the term "folliclis" for papulonecrotic tuberculid confined to the hands, which resembled folliculitis, and the term "acnitis" for papulonecrotic tuberculid confined to the face, which resembled acne.[8] Lichen scrofulosorum is a variant of papulonecrotic tuberculid.[6] This manifests as an eruption, usually follicular, that shows histopathologically superficial dermal granulomas that are most often around hair follicles or sweat ducts.[9]

In the early lesions of papulonecrotic tuberculid, the histologic picture is reported as an Arthus-type reaction with swelling of the arteriolocapillary endothelium, intraluminal collections of polymorphonuclear leukocytes and fibrin, and extravasation of neutrophils. These changes are followed by perivascular collections of mononuclear cells. Older lesions have a cone of necrosis extending from the epidermis to the dermis. Epithelioid and giant cells gather around the periphery.[5]

The histologic features in our patient are consistent with a diagnosis of papulonecrotic tuberculid. Although the earliest biopsy specimens did not show an Arthus-type reaction, they did suggest a hypersensitivity reaction. Because the histopathologic features of papulonecrotic tuberculid are dynamic, and because the first biopsy specimens were submitted by the local physician more than one month after the process began, it is assumed that the Arthus-like reaction in its earliest stage, as described by Morrison and Fourie,[5] was missed.

The biopsy specimen obtained two years later was clearly at the opposite end of the continuum. A granulomatous vasculitis had evolved with obliterative vascular changes leading to wedge-shaped necrosis and necrobiosis. The preservation of the elastic fibers in the areas of necrosis and their destruction in areas of granuloma formation are consistent with Pinkus and Mehregan's description[10] of papulonecrotic tuberculid. The necrobiosis without giant cell tubercle formation is also consistent because typical tubercles do not necessarily have to form to justify the diagnosis of papulonecrotic tuberculid. When necrosis with granuloma formation is less severe, papulonecrotic tuberculid can resemble the histopathologic picture of granuloma annulare.[10]

It is interesting that the diagnosis of granulomatous vasculitis and possibly allergic granulomatosis (Churg-Strauss syndrome) was raised by the dermatopathologist. One must include papulonecrotic tuberculid in the histologic differential diagnosis of allergic granulomatosis because both can have necrobiosis surrounded by granuloma formation and granulomatous vasculitis. Giant cells, which can be present in both conditions, were absent in our case. The eosinophils, typically present in Churg-Strauss vasculitis, were absent as well.

Thus, our biopsy material is consistent with the histologic spectrum of this disease.

The pathogenesis of tuberculids is currently thought to be the result of hematogenous dissemination.[1,8] Recently, Morrison and Fourie[5] have hypothesized that papulonecrotic tuberculid is the result of hematogenous dissemination that evokes an Arthus reaction that is then followed by the development of a delayed hypersensitivity reaction. Although immune complexes have been found in papulonecrotic tuberculid,[5] we were unable to demonstrate their presence in perilesional skin by the direct immunofluorescence test.

It is hoped that this case report will stimulate the clinician to search for similar cases among patients who have active tuberculosis and in those who are receiving long-term immunosuppressive therapy. Also, the dermatohistopathologist, confronted by a cutaneous granulomatous vasculitis suggestive of Churg-Strauss vasculitis, should include in his differential diagnosis the possibility of papulonecrotic tuberculid. We conjecture that a heightened index of suspicion regarding this disorder will lead to the discovery of more cases of this rare entity.

Nonproprietary Name and Trademark of Drug

Ethambutol hydrochloride—*Myambutol.*

References

1. Lever WF, Schaumburg-Lever G: *Histopathology of the Skin*, ed 5. Philadelphia, JB Lippincott Co, 1975, pp 282-283.
2. Wolff K: Mycobacterial diseases: Tuberculosis, in Fitzpatrick TB, Arndt KA, Clark WH Jr, et al (eds): *Dermatology in General Medicine*. New York, McGraw-Hill Book Co Inc, 1971, pp 1757-1759.
3. Greenbaum SS: Papulonecrotic tuberculid. *Arch Dermatol Syphilol* 16:491, 1927.
4. Irvine HG, Turnacliff DD: Tuberculous lesions of the skin with active foci. *Arch Dermatol Syphilol* 30:900, 1934.
5. Morrison JGL, Fourie FD: The papulonecrotic tuberculide: From Arthus reaction to lupus vulgaris. *Br J Dermatol* 91:263-270, 1974.
6. Wilkinson DS: Tuberculosis of the skin, in Rook A, Wilkinson DS, Ebling, FJG (eds): *Textbook of Dermatology*, ed 2. Oxford, Blackwell Scientific Publications, 1972, vol 1, pp 624-628.
7. Irgang S: Superficial papulonecrotic tuberculid in the Negro. *Arch Dermatol Syphilol* 47:627-636, 1943.
8. Montgomery H: Histopathology of various types of cutaneous tuberculosis. *Arch Dermatol Syphilol* 35:698-712, 1937.
9. Smith NP, Ryan TJ, Sanderson KV, et al: Lichen scrofulosorum: A report of four cases. *Br J Dermatol* 94:319-325, 1976.
10. Pinkus H, Mehregan AH: *A Guide to Dermatohistopathology*, ed 2. New York, Appleton-Century-Crofts, 1976, pp 295-299.

Primary Inoculation Tuberculosis of the Skin

Prosector's Paronychia

Lt Comdr D. Klaus Goette, MC, USA; Capt Kraig W. Jacobson, MC, USA; Maj Richard D. Doty, MC, USA

• Subsequent to an autopsy of a tuberculotic cadaver, a pathology resident presented with a painless paronychia and axillary adenopathy after surgical incision and broad-spectrum antibiotics had failed to improve his condition. Demonstration by culture of *Mycobacterium tuberculosis* var *hominis*, positive smears, and findings of acid-fast organisms in a skin biopsy specimen proved the diagnosis of tuberculosis. Conversion of a previously negative skin test permitted the diagnosis of primary inoculation tuberculosis of the skin.

The disease responded well to treatment with isoniazid, rifampin, and pyridoxine hydrochloride.

(*Arch Dermatol* 114:567–569, 1978)

Primary tuberculosis is an infection resulting from exposure to *Mycobacterium tuberculosis* in an individual not previously exposed to that organism.[1,2] In 90% to 95% of cases, primary tuberculosis occurs in the lung (Ghon complex), while in 5% to 10% it is conveyed through mucosal surfaces or the skin. Penetrating trauma is necessary for the initiation of the infection because the tubercle bacillus cannot transgress the normal skin barrier.[1,2] The decline in tuberculosis, in general occasioned by successful treatment, active immunization, and active public health measures, has relegated primary inoculation tuberculosis of the skin, at least in the United States, mostly to the realm of rare accidental inoculations of medical personnel.[3]

Here we report such a case and recount the vagaries of primary cutaneous inoculation tuberculosis.

Accepted for publication May 9, 1977.

From the Dermatology Service, Department of Medicine, Letterman Army Medical Center, Presidio of San Francisco.

The opinions or assertions contained herein are the private views of the authors and are not to be construed as official or as reflecting the views of the Department of the Army or the Department of Defense.

Reprint requests to Technical Publications Editor, Letterman Army Medical Center, Presidio of San Francisco, CA 94129.

REPORT OF A CASE

Four weeks after performing an autopsy on a patient with unsuspected fulminant tuberculosis, a 30-year-old pathology resident developed an asymptomatic paronychia on the third finger of his left hand with left epitrochlear and axillary adenopathy. He complained of continuing fever of 1.5 C, increased perspiration, fatigue, and anorexia despite self-treatment with a cephalosporin and later with a semisynthetic penicillin preparation for a suspected staphylococcal paronychia. An incision failed to produce pus; no culture was attempted. On consultation with the authors three weeks later, he had not experienced any improvement, and admitted after questioning that during the autopsy his left hand had been in direct contact with the patient's tissue through a hole in his glove.

The examination showed an almost painless paronychia involving the lateral radial nail fold of the left middle finger. The area was firmly indurated, swollen, livid red, fairly sharply demarcated, and measured approximately 10 × 15 mm (Fig 1). Painless adenopathy of 1 to 2 cm in diameter was palpable in the epitrochlear area and the axilla of the left arm. Furthermore, the tip of the spleen was palpable 3 cm below the left costal margin. Results of the remainder of the examination were normal.

Laboratory Examination

The following laboratory tests were normal or negative: complete blood cell count, urinalysis, VDRL, serum multiphasic autoanalyzer screen, sedimentation rate, and chest roentgenogram.

An intradermal intermediate strength PPD test (5 US units) showed a positive reaction of 20 mm of induration and erythema at 48 hours. The same skin test applied six months earlier during a routine physical examination was negative.

Smears taken from the wound were positive for acid-fast bacilli by Ziehl-Neelsen and fluorochrome stains. Cultures for acid-fast bacilli on Loewenstein-Jensen medium at 37 C were positive at four weeks for *M tuberculosis* var *hominis*. Cultures for atypical mycobacteria and other bacterial and fungal cultures were negative.

An incisional biopsy specimen of the lesion was obtained. Histologically, a granulomatous infiltrate was present in the papillary and reticular dermis (Fig 2). Tubercles made up of central foci of epithelioid cells, and a dense collar of lymphocytes and histiocytes peripherally prevailed (Fig 3). In addition, a perivascular round cell infiltrate was noted. The overlying epidermis was mildly acanthotic and spongiotic and showed mild orthohyperkeratosis. A Ziehl-Neelsen stain indicated rare acid-fast organisms (approximately one organism per five to eight high-power fields) (Fig 4).

Course

After the diagnosis of primary cutaneous inoculation tuberculosis was established, treatment was initiated with 300 mg isoniazid daily, 600 mg rifampin daily, and 50 mg pyridoxine hydrochloride per day. This regimen resulted in a dramatic resolution of the primary lesion, the regional adenopathy, and the systemic symptomatology within four weeks.

Interestingly, the patient's young daughter who "compassionately" had soaked her hand in her father's soaking solution, and may even have drunk some of it, developed a positive tine test after a negative test several months earlier. Three months later the patient's wife became tine-test positive.

COMMENT

Primary inoculation tuberculosis of the skin is the result of introduction of *M tuberculosis* into the traumatized skin or mucosa of a previously uninfected person. The site of entry may be a minor scratch, sore, hangnail, or puncture wound that may either heal

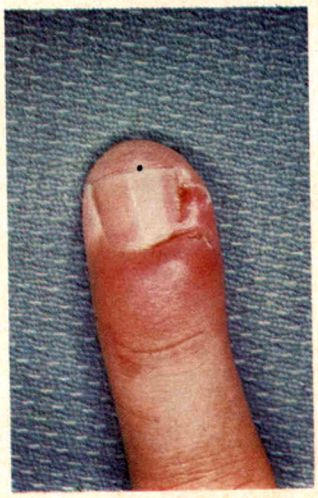

Fig 1.—Appearance of the paronychia lesion seven weeks after inoculation.

Fig 2.—Biopsy specimen of the lesion shows a tuberculous granulomatous infiltrate in the upper and middermis (hematoxylin-eosin, original magnification ×100).

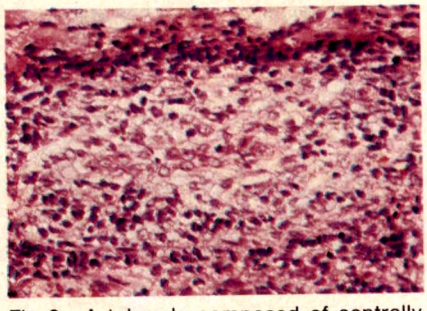

Fig 3.—A tubercle composed of centrally located epithelioid cells with a peripheral collar of histiocytes and lymphocytes (hematoxylin-eosin, original magnification ×240).

Fig 4.—A solitary, slender, bright red rod located in a vacuole (center) (Ziehl-Neelsen, original magnification ×1,000).

at first and later manifest as a tuberculous chancre or infection, or may slowly eventuate into a tuberculous ulceration after inoculation.[1-5] Characteristically, these lesions are more or less asymptomatic in contrast to staphylococcal or streptococcal infections. However, they may resemble syphilis, sporotrichosis, or atypical mycobacterial infections, all of which manifest painless regional lymph node enlargement as seen in primary inoculation tuberculosis.[1,2,4,6,7]

Varieties of traumatic skin lesions are legion, and so are the ways of contracting primary cutaneous inoculation tuberculosis. The most notorious and best recognized examples of this entity are prosector's warts acquired by pathologists or autopsy personnel in the process of handling tuberculotic cadavers.[4,8-10]

A tuberculous paronychia similar to that of our patient was observed by O'Donnell et al[11] in a nurse who cared for a child with unsuspected tuberculosis. Likewise a laboratory technician infected herself in performing guinea pig inoculations.[12] Poorly sterilized needles also have been implicated in primary tuberculotic infections of the skin.[13] A nurse with active tuberculosis administered intramuscular injections to patients, causing several primary infections at the injection sites.[14] Not only medical ministrations but also cosmetic surgical procedures may be involved in the disease. According to Michelson,[2] ear piercing resulted in primary tuberculosis; Dennis[15] describes its occurrence in a tattoo. The needling prick of an insect can also evolve into this condition.[1] A Good Samaritan developed primary tuberculosis of the left nasolabial fold after giving mouth-to-mouth resuscitation to a cardiac arrest patient who later was discovered to have active tuberculosis.[16]

These enumerated circumstances of acquiring primary cutaneous tuberculosis are uncommon. The majority of cases, especially in children, are contracted on the extremities or face through more common and mundane injuries of scratches, bruises, lacerations, nail punctures, or preexisting eczema, impetigo, or furuncles.[1,5,6,13,17-20] In occasional instances atypical mycobacteria, especially *M balnei*, might be responsible for the infection.

Besides primary infection of the skin, mucocutaneous inoculation has been noted frequently in the past. Miller[5] observed several cases occurring in the conjunctiva, and Scuderi and Cardia[21] listed a case subsequent to blepharoplasty. The same authors described primary lesions in the oral cavity,[21] an observation confirmed by many others.[5,19,22-24] Darlington and Salman[25] and Shengold and Sheingold[26] reported cases of primary inoculation tuberculosis of the oral cavity after tooth extractions.

Another infrequent mode of primary tuberculosis inoculation is via sexual intercourse with persons having tuberculosis of the genitourinary tract. Bjoernstad,[27] Fejér,[28] Strand,[29] and Agapkin[30] report several well-proven cases, and list a number of pertinent references to similar ones. Most tragic, however, are those instances of primary inoculation tuberculosis of the penis in infant boys subsequent to ritual circumcision. Holt's article[31] in 1913, lists 41 such cases, many of which have been traced to single operators with active pulmonary tuberculosis. In some of these cases the circumcision wound was sucked or rinsed with red wine from the operator's mouth. In this group 16 boys died of generalized miliary tuberculosis, some of tuberculous meningitis; in 12 others the eventual outcome was unknown. Wolff[32] reviewed the literature in 1921 and discovered a total of 56 cases of circumcision tuberculosis, as well as two additional cases of his own.

At the site of the inoculation with *M tuberculosis*, a tuberculous chancre forms within two to four weeks,[1,2,3] occasionally later and a regional and usually painless lymphadenopathy becomes prominent. The complex of the tuberculous chancre and regional adenopathy is the prototype of primary inoculation tuberculosis or primary cutaneous tuberculosis. This complex is the cutaneous analog of the primary tuberculous infection of the lung or the Ghon complex.[1,2,33,34] As opposed to primary inoculation tuberculosis, pseudoprimary cutaneous tuberculosis

signifies a tuberculous infection or reinfection of the skin in a patient with an active focus of tuberculosis elsewhere in the body.[1,2]

In all instances of mucosal or cutaneous primary inoculation tuberculosis, the axiom of no previous tuberculosis infection of the patient has to be inviolate before this diagnosis is applicable.[1,2,34] The best proof of this precondition is a negative skin test prior to the inoculation.[1,2,3]

In making this diagnosis, helpful information can be derived from the history of a poorly healing or initially healed and reactivated asymptomatic lesion with painless regional adenopathy, low-grade fever, and general symptoms of malaise, fatigue, and anorexia. The diagnosis, however, can only be established by demonstration of the organism in tissue smears, and by acid-fast stains in biopsy specimens and/or cultures, or by conversion of the skin test. Our patient fulfilled all of these criteria.

The histologic appearance of the lesion depends on its stage at the time of biopsy. In the early phase (three to four days), a mixed inflammatory infiltrate of polymorphonuclear leukocytes and lymphocytes is present throughout the dermis, with many acid-fast organisms visible on Ziehl-Neelsen stain.[1,2,35,36] Later, when tuberculous granulomas of giant cells, epithelioid cells, and lymphocytes are forming in response to the infection, the acid-fast bacilli are becoming scarce and often cannot be demonstrated.[1,2,35] Prominent caseation necrosis may be observed.[1,35]

The differential diagnosis of primary inoculation tuberculosis extends over the spectrum of chancriform conditions of deep fungal or bacterial origin such as sporotrichosis, blastomycosis, histoplasmosis, coccidioidomycosis, nocardiosis, syphilis, leishmaniasis, yaws, tularemia, and atypical mycobacterial disease.[37] These conditions can be readily excluded by serologic studies, cultures, skin biopsies, tissue smears, and historical and physical findings.

Therapeutically, the "first-line" drugs, isoniazid, streptomycin, and aminosalicylic acid, and "second-line" drugs, ethambutol, ethionamide, and rifampin, are considered for treatment.[38] Our patient responded dramatically to rifampin, isoniazid, and pyridoxine hydrochloride, with resolution of the primary lesion, clearing of the adenopathy, and freedom from systemic symptoms.

Complications of primary inoculation tuberculosis of the skin are rare miliary tuberculosis[19] and tuberculous meningitis[19]; erythema nodosum,[1,19,39] phlyctenular conjunctivitis,[19] tuberculous osteomyelitis[40]; and spontaneously draining tuberculous abscesses of lymph nodes.[19] In general the prognosis is good even in untreated cases.[1]

Whereas systemic spread of primary inoculation tuberculosis is rare,[41] this phenomenon is almost the rule in primary inoculation tuberculosis of circumcision wounds, with a death rate approximating 40%.[1,31,32] Fortunately this type of primary inoculation tuberculosis is nearly extinct. To our knowledge, the most recent case dates back to 1963.[42]

Although primary inoculation tuberculosis has become very rare in this country, occasional case reports and reviews help to reacquaint us and increase physicians' awareness of this occasionally reemerging, intriguing entity.

Nonproprietary Names and Trademarks of Drugs

Ethionamide—*Trecator-SC.*
Rifampin—*Rifadin, Rimactane.*

References

1. O'Leary PA, Harrison MW: Inoculation tuberculosis. *Arch Dermatol Syph* 44:371-390, 1941.
2. Michelson HE: The primary complex of tuberculosis of the skin. *Arch Dermatol Syph* 32:589-601, 1935.
3. Grady ED: Cutaneous inoculation tuberculosis. *Am Rev Tuberc* 63:526-537, 1951.
4. Miller FJW: Management of children with primary tuberculosis. *Br J Med* 2:1015-1020, 1952.
5. Miller FJW: Recognition of primary tuberculous infection of skin and mucosae. *Lancet* 1:5-9, 1953.
6. Walzer H: Discussion on primary inoculation tuberculosis of the skin. *Arch Dermatol* 100:646-647, 1969.
7. Wien MS, Cornbleet T: Inoculation tuberculosis of the skin simulating sporotrichosis. *Arch Dermatol Syph* 16:312-316, 1927.
8. Fidler HK: The primary cutaneous tuberculosis complex. *JAMA* 108:2034-2035, 1937.
9. Minkowitz S, Brandt LJ, Rapp Y, et al: Prosector's wart (cutaneous tuberculosis) in a medical student. *Am J Clin Pathol* 51:260-263, 1969.
10. Carr DT, Janes JM, Brunsting, LA: Primary inoculation tuberculosis of the thumb. *Proc Staff Meeting Mayo Clin* 32:386-388, 1957.
11. O'Donnell TF, Jurgenson PF, Weyerich NF: An occupational hazard: Tuberculous paronychia. *Arch Surg* 103:757-758, 1971.
12. Sahn SE, Pierson DJ: Primary cutaneous inoculation drug-resistant tuberculosis. *Am J Med* 57:676-678, 1974.
13. Valledor T, Exposito L, Costales F, et al: Tuberculosis primaria de la Piel en la infancia. *Rev Cub Pediatria* 26:147-188, 1954.
14. Heycock JB, Noble TC: Four cases of syringe transmitted tuberculosis. *Tubercle* 42:25-27, 1961.
15. Dennis JA, in discussion, Epstein, NN: Primary tuberculous complex of the skin. *Arch Dermatol Syph* 51:316-324, 1945.
16. Heilman KM, Muschenheim C: Primary cutaneous tuberculosis resulting from mouth-to-mouth respiration. *N Engl J Med* 273:1035-1036, 1965.
17. London I: Primary inoculation tuberculosis. *Arch Dermatol* 106:264, 1972.
18. Fisher I, Orkin M: Primary tuberculosis of the skin. *JAMA* 195:174-176, 1966.
19. Miller FJW, Cashman JM: The natural history of peripheral tuberculotic lymphadenitis associated with a visible primary focus. *Lancet* 1:1286-1289, 1955.
20. Canby JP: Primary cutaneous tuberculosis. *Pediatrics* 63:331-333, 1963.
21. Scuderi G, Cardia L: Nodular tuberculosis of the skin of the lids and of the regional lymph nodes. *Rev Bras Biol* 23:89-97, 1964.
22. Rimbaud P, Ravoire J, Duntze F: Chancre d'inoculation tuberculeux cutané avec volumineuse adenopathie inflammatoire. *Bull Soc Fr Dermatol Syph* 64:766-767, 1958.
23. Fouquet J: Les primo-infections cutanées et mugueuses. *Hospitals* 44:113-115, 1956.
24. Fouquet J, Heimann V, Teyssier L, et al: Les primo-infections cutanées et mugueuses: Considérations à leurs propos sur la pathogénie et le traitement des primo-infections tuberculeuses. *Rev Tuberc* 20:709-720, 1956.
25. Darlington CC, Salman I: Tuberculous lesions. *Am Rev Tuberc* 35:147-179, 1937.
26. Shengold MA, Sheingold H: Oral tuberculosis. *Oral Surg* 4:239-250, 1951.
27. Bjoernstad R: Tuberculous primary infection of genitalia. *Acta Dermatol Venereol* 27:106-114, 1947.
28. Fejér A: Sur la question de la tuberculose des organes genitaux externes à propos de deux cas très rares. *Acta Dermatol Venereol* 29:488-505, 1929.
29. Strand S: Tubercular primary lesion on penis: Chancre penis: Venereal tuberculosis. *Acta Dermatol Venereol* 26:461-470, 1946.
30. Agapkin IN: Primary tuberculous skin lesion of the penis. *Vestn Dermatol Venerol* 5:25-27, 1963.
31. Holt LE: Tuberculosis acquired through ritual circumcision. *JAMA* 61:99-102, 1913.
32. Wolff E: Ueber die Zirkumzisions-tuberkulose. *Klin Wochenschr* 58:1531-1533, 1921.
33. Ghon A: The primary complex in human tuberculosis and its significance. *Am Rev Tuberc* 7:314-317, 1923.
34. Ranke KE: Primaere, sekundaere und tertiaere Tuberkulose des Menschen. *Munch Med Wochenschr* 1:305-308, 1917.
35. Lever W, Schaumburg-Lever G: *Histopathology of the Skin*, ed 5. New York, JB Lippincott Co, 1975, p 278.
36. Montgomery H: Histopathology of various types of cutaneous tuberculosis. *Arch Dermatol Syph* 35:698-715, 1937.
37. Wilson JW: Comparative immunologic aspects of deep fungus disease. *Cutis* 16:231-234, 1975.
38. Wolff K: Mycobacterial diseases: Tuberculosis, in Fitzpatrick TB, Arndt KA, Clark WH, et al (eds): *Dermatology in General Medicine*. New York, McGraw Hill Book Co, 1971, pp 1743-1768.
39. Rotnes PL: Tuberkuloeser Primaer-komplex auf der Haut eines Erwachsenen. *Dermatol Wochenschr* 95:1605-1608, 1932.
40. Ackerberg E: Zwei Faelle von tuberkuloesen Primaer-komplexen der Haut und der Gingiva. *Acta Dermatol Venereol* 14:127-133, 1933.
41. Duken J: Ueber Verlaufsarten der extrapulmonalen Primaer-tuberkulose. *Z Kinderheilkd* 55:687-694, 1933.
42. Rollier R, Rollier M: Chancre tuberculeux de la verge chez un jeune musulman après circoncision. *Bull Soc Fr Dermatol Syph* 70:155-156, 1963.

Carcinoid in an Umbilical Nodule

Harold J. Brody, MD; William P. Stallings, MD; Robert M. Fine, MD; Ayten Someren, MD

• An umbilical nodule may be an early or late sign of metastasis from an internal location. To our knowledge, we are reporting the first case of carcinoid occurring as an umbilical mass.

The occurrence in our patient of idiopathic hyperparathyroidism, diabetes mellitus, and carcinoid suggests the diagnosis of multiple endocrine adenomatosis, type I, which may result from a developmental defect in the amine and amine precursor uptake and decarboxylation cell system.

(*Arch Dermatol* 114:570-572, 1978)

Tumors of the umbilicus are rare; they may be caused by granulomas, endometriomas, primary neoplasms, or metastatic deposits from carcinomata of the internal organs. We are reporting the case of a woman with probable metastatic carcinoid of the umbilicus. We were unable to find a similar case report in the literature.

REPORT OF A CASE

A 75-year-old woman was seen in the Dermatology Clinic of Grady Memorial (Atlanta) Hospital for evaluation of a slightly tender hyperpigmented 1 × 1-cm nodule that was noted five months previously (Fig 1). The initial impression was foreign body granuloma, and she received two intralesional steroid injections of triamcinolone at monthly intervals. When there was no improvement two months after her initial visit, a biopsy of the lesion was performed under local anesthesia.

Examination of the biopsy material following fixation in 10% formaldehyde solution revealed an intact epidermis. The dermis was infiltrated by solid islands, nests, and cords of tumor cells, separated by collagenous stroma (Fig 2). The cells were uniform in size and shape; however, those cells located at the periphery of the nests were slightly larger and more elongated (Fig 3). The nuclei were small, round, and uniform. The cytoplasms were abundant and contained eosinophilic granular secretory material easily seen with the routine hematoxylin-eosin stains. Masson-Fontana stains for argentaffin granules were strongly positive. The granular secretory product, present throughout the islands of tumor cells, was prominently aggregated at the periphery of these islands (Fig 4). Periodic acid, Schiff and mucicarmine stains were negative.

The general appearance on HE-stained sections was interpreted as carcinoid tumor with "A type" structural characteristics.[1] This pattern, together with "type 2" cell population[2] as seen on Masson-Fontana stains, was thought to be consistent with that of a carcinoid tumor of midgut origin, with possible primary site in small intestine or proximal colon (Fig 5). Although rarely malignant and metastasizing,[3,4] a primary ovarian carcinoid was also a consideration.

The patient was admitted to the Dermatology Service with a history of a 9-kg weight loss in six months, anorexia, and generalized arthralgias. She denied flushing, diarrhea, nausea, and vomiting. The patient had a history of diet-controlled adult-onset diabetes mellitus and also of a partial parathyroidectomy two years previously for idiopathic hyperparathyroidism. Sections of parathyroid gland at that time revealed nodular chief cell hyperplasia. She had been maintaining borderline high calcium levels in the range of 9.5 to 11.2 mg/100 ml for the last 1½ years.

Results of physical examination revealed an area of induration distorting the normal umbilical architecture. The thyroid was not enlarged and was without nodules. The abdomen was soft and without organomeg-

Fig 1.—Initial presentation: 1 × 1-cm nodule with periumbilical induration distorting normal umbilical architecture.

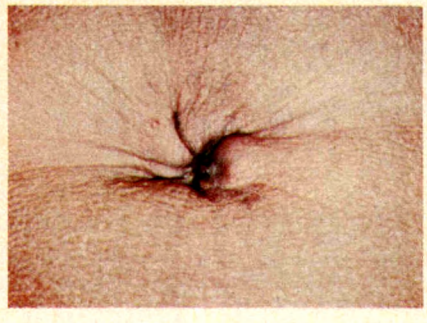

Fig 2.—Low-power of upper part of tumor in dermis showing islands and infiltrating nests of uniform cells and fibrous stroma (hematoxylin-eosin, original magnification ×78).

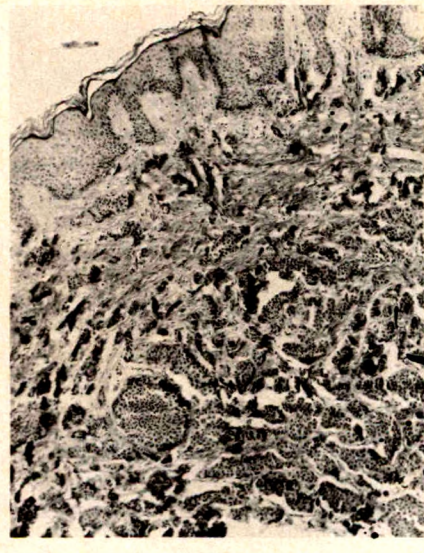

Accepted for publication April 13, 1977.

From the Departments of Dermatology (Drs Brody and Stallings) and Pathology (Dr Someren), Emory University School of Medicine (Dr Fine), Grady Memorial Hospital, and the Department of Dermatology (Dr Fine), Atlanta Veterans Administration Hospital (Dr Fine), Atlanta.

Reprint requests to Department of Dermatology, Emory University School of Medicine, 215 Woodruff Memorial Bldg, Atlanta, GA 30307 (Dr Brody).

aly. Results of a pelvic examination showed an irregular uterus of about eight weeks' gestation in size and no adnexal masses although the examination was far from optimal because of poor patient cooperation. She was thought to have uterine leiomyomatosis.

The following laboratory values were within normal levels: complete blood count, serum electrolytes, urinalysis, alkaline phosphatase, SGOT, lactic dehydrogenase, bilirubin, cholesterol, uric acid, total protein, albumin, morning plasma cortisol, serum calcitonin, serum luteinizing hormone, serum follicle-stimulating hormone, carcinoembryogenic antigen, and alpha feto-protein. The calcium level was 10.6 mg/100 ml (normal, 8.5 to 10.8 mg/100 ml) and the phosphorus level was 2.4 mg/100 ml (normal, 2.3 to 4.8 mg/100 ml). The patient had maintained documented fasting blood glucoses in the range of 200 to 300 mg/100 ml for the preceding two years but was now diet-controlled and maintaining a fasting blood glucose in the range of 120 to 140 mg/100 ml. Thyroid radioimmunoassay for T3 and T4 was within normal limits. Electrocardiogram showed a primary heart block with poor anterior forces. Liver-spleen scan, bone scan, protein electrophoresis, chest roentgenogram, and skull roentgenogram with view of the sella tursica were normal. Colonoscopy to the ileum showed no abnormalities. Barium enema showed effacement of the rectosigmoid area by a possible mass, and pelvic ultrasound revealed a mass in the left pelvis, probably an enlarged uterus, with a second mass below the umbilicus. A soft tissue mass in the left abdomen separate from the kidney was visualized on intravenous pyelography. Upper gastrointestinal (GI) series with small bowel follow-through showed rotation of the midgut but no evidence of obstruction or a mass. Twenty-four hour catheterized urine for 5-hydroxyindole acetic acid was 44 mg/24 hr (normal, less than 10 mg/24 hr). The patient was not thought to be a candidate for abdominal laparotomy.

Fig 3.—Higher power view of tumor composed of solid islands and nests of uniform cells with peripheral enlargement and elongation (hematoxylin-eosin, original magnification ×200).

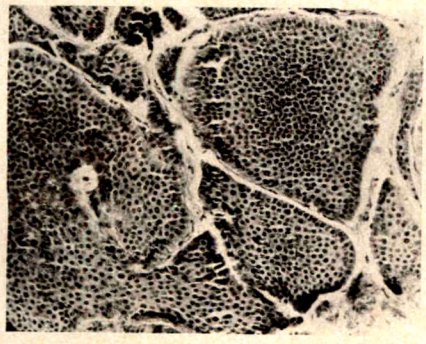

Fig 4.—Tumor cells showing diffuse positive argentaffin reaction with peripheral granule aggregation (Fontana's silver method, original magnification ×200).

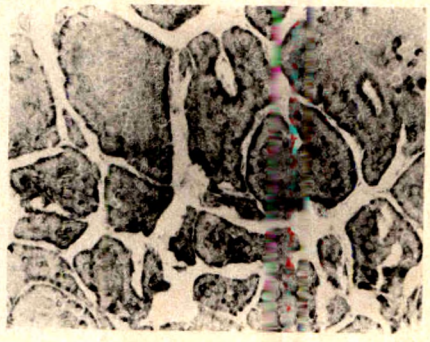

COMMENT

The clinical appearance of a nodule in or around the umbilicus is strongly suggestive of metastatic carcinoma; however, other conditions, such as endometriosis, primary umbilical carcinoma, granulomas caused by foreign body reactions to talc or buried hairs,[5] pyogenic granulomas, and persistent vitelline duct polyps,[6] must be considered. Biopsy can easily confirm the diagnosis. The most common tumor to metastasize to the umbilicus is gastric adenocarcinoma or the so-called Sister Joseph's nodule. Metastases from the pancreas, colon, ovary, gallbladder, kidney, breast, fallopian tube, and prostate are less common than from the stomach.[7] Norman et al[8] found six cases of GI tract carcinoid metastatic to skin; only two were symptomatic, and both had multiple cutaneous nodules. Of the four asymptomatic patients, two had single and two had multiple metastases; the affected sites were flank, axilla, chest, nose, and shoulder. In our patient, an elevated 5-hydroxyindole acetic acid level and a subumbilical mass distin-

Fig 5.—Predominant morphological features of carcinoids in relation to primary growth sites.

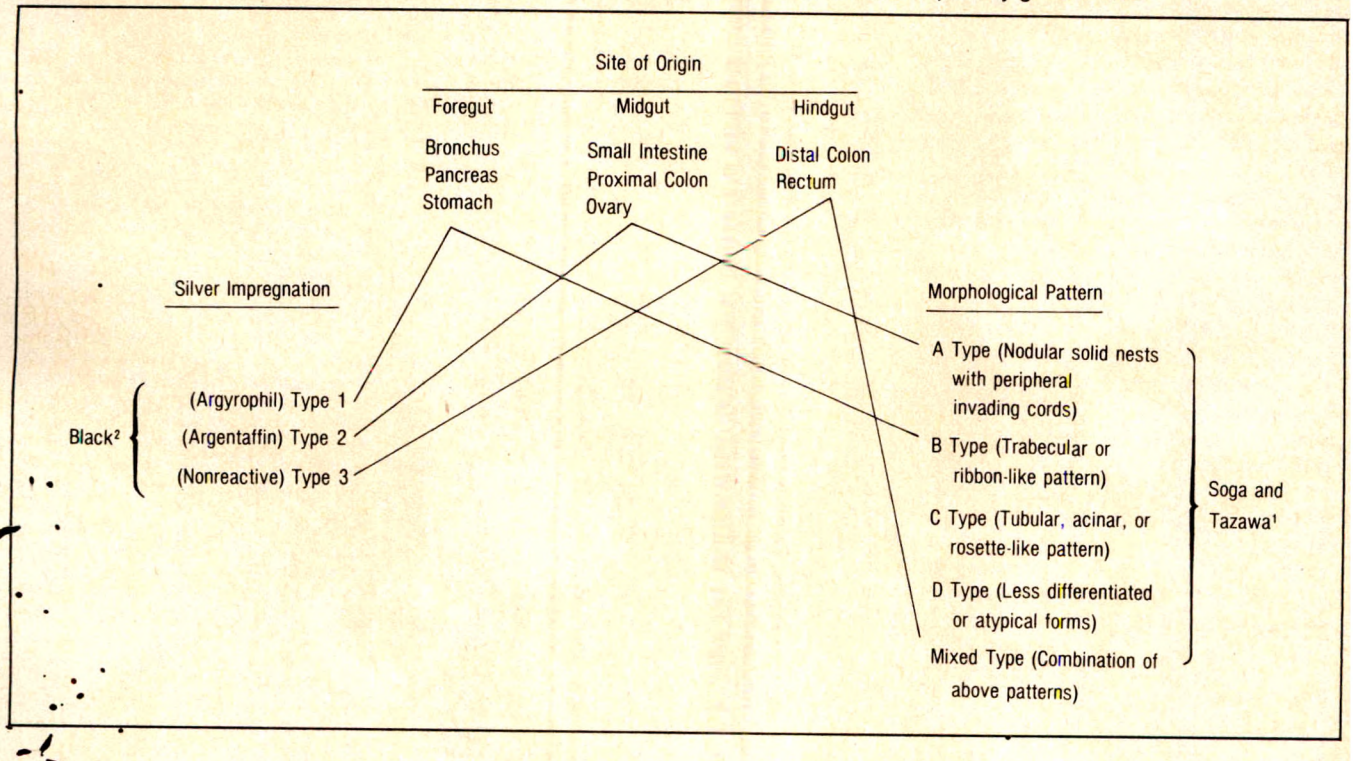

guished by pelvic ultrasound favor a metastatic process. Unfortunately, surgical verification was not practical in this case.

Although primary adenocarcinoma of the umbilicus is quite rare, primary carcinoid of the umbilicus is even more unusual. Primary umbilical tumors are assumed to arise from umbilical skin or in ectopic tissues, such as remnants of the omphalomesenteric duct or the uracus, or possibly in a preexisting benign endometrioma. Van Dijk and Ten Seldam[9] recently described a possible primary cutaneous carcinoid occurring as a scalp tumor in a woman who was flushed but otherwise asymptomatic without internal evidence of disease. They postulated a neuroectodermal derivation of the enterochromaffin cells as a possible origin for primary carcinoid of the skin. This is also suggested by Samaan et al[10] who described three patients with hyperparathyroidism, secondary to either adenoma or hyperplasia, and carcinoid of the GI tract. Parathyroid adenoma has been described in association with pulmonary carcinoid tumors as well.[11] The occasional association of these two tumors suggests the possibility of a common neuroectodermal origin of the peptide-secreting endocrine glands.

The simultaneous occurrence of multiple endocrine adenomatosis is now being recognized more frequently. Pearse[12] recently has put forward an interesting hypothesis to explain this association that conceptualizes a widely distributed microendocrine system that is functionally related to the synthesis and storage of polypeptide hormones. This system is composed of about 13 members of the amine and amine precursor uptake and decarboxylation (APUD) cell series. Included in this system are pancreatic islet cells, pituitary corticotrophs and melanotrophs, thyroid parafollicular cells, GI argyrophil and argentaffin cells, and adrenal medullary cells. All of these cells derive from neural crest elements[12,13] that migrate into primitive gut and that mature into endocrine cells. Neuroendocrine cells and related argyrophil and argentaffin cells are present throughout the gut and have the capacity to develop into peptide-producing endocrine tumors.

Although deriving from a common neuroectodermal origin, argyrophil and argentaffin cells have different characteristics. Argyrophil cells, "type 1 cells" of Black,[2] are more characteristic of the APUD cell series and have broader enzymatic activity. They are more numerous in the stomach, particularly in the pylorus and in the tissues formed as outpouching of the primitive foregut (pancreatic islets, bronchial mucosa, thyroid, and anterior pituitary) (Fig 5). Carcinoid tumors arising from the primitive foregut frequently have trabecular or ribbon-like structure "type B."[1] They contain argyrophil cells and are functional, with a varied endocrine potential (insulin, glucagon, gastrin, adrenocorticotropic hormone, melanocyte-stimulating hormone, catecholamine, kinins, histamine, serotonin).

Argentaffin cells are more numerous in the deeper glandular layers and crypts of the small intestine and proximal colon. Midgut carcinoids are composed of argentaffin "type 2" cells,[2] with "A type" structure,[1] producing nodular solid nests and peripheral invading cords. Argentaffin cells have no distinctive pattern of enzyme activity, produce serotonin and kallikrein, and are more likely to give rise to the carcinoid syndrome.

"Type 3" enterochromaffin cells of Black are more frequently in the hindgut and are argyrophil and argentaffin negative. Hindgut carcinoids show "mixed type" of structure[1] and are functionless.

It is now clear that the carcinoid tumor is common to a group of neoplasms that are histogenetically related. They occur in all areas where argyrophil-argentaffin cells exist. Histological similarities between carcinoids, islet cell tumors, and thyroid medullary carcinomas are also well recognized. Ectopic hormone production by these tumors underlie diverse clinical syndromes. The association of adenomas concurrently affecting multiple endocrine organs reflects the basic defect in the development of the APUD cell system, which may explain the etiology of the multiple endocrine adenomatosis.

Our patient could not be classified precisely into either type I (tumors of pituitary, pancreas, and parathyroids, resulting in hyperparathyroidism) or type II (pheochromocytoma, medullary thyroid carcinoma, hyperparathyroidism). She conceivably has multiple endocrine adenomatosis type I since hyperparathyroidism, carcinoid, and diabetes mellitus are present. Multiple endocrine adenomatosis type I has been associated with carcinoid tumors.[14]

To our knowledge, this is the first case of carcinoid to be reported as an umbilical mass, and this neoplasm must be included in any comprehensive differential diagnosis of umbilical nodules.

The Dermatology Foundation of Atlanta provided funds for printing the color photograph in this article.

Zeynel Karcioglu, MD, was the attending pathologist for the patient during her hospitalization.

Nonproprietary Name and Trademarks of Drug

Triamcinolone—*Aristocort Tablets, Kenacort.*

References

1. Soga J, Tazawa K: Pathologic analysis of carcinoids: Histologic re-evaluation of 62 cases. *Cancer* 28:990-998, 1971.

2. Black WC: Enterochromaffin cell types and corresponding carcinoid tumors. *Lab Invest* 19:473-486, 1968.

3. Quzilbash AH, et al: Functioning primary carcinoid tumor of the ovary: A light and electron-microscopic study with review of the literature. *Am J Clin Pathol* 62:629-638, 1974.

4. Scully RE: Recent progress in ovarian cancer. *Human Pathol* 1:73-98, 1970.

5. Samitz MH: Umbilical metastasis from carcinoma of the stomach: Sister Joseph's nodule. *Arch Dermatol* 111:1478-1479, 1975.

6. Shaffer B, et al: Ectopic gastrointestinal mucosa in the form of umbilical polyp. *Ann Dermatol Syph* 70:217, 1954.

7. Horn JJ, Fred HL, Lane Mantague, et al: Umbilical metastasis. *Arch Intern Med* 114:799-802, 1964.

8. Norman JL, Cunningham PJ, Cleveland BR, et al: Skin and subcutaneous metastasis from gastrointestinal carcinoid tumors. *Arch Surg* 103:767-769, 1971.

9. Van Dijk C, Ten Seldam REJ: A possible primary cutaneous carcinoid. *Cancer* 36:1016-1020, 1975.

10. Samaan NA, et al: Hyperparathyroidism and carcinoid tumor. *Ann Intern Med* 82:205-207, 1975.

11. Williams ED, Celestin LR: The association of bronchial carcinoid and pluriglandular adenomatosis. *Thorax* 17:120-127, 1962.

12. Pearse AGE: The cytochemistry and ultrastructure of polypeptide hormone producing cells of the APUD series and the embryologic, physiologic and pathologic implication of the concept. *J Histochem Cytochem* 17:303-313, 1969.

13. Bolande RP: The neurocristopathies: A unifying concept of disease arising in neural crest maldevelopment. *Human Pathol* 5:409-429, 1974.

14. Schein PS: NIH conference: Islet cell tumors: Current concepts and management. *Ann Intern Med* 79:239-257, 1973.

15. Brownstein MH, Helwig EB: Metastastic tumors of the skin. *Cancer* 29:1298-1307, 1972.

Cutaneous Signs of Spinal Dysraphism

Report of a Patient With a Tail-like Lipoma and Review of 200 Cases in the Literature

Vida Tavafoghi, MD; Amir Ghandchi, MD; George W. Hambrick, Jr, MD; George B. Udverhelyi, MD

The term "spinal dysraphism" was coined in 1940 by Dr Lichtenstein to designate incomplete fusion or malformations of structures in the dorsal midline of the back, particularly congenital abnormalities of the vertebral column and spinal cord. Raphes develop on the face and head, brancheal arches, sternum, and spinal column. When dysraphism occurs in these sites, failure of closure of fontanelles, cleft lip and palate, brancheal cysts, and abnormalities of the ribs and spine result.

A review of 200 cases of occult spinal dysraphism showed the condition to be more common in female patients and to be associated with cutaneous signs in more than 50% of instances. The age at which neurologic symptoms appeared in recorded cases is from birth to 76 years, the average being three years. A case of spinal dysraphism with a tail-like cutaneous structure is presented. The cutaneous manifestations accompanying spinal dysraphism that may lead to early recognition of this syndrome and early institution of treatment are discussed.

(*Arch Dermatol* 114:573-577, 1978)

A raphe is a seam or line of junction of symmetrical structures. Embryonally, in multicellular organisms numerous raphes result from the joining of paired structures, especially in the midline of the body. Raphes develop on the face and head, branchial arches, sternum, and spinal column. When dysraphism occurs in these sites, failure of closure of fontanelles, cleft lip and palate, branchial cysts, and abnormalities of the ribs and spine result.

Since the skin and nervous system are intimately related by their common ectodermal origin, it may be expected that anomalies of both the nervous system and of the skin occur together. The phacomatoses are well-known examples. Less well known are the cutaneous abnormalities that are associated with spinal anomalies in the lumbosacral regions.

The term "spinal dysraphism," which was introduced by Henneberg, was revised by Lichtenstein in 1940[1] to signify incomplete fusion or malformation of midline embryonic structures. Many authors use the term to refer to a group of congenital abnormalities, including diastematomyelia[2] (split spinal cord), congenital intraspinal mass lesions, abnormal development of the spinal cord, and medullary conus usually associated with spina bifida or other vertebral anomalies. These may include abnormalities in the cutaneous, muscular, osseous, and vascular tissues. Cutaneous changes overlying the defect include dimple, hemangioma, hyperpigmentation, hypertrichosis, lipoma, or scar.

Our purposes are to stress the cutaneous manifestations accompanying spinal dysraphism and to emphasize the responsibility of physicians, particularly pediatricians, urologists, neurologists, and dermatologists, for early recognition of the syndrome so that appropriate treatment may be achieved early. Our patient with a cutaneous tail-like tumor illustrates many of the features and treatment of the syndrome.

Spinal dysraphism falls into four types, according to developmental error[3]: (1) simple incomplete fusion of structure, such as spina bifida; (2) failure of separation of the germinal layers, ectoderm, mesoderm, and endoderm. A deep dermal dimple is an example of this group. (3) Abnormal growth of cell nests, such as cells from one germinal layer remaining among the cells of another. A part of the cutaneous ectoderm may remain with the mesoderm and may give rise to the dermoid or epidermoid cyst.[4] (4) A disturbance of the growth of otherwise normal tissue leading to the formation of intraspinal and even intramedullary lipoma.

The lesions affecting the spinal cord for general purposes are classified into three groups, according to their mode of action.[5] The first group consists of lesions causing pressure which include intrathecal lipoma, intradural, extradural, or both, transverse bands of ligamentous origin usually extradural, inverted laminae, intrathecal dermoid cysts, neurofibromas, or septa associated with diastematomyelia. The second group consists of lesions causing traction; lesions preventing the ascent of the spinal cord have a traction effect, fixing it at a definite level in the vertebral canal. The rates of growth of the spinal cord and vertebral column are different in the growing child. The length of the vertebral column increases at a greater rate than the spinal cord, which results in the ascent of the spinal cord within the vertebral canal. The distal end of the spinal cord is normally situated at or about the upper border of the body of the third lumbar vertebra and at the end of growth at the lower border of the body of the first lumbar vertebra or the upper border of the second. The most common lesion of this type is diastematomyelia, in which the spinal cord is bifid in part of its course. Fibrous bands may tether the spinal canal or cauda equina to the bone or skin directly or through attachment to the meninges. A persistent, tense filum terminale is also an example of traction lesions.[6] The third group consists of lesions causing traction and pressure; combinations of the previously mentioned lesions act together at the same time or separately at different times. It may be impossible to decide which is the cause of the damage.[7]

Clinically, spinal dysraphism may occur in an overt, easily recognized form, such as myelomeningocele or meningocele. The occult form of spinal dysraphism is easily missed.[8] A cutaneous sign usually evident at birth is present in more than half of such patients.

EMBRYOGENESIS OF THE ABNORMALITIES

The development of the lumbosacral area in the early embryo is complex and remains poorly understood. Comparable lesions have rarely been

Accepted for publication April 21, 1977.

From the Departments of Dermatology, Medicine, and Surgery, Johns Hopkins University, Baltimore. Drs Tavafoghi and Ghandchi are now with the No. 501 General Hospital and Eghbal Hospital, respectively, Tehran, Iran.

Presented at the American Medical Association meeting, Atlantic City, NJ, June 21, 1971.

Reprint requests to No. 35 Corner of Pahlavi and Iran Novin Ave, Tehran, Iran 14.

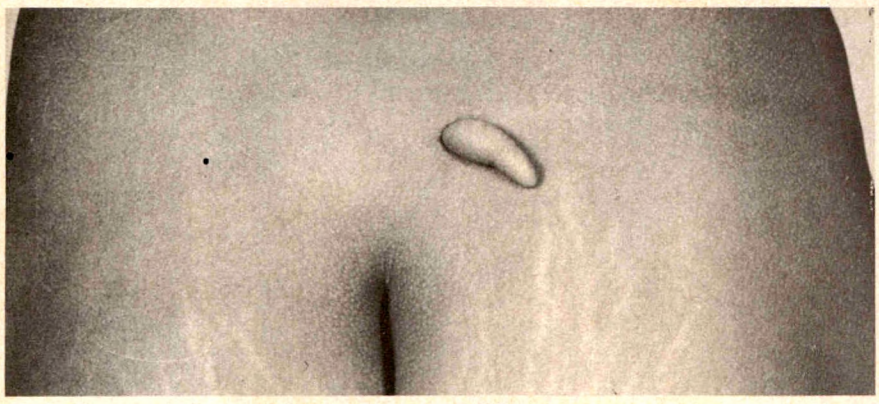

Fig 1.—Tail-like structure 4-cm long with 1.3 cm base just left of midline at L-5 to S-1.

Fig 2.—Close-up of structure in Fig 1, covered with numerous fine hairs.

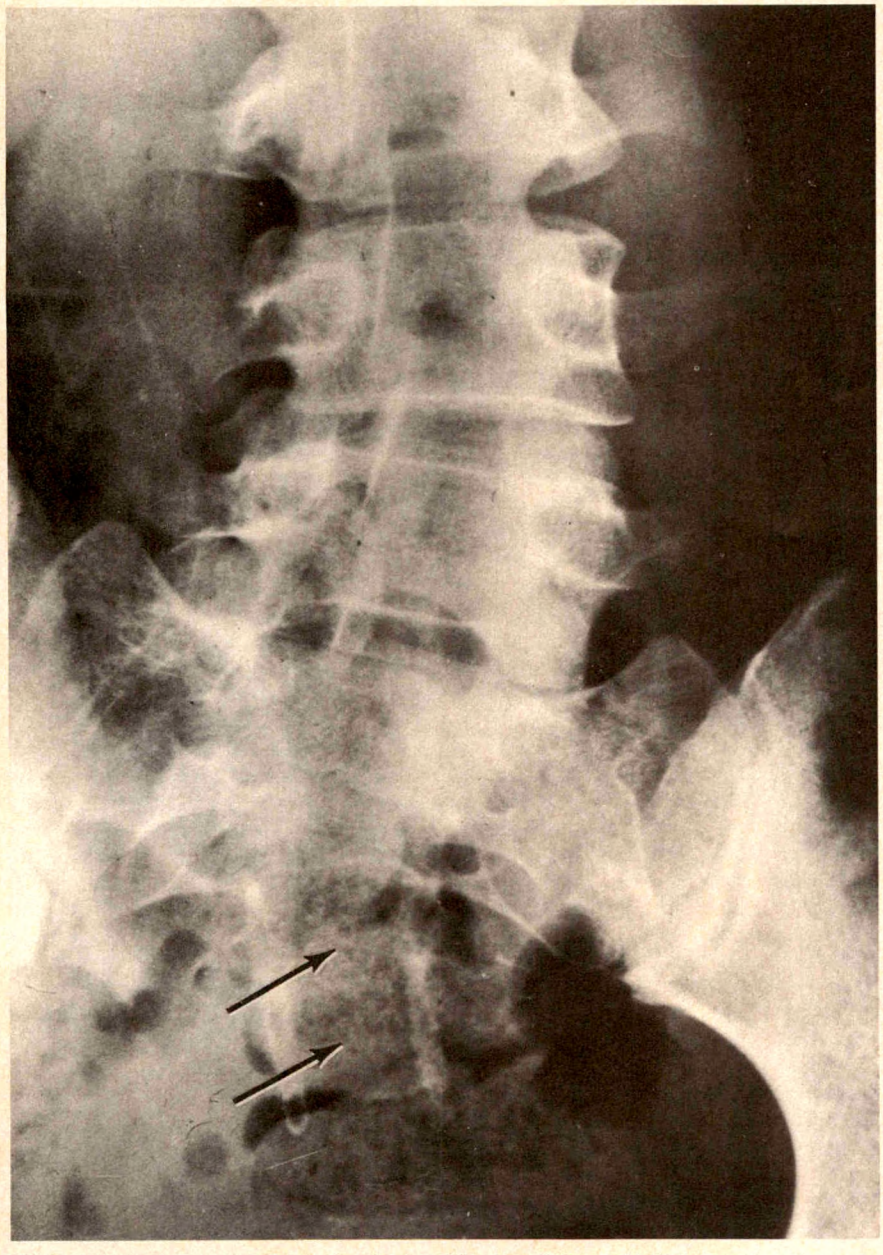

Fig 3.—Roentgenogram of spinal column with spina bifida of L-5 (arrows) and upper portion of sacrum, and absence of bodies of midsacral segments.

observed in animals. The neural groove in the ectoderm of the young embryo separates from the skin ectoderm and is surrounded by mesodermal structures to form the cerebrospinal axis. An abnormal event in some part of this process explains many forms of rachischisis. First, on closure of the groove, cells from the cutaneous ectoderm may be carried deeply along with neural ectodermal tissue and subsequently may give rise to the formation of a dermoid cyst, dermal sinus, or both, at any level of the spinal canal.

Second, the lower part of the spinal cord, ganglia, and associated nerve roots develop from a cellular mass known as "trunk-tail node, located caudal to the posterior neuropore." This may give rise to abnormalities, since in the earlier stages, these cells are pluripotential; thus, developmental errors involving cutaneous and/or neural ectoderm and mesoderm may result.

Third, the ascent of the tip of the conus from the second coccygeal level to third lumbar vertebral body occurs in the first 25 weeks of fetal life. A tethered or anchored conus prevents this event. This prolongation or anchoring may occur by several mechanisms: failure to ascent due to an abnormal filum terminale, binding down by a mass such as a lipoma or an abnormal sagittal splitting resulting in a bifid column and cord. The filum terminale is a normal remnant formed by a process of differentiation of the lowest portion of the early spinal cord attaching the conus of the spinal cord to the coccyx. Failure of this tissue to

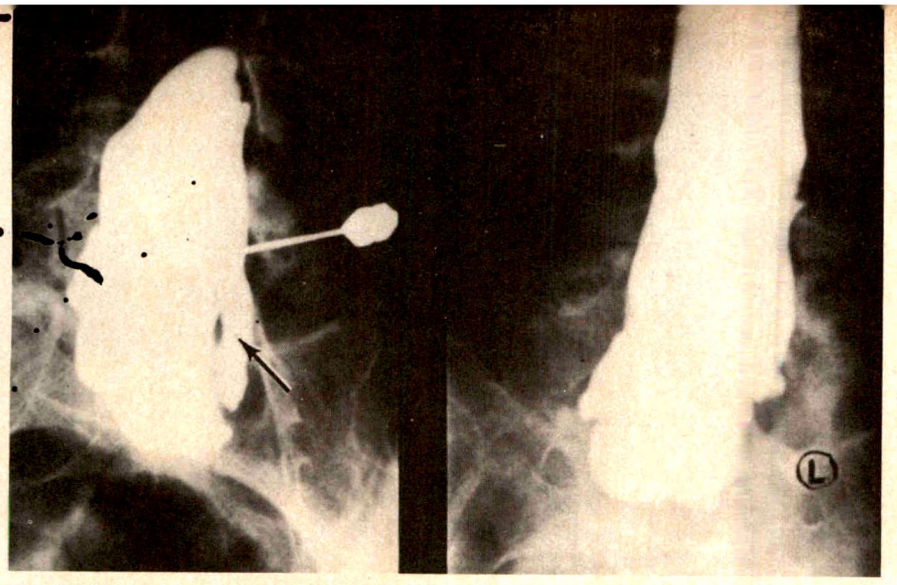

Fig 4.—Myelogram showing low tethered cord and large caudal pore indicating continuity with subcutaneous lipoma.

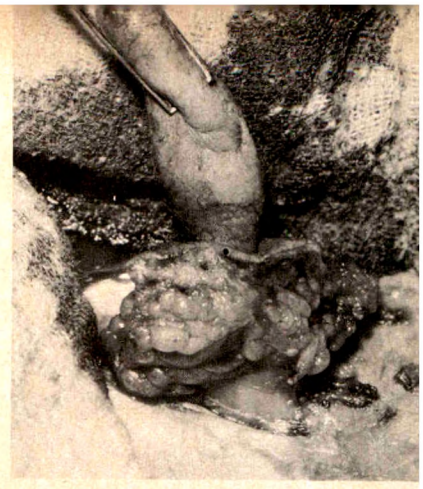

Fig 5.—Surgical removal of tail-like structure and connected subcutaneous lipoma.

Fig 6.—Section of tail-like structure and underlying lipoma (hematoxylin-eosin, low magnification).

undergo prominent differentiation leaves an abnormal prolongation of the conus; this is a common finding in children with dysraphism. Additionally, a double conus with cord prolongation representing the persistence of the sagittal splitting of caudal segments of the spinal axis occurs and is often accompanied by a double spinal column. Herniation of endoderm and ectoderm tissue through the midline gap may occur. Thus, spinal dysraphism may result from single or multiple disturbances during embryogenesis.

REPORT OF A CASE

A 21-year-old woman was referred to the Dermatology Clinic in January 1970 for removal of a tail-like lesion on her lower back. This was cosmetically embarrassing. She stated that it had grown only slightly through the years.

Her parents were healthy, and her mother had had a normal pregnancy and an uneventful delivery. There was no consanguinity in the family. At birth, she was noted to have a tail-like lesion. In early childhood, the patient was noted by her mother to have an abnormal weakness of the left leg. By age 9 years, the patient had developed a distinct limp that had not progressed. At the same time, she began to have pelvic pain and tightness with ambulation.

At age 16 years, an equinovarus deformity of the left foot resulted in an infected pressure ulcer of the plantar surface at the level of the metatarsal. The ulcer healed with medical treatment. Orthopedic procedures for correction of the left foot deformity were performed at ages 16 and 17 years.

Although her foot deformities were improved by surgery, she continued to experience intermittent swelling, excessive sweating, and coolness of the skin of the distal portion of the left leg. In her late teens, she began to develop urinary disturbances, consisting of hesitation and retention. She was examined by a urologist, and a diagnosis of neurogenic bladder was made. Despite multiple urologic and orthopedic examinations, no particular attention was directed to the cutaneous lesion and the possibility of an underlying neurologic defect.

Results of physical examination showed that the patient was well developed and of normal mentality. Results of examination of the skin showed a tapering tail-like structure 4 cm long with a base of 1.3 cm just to the left of the midline at the level of L-5 to S-1 (Fig 1). It was soft and nontender to palpation and was covered by normal skin that contained numerous fine hairs (Fig 2). Results of neurologic examination showed saddle hypoesthesia involving the S-3, S-4, S-5 dermatomes; this was more apparent on the left than on the right. Ankle and knee jerks were absent in the left leg, but were brisk in the right. Plantar response was flexion in the right foot but absent in the left. The patient's left calf measured 2 cm less than that of the right. There was a definite weakness of dorsal and plantar flexion of the left foot, with shortening of the entire left leg.

Laboratory studies disclosed the following values: WBC, 7,400/cu mm with normal differential cell count; RBC, 3,800,000/cu mm; hemoglobin 12.2 gm/100 ml; hematocrit, 34%; normal urine; negative urine culture; negative complement-fixation for syphilis; and nonreactive VDRL. Cerebrospinal fluid showed 1 mononuclear cell; negative Pandy's test; protein, 45 mg/100 ml; and glucose, 54 mg/100 ml. A chest roentgenogram was normal.

A roentgenogram of the spinal column showed spina bifida of L-5 and the upper portion of the sacrum, as well as thinning or absence of the bodies of the midsacral segments. This suggested spinal dysraphism associated with tethering of the cord and accompanying lipoma (Fig 3). After referral to neurosurgery, a myelogram showed dysraphism, a low tethered cord with abortive diastematomyelia on the left. The distal cord was visible at S-1

Cutaneous Lesions of Spinal Dysraphism

Cutaneous Lesion	No. of Patients With Single Lesion Only	No. of Patients With Two Associated Lesions					No. of Patients With Three Lesions
		With Dimple	With Lipoma	With Hairy Tuft	With Pigmented Macule	With Vascular Nevus	
Dimple/sinus	25	...	7	4	1	1	8
Lipoma	28	0	...	5	0	2	6
Hairy patch	14	4	3	...	3	1	5
Pigmented macule	11	1	0	4	...	0	4
Vascular nevus	7	1	2	2	0	...	3

or S-2, and a large caudal pore with irregularities indicated continuity with subcutaneous fat or lipoma (Fig 4). The cervical and dorsal regions were normal. Results of urologic examination showed neurogenic bladder and saddle anesthesia. Results of orthopedic examination showed 1.5 cm shortening of the left leg; hammer toes deformities of the left second, third, fourth, and fifth toes; a sunken metatarsal arch; and a completely anesthetic foot. A diagnosis of spinal dysraphism with lipomatous growth involving the cord was made. Surgical exploration was carried out in March 1970, and the findings supported the clinical diagnosis (Fig 5).

Histopathologic sections of the tail-like skin lesion and underlying fatty tumor showed an essentially unremarkable epidermis with many hair follicles. A mild round-cell perivascular infiltrate was present in the upper cutis; normal skin appendages were present. Extending from middermis down to the depth of the specimen were sheets of mature fat cells intermingled with collagenous and fibrous tissues. A considerable number of nerves were present throughout the specimen (Fig 6).

Fourteen months postoperatively the patient had no pain and no paresthesia, and urinary incontinence had improved, although occasional dribbling occurred when she became excited. Sexual response improved in that she was able to have an orgasm for the first time.

On examination, the right leg was unchanged. She walked with ease, but still limped; some sensory blunting was still present along S-1, S-2, and S-3 dermatomes. The wound on the left plantar surface had healed. There was a good anal external sphincter tone.

REVIEW OF 200 CASES

Of 200 cases of spinal dysraphism reported in the literature since 1940, 119 involved female and 81 involved male patients. The age of onset for neurologic symptoms varied from birth to 76 years. The average age for initial neurologic signs was 3 years in both patients with and without cutaneous signs. The average age of first visit to a physician for recognition of the condition was 7 years. There were 102 patients with cutaneous signs (including hairy patch, lipoma, dimple and sinus, pigmented macule, vascular nevus, and bony prominence covered with normal skin and 98 without them. The histopathologic features of the cutaneous signs has not been investigated, particularly in the patients with hyperpigmentation, vascular nevus, or hairy patch.

Twenty-one patients were symptom-free, and the cutaneous sign was the only clinical evidence of the condition. In 70 patients, there was a single cutaneous sign, and in 32 a combination of cutaneous signs. There were 66 female and 36 male patients with cutaneous signs, and there were 59 female and 39 male patients without them.

Forty-six patients had dimples and sinuses (Table) (27 female and 19 male patients). Twenty-five patients had dimples or sinuses alone, and the rest had a combination of cutaneous findings. Skin dimples are small, round, depressed areas of skin formed by fixation of the skin to the underlying fibrous or bony structures. Dimples and sinuses in spinal dysraphism usually occur in the midline. They may be barely visible, but usually are several millimeters in diameter and often attach themselves to the underlying bone. They are usually located in the postanal area and may be continuous, with a fibrous band attached to the dura in the sacral canal that is often accompanied by an elongated conus. The postanal dimple is not always evidence of a deeper abnormality, but its presence warrants further investigation. The sinus tract of fibrous band attachment to the laminae and to the spinal cord may be connected to an underlying dermoid or teratoma within the canal. These must not be confused with the common pilonidal sinus, which has no connection with the subarachnoid space.

Subcutaneous lipomas were found in 41 patients (Table) (31 female and ten male patients). Twenty-eight had lipomas alone and 13 had combinations. Subcutaneous lipomas were often associated with spina bifida. These usually occurred in or near the midline of the lumbosacral region. All had intracanal extension of the lipoma.[9] In the skin, these may be large and round (up to 20 to 30 cm), at the base transversely, and 10 to 15 cm above the skin surface. Lassman and James encountered the largest tumors in their younger children,[10] while the smaller and less noticeable tumors occurred in older patients. These may appear only as a light tumefaction of the skin in the lower part of the back, but even so, are distinguishable from normal body fat in the obese. Congenital lipomas are histologically not encapsulated and are finely lobulated, much like subcutaneous fat.[11] It was noted by Lassman and James that lipomas that extend beyond the midline are likely to be associated with a meningocele. The skin overlying a lipoma is usually normal, although dimples, excessive hair, discharging sinus, nevus, or discoloration may be evident.

Hairy patch[12] occurred in 30 patients (Table) (22 female and eight male patients). Fourteen had abnormal hair only, and 16 had a combination of hairy patch and other signs. Abnormal hair growth is the most common cutaneous sign evident at birth. A careful examination is necessary to detect this particular stigma if it is minimal. Skeletal abnormalities may be present in other portions of the spinal column.[13] Hairy patch was frequently associated with diastematomyelia of the spinal cord. Inspection may show a dimple. Abnormal hair includes the following: "faun's tail," appearing as a hairy patch that is minimally several centimeters but commonly much wider and lozenge-shaped, and occurring as coarse hair several inches in length in the midline; "silky down," represented by fine, soft nonterminal or lanugo hairs limited to a discrete midline area; localized hypertrichosis, consisting of normal-appearing hair or slightly coarse hair over the lower part of the back.

Pigmented macules occurred in 11 patients (Table) (seven female and four male patients). Two had pigmented macules as a single cutaneous finding; nine others had combinations. No mention has been made about the exact histologic nature of these pigmented lesions. It is not clear as to whether they simply represent hypermelanosis or actually are nevi containing nevus cells.

Vascular nevi or hemangiomas were seen in seven patients (Table) (four female and three male patients). One had it as a single sign and six others had combinations. In one patient, a vascular nevus occurred with wrinkled skin in the lumbosacral region. Capillary hemangiomas of the port wine, flat type hemangiomas have been reported in the skin of the midline of the back. It is an unusual location for the ordinary capillary nevus and should be considered as part of spinal dysraphism until proved otherwise. Foot ulceration was observed in two female patients.

Two patients had bony, hard prominences of the lumbosacral areas, one of which was a bony abnormality covered by skin. The other was a lipoma with overlying bony laminae and normal skin. No congenital scar was encountered in this review. Congenital skin scars consist of small irregular areas of thinned, depigmented skin. These are usually situated in the midline of the lumbar region.

Of these 102 patients, 87 had documented spina bifida or other bony defects. Thirteen had no abnormality of the spine; one died and was not studied.

Abnormalities of the lower limbs, such as cava-varus and weakness, are the most common symptoms.[14] The affected leg is usually slightly shorter than the other. The child walks oddly, resembling one who has been wearing a tight shoe. Cava-varus foot may progress to paralytic valgus deformity. Sensory changes may occur as well, but may be difficult to detect in children. Trophic ulceration also may appear.

The speed of the patient's worsening condition varies. Micturition may first occur in the adult without evidence of abnormality in the legs. Progressive worsening occurs in most patients and may eventually lead to ulceration, paraplegia, and incontinence. Pain is not common. Differential diagnosis includes cerebral palsy, old poliomyelitis, Friedreich's ataxia, and local conditions of the feet.

Any of the cutaneous manifestations is an indication for investigation, including a careful neurologic examination, roentgenography of the spinal column,[15] and myelography. Plain roentgenograms of the spine will usually show a spina bifida or other abnormalities. Their absence on x-ray film does not exclude the possibility of an underlying abnormality. Myelography is the most reliable method for exact diagnosis and localization of the defect.[16] Spinal fluid is obtained for examination during myelography and is usually normal. Most show abnormalities in the myelogram, but a normal myelogram does not absolutely exclude spinal dysraphism.

Treatment is surgical,[17] consisting of laminectomy and exploration of the spinal cord. The main purpose of surgery is to prevent neurologic deterioration; in more than 90% of patients, improvement has followed the operation. Patients with progressive neurologic deficits must undergo exploration of the spinal cord. For those patients in whom a neurologic abnormality is not evident, observation for neurologic disorders manifested by weakness and wasting of an extremity, altered bladder or bowel habits, etc, is in order. A subcutaneous lipoma is a clear indication of probable cord involvement, and exploration has been recommended by many investigators, even in the absence of neurologic symptoms in such patients to prevent future worsening of their conditions.[18]

Ninety-eight of the 102 patients with cutaneous signs underwent operations. One patient died of meningitis at age 25 years before surgery could be performed. Two patients were symptom-free and were under close observation. One patient with serious urinary complaints refused surgery. After undergoing operations, 17 patients recovered completely, 71 improved considerably, 3 had minor improvement, 6 remained unchanged, and only 1 patient's condition became worse.

COMMENT

Although the cutaneous signs of occult spinal dysraphism were stressed by Lichtenstein in 1940 and have been emphasized by many, including James and Lassman and Till, the dermatologic aspects have not been studied in detail. A dermatologist or pediatrician may be the first physician to see these patients, but neurologists, urologists, and neurosurgeons follow up and treat these patients. Results of histologic examination in such patients have largely been limited to the surgical specimens removed at exploration. The skin abnormalities have not been subjected to histologic scrutiny.

Correction of the cutaneous malformation is by no means an adequate therapeutic approach for this condition. It only serves to complicate a later definitive exploration and therapy. James and Lassman reviewed 26 cases of spinal dysraphism with lumbosacral lipoma and noted that surgical procedures were more difficult and dangerous when the superficial portion of the lipoma had been previously excised. Therefore, the early diagnosis with appropriate therapy may lead to a minimal neurologic defect.

To our knowledge, our patient is the first with a tail-like tumor consisting of cutaneous and intrathecal lipomas. Her lesion was typical for a subcutaneous lipoma extending into the spinal canal with tethering of the cord, producing both pressure and traction.

References

1. Lichtenstein BW: Spinal dysraphism: Spina bifida and myelodysplasia. *Arch Neurosurg Psychiatry* 44:792-809, 1940.
2. James CCM, Lassman LP: Diastematomyelia. *Arch Dis Child* 33:536-539, 1958.
3. Till K: Spinal dysraphism: A study of congenital malformations of the back. *Dev Med Child Neurol* 10:470-477, 1968.
4. Blockey NJ, Schorstein J: Intraspinal epidermoid tumours in the lumbar region of children. *J Bone Joint Surg Br* 43B:556-562, 1961.
5. James CCM, Lassman LP: Spinal dysraphism: The diagnosis and treatment of progressive lesions in spina bifida occulta. *J Bone Joint Surg* 44B:829-840, 1962.
6. Garceau GJ: The filum terminale syndrome. *J Bone Joint Surg* 53A:711-716, 1953.
7. Anderson FM: Occult spinal dysraphism. *J Pediatrics* 73:163-177, 1968.
8. Sharrard WJ: Occult spinal dysraphism. *Dev Med Child Neurol* 8:464-466, 1966.
9. Bassett BC: The neurologic deficit associated with lipomas of the cauda equina. *Ann Surg* 131:109-116, 1950.
10. Lassman LP, James CCM: Lumbo-sacral lipomas: Critical survey of 26 cases submitted to laminectomy. *J Neurol Neurosurg Psychiatry* 30:174-181, 1967.
11. Swanson HS, Barnett JC Jr: Intradural lipomas in children. *Pediatrics* 29:911-926, 1962.
12. Brickner WM: Spina bifida occulta. *Am J Med Sci* 155:473-502, 1918.
13. Shorey WD: Diastematomyelia associated with dorsal kyphosis producing paraplesia. *J Neurosurg* 12:300-305, 1955.
14. Burrows FGO: Some aspects of occult spinal dysraphism: A study of 90 cases. *Br J Radiol* 41:496-507, 1968.
15. Hilal SK, Marton D, Pollack E: Diastematomyelia in children. *Radiology* 112:609-621, 1974.
16. Gryspeerdt GL: Myelographic assessment of occult forms of spinal dysraphism. *Acta Radiologica* 1:702-717, 1963.
17. James CCM, Lassman LP: *Spinal Dysraphism: Spina Bifida Occulta.* London, Butterworth & Co, 1972.
18. Dubowitz F, Lorber J, Zachary RB: 'Lipoma of the cauda equina'; *Arch Dis Child* 40:207-213, 1965.

Atypical Purpura Fulminans With Benign Monoclonal Gammopathy

William R. Friedenberg, MD; Michael West, MD;
Donald J. Miech, MD; Joseph J. Mazza, MD

• A 67-year-old woman with a history of thrombophlebitis had been taking warfarin sodium for 1½ years when she developed multiple skin lesions resembling warfarin-induced skin necrosis or purpura fulminans. Despite discontinuing the warfarin and administering prednisone, the lesions increased in size. Disseminated intravascular coagulation (DIC) was found and resolved with heparin sodium therapy, and her skin lesions healed.

This patient was believed to have an atypical form of purpura fulminans rather than warfarin-induced skin necrosis because of the duration of warfarin therapy prior to the illness, the presence of DIC, and the dramatic resolution with heparin. A monoclonal (IgG) gammopathy was found, which stabilized as the skin lesions resolved, and fulfilled the criteria for a benign (asymptomatic) monoclonal gammopathy.

(*Arch Dermatol* 114:578-580, 1978)

Purpura fulminans and warfarin sodium (Coumadin) induced skin necrosis are two distinct entities that have different clinical characteristics but resemble each other histopathologically. The following case is unusual not only because of the overlap of clinical characteristics, making clear-cut distinction difficult, but also because of the association of the illness with a benign monoclonal gammopathy.

REPORT OF A CASE

Beginning in 1946, a 67-year-old woman suffered many episodes of thrombophlebitis. Sometime between 1960 and 1965, she underwent venous stripping and femoral ligation of both lower extremities. Following an episode of thrombophlebitis in 1973, she was treated with warfarin sodium. Two months prior to referral to us, the patient fell, bruising her left thigh and fracturing her right wrist. At that time use of the anticoagulant was discontinued. Three days later, the woman developed pain, hyperemia, and tenderness in her left thigh, but it resolved in one week. She then developed ecchymosis of her abdomen and, a few days later, a black blistering nodular lesion on her buttock. Similar lesions appeared on her breasts, right thigh, left flank, and perineal area. The woman remained hospitalized for five weeks and was treated with prednisone, 60 mg/day, without response. A biopsy was performed five days before she was transferred to our institution, and the specimen showed occlusion of vessel lumens by fibrin clot and hemorrhagic infarction (Fig 1). Because the lesion became progressively worse, the patient was transferred to St Joseph's Hospital.

Physical examination at that time disclosed an obese woman with normal vital signs, except for a sinus tachycardia of 100 beats/min. The lungs were clear, and cardiac auscultation showed a grade 1/6 systolic ejection murmur at the left sternal border with an S4 gallop. Results of the remainder of the examination were normal, except for the skin, which exhibited large hemorrhagic bullae with surrounding tender erythema and induration in seven areas including the thighs, breasts, and flanks (Fig 2).

At the time of admission, the prothrombin time (PT) was 16.5 seconds (control of 12 seconds) and the partial thromboplastin time (PTT) 32 seconds (control of 30 seconds). The plasma fibrinogen concentration was 85 mg/100 ml (normal, 140 to 350 mg/100 ml) and the fibrin-split products (by the staphylococcal clumping technique) 32 μg/ml (normal, less than 9 μg/ml). The blood hemoglobin value was 7.3 gm/100 ml, the hematocrit volume 23%, the WBC count 10,400/cu mm, with a differential cell count of 57% neutrophils, 25% lymphocytes, 7% monocytes, 4% band neutrophils, 6% metamyelocytes, and 1% myelocytes. There were two nucleated RBCs per 100 WBCs. The peripheral contained occasional burr cells and schizocytes, and many shift cells. The platelet count was 54,000/μl; the reticulocyte count, 12.3%; the serum iron concentration, 34 μg/100 ml; total iron-binding capacity, 175 μg/100 ml; total serum protein, 6.1 gm/100 ml (albumin of 3.2 gm/100 ml). Serum protein electrophoresis disclosed a monoclonal spike in the gamma region. Immunoglobulin concentrations were IgG, 1,580 mg/100 ml (normal, 900 to 1,500 mg/100 ml); IgA, 131 mg/100 ml (normal, 170 to 410 mg/100 ml), and IgM, 115 mg/100 ml (normal, 50 to 110 mg/100 ml). The concentrated urine for light chains showed trace amounts of κ chains, with no λ chains detectable. Results from tests for the following were normal or negative: serum calcium, phosphorus, BUN, serum creatinine, electrolytes, SGOT, alkaline phosphatase, cholesterol, uric acid, fasting glucose, cryoglobulins, B_{12} levels, folate, C3 complement, lupus erythematosus preparation, antinuclear antibody, rheumatoid factor, and cold agglutinins; intravenous pyelogram, upper gastrointestinal tract x-ray films, cholecystogram, and urine for hemosiderin were also normal.

Starting the second hospital day the patient was treated with a constant infusion of heparin sodium, 1,000 units/hr, following an initial bolus of 5,000 units intravenously. She was also treated with transfusions of packed cells, and compresses of providone-iodine to the skin lesions. The prednisone dosage was rapidly decreased and the medication discontinued in one week. Two days later the platelet count was 220,000/cu mm; PT was 13.0/12.0 seconds; the PTT, 34/30 sec; plasma fibrinogen, 256 mg/100 ml; fibrin-split products, 8 μg/ml; and the reticulocyte count, 2.6%. After two weeks of continuous therapy the heparin sodium was changed to intermittent administration. On the following day, one-half hour before the next dose of heparin was due, the patient developed acute onset of pain and tenderness in both medial areas of her breasts, which were previously uninvolved, and the skin rapidly developed increasing purplish discoloration and induration. At that time the PTT was 37/30 sec; PT, 14.0/12.5 sec; plasma fibrinogen, 315 mg/100 ml; the platelet count, 186,000/cu mm; and serum fibrin-split products, 128 μg/ml. Within minutes after a bolus of 5,000 units of heparin sodium was administered intravenously, the lesions began to resolve. A punch biopsy specimen at this time disclosed focal capillaritis.

A constant infusion of heparin sodium was continued and, on the following day, the PTT was 56/32 sec; the PT, 15.5/12.0 sec; the plasma fibrinogen, 264 mg/100 ml; serum fibrin-split products, 64 μg/ml; and the platelet count, 161,000/cu mm. After two weeks the rate of intravenous heparin was decreased by 50 units/hr/day and, one week later, when the PTT was 36/30 sec, the patient repeated the previous episode. Rapid administration of heparin stopped progression of the lesion but did not resolve it. A punch biopsy specimen at this time disclosed occlusion of the arterioles and veins by fibrin thrombi in the dermis, and immunofluorescence stains for immunoglobulins and complement were negative.

The patient was then treated with subcutaneous heparin every eight hours and her PTT was maintained between 40 and 45 seconds. Serum protein electrophoresis, 3½ weeks after admission, showed an increase in the M component with 2,200 mg/100 ml of IgG, 100 mg/100 ml of IgA, and 78 mg/

Accepted for publication April 27, 1977.

From the Marshfield (Wis) Clinic and the Marshfield Foundation, Inc.

Reprint requests to Marshfield Clinic, 1000 N Oak Ave, Marshfield, WI 54449 (Dr Friedenberg).

100 ml of IgM. A metastatic bone series was normal except for moderate diffuse osteoporosis. Bone marrow examination and biopsy showed myeloid hyperplasia with adequate iron stores and no sideroblasts; these findings are consistent with the anemia of inflammation or chronic disease. Plasma cells appeared normal and comprised less than 1% of marrow elements. The patient recovered uneventfully, and her skin lesions healed gradually.

The patient was seen six months after discharge, at which time she was asymptomatic. Three months previously warfarin had been substituted for heparin without untoward effects. The CBC, platelet count, and coagulation test results were normal except for the PT, which was 22/12.0 sec. The patient still had a monoclonal gammopathy with 1,800 mg/100 ml of IgG, 94 mg/100 ml of IgA, and 90 mg/100 ml of IgM, and the appearance of the protein electrophoresis was unchanged.

One year following discharge, the patient's protein electrophoresis was still unchanged, with 2,000 mg/100 ml of IgG, 85 mg/100 ml of IgA, and 120 mg/100 ml of IgM. The urine still showed small amounts of κ chains in the concentrated specimen. She was still asymptomatic and had a normal hemogram and normal coagulation test findings.

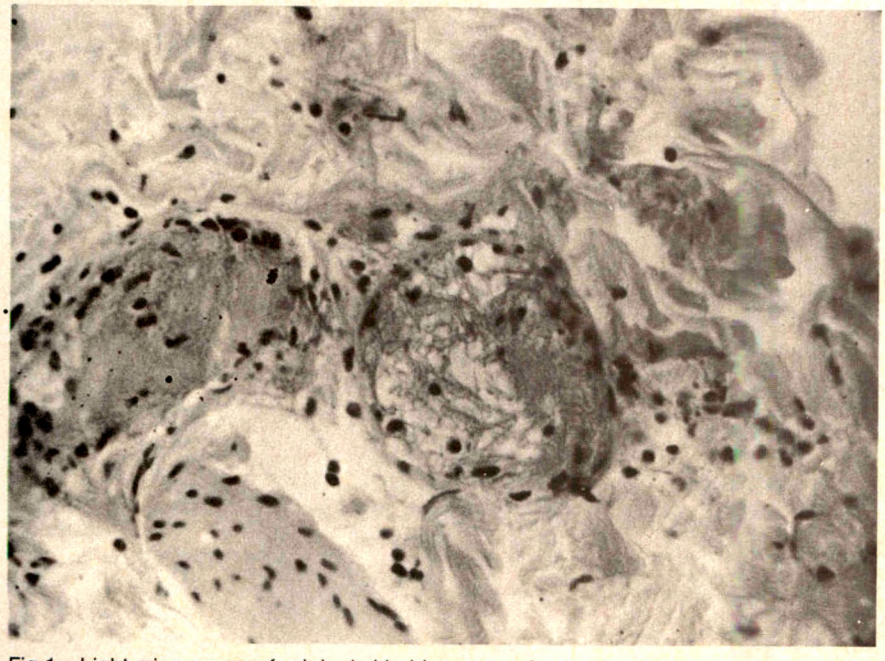

Fig 1.—Light microscopy of original skin biopsy specimen, showing occlusion of vessel lumens with fibrin clot, and hemorrhagic infarction (hematoxylin-eosin, original magnification ×400).

COMMENT

This case most resembles warfarin-induced skin necrosis and purpura fulminans.[1,2] Warfarin-associated skin necrosis was first reported by Flood in 1943, but it was thought to occur secondary to thrombophlebitis and not to be drug-induced.[3] In 1952, Verhagen and Wiersema, in Europe, called attention to the relationship between oral anticoagulants and soft-tissue necrosis,[4,5] but it was not until 1961 that Kipen, in the United States, described this association.[6] In 1968 Koch-Weser summarized 150 reported cases of skin necrosis associated with oral anticoagulants.[7] He found that (1) skin lesions appear three to ten days after the onset of treatment, 93% occurring from days 3 to 5; (2) 92% of cases occur in obese women with a median age of 54 years; (3) the indication for treatment with oral anticoagulants is usually venous thrombosis, but coronary and cerebrovascular disease are also included; (4) 80% of lesions occur in the lower body;

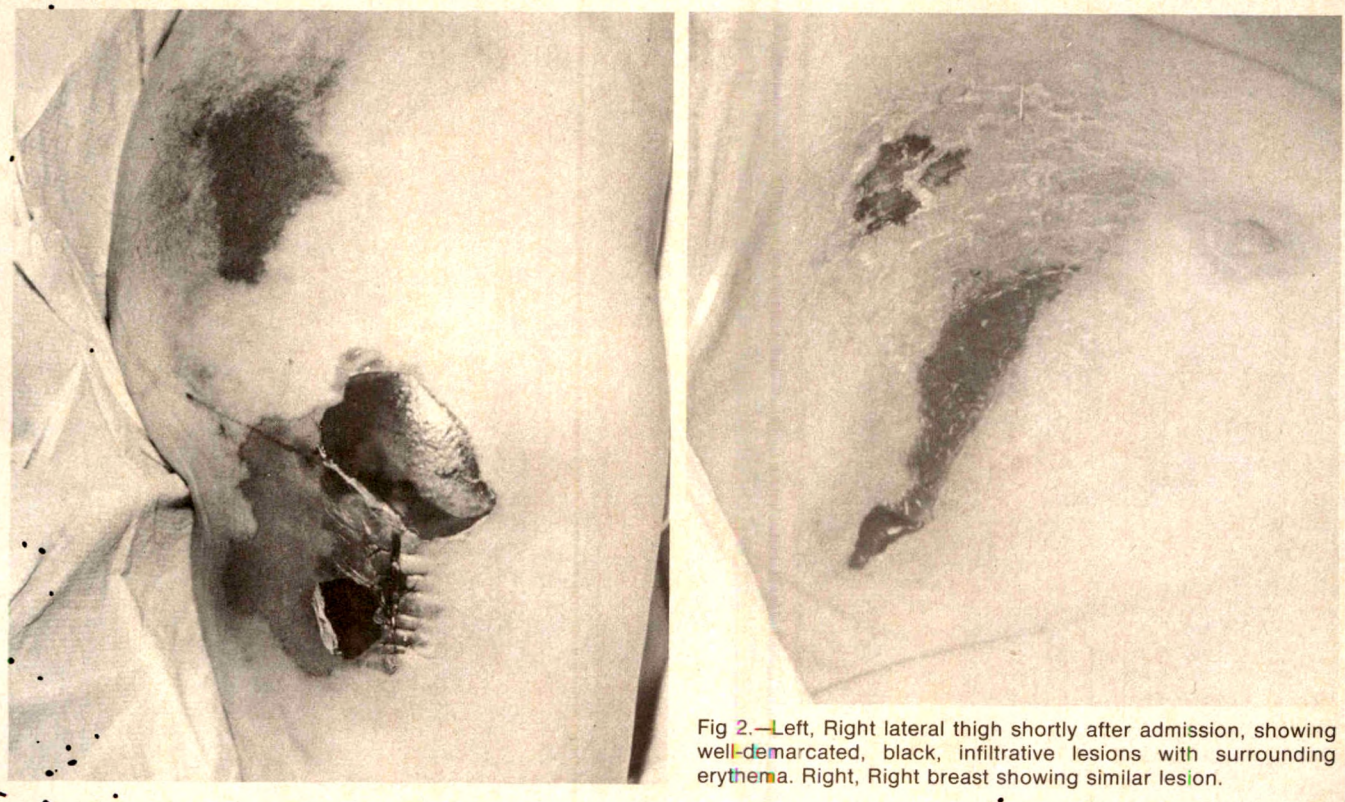

Fig 2.—Left, Right lateral thigh shortly after admission, showing well-demarcated, black, infiltrative lesions with surrounding erythema. Right, Right breast showing similar lesion.

multiple lesions are unusual, subcutaneous involvement may be prominent, and the breasts may be involved; (5) typically, a lesion begins as an erythematous patch, sometimes edematous and elevated, often poorly demarcated, painful, and tender; petechiae surround the area, which then becomes a solid red-blue-black color that within one day may become necrotic with hemorrhagic blisters.

Warfarin-induced skin necrosis is not associated with coagulation abnormalities and has been unresponsive to treatment with heparin, steroids, sympathetic blockade, local hyperthermia, and withdrawal of the warfarin therapy. The lesions may resolve despite continuation of warfarin therapy and may or may not recur when oral anticoagulants are given again.[7-12]

Histopathologically, the lesions show thrombosis of capillaries, venules, and small arterioles, hemorrhage with secondary necrosis of blood vessel walls, and a mild inflammatory infiltrate with neutrophils. These findings are the same as those found in purpura fulminans.[1,2,8,11-13]

Purpura fulminans typically occurs in children within three to 30 days following varicella, scarlet fever, or other streptococcal infections. The lesions are typically symmetrical, involve the lower extremities and buttocks, and begin as tender ecchymotic areas that enlarge rapidly, coalesce, and develop central necrosis with hemorrhagic blebs and a raised peripheral edge with surrounding erythema. They may spread to the trunk and upper extremities, but rarely involve the face or mucous membranes. Consumption coagulopathy is frequently observed, associated with a leukocytosis and microangiopathic hemolytic anemia. Disseminated intravascular coagulation is thought to play a prominent role in the pathogenesis of the illness, and heparin has proved effective in its treatment.[13-17]

This case resembles warfarin-induced skin necrosis, because the illness occurred in an obese, middle-aged woman receiving warfarin. The lesions affected the lower extremities, trunk, and breast, but spared the upper extremities, face, and mucosa, and they had a typical evolution and histopathologic appearance described with warfarin-induced lesions. The onset of illness, however, occurred after 1½ years of warfarin administration. Furthermore, disseminated intravascular coagulation with microangiopathic hemolytic anemia was a prominent feature and, as described in the case report, both the skin lesions and coagulopathy responded to heparin administration on repeated occasions, a fact not consistent with warfarin-induced skin necrosis. The clinical appearance, the evolution of the skin lesions, and their response to heparin, as well as their histopathology, are all compatible with purpura fulminans. Atypical features include the age of the patient, the lack of a preceding infection (although trauma may have played a role), and the subacute or chronic course of the illness. The sequence of events including the duration of warfarin therapy prior to the illness, the presence of disseminated intravascular coagulation, and the dramatic response to heparin on three occasions persuade us to classify this illness as an atypical case of subacute or chronic purpura fulminans.

A monoclonal gammopathy has not been reported in association with purpura fulminans or warfarin-induced skin necrosis. Although no criteria are absolute to distinguish a benign (asymptomatic) monoclonal gammopathy from a malignant (symptomatic) one, the following features suggest a benign origin in this case: (1) the lack of significant plasmacytosis in the bone marrow; (2) a level of IgG monoclonal immunoglobulin of less than 3 gm/100 ml; (3) the absence of Bence-Jones proteinuria; (4) the absence of lytic bone lesions on x-ray films; (5) the normal levels of IgA and IgM immunoglobulins; (6) the lack of progression of the monoclonal gammopathy during the one-year period of observation; (7) the correction of the anemia despite persistence of the monoclonal gammopathy.[18]

One can speculate that this illness began with the trauma this patient sustained while she was taking warfarin. The tissue necrosis associated with the injury released small amounts of thromboplastin, which caused local clotting in a warfarin-induced "presensitized" dermatovascular loop, as postulated by Nalbandian et al for the usual case of warfarin-induced skin necrosis.[11] This resulted in hemorrhage into the tissues and subsequently hemorrhagic infarction. The continued tissue necrosis started a vicious cycle of thromboplastin release, intravascular clotting, and tissue necrosis until interrupted by the administration of heparin. Tissue antigens chronically released during this process may have caused proliferation of a B-cell clone, resulting in the monoclonal gammopathy. Conversely, chronic antigen stimulation may have inhibited T-cell suppression of a B-cell clone by competitive inhibition, partially releasing control and production of the monoclonal gammopathy.

Lee L. Schloesser, MD, and Albert J. Zimmermann reviewed the manuscript, and Avril Duerr provided technical assistance.

References

1. Domonkos AN: *Andrews' Diseases of the Skin*, ed 6. Philadelphia, WB Saunders Co, 1971, pp 905-906.
2. Lever WF, Schaumberg-Lever G: *Histopathology of the Skin*, ed 5. Philadelphia, JB Lippincott Co, 1975, p 160.
3. Flood EP, Redish MH, Bociek SJ, et al: Thrombophlebitis migrans disseminata: Report of a case in which gangrene of a breast occurred. *NY State J Med* 43:1121-1124, 1943.
4. Verhagen H: Local haemorrhage and necrosis of the skin and underlying tissues, during anticoagulant therapy with dicumerol or dicumacyl. *Acta Med Scand* 148:453-467, 1954.
5. Verhagen H, Wiersema MU: Hemorrhagic purpura followed by necrosis during dicumerol therapy of thrombophlebitis: Eight cases. *Ned Tijdschr Geneeskd* 96:1578-1585, 1952.
6. Kipen CS: Gangrene of the breast: A complication of anticoagulant therapy: Report of two cases. *N Engl J Med* 265:638-640, 1961.
7. Koch-Weser J: Coumarin necrosis. *Ann Intern Med* 68:1365-1367, 1968.
8. Lacy JP, Goodin RR: Warfarin-induced necrosis of skin. *Ann Intern Med* 82:381-382, 1975.
9. Neumayr A, Schmid J: Kapillarpermeabilitat und antithrombon. *Schweiz Med Wochenschr* 25:616-618, 1948.
10. Stefenelli N, Tulzer H, Wewalka F: Skin necrosis as a side effect of anticoagulant therapy. *Thromb Diath Haemorrh* 5:136-144, 1960.
11. Nalbandian RM, Mader IJ, Barrett JL, et al: Petechiae, ecchymoses, and necrosis of skin induced by coumarin congeners. *JAMA* 192:603-608, 1965.
12. Davis CE Jr, Wiley WB, Faulconer RJ: Necrosis of the female breast complicating oral anticoagulant treatment. *Ann Surg* 175:647-656, 1972.
13. Dudgeon DL, Kellogg DR, Gilchrist GS, et al: Purpura fulminans. *Arch Surg* 103:351-358, 1971.
14. Yoshikawa T, Tanaka KR, Guze LB: Infection and disseminated intravascular coagulation. *Medicine* 50:237-258, 1971.
15. Targan SR, Chassin MRG, Guze LB: Dilantin-induced disseminated intravascular coagulation with purpura fulminans: A case report. *Ann Intern Med* 83:227-230, 1975.
16. Hjort PF, Rapaport SI, Jorgensen L: Purpura fulminans: Report of a case successfully treated with heparin and hydrocortisone: Review of 50 cases from the literature. *Scand J Haematol* 1:169-192, 1964.
17. Little JR: Purpura fulminans treated successfully with anticoagulation: Report of a case. *JAMA* 169:36-40, 1959.
18. Ritzmann SE, Loukas D, Sakai H, et al: Idiopathic (asymptomatic) monoclonal gammopathies. *Arch Intern Med* 135:95-106, 1975.

Necrotizing Fasciitis

Gerard G. Koehn, MD

• Two patients had limited necrotizing fasciitis. The morbidity and mortality from this infectious necrotizing process of the superficial fascia have not changed significantly since its initial description in 1924. The characteristic clinical findings of necrotizing fasciitis makes early recognition possible. Within 24 to 48 hours, redness, pain, and edema rapidly progress to central patches of dusky blue discoloration, with or without serosanguineous blisters. By the fourth or fifth day, these purple areas become gangrenous. Although necrotizing fasciitis originally was associated exclusively with β-hemolytic *Streptococcus*, recent cases have shown a variety of bacteria. The essential treatment remains wide local surgical débridement.

(*Arch Dermatol* 114:581-583, 1978)

Necrotizing fasciitis is rare and potentially fatal. In an era of effective antibiotic management of bacterial disease, the mortality of necrotizing fasciitis is surprisingly high. Although the disorder is seldom recognized early, characteristic clinical features make prompt diagnosis and treatment possible. Two cases of limited necrotizing fasciitis are presented by way of illustration.

REPORT OF CASES

CASE 1.—A 62-year-old female alcoholic was seen in the emergency room in April 1972, with extensive cellulitis of the left forearm. She had been inebriated for three days and had fallen and lacerated her arm one day previously. She had pain in the left arm, chills, fever, and night sweats, and she was receiving no medications.

On physical examination, the blood pressure was 130/90 mm Hg, the pulse rate was 120 beats per minute, and her temperature was 40 C. She was well developed, well nourished, in no acute distress, but obviously intoxicated. The liver was palpable 4 cm below the right costal margin. The left forearm had marked edema and redness surmounted by serosanguineous blisters, with tender adenopathy of the left axilla. Pustules were present on the right cheek, left buttocks, and left calf.

Laboratory data included a hemoglobin level of 13.7 gm/ml, a hematocrit value of 42%, and a WBC count of 14,100/cu mm with a left shift. Gram stain of the vesicle fluid of the left forearm showed neutrophils with a moderate number of cocci in chains. Culture of the vesicle fluid grew pure colonies of group A β-hemolytic *Streptococcus*. Blood cultures on two occasions were positive for group A β-hemolytic *Streptococcus* as well. An antistreptolysin O titer was 2,500 TU. Blood glucose levels varied from 211 to 265 mg/100 ml. The level was BUN 9.6 mg/100 ml; bilirubin level was 3.7 mg/100 ml; calcium level was 8.2 mg/100 ml; and phosphorus level was 1.9 mg/100 ml. The total protein value was 6.4 gm/100 ml, and the albumin level was 2.4 gm/100 ml.

The patient was admitted to the hospital and received cephalothin intravenously, 2 gm every six hours. Within 24 hours she developed generalized urticaria, which was believed to be due to her drug regimen, and 0.5 gm of lincomycin hydrochloride monohydrate every six hours was substituted. On the second hospital day, the central portions of the lesions on the left arm became hemorrhagic and gangrenous. Four days later, following a limited bedside débridement, the patient was taken to the operating room and large areas of necrotic fat were removed down to an adequately bleeding base. Five days later, the patient had a split-thickness graft applied to an area approximately 5 × 3 cm on the left arm. The graft took well and she was discharged on the 35th hospital day.

CASE 2.—A 63-year-old woman was first seen in November 1975 with a five-day history of pain and swelling of the right arm. She had burned the dorsal proximal phalanx of the right third finger on a stove approximately two weeks previously. She was seen by her private physician on the day before admission and had been placed on a regimen of cephalexin monohydrate, 0.25 gm three times a day. Because of her failure to improve and because she had become febrile, she was admitted to the hospital.

On physical examination, the patient appeared well developed and well nourished but acutely ill, with pain in the right arm. Her temperature was 39 C; pulse rate, 110 beats per minute; respirations, 20/min; blood pressure, 130/75 mm Hg. The right forearm and hand were red, edematous, and extremely painful, with a small number of hemorrhagic vesicles centrally and some suggestion of early necrosis (Fig 1).

Bacterial cultures of the blister fluid were negative. Gram stains showed a few Gram-positive cocci. The hemoglobin level was 14.7 gm/100 ml; hematocrit value, 46%; and WBC count, 13,100/cu mm with a left shift. Aerobic and anaerobic cultures of the blood were negative. The blood glucose level was 160 mg/100 ml, and the BUN level was 32 mg/100 ml. Normal laboratory data included calcium, phosphorous, serum protein, bilirubin, lactic dehydrogenase, SGOT, alkaline phosphatase, and urinalysis. A chest x-ray film was normal.

Within two days of admission, the lesion manifested enlarging areas of hemorrhage and necrosis, and the erythema and edema had spread proximally to the elbow and down to the dorsum of the hand. She continued to receive cephalothin intravenously and became afebrile on the fourth hospital day. There was no further extension of the lesion on the right arm.

A 4-mm punch biopsy specimen of the active margin, which was studded with a number of deep-seated miliary vesicles (Fig 2), was obtained. Microscopically, numerous dilated subepidermal and dermal lymphatic vessels were seen. A mixed perivascular infiltrate, mainly lymphocytes, histiocytes, and polymorphonuclear leukocytes, was seen in the dermis and extended to the subcutis (Fig 3 and 4). Probing of the subcutaneous tissue disclosed extensive undermining and an oily serosanguineous exudate. Culture of the deep fascial spaces was negative.

Two weeks following admission, the patient underwent wide débridement in the operating room. The surgeons found a stringy, gray, necrotic fascia, with extensive undermining of the skin that extended from the dorsum of the hand to just proximal to the elbow (Fig 5). Two weeks later, split-thickness skin grafts were placed on a clean, granulating base. These healed well, and the patient was discharged on the 41st day.

COMMENT

Since Meleney's original report in 1924,[1] necrotizing fasciitis has remained an unusual cutaneous infection. Reports of this affliction are particularly rare in the dermatologic literature.

Necrotizing fasciitis is an acute necrotizing process that involves the superficial fascia of the skin. The two cases presented herein are limited expressions of this potentially fatal disorder. Anatomically, the superficial fascia, which is the site of most of the necrosis, includes subcutaneous fat and a deeper membranous condensation of collagen and elastin.[2] The deep fascia, which encapsulates muscles, bone, and tendon, usually is not involved.

Some authors have emphasized the trivial nature of the initial skin injury that precedes necrotizing fasciitis, eg, a laceration, abrasion, parenteral injection, sewing-needle puncture,[3] dental extraction,[4] or varicella infection.[5] In a significant number of cases, no portal of entry is apparent.

The pathognomonic features of necrotizing fasciitis can develop rapidly. Within 24 to 48 hours, redness, pain,

Accepted for publication June 1, 1977.

From the Department of Dermatology, University of Colorado School of Medicine, Denver.

Reprints not available.

and edema quickly progress to central patches of dusky blue discoloration, with or without serosanguineous blisters. By the fourth or fifth day, these purple areas become gangrenous. At this point, the clinical picture can resemble a third-degree burn. The area that surrounds the necrosis is red, edematous, and gradually fades into normal skin. The edema described in case 2 of this report was of such extent that deep-seated vesicles were apparent clinically (Fig 2). At first, the wound is very painful, but anesthesia ensues later because subcutaneous necrosis causes local destruction of nerves.[6]

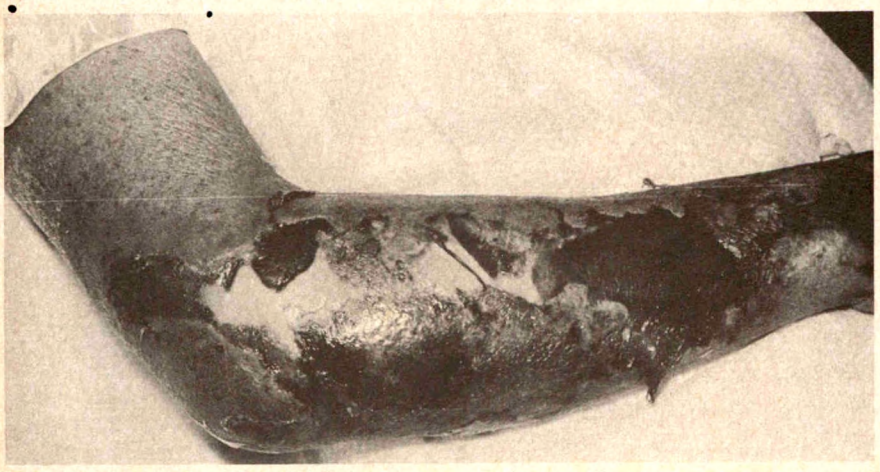

Fig 1.—Right arm showing hemorrhagic bullae, dermal necrosis, peripheral erythema, and swelling (case 2).



Fig 2.—Close-up of right elbow showing deep-seated vesicles within area of hemorrhage and necrosis.

Part of the work-up includes a limited incision of the skin and probing with a hemostat or with a similar instrument. If undermining of the skin is present and the probe is passed easily in the subcutaneous spaces, the diagnosis of necrotizing fasciitis is confirmed and immediate surgical intervention is indicated.[6] Further, one can observe a gray, stringy, necrotic fascia with a "dishwater" turbid serosanguineous exudate. This diagnostic incision and probing of the underlying skin is critical, since the overlying skin tends to remain viable or clinically uninvolved early while extensive subcutaneous necrosis and suppuration is occurring.[4,6]

Patients with necrotizing fasciitis as a rule have high fever, prostration, tachycardia, and clouding of the sensorium. Bacteremia is usual, and fatal septicemia sometimes results. Subcutaneous distant metastatic foci of infection and symmetrical gangrene sometimes suggest diffuse intravascular coagulation. Patients often have anemia, thrombocytopenia, and hypocalcemia. The latter may be related to ongoing extensive fat necrosis.

Within the past 20 years, the pattern of bacteria cultured from necrotizing fasciitis has changed. Early investigators recovered exclusively β-hemolytic streptococci.[1] Recent reports have implicated other organisms, including hemolytic *Staphylococcus*,[6,7] coliforms, enterococci, *Pseudomonas*,[8] and bacteroides.[9] The explanation for this trend probably

Fig 3.—Dilated subepidermal lymphatic vessels (case 2). Noted dilated endothelial-lined spaces with an absence of erythrocytes (hematoxylin-eosin, original magnification ×100).

Fig 4.—Junction of deep dermis and subcutis (case 2). Note dense accumulation of inflammatory cells (hematoxylin-eosin, original magnification ×250).

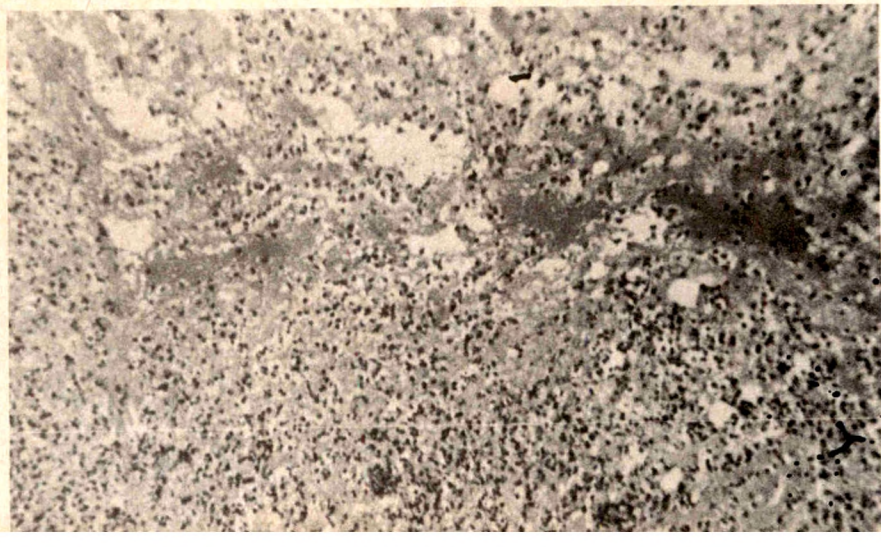

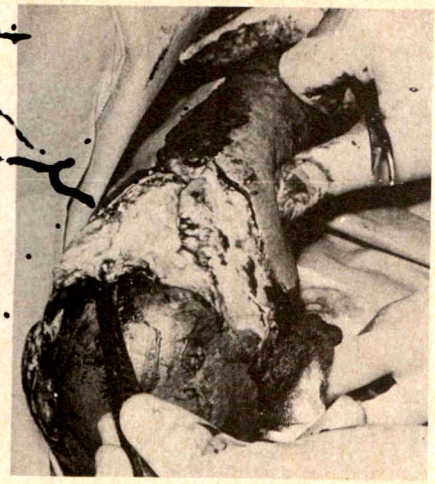

Fig 5.—Right elbow and forearm at surgery showing necrotic, stringy, superficial fascia (case 2).

lies in early antibiotic use and varying culture techniques. Because many forms of virulent bacteria apparently can produce necrotizing fasciitis, this disease should be considered as a clinical entity and not as a specific bacterial infection.[10]

The histopathologic features of necrotizing fasciitis have been reported rarely.[1,11] There is intense edema and granulation tissue with newly formed vessels, neutrophils, and mononuclear cells. Thrombosis of blood vessels and nerve damage are seen sometimes. The dilated subepidermal and dermal lymphatics described in case 2 of this report are interesting though nonspecific histologic findings.

The pathogenesis of this disorder is not well understood. One postulate is that a locally produced bacterial toxin[12-14] damages the deep fascia. This process may continue in spite of high-dose antibiotics and local high tissue levels of antibiotics.[15] The relative avascularity of cutaneous fascial spaces and concurrent debilitating illness also may favor the spread of infection.[8]

When necrotizing fasciitis is being considered as a diagnosis, other causes of acute inflammatory gangrene needed to be excluded. Erysipelas, as opposed to necrotizing fasciitis, lacks bullae and central necrosis. The wounds of gas gangrene are deep and crepitant, and skin necrosis occurs late.[3,7] Pyoderma gangrenosa usually evolves more slowly than necrotizing fasciitis.

Finally, Meleny's ulcer (progressive synergistic gangrene[16]; progressive bacterial gangrene[8]) is sometimes confused with necrotizing fasciitis. Although Meleny's ulcer originally was found in association with microaerophillic *Streptococcus* and *staphylococcus aureus*, subsequent cases have been reported with a wide variety of organisms, particularly Gram-negative ones.[8] The onset of Meleney's ulcer is slower, patients are not usually in toxic conditions, and necrosis is less widespread. There is little or no undermining of subcutaneous tissue or subcutaneous necrosis. This infection is mainly a postoperative complication, and often is seen around surgical drains and retention sutures.[17,18]

The mortality of necrotizing fasciitis has not improved significantly since Meleny's original report,[1] and has remained in the range of 20% to 50%. Concurrent illnesses such as diabetes mellitus or atherosclerosis adversely affect survival.[7] The prognosis is better if the necrotizing fasciitis is located on an extremity rather than on the trunk, head, or neck.[8,10]

The mainstay of treatment remains early surgical débridement, which in some instances can be life-saving. Adequacy of débridement is determined by inability to easily separate skin from underlying subcutaneous tissue. Split-thickness skin grafting can be carried out successfully when the surfaces are clean and granulating. Recently, excised viable skin was removed from areas of necrotizing fasciitis and stored with some success for later grafting.[8]

Intravenously administered antibiotics protect the patient from overwhelming sepsis, although some physicians have reported a relentless progression of the necrotizing process despite the appropriate use of antibiotics.[19,20] Most reports have recommended that aqueous penicillin, 20,000,000 units per day, be used; however, with increasing reports of causative organisms other than β-hemolytic streptococci, other antibiotics perhaps should be added. These would include a semisynthetic penicillin[14] in addition to a Gram-negative-spectrum antibiotic.

Supportive care includes careful fluid management and attention to anemia, thrombocytopenia, and hypocalcemia. High-dose corticosteroids have had inconclusive to poor results.[21,22] Hyperbaric oxygen, which is of doubtful value in necrotizing fasciitis, has proved useful in cases of Meleney's ulcer.[8]

Most physicians will not see a case of necrotizing fasciitis in a professional lifetime, but those who are responsible for the care of the skin should be aware of its existence. This report is intended to remind dermatologists of the characteristic clinical features of this rare disease. It is hoped that this entity be understood as a true dermatologic emergency and managed as such.

Nonproprietary Name and Trademark of Drug

Cephalothin sodium—*Keflin*.

References

1. Meleney FL: Hemolytic streptococcus gangrene. *Arch Surg* 9:317, 1924.
2. Gray H: *Anatomy of the Human Body*, Gosse CM (ed). Philadelphia, Lea & Febiger Publishers, 1962, pp 407-408.
3. Quintiliani R, Engh GA: Overwhelming sepsis associated with group A beta hemolytic streptococci. *J Bone Joint Surg* 53:1391-1399, 1971.
4. Crowson WN: Fatal necrotizing fasciitis developing after tooth extraction. *Am Surg* 39:525-527, 1973.
5. Smith EWP, Garsan A, Boglestan JA, et al: Varicella gangrenosa due to group A β-hemolytic streptococcus. *Pediatrics* 57:306-310, 1976.
6. Wilson B: Necrotizing fasciitis. *Am Surg* 18:416-431, 1952.
7. Rea WJ, Wyrick WJ Jr: Necrotizing fasciitis. *Ann Surg* 172:957-964, 1960.
8. Ledingham IM, Tehrani MA: Diagnosis, clinical course and treatment of acute dermal gangrene. *Br J Surg* 62:364-372, 1965.
9. Rein JM, Bard C: Bacteroides necrotizing fasciitis of the upper extremity. *Plast Reconstr Surg* 48:582-594, 1971.
10. Borkowf HI: Bacterial gangrene associated with pelvic surgery. *Clin Obstet Gynecol* 16:40-65, 1973.
11. Buchanan CS, Haserick JR: Necrotizing fasciitis due to group A β-hemolytic streptococci. *Arch Dermatol* 101:664-668, 1970.
12. Schwab JH: Analysis of the experimental lesions of connective tissue produced by a complex of C-polysaccharide from group A streptococci: I. In vivo reaction between tissue and toxin. *J Exp Med* 116:17, 1962.
13. Cromartie WJ, Schwab JH, Craddock JG: The effect of a toxic cellular component of group A streptococci on connective tissue. *Am J Pathol* 37:79-99, 1960.
14. McCloskey RV: Scarlet fever and necrotizing fasciitis caused by coagulase-positive, hemolytic *Staphylococcus aureus*, phage type 85. *Ann Intern Med* 78:85-87, 1973.
15. Graybill JR, Pierson DN, Charache P: Tissue antibiotic penetration in streptococcal gangrene. *Johns Hopkins Med J* 133:45-50, 1973.
16. Meleney FL: A differential diagnosis between certain types of infectious gangrene of the skin. *Surg Gynecol Obstet* 56:847-867, 1933.
17. Wilson HD, Haltalin KC: Synergistic bacterial gangrene. *Br Med J* 2:3, 1973.
18. Hutchinson PE, Summerly R, Lawson LJ: Postoperative progressive gangrene: A reminder. *Br J Dermatol* 94:89-96, 1976.
19. Paine TF, Novick RP, Hall WH: Fatal gangrene caused by *Streptococcus pyogenes*. *Arch Intern Med* 112:936, 1963.
20. Collins RH, Nadel MS: Gangrene due to hemolytic streptococcus: A rare but treatable disease. *N Engl J Med* 272:578-580, 1965.
21. Strasburg SM, Silver MS: Hemolytic streptococcus gangrene: An uncommon but frequently fatal infection in the antibiotic era. *Am J Surg* 115:763-768, 1968.
22. Cotter PW, Morris JB: Acute streptococcal gangrene. *J Bone Joint Surg* 44:891-895, 1962.

Multiple Cutaneous Metastases of a Scapular Chondrosarcoma

Donald T. King, MD; Arnold W. Gurevitch, MD; Frank M. Hirose, MD

• The onset of metastatic chondrosarcoma in a young woman was heralded by the appearance of multiple firm, tender, cutaneous nodules two years after the primary tumor in the left scapula had been resected. Chondrosarcoma rarely metastasizes to the skin, but when it does, it may have an identical histological appearance to a cartilaginous tumor of the skin, an entity that is generally considered clinically benign. Although it is very unlikely that an occult chondrosarcoma will be first manifested clinically by a solitary cutaneous metastasis, the abrupt appearance of multiple cutaneous cartilaginous lesions would seem to warrant an investigation for primary chondrosarcoma.

(*Arch Dermatol* 114:584-586, 1978)

Cutaneous metastasis of noncutaneous malignant neoplasms is an infrequent but well-recognized entity with an incidence varying from 1% to 2.7%.[1] Although it usually occurs late in the course of a fatal malignancy[2] and indicates a progression of the primary tumor,[3] a skin metastasis may rarely be the first sign of an internal malignant neoplasm.[4]

Cutaneous metastases are usually carcinomas, most commonly originating in the breast in the female and in the lung in the female and in the lung in the male.[5] Sarcomas, however, rarely metastasize to the skin. In an extensive recent series of metastatic tumors of the skin, sarcomas occurred in only 19 of 724 patients.[6] Although infrequent, metastatic sarcomas to the skin may nevertheless pose significant diagnostic problems because of possible confusion with primary cutaneous sarcomas or benign lesions. In addition, different metastatic sarcomas may appear to be very similar to one another histologically, thus making precise classification difficult in the absence of adequate sampling or intensive study, including electron microscopy. This is certainly true for metastatic chondrosarcoma, which may bear a histological similarity to a number of benign and malignant conditions. For example, cartilaginous tumors of the skin and other soft tissues are generally biologically benign and can be treated conservatively despite the fact that they have morphological features associated with chondrosarcoma.[7] Embryonic cartilaginous rests, such as Reichert's cartilage in the neck, may be in close proximity to the skin[8] and may be mistaken for a chondrosarcoma by the unwary. Malignant skin tumors of neural crest origin, such as malignant melanoma and malignant schwannoma, have been shown to contain fetal cartilage.[9] Chordomas, which are rare neoplasms of notochordal remnants, primarily have a mucinous stroma but may sometimes display a chondroid-appearing matrix.[10] Although usually only locally invasive, they occasionally become aggressive and metastasize to numerous organs, including the skin.[11] In addition, chondrosarcomas may produce a myxoid stroma. Similarly, other benign and malignant mesenchymal tumors such as liposarcoma, rhabdomyosarcoma, myosarcoma, neurofibroma, and nodular pseudosarcomatous fasciitis can have a myxoid stroma,[12] making correct differentiation and identification of these entities difficult and hazardous. An instance of scapular chondrosarcoma with multiple metastases to the skin as well as other organs is presented to illustrate the clinical and microscopic appearance of this rare dermatologic event and to bring into focus other cutaneous conditions that might be confused with it.

REPORT OF A CASE

A 31-year-old woman came to Harbor General (Torrance, Calif) Hospital in June 1971 because of an enlarging and painful swelling over her left posterior shoulder that was of six months' duration. Roentgenographs of the area revealed a soft tissue mass arising from the scapula with flocculent calcification strongly suggesting a chondrosarcoma. To preserve function of the left shoulder, a partial left scapulectomy was performed. Microscopically, the lesion was found to be a chondrosarcoma with extension into surrounding soft tissues. However, the margins of resection were free of tumor. In addition, results of a metastatic survey of the body were normal. The patient did well until the middle of 1973 at which time cystic-appearing lesions developed on the left vulva making sitting uncomfortable. Over the succeeding six months, additional cutaneous nodules appeared on the right thumb (Fig 1), right middle toe (Fig 2), and scalp, as well as within the mouth. The right thumb lesion occasionally drained a clear fluid. When the patient was readmitted in January 1974, the cutaneous lesions were found to be tender, firm, and skin colored to bluish red with a somewhat cystic or translucent appearance. The overlying epidermis was

Accepted for publication June 1, 1977.

From the Departments of Pathology (Drs King and Hirose), and Medicine (Dr Gurevitch), Division of Dermatology, Harbor General Hospital, Torrance, Calif, and the UCLA School of Medicine (Drs King, Gurevitch, and Hirose), Los Angeles.

Reprint requests to Department of Medicine, Division of Dermatology, Harbor General Hospital, Box 9, 1000 W Carson St, Torrance, CA 90509 (Dr Gurevitch).

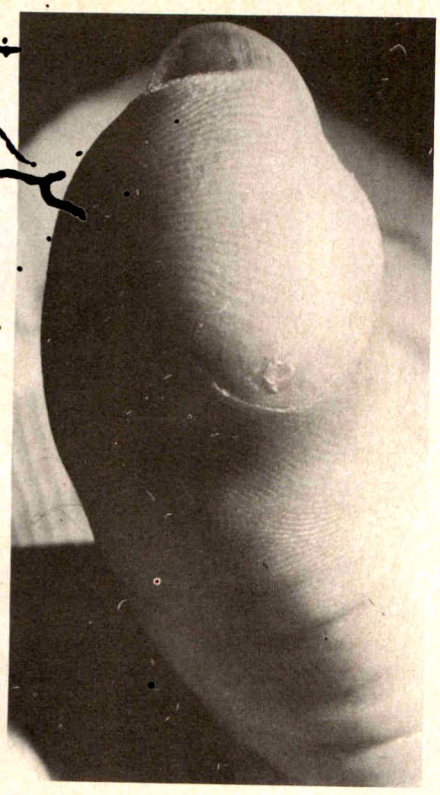

Fig 1.—Metastatic chondrosarcoma to right thumb.

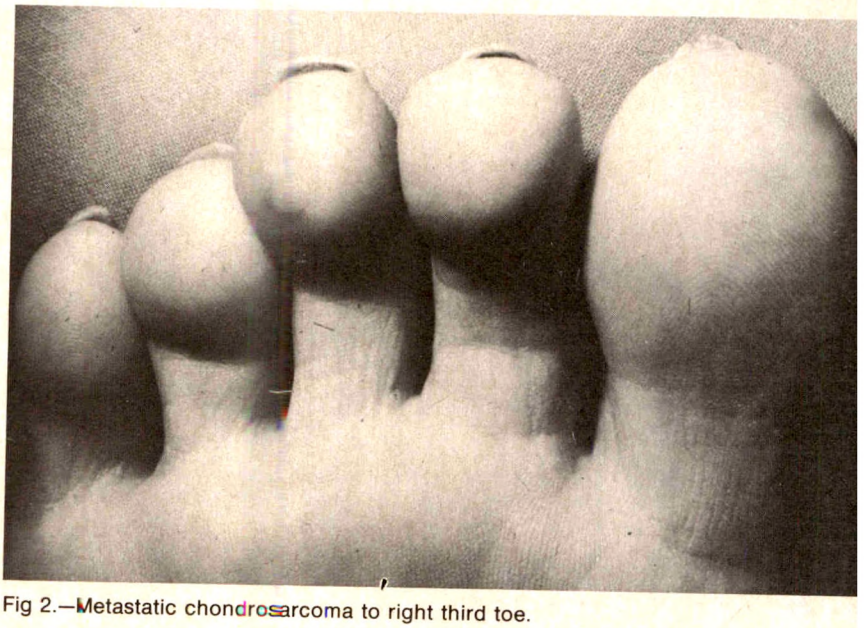

Fig 2.—Metastatic chondrosarcoma to right third toe.

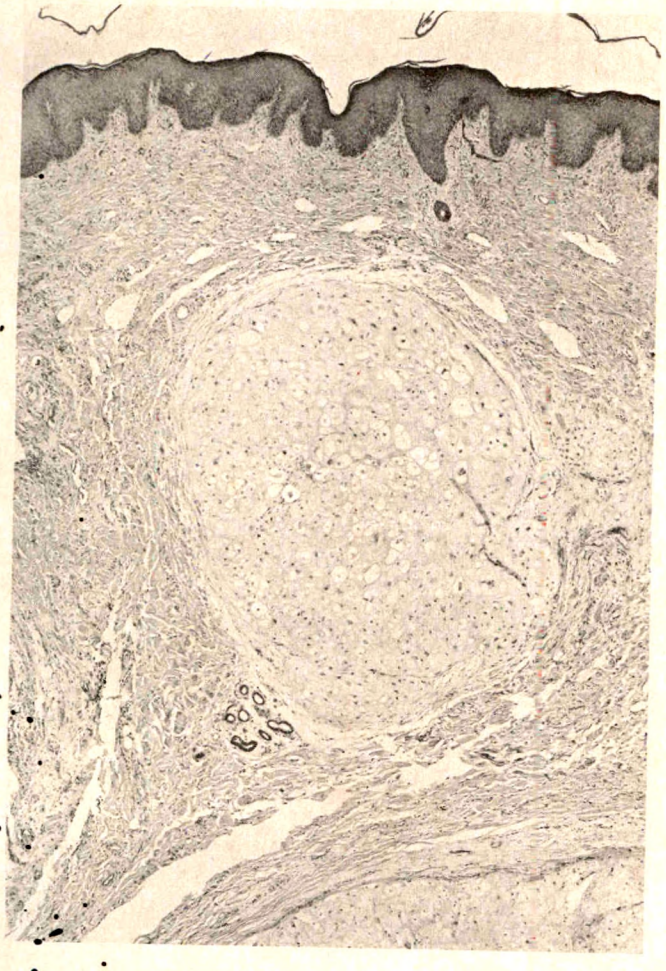

Fig 3.—Biopsy specimen from vulva showing nodule of metastati chondrosarcoma within dermis (hematoxylin-eosin, original magnifi cation ×24).

Fig 4.—Biopsy specimen of metastatic nodule on right third toe showing large cells with angulated, hyperchromatic nucle surrounded by myxomatous cartilage (hematoxylin-eosin, origina magnification ×150).

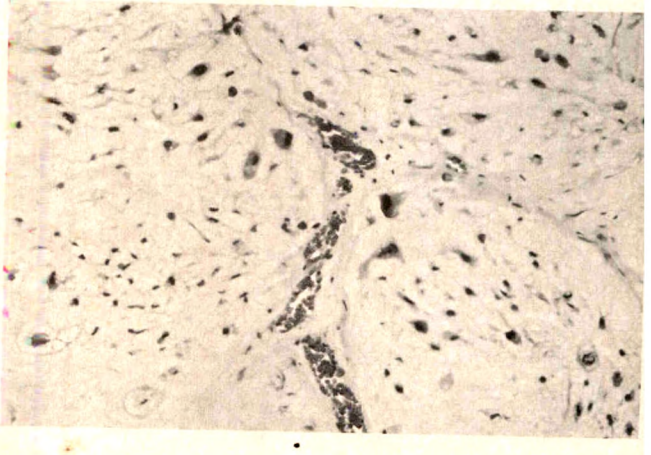

intact. The clinical differential diagnosis included metastatic chondrosarcoma, myxoid cysts, glomus tumor and eccrine poroma (thumb and toes), and epidermal inclusion cysts (vulva). Biopsy specimens of the maxillary, vulvar, and middle toe lesions showed chrondrosarcoma morphologically similar to the primary scapular lesion. Microscopically, the skin lesions were situated within the dermis and subcutaneous tissue. The large, irregular neoplastic cells were widely spaced and situated in lacunae. They contained large, plump, irregularly angulated ovoid nuclei with increased dense chromatin. Mitoses were rare. The surrounding stroma had both a myxomatous and chondroid pattern (Figs 3 and 4). A technetium Tc 99m diphosphonate bone scan revealed recurrence of the tumor in the left scapula and spreading to the calvarium, right knee, and right ankle. As palliative therapy, the patient received x-irradiation to the right thumb, plus weekly administration of actinomycin D. A partial left vulvectomy was also performed.

Two months later the patient was readmitted with fever and shortness of breath. Chest roentgenograms showed a bilateral pulmonary infiltrate that partially resolved with administration of antibiotics. A pericardial effusion with refractory congestive heart failure also developed. After stabilization, the patient was discharged only to return to the emergency room 24 hours later with acute pulmonary edema. Soon after arrival, the patient suffered a cardiac arrest and resuscitation efforts were unsuccessful.

Postmortem examination revealed spread of the chondrosarcoma to numerous organs. The middle lobe of the right lung was involved, with extension into the pulmonary vein and right atrial cavity. In addition, the dura mater, parietal cortex of the brain, left kidney, spleen, pericardium, pleura, mesentery, omentum, liver, pancreas, and ovary were involved by the tumor. Additional cutaneous metastatic sites included the right heel.

COMMENT

Chondrosarcoma is the second most common primary malignant neoplasm of bone, with osteosarcoma being the first. It most often originates in the pelvic bones but may begin in a wide variety of sites, including ribs, femur, humerus, spine, scapula, tibia, fibula, sacrum, and sternum. It is slightly more frequent in males and usually occurs in middle adulthood. A majority of the lesions originate de novo in bones, but they also may arise in preexisting benign lesions, especially osteocartilaginous exostoses, or even in teratomas or other composite tumors. Patients with familial disorders characterized by multiple osteocartilaginous exostoses, such as Ollier's disease and Maffucci's syndrome, have a high risk of chrondrosarcomas developing. Clinically, chondrosarcomas grow slowly and may remain locally invasive for a long period of time. However, metastasis can occur, usually via the blood stream and primarily involving the lungs. Other less common metastatic sites are the liver, kidney, brain, heart, and lymph nodes.[13] Cutaneous metastasis has been noted previously but is an extremely rare occurrence.[14]

Morphologically, chondrosarcomas may be characterized by their resemblance to normal cartilage, except for many cells containing one or two enlarged plump nuclei with increased and clumped chromatin content. A lobular growth pattern is confirmatory. Giant cartilage cells with large single and multiple nuclei readily confirm the sarcomatous nature of the tumor. Mitoses are usually uncommon but aid in the diagnosis. The intervening stroma in chondrosarcomas can show a spectrum from well-differentiated hyaline cartilage to chondroid tissue with myxomatous features.[15] As aforementioned, some of these morphological features, such as were seen in our case, may be shared by benign lesions found in the skin, making a pathological diagnosis treacherous and difficult. Perhaps the greatest problem for the pathologist is to differentiate a metastatic chondrosarcoma to the skin or subcutaneous tissue from a benign cartilaginous tumor of the skin and soft tissues. Some investigators have considered these benign lesions to be chondrosarcomas because of their striking histological similarity to true chondrosarcomas originating in bone.[16,17] However, in surveying ten soft tissue cartilaginous tumors of the hands and feet, Lichtenstein and Goldman[18] concluded that they are usually benign and nonaggressive, despite their ominous microscopic appearance. Nonetheless, they did caution that on rare occasions aggressive tumors may be encountered within the muscle or connective tissue of the buttock, thigh, or leg.

Metastatic chondrosarcoma should be included in the differential diagnosis of cartilage-containing tumors of the skin and soft tissue. The fact that metastatic chondrosarcomas and cartilaginous tumors of the skin and soft tissues are so similar histologically makes clinical data crucially important if the correct diagnosis is to be made. A solitary lesion on the hands or feet is almost certainly a benign cartilaginous tumor and no further study is needed. However, the rapid appearance of multiple lesions should arouse suspicion and suggest further study, such as a radiographic bone survey. This is especially true in patients with a history of chondrosarcoma or conditions predisposing them to the development of chondrosarcoma.

Nonproprietary Name and Trademark of Drug

Dactinomycin—*Cosmegen.*

References

1. Beerman H: Some aspects of cutaneous malignancy. *Am J Med Sci* 233:456-472, 1957.
2. Mehregan AH: Metastatic carcinoma to the skin. *Dermatologica* 123:311-325, 1961.
3. Reingold IM: Cutaneous metastases from internal carcinoma. *Cancer* 19:162-168, 1966.
4. Taboada CF, Fred HL: Cutaneous metastases. *Arch Intern Med* 117:516-519, 1966.
5. Brownstein MH, Helwig EG: Patterns of cutaneous metastasis. *Arch Dermatol* 105:862-868, 1972.
6. Brownstein MH, Helwig EB: Metastatic tumors of the skin. *Cancer* 29:1298-1307, 1972.
7. Holmes HS, Bovenmeyer DA: Cutaneous cartilaginous tumor. *Arch Dermatol* 112:839-840, 1976.
8. Ash JE, Raum M: An Atlas of Otolaryngic Pathology, Armed Forces Institute of Pathology, 1956, p 444.
9. Wahlström T, Saxën L: Malignant skin tumors of the neural crest origin. *Cancer* 38:2022-2026, 1976.
10. Lichtenstein L: *Bone Tumors*. St Louis, CV Mosby Co, 1972, pp 338-339.
11. Willis RA: Sacral chordoma with widespread metastases. *J Pathol Bacteriol* 33:1035-1043, 1930.
12. Fine G, Horn RC: Soft tissue tumors: Aids in differential diagnosis. *Pathol Ann* 4:211-229, 1969.
13. Spjut HJ, Dorfman HD, Fechner RE, et al: *Tumors of Bone and Cartilage*. Atlas of Tumor Pathology, Armed Forces Institute of Pathology, 1971, fascicle 5, pp 84-86.
14. Cruickshank AH: Chondrosarcoma of a phalanx with cutaneous metastases. *J Pathol Bacteriol* 57:144-145, 1945.
15. Barnes R, Catto M: Chondrosarcoma of bone. *J Bone Joint Surg* 48B:729-764, 1966.
16. Stout AP, Verner EW: Chondrosarcoma of the extraskeletal soft tissues. *Cancer* 6:581-590, 1953.
17. Goldenberg RR, Cohen P, Steinlauf P: Chondrosarcoma of the extraskeletal soft tissue: A report of seven cases and review of the literature. *J Bone Joint Surg* 49A:1487-1507, 1967.
18. Lichtenstein L, Goldman RL: Cartilage tumors in soft tissues, particularly in the hand and foot. *Cancer* 17:1203-1208, 1964.

Aneurysm of the Superficial Temporal Artery

Edward C. Lewis II, MD, Edward G. Southwick, MD

• An aneurysm of the superficial temporal artery is a rare lesion, which should be suspected after blunt trauma to the forehead that is followed by the appearance of a pulsatile cystic lesion in the region of the superficial temporal artery. Treatment by excision of the aneurysm with ligation of the afferent and efferent arteries is curative.

As this lesion may be mistaken clinically for an epidermal inclusion cyst, aneurysm should be included in the differential diagnosis prior to therapy.

***(Arch Dermatol* 114:587-588, 1978)**

With the diminished use of swords as weapons, aneurysms of the superficial temporal artery have become a medical rarity. From 1934 to 1976, there were 11 aneurysms of the superficial temporal artery reported in the literature.[1-4] Of these aneurysms, only two were diagnosed by angiography preoperatively.[5,6] We herein present a recently observed case of this condition.

REPORT OF A CASE

A 15-year-old boy was seen on Jan 4, 1976, because of a "cyst" on the right side of his forehead (Fig 1). The patient stated the mass had appeared approximately three weeks previously, when he was punched on the right side of the forehead. Shortly thereafter, he developed a 2.5-cm mass, which gradually decreased in size to 1.0 cm and was located over the right lateral eyebrow. The mass was cosmetically objectionable, but was otherwise asymptomatic.

Systemic review and family history of the patient were noncontributory. Positive physical findings were limited to the head, where a 1.0-cm, pulsating, spherical mass was noted in the course of the anterior division of the right superficial temporal artery, just superior to the right lateral eyebrow. There was no palpable thrill over the mass, nor could a bruit be heard. T pulsations of the mass disappeared wi pressure on the afferent portion of t superficial temporal artery. A comple vascular examination disclosed otherwi normal pulses in the head and nec abdomen, and all extremities. The blo pressure was 100/50.

A right external carotid arteriogra taken on Jan 4, 1976, demonstrated a so tary aneurysm of the anterior branch the right superficial temporal artery (Fig and 3). There was no evidence of commun cation with the deeper vascular structu or with the venous system. The followin day, the lesion was excised in the operatin room without difficulty, and the patient postoperative course was uneventful. Hi topathological examination of the spe imen revealed a 1.0-cm aneurysm of th right superficial temporal artery, with

Fig 1.—Aneurysm of superficial tempora artery. Note similarity of this lesion t epidermal inclusion cyst.

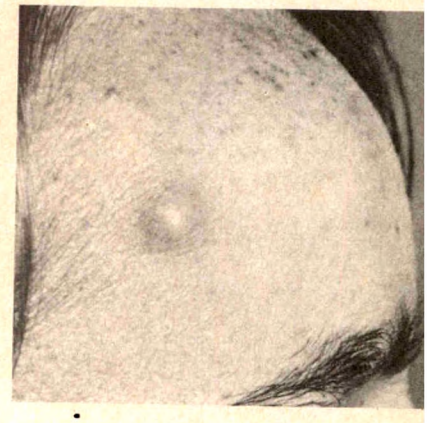

Accepted for publication June 6, 1977.

From the Division of Plastic Surgery, Department of Surgery (Dr Lewis), and the Division of Dermatology, Department of Medicine (Dr Southwick), University of Utah College of Medicine, Salt Lake City.

Reprint requests to 1220 E 3900 S, Salt Lake City, UT 84117 (Dr Lewis).

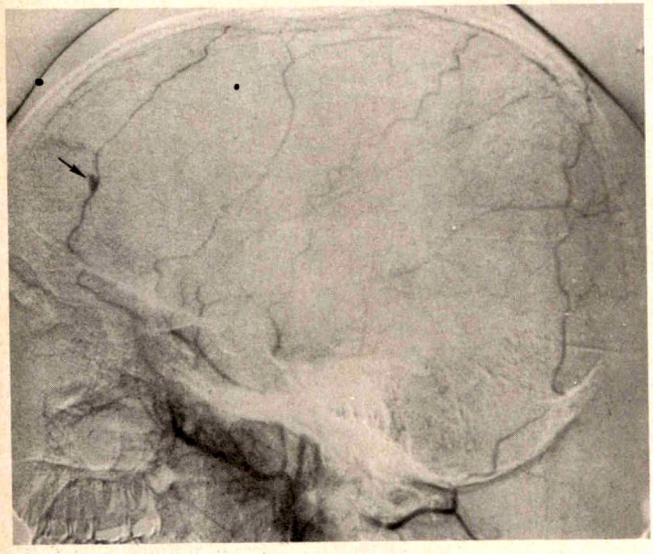

Fig 2.—Right lateral view of arteriogram of superficial temporal artery demonstrates presence of aneurysm on right side (arrow).

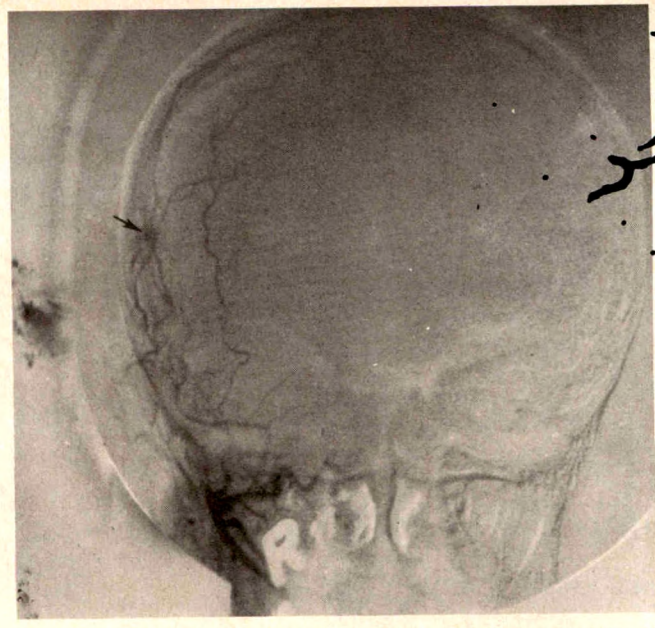

Fig 3.—Frontal view of arteriogram demonstrates presence of aneurysm (arrow).

patent lumen and small areas of thrombosis.

COMMENT

Aneurysms of the superficial temporal artery are a medical rarity. In the past, injuries secondary to dueling were common causes of this lesion; however, the usual cause now is blunt trauma.[4,5,7]

The aneurysm is first seen as a rapidly appearing cystic mass following blunt trauma to the forehead, and may be associated with headaches. The usual complaint is of a cosmetically objectionable lesion in the area of the superficial temporal artery. The differential diagnosis of a pulsatile lesion of the lateral forehead includes an arterial venous fistula, aneurysm of the middle meningeal artery with erosion of the temporal bone,[8] and an epidermal inclusion cyst, hematoma, or abscess overlying the temporal artery. Clinicians should appreciate that a lesion that clinically seems to be an epidermal inclusion cyst over the area of the superficial temporal artery may be pulsatile and may indeed be an aneurysm of this artery. In such cases, it is important to be certain of the latter possibility, and to have the appropriate operative capabilities available.

References

1. Gittes RF, Kartchner MM: Posttraumatic temporal artery aneurysm: Recurrent surgical curiosity. *Arch Surg* 87:398-400, 1963.
2. Hite SJ, Groves RA, Sharkey PC: Superficial temporal artery aneurysms. *Neurology* 16:1044-1046, 1966.
3. Winslow N, Edwards M: Temporal aneurysm: Analysis of cases reported in literature to June 1, 1934, and report of case of traumatic origin. *Am J Surg* 28:696-702, 1935.
4. Hait G, Mushorn RH: Aneurysms of the superficial temporal artery. *Br J Plast Surg* 29:286-287, 1976.
5. Wilson B: Aneurysms of the superficial temporal artery. *Am J Roentgenol* 105:331-333, 1969.
6. Wortzman G: Traumatic pseudo-aneurysm of superficial temporal artery: Case report. *Radiology* 80:444-446, 1963.
7. Davies DGL: Traumatic aneurysm of superficial temporal artery. *Br J Surg* 49:343-344, 1962.
8. Berk ME: Aneurysm of middle meningeal artery. *Br J Radiol* 34:667-668, 1961.

New Requirement for Authors

Congress recently passed *The Copyright Revision Act of 1976*, effective Jan 1, 1978, which affects the American Medical Association's procedure for reviewing manuscripts submitted for publication.

In view of this law, all transmittal letters accompanying manuscripts submitted for publication should contain the following language: "In consideration of the AMA taking action in reviewing and editing my submission, the author(s) undersigned hereby transfers, assigns, or otherwise conveys all copyright ownership to the AMA in the event that such work is published by the AMA."

Aspiration Metastases From Basal Cell Carcinoma

The 92nd Known Case

Ramon A. Guillan, MD, Richard P. Johnson, MD

• Was aspiration a cause of lung metastases from basal cell carcinoma? We compared our case to prior reported cases with metastases to the lung attributable to aspiration and considered a prior experimental model. We are convinced we have another case of aspiration metastases from basal cell carcinoma, and hereby report "the 92nd known case."
(*Arch Dermatol* 114:589-590, 1978)

Although a recent review by Costanza et al[1] has shown the number of reported cases of metastatic basal cell carcinoma to be 91, including 13 previously uncounted cases plus one of their own, this type of behavior for this tumor is still a rarity. A survey by Cotran[2] of over 9,000 cases disclosed the proportion of basal cell carcinomas that metastasize to be 0.1% and this figure is probably too high. A limited survey by Paver et al[3] in Australia and New Zealand disclosed a rather high incidence of basal cell carcinoma but an incidence of metastases in the order of 0.0028%. Of the reported cases, the lymph nodes are involved in 70% of cases, lungs and pleura in 20%, liver in 18%, and bone in 17%.[3]

Accepted for publication June, 6, 1977.
From the Veterans Administration Hospital, Topeka, Kansas.
Reprint requests to VA Hospital, 2200 Gage Blvd, Topeka, KS 66622 (Dr Guillan).

In 1958, Pickren and Katz[4] proposed the hypothesis that in certain cases lung metastases could be due to aspiration of viable tumor cells providing certain conditions were met. These included (1) a route for the cells to penetrate into the respiratory tract, such as facial deformities, fistulas, surgical communication, and so on; (2) a means of displacement of tumor cells caused by fragmentation of tumor, trauma, and so on, allowing cells to enter the respiratory tract; (3) facilitation of this aspiration process by unconsciousness or lack of cough reflex; and (4) an implantation of malignant cells in the lung. Unless these conditions exist, it should be assumed that dissemination to the lung is probably hematogenous.

From the time Pickren and Katz[4] presented this idea, it became an accepted concept in the literature, but it has not been examined. Wermuth and Fajardo[5] have recently employed this mechanism of aspiration as the cause of lung metastases from basal cell carcinoma in a case they reported. One may conclude that 20% of the metastases of basal cell carcinoma are pulmonary. Of these only a small percentage are attributable to aspiration of tumor cells.

We wish to report an additional case of metastatic basal cell carcinoma, bringing the total number of cases reported to 92, and to review this idea of aspiration as a cause of lung metastases from basal cell carcinoma as illustrated by the following case report.

REPORT OF A CASE

A 60-year-old man was admitted for the first time in August 1969 to the Veterans Administration Hospital in Topeka, Kan, for follow-up and further treatment of a basal cell carcinoma of the face that had been present since 1943. The histologic findings of prior specimens had shown some to be inadequately resected and others to be multicentric tumors. Past history disclosed numerous surgical procedures for recurrent basal cell carcinoma of the face, including excision of the left orbit, left cheek, and left lateral aspect of the nose in 1962, and removal of ten additional lesions in 1963, all basal cell carcinomas, only one of which was considered well resected. Further treatment in the past had included x-ray therapy, skin grafting, high-voltage radiation, and local conservative care. In 1971, fluorouracil ointment was used locally and resulted in temporary cessation of tumor growth.

All treatment modalities proved to be unsuccessful. The patient proceded along a downhill course with progressively severe facial erosion. There was an inability to swallow and clinically apparent aspiration accompanied by choking and coughing. He developed signs and symptoms of bronchopneumonia and died. Permission for full autopsy was granted.

AUTOPSY FINDINGS

The significant finding at autopsy was massive destruction of the left

Fig. 1.—Section of lung metastasis showing histologic findings similar to those of the skin lesion, with masses of tumor cells contained within alveolar lumina (hematoxylin-eosin, ×125).

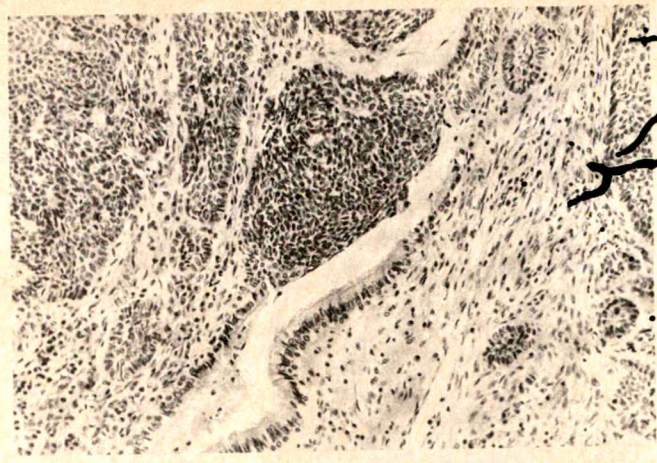

Fig 2.—Another section of lung metastasis illustrating peribronchial infiltration of tumor and partial ulceration of the bronchial epithelium (hematoxylin-eosin, ×125).

side of the face extending deep within the oropharynx and nasopharynx, exposing underlying bone that was itself partially covered with tumor and granulation tissue. The frontal bone of the skull was involved with infiltration into the left frontal portion of the brain. Multiple, round, whitish, centrally located tumor nodules were present in both lungs. The lungs also showed bronchopneumonia with abscess formation and passive congestion. Lymph nodes were free of tumor.

Histologic examination of the primary tumor, and sections of the lung metastases (Fig 1 and 2) disclosed basal cell carcinoma with peripheral palisading of cells. The histologic findings were similar to those of the tumors that were resected from the face of this patient during the past 28 years.

COMMENT

In comparing our case with other reported and accepted cases, the criteria for metastatic basal cell carcinoma proposed by Cotran[2] are met. These criteria are (1) the primary tumor should arise from the skin and not from salivary gland or mucous membrane; (2) metastases should be shown in lymph nodes or viscera and should not be explainable by direct extension of the tumor; (3) the histologic findings of the primary and metastatic lesions should be similar and documented. In addition, the criteria for lung metastases by aspiration as set forth by Pickern and Katz[4] and discussed in the introduction are fulfilled in that this patient did have ample passageway for the aspiration of tumor cells due to severe loss of soft tissue of the face, repeated surgical procedures and opportunity for traumatic dislodgement of cells, a depressed cough reflex and clinical and autopsy evidence of aspiration, and histologic evidence of implantation of tumor in the lungs.

In comparing our case with those reported by Pickren and Katz,[4] as well as by Wermuth and Fajardo,[5] with lung metastases attributable to aspiration, the tumor histology present in the lungs was one of tumor growth from a main bronchus to involve the surrounding alveoli in two cases and of growth within alveolar lumina in another. This growth within alveolar lumina is shown in Fig 1 in our case.

In an experimental model done much earlier by Furth[6] in white mice susceptible to the tumor strains used, intranasal instillation of neoplastic cells seemed to uniformly show peribronchial infiltration of tumor in those animals developing lung neoplasms from the inhalation of cells. An area of histology similar to this experimental model was searched for in our case and is illustrated in Fig 2, where peribronchial infiltration is clearly evident. We believe this case to be notable for the degree of correlation, both with prior cases attributable to aspiration, as well as with the initial experimental model showing aspiration as a possible route to lung metastases. Also of note is how extensive this can be, as illustrated by the number of separate metastatic foci in the lung encountered in this case.

In view of the clinical and experimental evidence presented, as well as the locally invasive nature of basal cell carcinoma, we believe that aspiration metastases of basal cell carcinoma is a valid concept and was the causative factor in the development of lung metastases in our case. A possible factor influencing this behavior is that of tumor host response; for some unknown reason the body was unable to contain and destroy tumor cells at the level of the skin.

References

1. Costanza ME, Dayal Y, Binder S, et al: Metastatic basal cell carcinoma: Review, report of a case, and chemotherapy. *Cancer* 34:230-235, 1974.
2. Cotran RS: Metastasizing basal cell carcinomas. *Cancer* 14:1036-1040, 1961.
3. Paver K, Poyzer K, Burry N, et al: The incidence of basal cell carcinoma and their metastases in Australia and New Zealand, letter. *Australas J Dermatol* 14:53, 1973.
4. Pickren JW, Katz AD: Aspiration metastases from basal cell carcinoma. *Cancer* 11:783-789, 1958.
5. Wermuth BM, Fajardo LF: Metastatic basal cell carcinoma: A review. *Arch Pathol* 90:458-462, 1970.
6. Furth J: Experiments on spread of neoplastic cells through respiratory passages. *Am J Pathol* 22:1101-1107, 1946.

Hereditary Painful Callosities

William Roth, MD; Neal S. Penneys, MD, PhD; Nancy Fawcett, MD

• An autosomal dominant genodermatosis that is characterized by painful callosities develops over pressure points. Histologically, these lesions are similar to epidermal nevi.

(*Arch Dermatol* 114:591-592, 1978)

We have recently evaluated a patient with an unusual genodermatosis that is characterized by the development of painful callosities at pressure points. Review of the literature did not produce evidence of a similar kindred.

REPORT OF A CASE

The State of Florida Department of Health and Rehabilitative Services referred a 16-year-old girl with painful callosities of both soles. Skin lesions were first noted at age two and coincided with upright ambulation. Skin overlying pressure points on the weight-bearing areas gradually thickened, became painful, and large callosities developed. Walking produced pain that was most severe during the first hour of ambulation each morning. There was swelling of the callosities with increased pain after exposure to water. Frequent paring of the lesions and the use of oversized shoes allowed her to walk. During the preceding six months, she had noticed coarsening of the skin below both knees that she associated with kneeling. There was no personal or family history of hair, nail, or eye disease, arthritis, or hyperhidrosis of the palms. The paitent has had poor dental hygiene and increasing tooth decay since age 14.

On her skin were tender yellowish-brown hyperkeratotic plaques that protruded up to 1.5 cm from the heels, distal plantar surfaces, and sides of the toes (Fig 1). A symmetrical, flesh-colored papular eruption extended from the midpatella 10 cm distally along the anterior tibial surfaces. Remarkable dental caries and gingivitis were thought by the Department of Oral Surgery to be related to poor hygiene, although an association with the callosities could not be ruled out.

Results of the following tests were either within normal limits or negative: complete blood cell count, VDRL, chest roentgenogram, a blood chemistry profile using an automated analysis system (SMA-6, SMA-12), and amino acid, mucopolysaccharide, and hydroxyproline screening tests on the urine and serum. Bone age, which was determined by roentgenograms of the hands, was 15 to 16 years. A long bone survey and scanogram revealed that the right tibia was 0.4 cm longer than the left. Roentgenograms of the feet showed soft-tissue thickening without bone changes.

Similar histories were obtained from other affected family members. Painful callosities would develop in areas that had received trauma. Family members generally had normal dentition, although many had problems that were related to poor oral hygiene. The patient's father performed

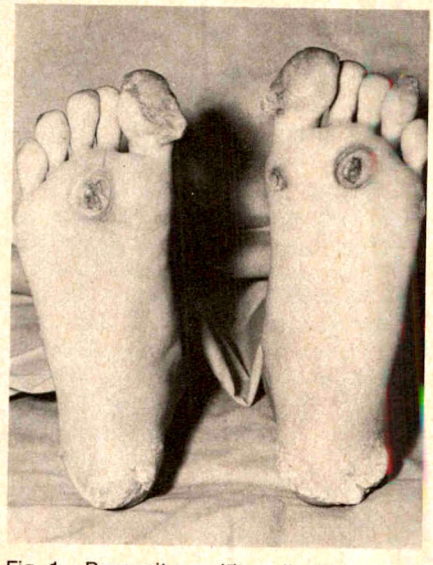

Fig 1.—Propositus with callosities overlying pressure points on soles and toes.

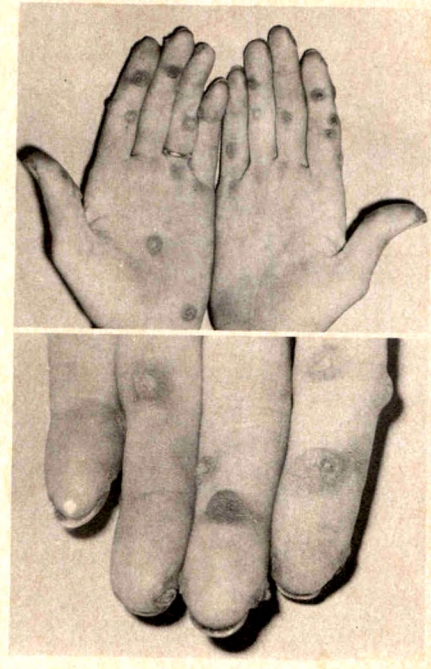

Fig 2.—Top and bottom, Pressure-induced lesions on palms and fingers of father of propositus.

Accepted for publication July 18, 1977.

From the Departments of Dermatology (Drs Roth and Penneys) and Pediatrics (Dr Fawcett), University of Miami School of Medicine, Miami.

Reprints not available.

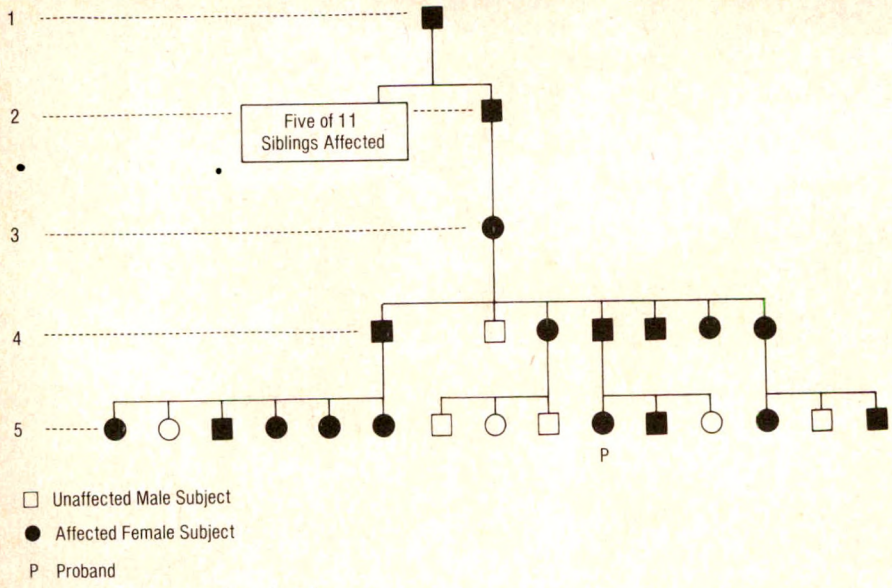

Fig 3.—Family tree of proband.

Fig 4.—Excisional biopsy specimen of lesion on toe illustrating massive compact hyperkeratosis (hematoxylin-eosin, ×25).

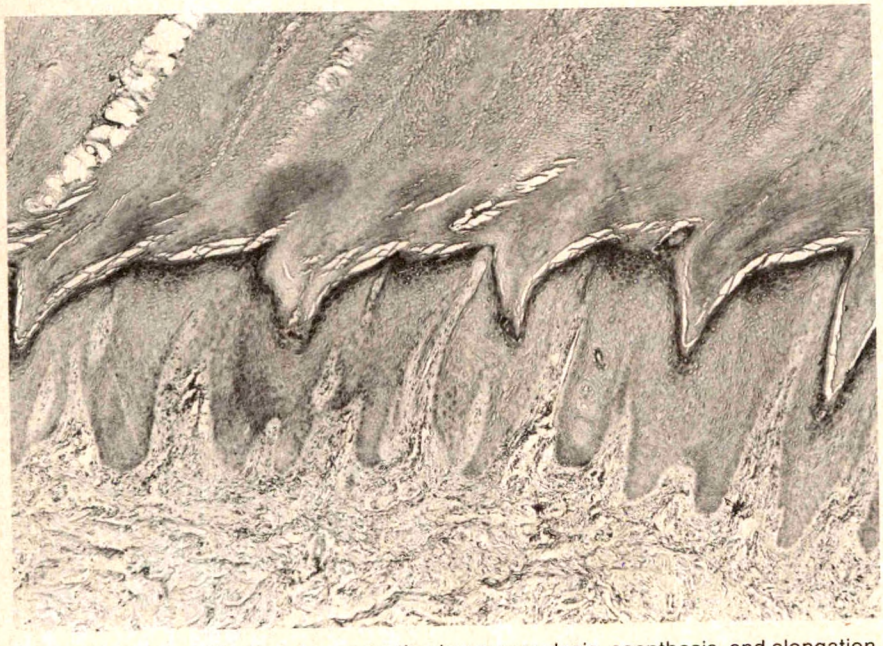

Fig 5.—Higher magnification demonstrating hypergranulosis, acanthosis, and elongation of epidermal rete (hematoxylin-eosin, ×110).

manual labor and, in addition to lesions on his feet, had multiple callosities on the palms and dorsa of the hands and fingers (Fig 2, top and bottom). He observed that callosities would frequently form where there had been lacerations. Of the many affected relatives, none had received medical therapy of lasting benefit. Interviews with other family members suggested an autosomal dominant disorder for at least five generations (Fig 3).

PATHOLOGIC FINDINGS

Biopsy specimens were taken from two areas: a massive, hyperkeratotic lesion on the lateral aspect of the left hallux and a papule over the patella. The histopathologic picture was similar in both specimens, although it was more accentuated in the hyperkeratotic lesion. There was compact hyperkeratosis beneath which was a papillomatous and acanthotic epidermis with elongation of the rete ridges (Fig 4 and 5). An inflammatory infiltrate was not prominent. We felt that the picture was compatible with an epidermal nevus.

COMMENT

Classification of genodermatoses that are characterized by palmoplantar hyperkeratosis is a conundrum because of the innumerable variants and descriptive names reported in the literature.[1] Our review did not produce a similar kindred in which the unique feature of a relationship between an external factor, pressure, and the development of a skin lesion, callosity, was observed. Histologically, these lesions had patterns similar to those seen in epidermal nevi. Although this was a nonspecific picture, it served to differentiate these lesions from such entities as plantar porokeratosis and clavus.

Therapy in our case was directed at redistributing pressure over the entire plantar aspect of the foot. This was accomplished by specially designed shoes constructed by the Department of Physical Rehabilitation.

This investigation was supported in part by the Dermatology Foundation of Miami and by Public Health Service research grant AM 19079 from the National Institutes of Health. Neal S. Penneys, MD, is the recipient of Research Career Development Award AM 00203 from the National Institutes of Health.

References

1. Costello MJ, Gibbs RC: *The Palms and Soles in Medicine.* Springfield, Ill, Charles C Thomas Publisher, 1967, pp 589-625.

Human Infection With *Dirofilaria*

Hushang M. Payan, MD

• Human infection with *Dirofilaria* is rare. Fewer than 100 cases have been reported in the world's literature. Among the cases reported in the United States, most of the patients have been from Florida and Louisiana. The majority of the patients had a single lesion that involved either the skin or the lung. The case presented here is unusual because the patient had two skin lesions, and because the condition occurred in a patient who lived in the North-Central portion of the United States (Upper Michigan).

(*Arch Dermatol* 114:593-594, 1978)

Dirofilariasis, or "heart worm disease" is fairly common in dogs, cats, wolves, muskrats, and raccoons.[1] Human cases are extremely rare.[2] About 50 cases have been reported in the United States, most of which are from the southeastern states (Florida, Louisiana, etc).[3] Infection of man by *Dirofilaria* is as rare elsewhere as it is in the United States.[4] Among the reported cases, seldom does a patient have more than one lesion.[3]

In this communication, a case of human dirofilariasis with two unusual features is reported: (1) the disease manifested itself with two separate skin lesions; and (2) this is the first recorded case to occur in Upper Michigan, a geographic location in the North Central United States where the disease has been rarely reported.

REPORT OF A CASE

The patient, a 29-year-old woman, consulted her physician because of "two lumps," one on the occipital region of the scalp, and one on the mid-sternal region of the chest. The lesions were present four to five weeks before the patient sought medical attention. The lesions were described as being "like mosquito bites at the beginning, but they were persistent and kept enlarging gradually." Pruritus was present occasionally, but this was not a major problem. The physician found a fairly well-defined, firm nodule in both areas that was slightly red and tender; each nodule measured 1.5 × 2 cm in greatest diameter.

Several weeks after the lesions were removed and the diagnosis was made, the patient was questioned again and thoroughly examined. She had had dogs all her life. She also had had a raccoon for about three months the previous summer, which was 18 months prior to the development of the lesions. Some eight years before this, the patient had traveled to the state of New York for a short time. She had never been outside of the Upper Peninsula of Michigan otherwise. Complete physical examination of the patient revealed no important physiopathological findings. The roentgenogram of the chest was negative. Examination of the peripheral blood for filaria was nonproductive. The periph-

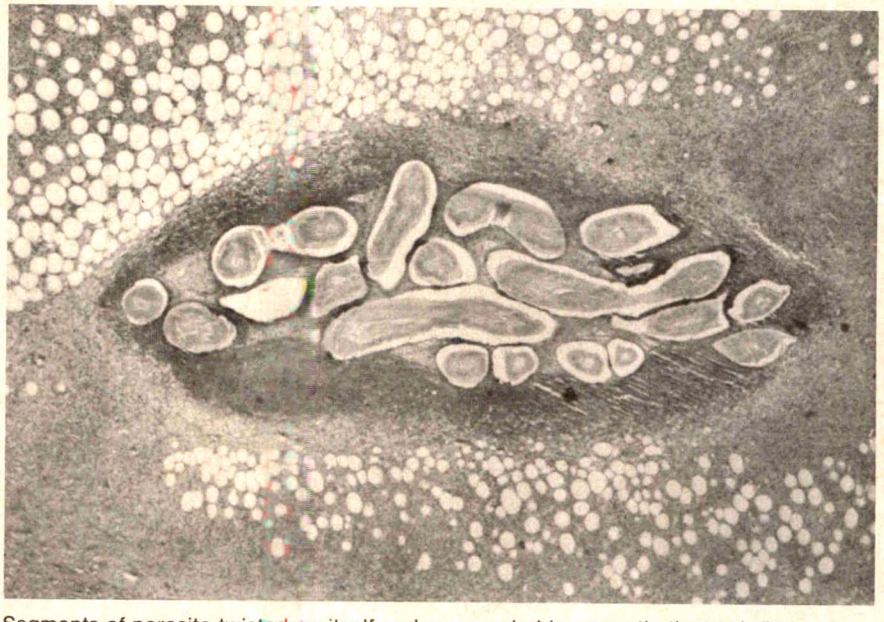

Segments of parasite twisted on itself and surrounded by necrotic tissue. Inflammatory reaction is seen in subcutaneous adipose tissue (hematoxylin-eosin, ×10).

Accepted for publication July 25, 1977.

• From the Department of Pathology, Bell Memorial Hospital, Ishpeming, Mich, and the University of Wisconsin School of Medicine, Madison.

Reprint requests to Bell Memorial Hospital, 101 South St, Ishpeming, MI 49849.

eral blood revealed 8,600 WBCs, with 70% neutrophils, 26% lymphocytes, 2% monocytes, and 2% eosinophils. The remainder of the laboratory reports were all within normal limits. An indirect hemaglutination test for filariasis was found to be positive with a titer of 1:256. The bentonite flocculation test was also positive with a titer of 1:5.

Histological examination of both lesions revealed a single degenerating male filaria in the center of each lesion, surrounded by necrotic subcutaneous tissue. The worms were identified as *Dirofilaria tenuis* by their thick, laminated cuticles, which formed internal and external longitudinal cuticular ridges. An intense inflammatory reaction was noticed around the lesion that was formed by numerous histiocytes, lymphocytes, plasma cells, and many eosinophils (Fig 1).

COMMENT

Fewer than 100 cases of dirofilariasis have been reported in the world's literature.[5-8] Beaver and Orihel, in 1965, collected reports of 39 cases from the United States.[3] The majority of reported cases in this country are from the southeast (particularly, Florida).

The majority of patients have a single subcutaneous nodule that discloses a degenerated or dead worm at the center. The second most commonly involved organ in man is the lung.[9] The lesion usually appears as a small infarct of the periphery of the lung. Coin lesions of the lung also have been reported recently.[10,11] In a few cases, the parasite has been found near or in the heart at autopsy.[12] The cause of death in these patients was not related to the presence of the parasite.[12]

Several papers in recent years maintain that tropical eosinophilia relates to *Dirofilaria*. This assumption is made on the basis of high antigen titers.[13,14] Microfilaremia has not been found in any of the patients studied.[15] The dirofilariasis is transmitted by mosquito bite from regular hosts, such as dogs and raccoons. Man is not a suitable host and therefore, since the parasite cannot reach sexual maturity, microfilaremia does not prevail. The parasite in most cases will lodge in the subcutaneous adipose tissue or in the peripheral blood vessels of the lungs. In such a location, the parasite will then degenerate and cause an inflammatory nodule around it.

The diagnosis in the present case was based on histopathological findings as well as on the antigen titer. This case is unusual in its occurrence in a north-central geographic location and in the manifestation of two skin lesions rather than one in the patient.

The slides were reviewed by James L. Hall, MD, Armed Forces Institute of Pathology, Washington, DC.

The serology examinations were done by the Michigan Department of Public Health Laboratories, Lansing, Mich.

References

1. Smith J, Jones T, Hunt R: *Veterinary Pathology*, ed 4. Philadelphia, Lea & Febiger Publishers, 1972, pp 744-745.
2. Grove D, Warren K, Mahmoud A: Algorithms in the diagnosis and management of exotic diseases: Filariasis. *J Infect Dis* 132:340-353, 1975.
3. Beaver P, Orihel T: Human infection with filariae of animals in the United States. *Am J Trop Med Hyg* 14:1010-1029, 1965.
4. Welty R, Ludden T, Beaver P: Dirofilaria in man: Report of a case from the state of Washington. *Am J Trop Med Hyg* 12:888-891, 1963.
5. Davies P, Cunningham T, Gould R: Dirofilaria infection. *NY State J Med* 73:1999-2001, 1973.
6. Jung R, Espenan P: A case of infection in man with *Dirofilaria*. *Am J Trop Med Hyg* 16:172-174, 1967.
7. Neafie R: Case for diagnosis. *Milit Med* 137:70-76, 1972.
8. Pacheco G, Schofield H: *Dirofilaria tenuis* containing microfilariae in man. *Am J Trop Med Hyg* 17:180-182, 1968.
9. Feld H: *Dirofilaria immitis* (dog heart worm) as a cause of a pulmonary lesion in man. *Radiology* 108:311-312, 1973.
10. Hendricks G, Barnes W, Lerman B: *Dirofilaria immitis:* A cause of pulmonary coin lesions in human beings. *Ann Thorac Surg* 15:526-530, 1973.
11. Robinson M, Viamonte M, Viamonte M: Dirofilariasis diagnostic consideration of pulmonary coin lesions. *South Med J* 67:461-462, 1974.
12. Abadie S, Swartzwelder C, Holman R: A human case of *Dirofilaria immitis* infection. *Am J Trop Med Hyg* 14:117-118, 1965.
13. Dobson C, Welch J: Dirofilariasis as a cause of eosinophilic meningitis in man diagnosed by immunofloresence and Arthus hypersensitivity. *Trans R Soc Trop Med Hyg* 68:223-228, 1974.
14. Feldman R, Holden M: Meningial irritation, hemoptysis and eosinophilia: A case of human dirofilariasis. *JAMA* 228:1018-1019, 1974.
15. Neva F, Kaplan A, Pacheoco G, et al: Tropical eosinophilia. *J Allergy Clin Immunol* 55:422-429, 1975.

Histoplasmosis Due to *Histoplasma capsulatum* var *duboisii* in a Canadian Immigrant

James R. Nethercott, MD; R. Kanee Schachter, MD; Kathleen F. Givan, MD; Donald E. Ryder, MD

• Histoplasmosis due to *Histoplasma capsulatum* var *duboisii* developed in a Canadian immigrant one year after his entry into Canada. He had lived in Guinea for two years prior to immigration. Lymphatic infection characterized the course of his illness. The clinical and pathologic features of this disease's distinctive skin and bone manifestations are outlined. The causal agent's mycologic features are compared with those of *H capsulatum* var *capsulatum*. Treatment with amphotericin B was successful.

(*Arch Dermatol* 114:595-598, 1978)

In 1952, Dubois et al[1] reported an unusual form of histoplasmosis which developed in a Belgian who had lived in the Belgian Congo. The causative yeast cells were much larger than in other cases of histoplasmosis, which had been described up to that time. The mycelial growth was identical. This pathogen's distinctive biologic features were reported by Dubois and Vanbreuseghem[2] and by Vanbreuseghem[3,4] who designated it a new species, *Histoplasma duboisii*. A controversy ensued among mycologists as to whether the organism represented a new species or a variant of *H capsulatum*. In 1975, Kwan-Chung[5] established that the causal agents of "African" and "common" histoplasmosis are the same species.

Cockshott and Lucas[6] collected 54 cases from the literature in 1964. By 1971, 46 more cases had been reported.[7] From these cases, a picture of histoplasmosis due to *H capsulatum* var *duboisii* (HD) emerges, which is characterized by granulomatous inflammation of bone and skin. Primary lung involvement is rare, in contrast to histoplasmosis due to *H capsulatum* var *capsulatum* (HC).

To our knowledge, all affected individuals have resided in West Africa, except for one case that was reported from India,[8] and signs of the disease have first developed in several patients in Europe. This case is the first to be reported, to our knowledge, from the western hemisphere.

Accepted for publication Aug 19, 1977.

• From the Departments of Medicine (Dermatology) and Laboratories, Women's College Hospital, University of Toronto.

Reprint requests to 600 Sherbourne St, Suite 411, Toronto, Ontario M4X 1W4 Canada (Dr Nethercott).

REPORT OF A CASE

A 24-year-old man was stationed with the Portuguese Army in Guinea from August 1969 to September 1971. On wilderness patrols, he suffered many insect bites, and on a few occasions, he slept in chicken coops to avoid exposure to the elements. To supplement his meager army diet, he ate domestic fowl, macaws and, on two occasions, baboon. He returned to Portugal in September 1971, at which time he noted a small, painless, nontender lump on the left side of his neck. On entry to Canada in March 1972, a physician found him to be in apparent good health.

While playing soccer in August 1972, he developed pain in the left side of the groin. His doctor detected several firm, matted nodes in the left side of the groin. A lymph node biopsy was carried out. Tissue was sent to the Armed Forces Institute of Pathology at Bethesda, Md. The histopathologic condition suggested a diagnosis of HD. No attempt was made to culture the organism at that time. No other lymph node disease or visceral disease was present. The physicians, who were involved, elected to observe the patient with the hope that a spontaneous remission would ensue.

Axillary lumps developed in October 1972, and palpable nodes developed in both cervical regions in November 1972. The patient was referred to us in January 1973. There was no past or family history of fungal disease, diabetes, hematologic disease, atopy, or skin disease. The patient denied weight loss, fever, night sweats, or inanition. Systemic questioning was otherwise unrevealing. At the time of his admission, physical findings were limited to the skin and lymphatic system. Two lymph nodes that measured 3 × 3-cm were noted in the left femoral area, while the right side of groin was clear. Nodes that measured 2 × 2 cm were present in each axilla. Both posterior triangles contained 1.5 × 1.5-cm nodes. One 1 × 1-cm lymph node was noted in the left anterior triangle of the neck. All nodes were firm, fixed, and nontender. In the femoral area, a sinus that measured 1 cm in diameter and drained purulent material, was noted at the previous biopsy site (Fig 1).

Investigation disclosed the following values: hemoglobin, 12.3 gm/100 ml; hematocrit, 38%; WBC, 10,600/cu mm, with 75% neutrophils, 20% lymphocytes, 4% monocytes, and 1% basophils; and platelets, 289,000/cu mm. The ESR was elevated at 71 mm. Results of bone marrow morphologic and iron store studies were normal. The level of γ-globulin was elevated to 2.2 mg/100 ml, with IgG increased on immunoelectrophoresis. The levels of serum bilirubin, serum alkaline phosphatase, SGOT, and BUN were normal. Results of a three-hour oral glucose tolerance test were normal. His pretreatment creatinine clearance was 120 ml/min, and results of urinalysis showed no proteinuria, casts, hematuria, or pyuria. Roentgenograms of his chest, spine, calvarium, long bones, and pelvis were normal. Radioactive pyrophosphate bone scans done in January and June 1973 were normal. Normal diurnal serum cortisol levels were obtained in February and June 1973. Cultures of sputum, bone marrow, urine, and purulent drainage failed to grow acid-fast bacteria.

In January 1973, the HC mycelial phase complement fixation titer was 1:16. The titer fell to 1:2 in June 1973. A histoplasmin skin test carried out after the serologic test in January was positive.

A second lymph node biopsy specimen was obtained in January 1973, from the right posterior cervical area. Pus surrounded the tissue at the time of surgery. A saline preparation of this material was examined microscopically. Figure 2 demonstrates the elliptical budding spores that

Fig 1.—Draining sinus from enlarged matted left femoral lymph node.

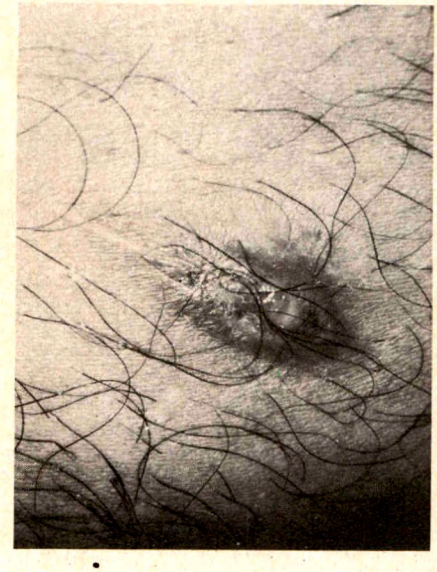

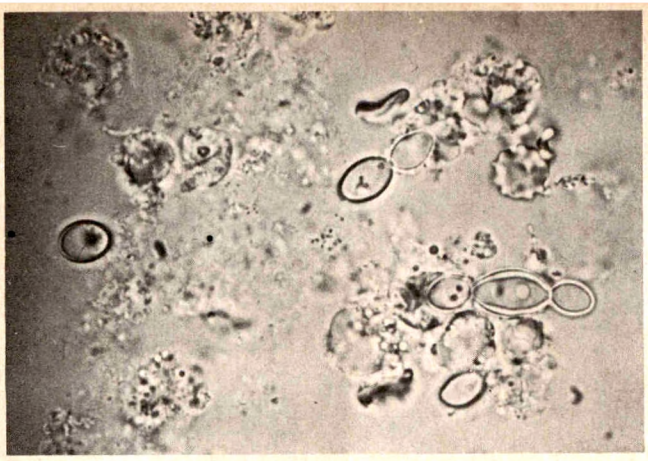

Fig 2.—Wet mount of pus from tissue around involved cervical lymph node. Note football-shaped, thick-walled yeast cell budding at one end with narrow isthmus (×400).

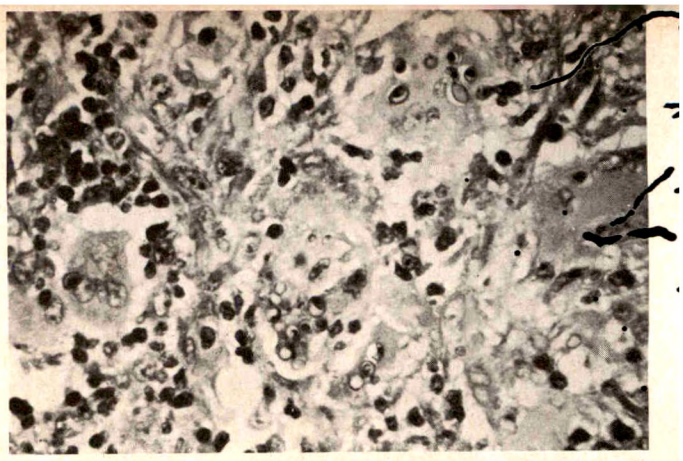

Fig 3.—Histopathologic condition of involved cervical lymph node. Infiltrate of small, round cells, histiocytes, and multinucleated giant cells filled with 8- to 15-μ long, PAS-positive yeast cells, has replaced normal nodal architecture (PAS, ×250).

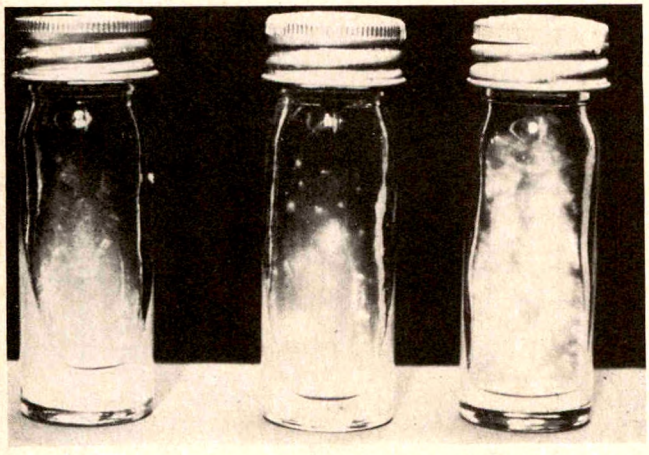

Fig 4.—Gross appearance of mycelial phase of *H duboisii* at 37 C. Amphotericin B was present in cultures at 1.1, 0.9, and 0.7 μg/ml in tubes from left to right respectively, which gave minimal inhibitory concentration of approximately 0.8 μg/ml.

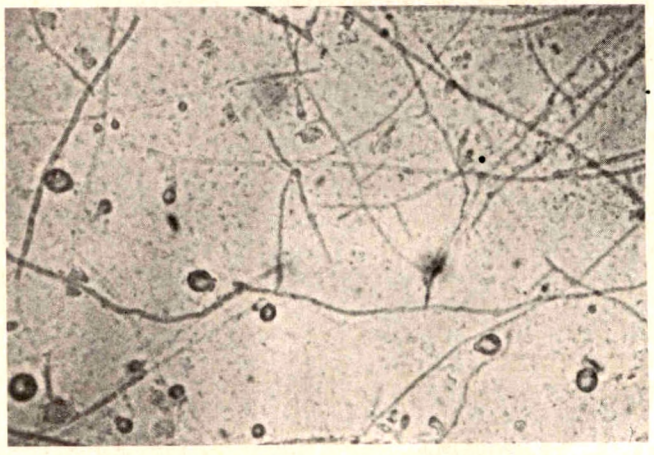

Fig 5.—Mycelial phase at 20 C of *H duboisii* illustrating septate hyphae and round microaleuriospores on conidiophores (×250).

were evident. A prominent inclusion was evident in the yeast cell cytoplasm which stained well with PAS. Organisms were seen to bud at one end with a narrow isthmus. Sometimes both ends would bud simultaneously. Double budding led to chains of organisms occasionally. The yeast cells were from 7 to 15 μ in diameter. The yeast cell wall was up to 2 μ at its thickest point, while thinner at the ends. At no time were the typical, small round yeast cells of HC seen.

Tissue from involved lymph nodes exhibited granulomatous inflammation with focal areas of suppuration. Many histiocytes and large giant cells that contained numerous yeast cells were evident (Fig 3). Only occasional yeast cells were found extracellularly. The organism stained effectively with hematoxylin-eosin, PAS, and Gridley's stains. Focal collections of neutrophils were scattered throughout the nodal tissue.

Inocula from the femoral sinus drainage, the pus obtained at the time of the previously mentioned biopsy, sputum, bone marrow, and urine, were cultured on Sabouraud's agar slants in screw-topped tubes at 20 C. After three weeks, a white, fluffy growth had developed from the first samples that were taken from the first two sites only (Fig 4). Microscopic examination of the aerial growth revealed septate-branched hyphae, round microaleuriospores on conidiophores and large tuberculate macroaleuriospores, which are typical of *H capsulatum* (Fig 5 and 6). After subculture, growth at 37 C was assessed. After prolonged growth in culture, round and ovoid yeast cells that measured 10 to 15 μ in diameter and were previously seen in tissue, were once again seen. The minimal inhibitory concentration of amphotericin B for the mycelial phase of the organism was established at approximately 0.8 μg/mg as outlined in Fig 4.

The tissue pathologic condition and biologic characteristics of the causal organism established the diagnosis. Therapy was commenced in January 1973 (Fig 7). Amphotericin B was given intravenously on alternate days. The initial dose was 5 mg; the dose was increased by 5 mg each treatment day until 50 mg was given each time. During the first weeks of treatment, the patient received 600 mg of rifampin (Rimactane) each morning, then the dose was decreased to 300 mg daily, due to dyspepsia. Figure 7 illustrates the results of the investigations, which exhibit substantial alteration. Anemia developed, but it was not severe enough to warrant transfusion. Hypokalemia was corrected easily with oral potassium supplement. Azotemia developed slowly.

In May 1973, a fluctuant, nontender, cold, erythematous tumor developed medial to the middle third of the left sternomastoid muscle (Fig 8). This lesion was incised, and thick yellow pus drained from it. A wet preparation revealed typical yeast cells but with no budding. No growth occurred when this material was cultured. In late May and early June 1973, the amphotericin B therapy was slowly stopped by lengthening the interval between treatments, due to deteriorating renal function. During this last month, the patient received 100 mg of hydrocortisone with each infusion, in addition to dimenhydrinate (50 mg) that was given intramuscularly, heparin sodium (100 IU) that was given intravenously, and secobarbital (100 mg) and amobarbital (100 mg), which were given by mouth. The addition of hydrocortisone was necessary to control the severe rigors, chills, and fever, which occurred during infusions.

In June 1973, a tender mass was noted in the left side of the groin. The left thigh

measured 2 cm more in diameter than the right. Another abscess was suspected, so the area was explored but only large, fibrotic lymph nodes were found.

After treatment was discontinued, the patient's status improved. By September 1973, the anemia had resolved, and the creatinine clearance had returned to 60 ml/min. No palpable lymph nodes could be found though some induration persisted in the left side of the groin. The middle of the left thigh was only 1 cm larger in diameter than the right. The patient has returned to full employment. Leg edema was fully resolved by December 1973. At the time of writing this communication, he has been free of evidence of disease for more than four years.

COMMENT

The causal agent in this patient differs from HC in the yeast phase.

Fig 6.—Large tuberculate macroaleuriospore present in mycelial phase culture (×400).

This parasitic form that measures 8 to 15 μ in diameter is characteristically seen in infected tissues. Although such large yeast cells may occur in necrotic tissue of HC, they are unusual.[4] The presence of such large yeast cells in fresh material from clinical lesions is quite suggestive of HD.

After prolonged in vitro growth at 37 C, the yeast cells of HC become larger. Thus, the *Histoplasma* sp has the ability to assume a "larger form" under certain conditions. The variants of HD and HC differ in their propensity to exist in this state.

Careful investigations in the past have suggested that the variant of HD constituted a new species.[3,4,9] The argument rested largely on the different yeast cell growth characteristics. Kwan-Chung[5] has proved that the two variants are sexually compatible and have the common perfect state, *Emmonsiella capsulata*. They are the same species.

Although variants of the same species, the differences in yeast cell growth as parasites results in quite different pathologic features. The disease due to HC typically exhibits pulmonary disease as a primary feature, with occasional hematogenous or lymphatic dissemination.[10] Primary extrapulmonary disease is rare, especially cutaneous lesions.[11] Granulomatous inflammation with yeast cells that measure 3 to 5 μ in diameter, largely in histiocytes, but occasionally in Langhans' giant cells or free in the tissues, is typical.[12] Suppuration is not common.

The variant of HD typically causes osseous or skin lesions.[13] Suppuration is common. Pulmonary involvement has not been reported as a primary event, though it may develop in the course of disseminated disease.[14] The granulomatous reaction contains many Langhans' giant cells that are parasitized by yeast cells that measure 8 to 15 μ in diameter and stain well with PAS and Gomori's methenamine silver stains.[15,16] The histologi features are diagnostic.

Causal Factors

To our knowledge, except for o case,[8] all those who have contract histoplasmosis due to HD have done in Central Africa.[6] Most cases h occurred in West Africa. Five case HD had been reported for each cas HC in Central Africa up to 19 *Histoplasma capsulatum* var *co latum* was often related to expo to bat-infested caves as is tru North America.[17] No relationsh environmental factors has been mined for HD. Attempts to iso from the soil of the area have unsuccessful in contrast to HC disease developed in one patien site of an insect bite, which rai possibility of an insect vector. phatic involvement, initially to the left leg, characteri patient's disease. Similar ly

Fig 7.—Treatment schedule and changes in important laboratory parameters throughout course of therapy.

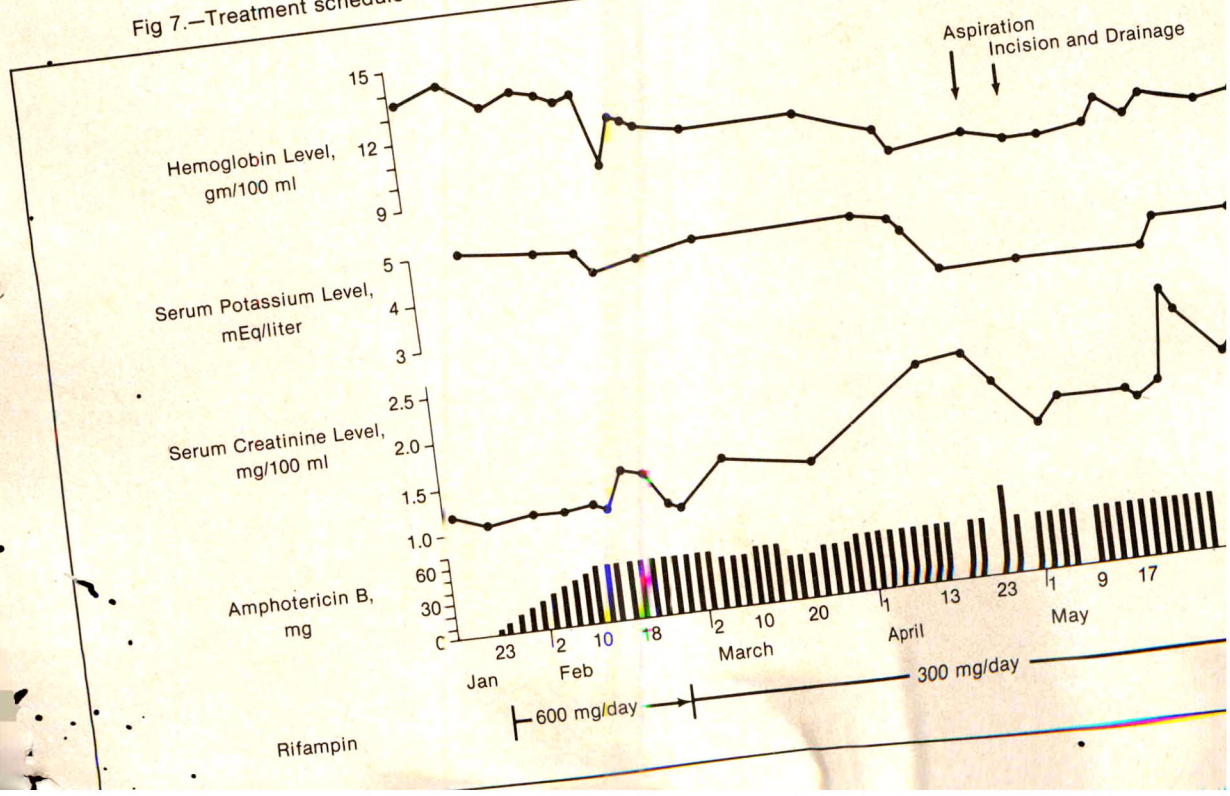

Fig 8.—Cold abscess pointing from behind midpoint of left sternomastoid muscle.

disease occurs in hamsters following intracutaneous inoculation,[20] which suggests that our patient's disease may have begun in that fashion. Baboons contract HD.[6] Our patient ate two baboons. This raises the question of the infection being contracted by ingestion of infected baboon meat. The rarity of the disease among baboons in West Africa and the initially unilateral lymphatic disease in the patient are against this possibility.

Histoplasma capsulatum var *duboisii* characteristically causes skin lesions such as superficial cutaneous granulomas, subcutaneous granulomas and abscesses, and osteomyelitic lesions with skin involvement.[21] Invasion of bone occurs commonly and involves the calvarium or long bones most frequently.[22] Rarely, vertebral osteomyelitic lesions have caused spinal cord compression.[22] Disease that is localized principally to the lymphatic system, as in our patient, is uncommon.

Histoplasma capsulatum var *capsulatum* leads to acute or chronic pulmonary disease. The clinical features of illness induced by the two variants of HC are usually distinctive. *Histoplasma capsulatum* var *duboisii* is commonly referred to as "African histoplasmosis." Although all cases of HD, except one, have been contracted in Africa, the term "African histoplasmosis" is misleading. *Histoplasma capsulatum* var *capsulatum* occurs in Africa commonly.[7,23] Clinical disease virtually identical to that of HD has been described in Nigerian children, where the causal agent proved to be HC.[24] The geographic reference in the description of disease caused by HD should be best omitted.

Drug Therapy

Amphotericin B has proven to be an effective chemotherapeutic agent in the treatment of HD.[6] Drug intoxication is a limiting factor in its use. Utz et al[25] have emphasized the need to give the lowest dose of amphotericin B appropriate to the offending organisms' in vitro sensitivity so as to decrease toxic side effects. Bindschadler and Bennett[26] followed amphotericin B blood levels for differing doses and treatment schedules. An alternate day dosage of 50 mg given intravenously should give peak blood levels of 1.5 ± 0.5 μg/ml and trough levels of 0.5 ± 0.5 μg/ml; our alternate day dosage of 50 mg was thus likely to give amphotericin B levels adequate for our patient's organism which had a minimal inhibitory concentration of 0.8 μg/ml.

The use of other drugs in combination with amphotericin B to enhance its antifungal effect and decrease toxicity has been proposed.[27] Amphotericin B and rifampin have been shown to exhibit synergism against HC in vitro[28] and in vivo.[29] Seriki et al[24] have used the two drugs together in the treatment of disseminated HD. They thought the combined therapy was beneficial, based on their clinical observations.

In view of the possible benefits of combined therapy, our patient received amphotericin B and rifampin. An in vitro growth inhibition assay of the patient's yeast by the two drugs was not performed. Without this information, no conclusions can be drawn regarding the benefit of combined therapy.

The total dose of amphotericin B (38 mg/kg), which was administered, is comparable with doses that have been previously reported to be effective in disseminated HD.[30] This observation does not give support to the suggestion that rifampin was synergistic.

The long disease-free period and the falling HC complement fixation titer suggest that the patient has been cured. Amphotericin B is once again shown to be an effective drug in the treatment of HD albeit not without substantial side effects.

W. Peter Cockshott, MD, and A.O. Lucas, MD, assisted in the management of this case.

Nonproprietary Name and Trademark of Drug

Amphotericin B—*Fungizone*.

References

1. Dubois A, Janssens P, Brutsaert P: Un cas d'histoplasmose Africaine, avec une note mycologique sur *Histoplasma duboisii* n sp par R Vanbreuseghem. *Ann Soc Belg Med Trop* 32:6, 569-584, 1952.
2. Dubois A, Vanbreuseghem R: L'histoplasmose Africaine. *Bull Acad R Med Belg* 17:551-564, 1952.
3. Vanbreuseghem R: Transmissibilite au cobaye *d'Histoplasma duboisii* a partir de la forme parasitaire humaine. *Ann Soc Belg Med Trop* 33:171-175, 1953.
4. Vanbreuseghem R: *Histoplasma* and large forms of *H capsulatum*. *M* 48:264-269, 1956.
5. Kwan-Chung KJ: Perfect state (*E siella capsulatum*) of the fungus causing form African histoplasmosis. *Mycologia* 990, 1975.
6. Cockshott W, Lucas, A: Histopla duboisii. *Q J Med* 33:223-238, 1964.
7. DeVroey C: Epidemiology of African plasmosis. *Ann Soc Belg Med Trop* 52:4 1972.
8. Swamidasan G, Kalydran R, Vanbreus em R: A case of "large forms" histoplasn from South India. *Ann Soc Belg Med Trop* 52: 458, 1972.
9. Fadulu S, Larsh H: Biochemical charact zation and skin test sensitivity of myce growth filtrate of *Histoplasma duboisii*. *Am Trop Med Hyg* 21:110-119, 1972.
10. Vanek J, Schwarz J: The gamut of hist plasmosis. *Am J Med* 50:89-96, 1971.
11. Studdard J, Sneed W, Taylor N, et a Cutaneous histoplasmosis. *Am Rev Respir Di* 113:689-693, 1976.
12. Lever W, Schaumburg-Lever G: *Histopa thology of the Skin*, ed 5. Toronto, JB Lippincott, 1975, pp 323-324.
13. Lucas A: Cutaneous manifestations of African histoplasmosis. *Br J Dermatol* 82:435-447, 1970.
14. Clarke B, Greenwood B: Pulmonary lesions in African histoplasmosis. *J Trop Med Hyg* 71:4-10, 1968.
15. Emmons C, Binford C, Utz J: *Medical Mycology*, ed 2. Philadelphia, Lea & Febiger, 1970, pp 290-291.
16. Williams A, Lawson A, Lucas A: African histoplasmosis due to *Histoplasma duboisii*. *Arch Pathol* 92:306-318, 1972.
17. Emmons CW: Association of bats with histoplasmosis. *Public Health Rep* 73:590-595, 1958.
18. Emmons CW: Isolation of *Histoplasma capsulatum* from soil in Washington, DC. *Public Health Rep* 76:591-596, 1961.
19. Delacretax J, Grigoriu D: Histoplasmose Africaine developpee sur une pique d'insecte. *Sabouraudia* 10:24-25, 1972.
20. Salfelder K, Schwarz J: Experimental cutaneous infection of hamsters with *Histoplasma duboisii*. *Mykosen* 11:273-284, 1968.
21. Lucas AO: Cutaneous manifestations of African histoplasmosis. *Br J Dermatol* 82:435-447, 1970.
22. Cockshott WP, Lucas AO: Radiologic findings in *Histoplasma duboisii* infections. *Br J Radiol* 37:653-660, 1964.
23. Doy R: Acute pulmonary histoplasmosis. *Cent Afr J Med* 20:119-123, 1974.
24. Seriki O, Aderele W, Johnson A, et al: Disseminated histoplasmosis due to *Histoplasma capsulatum* in two Nigerian children. *J Trop Med Hyg* 78:248-255, 1975.
25. Drutz D, Spickard A, Rogers D, et al: Treatment of disseminated mycotic infections—a new approach to amphotericin B therapy. *Am J Med* 45:406-418, 1968.
26. Bindschadler D, Bennett J: A pharmacologic guide to the use of amphotericin B. *J Infect Dis* 120:427-436, 1969.
27. Smith J: Synergism of amphotericin B with other antimicrobial agents. *Ann Intern Med* 78:450, 1973.
28. Koboyashi G, Medoff G, Schlessinger D, et al: Amphotericin B potentiation of rifampicin as an antifungal agent against the yeast phase of *Histoplasma capsulatum*. *Science* 177:709-710, 1972.
29. Kitahara M, Koboyashi G, Medoff G: Enhanced efficacy of amphotericin B and rifampicin combined in the treatment of murine histoplasmosis and blastomycosis. *J Infect Dis* 113:663-668, 1976.
30. Sarosi G, Voth D, Bernhoff A, et al: Disseminated histoplasmosis: Results of long-term follow-up. *Ann Intern Med* 75:511-[illegible] 1971.

Dermatofibrosarcoma Protuberans With Lymph Node and Pulmonary Metastases

Leonard B. Kahn, MBBCh, MMed, MRCPath; Norma Saxe, MBChB, FFDerm (SA); Walter Gordon, MD, FRCP (Edin)

• Dermatofibrosarcoma protuberans is a locally aggressive histiocytic tumor that, on rare occasions, may metastasize to regional lymph nodes or even to distant sites. We report a dermatofibrosarcoma protuberans with lymph node involvement in a 27-year-old woman. The tumor recurred repeatedly after local excisions, and ten years after the first resection, widespread pulmonary metastases developed in the patient and she died four years later. More than 400 patients with dermatofibrosarcoma protuberans have been reported in the literature; including the present case, five of these patients had lymph node metastases, 17 patients had hematogenous spread, and three had both lymphatic and blood-borne metastases.

(*Arch Dermatol* 114:599-601, 1978)

Dermatofibrosarcoma protuberans (DFSP) is a rare, locally aggressive, histiocytic tumor that originates in the dermis. The majority of the cells resemble fibroblasts and are considered to be facultative fibroblasts. The tumor has a distinctive clinical appearance, and is composed usually of multiple purplish, protruding and coalescing nodules with attenuation of the overlying epidermis. Infrequently, ulceration of the overlying skin occurs. The trunk is the most frequent location of this tumor, but it may occur anywhere in the skin.[1] Characteristically, DFSP shows a tendency to recur locally after excision, but distant hematogenous spread is rare and lymphatic spread even more rare. In a review of the literature, Brenner et al[2] found 17 patients with hematogenous spread and six patients with spread to lymph nodes, and these authors reported a seventh patient with regional node metastases.

We report a patient with DFSP that metastasized to cervical and axillary nodes and that showed radiological evidence of pulmonary metastases. The development of both lymphatic and hematogenous metastases has been documented only twice previously.

REPORT OF A CASE

In 1960, a 27-year-old woman had a small, reddish tumor that had been growing slowly for three years on the posterior aspect of her right shoulder. She refused surgery but returned a few months later, in 1961, and by this time, the tumor had enlarged considerably and bled occasionally. The tumor was dome-shaped, reddish-blue, multinodular, and measured 7 × 5 cm. She also had enlarged lymph nodes in the right axillary and cervical regions.

The tumor was excised, and a split skin graft was applied. A pathological diagnosis of DFSP was made. In addition, a small, 1-cm, pigmented nodule was removed from the right upper arm and, histologically, this nodule showed features of a dermatofibroma. A biopsy was performed on a lymph node in the right cervical area, and the specimen was shown to be infiltrated by the DFSP. The patient refused block dissection of these nodes. Multiple recurrences at the same site, as well as around the edges of the skin graft necessitated further surgery in 1966, 1968, and 1970 (Fig 1). Episodes of bleeding from these sites were treated with blood transfusions. A chest roentgenogram taken in 1968 was unremarkable, but multiple rounded opacities were noted in both lung fields in 1970 (Fig 2).

In 1974, extensive tumor recurrence was associated with gross lymphedema of the right forequarter. There was diffuse nodular induration over the shoulder. The pulmonary metastases had not changed notably over the four-year period. The tumor was considered irresectable, and the patient died 16 years after the first appearance of the tumor.

PATHOLOGICAL FEATURES OF THE TUMOR

The pathological features of the tumor were identical in the multiple excisions. Macroscopically, the tumor mass was composed of multiple, coalescing nodules. These were located predominantly in the dermis but extended into the subcutis and even into skeletal muscle. The tumor was composed predominantly of spindle-shaped cells arranged in a storiform pattern (Fig 3). In addition to the spindle-shaped cells, lipid-laden foam cells, hemosiderin-laden macrophages, and Touton-type giant cells were present focally in the lesion (Fig 4). Mitoses were present in moderate numbers, and there was a mild degree of cellular atypism. The tumor had infiltrating margins, and the overlying epidermis was atrophic and even ulcerated in areas. Sections from the lymph nodes that were biopsied in 1961 showed partial replacement by tumor, with features identical to those described (Fig 5, left and right). The tumor was present in both a subcapsular location (Fig 5, left) and in sinuses within the depths of the node (Fig 5, right).

Accepted for publication Aug 24, 1977.

From the Departments of Pathology and Dermatology, University of Cape Town Medical School and Groote Schuur Hospital, Cape Town, South Africa.

Dr. Kahn is now with the Department of Pathology, Univeristy of North Carolina School of Medicine, Chapel Hill.

Reprint requests to Department of Pathology, University of North Carolina School of Medicine, Chapel Hill, NC 27514 (Dr Kahn).

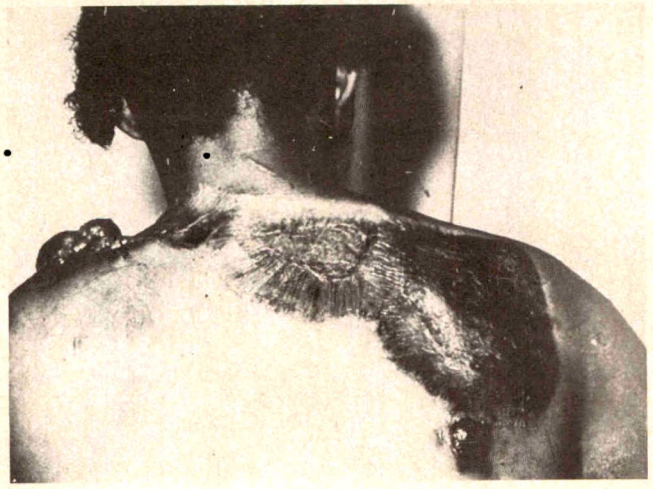

Fig 1.—Recurrent nodules of dermatofibrosarcoma protuberans at margins of skin graft.

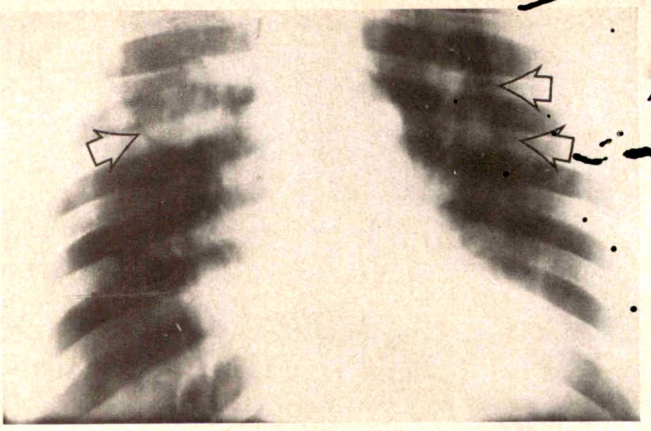

Fig 2.—Chest tomogram showing multiple secondary tumor deposits (arrows).

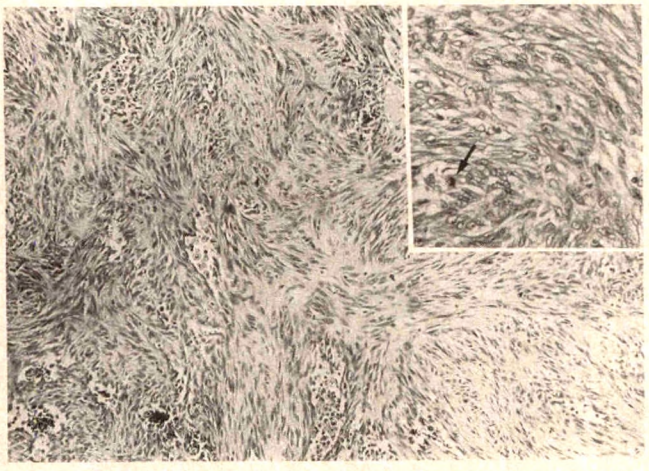

Fig 3.—Spindle-shaped cells of dermatofibrosarcoma protuberans growing in typical storiform pattern. Inset, detail of cells with occasional mitoses (arrow). (Hematoxylin-eosin, ×125; inset, ×320.)

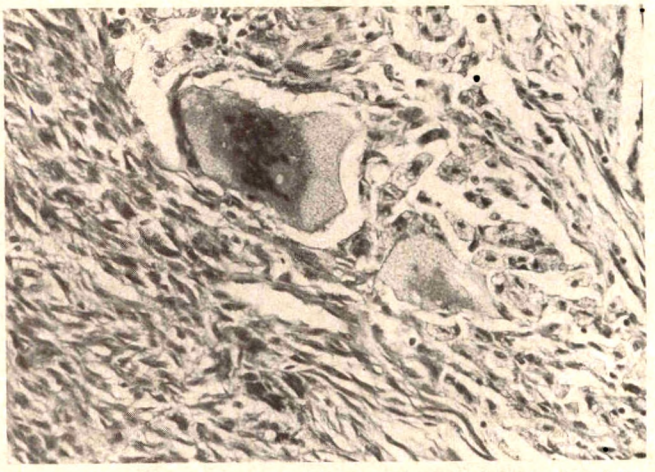

Fig 4.—Focal area containing Touton-type giant cells and lipid-laden histiocytes within tumor (hematoxylin-eosin, ×320).

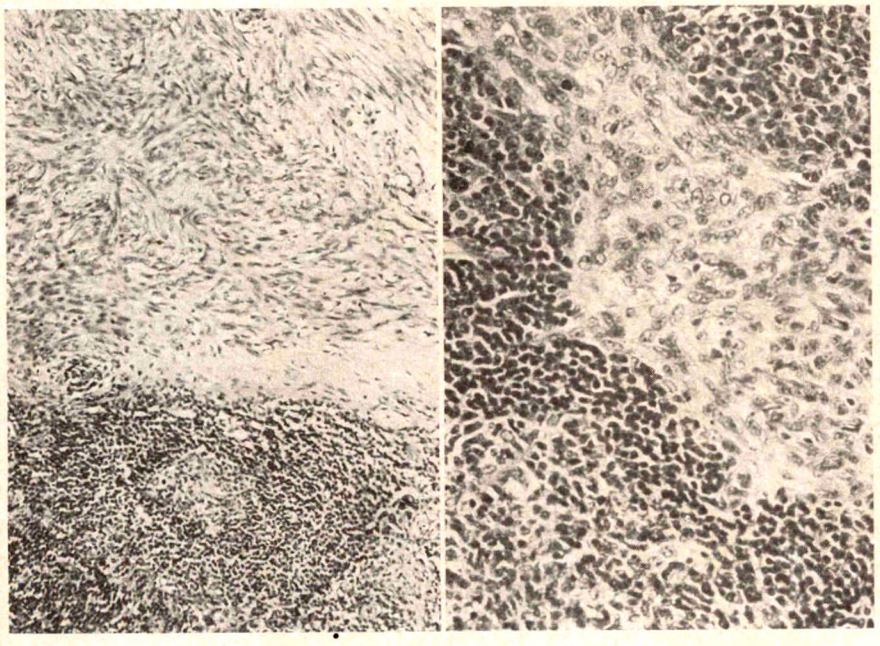

Fig 5.—Left, Metastatic dermatofibrosarcoma protuberans (DFSP) in subcapsular location within lymph node; appearance is identical to primary lesion (hematoxylin-eosin, ×125). Right, Metastatic DFSP within more deeply placed sinus in lymph node. Germinal center is seen in left lower corner (hematoxylin-eosin, ×320).

COMMENT

Dermatofibrosarcoma protuberans was described as a clinicopathological entity by Darier and Ferrand[3] and given the name DFSP by Hoffman.[4] Dermatofibrosarcoma protuberans frequently recurs following local resection owing to incomplete removal of its finger-like extensions. To establish the correct diagnosis at the outset and to perform a wide and deep local excision of the lesion is important.

Histological Differentiation

Histologically, the tumor must be differentiated from a dermatofibroma, which is smaller, is a single nodule, shows a lack of infiltration of subcutis, and shows a paucity or an absence of both mitoses and anaplasia; from a storiform neurofibroma, which is a single nodule, has melanin in some of the cells, and shows an absence of both mitoses and anaplasia; from an atypical fibroxanthoma, which shows a lack of storiform pattern, exhibits greater cellular anaplasia and mitotic activity (including abnormal forms), and has greater polymorphism of cell type; and from a soft-tissue, malignant fibrous histiocytoma, which has greater cellular anaplasia, including multinucleate giant cells, and is located in subcutaneous or deeper tissue. In this regard, O'Brien and Stout[5] consider the DFSP as belonging to the broader group of tumors that they themselves have termed malignant fibrous xanthomas.

Tumor Recurrence

Taylor and Helwig[6] documented recurrence in 48 of 98 patients (49%) with DFSP who had been followed for ten months to 17 years; 20 of these patients had more than one recurrence. In 18 of the 48 patients the first recurrence occurred within one year. McPeak et al[7] reported recurrence in 45 of 82 such patients (55%) who had been followed from three to 15 years. Approximately 80% of the recurrent tumors developed within three years of resection. Pack and Tabah[8] reported recurrences in eight of 39 patients (20.5%) with a six- to 19-year follow-up. Burkhardt et al[9] noted recurrences in 31 of 56 patients (55.4%) seen at the Mayo Clinic during a 50-year period.

Histologically, no differences have been found between the recurring and nonrecurring lesions, and the recurrences are usually identical in appearance to the primary lesions. To determine the biologic behavior of tumors of histiocytic origin, including the DFSP, from their histological features is difficult.[5] However, McPeak et al[7] did note a higher mitotic rate (more than 8 mitoses per ten high-power fields) in three of five of the metastasizing lesions of their patients, as compared with the rate for the nonmetastasizing lesions (zero to four mitoses per ten high-power fields).

Our patient demonstrated a rare occurrence of both biopsy-proved nodal metastasis and radiological pulmonary metastases. Despite these metastases, she remained generally well and was able to carry on normal daily activities until shortly before her death.

Lymph Node Involvement

Of more than 400 cases of DFSP documented in the literature, only seven examples of lymphatic spread to regional nodes have been reported.[2,10-14] In view of this low frequency, prophylactic node dissection is not indicated. Patients should be carefully followed up not only because of the propensity to local recurrence, but also because of the possibility of lymphatic and hematogenous spread. The histological appearance of the nodal metastases in our patient, as well as in one of the patients described by Przybora and Wojnerowicz,[13] and in one patient reported by Woolridge,[14] and one patient reported by Brenner et al,[2] was identical to those of the primary tumor. The nodal metastasis in the patient reported by Fisher and Hellstrom[10] resembled a malignant lymphoma, but there were similar foci in the primary tumor; in the other patient of Przybora and Wojnerowicz,[13] the nodal metastases resembled an ordinary fibrosarcoma. In the remaining two cases[11,12] we were unable to determine the histological appearance of the nodal metastases.

Brenner et al[2] traced 17 patients with hematogenous metastases, not all of which were histologically proved. An additional two examples, together with the present case, bring the number of cases with hematogenous spread to 20.[5,14] We were unable to determine the histological appearance of these metastases in 14 patients, either because the lesions had not been biopsied or because the information was not readily available. In four patients, the hematogenous metastases resembled the primary tumor;[7,15] in one patient, the metastases resembled a reticulum cell lymphoma[10] and in another patient the metastases resembled fibrosarcoma.[5] Only three cases, including the present one, have demonstrated both regional node metastases and radiological evidence of pulmonary metastases. This combination of hematogenous and lymphatic spread is distinctly unusual.

References

1. Sauter LS, DeFeo CP: Dermatofibrosarcoma protuberans of the face. *Arch Dermatol* 104:671-674, 1971.
2. Brenner W, Schaefler K, Chhabra H, et al: Dermatofibrosarcoma protuberans metastatic to a regional lymph node. *Cancer* 36:1897-1902, 1975.
3. Darier J, Ferrand M: Dermatofibrosarcoma progressifs et récidivants ou fibrosarcomes de la peau. *Ann Derm Syph* 6:545-570, 1924.
4. Hoffman E: Uber des Knollentreibende Fibrosarkom der Haut (Dermatofibrosarcoma protuberans). *Derm Z* 43:1-28, 1925.
5. O'Brien JE, Stout AP: Malignant fibrous xanthomas. *Cancer* 17:1445-1455, 1964.
6. Taylor HB, Helwig EB: Dermatofibrosarcoma protuberans: A study of 115 cases. *Cancer* 15:717-725, 1962.
7. McPeak CJ, Druz T, Nicastri AD: Dermatofibrosarcoma protuberans: An analysis of 86 cases—five with metastasis. *Ann Surg* 166:803-816, 1967.
8. Pack GT, Tabah EJ: Dermatofibrosarcoma protuberans. *Arch Surg* 62:391-411, 1951.
9. Burkhardt BR, Soule EH, Winkelmann RK, et al: Dermatofibrosarcoma protuberans: Study of 56 cases. *Am J Surg* 111:638-644, 1966.
10. Fisher ER, Hellstrom HR: Dermatofibrosarcoma with metastases simulating Hodgkin's disease and reticulum cell sarcoma. *Cancer* 19:1165-1171, 1966.
11. Gentele H: Malignant fibroblastic tumors of skin: Clinical and pathological-anatomical studies of 129 cases of malignant fibroblastic tumors from cutaneous and subcutaneous layers observed at Radiumhemmet during period 1927-1947. *Acta Derm Venereol* 27(suppl):1-80, 1951.
12. Levi I: Sopra un caso di fibrosarcoma primitivo della cute del Pene. *G Ital Dermatol Sifilol* 71:1559-1574, 1930.
13. Przybora LA, Wojnerowicz C: Malignancy of dermatofibrosarcoma protuberans and report of 2 cases with lymph gland metastases. *Oncologia* 12:236-254, 1959.
14. Woolridge WE: Dermatofibrosarcoma protuberans: Tumor too lightly considered. *Arch Dermatol* 75:132-134, 1957.
15. Penner DW: Metastasizing dermatofibrosarcoma protuberans. *Cancer* 4:1083-1086, 1951.

Nasopharyngeal Carcinoma Associated With Long-Term Arsenic Ingestion

Stephen D. Prystowsky, MD; Gerald J. Elfenbein, MD; Stanford I. Lamberg, MD

• A nasopharyngeal carcinoma occurred in a 41-year-old white woman who had received Fowler's solution (potassium arsenite) almost yearly for more than 20 years for the treatment of psoriasis. Palmar and plantar keratoses were present. Because of the rarity of this malignant neoplasm in white people, a relationship with arsenic ingestion is suggested.

(*Arch Dermatol* 114:602-603, 1978)

Skin cancer that results from long-term arsenic ingestion is well known.[1-5] Cases of visceral cancer secondary to arsenic are uncommon.[1,2,5-11] Definite evidence that arsenic is the direct cause of visceral cancer is difficult to establish, since there is usually a long, latent period between exposure and malignancy.[1,2,8] The purpose of this communication is to report a nasopharyngeal epithelioma, an uncommon epithelial tumor,[12] that may have been related to long-term arsenic ingestion.

REPORT OF A CASE

A 41-year-old white woman was admitted to a hospital in June 1974, for evaluation and treatment of metastatic nasopharyngeal carcinoma. She had psoriasis for 35 years, which was treated with Fowler's solution (potassium arsenite) for at least 20 years.

The present illness began in October 1973, with a painful mass on her neck. In November 1973, a biopsy specimen of the mass was interpreted as metastatic nasopharyngeal carcinoma. The primary symptom was found in the lateral wall of the right side of the nasopharynx. No evidence for distant metastasis could be detected by roentgenograms and isotope scans. The patient's condition was treated with 6,200 rads to the nasopharynx and both sides of the neck. In March 1974, pain, proptosis, increased lacrimation, and loss of visual acuity in the right eye developed in the patient. Biopsy specimen of the lacrimal gland revealed metastatic nasopharyngeal carcinoma. Visual acuity improved after 5,000 rads to the orbit of the right eye.

In May 1974, dysphagia, orthopnea, and paroxysmal nocturnal dyspnea developed in the patient, and again, she was admitted to the hospital. Pertinent physical findings included decreased visual acuity and conjunctival edema of the right eye, edema and induration of the face and neck, and bilateral enlargement of the cervical and axillary lymph nodes. Numerous, well-demarcated papulosquamous plaques, which are typical of psoriasis, were present on the face, scalp, elbows, and trunk. Yellow, keratotic, 2- to 4-mm lesions were

Multiple, hard keratotic lesions studding soles; these were also present on palms.

Accepted for publication Sept 6, 1977.

From the Department of Dermatology, Baltimore City Hospitals, (Drs Prystowsky and Lamberg), and the Department of Medicine, The Oncology Center, The Johns Hopkins Hospital (Dr Elfenbein), Baltimore. Dr Prystowsky is now at The Letterman Army Institute of Research, San Francisco. Dr Elfenbein is an investigator of the Howard Hughes Medical Institute.

Reprint requests to Baltimore City Hospitals, 4940 Eastern Ave, Baltimore, MD 21224 (Dr Lamberg).

present on the palms and soles (Figure). Positive laboratory data included a serum antibody titer of 1:400 to Epstein-Barr's virus. Large paratracheal and bilateral hilar adenopathy was seen on chest roentgenogram, and a roentgenogram of soft tissue showed a large retropharyngeal swelling.

On day 1, cyclophosphamide (60 mg/kg) was given as an intravenous (IV) bolus; on days 9 to 11, cyclophosphamide (20 mg/kg/24 hr) was given as an IV infusion; and on day 15, cyclophosphamide (60 mg/kg/24 hr) was given as an IV infusion. Complications during therapy included prolonged bone marrow aplasia, facial and cervical cellulitis, and monilial esophagitis. The patient recovered, and the repeated chest roentgenogram revealed disappearance of the paratracheal and hilar nodes. The patient was discharged and received a monthly regimen of IV cyclophosphamide (30 mg/kg) for one year and then a bimonthly regimen of cyclophosphamide (30 mg/kg) for 12 months. The patient is in an unmaintained, complete clinical remission now—more than 32 months postinduction.

COMMENT

Nasopharyngeal cancer is frequent in south China, certain other parts of Asia and in north Africa but is uncommon in white people.[12,13] In white populations, this cancer usually comprises 0.25% to 0.50% of all malignant tumors.[14] In the regions of the world with high incidence, nasopharyngeal carcinoma has been clearly shown to be related to Epstein-Barr's virus both by viral titers and by DNA molecular hybridization studies.[15-17] In the regions of the world with nonendemic nasopharyngeal epithelioma, this relationship is less clear.[15-18] The mechanism, whereby Epstein-Barr's virus is related to nasopharyngeal cancer, is still a subject for discussion.[19-20] There is also an apparent genetic predisposition to nasopharyngeal carcinoma in areas with endemic disease, with certain HLA antigens that predominate in the population at risk as compared with control populations.[21-22] In the sporadic cases in nonendemic areas, the genetic predisposition has not been studied.

Cutaneous epithelial carcinomas that result from long-term arsenic ingestion have been previously established.[1-8] Certain rare visceral tumors, such as hemangioendothelial sarcoma of the liver[6,9,11] appear to be associated with arsenic. Psoriasis is not associated with nasopharyngeal carcinoma, though one reported case that was treated with methotrexate for psoriasis developed this uncommon malignant neoplasm.[23]

This report of a sporadic case of nasopharyngeal carcinoma is associated with long-term arsenic ingestion and demonstrated arsenical keratoses. Epstein-Barr's virus titer in this patient is at the geometric mean of those patients with nasopharyngeal carcinoma from China and Africa but high for those cases of sporadic nasopharyngeal cancer. Although we cannot exclude the role of Epstein-Barr's virus in this patient's malignancy, we suggest that nasopharyngeal epithelioma, like the hemangioendothelial sarcoma of the liver, may be associated with long-term arsenic ingestion in selected patients who are not genetically predisposed or residing in endemic regions of the world. Furthermore, long-term arsenic ingestion may be additive or synergetic with other causal factors in oncogenesis. Additional factors suggested as possible causes of nasopharyngeal carcinoma include viruses, tuberculosis, syphilis, tobacco, opium, heroin, and incense.[24]

References

1. Neubauer O: Arsenical cancer: A review. *Br J Cancer* 1:192-251, 1947.
2. Sommers SC, McManus RG: Multiple arsenical cancers of skin and internal organs. *Cancer* 6:347-359, 1953.
3. Fierz VU: Katamnestische Untersuchungen über die Nebenwirkungen der Therapie mit anorganischem Arsen bei Hautkrankheiten. *Dermatologica* 131:41-58, 1965.
4. Yeh S: Skin cancer in chronic arsenicism. *Hum Pathol* 4:469-485, 1973.
5. Yeh S, How SW, Lin CS: Arsenical cancer of skin—histologic study with special reference to Bowen's disease. *Cancer* 21:312-339, 1968.
6. Regelson W, Kim U, Ospina J, et al: Hemangioendothelial sarcoma of liver from chronic arsenic intoxication by Fowler's solution. *Cancer* 21:514-522, 1963.
7. Minkowitz S: Multiple carcinomata following ingestion of medicinal arsenic. *Ann Intern Med* 61:296-299, 1964.
8. Robson AO: Medicinal arsenic poisoning and lung cancer. *Br Med J* 2:207-209, 1963.
9. Roth F: Cancer in vineyard secondary to arsenic. *Zentralbl Allg Pathol* 100:529-530, 1959.
10. Lee AM, Fraumeni JF: Arsenic and respiratory cancer in man: An occupational study. *J Natl Cancer Inst* 42:1045, 1969.
11. Rosset M: Arsenical keratoses associated with carcinomas of the internal organs. *Can Med Assoc J* 78:416-419, 1958.
12. Shedd DP: Nasopharyngeal carcinoma, in Holland JF, Frei E (eds): *Cancer Medicine*. Philadelphia, Lea & Febiger, 1973.
13. Bailar JC: Nasopharyngeal cancer in white populations—a worldwide survey in, Muir CS, Shanmugaratnam K (eds): *Cancer of the Nasopharynx*. Flushing, NY, Medical Examination Publishing Co Inc, 1967, pp 18-23.
14. Batsakis JG (ed): Carcinomas of the nasopharynx, in *Tumors of the Head and Neck*. Baltimore, Williams & Wilkins Co, 1974, p 128.
15. Henle W, Henle G, Ito HC, et al: Antibodies to Epstein-Barr virus in nasopharyngeal carcinoma, other head and neck neoplasms and control groups. *J Natl Cancer Inst* 44:225-231, 1970.
16. Wolf H, Zur Hausen H, Becker W: EB viral genomes in epithelial nasopharyngeal carcinoma cells. *Nature New Biol* 244:245-247, 1973.
17. Wolf H, Zur Hausen H, Klein G, et al: Attempts to detect virus-specific DNA sequences in human tumors: III. Epstein-Barr viral DNA in non-lymphoid nasopharyngeal carcinoma cells. *Med Microbiol Immunol* 161:15-21, 1975.
18. de Schryver A, Klein G, Henle W, et al: EB virus-associated antibodies in Caucasian patients with carcinoma of the nasopharynx and in long-term survivors after treatment. *Int J Cancer* 13:319-325, 1974.
19. Zur Hausen H: Biochemical approaches to detection of Epstein-Barr virus in human tumors. *Cancer Res* 36:678-680, 1976.
20. Ziegler JL, Magrath IP, Gerber P, et al: Epstein-Barr virus and human malignancy. *Ann Intern Med* 86:323-336, 1977.
21. Simons MT, Day NE, Wee GB, et al: Nasopharyngeal carcinoma: V. Immunogenetic studies of southeast Asian ethnic groups with high and low risk for the tumor. *Cancer Res* 34:1192-1195, 1974.
22. Simons MJ, Wee GB, Day NE, et al: Immunogenetic aspects of nasopharyngeal carcinoma: I. Differences in HLA antigen profiles between patients and control groups. *Int J Cancer* 13:122-134, 1974.
23. Craig SR, Rosenberg EW: Methotrexate-induced carcinoma? *Arch Dermatol* 103:505-506, 1971.
24. Toomey JM: Cysts and tumors of the pharynx, in Paparella MM, Shumrick DA (eds): *Otolaryngology: Head and Neck*, vol 3. Philadelphia, WB Saunders Co, 1973, p 345.

SOLBAR®

Shuns UVB and UVA –

SOLBAR®

Contains Water Insoluble Benzophenones.

Aids in Preventing Wrinkling, Freckling and Drying due to overexposure to the sun.

PERSŌN & COVEY INC.
GLENDALE, CALIF. 91201

P. acnes comes out in the Wash

A recent research study showed Desquam-X® Wash (4% BENZOYL PEROXIDE) can reduce P. acnes 87.7% in 1 day*

Purpose of the *in vivo* study was to generate data showing the reduction of anaerobic facial bacteria (P. acnes).

Desquam-X Wash was applied b.i.d. No other acne therapy was administered.

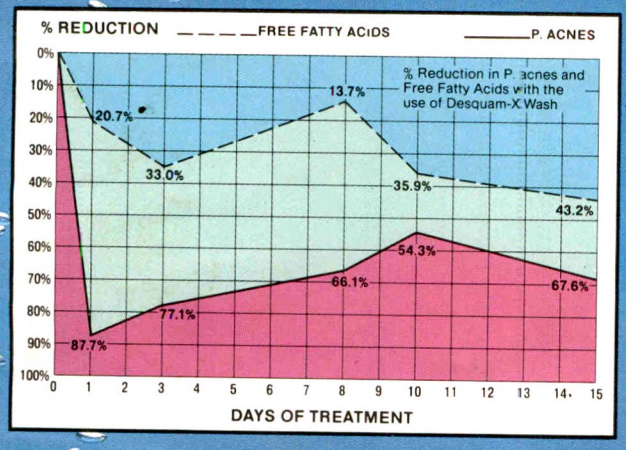

The first benzoyl peroxide cleanser, available only on your Rx.

Desquam-X® Wash (4% Benzoyl Peroxide) THERAPEUTIC CLEANSER

NDC 0072-6900-05

CONTENTS: DESQUAM-X® WASH contains 4% benzoyl peroxide, sodium octoxynol-3-sulfonate, water, sodium dioctyl sulfo-succinate, sodium lauryl sulfoacetate, magnesium aluminum silicate, methocel A4M, EDTA.

INDICATIONS: May be used topically alone for mild to moderate acne vulgaris. In severe, complicated acne Desquam-X Wash may be used as an adjunct to therapeutic regimens which might include antibiotics, retinoic acid products, and/or sulfur and salicylic acid containing preparations.

ACTION: Provides drying and desquamation desirable in the topical treatment of acne. Desquam-X Wash has demonstrated antibacterial activity against Propionibacterium acnes. Desquam-X Wash has also been shown to reduce the concentration of free fatty acids in the sebum.

DIRECTIONS FOR USE: Wash vigorously with Desquam-X Wash once or twice daily, avoiding contact with eyes or mucous membranes. Drying and peeling may be modified by adjusting the dosage schedule.

CONTRAINDICATIONS: Not to be used in patients known to be sensitive to benzoyl peroxide or other ingredients.

PRECAUTIONS: Avoid contact with eyes and mucous membranes. To prevent bleaching, avoid contact with hair. Keep this and all drugs out of the reach of children. For external use only.

NOTE: May bleach colored fabrics. Store below 77°F.

HOW SUPPLIED: Plastic bottles 5 oz. (141.8 g.)

CAUTION: Federal law prohibits dispensing without a prescription.

*Data on file, Westwood Pharmaceuticals.

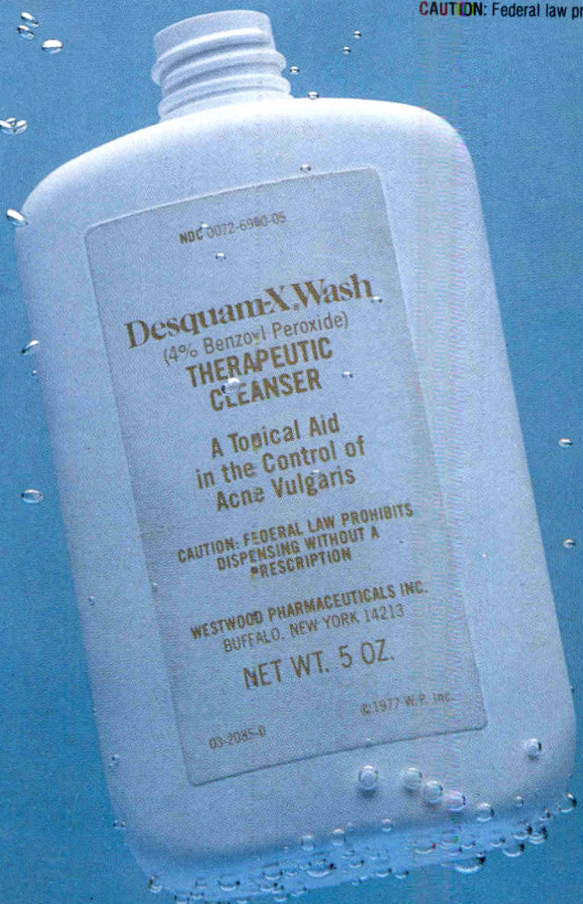

WESTWOOD
PHARMACEUTICALS INC.
Buffalo, New York 14213

©1978, W.P. Inc.

New Desquam-X®

(5 OR 10% BENZOYL PEROXIDE, 6% LAURETH-4)

water base gel is not watered down.

Clinically as effective as the alcohol formulation and even more cosmetically acceptable than before.

One study shows Desquam-X10®
(10% BENZOYL PEROXIDE, 6% LAURETH-4)
reduced P. acnes 99.9% in 3 days*

Purpose* of the *in vivo* study was to generate data showing the reduction of anaerobic facial bacteria (P. acnes).

Desquam-X 10 was applied b.i.d. No other acne therapy was administered.

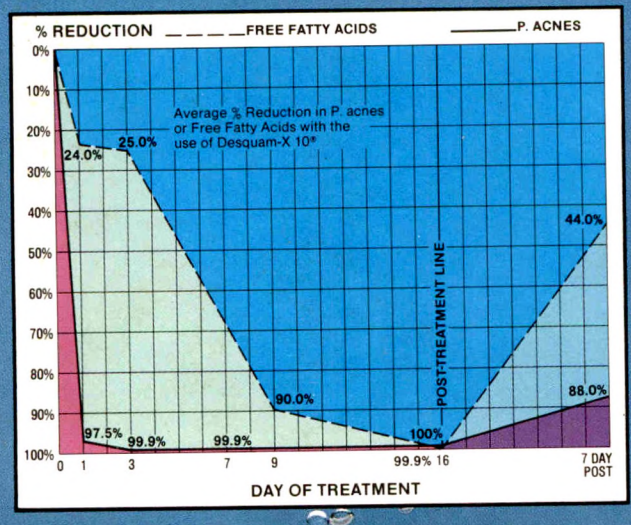

- **Large new 3 oz. tube for patient economy and convenience**
- **Eliminates alcohol sting**

Desquam-X5®	Desquam-X10®
NDC 0072—6621-01—1.5 oz.	NDC 0072—6721-01—1.5 oz.
NDC 0072—6621-03—3 oz.	NDC 0072—6721-03—3 oz.

CONTENTS: Desquam-X5 contains 5% Benzoyl Peroxide, 6% laureth-4, carbomer 940, di-isopropanolamine, disodium edetate and water.

Desquam-X10 contains 10% Benzoyl Peroxide, 6% laureth-4, carbomer 940, di-isopropanolamine, disodium edetate and water.

INDICATIONS: May be used topically alone for mild to moderate acne vulgaris and as an adjunct in therapeutic regimens for severe, complicated acne which might include systemic antibiotics, retinoic acid products and/or sulfur and salicylic acid containing preparations.

ACTION: Provides the desirable drying and desquamation needed in the topical treatment of acne. Desquam-X has been demonstrated to have anti-bacterial effects, especially against Propionbacterium acnes.

DIRECTIONS FOR USE: After washing as instructed, rub Desquam-X into affected areas twice daily. In fair skinned individuals or under excessively dry atmospheric conditions it is suggested that therapy be initiated with one application daily.

The desired degree of drying and peeling can be obtained by modification of the dosage schedule.

CONTRAINDICATIONS: Not to be used in patients known to be sensitive to any ingredient of Desquam-X.

PRECAUTIONS: Avoid contact with eyes and mucous membranes. For external use only. Keep this and all drugs out of the reach of children.

Store below 75°F.

NOTE: May bleach colored fabrics.

HOW SUPPLIED: Plastic tubes 1.5 oz. (42.5g); 3 oz. (85 g).

CAUTION: Federal law prohibits dispensing without prescription.

*Data on file, Westwood Pharmaceuticals.



WESTWOOD
PHARMACEUTICALS INC.
Buffalo, New York 14213

©1978, W.P. Inc.

Whenever epidermabrasion is needed...

Many skin conditions can benefit from epidermabrasion—the controlled removal of the stratum disjunctum and other keratin excrescences of the stratum corneum. BUF-PUF offers a pleasant, easy-to-use method for patients to achieve thorough cleansing and smoother, healthier skin from head to toe.

Acne
BUF-PUF loosens comedones while it cleans and helps remove excess oil.

Psoriasis
Used wet or dry, BUF-PUF debrides scales from psoriatic lesions without manifesting a Koebner reaction.

Hyperkeratosis
Rapid, often dramatic results can be seen when BUF-PUF is used to remove the upper layers of toughened or scaly skin.

Keratosis pilaris
BUF-PUF is particularly helpful here because its abrasive action concentrates on the elevated areas of the skin surface.

Tinea versicolor
The gently abrasive action of BUF-PUF helps remove the scales, allowing better penetration of topical therapeutic agents.

BUF-PUF®
Nonmedicated Cleansing Sponge

Riker Laboratories, Inc. SUBSIDIARY OF 3M COMPANY
NORTHRIDGE, CALIFORNIA 91324
©1978, Riker Laboratories, Inc.



anywhere on potency without fluorination

The potency of Tridesilon—*nonfluorinated* antiinflammatory topical corticoid—has again been confirmed. In a recently published clinical study,[1] desonide 0.05% was compared with fluocinonide (in identical concentration) for various dermatologic disorders including contact dermatitis, nummular eczema, lichen simplex chronicus, seborrheic dermatitis, and atopic eczema.

The desonide group showed better improvement scores in erythema and scaling after the first week; the two-week scores were not significantly different. "...desonide demonstrated potency and efficacy equivalent to those of the fluorinated compound in the disorders treated, and no adverse effects were noted with the former."[1]

This is added corroboration that with topical steroids potency and efficacy do not always depend on fluorination. Desonide, though nonfluorinated, has shown clinical comparability with the most widely prescribed fluorinated topical steroids.[2]

*Not for ophthalmic use.

References: 1. Barsky S: Clinical comparison of desonide cream with fluocinonide cream in steroid-responsive dermatologic disorders. *Cutis* 18:826, 1976. **2.** Reprints available on request.

Contraindications: Tridesilon (desonide) 0.05% Creme and Ointment, topical steroids, are contraindicated in vaccinia and varicella, and in those patients with a history of hypersensitivity to any of the components of the preparation.
Precautions: If irritation develops, the drug should be discontinued and appropriate therapy instituted.
In the presence of an infection, the use of an appropriate antifungal or antibacterial agent should be instituted. If a favorable response does not occur promptly, the corticosteroid should be discontinued until the infection has been adequately controlled.
If extensive areas are treated or if the occlusive technique is used, the possibility exists of increased systemic absorption of the corticosteroid and suitable precautions should be taken.
Although topical steroids have not been reported to have an adverse effect on pregnancy, the safety of their uses in pregnant females has not absolutely been established. Therefore, they should not be used extensively on pregnant patients, in large amounts, or for prolonged periods of time.
These products are not for ophthalmic use.
Adverse Reactions: The following local adverse reactions have been reported with topical corticosteroids: burning sensations, itching, irritation, dryness, folliculitis, hypertrichosis, acneform eruptions, hypopigmentation.
The following may occur more frequently with occlusive dressings than without such therapy: maceration of the skin, secondary infection, skin atrophy, striae, miliaria.
Dosage and Administration: Apply a thin film of Tridesilon (desonide) to the affected skin and massage lightly. The usual dosage is two or three times daily.
Depot Stocked: *DPSC:* 15 gm: NSN 6505-00-148-6969; 60 gm: NSN 6505-00-148-6968; 5 lb: NSN 6505-01-004-9217. *VA:* 60 gm: SN 6505-00-136266A; 5 lb: SN 6505-01-012-4486A.



Tridesilon®
(desonide) 0.05% creme and ointment

adjunctive therapy in acute and chronic steroid-responsive dermatoses

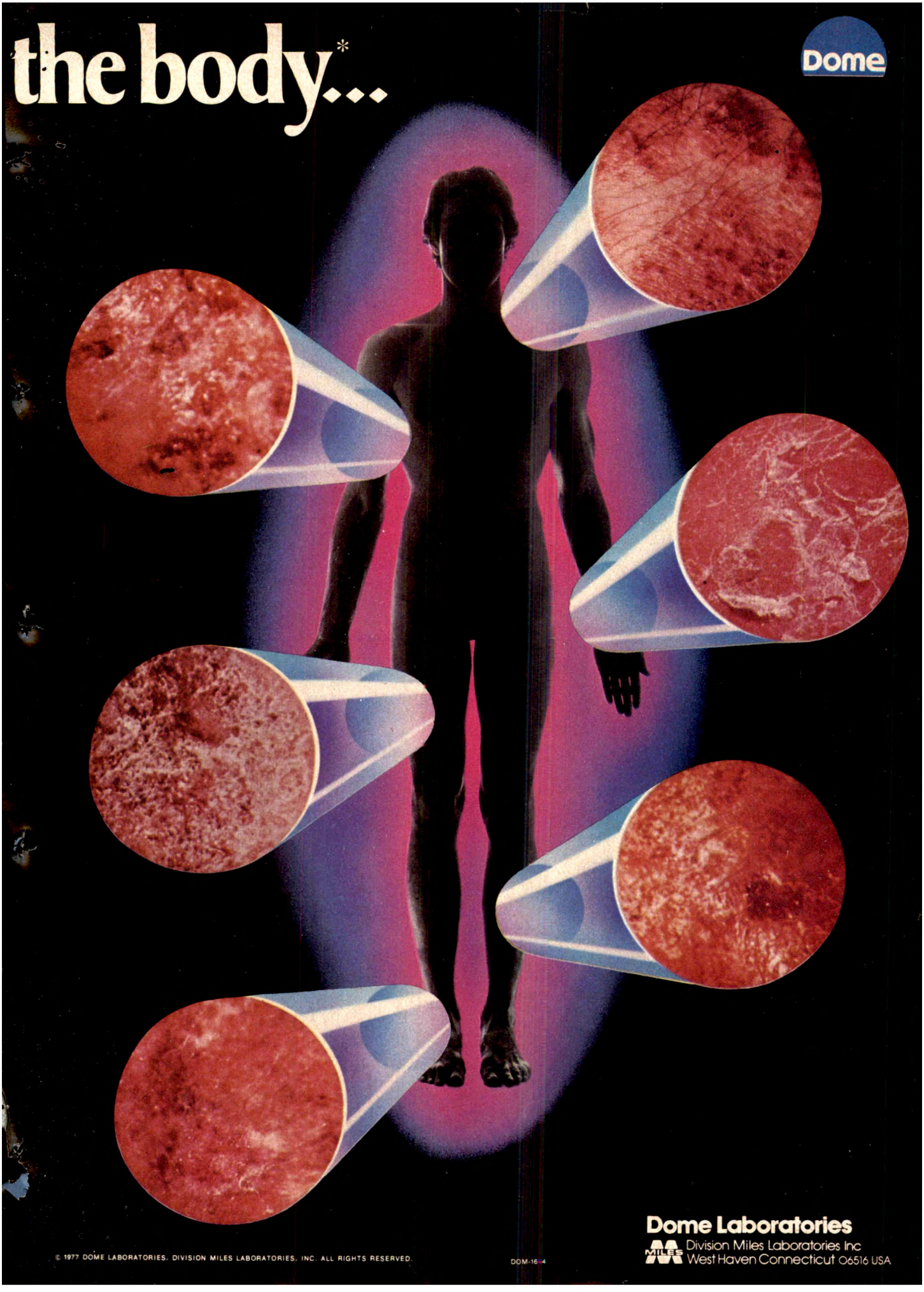
the body*...
Dome
Dome Laboratories
Division Miles Laboratories Inc
West Haven Connecticut 06516 USA
© 1977 DOME LABORATORIES, DIVISION MILES LABORATORIES, INC. ALL RIGHTS RESERVED.
DOM-16-4

When they first consult you for seborrheic dermatitis, they've tried everything but magic.

Only you can work the magic of a Capitrol® Rx.

(chloroxine 2%)

EFFECTIVENESS

- In a recent clinical study, 76% of patients reported clinical improvement with Capitrol®*
- Two treatments a week are usually sufficient.
- Contains an effective antibacterial.

ELEGANCE

- Cosmetically elegant, contains no tar or heavy metals.

SAFETY

- The most commonly reported adverse effect has been discoloration of light-colored hair (e.g. blond, gray or bleached). Some itching, burning and dryness have been reported.*

* Information on file at Westwood Pharmaceuticals, Inc.

Caution: Federal law prohibits dispensing without prescription.

Description: Capitrol® shampoo provides 2% chloroxine (each gram contains 20 mg. chloroxine) suspended in a shampoo base containing: sodium octoxynol-3 sulfonate, PEG-6 lauramide, dextrin, stearyl alcohol/ceteareth-20, sodium lauryl sulfoacetate, dioctyl sodium sulfosuccinate, magnesium aluminum silicate, PEG-14M, EDTA, citric acid, water, color and fragrance. The pH of the shampoo is 7.0.

The chemical name of chloroxine is 5,7-dichloro-8-hydroxyquinoline.

Actions: Chloroxine is a synthetic antibacterial compound. It has a structural similarity to a number of substituted 8-hydroxyquinolines that have been in therapeutic use for some years.

Indications: Capitrol® is indicated in the treatment of dandruff and mild to moderately severe seborrheic dermatitis of the scalp.

Contraindications: Capitrol® (chloroxine) may produce allergic contact sensitization reactions in patients who are sensitive to hydroxyquinolines or EDTA. This shampoo should not be used on acutely inflamed (exudative) lesions of the scalp.

Precautions: Patients should be advised to exercise care not to allow Capitrol to enter the eyes. For external use only. Keep this and all drugs out of the reach of children.

Adverse Reactions: Irritation and burning of the scalp and adjacent areas have been reported. Allergic type skin eruptions may occur in patients who are sensitive to any component of the shampoo. As with any medicated shampoo, chemical conjunctivitis may result if Capitrol enters the eyes. Discoloration of light-colored hair (e.g. blond, gray or bleached) may follow use of this preparation. Dryness of the scalp and increased itching have been reported.

Dosage and Administration: Capitrol® (chloroxine) should be massaged thoroughly into the wet scalp, avoiding contact with the eyes. Lather should remain on the scalp for approximately three minutes, then rinsed. The application should be repeated and the scalp rinsed thoroughly. Two treatments per week are usually sufficient.

How Supplied: Capitrol (chloroxine shampoo) is supplied in 85 g plastic tubes.

WESTWOOD
PHARMACEUTICALS INC.
Buffalo, New York 14213

© 1978 W.P. Inc.

Mycosis Fungoides With Blast Cell Transformation

Christine I. Harrington, MB, ChB, MRCP, David N. Slater, B Med Sci, MB, ChB

An unusual case of mycosis fungoides underwent apparent blast cell transformation after two years and the patient died in a leukemic state.

Report of a case

A 57-year-old man had a six-month history of raised red patches on the trunk and limbs. The clinical diagnosis of mycosis fungoides was confirmed by a skin biopsy specimen that demonstrated Daurier-Pautrier epidermal abscesses and a dermal "band-like" infiltrate of mixed mononuclear cells, including large and small hyperchromatic mycosis cells.[1,2] The initial lesions responded to ultraviolet light and topical fluocinonide and new lesions that appeared after seven months were treated with cyclophosphamide, prednisolone sodium phosphate, and local radiotherapy (total 4,000 R). Eighteen months later, results of the liver function tests became abnormal and inguinal lymphadenopathy developed. Two ten-day courses of chemotherapy (cyclophosphamide, vincristine sulfate, procarbazine hydrochloride, and prednisolone) were administered, but the third course was terminated owing to the development of pancytopenia. During the next month, the WBC count rose from 1,800/cu mm to 40,000/cu mm, 73% of which were atypical mononuclear cells with convoluted nuclei. Eighty-five percent of these measured 10 to 20μ and possessed plentiful basophilic cytoplasm (Fig 1), as is seen in blast cells. The fine nuclear chromatin and prominent nucleoli distinguished these cells from large mycosis cells.[1] The presence of fine PAS-positive granules, a high acid phosphatase activity, and a negative nonspecific esterase activity suggested that the cells had a T-cell lymphoid origin.[3] The remaining 15% of the mononuclear cells measured less than 10μ, had minimal cytoplasm and dense nuclear chromatin (Fig 2), and were indistinguishable from small mycosis cells.[2] Death occurred before immunological cell marker studies were performed. Necropsy revealed extensive malignant deposits that were composed of cells identical to those in the blood stream, skin (Fig 3), lymph nodes, spleen, liver, kidney, and thymus.

Comment

Schwarze and Ude have reported a comparable case of a patient who developed an immunoblastic sarcoma of the T-cell type, but the presence of erythroderma suggested a Sézary variant.[4] The peripheral blood in up to 38% of patients with mycosis fungoides contains cells similar to those in the Sézary syndrome,[2] and the smaller mononuclear cells in this case appeared to be of a similar type. It is probable that the larger cells were derived from mycosis cells that had undergone blast transformation and the extensive immunosuppressive therapy may have been an initiating factor, as has been suggested previously.[5] The lack of substantial deposits in the bone marrow is consistent with cells "spilling-over" into the blood stream and Greenberg et al[6] have reported a case of T-cell lymphoma that terminated in a similar fashion.

From the Rupert Hallam Department of Dermatology, Hallamshire Hospital (Dr Harrington) and the Academic Division of Pathology, University of Sheffield Medical School (Dr Slater), Sheffield, England.

Reprints not available.

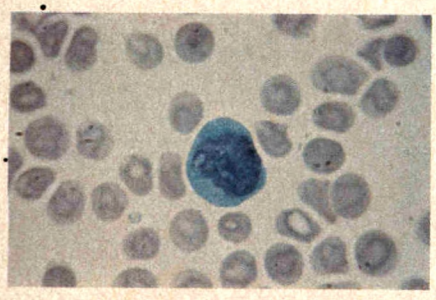

Fig 1.—Atypical blast cell with convoluted nucleus, prominent nucleoli, and plentiful basophilic cytoplasm (Leishman's stain, ×1,000).

Fig 2.—Small atypical mononuclear cell resembling small mycosis cells in skin (Leishman's stain, ×1,000).

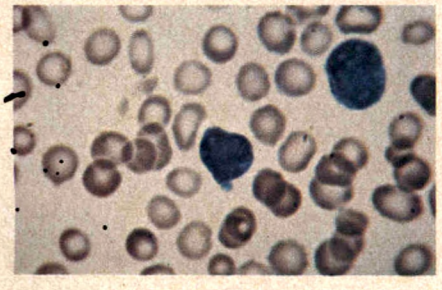

Fig 3.—Skin showing spectrum of cells ranging from small mycosis cells with hyperchromatic and convoluted nuclei to larger cells similar to blast cells in blood (hematoxylin-eosin, ×600).

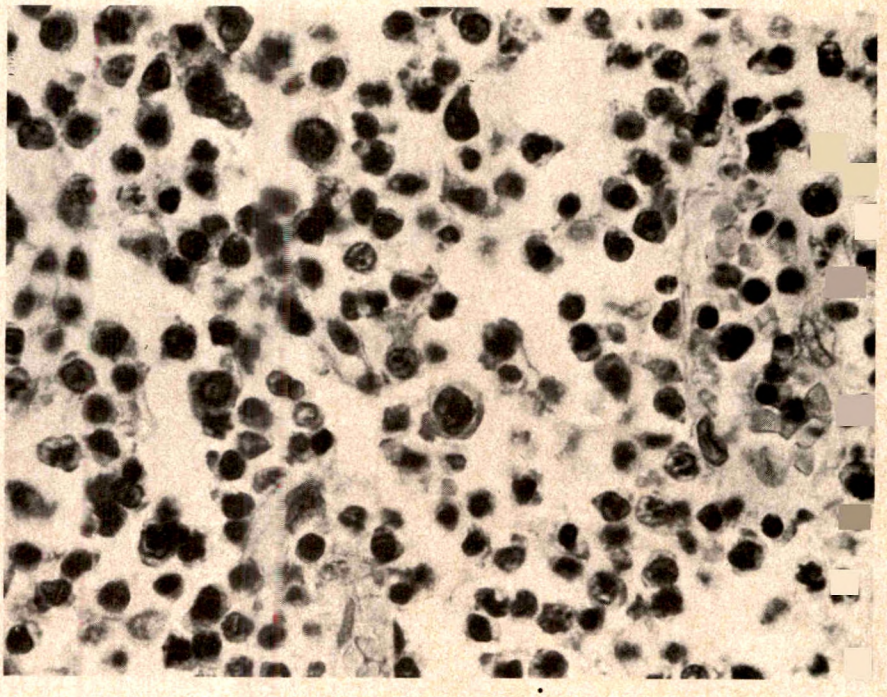

I. B. Sneddon, MRCP, and J. Richmond, MD, gave permission to report this case, the patient of which was admitted under their care.

Nonproprietary Name and Trademarks of Drugs

Fluocinonide–*Lidex, Topsyn.*
Vincristine sulfate–*Oncovin.*

References

1. Rappaport H, Thomas LB: Mycosis fungoides: The pathology of extracutaneous involvement. *Cancer* 34:1198-1229, 1974.
2. Lutzner MA, Hobbs JW, Horvath P: Ultrastructure of abnormal cells in Sézary syndrome, mycosis fungoides, and parapsoriasis en plaque. *Arch Dermatol* 103:375-386, 1971.
3. Dacie JV, Lewis SM, Catovsky D: Blood cell cytochemistry and supplementary techniques, in Dacie JV, Lewis SM (eds): *Practical Haematology*, ed 5. London, Churchill Livingstone, 1975, pp 120-149.
4. Schwarze EW, Ude P: Immunoblastic sarcoma with leukaemic blood picture in the terminal stage of mycosis fungoides. *Virchous Arch Pathol Anat* 369:165-172, 1975.
5. Ledonne JE: Mycosis fungoides: Report of a case terminating in myelogenous leukaemia. *N Engl J Med* 250:240-242, 1954.
6. Greenberg BR, Peter CR, Glassey F, et al: A case of T-cell lymphoma with convoluted lymphocytes. *Cancer* 38:1602-1607, 1976.

Twenty-Nail Dystrophy

A Variant of Lichen Planus

Richard K. Scher, MD; Robert Fischbein, MD; A. Bernard Ackerman, MD

Twenty-nail dystrophy of childhood was described by Hazelrigg and colleagues[1] as a distinct clinical entity. However, no nail biopsies were performed by these authors in their study, and to our knowledge, there is not any published instance of it being done.

In the section for diagnosis and treatment of nail diseases at our institution, we were aware of having seen six cases that very closely matched those described by Hazelrigg et al.[1] Our clinical diagnosis in all of these cases was lichen planus. We performed a nail biopsy on one such patient. Incidentally, one of our subjects was an adult; this finding has been reported elsewhere.[2,3]

Report of a Case

A 7-year-old boy had abnormalities of all 20 nails. The changes consisted of onychorrhexis with distal splitting (Fig 1). The nails exhibited increased fragility and were thinner and less transparent than normal. No abnormal findings were noted on any portion of the nail unit except for the nail plate. The nail matrix, of course, could not be seen, but we assumed that it was defective because it was the source of the nail plate. Results of examination of the skin, hair, teeth, and mucous membranes were normal. No family member had similar changes. In multiple studies, preparations of nail scrapings were consistently negative for fungi.

From the Department of Dermatology, New York University Medical Center.
Reprints not available.

Results

A hematoxylin-eosin-stained biopsy preparation revealed irregular, psoriasiform epithelial hyperplasia with hypergranulosis. A dense, lichenoid infiltrate of histiocytes and lymphocytes, which obscured the interface between the connective tissue and epithelium, was seen. Staining with PAS failed to reveal any fungal elements. A microscopic picture of lichen planus is shown in Fig 2.

Fig 1.—Left, Nails of patient's right hand exhibit onychorrhexis with distal splitting. Right, Nails of right foot show same abnormal brittleness.

Comment

We think that 20-nail dystrophy of childhood is in reality a variant of lichen planus. Hazelrigg et al[1] stated "The thin and longitudinally ridged nails of lichen planus resemble the nails of 20-nail dystrophy more closely than any other condition in the differential diagnosis." They added that "pterygium formation has not been observed in 20-nail dystrophy, and the skin and buccal mucous membranes show no signs of lichen planus." It is known that nail involvement alone may occur in lichen planus.[4] Furthermore, pterygia are late manifestations and therefore not always seen. They usually occur in the more destructive type of lichen planus that has been found in adults[5] and appear to be distinctly absent in this benign

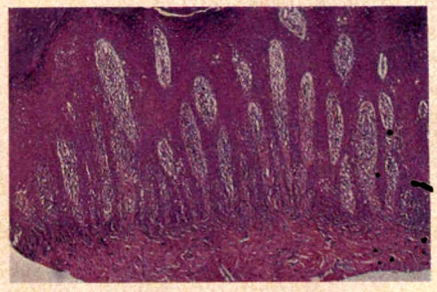

Fig 2.—Biopsy specimen of nail showing changes of lichen planus (hematoxylin-eosin, ×50).

variety found in children.

In conclusion, we propose that the excellent report of 20-nail dystrophy of childhood should not be considered a new entity but rather a subgroup of lichen planus. There is no objection to the term 20-nail dystrophy, but the suggestion that it occurs only in children now appears incorrect.

References

1. Hazelrigg DE, Duncan C, Jarratt M: Twenty-nail dystrophy of childhood. *Arch Dermatol* 113:73-75, 1977.
2. Synkowski DR: Twenty-nail dystrophy. *Arch Dermatol* 113:1462, 1977.
3. Baran R, Dupré A: Vertical striated sandpaper nails. *Arch Dermatol* 113:1613, 1977.
4. Burgoon CF Jr, Kostrzewa RM: Lichen planus limited to the nails. *Arch Dermatol* 100:371, 1969.
5. Zaias N: The nail in lichen planus. *Arch Dermatol* 101:264-271, 1970.

The Coexistence of Two Types of Porphyria in One Family

Joel Levine, MD; Capt W. Taylor Johnson, MC, USN; Donald P. Tschudy, MD

Erythropoietic protoporphyria (EPP) and porphyria cutanea tarda (PCT) are well-defined disorders of porphyrin metabolism that have been studied extensively, including hereditary mechanisms of transmission. The former appears to be transmitted via a Mendelian dominant pattern of inheritance, whereas the latter usually has no demonstrable hereditary pattern.[1]

The present report describes a father with PCT and a daughter with EPP. In both, the clinical and chemical findings were characteristic of their respective diseases.

Report of Cases

Case 1.—A 47-year-old man was first seen in 1971 with a three-year history of skin eruptions. He described painful blisters of the hands and face and increased skin fragility followed by residual hyperpigmentation and scarring after exposure to the sun. He frequently observed wine-red urine. Ethanol consumption was heavy but there was no history of other drugs. The patient recalled similar skin changes in his father, who also had a heavy ethanol consumption. The patient has two children, aged 12 years (case 2) and aged 10 years (case 3), by the same wife; they will be discussed subsequently.

From the Department of Dermatology, National Naval Medical Center, Bethesda, Md (Dr Johnson) and the Metabolism Branch, National Cancer Institute, National Institutes of Health, Bethesda, Md (Drs Levine and Tschudy). Dr Levine is now with University of Connecticut Health Center, Farmington.

Reprint requests to Department of Dermatology, National Naval Medical Center, Bethesda, MD 20014 (Dr Johnson).

Physical examination showed a stocky man with plethoric facies and a deep tan excluding the bathing trunk area. The facial skin was partially hyperpigmented, furrowed, and leathery. The hands had many bullae, 0.5 to 1.0 cm in diameter, circular erosions, superficial scars, and severe hyperpigmentation. Hypertrichosis or sclerodermoid changes were not noted. The liver span was 13 cm with a nontender edge that was palpable 2 cm below the costal margin. The spleen was not enlarged and there were no signs of portal hypertension.

Pertinent laboratory studies included a normal WBC count, a hemoglobin level of 15.2 gm/100 ml, and a hematocrit value of 46%. The serum iron level was 142 μg/100 ml with a total iron binding capacity of 372 μg/100 ml (38% saturation). Findings from the following laboratory tests were normal: prothrombin time, partial thromboplastin time, and platelet count. His blood type was O. He was Rh positive and had HLA-A2, HLA-A7, and HLA-Aw15. Results of the following tests showed normal values: serum alkaline phosphatase, SGOT, and bilirubin (total). Findings from an upper gastrointestinal tract film series, Te^{99} liver test, and spleen scan were normal. Multiple skin biopsy specimens of intact bullae showed subepidermal bullae with no acantholysis. There was homogenization of dermal collagen and minimal to absent inflammatory reaction.

The urine, fecal, and RBC porphyrin and porphyrin precursor values are presented in the Table. The patient was advised to curtail ethanol consumption and his condition was treated with phlebotomy every two weeks for six weeks, but he declined phlebotomy thereafter. He continues to have intermittent blisters and increased fragility of his skin.

Case 2.—Patient 2, aged 12 years, is the oldest daughter of patient 1. A history showed severe sunlight intolerance that was characterized by an acute burning, erythematous, wheal-like swelling of the face, hands, and dorsa of the feet since age 3. There was residual local hyperpigmentation and crust formation but no blisters or increased fragility. These changes were seasonal; they were worse in spring and summer and were unassociated with any systemic symptoms or change of urine color. Relief with sunscreens, antipruritics, and antihistamines was minimal.

Physical examination showed a normally developed girl with pertinent physical findings limited to the integument. The skin of the hands, feet, and lower half of the face was thickened, furrowed, and hypopigmented. The skin of the nose was wrinkled and had irregular areas of hypopigmentation. There was slight scaling on the face and hands. Hypertrichosis and scarring were not present. The liver and spleen were not enlarged.

Pertinent laboratory findings were a normal WBC count, normal differential cell count, a hemoglobin level of 13 gm/100 ml, and a hematocrit value of 38%. There was a moderate microcytosis associated with a mean corpuscular volume of 80 and a mean corpuscular hemoglobin count of 34.5. The reticulocyte count was 0.6% and the serum iron level was 79 μg/100 ml with a total iron binding capacity of 374 μg/100 ml (21% saturation). Findings from the following laboratory tests were normal: prothrombin time, partial prothrombin time, and platelet count. Her blood type was B. She was Rh negative and had HLA-A1, HLA-A5, and HLA-A15. Serum total bilirubin, transaminase, and lactic dehydrogenase levels were normal, but the serum alkaline phosphatase value was 163 IU/liter (normal, 30 to 85 IU/liter). Fractionation showed it to be of bone origin. Erythrocyte, urine, and fecal porphyrin values are presented in the Table.

Case 3.—Patient 3, aged 10 years, is the second daughter of patient 1. She has no

Porphyrin Values of Four Family Members*

Patient	Age, yr	Date	Stool, μg/gm Dry Weight: Uro	Stool: Copro	Stool: Proto	Urine: PBG, mg/Day	Urine: ALA, mg/Day	Urine: Uro, μg/Day	Urine: Copro, μg/Day	RBC, μg/100 ml: Proto	RBC: Copro
Normal value			<4	<33	<100	<3	<4	<60	<300	<60	<2
Patient 1; father; blood type, O; Rh +; HLA-A2, HLA-A7, HLA-Aw15	44	10/71	...	...	...	...	...	...	...	...	...
		3/72	3.20	38.0	4.0	1.4	2.80	1,890.0	246.0	5.1	11.0
		4/72	...	...	...	...	...	...	...	13.7	1.6
		1/73	594.00	1,037.0	0.5	2.5	2.70	1,824.0	337.0	21.6	4.8
		5/73	208.00	1,662.0	1.9	2.2	1.20	5,800.0	1,736.0	16.2	18.9
Patient 2; daughter; blood type, B; Rh−; HLA-A5, HLA-A7, HLA-Aw15	13	10/71	...	...	...	3.0	1.20	10.4	7.5	1,257.0	11.5
		3/72	0.32	8.4	9.3	...	...	...	...	69.0	17.5
		4/72	...	...	...	...	...	...	...	116.0	2.8
		1/73	2.70	11.4	0.4	0.4	0.40	24.4	90.0	5,150.0	3.5
		5/73	19.00	44.0	1.9	1.2	0	18.0	78.4	55.3	3.4
Patient 3; daughter	10	4/72	...	...	...	...	...	...	...	13.0	2.8
Patient 4; mother; blood type, AB; HLA-A1, HLA-A5, HLA-Aw15	40	3/72	0.75	13.3	6.3	0.7	0.80	14.4	32.0	17.1	11.9
		4/72	...	...	...	...	...	...	...	19.8	3.9
		1/73	...	...	...	0.2	0.44	6.6	41.0	13.5	1.2
		5/73	12.80	85.0	1.5	0.9	0	35.8	225.0	8.8	0.5

*Uro indicates uroporphyrin; copro, coproporphyrin; proto, protoporphyrin; PBG, porphobilinogen; ALA, amino levulinic acid.

signs or symptoms of a photosensitive dermatitis or any systemic disease. Red blood cell porphyrin values are presented in the Table.

Methods

Porphyrins were measured as described by Schwartz et al.[2] Porphyrin precursors (aminolevulinic acid and porphobilinogen) were measured by the method of Marver et al.[3]

Results

The values of fecal, urinary, and RBC porphyrins in four members of the family are presented in the Table. In the father the chemical findings are characteristic of PCT—greatly increased urinary uroporphyrin levels with normal to increased levels of urinary coproporphyrin. There is also an increase of fecal uroporphyrin and coproporphyrin levels. Red blood cell protoporphyrin levels were normal, but some elevation of coproporphyrin levels was seen. In the daughter (case 2), the chemical findings are those of EPP—high RBC protoporphyrin levels with normal urine porphyrin levels. The range of protoporphyrins in the erythrocytes is greater than one usually sees in EPP and the reasons for the fluctuation are uncertain. The mother and the other daughter (case 3) showed no abnormalities indicative of porphyria on the examinations performed. The one elevated value of erythrocyte coproporphyrin in the mother occurred on a day when the other two measurements of erythrocyte coproporphyrin (of patients 1 and 2) were also elevated. Fluorescent microscopy of erythrocytes was not performed.

Comment

The clinical and chemical values in patient 1 and his daughter (patient 2) clearly indicate that he has one type of porphyria, PCT, and she another type, EPP.

The present study raises a fascinating question as to the origin and consequence of EPP in patient 2. This disease has been shown to be transmitted as a Mendelian dominant disorder and should, therefore, be present in either parent.[1] Previous studies have shown that although parents of an affected person are often asymptomatic, they nevertheless may have an increase of either RBC or fecal protoporphyrin levels. Both parents of patient 2 had normal RBC and fecal protoporphyrin levels on repeated examination. Thus, neither parent could be easily implicated as the source of her disease. A number of possibilities might be considered as explanations of this apparent discrepancy. First, the antigenic data from ABO blood groups do not suggest illegitimacy. Second, porphyrin values are known to fluctuate widely in EPP, sometimes to within normal range. It is possible that serial multiple measurements of these values might have revealed a carrier parent. Unfortunately, this was not possible. Third is the possibility that the disease in patient 2 could represent a new mutation.

Recently developed techniques, such as determination of ferrochelatase (heme synthetase) activity in fibroblast cultures, as described by Bloomer et al,[4] in patients with EPP and their parents or uroporphyrinogen decarboxylase determinations in the liver and erythrocytes of patients with PCT and their families, as described by Kushner et al,[5] may shed some light on the hereditary pattern in the present family.

At this time, however, the reported coexistence of PCT and EPP in sequential members of one family remains an unexplained and unique event.

References

1. Tschudy DP: Porphyrin metabolism and the porphyrias, in Bondy PK, Rosenberg LE (eds): *Duncan's Disease of Metabolism*, 7. Philadelphia, WB Saunders Co, 1974, pp 775-824.
2. Schwartz S, Berg MH, Bossenmaier I, et al: Determination of porphyrins in biological material. *Methods Biochem Anal* 8:221-293, 1960.
3. Marver HS, Tschudy DP, Perlroth MG, et al: The determination of aminoketones in biological fluids. *Anal Biochem* 14:53-60, 1966.
4. Bloomer JR, Bonkowsky HL, Ebert PS, et al: Inheritance in protoporphyria. *Lancet* 2:226-228, 1976.
5. Kushner JP, Barbuto AJ, Lee GR: An inherited enzymatic defect in porphyria cutanea tarda. *J Clin Invest* 58:1089-1097, 1976.

Prevent over-abrasion. Prescribe the natural cleansing control of Komex.

For patients with oily skin or acne, the natural cleansing control of Komex offers a gentle alternative to harsh abradants. Oil, sebum, make-up and surface debris are cleansed away gently by the unique Komex combination of surface active agents and naturally occurring water soluble cleansing particles. The more water your patients use the more gently Komex cleanses.

For thorough cleansing and conditioning without over-abrasion, prescribe the natural cleansing control of Komex.

Caution: Avoid contact with eyes.
Do not use on inflamed skin.

Barnes-Hind Pharmaceuticals, Inc.
895 Kifer Road
Sunnyvale, California 94086

Komex®

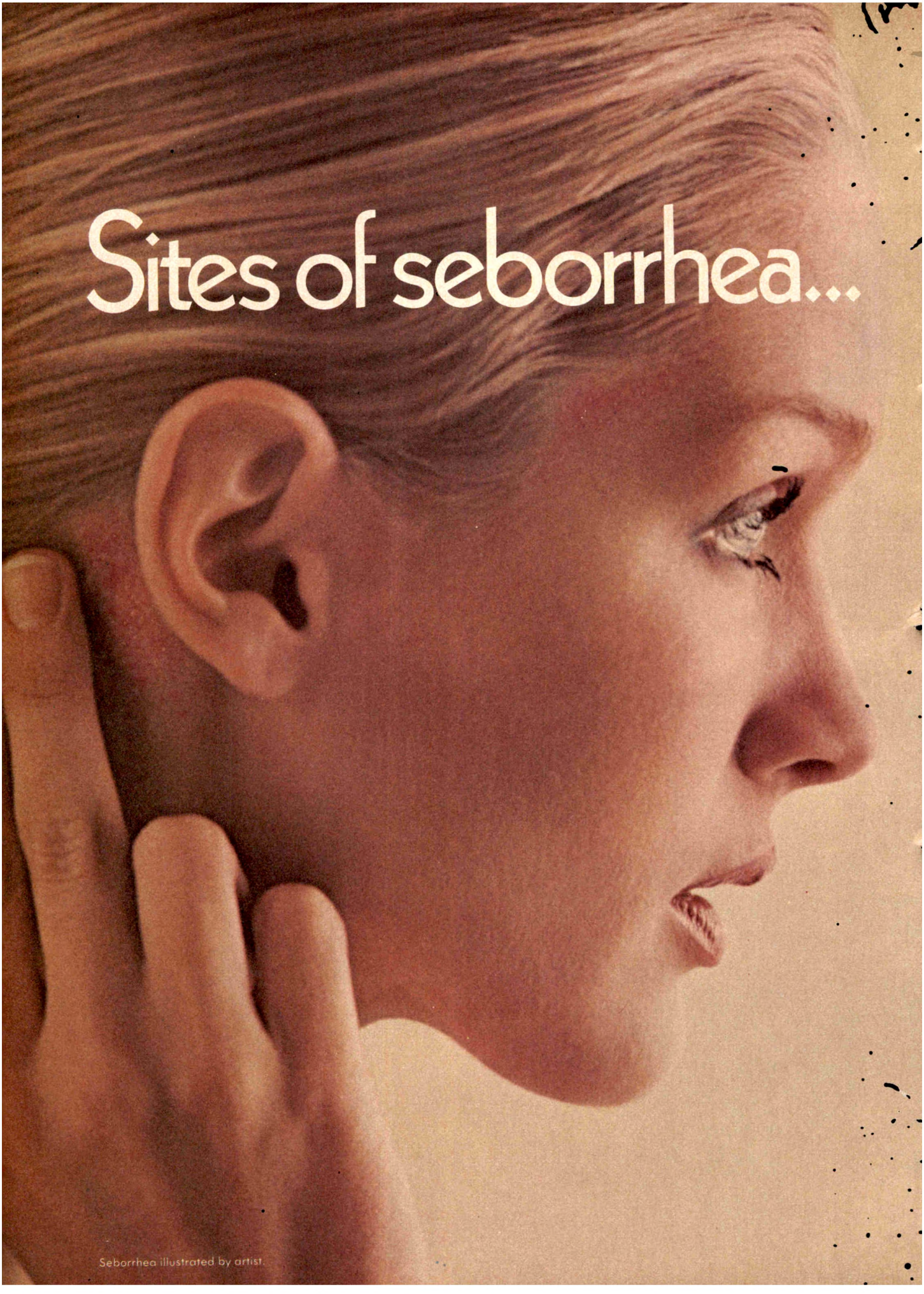
Sites of seborrhea...
Seborrhea illustrated by artist.

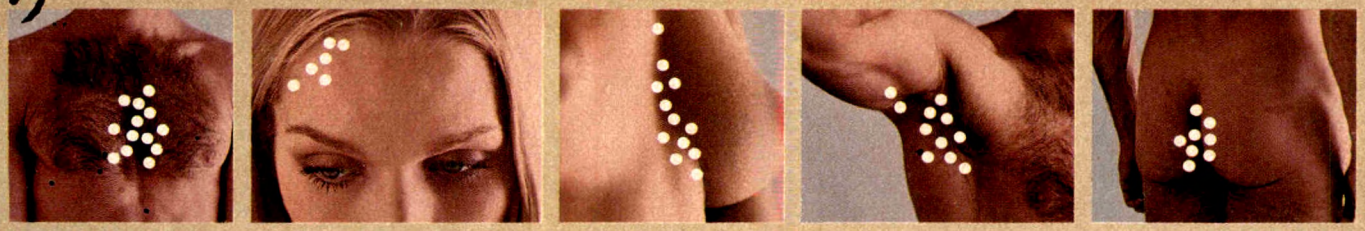

spots for Uticort™ (betamethasone benzoate gel, USP)

a highly effective topical steroid in a special base

UTICORT contains the fluorinated corticosteroid ester — betamethasone benzoate 0.025% — in a specially formulated, clear, self-liquefying gel base to increase steroid activity.

Patients with seborrheic dermatitis treated with UTICORT improved 86% in an average of 11.6 days.

liquefies on application for better surface contact

UTICORT is especially valuable in the treatment of seborrheic dermatitis on hairy areas of the body.

cosmetically acceptable

UTICORT dries to a clear film and can be used confidently on either smooth or hairy skin areas. Moreover, it is greaseless, nonstaining, and nonsticky.

preservative free

Contains no parabens or other potentially sensitizing preservatives.

Brief summary of prescribing information

INDICATIONS. Uticort Gel (betamethasone benzoate gel, USP) is intended for relief of the inflammatory manifestations of corticosteroid-responsive dermatoses.

CONTRAINDICATIONS. Topical steroids are contraindicated in viral diseases of the skin, such as varicella and vaccinia. Topical steroids are contraindicated in patients with a history of sensitivity to any of the components of the preparation.

This preparation is not for ophthalmic use.

PRECAUTIONS. If irritation develops, the gel should be discontinued and appropriate therapy instituted. In the presence of an infection, the use of appropriate antifungal or antibacterial agents should be instituted. If a favorable response does not occur promptly, the corticosteroid should be discontinued until the infection has been adequately controlled.

If extensive areas are treated, or if the occlusive technique is used, the possibility exists of increased systemic absorption of the corticosteroid, and suitable precautions should be taken.

Although topical steroids have not been reported to have an adverse effect on pregnancy, the safety of their use in pregnant females has not absolutely been established. Therefore, they should not be used extensively on pregnant patients, or in large amounts, or for prolonged periods of time.

Due to the alcohol content of the vehicle, Uticort Gel (betamethasone benzoate gel, USP) may cause mild, transient stinging without irritation if used on excoriated skin.

ADVERSE REACTIONS. The following local adverse reactions have been reported with topical corticosteroids: burning sensations, itching, irritation, dryness, folliculitis, secondary infection, skin atrophy, striae, hypertrichosis, acneform eruptions, and hypopigmentation.

DOSAGE AND ADMINISTRATION. Apply to affected areas two to four times daily as needed.

HOW SUPPLIED. N 0071-3025 Uticort Gel is supplied in 15 gram and 60 gram tubes.

Caution: Federal law prohibits dispensing without prescription.

UE

PARKE-DAVIS

PD-JA-2343•1-P (1-78)

PARKE, DAVIS & COMPANY Detroit, MI 48232

For Skin That Needs Your Special Skills...
Neutrogena...
for exceptional patient compliance.*

For Skin without Water

Neutrogena® Dry-Skin Soap**

Neutrogena® Rainbath® Bath Gel**

Neutrogena® Hand Cream**

Neutrogena®

Dedicated to Sensitive Skin Care.

Neutrogena Corp., 5755 West 96th Street, Los Angeles, California 90045

*Journal reprints on clinical evaluation describing patient compliance are available on request.
**Available as unscented formulas.

for the part-time occupational physician...

an invaluable quick reference guide to occupational dermatoses

The AMA's new guide, *Occupational Dermatoses,* is an invaluable aid for physicians working part-time in occupational health programs.

It provides a ready reference for specific information on the causes, diagnosis, prevention, and treatment of occupational skin diseases. It also discusses management of prolonged and recurrent dermatoses, medico-legal aspects, and provides extensive references.

To order your copy ($1 ea.) of *Occupational Dermatoses, OP-108,* write: Order Dept., American Medical Association, 535 N. Dearborn St., Chicago, Ill. 60610.



Comes on strong

Against inflammatory dermatoses

Aristocort®-A

TRIAMCINOLONE ACETONIDE

0.5% Cream and Ointment

INDICATIONS: For relief of inflammatory manifestations of corticosteroid-responsive dermatoses.

CONTRAINDICATIONS: Viral skin diseases, such as varicella and vaccinia; hypersensitivity to any component (not for ophthalmic use); when circulation is markedly impaired.

WARNINGS: Safety of use in pregnancy has not been absolutely established. Do not use extensively, in large amounts, or for prolonged periods of time in pregnant patients.

PRECAUTIONS: If irritation develops, discontinue use and institute appropriate therapy. In infections, use appropriate antifungal or antibacterial agents; if a favorable response does not occur promptly, discontinue the corticosteroid until the infection is adequately controlled. If extensive areas are treated or the occlusive technique is used, increased systemic absorption of the corticosteroid may occur; take suitable precautions.

ADVERSE REACTIONS: (local) Burning sensations, itching, irritation, dryness, folliculitis, secondary infection, skin atrophy, striae, hypertrichosis, acneform eruption and hypopigmentation.

ARISTOCORT-A CREAM: Each gram contains 5 mg. (0.5%) of the highly active steroid, Triamcinolone Acetonide (a derivative of triamcinolone) in AQUATAIN, a specially formulated base composed of emulsifying wax NF, isopropyl palmitate, glycerin USP, sorbitol solution USP, lactic acid, 2% benzyl alcohol and purified water. AQUATAIN is non-staining, water-washable, paraben-free, spermaceti-free and has a light texture and consistency.

ARISTOCORT-A OINTMENT: Each gram contains 5 mg. (0.5%) of the highly active steroid, Triamcinolone Acetonide (a derivative of triamcinolone) in a specially formulated base composed of emulsifying wax NF, white petrolatum, and propylene glycol.

Lederle LEDERLE LABORATORIES, A Division of American Cyanamid Company, Pearl River, New York 10965 067-7

Books

Readers are advised that in view of The Copyright Revision Act of 1976, *all Book Reviews submitted for publication must contain on the transmittal letter the following language: "The person(s) undersigned hereby grant the American Medical Association permission to publish this Book Review and in addition, hereby assigns all copyright ownership therein to the AMA."*

Questions and Answers About Acne, by John R.T. Reeves, MD, 111 pp, with illus, $5.95, Prentice-Hall Inc, 1977.

A cliché pervasive in most laudative book reviews is the coaxing suggestion that the volume be added to one's library shelf. In the case of *Questions and Answers About Acne,* it might be advisable to keep it closer at hand. For, in this volume, Dr Reeves informs the acne patient, to whom this book is addressed, how the dermatologist or other physician should treat acne, even with the inclusion of appropriate office visit fees. In today's consumer-oriented climate, such a tendentious approach, while less unsettling than it might have been in an older day, potentially suffers the risk of author bias when dealing with acne, a complex disease of unknown cause, in which not all treatments have been evaluated adequately. As an example, the author's condemnation of bacterial toxoid treatment is understandable; yet some physicians still use this therapy, and there is no indisputable evidence as to its ineffectiveness.

The first portion of the book, devoted to the etiopathogenesis of acne, is marred by numerous erroneous or unsupportable statements about acne. Whether these are partially intentional on Dr Reeves' part so as to simplify the presentation to the lay reader, or whether they reflect the author's unfamiliarity with some aspects of the disease he writes about, is difficult to say. The following examples are illustrative: "In acne, the oil glands become plugged, infected and ruptured.... Some oil glands empty directly onto the skin surface.... In the late twenties and early thirties oil production begins to fall quite a bit.... Cortisone and progesterone stimulate the oil glands.... High estrogen in pregnancy prevents oiliness.... In menopause, oil glands produce more oil.... Only birth control pills with high estrogen content will help acne.... Washing reduces the likelihood of the formation of inflamed lesions.... Mild sunburn with peeling will remove keratin from pores, and the penetration of the sun's rays into the skin kills bacteria and possibly slows down oil gland activity." That this is the weakest section of the book is perhaps fortunate, as the average reader is apt to give it little more than cursory attention.

The remainder and larger portion of the book deals with the various treatments used for acne and is clearly the best and most useful section. It describes the treatments in readily understandable language for the layman, and it is almost invariably accurate and quite complete, including even a section on dapsone. One issue, however, deserves comment. In discussing oral antibiotic treatment, the author writes that during flare-ups of acne, doses of drug should be increased temporarily, ie, for 7 to 14 days. This is a common self-practice among patients but is more likely to be of a psychological rather than biological benefit, since controlled studies have shown that improvement of acne with any given level of antibiotic is rarely evident in less than two weeks.

PETER E. POCHI, MD
Boston

Oral Manifestations of Inherited Disorders, by Heddie O. Sedano, John J. Saik, Jr, and Robert J. Gorlin, 214 pp, with illus, $19.95, Woburn, Mass, Butterworths Publishers Inc, 1977.

According to the publisher, this book is "intended for those professionals interested in malformation syndromes and inherited disorders who might not have a detailed knowledge of the oral cavity and its possible alterations in inherited syndromes." Because more than half of the syndromes discussed in this book have cutaneous features (70 of 129), dermatologists should be one group for whom this book was written.

The first chapter begins with a section on genetic counseling, which is oversimplified, followed by a concise but informative discussion of the normal oral cavity. The remainder of the book is devoted to descriptions of individual syndromes. A brief one-to-two page description of each entity is accompanied by several current references and usually a single, small black-and-white photograph. Although it would be nice to have illustrations, this probably could not have been done without resulting in a more expensive and therefore less accessible book. There is a useful table that lists ectodermal structures that are affected in the various ectodermal dysplasias.

The syndromes are organized into six major categories, eg, systemic inherited disorders with dental involvement and systemic disorders associated with facial clefting, and within these categories, the syndromes are listed alphabetically. In many instances, the authors have chosen to use a descriptive name rather than an eponym. For example, "Hyperkeratosis Palmoplantaris and Periodontoclasia in Childhood" is the listing for Papillon-Lefèvre's syndrome. For those of us who can't remember the name but never forget a face, this effort in descriptive naming is commendable. However, in using alternative and often less well-known names it is important that a book of this type be thoroughly indexed and cross-referenced. The absence of such indexing is this book's most serious failing, which will often significantly limit its usefulness to the hurried practitioner. For example, Papillon-Lefèvre's syndrome is not listed in the index; there are also no listings for any other eponyms, including those retained by the authors as the preferred name. Instead, the index is organized by organ system, and individual listings are signs and symptoms referrable to that system. This has not been done as thoroughly and logically as one would desire. For example, mucocutaneous candidiasis is referred to in this book as the "endocrine-candidosis syndrome"; under "skin" in the index it is referenced only by the following headings: "dry," "hair, alopecia," and "hair, eyebrows."

There are some relevant conditions which have been omitted, eg, Darier's disease; however, it could have been renamed and obscurely indexed, but most likely some omissions were necessary to keep costs of publication within bounds. The book is very reasonably priced at $19.95. There is a need for this book, and it has no competitors. I recommend it to all who have an interest in this subject.

MARY L. WILLIAMS, MD
San Francisco

ACNE'S ANXIETY

BENZAGEL® 5% Acne Gel 10% Acne Gel

(5% or 10% benzoyl peroxide, 6% polyoxyethylene lauryl ether, 40% alcohol)

Early visible improvement helps to relieve anxiety and promotes patient cooperation—Simple and pleasant to use

- Benzoyl peroxide in a special alcohol gel base—Reliable and predictable, imparts a pleasant cooling sensation with controlled drying of sebaceous oils. Accelerates desquamation.
- "BP base/bond" for uniform therapeutic deposition of benzoyl peroxide—Reduces burning sensation on application, for greater patient acceptance.
- Effective antibacterial and comedolytic action—Rapid improvement is seen, often within two weeks.

BENZAGEL® a basic component of acne therapy

Description: 5% or 10% benzoyl peroxide, 6% polyoxyethylene lauryl ether and 40% alcohol in an astringent gel containing colloidal magnesium aluminum silicate, hydroxypropyl methylcellulose, citric acid, fragrance and purified water.

Action: Provides drying, desquamative and antiseptic activity.

Indication: An aid in the treatment of acne.

Dosage and Administration: Wash affected areas prior to application. Apply once or more daily or as directed by physician.

Contraindications: Should not be used by patients having known sensitivity to either benzoyl peroxide or polyoxyethylene lauryl ether.

Precautions: For External Use Only. Not for ophthalmic use. Keep away from eyes and mucosae. Very fair individuals should begin with a single application at bedtime allowing overnight medication. May bleach colored fabrics. Keep this and all other medications out of the reach of children.

Caution: Federal law prohibits dispensing without prescription.

How Supplied: Plastic tubes, 1½ oz. and 3 oz.

For Patient Starters
Call Toll-Free (800) 523-6674

Dermik

Dermik Laboratories, Inc.
Fort Washington, Pa. U.S.A. 19034

Admit it, most women will never give up their cosmetics.

Your patient's cosmetics should care as much about her skin as you do. Because you'll never convince most women not to wear makeup. Allercreme does care. That's why we go to such great lengths to make sure our hypo-allergenic cosmetics and skin care products are as safe and pure as we can make them.

We analyze everything.

We will never use a known irritant in any of our products. In fact, we don't take any ingredient for granted. Even those considered to be tried and proven.

Our cosmetic chemists and medical staff review every single ingredient in all Allercreme products for safety and purity. And before we market any new product, we test it on human skin for irritation and sensitivity potential. If there is the least hint of irritation or sensitization, the product will never leave our laboratories.

We come to you.

You never have to go out of your way to see us. We call on dermatologists and other interested physicians in person to answer any questions, supply you with formulas, research, technical information and samples of Allercreme products.

If any of your patients ever has the slightest indication of sensitivity to any of our products, we will provide patch test kits; we'll work directly with you to identify the offending ingredient and recommend substitute products free of it.

We show we care.

You can be sure that any product with the Allercreme name on the label will always care as much about your patients' skin as you do. Because Allercreme will constantly be researching new hypo-allergenic cosmetics and skin care products that can live up to our high standards for purity, fashion and performance. And that's a promise.

HYPO-ALLERGENIC
Allercreme®

We care about your patients' skin.

Readers are advised that in view of The Copyright Revision Act of 1976, *all Letters to the Editor submitted for publication must contain on the transmittal letter the following language: "The person(s) undersigned hereby grant the American Medical Association permission to publish this Letter and in addition, hereby assigns all copyright ownership therein to the AMA."*

Tape Treatment for Fiberglass Splinters

To the Editor.—Now that the home insulation fad is upon us, we have received some inquiries from "do-it-yourselfers" concerning the problem of fiberglass splinters in the hands and forearms. We have found that the best remedy for this problem is the application of ordinary plumbers' duct tape to the affected areas. The excellent adhesiveness of this tape promptly extracts these troublesome splinters.

JAMES H. DEEKEN, MD
Kansas City, Mo

Dermatitis and Sézary's Cells

To the Editor.—Sézary's cells are characteristically found in the peripheral blood smears of patients with Sézary's syndrome and have been noted histologically in malignant, premalignant, and benign dermatoses.[1,2] These cells also have been noted in the peripheral blood of patients with "pre-Sézary's erythroderma syndrome."[3] However, we have found that a few Sézary's cells are commonly present in the peripheral blood of patients with generalized dermatitis of varied causes.

When serial peripheral blood smears were taken from patients at the Mayo Clinic, who were hospitalized for exfoliative dermatitis, Sézary's cells amounted to 1% to 3% of the total cell count and were frequently found during the acute phase of the severe dermatitis. We found that Sézary's cells were no longer demonstrable when the dermatitis cleared; this also was noted in generalized contact dermatitis, atopic dermatitis, and exfoliative psoriasis.

The graph of serial counts of Sézary's cells is characteristic and shows the variable percentage of Sézary's cells (Figure) during the hospitalization of a 72-year-old woman who had a 20-year history of psoriasis vulgaris and who developed an acute generalized exfoliative dermatitis when she was treated with a psoralen and ultraviolet light.

SCOTT C. DUNCAN, MD
R. K. WINKELMANN, MD, PHD
Rochester, Minn

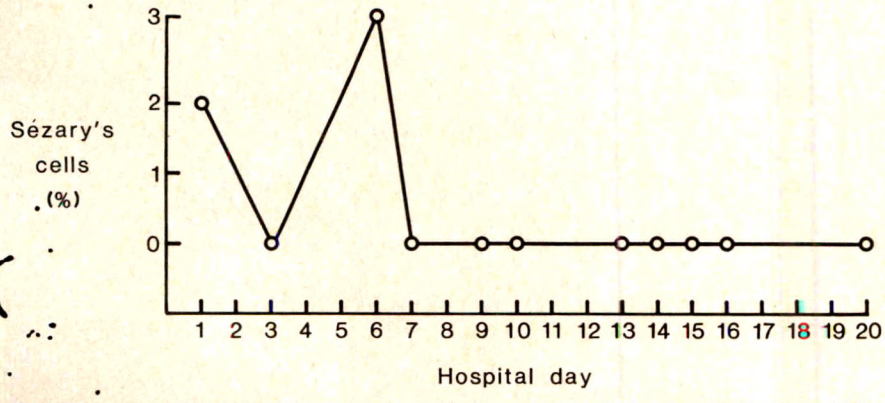

Serial counts of Sézary's cells shows variable percentage during hospitalization of 72-year-old woman with 20-year history of psoriasis vulgaris.

1. Holdaway DR, Winkelmann RK: Histopathology of Sezary syndrome. *Mayo Clin Proc* 49:541-547, 1974.
2. Flaxman BA, Zelazny G, Van Scott EJ: Nonspecificity of characteristic cells in mycosis fungoides. *Arch Dermatol* 104:141-147, 1971.
3. Winkelmann RK, Perry HO, Muller SA, et al: The pre-Sezary erythroderma syndrome. *Mayo Clin Proc* 49:588-589, 1974.

Studies on Betamethasone Valerate vs Fluocinonide

To the Editor.—We have read the article in the ARCHIVES by Munro et al (113:599-601, 1977) with interest.

It is a little difficult to understand how a white cream, 0.05% fluocinonide (Lidex/Metosyn), and a vaseline-like ointment, 0.1% betamethasone valerate (Valisone/Betnovate) could be self-administered and yet not be differentiated by the patients. Thus the descriptor "double-blind" is perhaps not entirely appropriate for the patients, even though an attempt was made to blind the investigators.

Given the difference in these results from the several other trials quoted, we would have liked to see not only the "approximation" assessments reported (patient/physician preferences), but also the clearly more numerous clinical observations that were recorded, particularly because the patients were not blinded. While preferences may well have been shown elsewhere to be generally representative of clinical observations, we have nothing to show us that such a correlation indeed existed in this study.

Somewhat unusually, the authors have chosen to compare one drug formulated as an ointment with another formulated as a cream, even a cream with the special properties of fatty alcohol propylene glycol (FAPG). The physical nature of an

ointment provides the occlusion that is well known to enhance efficacy. Similarly, vasoconstriction tests, which have long been reasonably reliable forecasters of clinical efficacy, show the augmenting effect of more occlusive bases.

That fluocinonide is not available in the United Kingdom as an ointment, and that the betamethasone valerate ointment formulation used in this study is not available in the United States is unfortunate. Perhaps to compare betamethasone valerate ointment with fluocinonide ointment—a comparison we welcome at any time—would be more useful.

D. STEPHEN ROBINS, MD
Palo Alto, Calif

Suppression of Corticosteroid-Induced Atrophy and Telangiectasia With Vitamin A

To the Editor.—Side effects of prolonged use of topical corticosteroids include atrophy, striae, telangiectasia, and linear ulcerations. A rat bioassay model has been developed to evaluate these side effects and similar work has been done by Rist et al (unpublished data, 1977). Vitamin A is known to suppress the inhibitory effects of glucocorticoids on wound repair.[2,3] With these facts, we undertook a blind study to see if topical vitamin A would suppress the atrophy and telangiectasia associated with long-term topical corticosteroids.

Forty-one-week-old Sprague Dawley rats were separated into four groups, each with a 3-sq cm shaved area on their back. Group one was treated with 0.1 gm of 0.1% halcinonide daily. Group two was treated with 0.1 gm of 0.1% halcinonide plus 7,500 IU of vitamin A ester per milligram of anhydrous lanolin base daily. Group three was treated with 0.1% halcinonide cream daily plus 500 IU of vitamin A intraperitoneally every third day, and group four was treated with a control cream base only. The rats were weighed weekly and after 30 days were killed and skin thickness and telangiectasia were measured.

We found that vitamin A topically or intraperitoneally had no effect on preventing the expected decreased weight gain (Table); indeed, it may have enhanced this systemic effect of the steroid. This effect will be discussed more fully in a subsequent report. However, vitamin A topically did somewhat suppress the atrophy produced by the topical steroid alone, and this was significant to a P value (Student's t test) greater than .001. In addition, it did prevent appearance of telangiectasia. Vitamin A intraperitoneally had no effect.

This preliminary finding could be used to lower the undesirable side effects of otherwise therapeutically potent corticosteroid. We are continuing this line of research and further details will be presented in a future paper.

TOVIO RIST, MD
Knoxville, Tenn
MAJ CHARLES W. RUGGLES, MC, USAF
MAJ MICHAEL E. RYAN, MC, USAF
LT COL RAYMOND L. GARCIA, MC, USAF
CAPT DONALD OSBORNE, BSC, USAF
San Antonio, Tex

Nonproprietary Names and Trademarks of Drugs

Halcinonide—*Halog.*
Vitamin A—*Aquasol A, Derm-A Caps, Solu-Caps, Super Vitamin A, Vitamin A Capsules.*

1. Smith JG Jr, Wehr RF, Chalker DK: Corticosteroid induced cutaneous atrophy and telangiectasia. *Arch Dermatol* 112:1115-1117, 1976.
2. Hunt TR, Ehrlich HP, Garcia JA, et al: Effect of vitamin A on reversing the inhibitory effect of cortisone on healing of open wounds in animals and man. *Ann Surg* 170:633-640, 1970.
3. Ehrlich HP, Hunk TK: Effect of cortisone and vitamin A on wound healing. *Ann Surg* 167:324-328, 1968.

Comparison of Four Groups of Rats in Respect to Weight Gain, Skin Atrophy, and Telangiectasia

	Wt Gain, % Over Initial	Skin Thickness, 10^{-2} in (Average of Ten Rats)	Telangiectasia, 0-3+ (Average of Ten Rats)
Control	145	9.1	0
0.1% Halcinonide	96	4.4*	2-3
Halcinonide and topical vitamin A	67	5.9*	0
Halcinonide and intraperitoneal vitamin A	57	4.5	2-3

*The P value of .001 between halcinonide and halcinonide vitamin A is based on calculations involving the skin thickness of each individual rat in the two groups.

Sweet's Disease

To the Editor.—Acute febrile dermatosis was first described by Sweet in 1964.[1] Prominent features of the disease are: fever; leukocytosis; raised, painful, erythematous plaques on the face, neck, and limbs; and a dense polymorphonuclear leukocytic infiltrate. This case is presented because of the rare occurrence of the syndrome in a man.

Report of a Case.—A 25-year-old man was seen in the Cook County emergency room with a two-day history of high fever, headache, nausea, and abdominal discomfort, followed by the sudden appearance of painful plaque-like lesions involving the medial aspect of the right thigh. The patient stated that he had experienced five similar episodes every two to three months in the last two years. The skin lesions always appeared in a band 10- to 15-cm wide on the inner aspect of his right thigh, extending from the groin to the knee. He had never received medical treatment for his complaints. The patient was otherwise in excellent health. He had taken no medication either prior to or during his illness. The patient had lived in the United States for one year.

On physical examination the patient had an oral temperature of 39.1 C. General physical examination revealed no abnormalities. No regional lymphadenopathy was present. A widespread eruption of painful, erythematous, raised, sharply demarcated, warm nodules and plaques that ranged in size from 0.5- to 10-cm was present on the medial aspect of the right thigh. The hematocrit was 46%, and the WBC count was 17,000/cu mm with 89% polymorphonuclear neutrophils. The results of urinalysis, and the BUN, glucose, and electrolyte levels were normal. The ESR was moderately elevated. Histological examination showed an intact epidermis. Throughout all levels of the epidermis, perivascular, mononuclear, and neutrophilic inflammatory cells, in varying proportions, were loosely arranged. The Gram stain was negative for organisms.

The patient's fever subsided in two days. No systemic therapy was instituted. The cutaneous lesions became larger and darker during a two-week period, then gradually diminished. Six weeks after the onset of symptoms, the lesions had resolved completely.

Comment.—This case is unusual in that it is the fifth report of Sweet's disease occurring in a man. The disease predominantly affects middle-aged women who have had preceding upper respiratory infections. Approximately one third of reported patients have recurrences.[2] The cause of acute febrile neutrophilic dermatosis is undetermined, although the condition may be a hypersensitive reaction to nonspecific infective agents. Systemic steroids control the reaction.

The four previous reports of Sweet's disease in men have described variations from the classical presentation in women. White blood cell counts of men have been reported to be less than 13,000/cu mm.[3-6] Two reports have described mixed lymphocytes and neutrophils histologically,[3,4] in contrast with the dense neutrophilic dermal infiltrate seen typically. Interestingly, one man had a testicular embryonic cell carcinoma.[3] A metastatic adenocarcinoma was reported in another man.[5]

LOIS Y. MATSUOKA, MD
WILLIAM STORINO, MD
Chicago

1. Sweet RD: An acute febrile neutrophilic dermatosis. *Br J Dermatol* 76:349-356, 1964.
2. Kopf AW, Andrade R: *Yearbook of Dermatology*. Chicago, Yearbook Medical Publishers, 1970, p 304.
3. Shapiro L, Baraf C, Richheimer L: Sweet's syndrome (acute febrile neutrophilic dermatosis). *Arch Dermatol* 103:81-84, 1971.
4. Goldman G, Moschella S: Acute febrile neutrophilic dermatosis (Sweet's syndrome). *Arch Dermatol* 103:654-660, 1971.
5. Greer K, Pruitt J, Bishop G: Acute febrile neutrophilic dermatosis (Sweet syndrome). *Arch Dermatol* 111:1461-1463, 1975.
6. Petrozzi J, Warthan T: Sweet's syndrome: Unique local response to streptococcal antigen. *Cutis* 17:267-272, 1976.

Cutis Punctata Linearis Colli

To the Editor.—In the interesting exchange of letters between Dr W. D. Jacoby and Drs T. Butterworth and W. C. Johnson (*Arch Dermatol* 112:1034-1035, 1976) concerning identity or differences of cutis punctata linearis colli and juxtaclavicular beaded lines, all three authors agree that these phenomena are based on a common variant of the skin in this area. All of them, and also Even-Paz and Sagher,[1] who said in 1963 that this feature of normal skin surface seems to have escaped attention in dermatological texts, have overlooked the very clear description in the rarely failing source of dermato-anatomical information, Felix Pinkus' "Anatomie der Haut."[2]

After discussing direction of hairs in the form of hair streams and basic arrangement of hairs in groups of three or more in parallel lines at right angles to the hair streams, F. Pinkus reproduces a clear photograph of linear arrangement of hair groups in the juxtaclavicular area (Fig 211 on p 241). His discussion of "Querordnung der Haargruppen" (transverse ordering of hair groups) reads as follows in free translation (pp 242-243):

The hair groups of the human body occur at definite distances. On the surface, we see only the free hair. Below the surface, an astonishing quantity of glands, muscles, and connective tissue bearing blood vessels and nerves belong to each small hair. In certain places, one can recognize a systematic linear ordering of the hair groups. The arrangement usually is vertical to the direction of the hair streams and follows rather closely the direction of visible skin folds. This lateral (transverse) ordering is illustrated in the diagram (Fig 212). It is most distinct on the anterior neck and chest. Here, the orderly arrangement forms circles around the neck, which descend slightly from the lateral portions toward front and nape. The lines descend from the shoulders medially to the sternal midline, surround the mammae and form circumareolar rings on the female breast. The lines that descend from the outer parts of the shoulders form rings around the upper part of the arms. In the lower sternal area, the lines cross by descending at the lower chest toward the midline, where they meet those of the other side in an open angle. They run transversely across the upper abdomen. Lateral linear arrangement of hair groups is seen also on posterior shoulders and back where they descend from both sides toward the midline, and there are horizontal lines in lumbar and sacral areas. In all other areas of the body, that is on the face, lower abdomen, portions of the back, and on the extremities, the hair groups are distributed at smaller or larger distances diffusely, without obvious linear arrangement.

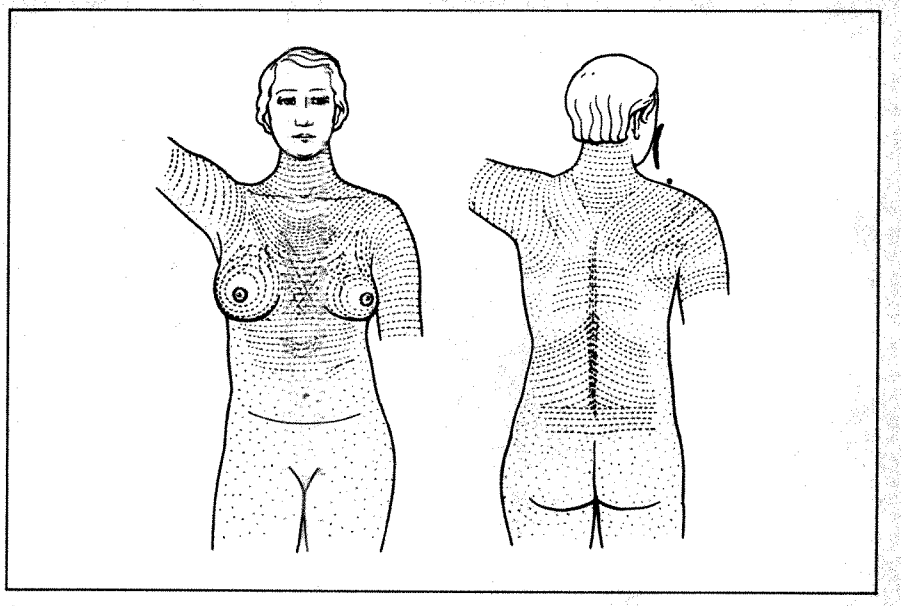

Arrangement of hair groups in transverse lines. Areas of indifferent arrangement are stippled. Visible linear ordering is indicated by interrupted lines. Diagram was constructed from observation of several subjects. (Reproduction of Fig 212 of Pinkus, in Jadassohn.[2])

This detailed description and the diagram reproduced in the Figure makes it clear that juxtaclavicular lines of pilosebaceous complexes are a normal and universal feature of human skin. Whether the lines appear "beaded" to the naked eye depends on the size of the subsurface components, especially the sebaceous glands. I agree that these data should be included in future texts, and I suggest that any investigator of the subject may well base his observations on the 50-year-old first description.

HERMANN PINKUS, MD
Monroe, Mich

1. Even-Paz Z, Sagher F: Cutis punctata linearis colli: Stippled skin. *Dermatologica* 126:1-12, 1963.
2. Pinkus F: Anatomie der haut, in Jadassohn J (ed): *Handbuch der Haut-und Geschlechtskrankheiten*. Berlin, Julius Springer, 1927, vol 1, pp 1-378.

In Reply.—Although I had not been aware of Dr F. Pinkus' observations in his "Anatomie der Haut," my knowledge of disseminate and recurrent infundibulo-folliculitis, and of cutis punctata linearis colli has taught me the linear distribution of the pilosebaceous structures in the regions of the clavicles. In fact, I thought that this anatomical arrangement was common knowledge and that the discoverer had been lost in antiquity.

Dr Johnson and I made no pretense that we were making an original observation in regard to the distribution of the pilosebaceous structures. We were intrigued, however, by the occurrence of linear papules in the vicinity of the clavicles. We knew that the linear arrangement was dependent on the distribution of the follicular structures. But why does a quarter of the population show such papules, and why are they more common in blacks than in whites?

Why are the papules most numerous in the age-group of 11- to 40-year-olds? Unfortunately, we could not provide the answers, and we had to conclude that the papules probably represent an anatomical variant rather than a disease process.

We have made no claim to originality in our observations. If the beaded lines are anatomical differences, then they should be mentioned in textbooks of dermatology and anatomy. Let them become a part of our general knowledge irrespective of who described the linear arrangement of the follicular structures and who stressed a particular anatomical variant.

THOMAS BUTTERWORTH, MD
Reading, Pa

Including All Possible Sources

To the Editor.—In your February 1977 issue of the ARCHIVES (113:235), the late Dr W. Reed mentioned that there was no literature on sclerodermoid porphyria cutanea tarda. It is, alas, a fact that English or American papers very seldom contain non-English references. Nevertheless, I would like to mention a paper published in 1967, in the *Archives Belges de Dermatologie.* The title of the paper was "La porphyrie sclérodermiforme," and the authors mentioned 12 references, including even a reference of Zimmerman, published in the April 1955 ARCHIVES.

The statement of Dr Reed is a confirmation of the tendency of English-speaking writers to neglect the continental works. While it is evident that English is "the" scientific dominant language, I would like to remind your readers that other sources of bibliography still exist. Despite this frustrating situation, I can assure you that I have no intention of cutting my subscription to the ARCHIVES.

J. DELESCLUSE, MD
Brussels, Belgium

Stevens-Johnson Syndrome

To the Editor.—With regards to the brief report, "Permanent Anonychia After Stevens-Johnson Syndrome," in the July ARCHIVES (113:970, 1977), the authors state that nothing has been written about nail changes in the Stevens-Johnson syndrome. This is not the case. In 1946 Wentz and Seiple,[1] in a report on the Stevens-Johnson syndrome, called attention to the fact that one of their cases had a complication of sloughing of all the fingernails and toenails, with eventual regrowth. In 1951 Ashby and Lazar,[2] in a review of 81 cases of Stevens-Johnson syndrome, called attention to the fact that paronychia, as well as shedding of the nails, may be seen in cases of the Stevens-Johnson syndrome, but that they are unusual. Finally, in 1966, Coursin[3] reviewed the Stevens-Johnson syndrome and called attention to the fact that paronychia and shedding of the nails may be observed in Stevens-Johnson syndrome.

We agree with the authors that nail changes are unusual complications of Stevens-Johnson syndrome and we are unaware of permanent anonychia having been reported after the Stevens-Johnson syndrome. However, shedding of the nails, as well as paronychial involvement, have been previously reported.

JOSEPH J. CHANDA, MD
Ann Arbor, Mich
JEFFREY P. CALLEN, MD
Louisville

1. Wentz HS, Seiple HH: Stevens-Johnson syndrome, a variation of erythema multiforme exudativum (Hebra): A report of two cases. *Ann Intern Med* 26:277-283, 1947.
2. Ashby DW, Lazar T: Erythema multiforme exudativum major (Stevens-Johnson syndrome). *Lancet* 1:1091-1095, 1951.
3. Coursin DB: Stevens-Johnson syndrome: Nonspecific parasensitivity reaction? *JAMA* 198:113-116, 1966.

Pedunculated Malignant Melanoma

To the Editor.—The June 1975 issue of the ARCHIVES (111:755-756, 1975) contains a report entitled "Pedunculated Malignant Melanoma." The authors describe one case and report on three others; they state: "To our knowledge these are the only ones reported in the English literature." We feel that this comment requires further clarification.

In 1970, G. L. Beardmore et al reported 105 cases of fatal malignant melanoma; 36 (35%) of these were pedunculated ones.[1] In our own series, during the years 1955 to 1976, we examined 170 patients and found ten with pedunculated melanomas. Seven of these patients are alive. Five of them (two with metastases) have survived more than five years and two have survived almost two years. One patient died of an intermittent disease and two others of metastatic melanoma. Only in one of these patients (with more than five-years-survival) had the tumor infiltrated the reticular layer of the dermis (Clark's level IV) and the dermis adjacent to the pedicle of the tumor. In all of the other patients, the malignant cells were confined to the pedunculated mass without infiltration of the reticular layer of the dermis at the base of the pedicle. The depth of these tumors, measured according to Breslow,[2] ranged from 2½ mm to 1½ cm. One tumor was also papillary (Figure). Beardmore et al state that the pedunculated melanoma appears to be of more malignant nature than other morphological forms.[2] This cannot be the implication in our group since five patients have survived more than five years.

We would be pleased if other authors would report on their findings. A larger number of cases are

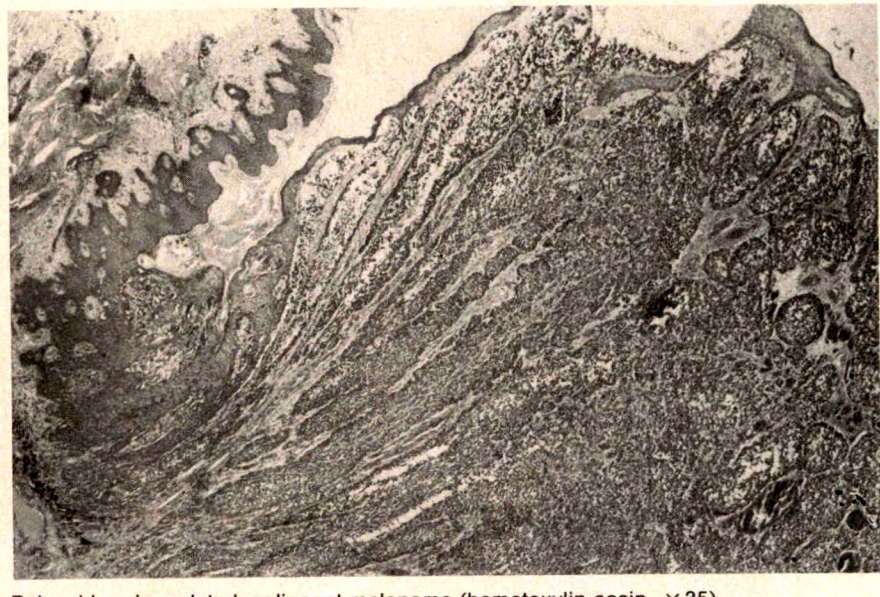

Polypoid pedunculated malignant melanoma (hematoxylin-eosin, ×35).

required in order to draw more specific conclusions on the prognostic value of the morphological form of melanomas. Certainly the pedunculated melanoma is not as rare as Niven and Lubin have indicated, and its prognostic importance should be elucidated.

RAPHAEL SHAFIR, MD
RAFAELE DAVID, MD
SAM SLUTZKI, MB, BS
Tel-Aviv, Israel

1. Beardmore GL, Quinn RL, Little JH: Malignant melanoma in queensland: Pathology of 105 fatal cutaneous melanomas. *Pathology* 2:277-286, 1970.

2. Breslow A: Thickness, cross-sectional areas and depth of invasion in the prognosis of cutaneous melanoma. *Ann Surg* 172:902-908, 1970.

Role of Race in Scabies Infestation

To the Editor.—I would like to think few, experienced dermatologists would argue that there are some obvious differences between the reactivity of heavily pigmented skin, ie, black, and mildly pigmented skin, ie, white, to identical or similar stimuli. The prevalence of keloids or follicular eruptions in blacks and the overwhelming predominance of rosacea or actinic keratoses in whites are well-known examples of the phenomenon to which I refer.

In this regard, a review of my records, which covered a continuous 18-month period that ended March 1977, reveals that of 37 patients who had scabies (confirmed by microscopic identification of the mite and/or eggs or by a salutary response to antiscabietic therapy), 31 were white, one was black, and the remainder represented other racial groups. This data are made more noteworthy by the fact that the patient population was 48% black, 36% white, and the rest comprised other races; moreover, the socioeconomic status of all the patients was comparable and clearly middle class.

These findings are not without support. Alexander Romeo, MD (oral communication, May 1977) recalled that during an outbreak of scabies at a hospital located in a predominantly black area of Washington, DC, almost all of the patients who had the condition were white. Harold R. Minus, MD (oral communication, May 1977) also stated that very few cases of scabies were seen at the Howard University Hospital Dermatology Clinic during a period when scabies was practically rampant in the Washington, DC area.

All these findings and observations would suggest that under similar environmental circumstances, whites may be more susceptible to scabies infestations than blacks. Why such a discrepancy might exist is difficult to explain, but differences in stratum corneum density or pigmentation may be important.

I would be interested in knowing the experience of readers of the ARCHIVES with regard to race and scabies.

A. MELVIN ALEXANDER, MD
Silver Spring, Md

Pemphigus Vegetans of Hallopeau

To the Editor.—The article in the ARCHIVES (113:942-945, 1977) titled "Pemphigus Vegetans of Hallopeau," by Nelson et al was of great interest to me for three reasons. First is that classical examples of this condition are rare but readily recognizable; second is that the controversy as to its nosology has continued since Hallopeau[1] first described the disease in 1869 and illustrated a case in the *International Atlas of Rare Diseases of the Skin*[2]; third pyodermite végétante has been associated with a particular subacute or "benign" type of ulcerative colitis that may not be clinically obvious or cause the patient to complain and that may only be determined by direct questioning of the patient on his bowel habits or by routine proctoscopy, double contrast barium enema, and rectal biopsy.

The detection of this type of ulcerative colitis is important because although constitutional effects may be quite minimal, one of the patients described by me in 1966[3,4] had a carcinoma of the colon develop 20 years after the appearance of the vegetating skin lesion that had become manifest almost simultaneously with watery stools four times a day. The liability to development of a carcinoma of the colon is a well-recognized serious complication of chronic ulcerative colitis and may determine the surgical approach to its treatment. Moreover, in another patient, a partial colectomy for the chronic ulcerative colitis, leaving the rectum, was followed by an improvement of the skin lesions at first but subsequently, a severe relapse occurred; the rectal stump was then removed and the skin healed and remained so during a seven year follow-up. A somewhat similar history may be obtained in the other dermatosis associated with ulcerative colitis, pyoderma gangrenosum, when complete healing of the skin may only occur after total removal of the diseased large bowel and rectum.

The main purpose of this letter is to recall that pyodermite végétante is a dermatosis causally associated with ulcerative colitis. Perhaps the authors of the article might have placed more emphasis on this. Of course, this association has been previously noted by other authors, for example by Fernet in 1912[5], and by Goldsmith in 1941.[6]

Personally, I do not believe that pyodermite végétante forms part of the spectrum of pemphigus vulgaris and should be used as a synonym for pemphigus vegetans. As Nelson et al repeat, Hallopeau himself agreed that the disease, which he had described, was a variant of pemphigus vulgaris (Neumann), but one may recall the two contemporary American dermatologists, Pusey in 1906[7] and Fordyce and Gottheil,[8] also in 1906, who believed that Hallopeau had too readily accepted that the disease, which he had named, was a variant of pemphigus vulgaris.

Briefly, in my view, neither the morphology, the histopathology, nor the exfoliative cytology (Zanck test) is compatible with pemphigus vulgaris or pemphigus vegetans. Our immunofluorescence techniques were probably not as refined in 1966, but in the two cases under investigation, intercellular antibodies were not demonstrated by the indirect method, using the patients' skin as substrate. The histopathology detailed in my articles[3,4] indicated that the primary changes occur in the papillary bodies and that the epidermis may show cells that are dissociated but not truly acantholytic. The increase in size of the rete pegs is a response to the underlying inflammatory and cellular infiltrate that includes a striking number of eosinophils, indicative of the immunologic component of the pathologic condition. In my opinion, the eosinophilic "abscess" does not originate in the acantholytic epidermis but represents epithelial enclosure and elimination.

In addition, occasional acantholytic cells may be a feature of other dermatoses, eg, dermatitis herpetiformis, and it would not be entirely unexpected to find circulating antibodies to intercellular substance of the epidermis where there has been prolonged inflammation and damage to the epidermis.

Clinically, besides the vegetating epidermis, which may be studded with pustules, there are vesicles recalling

dermatitis herpetiformis and also bullae with thick necrotic roofs that do not peel away and do not show the ragged epidermal fringe of pemphigus vulgaris. The mucous membrane signs in the mouth and conjunctivas are particularly characteristic of pyodermite végétante, showing a slightly granular thickening, necrotic points, and "snail track" areas of necrosis quite unlike the erosions of pemphigus vulgaris.

LOUIS FORMAN, MD
London

1. Hallopeau H: Sur une nouvelle forme de dermatite pustuleuse chronique en foyers à progression excentrique, in: *Congres International de Dermatologic Syphilis Comptes Rendus*. Paris, Masson, 1890, p 344.
2. Hallopeau H: *International Atlas of Rare Skin Diseases, 1889-1897*, Hamburg, Leopold Voss.
3. Forman L: Two cases of pyodermite végétante (Hallopeau): An eosinophilic pustular and vegetating dermatitis with conjunctival, oral and colonic involvement. *Pro Roy Soc Med* 58:244-249, 1965.
4. Forman L: The skin and the colon: The Prosser White oration delivered July 10th, 1965. *St John's Hosp Derm Soc* (new series) 52(2):139-154, 1966.
5. Fernet G: Dermatitis pustulosa vegetans recurrens. *J Cutan Dis* 30:517-523, 1912.
6. Goldsmith WN: A case of pyodermite végétante (Hallopeau). *Br J Dermatol* 53:299-318, 1941.
7. Pusey WA: Vegetating dermatoses: with report of two cases. *J Cutan Dis* 24:543-555, 1906.
8. Fordyce JA, Gottheil WS: Dermatitis vegetans in its relation to DH. *J Cutan Dis* 24:543-555, 1906.

In Reply.—We certainly appreciate Dr Forman's interest in our article and his continuing efforts to unravel a controversy that has existed for nearly a century.

The historical background for this discussion has been amply covered, both in our article and Dr Forman's letter. That a difference exists between pemphigus vegetans of Neumann and pemphigus vegetans of Hallopeau is certain. Pemphigus vegetans of Hallopeau has a benign course, a lack of bullae, a preference for flexural areas, and a sequence of pustules followed by vegetations, whereas pemphigus vegetans of Neumann usually begins and ends as pemphigus vulgaris, from which it differs only in that many denuded areas heal with papillomatous formations. Its prognosis is similar to pemphigus vulgaris. The controversy boils down to whether pemphigus vegetans of Hallopeau and pyodermite végétante (pyoderma vegetans) are separate diseases. That Hallopeau's name is often associated with both entities certainly doesn't help matters.

Dr Forman notes the association of pyodermite végétante with bowel disease. Our patient had no symptoms referable to his bowel, and upper gastrointestinal roentgenographs and results of proctoscopic examination were normal. Barium enema films showed only diverticulosis without evidence of diverticulitis.

Dr Forman also correctly notes that acantholysis is a nonspecific histological finding and should not be a differentiating point. Therefore, we have proposed that immunofluorescence studies should be the deciding factor in separating pemphigus vegetans of Hallopeau (a true type of pemphigus) from pyodermite végétante, if indeed a difference exists. Such studies on our patient showed direct and indirect immunofluorescence studies typical of pemphigus.

Since publication of our article, we have had an opportunity to study another patient with clinical findings more typical of pyodermite végétante; direct and indirect immunofluorescence studies were negative (unpublished data, 1976).

Clearly, immunofluorescence studies are the key to this fascinating controversy. We hope the interest of Dr Forman and other fine investigators continues and that when examples of this rare entity are encountered, they are fully studied and reported.

CHRISTOPHER G. NELSON, MD
St Petersburg, Fla

Depigmentation of Normal Skin to Treat Patients With Melanomas

To the Editor.—The letter to the editor by Paslin in the September 1977 issue of the ARCHIVES (p 1302) shows that he missed completely the point of our editorial in the April issue (p 421). Dr Paslin is correct when he states that it has been known for a long time that a variety of phenols and catechols are toxic to melanoma cells and that so far no one has been able to make use of this direct cytotoxicity to treat animals or patients with melanomas. In our editorial, we suggested that the depigmenting agents be used to destroy normal pigment cells in the skin to evoke an immunologic response that in turn would destroy or suppress melanoma cells that were left in the body after the primary lesion was excised. We did not suggest that the agents be used for a direct cytotoxic effect on melanoma cells.

AARON B. LERNER, MD
JAMES J. NORDLUND, MD
New Haven, Conn

Chlor-Trimeton® 12mg.
brand of chlorpheniramine maleate, USP
Repetabs® Tablets, brand of repeat-action tablets

Clinical Considerations:
INDICATIONS

Based on a review of this drug by the National Academy of Sciences—National Research Council and/or other information, FDA has classified the indications for CHLOR-TRIMETON REPETABS Tablets as follows: "Probably" effective: For perennial and seasonal allergic rhinitis; vasomotor rhinitis; allergic conjunctivitis due to inhalant allergens and foods; mild, uncomplicated allergic skin manifestations of urticaria and angioedema; amelioration of allergic reactions to blood or plasma; dermatographism; as therapy for anaphylactic reactions adjunctive to epinephrine and other standard measures after the acute manifestations have been controlled.
Final classification of the less-than-effective indications requires further investigation.

CONTRAINDICATIONS Use in Newborn or Premature Infants: This drug should not be used in newborn or premature infants.
Use in Nursing Mothers: Because of the higher risk of antihistamines for infants generally and for newborns and prematures in particular, antihistamine therapy is contraindicated in nursing mothers.
Use in Lower Respiratory Disease: Antihistamines should not be used to treat lower respiratory tract symptoms, including asthma.
Antihistamines are also contraindicated in the following conditions: hypersensitivity to chlorpheniramine maleate and other antihistamines of similar chemical structure; monoamine oxidase inhibitor therapy.
WARNINGS Antihistamines should be used with considerable caution in patients with: narrow angle glaucoma; stenosing peptic ulcer; pyloroduodenal obstruction; symptomatic prostatic hypertrophy; bladder neck obstruction.
Use in Children: In infants and children especially, antihistamines in overdosage may cause hallucinations, convulsions or death.
As in adults, antihistamines may diminish mental alertness in children. In the young child particularly, they may produce excitation.
Use in Pregnancy: Experience with this drug in pregnant women is inadequate to determine whether there exists a potential for harm to the developing fetus.
Use with CNS Depressants: Chlorpheniramine maleate has additive effects with alcohol and other CNS depressants (hypnotics, sedatives, tranquilizers, etc.).
Use in Activities Requiring Mental Alertness: Patients should be warned about engaging in activities requiring mental alertness, such as driving a car or operating appliances, machinery, etc.
Use in The Elderly (approximately 60 years or older): Antihistamines are more likely to cause dizziness, sedation, and hypotension in elderly patients.
PRECAUTIONS Chlorpheniramine maleate has an atropine-like action and therefore should be used with caution in patients with: a history of bronchial asthma; increased intraocular pressure; hyperthyroidism; cardiovascular disease; hypertension.
ADVERSE REACTIONS Slight to moderate drowsiness occurs relatively infrequently with chlorpheniramine maleate. Other possible side effects common to antihistamines in general include:
General: urticaria, drug rash, anaphylactic shock, photosensitivity, excessive perspiration, chills, dryness of mouth, nose, and throat.
Cardiovascular System: hypotension, headache, palpitations, tachycardia, extrasystoles.
Hematologic System: hemolytic anemia, thrombocytopenia, agranulocytosis.
Nervous System: sedation, dizziness, disturbed coordination, fatigue, confusion, restlessness, excitation, nervousness, tremor, irritability, insomnia, euphoria, paresthesias, blurred vision, diplopia, vertigo, tinnitus, acute labyrinthitis, hysteria, neuritis, convulsions.
Gastrointestinal System: epigastric distress, anorexia, nausea, vomiting, diarrhea, constipation.
Genitourinary System: urinary frequency, difficult urination, urinary retention, early menses.
Respiratory System: thickening of bronchial secretions, tightness of chest and wheezing, nasal stuffiness.
11046240 February 1977
For more complete details, consult package insert or Schering literature available from your Schering Representative or Professional Services Department, Schering Corporation, Kenilworth, New Jersey 07033.

Purity & Quality*

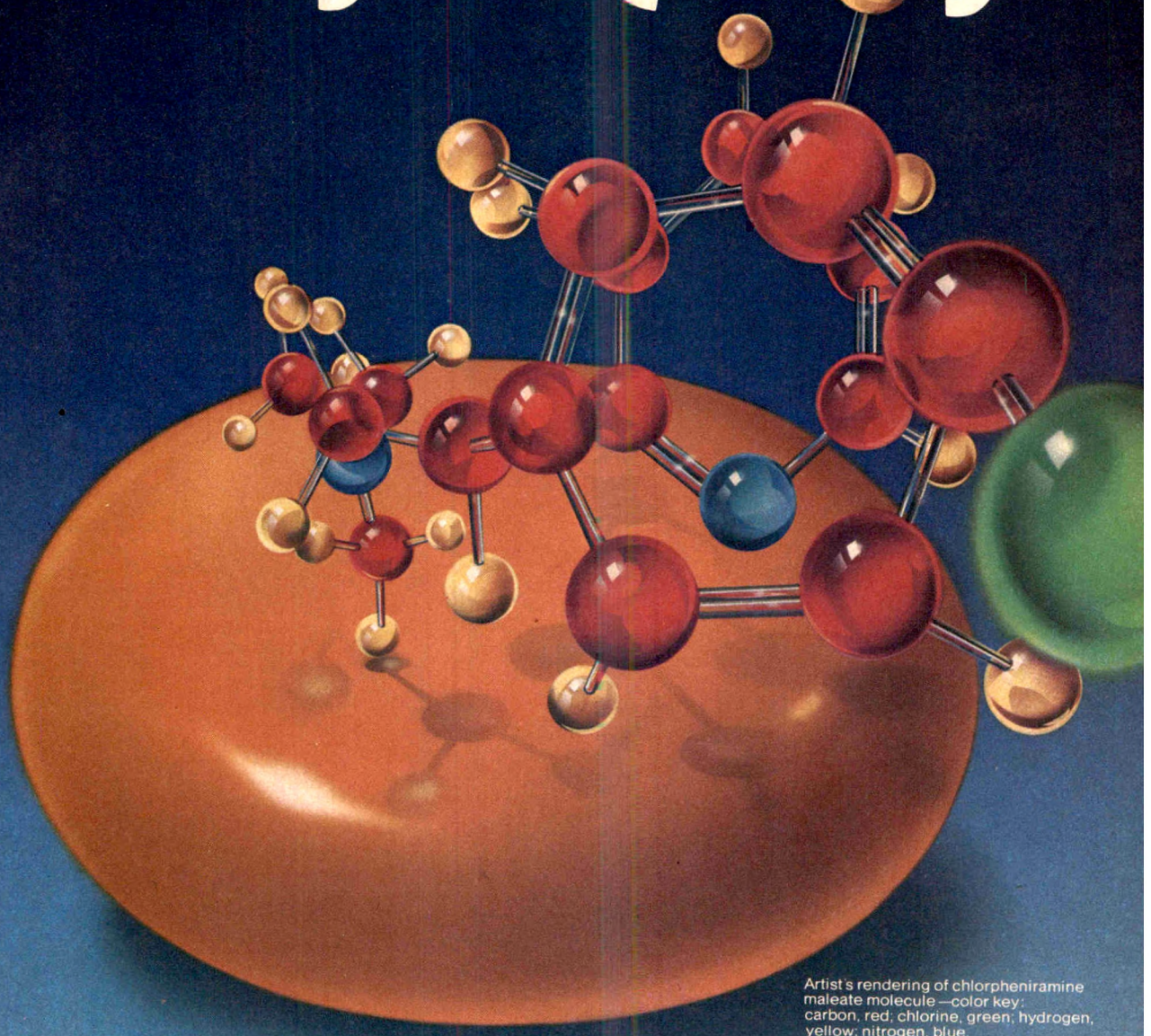

Artist's rendering of chlorpheniramine maleate molecule—color key: carbon, red; chlorine, green; hydrogen, yellow; nitrogen, blue.

Chlor-Trimeton® 12mg.

brand of
chlorpheniramine maleate, USP

Repetabs® Tablets, brand of repeat-action tablets

Available on prescription only.

An original Schering research discovery

*This drug has been evaluated as "probably" effective.
See Clinical Considerations section on opposite page.

COPYRIGHT © 1978, SCHERING CORPORATION. ALL RIGHTS RESERVED

SLS-177

Get down to the level of normal skin.

Remove hyperkeratotic build up safely and effectively.

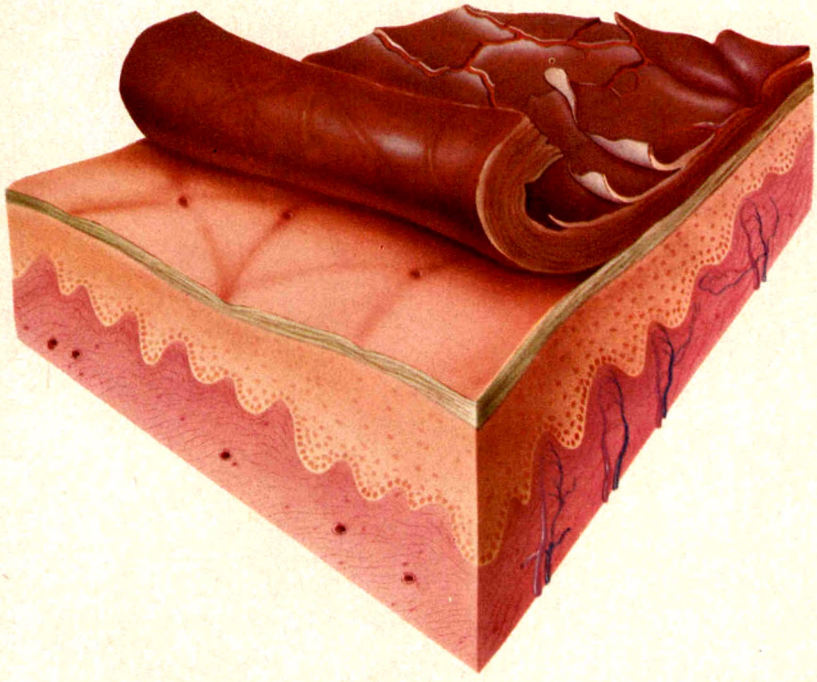

Keralyt® Gel is clear, and easy to apply. Keralyt Gel's mechanism of action is believed to be its ability to dissolve the intracellular material that binds the cells of the stratum corneum, thus aiding the simple, safe removal of excessive hyperkeratotic skin.

Keralyt's keratolytic action is an important preliminary to other topical agents. After the hyperkeratotic barrier is removed, tar, steroids, and other therapy can function with less impediment.

Keralyt® GEL

NDC-0072-6500-01

Rx CAUTION: FEDERAL LAW PROHIBITS DISPENSING WITHOUT PRESCRIPTION.

CONTENTS: 6% salicylic acid in a gel containing propylene glycol (60%), ethyl alcohol (19.4%), hydroxypropyl cellulose and water.

ACTION AND USES:
For Dermatological Use: Keralyt is a topical aid in the removal of excessive keratin in hyperkeratotic skin disorders, including the various ichthyoses (vulgaris, sex-linked and lamellar), keratosis palmaris and plantaris, keratosis pilaris, pityriasis rubra pilaris, psoriasis (including body, scalp, and palms and soles). Keralyt has been reported as helpful as adjunctive therapy for fungal infections.

For Podiatric Use: Keralyt is a topical aid in the removal of excessive keratin in dorsal and plantar hyperkeratotic lesions. Keralyt has been reported as helpful as adjunctive therapy for verruca plantaris.

DIRECTIONS FOR USE: The preferable method of use is to apply thoroughly to the affected area and place under occlusion at night. The skin should be hydrated for at least five minutes prior to application. The medication is washed off in the morning, and if excessive drying and/or irritation is observed, a bland cream or lotion may be applied. Once clearing is apparent, the occasional use of Keralyt will usually maintain the remission. In those areas where occlusion is difficult or impossible, application may be made more frequently, and hydration by wet packs or baths prior to application apparently enhances the effect. Unless hands are being treated, rinse hands thoroughly following application.

CONTRAINDICATIONS: Not to be used in patients known to be sensitive to any ingredient of Keralyt.

PRECAUTIONS: In view of the salicylic acid content, use in children under 12 years of age should be limited to no more than one tube (1 oz.) in 24 hours. Avoid contact with eyes and mucous membranes. For external use only. Keep this and all medications out of reach of children.

HOW SUPPLIED: Plastic tubes 1 oz. (24.8 gm.)

Keralyt® GEL

6% salicylic acid in a gel containing propylene glycol (60%), ethyl alcohol (19.4%), hydroxypropyl cellulose and water.
Please see full prescribing information.

WESTWOOD
PHARMACEUTICALS INC.
Buffalo, New York 14213

©1977, W.P. Inc.

Available only on your prescription.

Faculty Position.—A faculty position is open in the Department of Medicine, University of Washington, School of Medicine, Seattle, for an associate professor. Responsibilities include patient care, teaching, and research. Applicants must be full-time dermatologists with international reputation in the sphere of immunology and academic qualifications for tenured rank. If interested, contact George F. Odland, MD, Division of Dermatology, RM-14, Department of Medicine, University of Washington, School of Medicine, Seattle, WA 98195; telephone, (206) 543-5290.

Faculty Position.—A faculty position is open in the Department of Medicine, University of Washington, School of Medicine, Seattle, for an assistant professor. Responsibilities include patient care, teaching, and research. A dermatologist is wanted with research background in biochemistry to direct clinical and laboratory programs at an affiliated university hospital. Preference will be given to an individual board-certified in internal medicine. If interested contact George F. Odland, MD, Division of Dermatology, RM-14, Department of Medicine, University of Washington, School of Medicine, Seattle, WA 98195; telephone, (206) 543-5290.

Faculty Position.—A faculty position is open in the Department of Medicine, University of Washington, School of Medicine, Seattle, for an assistant professor. Responsibilities include patient care, teaching, and research. Applicants must be Dermatologists with experience in clinical and biophysical research as well as undergraduate teaching. Preference will be given to an individual who is board-certified in internal medicine. If interested contact George F. Odland, MD, Division of Dermatology, RM-14, Department of Medicine, University of Washington, School of Medicine, Seattle, WA 98195; telephone, (206) 543-5290.

Faculty Position.—A faculty position is open in the Department of Medicine, University of Washington, School of Medicine, Seattle, for an assistant professor. Responsibilities include patient care, teaching, and research. Applicants must be full-time dermatologists with established research capabilities in the field of clinical pharmacology. Preference will be given to individuals with experience in directing clinical research and individuals with advanced degrees in a basic discipline. If interested contact George F. Odland, MD, Division of Dermatology, RM-14, Department of Medicine, University of Washington, School of Medicine, Seattle, WA 98195; telephone, (206) 543-5290.

Skin of Vertebrates.—An international symposium, "The Skin of Vertebrates," of the Linnean Society of London and British Association of Dermatologists will be held in London on Sept 25-27, 1978. Further details may be obtained from Mr T. O'Grady, Linnean Society of London, Burlington House, Piccadilly, London W1V OLQ, England.

American Society for Dermatologic Surgery Meeting.—The American Society for Dermatologic Surgery (ASDS) will hold its Fourth Annual Clinical and Scientific Meeting April 5-9, 1978, at Vacation Village, San Diego. The course moderator will be Theodore Tromovitch, MD, and the program chairman will be Samuel J. Stegman, MD.

For registration information write to Robert Brown, Incentive Co, 2207 Chestnut St, Philadelphia, PA 19103. For program information write to Theodore Tromovitch, MD, or Samuel J. Stegman, MD, 350 Parnassus Ave, San Francisco, CA 94117.

The registration fees will be as follows: ASDS members, $100; nonmembers, $150; physicians in training, $75; and spouses, $10. Twenty-four hours of continuing medical education credit will be offered.

1978 Examinations of the American Board of Dermatology.—The 1978 certifying examination of the American Board of Dermatology will be given on Oct 29 and 30 in Chicago at the O'Hare/Kennedy Holiday Inn. Applications to take this examination must be received by June 1, 1978.

The examination for certification of special competence in dermatopathology will be given on Nov 7, 1978 in Miami Beach. Applications for this examination from diplomates of the American Board of Dermatology must be received by the board office not later than July 1, 1978. It is important to emphasize that applications from those diplomates of the American Board of Dermatology and the American Board of Pathology who qualify to take this special competence examination in the "experience" category (that is, training in dermatology or pathology must have been completed by Dec 31, 1974 and completion of two years of experience in dermatopathology in a manner acceptable to the American Board of Dermatology and the American Board of Pathology) *must be received in the Board office by not later than Dec 31, 1978.* After Dec 31, 1978, applications will not be accepted unless the candidate has had one year of approved, full-time, dermatopathology residency training. Currently, the 12 approved training centers are Massachusetts General Hospital, Mayo Graduate School, New York University, Temple University, University of Minnesota, University of Oklahoma, University of Pennsylvania, University of Texas SW Medical Branch in Dallas, Duke University, University of Chicago Affiliated Hospitals, Cleveland Clinic, and the University of Cincinnati Hospital Group.

Early in May 1978, the American Board of Dermatology will make an in-training examination available to all dermatology training centers. All residents-in-training, as well as dermatologists who have completed their training, may apply through a training center director to take this in-training examination.

For additional information and ap-

plication forms for any of these examinations, please write to Clarence S. Livingood, MD, executive director; American Board of Dermatology, Henry Ford Hospital, Detroit, MI 48202.

Allergy and Immunology.—The American Dermatologic Society for Allergy and Immunology (ADSAI) will have its third annual meeting in Denver, at the Airport Hilton Hotel, Sept 28-30, 1978. This will be an outstanding meeting in immunodermatology honoring Dr Robert Good, who is the head of the Sloan Kettering Institute in New York City, and who is one of the major contributors to the new theories in immunology. In addition, the faculty will include Dr Harvey Blank, who will speak on new information regarding herpes simplex; Dr Aaron Lerner, who will speak on new therapy for malignant melanoma; also, Drs Peter Lynch, Hermann Pinkus, and Robert Goltz. Fees for this meeting are $100 for members and $125 for nonmembers. Registration checks should be sent to Dr Michael Fellner, 30 E 60th St, New York, NY 10022.

Congress on Allergology.—The Tenth International Congress of Allergology of the International Association of Allergology will be held Nov 4-11, 1979, in Jerusalem, under the auspices of the Israel Society of Allergy and Clinical Immunology. For further information contact Israel Glazer, MD, chairman, organizing committee, Tenth International Congress of Allergology, PO Box 16271, Tel Aviv, Israel.

American Society for Dermatologic Surgery Meeting.—The American Society for Dermatologic Surgery will hold its Sixth Annual Clinical and Scientific Meeting March 26-30, 1980, at MGM Hotel, Las Vegas. The course moderator will be Theodore Tromovitch, MD. For information write to Theodore Tromovitch, MD, 350 Parnassus Ave, San Francisco, CA 94117.

J. N. Taub Award for Psoriasis Research.—Dr Howard Green, professor of cell biology, Massachusetts Institute of Technology, has been selected as the 1977 winner of the $1,000 Mr and Mrs J. N. Taub International Memorial Award for Psoriasis Research.

This award is given to Dr Howard Green for single contributions in the field of cell and molecular biology. He originated the 3T3 fibroblast-like cell, which has been used by many researchers to unravel the molecular basis of cell proliferation. He has recently devised a method by which human keratinocytes can be serially subcultured. The availability of large quantities of human epidermal cells on a routine basis makes feasible the application of modern molecular biology to the study of those skin diseases in which the epidermis is an important participant.

Dr Green was selected by a seven man committee, and the announcement was made by Dr John M. Knox during the Psoriasis Symposium at the academy. The award was established in 1957 by Carol and Henry J. N. Taub in honor of their grandparents, Mr and Mrs J. N. Taub. Their establishment of this program carried with it the hope that the award would be an incentive to develop a cure to alleviate one of the problems of mankind.

Primary Care Dermatology.—"Primary Care Dermatology," an accredited continuing medical education conference, will be held May 19-21, 1978, at Northwestern University Medical School, Chicago. It will be presented by the Department of Dermatology, with Henry H. Roenigk, Jr, MD, as conference author. For information contact the Alumni Center for Continuing Education, 301 E Chicago Ave, Chicago, IL 60611. The telephone number is 312-649-8533.

Friends of Bill Reed.—David Norris, MD, who is from the Department of Dermatology, University of Colorado, and who won the Stelwagon Award for his presentation at the Residents Forum last December in Dallas, has received an additional award. He has become the first Bill Reed International Traveling Fellow and will attend the annual meeting of the British Association of Dermatology in Nottingham, England, July 13-15, 1978.

The Friends of Bill Reed have established an endowed Fellowship Fund to be administered in perpetuity by the American Academy of Dermatology. Its aim is to enhance and encourage international exchange between young dermatologists the world over. Anyone who wishes to contribute to this fund should send their check to the American Academy of Dermatology, 820 Davis St, Evanston, IL 60201.

SYNALAR®
(fluocinolone acetonide)
CREAM 0.025%
CREAM 0.01%
OINTMENT 0.025%
SOLUTION 0.01%

Description Synalar (fluocinolone acetonide) has the chemical name 6α, 9α-difluoro-16α-hydroxyprednisolone-16, 17-acetonide.

The cream contains fluocinolone acetonide 0.25 mg./g. or 0.1 mg./g. in a water-washable aqueous base of stearic acid, propylene glycol, sorbitan monostearate, and monooleate, polysorbate 60, purified water and citric acid with methylparaben and propylparaben as preservatives.

The ointment contains fluocinolone acetonide 0.25 mg./g. in a white petrolatum U.S.P. vehicle.

The solution contains fluocinolone acetonide 0.1 mg./g. in a water-washable base of propylene glycol with citric acid.

Indications For relief of the inflammatory manifestations of corticosteroid-responsive dermatoses.

Contraindications Topical steroids are contraindicated in vaccinia and varicella.

Topical steroids are contraindicated in those patients with a history of hypersensitivity to any of the components of the preparation.

Precautions If irritation develops, the product should be discontinued and appropriate therapy instituted.

In the presence of an infection the use of an appropriate antifungal or antibacterial agent should be instituted. If a favorable response does not occur promptly, the corticosteroid should be discontinued until the infection has been adequately controlled.

If extensive areas are treated or if the occlusive technique is used, the possibility exists of increased systemic absorption of the corticosteroid and suitable precautions should be taken.

Although topical steroids have not been reported to have an adverse effect on pregnancy, the safety of their use in pregnant females has not absolutely been established. Therefore, they should not be used extensively on pregnant patients, in large amounts, or for prolonged periods of time.

Synalar products are not for ophthalmic use.

Adverse reactions The following local adverse reactions have been reported with topical corticosteroids: burning, itching, irritation, dryness, folliculitis, hypertrichosis, acneform eruptions, hypopigmentation.

The following may occur more frequently with occlusive dressings than without such therapy: maceration of the skin, secondary infection, skin atrophy, striae, miliaria.

How Supplied
Synalar (fluocinolone acetonide)
Cream 0.025% — 15 and 60g. tubes and 120 and 425g. jars.
Cream 0.01% — 15, 45 and 60g. tubes and 120 and 425g. jars.
Ointment 0.025% — 15 and 60g. tubes and 425g. jars.
Solution 0.01% — 20cc. and 60cc. plastic squeeze bottles.

Also Available
Synalar-HP® (fluocinolone acetonide) Cream 0.2% 5g. and 12g. tubes.

SYNTEX
SYNTEX LABORATORIES, INC.
PALO ALTO, CALIFORNIA 94304

USEFUL TODAY AS THE
Y IT WAS INTRODUCED

SYNALAR

(FLUOCINOLONE ACETONIDE)

See preceding page for summary of prescribing information.

NTEX

"Doctor, with my baby's sensitive skin... what soap should I use?"

Pure mild Ivory is one of the safest possible soaps you can recommend for sensitive skin. More doctors recommend Ivory than any other soap.

It makes sense. Ivory's absence of many extra ingredients helps minimize chances of irritation.

Thirty-eight years of laboratory testing—including patch tests and arm immersion experiments—confirm that Ivory is one of the mildest, least irritating soaps you can recommend.

And 89 years of safe consumer use support this clinical experience.

Ivory may safely be used as an adjunct to treatment of cradle cap, scabies, impetigo and seborrhea.



Take a close look at



Cordran® SP
flurandrenolide

New, improved formulation provides these advantages over original Cream Cordran*

- greater solubility for faster, more complete absorption and, therefore, faster action
- increased vasoconstrictive activity
- greater efficacy in psoriasis
- contains no potentially sensitizing preservatives

*Data on file, Dista Products Company.

Cream Cordran® SP
and
Ointment Cordran®
flurandrenolide

Brief Summary. Consult the package literature for prescribing information.
Description: Cordran is a potent corticosteroid intended for topical use.
Actions: Cordran is primarily effective because of its anti-inflammatory, antipruritic, and vasoconstrictive actions.
Indications: For relief of the inflammatory manifestations of corticosteroid-responsive dermatoses.
Contraindications: Topical corticosteroids are contraindicated in vaccinia and varicella and in patients with a history of hypersensitivity to any of their components.
Precautions: If irritation develops, the product should be discontinued and appropriate therapy instituted.

In the presence of an infection, an appropriate antifungal or antibacterial agent should be used. If a favorable response does not occur promptly, the corticosteroid should be discontinued until the infection has been adequately controlled.

If extensive areas are treated or if the occlusive technique is used, there is a possibility of increased systemic absorption of the corticosteroid, and suitable precautions should be taken.

Although topical corticosteroids have not been reported to have an adverse effect on pregnancy, the safety of their use on pregnant women has not been absolutely established. Therefore, they should not be used extensively, in large amounts, or for prolonged periods of time on pregnant patients.

These products are not for ophthalmic use.
Adverse Reactions: The following local adverse reactions have been reported with topical corticosteroid formulations: acneform eruptions, burning, dryness, folliculitis, hypertrichosis, hypopigmentation, irritation, itching.

The following may occur more frequently with occlusive dressings: maceration of the skin, miliaria, secondary infection, skin atrophy, striae.
Administration and Dosage: For moist lesions, a small quantity of the cream should be rubbed gently into the affected areas two or three times a day. For dry, scaly lesions, the ointment is applied as a thin film to affected areas two or three times daily. [122277]

Additional information available to the profession on request.

DISTA
Dista Products Company
Division of Eli Lilly and Company
Indianapolis, Indiana 46206

800194

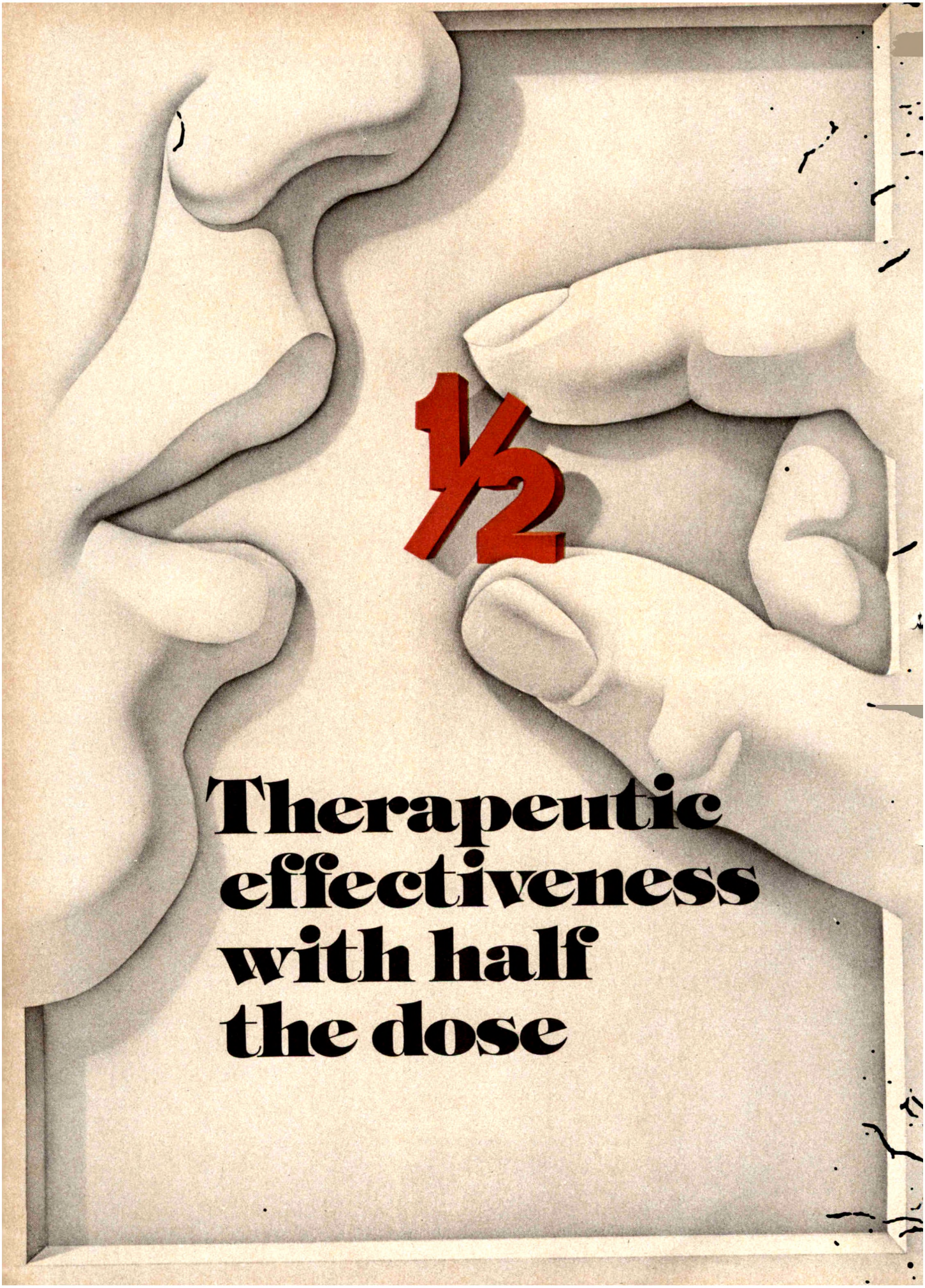
½
Therapeutic effectiveness with half the dose

Schering

Once-a-day dosage

Fulvicin® P/G*

brand of

griseofulvin [ultramicrosize], USP

(specially processed) **125 mg. tablets**

*"P/G" means a new polyethylene glycol system for enhanced absorption –

A 250 mg. daily dose (two 125 mg. tablets) of new FULVICIN P/G can replace 500 mg. of griseofulvin (microsize), USP. This is made possible by a special process in which the ultramicrosize griseofulvin crystals are partly dissolved in polyethylene glycol and dispersed through the tablet matrix for enhanced absorption.

Patient convenience –

FULVICIN P/G can be prescribed as two 125 mg. tablets once a day. Compliance is further assured by the easy-to-swallow size of the tablets.

Patient savings –

FULVICIN P/G is up to 35 per cent less expensive per dose than all microsize griseofulvin formulations.**

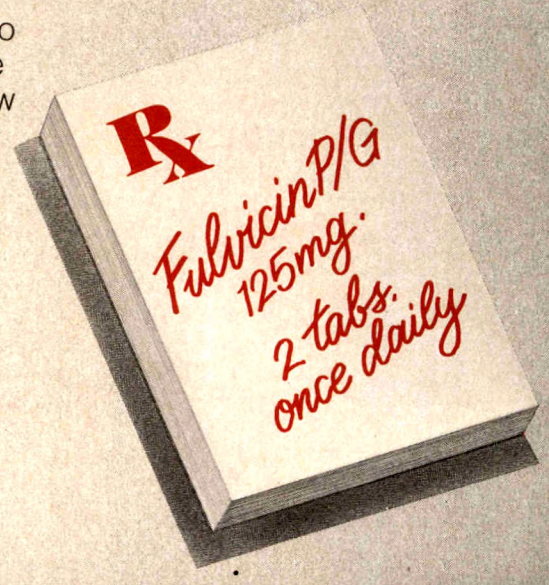

**Based on list-price comparison.

See Clinical Considerations section on following page.

COPYRIGHT © 1977, SCHERING CORPORATION. ALL RIGHTS RESERVED. SLS-945

Schering

Fulvicin® P/G

griseofulvin [ultramicrosize], USP

(specially processed) **125 mg. tablets**

Clinical Considerations: INDICATIONS FULVICIN P/G Tablets are indicated for the treatment of ringworm infections of the skin, hair, and nails, namely: tinea corporis, tinea pedis, tinea cruris, tinea barbae, tinea capitis, tinea unguium (onychomycosis) when caused by one or more of the following genera of fungi: *Trichophyton rubrum, Trichophyton tonsurans, Trichophyton mentagrophytes, Trichophyton interdigitalis, Trichophyton verrucosum, Trichophyton megnini, Trichophyton gallinae, Trichophyton crateriform, Trichophyton sulphureum, Trichophyton schoenleini, Microsporum audouini, Microsporum canis, Microsporum gypseum,* and *Epidermophyton floccosum.* Note: Prior to therapy, the type of fungi responsible for the infection should be identified. The use of this drug is not justified in minor or trivial infections which will respond to topical agents alone. Griseofulvin is not effective in the following: Bacterial infections, Candidiasis (Moniliasis), Histoplasmosis, Actinomycosis, Sporotrichosis, Chromoblastomycosis, Coccidioidomycosis, North American Blastomycosis, Cryptococcosis (Torulosis), Tinea versicolor, and Nocardiosis. **CONTRAINDICATIONS** This drug is contraindicated in patients with porphyria, hepatocellular failure, and in individuals with a history of hypersensitivity to griseofulvin. **WARNINGS** *Prophylactic Usage:* Safety and efficacy of griseofulvin for prophylaxis of fungal infections have not been established. *Animal Toxicology:* Chronic feeding of griseofulvin, at levels ranging from 0.5-2.5% of the diet, resulted in the development of liver tumors in several strains of mice, particularly in males. Smaller particle sizes result in an enhanced effect. Lower oral dosage levels have not been tested. Subcutaneous administration of relatively small doses of griseofulvin once a week during the first three weeks of life has also been reported to induce hepatomata in mice. Although studies in other animal species have not yielded evidence of tumorogenicity, these studies were not of adequate design to form a basis for conclusions in this regard. In subacute toxicity studies, orally administered griseofulvin produced hepatocellular necrosis in mice, but this has not been seen in other species. Disturbances in porphyrin metabolism have been reported in griseofulvin-treated laboratory animals. Griseofulvin has been reported to have a colchicine-like effect on mitosis and cocarcinogenicity with methylcholanthrene in cutaneous tumor induction in laboratory animals. *Usage in Pregnancy:* The safety of this drug during pregnancy has not been established. *Animal Reproduction Studies:* It has been reported in the literature that griseofulvin was found to be embryotoxic and teratogenic on oral administration to pregnant rats. Pups with abnormalities have been reported in the litters of a few bitches treated with griseofulvin. Additional animal reproduction studies are in progress. Suppression of spermatogenesis has been reported to occur in rats, but investigation in man failed to confirm this. **PRECAUTIONS** Patients on prolonged therapy with any potent medication should be under close observation. Periodic monitoring of organ system function, including renal, hepatic, and hematopoietic, should be done. Since griseofulvin is derived from species of penicillin, the possibility of cross sensitivity with penicillin exists; however, known penicillin-sensitive patients have been treated without difficulty. Since a photosensitivity reaction is occasionally associated with griseofulvin therapy, patients should be warned to avoid exposure to intense natural or artificial sunlight. Should a photosensitivity reaction occur, lupus erythematosus may be aggravated. Griseofulvin decreases the activity of warfarin-type anticoagulants so that patients receiving these drugs concomitantly may require dosage adjustment of the anticoagulant during and after griseofulvin therapy. Barbiturates usually depress griseofulvin activity, and concomitant administration may require a dosage adjustment of the antifungal agent. **ADVERSE REACTIONS** When adverse reactions occur, they are most commonly of the hypersensitivity type, such as skin rashes, urticaria, and rarely, angioneurotic edema, and may necessitate withdrawal of therapy and appropriate countermeasures. Paresthesias of the hands and feet have been reported rarely after extended therapy. Other side effects reported occasionally are oral thrush, nausea, vomiting, epigastric distress, diarrhea, headache, fatigue, dizziness, insomnia, mental confusion, and impairment of performance of routine activities. Proteinuria and leukopenia have been reported rarely. Administration of the drug should be discontinued if granulocytopenia occurs. When rare, serious reactions occur with griseofulvin, they are usually associated with high dosages, long periods of therapy, or both.

10705231 JANUARY 1977

For more complete details, consult package insert or Schering literature available from your Schering Representative or Professional Services Department, Schering Corporation, Kenilworth, New Jersey 07033.



INDEX TO ADVERTISERS

A

Abbott Laboratories 476-477

B

Barnes-Hind Pharmaceuticals 515
Burroughs Wellcome Company 475

C

Cooper Laboratories, Inc. 491, 517

D

Dermik Laboratories 525, 621
Dista Products Company 635
Doak Pharmacal Company 499
Dome Laboratories 514-515, 608-609

F

Frankel, Edward B., M.D. 494

G

General Foods 509
General Medical Company 521

H

Herbert, G.S., Laboratories, Division of Allergan Pharmaceuticals 473, 495
Hoechst-Roussel Pharmaceuticals 496-498

L

Lederle Laboratories, Division of American Cyanamid Company 489-490, 619

N

Neutrogena Corporation 618

O

Owen Laboratories, Inc. ..... 3rd Cover

P

Parke-Davis & Company 520-521, 616-617
Person & Covey, Inc. 604
Pharmacia Diagnostics 482
Procter & Gamble Company 516A-516B, 622A-622F, 634
Purdue Frederick Company 500

R

Reed & Carnrick 518-519
Riker Laboratories, Inc. 607
Roche Laboratories, Division of Hoffmann-LaRoche, Inc. 501-503
Roerig, J.B., Company Division of Pfizer, Inc. 512-513

S

Schering Corporation 492-494, 628-629, 636-638
Smith Kline & French Laboratories 484
Squibb, E.R., & Sons, Inc. 522-524
Stiefel Laboratories, Inc. 483, 507-508
Stuart Pharmaceuticals Div. of ICI Americas Inc. 481
Syntex Laboratories, Inc. 486-488, 504-506, 632-633

T

Texas Pharmacal Company 622

W

Westwood Pharmaceuticals, Inc. ..... 2nd Cover, 479, 510-511, 526, 605-606, 610, 630, 4th Cover

While every precaution is taken to insure accuracy, we cannot guarantee against the possibility of an occasional change or omission in the preparation of this index.

Tar therapy has progressed one step further.

psoriGel™: a proven effective tar concentrate in an emollient vehicle for the treatment of psoriasis, eczema, and other tar responsive dermatoses.

Owen
Owen Laboratories, Dallas, Texas 75234
Division of Alcon Laboratories, Inc.

When treating tar-responsive dermatoses...

You'll have to tell your patients it's tar.

NEW

estar™

Therapeutic Tar Gel

The odor won't.

For full product information, see PDR.

WESTWOOD
PHARMACEUTICALS INC.
Buffalo, New York 14213

©1976, W.P. Inc.

Published by the American Medical Association

May 1978
Volume 114, Number 5

archives of Dermatology

Speckled (Particulate) Epidermal Nuclear IgG Deposition in Normal Skin ..... S. D. Prystowsky, D. L. Tuffanelli 705

Psoralen-UVA-Treated Psoriatic Lesions ..... K. Hashimoto, H. Kohda, M. Kumakiri, S. L. Blender, I. Willis 711

Intravascular Papillary Endothelial Hyperplasia ..... R. J. Barr, J. H. Graham, L. A. Sherwin 723

Variably Occlusive Tape Systems and the Mitotic Activity of Stripped Human Epidermis ..... L. B. Fisher, H. I. Maibach, R. J. Trancik 727

Palmar and Plantar Pustulosis Elicited by *Candida* Antigen ..... M. Uehara 730

Origin of Familial Malignant Melanomas From Heritable Melanocytic Lesions ..... W. H. Clark, Jr, R. R. Reimer, M. Greene, A. M. Ainsworth, M. J. Mastrangelo 732

Scalpel Excision of Basal Cell Carcinomas ..... R. S. Bart, D. Schrager, A. W. Kopf, J. Bromberg, N. Dubin 739

Multiple Hamartoma Syndrome (Cowden's Disease) ..... D. D. Nuss, J. L. Aeling, D. E. Clemons, W. N. Weber 743

The Epidemiology of Scabies in Denmark, 1900 to 1975 ..... J. Christophersen 747

Tumbleweed Dermatitis ..... R. F. Powell, E. B. Smith 751

Sister Chromatid Exchanges in Bloom's Syndrome ..... C. H. Dicken, G. Dewald, H. Gordon 755

Keratosis Follicularis Spinulosa Decalvans ..... H. Britton, J. Lustig, B. J. Thompson, S. Meyer, N. B. Esterly 761

Hyperimmunoglobulin E Syndrome ..... J. Stanley, D. Perez, I. Gigli, I. Goldstein, R. L. Baer 765

Childhood Pemphigus Treated With Gold ..... R. L. Paltzik, T. A. Laude 768

Unilateral Segmental Hyperhidrosis ..... A. Dworin, A. J. Sober 770

The Sézary Syndrome ..... M. G. Menefee, D. C. Zellner, R. C. Wright 772

Universal Acquired Melanosis ..... R. Ruiz-Maldonado, L. Tamayo, J. Fernández-Diez 775

Cicatricial Pemphigoid (Brunsting-Perry Type) ..... W. D. Jacoby, Jr, C. W. Bartholome, S. C. Ramchand, E. B. Simmons, T. K. Burnham 779

Aggressive Basal Cell Carcinoma of the Scalp ..... D. E. Gormley, P. Hirsch 782

Essential IgG Cryoglobulinemia With Purpura and Cold Urticaria ..... H. Koda, A. Kanaide, M. Asahi, H. Urabe 784

AMA AMERICAN MEDICAL ASSOCIATION

When they first consult you for seborrheic dermatitis, they've tried everything but magic.

Only you can work the magic of a Capitrol® Rx.

(chloroxine 2%)

EFFECTIVENESS

- In a recent clinical study, 76% of patients reported clinical improvement with Capitrol®*
- Two treatments a week are usually sufficient.
- Contains an effective antibacterial.

ELEGANCE

- Cosmetically elegant, contains no tar or heavy metals.

SAFETY

- The most commonly reported adverse effect has been discoloration of light-colored hair (e.g. blond, gray or bleached). Some itching, burning and dryness have been reported.*

* Information on file at Westwood Pharmaceuticals, Inc.

Caution: Federal law prohibits dispensing without prescription.

Description: Capitrol® shampoo provides 2% chloroxine (each gram contains 20 mg. chloroxine) suspended in a shampoo base containing: sodium octoxynol-3 sulfonate, PEG-6 lauramide, dextrin, stearyl alcohol/ceteareth-20, sodium lauryl sulfoacetate, dioctyl sodium sulfosuccinate, magnesium aluminum silicate, PEG-14M, EDTA, citric acid, water, color and fragrance. The pH of the shampoo is 7.0.

The chemical name of chloroxine is 5,7-dichloro-8-hydroxyquinoline.

Actions: Chloroxine is a synthetic antibacterial compound. It has a structural similarity to a number of substituted 8-hydroxyquinolines that have been in therapeutic use for some years.

Indications: Capitrol® is indicated in the treatment of dandruff and mild to moderately severe seborrheic dermatitis of the scalp.

Contraindications: Capitrol® (chloroxine) may produce allergic contact sensitization reactions in patients who are sensitive to hydroxyquinolines or EDTA. This shampoo should not be used on acutely inflamed (exudative) lesions of the scalp.

Precautions: Patients should be advised to exercise care not to allow Capitrol to enter the eyes. For external use only. Keep this and all drugs out of the reach of children.

Adverse Reactions: Irritation and burning of the scalp and adjacent areas have been reported. Allergic type skin eruptions may occur in patients who are sensitive to any component of the shampoo. As with any medicated shampoo, chemical conjunctivitis may result if Capitrol enters the eyes. Discoloration of light-colored hair (e.g. blond, gray or bleached) may follow use of this preparation. Dryness of the scalp and increased itching have been reported.

Dosage and Administration: Capitrol® (chloroxine) should be massaged thoroughly into the wet scalp, avoiding contact with the eyes. Lather should remain on the scalp for approximately three minutes, then rinsed. The application should be repeated and the scalp rinsed thoroughly. Two treatments per week are usually sufficient.

How Supplied: Capitrol (chloroxine shampoo) is supplied in 85 g plastic tubes.

WESTWOOD
PHARMACEUTICALS INC.
Buffalo, New York 14213

© 1978, W.P. Inc.



Hymenoptera Allergy

Phadebas RAST provides an accurate means of documenting IgE mediated allergic sensitivity to stinging insects.

Phadebas RAST®

the *in vitro* alternative

Pharmacia Diagnostics AB
Uppsala, Sweden

Pharmacia Diagnostics

Argentina Laboratorios Dr. Gador y Cia., S.A.C.I. Casilla de Correo 4041 1006 BUENOS AIRES. **Australia** Pharmacia (South Seas) Pty. Ltd. P.O. Box 175 4 Byfield Street NORTH RYDE N.S.W. 2113. **Austria** Pharmacia Gesellschaft m.b.H. Rathausplatz 4 A-1010 WIEN. **Belgium** N.V. Pharmacia Belga S.A. Bld. Gen. Jacqueslaan 26 B-1050 BRUSSELS. **Brazil** Emprêsa Medimex Importação e Comércio Ltda. Rua Cardoso Marinho, 40 Caixa Postal 33-ZC-00 RIO DE JANEIRO. **Canada** Pharmacia (Canada) Ltd. 2044 boul. St. Régis Blvd. DORVAL, Québec H9P 1H6. **Denmark** Pharmacia AS, Herredsvejen DK-3400 HILLERÖD. **Finland** Pharmacia OY Norrskensvägen 6, SF-02100 ESBO. **France** Pharmacia France S.A. Rue de Marly Parly 2 F-78150 LE CHESNAY. **German Federal Rebublic** Deutsche Pharmacia G.m.b.H. Munzinger Strasse 9 Postfach 5480 D-7800 FREIBURG. **Great Britain** Pharmacia (G.B.) Ltd. Paramount House 75 Uxbridge Road LONDON W5 5SS. **Greece** G.A. Kambanis Imports-Exports-Representations 3 Iridanou Street ATHENS 612. **Italy** Importex Chimici Farmaceutici S.p.A. P.O. Box 467 Via Flavia 122/124 I-34100 TRIESTE. **Mexico** Internacional Cientifica S.A. Apartado Postal 2-807 Angel del Campo 17-A MEXICO 12 D.F. **The Netherlands** Gist-Brocades N.V. Diagnostics Dept. P.O. Box 324 Frijdastraat 7–9 RIJSWIJK (Z H) 2109. **Norway** Norsk Pharmacia A/S Postboks 2005 Grünerløkka OSLO 5. **Portugal** J.A. Baptista D'Almeida Lda. Apartado 1339 LISBOA 1. **Spain** Atom, Paseo del Monte 34 BARCELONA 12. **Sweden** Pharmacia Norden AB Diagnostics Dept. Box 159 751 04 UPPSALA 1. **Switzerland** Pharmacia -pdf- (Schweiz) A.G. 214 Seefeldstrasse CH-8034 ZUERICH. **USA** Pharmacia Diagnostics Division of Pharmacia Inc. 800 Centennial Avenue PISCATAWAY New Jersey 08854. **Other countries** Pharmacia Diagnostics AB Box 17 S-751 03 UPPSALA 1 Sweden.

Archives of DERMATOLOGY
Copyright © 1978 by the AMERICAN MEDICAL ASSOCIATION

VOL 114, NO. 5 MAY 1978

ORIGINAL CONTRIBUTIONS

Speckled (Particulate) Epidermal Nuclear IgG Deposition in Normal Skin
Stephen D. Prystowsky, MD, Denny L. Tuffanelli, MD, San Francisco 705

Psoralen-UVA-Treated Psoriatic Lesions
Ken Hashimoto, MD; Hiromu Kohda, MD, PhD; Masanobu Kumakiri, MD; Steven L. Blender, MD, Memphis; Isaac Willis, MD, Decatur, Ga 711

Intravascular Papillary Endothelial Hyperplasia
Ronald J. Barr, MD; James H. Graham, MD; Lawrence A. Sherwin, MD, Irvine, Calif 723

Variably Occlusive Tape Systems and the Mitotic Activity of Stripped Human Epidermis
Louis B. Fisher, PhD, La Jolla, Calif; Howard I. Maibach, MD, San Francisco; Ronald J. Trancik, PhD, St Paul 727

Palmar and Plantar Pustulosis Elicited by *Candida* Antigen
Masami Uehara, MD, Kyoto, Japan 730

Origin of Familial Malignant Melanomas From Heritable Melanocytic Lesions
Wallace H. Clark, Jr, MD, Philadelphia; Ronald R. Reimer, MD; Mark Greene, MD, Bethesda, Md; Ann M. Ainsworth, MD; Michael J. Mastrangelo, MD, Philadelphia 732

Scalpel Excision of Basal Cell Carcinomas
Robert S. Bart, MD; David Schrager; Alfred W. Kopf, MD; Judith Bromberg, MS; Neil Dubin, PhD, New York 739

Multiple Hamartoma Syndrome (Cowden's Disease)
Col Donald D. Nuss, MC, USA; Col John L. Aeling, MC, USA; Maj Donald E. Clemons, MC, USA; Maj Wallace N. Weber, MC, USA, Denver 743

The Epidemiology of Scabies in Denmark, 1900 to 1975
Jette Christophersen, MD, Copenhagen 747

Tumbleweed Dermatitis
Ralph F. Powell, MD; Edgar B. Smith, MD, Albuquerque, NM 751

CASE REPORTS

Sister Chromatid Exchanges in Bloom's Syndrome
Charles H. Dicken, MD; Gordon Dewald, PhD; Hymie Gordon, MD, Rochester, Minn 755

Keratosis Follicularis Spinulosa Decalvans
Helen Britton, MD; James Lustig, MD; Brenda J. Thompson, MD; Steven Meyer, MD; Nancy B. Esterly, MD, Chicago 761

Hyperimmunoglobulin E Syndrome
John Stanley, MD; Daniel Perez, MD; Irma Gigli, MD; Ira Goldstein, MD; Rudolf L. Baer, MD, New York 765

Childhood Pemphigus Treated With Gold
Robert L. Paltzik, MD; Teresita A. Laude, MD, Brooklyn, NY 768

Unilateral Segmental Hyperhidrosis
Aaron Dworin, MD; Arthur J. Sober, MD, Boston 770

(Continued on page 642)

EDITORIAL BOARD

Chief Editor
John H. Epstein, MD
450 Sutter Street
San Francisco 94108

Assistant Chief Editor
Kimie Fukuyama, MD
San Francisco

Assistant Chief Editor
Denny L. Tuffanelli, MD
San Francisco

Donald C. Abele, MD
Augusta, Ga

Harry L. Arnold, Jr, MD
Honolulu

Walter C. Lobitz, Jr, MD
Portland, Ore

Frederick D. Malkinson, MD
Chicago

Sigfrid A. Muller, MD
Rochester, Minn

W. Mitchell Sams, Jr, MD
Chapel Hill, NC

John S. Strauss, MD
Iowa City

Gerald D. Weinstein, MD
Miami

for psoriasis/eczema
psoriGel™
a tar concentrate in an emollient gel
NET WT. 4 OZ.
Tar therapy has progressed one step further.
psoriGel™: a proven effective tar concentrate in an emollient vehicle for the treatment of psoriasis, eczema, and other tar responsive dermatoses.
Owen
Owen Laboratories, Dallas, Texas 75234
Division of Alcon Laboratories, Inc.

CONTENTS—Continued

The Sézary Syndrome
Max G. Menefee, MD, PhD; David C. Zellner, MD; Robert C. Wright, MD, Cincinnati 772

Universal Acquired Melanosis
Ramón Ruiz-Maldonado, MD; Lourdes Tamayo, MD; Jorge Fernández-Diez, MD, Mexico City 775

Cicatricial Pemphigoid (Brunsting-Perry Type)
W. David Jacoby, Jr, MD; Charles W. Bartholome, MD; Subash C. Ramchand, MD; Everett B. Simmons, MD; Thomas K. Burnham, MD, BS, (Lond), Detroit 779

Aggressive Basal Cell Carcinoma of the Scalp
Daniel E. Gormley, MD; Paul Hirsch, MD, Los Angeles 782

Essential IgG Cryoglobulinemia With Purpura and Cold Urticaria
Hiromu Koda, MD; Akiko Kanaide, MD; Masakazu Asahi, MD; Harukuni Urabe, MD, Fukuoka, Japan 784

REGULAR DEPARTMENTS

Short Report 791

Alopecia Mucinosa of the Face Associated With Mycosis Fungoides Alan N. Binnick, MD; Fredrick D. Wax, MD; William E. Clendenning, MD, Hanover, NH

Books 794

Letters to the Editor 798

Diagnosis of Scabies Gunnar Kavli, MD, Tromsø, Norway . . . **Condyloma Acuminatum** Arthur W. Gulick, MD, Ann Arbor, Mich . . . **Human Wart Virus** R. D. Wilkinson, MD; Peter Gill, PhD; Rob Miller, MD; John Kosiuk, Montreal . . . **Systemic Absorption of Topical Clindamycin** David A. Voron, MD, Arcadia, Calif; Ronald J. Algra, MD; Theodore Rosen, MD; Margaret Waisman, MD, Houston . . . **Hydrocortisone vs High-Potency Corticosteroid Ointments** Howard P. Baden, MD, Boston . . . **Seroepidemiologic Search for Cause of Psoriasis** Joan J. Ratner, MD, Kendall O. Smith, San Antonio, Tex . . . **Curious Comedo Genesis** Joseph M. Scherzer, MD, Scottsdale, Ariz . . . **Clotrimazole vs Haloprogin in the Treatment of Tinea Cruris** Christopher M. Papa, MD, New Brunswick, NJ, Lt Col Jules V. VanDersarl, MC, USAF, Madrid, Spain . . . **Bacitracin-Induced Anaphylaxis** Michael A. Vale, MD; Adrian Connolly, MD; Allen M. Epstein, MD; Margo R. Vale, MD, New York . . . **Resistant Condylomata Acuminata in Diabetics** Lawrence E. Skurat-on, MD, Bowie, Md . . . **Essential Fatty Acid Deficiency** Arnold L. Schroeter, MD, Stephen B. Tucker, MD, Rochester, Minn . . . **Simultaneous Occurrence of Familial Benign Chronic Pemphigus (Hailey-Hailey Disease) and Syringoma on the Vulva** Donald T. King, MD; Frank M. Hirose, MD, Torrance, Calif; Laura A. King, MD, Irvine, Calif . . . **Graft-vs-Host Reaction** Jean-H Saurat, MD; Eliane Gluckman, MD, Paris; Lt Col Richard B. Odum, MC, USA, San Francisco . . . **Penile Cysts and Canals** Loren E. Golitz, MD; Richard Asarch, MD; William Sausker, MD; George M. Kreye, MD, Denver; Ralph F. Powell, MD; Charles H. Palmer, MD; Edgar B. Smith, MD, Albuquerque, NM . . . **Erythema Elevatum Diutinum** Floyd R. Tanzer, MD, Yelva L. Lynfield, MD, Brooklyn, NY . . . **Topical Sulfadiazine Silver for Bullous Pemphigoid** John M. Chadwick, MD, Thomas F. Downham II, MD, Detroit . . . **Primary Acquired Cold Urticaria** Colin A. Ramsay, MD, MRCP, Toronto, Alan A. Wanderer, MD, Denver . . . **Epidermotropic Mycosis Fungoides** James Warren Steger, MD, San Diego, Daniel Santa Cruz, MD, St Louis

News and Notes 808

Society Transactions 811

Index to Advertisers 812

Instructions for Authors 646

IMPROVED
SELSUN® ℞
(SELENIUM SULFIDE LOTION, U.S.P.)

- **Nicer fragrance**
- **Lighter color**
- **Richer sudsing**
- **Same efficacy and safety**

as the formula proved in millions of cases for over a quarter century

BRIEF SUMMARY

Contains: Selenium sulfide, 2½%, w/v; bentonite; lauric diethanolamide; ethylene glycol monostearate; titanium dioxide; amphoteric—2; sodium lauryl sulfate; sodium phosphate (monobasic); glyceryl monoricinoleate; citric acid; captan; perfume; and water.

Indications: For the treatment of dandruff and seborrheic dermatitis of the scalp.

Contraindications: Should not be used by patients allergic to any of its components.

Warnings: Safety for use on infants has not been established.

Precautions: Cutaneous sensitization of the scalp or adjacent areas has been reported; if sensitivity reactions should occur, discontinue use. Chemical conjunctivitis may result if product enters the eyes. Do not use when acute inflammation or exudation is present as an increase in absorption may occur.

Adverse Reactions: As with other shampoos, oiliness or dryness of the hair and scalp may occur following use; there have been occasional reports of an increase in the amount of normal hair loss. Hair discoloration may occur; can be avoided or minimized by thorough rinsing.

8033233

ABBOTT

IMPROVED

Selsun®... the sweet smell of success.

(SELENIUM SULFIDE LOTION, U.S.P.) ℞

- Nicer fragrance
- Lighter color
- Richer sudsing
- Same efficacy and safety

ABBOTT

Please see opposite page for Brief Summary.

Archives of Dermatology

James H. Sammons, MD
Executive Vice-President

Thomas F. Hannon
Group Vice-President,
Publishing Operations

William R. Barclay, MD
Group Vice-President,
Scientific Publications

Norman D. Richey
Director, Publication
Production Division

John T. Baker
Director, Marketing Division

Helen R. Mazur
Director, Circulation-Fulfillment

John T. Baker, General Sales Manager; **Robert Corcoran,** Eastern Sales Manager; **Fred Bauman, Richard M. Johnson,** Eastern Sales Representatives; **Alice Harvey, William J. Healy,** Midwest Sales Representatives; **Thomas J. Carroll,** West Coast/Northern Sales Representative

PUBLICATION STAFF

Offices: 535 N Dearborn St
Chicago, IL 60610

Robert W. Mayo
Executive Editor and Director,
Scientific Publications Division

Sandra Williamson
Administrative Assistant

Marlene M. Hinsch, Production Manager

Diana A. Morgan, Editorial Processing Manager

Copy Editing: Rosanne Schulenberg (Supervisor), Patti Narret, Kathy Swartz, Elizabeth Warden

Proofreading: Lorraine L. Kruse (Supervisor), Verna Coffman, Patricia Coyne, Elizabeth Petrikenas, Mary Kay Tinerella, Dorothy Troy, Patricia Zawadski

Production Supervisors: Julia Bero (Layout), Thomas J. Handrigan (Illustrations), Marlene M. Hinsch (Editorial), James P. Bagniewski (Advertising)

Art and Senior Production Assistants: Betty Frigerio, Floriana Hayes, Shirley Latronica, Donna Pender, Nancy Keyes, Marilyn Moroney, Susan Routhier, JoAnne Weiskopf

Production Assistants: Karen Branham, E. Linda Eisenberg, Anna Goins, Lucille Kuznicki

Manuscript Records: Denise Henderson

Indexing: Phyllis H. O'Donnell (Supervisor), Jane P. Mauldin, Helen F. Topel

Please address communications concerning accepted or published communications to: AMA Specialty Journals, 535 N Dearborn St, Chicago, IL 60610.

Conditions for Acceptance of Color Illustrations

Illustrations in full color are accepted for publication in ARCHIVES OF DERMATOLOGY if the editor believes that color will add significantly to the published manuscript.

When color illustrations are accepted, the American Medical Association will pay part of the expense of reproduction and printing, the remainder to be borne by the author or the institution with which he is affiliated. After deducting AMA's contribution, the author's share is $275 for up to six square finished illustrations. Additional illustrations and special effects, such as outlining, opaquing, or surprinting, will be billed to the author at cost.

Color transparencies must be submitted for evaluation. Do not send color prints unless accompanied by original transparencies. If transparencies are mounted in frames or glass, the material should be carefully packed in gauze and sent with the manuscript in a separate container or between two pieces of pressboard.

Advertising and Subscription Information

ADVERTISING OFFICES: 535 N Dearborn St, Chicago, IL 60610, Area Code 312, 751-6000; and 600 Third Ave, New York, NY 10016, Area Code 212-867-6640.

ADVERTISING PRINCIPLES: Each advertisement in this issue has been reviewed and complies with the principles governing advertising in AMA scientific publications. A copy of these principles is available on request.

CHANGE OF ADDRESS: Please notify the publisher at least six weeks in advance, including both old and new address, and a mailing label taken from the most recent copy. Include your new zip code number.

Dome-Paste® Bandage

Modified Unna's Boot

Encourages healing of skin lesions... contributes to patient's comfort

Now a new 3-inch width... easy application for smaller limbs, fewer wrinkling problems than with fraying bandages, greater economy.

- ☐ Also in standard 4-inch width with nonraveling, thread-locked edges.
- ☐ Both sizes in 10-yard rolls; neutral-colored, rayon-reinforced for strength.
- ☐ Uniformly impregnated with zinc oxide, gelatin, calamine.
- ☐ Each roll sealed in a polyethylene bag to preserve freshness.
- ☐ Always ready for immediate use.

DOM-1306R2

Dome Laboratories

Division Miles Laboratories Inc MILES
West Haven Connecticut 06516 USA

Instructions for Authors

Send manuscripts by first-class mail to the Chief Editor, John H. Epstein, MD, 450 Sutter St, San Francisco, CA 94108. Manuscripts are received with the understanding that they are not under simultaneous consideration by another publication. Accepted manuscripts become the permanent property of the ARCHIVES and may not be published elsewhere without permission from the publisher (AMA).

In addition, in view of *The Copyright Revision Act of 1976*, effective Jan 1, 1978, transmittal letters to the editor should contain the following language: "In consideration of the American Medical Association taking action in reviewing and editing my submission, the author(s) undersigned hereby transfers, assigns, or otherwise conveys all copyright ownership to the AMA in the event that such work is published by the AMA." We regret that transmittal letters not containing the foregoing language signed by all authors of the submission will necessitate delay in review of the manuscript.

Author Responsibility.—All accepted manuscripts are subject to copy editing. The author will receive an edited typescript rather than galley proofs for approval. The author is responsible for all statements in his work, including changes made by the copy editor.

Designate one author as correspondent and provide his address and telephone number. Order reprints at the time the typescript is returned after editorial processing. Specify address to which requests for reprints should be sent.

Manuscript Preparation.—Submit an original typescript and two high-quality copies of the entire manuscript. All copy (including references, legends, and tables) must be typed double-spaced on 22 × 28-cm (8½ × 11-inch), heavy-duty white bond paper. Ample margins should be provided.

Refer to patients by number (or, in anecdotal reports, by fictitious given names). Real names or initials should not be used in the text, tables, or illustrations.

Titles.—Titles should be short, specific, and clear. They should not exceed 42 characters per line, including punctuation and spaces, and be limited to two lines, if possible. The title page should include the full names and academic affiliations of all authors, the address to which requests for reprints should be sent, and, if the manuscript was presented at a meeting, the name of the organization, place, and date on which it was read.

Style of Writing.—The style of writing should conform to acceptable English usage and syntax. Slang, medical jargon, obscure abbreviations, and abbreviated phrasing are to be avoided.

Informed Consent.—Manuscripts reporting the results of experimental investigations of human subjects must include a statement to the effect that informed consent was obtained after the nature of the procedure(s) had been fully explained.

Abstract.—Provide an abstract (135-word maximum) of the article, including statements of the problem, method of study, results, and conclusions. The abstract replaces the summary.

References.—List references in consecutive numerical order (not alphabetically). Once a reference is cited, all subsequent citations should be to the original number. All references must be cited in the text or tables. Unpublished data and personal communications should not be listed as references. References to journal articles should include (1) author(s), (2) title, (3) journal name (as abbreviated in *Index Medicus*), (4) volume number, (5) inclusive page numbers, and (6) year, in that order. References to books should include (1) author(s), (2) chapter title (if any), (3) editor (if any), (4) title of book, (5) city of publication, (6) publisher, and (7) year. Volume and edition numbers, specific pages, and name of translator should be included when appropriate. The author is responsible for the accuracy and completeness of the references and for their correct text citation.

Metrication.—All measurements must be in metric units. English units may also be given parenthetically if the measurements were originally done in English units.

Illustrations.—Use only those illustrations that clarify and augment the text. Submit illustrations in duplicate, unmounted and untrimmed. Do not send original artwork. Send high-contrast glossy prints (not photocopies). Figure number, name of senior author, and arrow indicating "top" should be typed on a gummed label and affixed to the back of each illustration. All lettering must be legible after reduction to column size. Artwork submitted for publication may be relettered to achieve uniformity of lettering style throughout the journal. Magnification and stain should be provided when pertinent. Illustrations should preferably be in a proportion of 12.5 × 18 cm (5 × 7 inches).

An experienced medical illustrator should be employed whenever possible for the preparation of all artwork. Template lettering or preset type is preferred to hand-lettered labels. If halftone artwork with labels is submitted, affix type and leaders to a clear acetate overlay registered to the base drawing. Labels and leaders should be applied directly to the drawing board surface if the artwork consists only of line ink technique.

Illustrations in full color are accepted for publication if the editors believe that color will add significantly to the published manuscript. The ARCHIVES will pay part of the expense of reproduction and printing color illustrations, the remainder to be borne by the author or his sponsor. After deducting the ARCHIVES contribution, the author's share is $275.00 for up to six square-finished illustrations that can be arranged on a one-page layout. Any additional illustrations or special effects will be billed to the author at cost. Positive color transparencies (35 mm preferred) must be submitted for an evaluation. Do not send color prints unless accompanied by original transparencies. All transparencies should be carefully packed and sent with the manuscript.

Legends.—Legends should be typed double-spaced, beginning on a separate sheet of paper. Length should be limited to a maximum of 40 words.

Photographic Consents.—A letter of consent must accompany all photographs of patients in which a possibility of identification exists. It is not sufficient to cover the eyes to mask identity.

Acknowledgments.—Illustrations from other publications must be acknowledged. Include the following when applicable: author(s), title of article, title of journal or book, volume number, page(s), month, and year. The publisher's permission to reprint should be submitted to the ARCHIVES after the manuscript has been formally accepted.

Statistical Review.—Manuscripts containing statistical evaluations should include the name and affiliation of the statistical reviewer.

Tables.—Each table should be typed double-spaced, including all headings, on a separate sheet of 22 × 28-cm (8½ × 11-inch) paper. Do not use larger size paper. If a table must be continued, use a second sheet and repeat all heads and stubs. Each table must have a title.

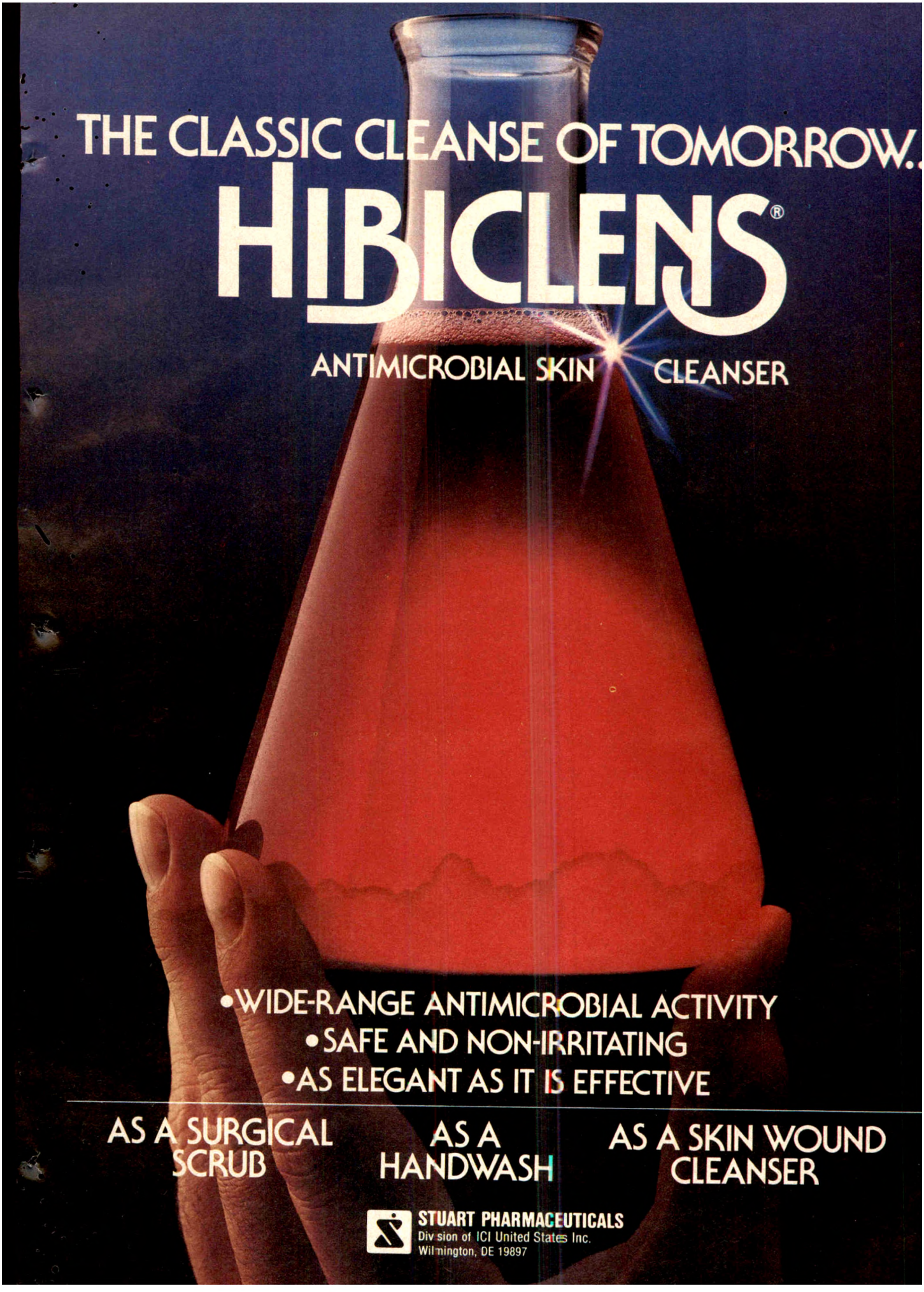
THE CLASSIC CLEANSE OF TOMORROW..
HIBICLENS®
ANTIMICROBIAL SKIN CLEANSER
•WIDE-RANGE ANTIMICROBIAL ACTIVITY
•SAFE AND NON-IRRITATING
•AS ELEGANT AS IT IS EFFECTIVE
AS A SURGICAL SCRUB
AS A HANDWASH
AS A SKIN WOUND CLEANSER
STUART PHARMACEUTICALS
Division of ICI United States Inc.
Wilmington, DE 19897

What can a month of follow-up tell you about this antifungal?

MicaTin makes it clear.

MicaTin can clear the most common fungal infections. More than that, it can keep them clear. Over 90% of patients successfully treated with MicaTin were found to be free of the original infection up to one month (median) after cessation of therapy.

MicaTin—a high rate of clearance demonstrated in extensive studies*

MicaTin provided clinical clearance or improvement in 88-94% of patients treated for tinea pedis,† tinea corporis,† tinea cruris,† candidiasis and tinea versicolor.

And most infections remained clear at follow-up

The patients in these studies were then evaluated to determine if MicaTin was effective in keeping these fungal infections clear. Of the 121 patients who were clear of tinea pedis, tinea corporis and tinea cruris at the end of treatment and available for follow-up, 92% showed no clinical or mycological recurrence of the original infection one month (median) later. And of the 34 patients cleared of cutaneous candidiasis and available for follow-up, 91% were still clear two weeks (median) later.

MicaTin—for the fungal infections you see every day

MicaTin is effective against the most prevalent fungal pathogens and provides fast symptomatic relief—usually within 72 hours for a majority of the patients.

MicaTin also has a low incidence of side effects. Reports of "burning" sensation, irritation and maceration with MicaTin have been few and isolated. It should not be used in patients with known hypersensitivity to any of its ingredients.

And MicaTin is economically priced—its retail cost is usually lower than that of other prescription antifungals.

MicaTin. So effective the first time around, it's seldom needed a second.

*Data on file, Johnson & Johnson. T. corporis, T. cruris, and candidiasis should be treated B.I.D. for 2 weeks, T. versicolor once daily for 2 weeks, and T. pedis B.I.D. for one month.

† When infecting organisms are Trichophyton rubrum, Trichophyton mentagrophytes and Epidermophyton floccosum.

Before prescribing, please consult complete product information, a summary of which follows:

Indications: For topical application in the treatment of tinea pedis (athlete's foot), tinea cruris, and tinea corporis caused by Trichophyton rubrum, Trichophyton mentagrophytes, and Epidermophyton floccosum, in the treatment of cutaneous candidiasis (moniliasis), and in the treatment of tinea versicolor.

Contraindications: MicaTin has no known contraindications.

Precautions: If a reaction suggesting sensitivity or chemical irritation should occur, use of the medication should be discontinued.

For external use only. Avoid introduction of MicaTin brand miconazole nitrate cream 2% and lotion 2% into the eyes.

Adverse Reactions: There have been isolated reports of irritation, burning, and maceration associated with application of MicaTin.

How Supplied: MicaTin brand cream 2% containing miconazole nitrate at 2% strength is supplied in 3 oz., 1 oz. and 15 g. tubes. MicaTin brand lotion 2% containing miconazole nitrate at 2% w/w strength is supplied in polyethylene squeeze bottles in quantities of 12 and 30 ml.

AN ETHICAL SPECIFIC FROM
THE DERMATOLOGICAL DIVISION OF

Johnson & Johnson
NEW BRUNSWICK, NEW JERSEY 08903

MicaTin
BRAND
miconazole nitrate 2%
Cream/Lotion
by prescription only

©Johnson & Johnson 1978



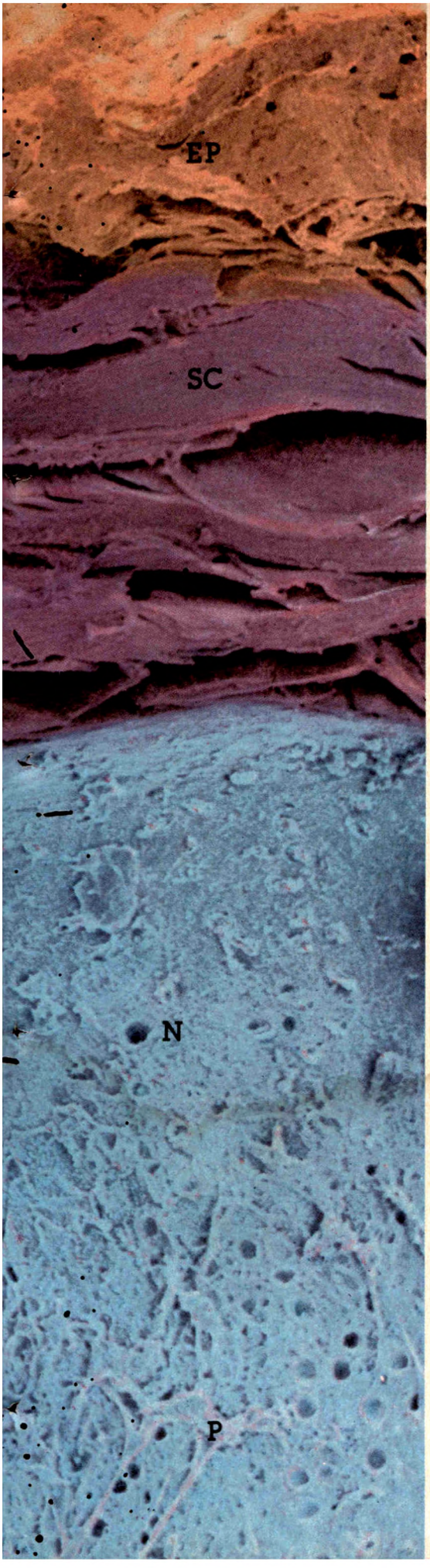

Potency in psoriasis

Potency — A singularly important criterion in selecting a topical steroid for psoriasis, as well as all other acute inflammatory steroid-responsive conditions.

Fluocinonide — A steroid that is 100% dissolved in the Lidex base for optimal lesion penetration. Anti-inflammatory, vasoconstrictive, antipruritic actions, backed by a proven record of performance.

Available in a form that's right for the case at hand — cream, ointment, or Topsyn® (fluocinonide) Gel, 0.05%.

Lidex®
(fluocinonide) 0.05%

See following page for summary of prescribing information.

Cryofractured section of psoriatic epidermis photographed en face. Epidermis (EP) is thickened and stratum corneum (SC) is both thickened and highly disorganized. Dark oval depressions are nuclei (N). Stringy adherent material is exuded serum protein (P).

Color imposed on black-and-white photomicrograph magnified 209X.

SYNTEX
SYNTEX LABORATORIES, INC.
PALO ALTO, CALIFORNIA 94304

LIDEX® (fluocinonide)
Cream and Ointment 0.05%

TOPSYN® (fluocinonide)
Gel 0.05%

Summary of prescribing information

Description

LIDEX cream 0.05%, LIDEX ointment 0.05% and TOPSYN gel 0.05% contain the active compound fluocinonide. Fluocinonide, which is the 21-acetate ester of fluocinolone acetonide, has the chemical formula 6α, 9α-difluoro-11β, 16α, 17α, 21-tetrahydroxypregna-1,4-diene-3, 20-dione, cyclic 16, 17-acetal with acetone 21-acetate. LIDEX cream contains fluocinonide in FAPG® cream, a specially formulated cream base consisting of stearyl alcohol, polyethylene glycol 6000, propylene glycol, 1, 2, 6-hexanetriol and citric acid. This white cream vehicle is greaseless, non-staining, anhydrous and completely water miscible. The base provides emollient and hydrophilic properties. In this formulation, the active ingredient is totally in solution.

LIDEX ointment contains fluocinonide in a specially formulated ointment base consisting of Amerchol CAB (mixture of sterols and higher alcohols), white petrolatum, propylene carbonate and propylene glycol. It provides the occlusive and emollient effects desirable in an ointment. In this formulation the active ingredient is totally in solution.

TOPSYN gel contains fluocinonide in a specially formulated gel base consisting of propylene glycol, propyl gallate, disodium edetate, and Carbopol 940 (carboxypolymethylene) with NaOH and/or HCL added to adjust the pH. This clear, colorless, thixotropic vehicle is greaseless, non-staining and completely water miscible. In this formulation, the active ingredient is totally in solution.

Indications

LIDEX cream and ointment and TOPSYN gel are intended for the relief of inflammatory manifestations of corticosteroid responsive dermatoses.

Contraindications

Topical steroids are contraindicated in vaccinia and varicella. Topical steroids are contraindicated in those patients with a history of hypersensitivity to any of the components of the preparation.

Precautions

If irritation develops, the cream, ointment or gel should be discontinued and appropriate therapy instituted. In the presence of an infection the use of an appropriate antifungal or antibacterial agent should be instituted.

If a favorable response does not occur promptly, the corticosteroid cream, ointment or gel should be discontinued until the infection has been adequately controlled.

If extensive areas are treated, the possibility exists of increased systemic absorption and suitable precautions should be taken.

Although topical steroids have not been reported to have an adverse effect on pregnancy, the safety of their use in pregnant females has not absolutely been established. Therefore, they should not be used extensively on pregnant patients, in large amounts or for prolonged periods of time.

LIDEX® (fluocinonide) cream and ointment and TOPSYN® (fluocinonide) gel are not for ophthalmic use.

Adverse reactions

The following local adverse reactions have been reported with topical corticosteroids:

burning	folliculitis
itching	acneform eruptions
irritation	hypopigmentation
dryness	striae
secondary infection	skin atrophy

Dosage and administration

A small amount should be gently massaged into the affected area three or four times daily, as needed.

How supplied

LIDEX Cream 0.05% – 15 g 30 g and 60 g tubes.
LIDEX Ointment 0.05% – 15 g 30 g and 60 g tubes.
TOPSYN Gel 0.05% 15 g and 60 g tubes.

SYNTEX
SYNTEX LABORATORIES, INC.
PALO ALTO, CALIFORNIA 94304

Expand Your Horizons And Those of Your Nursing Home Patients.

This compilation of articles and memoranda is geared to further your understanding of your role in regard to: your nursing home patients; their families; and the nursing home staff. Published by the American Medical Association, **The Medical Director in the Long-Term Care Facility** is the only book of its kind.

The Table of Contents includes:

- Doctor's Role in the Nursing Home
- Medical Direction in Long-Term Care Facilities
- Role Relationships of the Medical Director
- The Role of the Physician in Long-Term Care Facilities—The Administrator's Viewpoint
- Federal Regulations and Proposed Duties for the Medical Director in the Skilled Nursing Facility
- The Nursing Home's Medical Director—A New Breed of Mentor

The Medical Director in the Long-Term Care Facility should help you to meet the nursing home problems which you encounter. Use the coupon to order this valuable compendium today.

$3.50

S/J

Order Dept./OP-22
American Medical Association
535 N. Dearborn/Chicago, IL 60610

Please send _____ copy(ies) of THE MEDICAL DIRECTOR IN THE LONG-TERM CARE FACILITY, OP-22, at $3.50 each. Enclosed is $ _____, payable to the AMA.

Name _____

Address _____

City/State/Zip _____

Head & Shoulders® second to none



*Orentreich, N., *et al.*: Comparative study of two antidandruff preparations, J. Pharm. Sci. *58*:1279 (Oct.) 1969.

Head & Shoulders proved as effective as leading Rx shampoo in dandruff control

Results of a double-blind clinical study, graphically shown at the left, demonstrated that *Head & Shoulders* is as effective in reducing the severity of dandruff as the most commonly prescribed prescription product. The test products were *Head & Shoulders,* a 2.5 per cent Selenium Sulfide Suspension, and a placebo (Head & Shoulders without its active ingredient).

Cosmetically pleasing, easy to use

- Leaves hair clean, manageable, and attractive.
- Requires no change in normal shampooing techniques to achieve therapeutic effect—need not be left on scalp for a specified time.
- Gentle enough to be used every time your patient shampoos.

Head & Shoulders®

A therapeutic shampoo with zinc pyrithione

©1978 BY PROCTER & GAMBLE

Head & Shoulders®

Active Ingredient Zinc Pyrithione suspended in an Anionic Detergent System

COMPOSITION:
Lotion: Zinc Pyrithione in a shampoo base of Water; Tea-Lauryl Sulfate; Cocamide MEA; Triethanolamine; Magnesium Aluminum Silicate; Hydroxypropyl Methylcellulose; Fragrance; FD&C Green #3; and D&C Green #5.

Cream: Zinc Pyrithione in a shampoo base of Water; Sodium Cocoglyceryl Ether Sulfonate; Sodium Chloride; Sodium Lauroyl Sarcosinate; Cocamide DEA; Cocoyl Sarcosine; Fragrance; FD&C Green #3; and D&C Green #5.

INDICATIONS:
Treatment of dandruff and seborrheic dermatitis of the scalp.

PRECAUTION:
Not to be taken internally. Keep out of children's reach. Avoid getting shampoo in eyes—if this happens, rinse eyes thoroughly with water.

DOSAGE:
Use at least twice a week initially for two weeks, and ad libitum thereafter. A minimum of four shampooings are recommended before full antiseborrheic effectiveness should be expected. Testing shows that Head & Shoulders is safe and gentle enough to use for every shampoo.

SUPPLIED:
Lotion form available in 3.6 fl. oz., 6.5 fl. oz., 11.0 fl. oz., 15.0 fl. oz.

Cream form available in 2.4 oz. and 5.0 oz. jars or 1.7 oz., 4.3 oz., and 7.0 oz. tubes.

HSR-327



a quick reference to the AMA's large collection of medical films

and its yours free with the coupon below

You'll find nearly 100 pages of medical motion picture titles and descriptions in this new catalog—well over 300 titles and many of them brand new! All are available on loan basis for a slight service charge.

American Medical Association S/J
535 N. Dearborn St.
Chicago, Ill. 60610
ATTN: Dept. of Audio Visual Self Learning Programs.

Please send me your catalog:
AMA Medical Health Film Library 1976

Name _____

Title _____

Organization _____

Address _____

City _____

State/Zip _____

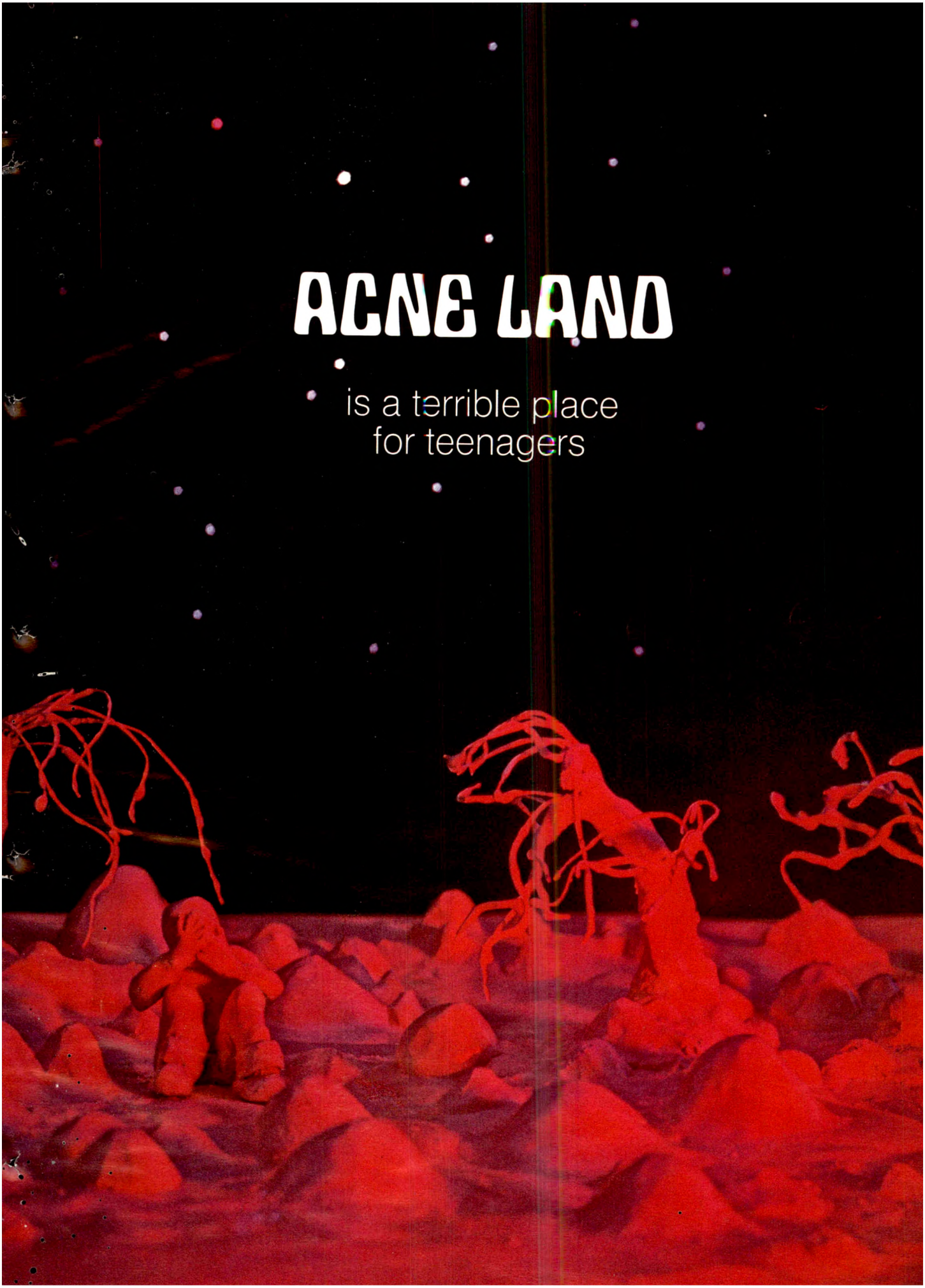
ACNE LAND
is a terrible place
for teenagers

Acne Land
is a terrible place for teenagers
but the Oxyls from Stiefel
make it more liveable

PanOxyl® 5 & 10 Gels

(benzoyl peroxide)

The longest-used, most-widely prescribed and most reported benzoyl peroxide gel

Truly as close a thing as there is to a "drug of choice" for acne, PanOxyl Gels have been prescribed in literally millions of patient experiences. PanOxyl has been found more effective than tetracycline,[1,2] and superior in effectiveness and safety to other topical agents in studies all over the world.[3,4,5,6,7]

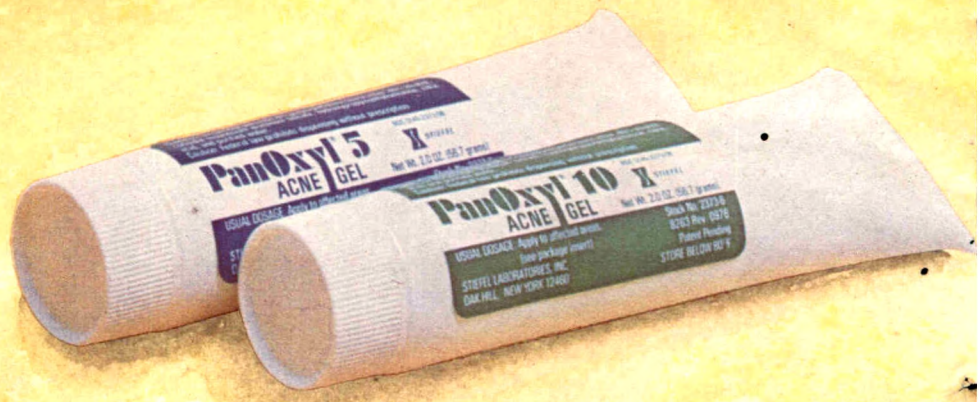

Composition: PanOxyl 5 contains 5% benzoyl peroxide. PanOxyl 10 contains 10% benzoyl peroxide. PanOxyl 5 and PanOxyl 10 also contain 6% polyoxyethylene lauryl ether and 40% ethyl alcohol in a gel base formulated with colloidal magnesium aluminum silicate, hydroxypropylmethylcellulose, citric acid and purified water.

Action and Uses: The topical use of PanOxyl 5 and PanOxyl 10 provides therapeutic control of acne through drying and desquamative action, as well as providing antiseptic activity.

Indications: Use as an aid in the treatment of acne.

Dosage and Administration: Apply 1 or more times daily to affected areas. Washing the face with soap and water prior to application greatly enhances the efficacy of the medication.

Contraindications: Patients with a known sensitivity to benzoyl peroxide should not employ these medications.

Precautions: For external use only. Avoid contact with the eyes or mucosal membranes. Very fair individuals should always be started on a single application at bedtime, allowing the medication to remain on the skin overnight. PanOxyl may bleach colored fabrics.

How Supplied: 2 oz. and 4 oz. plastic tubes.

Caution: Federal law prohibits dispensing without prescription.

U.S. Pat. No. 4056611

Sulfoxyl®

(benzoyl peroxide and sulfur)

Regular and Strong Lotions

Adds the therapeutic benefits of sulfur to benzoyl peroxide

. . . a combination which gives greater effectiveness than either substance used alone.[8] The added drying and desquamative properties of sulfur make Sulfoxyl a logical choice in the presence of excessive oiliness.

Composition: Sulfoxyl Lotion Regular contains 5% benzoyl peroxide and 2% sulfur; Sulfoxyl Lotion Strong contains 10% benzoyl peroxide and 5% sulfur, each in a lotion base formulated with polyethylene glycol monostearate, stearic acid, glycerol monostearate, isopropyl palmitate, propylene glycol, zinc soap and purified water.

Indications: Use as a topical aid in the treatment of acne.

Dosage and Administration: After cleansing the skin, smooth Sulfoxyl Lotion gently into the affected areas, once daily for three days. If no discomfort is felt, frequency of application can then be increased to twice daily. The amount of drying and desquamation can be modified by adjusting the dosage schedule.

Contraindications: Patients with a known sensitivity to benzoyl peroxide, sulfur or any of the other formulation ingredients should not use these medications.

Precautions: For external use only. Avoid contact with eyes, mucous membranes and sensitive areas of the neck. Notify physician if excessive dryness or irritation occurs or increases. Keep from heat.

Caution: Patients should be warned that these formulations may bleach colored linens, towels and apparel.

How Supplied: 1.0 oz. plastic bottles.

Caution: Federal law prohibits dispensing without prescription.

Benoxyl® 5 & 10 Lotions

(benzoyl peroxide)

Simple, economical, therapeutic and versatile

Simple benzoyl peroxide alone may be considered ideal for initiating therapy, for maintenance therapy or for use concomitantly with other agents.

Benoxyl 5 contains 5% benzoyl peroxide and Benoxyl 10, 10% benzoyl peroxide in a grease-free washable base.

Benoxyl 5 and Benoxyl 10 are available in 1 oz. and 2 oz. plastic bottles.

U.S. Pat. No. 3535422

References

1. Fulton, J.E., Jr.: Acne vulgaris. *Current Ther.* ed. Conn., H.F., 558-560, 1975
2. Fulton, J.E., Jr.: Topical antibacterial therapy for acne. *Arch Derm.* **110**, 83-6, July, 1974
3. Liddell, K.: Benzoyl peroxide gel in the treatment of acne vulgaris. *Brit. J. Clin. Pract.* **28**, 10, 379-82, Nov., 1975
4. Hare, P.J.: Benzoyl peroxide gel compared with retinoic acid in acne vulgaris. *Brit. J. Clin. Pract.* **29**: 3, 63-66, Mar., 1975
5. Cotterill, J. A., Harrogate District Hospital: Treatment of acne vulgaris by a benzoyl peroxide gel: a controlled study. *Med. Digest*, **22**:2, Feb., 1977
6. Rassner, G., Director, Department of Dermatology, University of Ulm: The results of trials with benzoyl peroxide acne gel in the treatment of acne vulgaris. Submitted for publication.
7. Constantino, M.A.; Mandelbaum, S.H.; Bechelli, C. and Sampaio, S.A.P.: Treatment of acne vulgaris with benzoyl peroxide and tretincin: comparative study. *Rev. Bras. Clin. Ther.*, **5**: 7, 263-8, July, 1976
8. Kirton, V. and Wilkinson, D.S.: Benzoyl peroxide in acne. *Practitioner*, **204**: 683, 1970

STIEFEL
Logical Dermatologicals

Stiefel Laboratories, Inc.
Oak Hill, N.Y. 12460

OBJECTIVE: TO SEEK OUT AND DESTROY SOLAR KERATOSES

BEFORE

2/6/75—Diffuse hyperplastic solar keratoses over the dorsa of both hands were present at the start of treatment with twice daily applications of Efudex® (fluorouracil) 5% Cream.

DURING

2/21/75—After slightly more than two weeks of therapy, lesions had become inflamed and excoriated, and subclinical lesions not visible before treatment had become inflamed. Treatment was terminated on 2/27/75 and healing was complete within 2 to 3 weeks.

AFTER

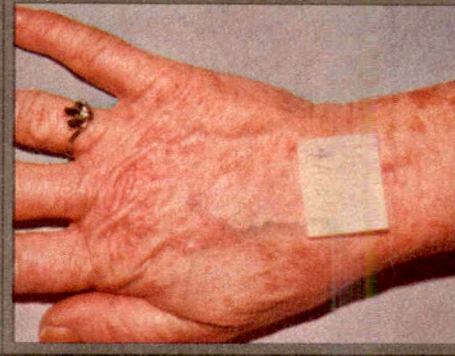

8/4/77—There was no evidence of recurrence at follow-up visit 30 months later. (Note: The redness seen in this photograph is the result of insect bites and is unrelated to the course of therapy.)

Please consult summary of product nformation on third page of this advertisement.

■ AN EFFECTIVE TOPICAL ALTERNATIVE TO SURGERY FOR MULTIPLE LESIONS AND DIFFICULT TREATMENT SITES.

■ COSMETICALLY GRATIFYING RESULTS, WITH MINIMAL OR NO SCARRING.

■ HIGH DEGREE OF SAFETY...SYSTEMIC TOXICITY RARE.

■ CONVENIENT, ECONOMICAL B.I.D. APPLICATION. APPLY WITH CARE NEAR EYES, NOSE AND MOUTH.

AN EXCLUSIVE ROCHE FORMULATION

Efudex® 5% Cream

fluorouracil/Roche

Solar Keratosis—a premalignant lesion

Among any light-skinned population, extended exposure to the sun may lead to solar keratoses, which commonly occur as multiple lesions on exposed portions of the skin. Because they are the most common types of lesions that progress from minor alteration to cancer,[1] they should be treated. Efudex is a proven cytotoxic agent, with a marked effect on more rapidly growing cells.

1. Pinkus H: The border line between cancer and noncancer, in *Year Book of Dermatology*, edited by Kopf AW, Andrade R. Chicago, p. 16. Copyright© 1967 by Year Book Medical Publishers, Inc. Used by permission.

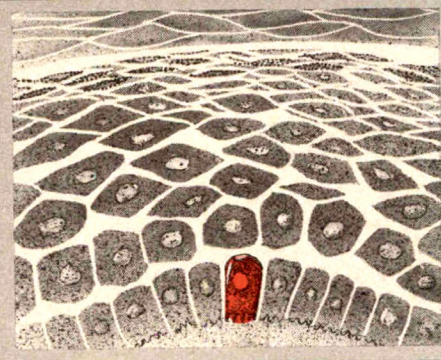

The development of a precancerous epidermal lesion from a germinal basal cell*

This mother cell, with a slightly higher mitotic rate, produces more dysplastic basal cells and also prickle cells.

When these prickle cells reach the surface, a visible clinical lesion results.



These cells undergo parakeratosis and form a scale. The heavy outline denotes dysplastic cell.

*Adapted from Pinkus H: The border line between cancer and noncancer, in *Year Book of Dermatology*, edited by Kopf AW, Andrade R. Chicago, p. 17. Copyright© 1967 by Year Book Medical Publishers, Inc. Used by permission.

INDICATED FOR SUPERFICIAL BASAL CELL CARCINOMA

Management of superficial basal cell carcinoma is often complicated by multiple lesions which may extend over large areas of the body. Conventional treatments such as surgical or radiation therapy are still preferred for single lesions or those in easily accessible locations. However, topical chemotherapy with Efudex (fluorouracil) 5% can be used for the treatment of multiple superficial lesions over large areas of the body as well as difficult treatment sites. Although during treatment with Efudex (fluorouracil) the lesions and some of the surrounding skin may become inflamed and blistered temporarily, final results are cosmetically gratifying

AN EXCLUSIVE ROCHE FORMULATION

Efudex® 5% Cream
fluorouracil/Roche

Before prescribing, please consult complete product information, a summary of which follows:

Indications: Multiple actinic or solar keratoses. In 5% strength, superficial basal cell carcinoma when conventional methods are impractical, such as with multiple lesions or difficult treatment sites. Establish diagnosis before treating, as this method has not been proven effective in other types of basal cell carcinomas. Conventional techniques preferred for isolated, easily accessible lesions, as success rate is nearly 100%. Success rate with Efudex is about 93%.

Contraindications: Patients with known hypersensitivity to any of its components.

Warnings: If occlusive dressing is used, may increase inflammatory reactions in adjacent normal skin. Avoid prolonged exposure to ultraviolet rays. Safe use in pregnancy not established.

Precautions: If applied with fingers, wash hands immediately. Apply with care near eyes, nose and mouth. Solar keratoses failing to respond should be biopsied. Warn patients that treated area may be unsightly during therapy and sometimes for several weeks after. Perform follow-up biopsies in superficial basal cell carcinoma.

Adverse Reactions: Local—pain, pruritus, hyperpigmentation and burning at application site most frequent; also dermatitis, scarring, soreness, tenderness, suppuration, scaling and swelling. Also reported—insomnia, stomatitis, irritability, medicinal taste, photosensitivity, lacrimation, telangiectasia, leukocytosis, thrombocytopenia, toxic granulation and eosinophilia.

Dosage and Administration: When Efudex is applied erythema occurs, then vesiculation, erosion, ulceration, necrosis, epithelization. *Actinic or solar keratosis*—apply sufficient quantity to cover lesions, twice daily. Usual length of therapy is 2 to 4 weeks. *Superficial basal cell carcinomas*—apply sufficient quantity **(only 5% strength recommended)** to cover lesions, twice daily. Continue treatment for at least 3 to 6 weeks, but possibly as long as 10 to 12.

How Supplied: Solution, 10-ml drop dispensers containing 2% or 5% fluorouracil on a weight/weight basis. Cream, 25-Gm tubes containing 5% fluorouracil in a vanishing cream base.

ROCHE

Roche Laboratories
Division of Hoffmann-La Roche Inc.
Nutley, New Jersey 07110

Complete and continuous [illegible]er[illegible]e or tar-re[illegible]p[illegible]n i[illegible] dermatoses encourages full patient co-operation 24 hours a day.

estar® Gel is transparent and virtually odor-free for inconspicuous daytime therapy.

A Balnetar® bath in the evening helps relieve irritating symptoms throughout the night.

Elegant Sebutone® extends tar therapy to the scalp in psoriasis, seborrhea, itchy scalp.

Westwood® Tar products contain the first chemically and biologically standardized tar, bioassayed to insure uniform therapeutic activity. Westwood® Tar is anti-pruritic, keratoplastic, and anti-eczematous.

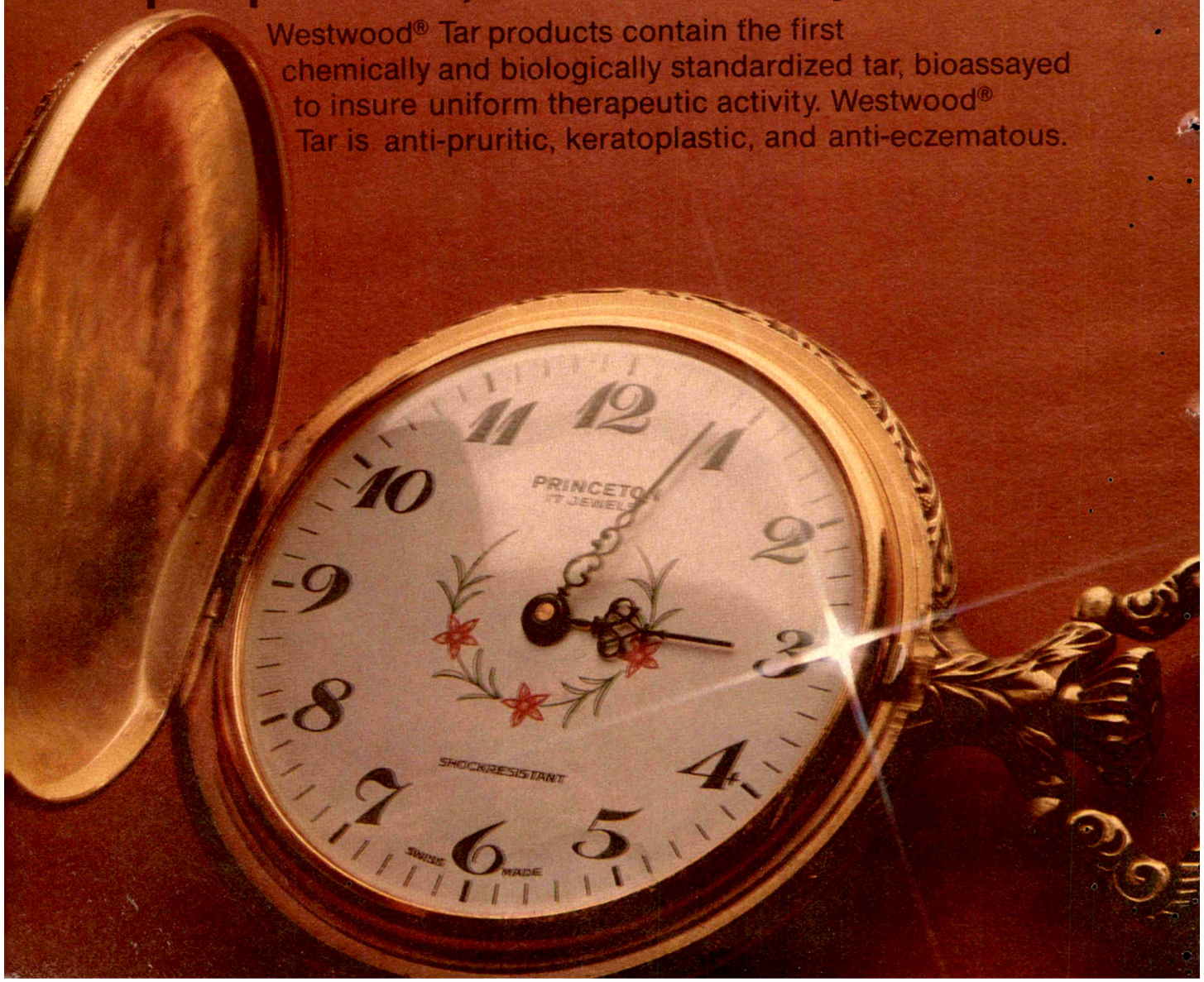

Therapeutic Tar Gel, 3 oz. Plastic Tube. Equivalent to 5% Coal Tar USP

Therapeutic Emollient Tar Bath, 8 fl. oz. Plastic Bottles. Equivalent to 2.5% Coal Tar USP

Antiseborrheic Liquid Tar Shampoo, 4 and 8 oz. Plastic Bottles. Equivalent to 0.5% Coal Tar USP

estar®

Therapeutic Tar Gel. 3 oz. Plastic Tube.

CAUTION: AFTER USING, TREATED AREAS SHOULD BE PROTECTED FROM SUNLIGHT, ESPECIALLY IF ESTAR HAS BEEN USED ON THE FACE. THIS PRECAUTION SHOULD BE TAKEN FOR AT LEAST 24 HOURS AFTER APPLICATION, UNLESS OTHERWISE DIRECTED. ESTAR SHOULD NOT BE USED ON HIGHLY INFLAMED OR BROKEN SKIN. If used on the scalp temporary discoloration of blond, bleached, or tinted hair may occur. If undue irritation develops or increases, the usage schedule should be changed or ESTAR discontinued. Contact with the eyes should be avoided. In case of contact, flush eyes with water.

Slight staining of clothing may occur. Standard laundry procedures will usually remove stains. For external use only.

Balnetar®

Therapeutic Emollient Tar Bath. 8 fl. oz. Plastic Bottle.

CAUTION: If irritation persists, discontinue use. In rare instances temporary discoloration of blond, bleached or tinted hair may occur. In rare cases BALNETAR may cause allergic irritation attributable to coal tar.

PRECAUTION: After use of BALNETAR, patient should avoid exposure to direct sunlight unless sunlight is being used therapeutically in a supervised, modified Goeckerman regimen. Contact with eyes should be avoided. Patient should be cautioned against slipping when BALNETAR is used in bathtub. Also advise patient that use in a plastic or fiberglass tub may cause staining of the tub.

Sebutone®

Antiseborrheic Liquid Tar Shampoo. 4 oz. and 8 oz. Plastic Bottles.

CAUTION: If undue skin irritation develops or increases, discontinue use. In rare instances, temporary discoloration of blond, bleached or tinted hair may occur.

PRECAUTION: Contact with the eyes is to be avoided. In case of contact flush eyes with water.

WESTWOOD
PHARMACEUTICALS INC.
Buffalo, New York 14213
In Canada, Belleville, Ontario K8N 5E9

Clinically proven.
Cosmetically superior.
Conveniently packaged and economically priced.

anywhere on potency without fluorination

The potency of Tridesilon—*nonfluorinated* antiinflammatory topical corticoid—has again been confirmed. In a recently published clinical study,[1] desonide 0.05% was compared with fluocinonide (in identical concentration) for various dermatologic disorders including contact dermatitis, nummular eczema, lichen simplex chronicus, seborrheic dermatitis, and atopic eczema.

The desonide group showed better improvement scores in erythema and scaling after the first week; the two-week scores were not significantly different. "...desonide demonstrated potency and efficacy equivalent to those of the fluorinated compound in the disorders treated, and no adverse effects were noted with the former."[1]

This is added corroboration that with topical steroids potency and efficacy do not always depend on fluorination. Desonide, though nonfluorinated, has shown clinical comparability with the most widely prescribed fluorinated topical steroids.[2]

*Not for ophthalmic use.

References: 1. Barsky S: Clinical comparison of desonide cream with fluocinonide cream in steroid-responsive dermatologic disorders. *Cutis* 18:826, 1976. **2.** Reprints available on request.

Contraindications: Tridesilon (desonide) 0.05% Creme and Ointment, topical steroids, are contraindicated in vaccinia and varicella, and in those patients with a history of hypersensitivity to any of the components of the preparation.
Precautions: If irritation develops, the drug should be discontinued and appropriate therapy instituted.
In the presence of an infection, the use of an appropriate antifungal or antibacterial agent should be instituted. If a favorable response does not occur promptly, the corticosteroid should be discontinued until the infection has been adequately controlled.
If extensive areas are treated or if the occlusive technique is used, the possibility exists of increased systemic absorption of the corticosteroid and suitable precautions should be taken.
Although topical steroids have not been reported to have an adverse effect on pregnancy, the safety of their uses in pregnant females has not absolutely been established. Therefore, they should not be used extensively on pregnant patients, in large amounts, or for prolonged periods of time.
These products are not for ophthalmic use.
Adverse Reactions: The following local adverse reactions have been reported with topical corticosteroids: burning sensations, itching, irritation, dryness, folliculitis, hypertrichosis, acneform eruptions, hypopigmentation.
The following may occur more frequently with occlusive dressings than without such therapy: maceration of the skin, secondary infection, skin atrophy, striae, miliaria.
Dosage and Administration: Apply a thin film of Tridesilon (desonide) to the affected skin and massage lightly. The usual dosage is two or three times daily.
Depot Stocked: *DPSC:* 15 gm: NSN 6505-00-148-6969; 60 gm: NSN 6505-00-148-6968; 5 lb: NSN 6505-01-004-9217. *VA:* 60 gm: SN 6505-00-136266A; 5 lb: SN 6505-01-012-4486A.



Tridesilon®
(desonide) 0.05% creme and ointment

adjunctive therapy in acute and chronic steroid-responsive dermatoses

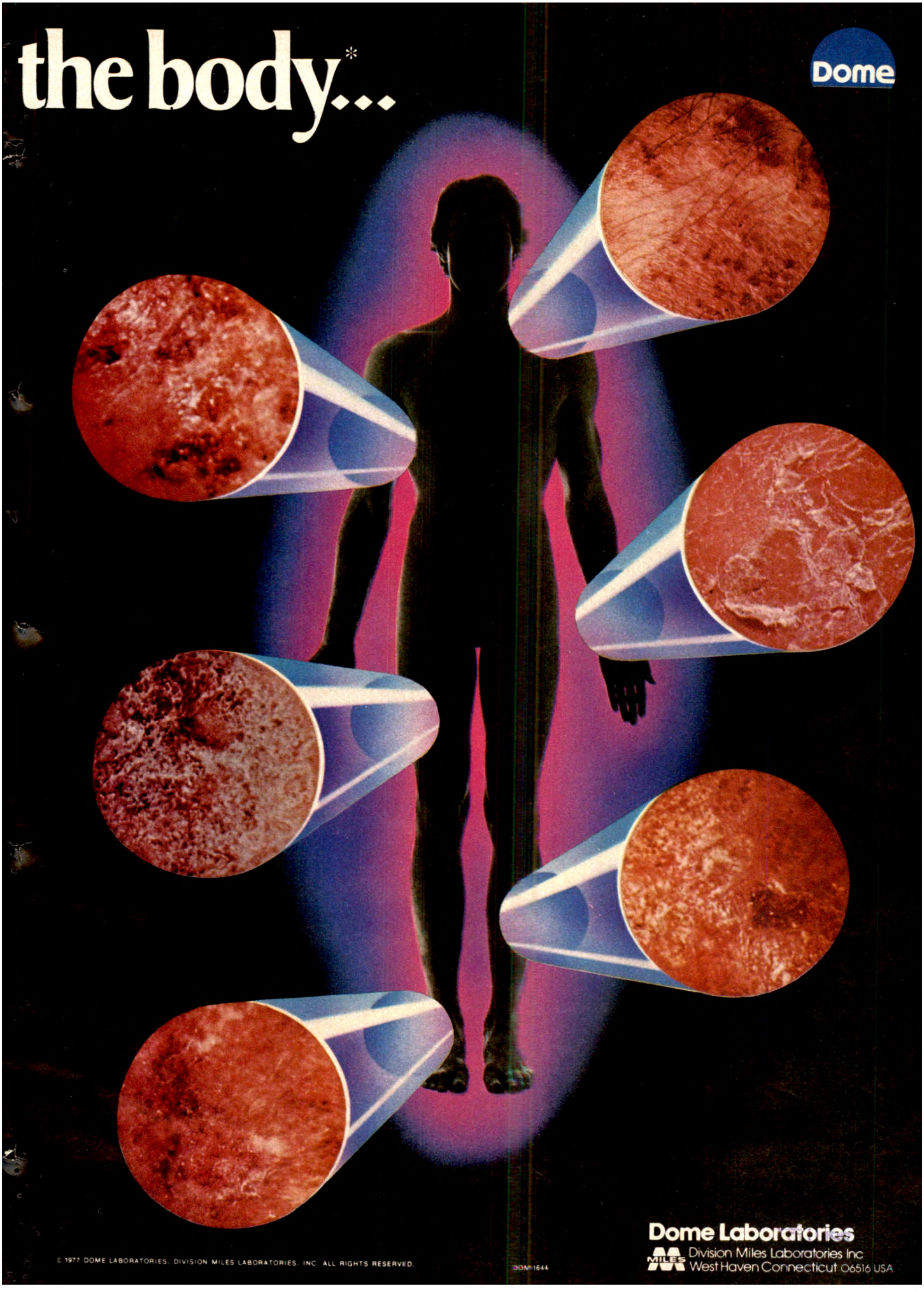
the body*...
Dome
Dome Laboratories
MILES
Division Miles Laboratories Inc
West Haven Connecticut 06516 USA
© 1977 DOME LABORATORIES, DIVISION MILES LABORATORIES, INC. ALL RIGHTS RESERVED.
DOM-1644

For the soap-assaulted skins...

AVEENO® BAR

Uncomplicated soap-free adjunctive therapy.

In treating atopic and contact dermatitis, primary therapy can be hindered by continued use of alkaline soaps...conversely, adjunctive therapy can enhance treatment and reduce complications. AVEENO® BAR is your logical uncomplicator.

- **Soothing action** from 50% (by weight) colloidal oatmeal.
- **Gentle cleansing** – 100% soap-free.
- **Helps restore normal skin pH** – AVEENO® BAR is non-alkaline.

Available in 3.2 oz. and 4.4 oz. bars.



Cooper Cooper Laboratories, Inc., Wayne, New Jersey 07470

New Desquam-X®
(5 OR 10% BENZOYL PEROXIDE, 6% LAURETH-4)
water base gel is not watered down.

Clinically as effective as the alcohol formulation and even more cosmetically acceptable than before.

One study shows Desquam-X10®
(10% BENZOYL PEROXIDE, 6% LAURETH-4)
reduced P. acnes 99.9% in 3 days*

Purpose of the *in vivo* study was to generate data showing the reduction of anaerobic facial bacteria (P. acnes).

Desquam-X 10 was applied b.i.d. No other acne therapy was administered.

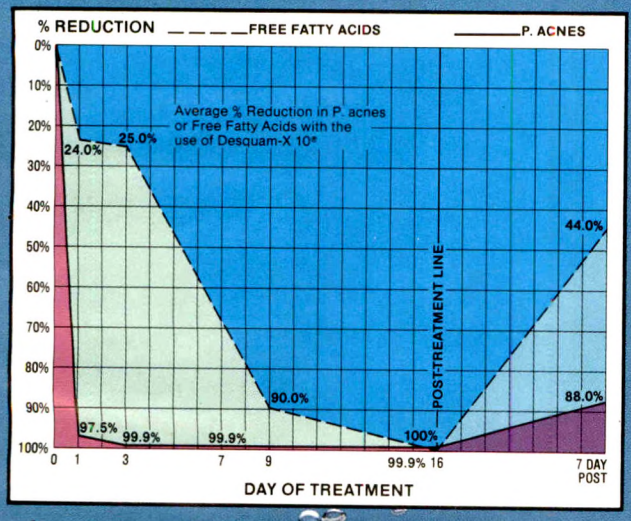

- **Large new 3 oz. tube for patient economy and convenience**
- **Eliminates alcohol sting**

Desquam-X5®	Desquam-X10®
NDC 0072—6621-01—1.5 oz.	NDC 0072—6721-01—1.5 oz.
NDC 0072—6621-03—3 oz.	NDC 0072—6721-03—3 oz.

CONTENTS: Desquam-X5 contains 5% Benzoyl Peroxide, 6% laureth-4, carbomer 940, di-isopropanolamine, disodium edetate and water.

Desquam-X10 contains 10% Benzoyl Peroxide, 6% laureth-4, carbomer 940, di-isopropanolamine, disodium edetate and water.

INDICATIONS: May be used topically alone for mild to moderate acne vulgaris and as an adjunct in therapeutic regimens for severe, complicated acne which might include systemic antibiotics, retinoic acid products and/or sulfur and salicylic acid containing preparations.

ACTION: Provides the desirable drying and desquamation needed in the topical treatment of acne. Desquam-X has been demonstrated to have anti-bacterial effects, especially against Propionbacterium acnes.

DIRECTIONS FOR USE: After washing as instructed, rub Desquam-X into affected areas twice daily. In fair skinned individuals or under excessively dry atmospheric conditions it is suggested that therapy be initiated with one application daily.

The desired degree of drying and peeling can be obtained by modification of the dosage schedule.

CONTRAINDICATIONS: Not to be used in patients known to be sensitive to any ingredient of Desquam-X.

PRECAUTIONS: Avoid contact with eyes and mucous membranes. For external use only. Keep this and all drugs out of the reach of children.

Store below 75°F.

NOTE: May bleach colored fabrics.

HOW SUPPLIED: Plastic tubes 1.5 oz. (42.5g); 3 oz. (85 g).

CAUTION Federal law prohibits dispensing without prescription.

*Data on file, Westwood Pharmaceuticals.



WESTWOOD
PHARMACEUTICALS INC.
Buffalo, New York 14213

©1978, W.P. Inc.

P. acnes come out in the Wash

A recent research study showed Desquam-X® Wash

(4% BENZOYL PEROXIDE)

can reduce P. acnes 87.7% in 1 day*

Purpose of the *in vivo* study was to generate data showing the reduction of anaerobic facial bacteria (P. acnes).

Desquam-X Wash was applied b.i.d. No other acne therapy was administered.

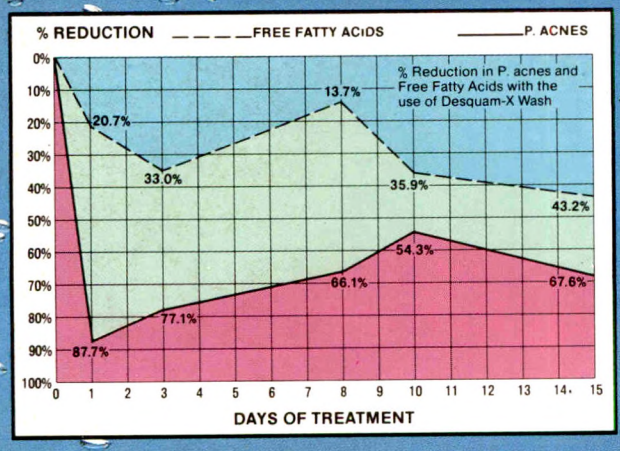

The first benzoyl peroxide cleanser, available only on your Rx.

Desquam-X® Wash (4% Benzoyl Peroxide) THERAPEUTIC CLEANSER

NDC 0072-6900-05

CONTENTS: DESQUAM-X® WASH contains 4% benzoyl peroxide, sodium octoxynol-3-sulfonate, water, sodium dioctyl sulfo-succinate, sodium lauryl sulfoacetate, magnesium aluminum silicate, methocel A4M, EDTA.

INDICATIONS: May be used topically alone for mild to moderate acne vulgaris. In severe, complicated acne Desquam-X Wash may be used as an adjunct to therapeutic regimens which might include antibiotics, retinoic acid products, and/or sulfur and salicylic acid containing preparations.

ACTION: Provides drying and desquamation desirable in the topical treatment of acne. Desquam-X Wash has demonstrated antibacterial activity against Propionibacterium acnes. Desquam-X Wash has also been shown to reduce the concentration of free fatty acids in the sebum.

DIRECTIONS FOR USE: Wash vigorously with Desquam-X Wash once or twice daily, avoiding contact with eyes or mucous membranes. Drying and peeling may be modified by adjusting the dosage schedule.

CONTRAINDICATIONS: Not to be used in patients known to be sensitive to benzoyl peroxide or other ingredients.

PRECAUTIONS: Avoid contact with eyes and mucous membranes. To prevent bleaching, avoid contact with hair. Keep this and all drugs out of the reach of children. For external use only.

NOTE: May bleach colored fabrics. Store below 77°F.

HOW SUPPLIED: Plastic bottles 5 oz. (141.8 g.)

CAUTION: Federal law prohibits dispensing without a prescription.

*Data on file, Westwood Pharmaceuticals.

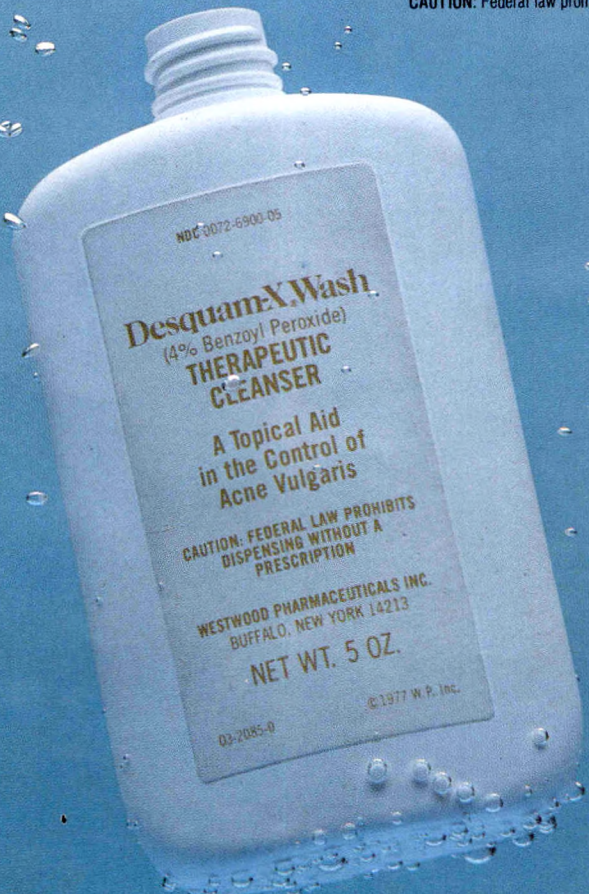

WESTWOOD
PHARMACEUTICALS INC.
Buffalo, New York 14213

©1978, W.P. Inc.

Whenever epidermabrasion is needed...

Many skin conditions can benefit from epidermabrasion—the controlled removal of the stratum disjunctum and other keratin excrescences of the stratum corneum. BUF-PUF offers a pleasant, easy-to-use method for patients to achieve thorough cleansing and smoother, healthier skin from head to toe.

Acne

BUF-PUF loosens comedones while it cleans and helps remove excess oil.

Psoriasis

Used wet or dry, BUF-PUF debrides scales from psoriatic lesions without manifesting a Koebner reaction.

Hyperkeratosis

Rapid, often dramatic results can be seen when BUF-PUF is used to remove the upper layers of toughened or scaly skin.

Keratosis pilaris

BUF-PUF is particularly helpful here because its abrasive action concentrates on the elevated areas of the skin surface.

Tinea versicolor

The gently abrasive action of BUF-PUF helps remove the scales, allowing better penetration of topical therapeutic agents.

BUF-PUF®

Nonmedicated Cleansing Sponge

Riker Laboratories, Inc. SUBSIDIARY OF 3M COMPANY

NORTHRIDGE, CALIFORNIA 91324

© 1978, Riker Laboratories, Inc.

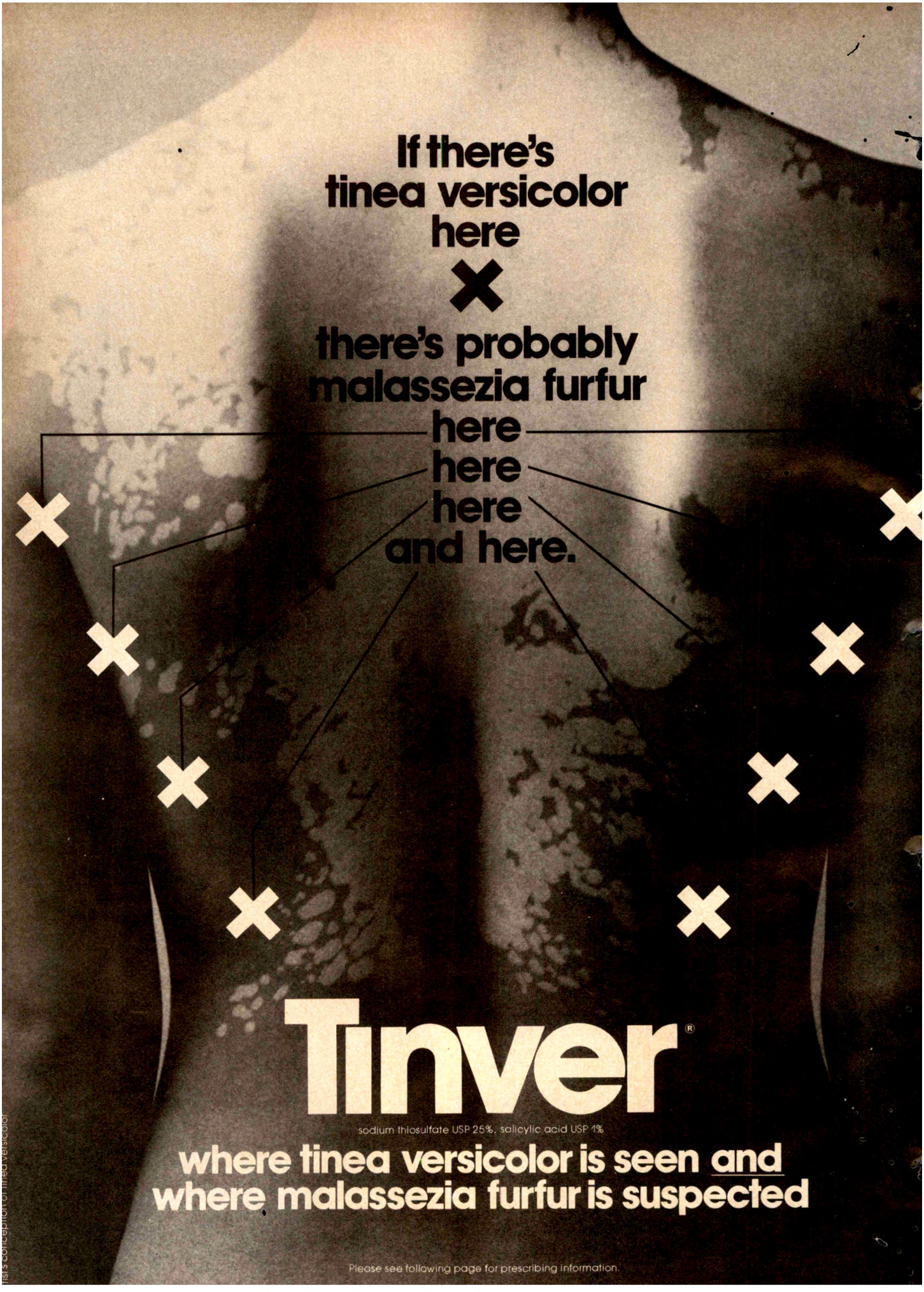

ISI's conception of tinea versicolor

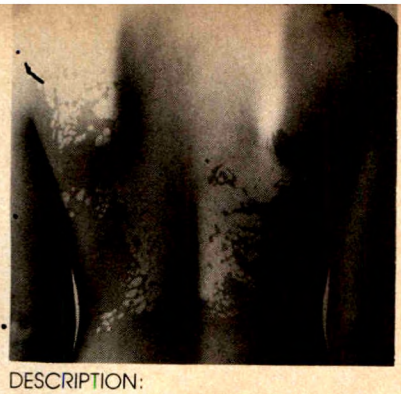

DESCRIPTION:
Sodium thiosulfate 25%, salicylic acid 1%, isopropyl alcohol NF 10%, propylene glycol USP, menthol USP, disodium edetate, colloidal alumina, and purified water.

INDICATIONS:
For topical use in the treatment of tinea versicolor (Malassezia furfur infection).

PRECAUTIONS:
If signs of irritation or sensitivity develop, discontinue use. Do not use on or about the eyes.

ADMINISTRATION:
Thoroughly wash, rinse and dry the affected areas before application of medication. Apply a thin film of lotion to all affected areas and other susceptible areas twice a day. Although diagnostic evidence of the disease may disappear in a few days, it is advisable to continue treatment for a much longer period. Clothing should be boiled to prevent reinfection.

HOW SUPPLIED:
6 fl. oz. plastic dispenser bottles.

CAUTION:
U.S. Federal law prohibits dispensing without prescription.

Barnes-Hind Pharmaceuticals, Inc.
895 Kifer Road
Sunnyvale, California 94086

Tinver®

sodium thiosulfate USP 25%, salicylic acid USP 1%

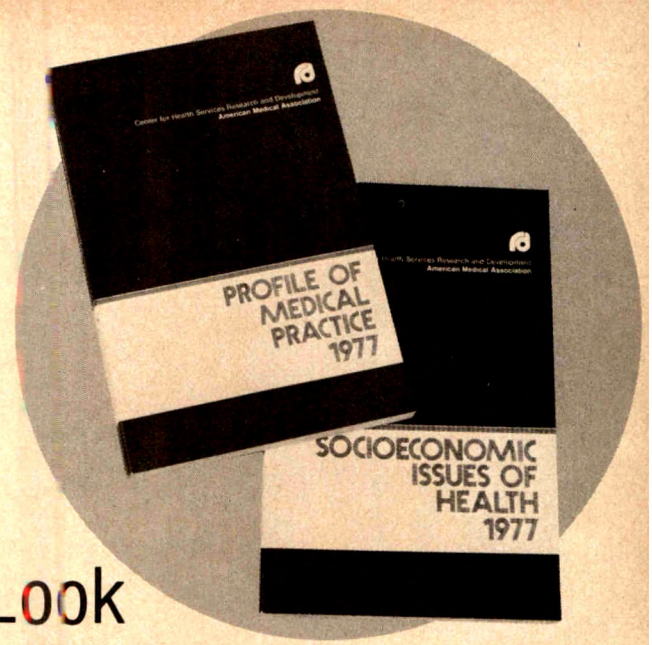

A New Look for the 1977 Red and Blue Books

Those familiar **Red and Blue Books,** published by the American Medical Association's Center for Health Services Research and Development, now have new size. . .new format. . .new data. As a result, you will find them more useful and convenient than ever. Here's a closer look at the 6th annual edition of these authoritative volumes:

Profile of Medical Practice 1977 (Red Book)
The focus is on characteristics of medical practice such as physicians' work patterns, professional expenses, and net income from medical practice. Among the topics covered in short articles are: physician productivity, rural group practice, and hospital utilization by physicians.

Socioeconomic Issues of Health 1977 (Blue Book)
Current data on medical education, medical manpower in the U.S., and financial characteristics of the health services delivery system are featured. Also included are essays on such issues as national health insurance, second surgical opinion programs, and the physician's role in cost accountability.

Quantities are limited, so order today!

S/J

Order Dept.
American Medical Association
535 N. Dearborn
Chicago, IL 60610

_____Profile of Medical Practice (OP-6) $4.50
_____Socioeconomic Issues of Health (OP-5) $4.50

Enclosed is my check for $_____, payable to the American Medical Association.

Name_____

Address_____

City/State/Zip_____

UNIVERSITY COLLEGE OF MEDICINE LIBRARY

Why prescribe two?

(Shown actual size)

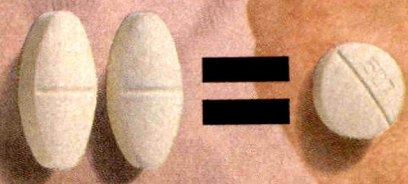

Other Ultramicrosize griseofulvin 125 mg. tablet

New Ultramicrosize FULVICIN P/G 250 mg. tablet

One tablet/once a day for enhanced patient compliance

The new one-a-day convenience of improved, ultramicrosize FULVICIN P/G helps maintain treatment and prevent missed doses.

One-half the dose

Therapeutic effectiveness—enhanced G.I. absorption makes it possible for 250 mg. of FULVICIN P/G to effectively replace 500 mg. of microsize griseofulvin. This is due to a special process by which ultramicrosize griseofulvin crystals, dissolved in P/G (polyethylene glycol), are dispersed throughout the tablet.

Easy-to-swallow tablets

Compare the size of the new 250 mg. tablet of FULVICIN P/G with the two-a-day 125 mg. tablet of the other ultramicrosize griseofulvin.

Significant savings to patients

New, improved FULVICIN P/G is up to 35 per cent less expensive per dose than all microsize griseofulvin formulations.*

Unique dosage flexibility

New, improved FULVICIN P/G is the only ultramicrosize griseofulvin to offer two strengths—125 mg. and 250 mg. tablets—for easy dose titration. And for added flexibility, the tablets are scored.

*Based on list-price comparisons

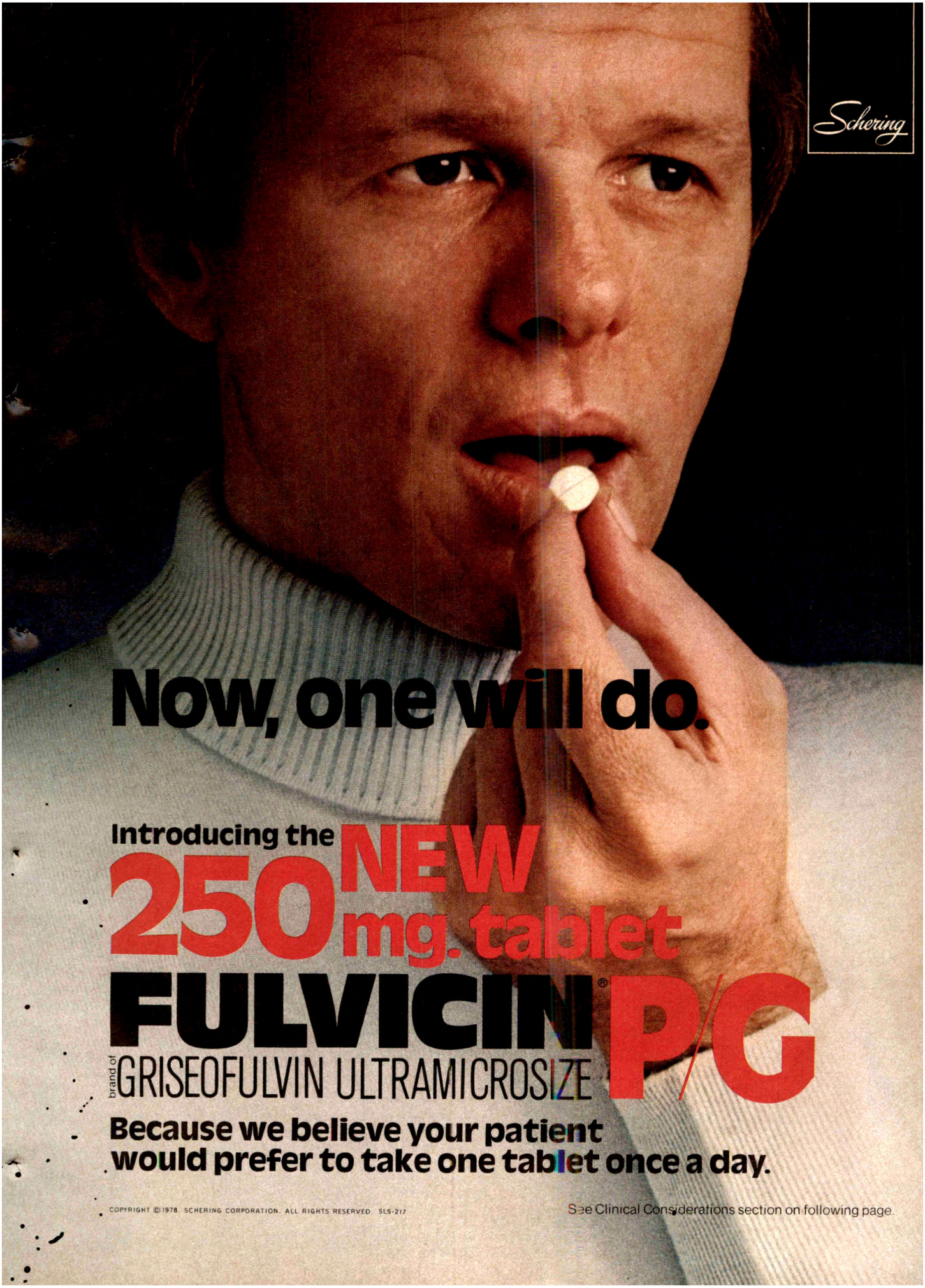
Schering
Now, one will do.
Introducing the NEW 250 mg. tablet
FULVICIN® P/G
brand of GRISEOFULVIN ULTRAMICROSIZE
Because we believe your patient would prefer to take one tablet once a day.
COPYRIGHT © 1978, SCHERING CORPORATION. ALL RIGHTS RESERVED. SLS-217
See Clinical Considerations section on following page.

FULVICIN P/G
GRISEOFULVIN ULTRAMICROSIZE
Tablets

Clinical Considerations: **INDICATIONS** FULVICIN P/G Tablets are indicated for the treatment of ringworm infections of the skin, hair, and nails, namely: tinea corporis, tinea pedis, tinea cruris, tinea barbae, tinea capitis, tinea unguium (onychomycosis) when caused by one or more of the following genera of fungi: *Trichophyton rubrum, Trichophyton tonsurans, Trichophyton mentagrophytes, Trichophyton interdigitale, Trichophyton verrucosum, Trichophyton megninii, Trichophyton gallinae, Trichophyton crateriforme, Trichophyton sulphureum, Trichophyton schoenleinii, Microsporum audouinii, Microsporum canis, Microsporum gypseum,* and *Epidermophyton floccosum.* Note: Prior to therapy, the type of fungi responsible for the infection should be identified. The use of this drug is not justified in minor or trivial infections which will respond to topical agents alone. Griseofulvin is not effective in the following: bacterial infections, candidiasis (moniliasis), histoplasmosis, actinomycosis, sporotrichosis, chromoblastomycosis, coccidioidomycosis, North American blastomycosis, cryptococcosis (torulosis), tinea versicolor, and nocardiosis. **CONTRAINDICATIONS** This drug is contraindicated in patients with porphyria, hepatocellular failure, and in individuals with a history of sensitivity to griseofulvin. **WARNINGS** *Prophylactic Usage:* Safety and efficacy of griseofulvin for prophylaxis of fungal infections have not been established. *Animal Toxicology:* Chronic feeding of griseofulvin, at levels ranging from 0.5-2.5% of the diet resulted in the development of liver tumors in several strains of mice, particularly in males. Smaller particle sizes result in an enhanced effect. Lower oral dosage levels have not been tested. Subcutaneous administration of relatively small doses of griseofulvin once a week during the first three weeks of life has also been reported to induce hepatomata in mice. Although studies in other animal species have not yielded evidence of tumorogenicity, these studies were not of adequate design to form a basis for conclusions in this regard. In subacute toxicity studies, orally administered griseofulvin produced hepatocellular necrosis in mice, but this has not been seen in other species. Disturbances in porphyrin metabolism have been reported in griseofulvin-treated laboratory animals. Griseofulvin has been reported to have a colchicine-like effect on mitosis and cocarcinogenicity with methylcholanthrene in cutaneous tumor induction in laboratory animals. *Usage in Pregnancy:* The safety of this drug during pregnancy has not been established. *Animal Reproduction Studies:* It has been reported in the literature that griseofulvin was found to be embryotoxic and teratogenic on oral administration to pregnant rats. Pups with abnormalities have been reported in the litters of a few bitches treated with griseofulvin. Additional animal reproduction studies are in progress. Suppression of spermatogenesis has been reported to occur in rats, but investigation in man failed to confirm this. **PRECAUTIONS** Patients on prolonged therapy with any potent medication should be under close observation. Periodic monitoring of organ system function, including renal, hepatic, and hematopoietic, should be done. Since griseofulvin is derived from species of *Penicillium,* the possibility of cross sensitivity with penicillin exists; however, known penicillin-sensitive patients have been treated without difficulty. Since a photosensitivity reaction is occasionally associated with griseofulvin therapy, patients should be warned to avoid exposure to intense natural or artificial sunlight. Should a photosensitivity reaction occur, lupus erythematosus may be aggravated. Griseofulvin decreases the activity of warfarin-type anticoagulants so that patients receiving these drugs concomitantly may require dosage adjustment of the anticoagulant during and after griseofulvin therapy. Barbiturates usually depress griseofulvin activity, and concomitant administration may require a dosage adjustment of the antifungal agent. **ADVERSE REACTIONS** When adverse reactions occur, they are most commonly of the hypersensitivity type, such as skin rashes, urticaria, and rarely, angioneurotic edema, and may necessitate withdrawal of therapy and appropriate countermeasures. Paresthesias of the hands and feet have been reported rarely after extended therapy. Other side effects reported occasionally are oral thrush, nausea, vomiting, epigastric distress, diarrhea, headache, fatigue, dizziness, insomnia, mental confusion, and impairment of performance of routine activities. Proteinuria and leukopenia have been reported rarely. Administration of the drug should be discontinued if granulocytopenia occurs. When rare, serious reactions occur with griseofulvin, they are usually associated with high dosages, long periods of therapy, or both. **HOW SUPPLIED** FULVICIN P/G Tablets, 125 mg., white, compressed, scored tablets impressed with the Schering trademark and product identification numbers, 228; bottle of 100. FULVICIN P/G Tablets, 250 mg., white, compressed, scored tablets impressed with the Schering trademark and product identification numbers, 507; bottle of 100. **Store at controlled room temperature 59°F to 86°F (15°C to 30°C).**
10705266 JANUARY 1978

For more complete details, consult package insert or Schering literature available from your Schering Representative or Professional Services Department, Schering Corporation, Kenilworth, New Jersey 07033.

How are you keeping up with happenings in your specialty?

Keep up-to-date with an AMA Specialty Journal. Month after month, it will bring you articles on original research, news of medical significance, and comments on current events in the specialty field of your interest.

Start an AMA Specialty Journal coming today.

- ☐ American Journal of Diseases of Children
- ☐ Archives of Dermatology
- ☐ Archives of General Psychiatry
- ☐ Archives of Internal Medicine
- ☐ Archives of Neurology
- ☐ Archives of Ophthalmology
- ☐ Archives of Otolaryngology
- ☐ Archives of Pathology and Laboratory Medicine
- ☐ Archives of Surgery

	U.S. & Poss.	All Other Countries
☐ 24 issues.....	$28.00	$38.00
☐ 12 issues.....	$18.00	$28.00

Payment must accompany all orders. Make checks payable to the American Medical Association.

Name _____

Address _____

City _____ State _____ Zip _____

Return to: Subscription Department, AMA
535 North Dearborn St., Chicago, Ill. 60610

PREDICTION:

There will be 3 Eclipses in 1978.

INTRODUCING NEW ECLIPSE® GEL:

Non-comedogenic, it provides superior protection from sun damage for your patients with acne or oily skin.

INTRODUCING NEW ECLIPSE® LIP AND FACE PROTECTANT:

Convenient stick form moisturizes while it protects against burning, chapping and drying effects of sun, wind and cold.

ORIGINAL ECLIPSE® LOTION:

Combines the superior efficacy of two PABA esters with the moisturizing Aquacare® base to protect your patients with dry to normal skin.

THE ECLIPSE® FAMILY OF SUNSCREENS:

- Provide maximum skin protection. Absorb more than 99% of burning rays.
- Lotion and Gel contain 6% PABA esters... superior to 5% PABA formulations.
- Continue to protect after swimming with superior wash-off resistance.
- Do not develop unsightly and uncomfortable peeling of formulation.
- Protect immediately upon application. Patient does not have to wait before exposure.
- Are formulated to protect every patient skin type in every type of weather.

Herbert Laboratories • Dermatology Division of Allergan Pharmaceuticals, Inc., Irvine, CA 92713, U.S.A.

THE ONLY WAY TO END THE EPIDEMIC IS OVER HER DEAD BODY.

Kill the female itch mite (*sarcoptes scabiei*) and you've stopped the current scabies epidemic. Because when she burrows deep into the stratum corneum, she defies diagnosis and resists removal by surface-acting medications and cleansers. Her success has been making headlines around the country—with reports of scabies outbreaks in rural and suburban areas as well as in the cities.

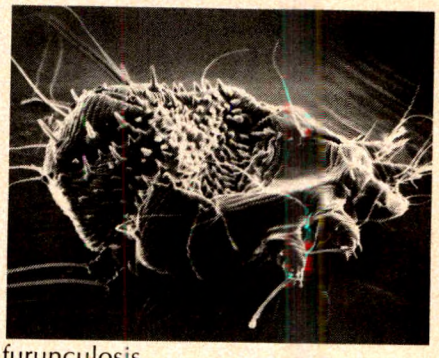

A quick and simple diagnosis. Scabies can mimic a number of dermatological conditions,[1-3] such as urticaria, furunculosis and dermatitis—as well as syphilis with which it may coexist. But there's an almost foolproof way to recognize it. Even in the absence of the fierce nocturnal itching[3] and the lesion distribution characteristic of the disease (hands, wrists and elbows in 9 out of 10 cases),[1] a quick microscopic look can confirm your scabies diagnosis.

To demonstrate the itch mite, look for an unscratched, inhabited burrow (wherever the patient says he itches at that very moment is a likely spot). Use a strong light, a magnifying glass and a surgical blade to which a drop of mineral oil is added. Scrape several sites. Transfer the material to a slide, cover and examine under low power magnification.[1,3,4] (If you don't spot any parasites in egg, larvae or adult stages, look for their red fecal compactions. They can be just as diagnostic.)

Kwell: penetrating action to kill mites, their eggs and larvae. Once you've found scabies, there's a positive way to eradicate it. Kwell (1% gamma benzene hexachloride) Lotion or Cream. It penetrates to reach the scabietic burrows, kills the female mites and, of course, the less tenacious males, as well as their eggs and any larvae that may have hatched. In fact, Kwell works so consistently and well against scabies that it has been the most widely prescribed scabicide for three decades.

Nearly 100% effective. The clinical record of Kwell has never been surpassed by any other pediculicide. It is "nearly 100% effective,"[1] and often works with a single application (a second or third application may be made at weekly intervals, if needed). Your patients will appreciate the low risk of sensitization and irritation.[5,6] And you will appreciate that Kwell works so predictably that it serves to confirm your diagnosis of scabies. Not many pharmaceutical preparations can match *that* record of dependability.

Contraindications: Kwell is contraindicated in individuals who develop hypersensitivity to the product or to any of its components.

Precautions: If accidental ingestion occurs, prompt institution of gastric lavage will rid the body of large amounts of the toxicant. However, since oils favor absorption, saline cathartics for intestinal evacuation should be given rather than oil laxatives.

Central nervous system manifestations can be antagonized by the administration of pentobarbital or phenobarbital in sufficiently large doses to the limit of their therapeutic effectiveness. It is not desirable to depress the patient to the point of hypnosis. However, persons poisoned with stimulants may tolerate large doses of barbiturate without undue depression and with great benefit. Intravenous calcium gluconate may be used in conjunction with the barbiturates. Epinephrine should not be used because ventricular fibrillation may result.

If accidental contact with eyes occurs, flush with water. If irritation or sensitization occurs, discontinue the product and consult physician.

Adverse Reactions: Eczematous eruptions due to sensitization of this product have been reported.

Available on prescription as Kwell Lotion in 2 and 16 fl. oz. bottles, and as Kwell Cream in 2 oz. and 1 lb. jars. See package insert for complete prescribing information.

References: 1. *Patient Care 7*:94, Nov. 1, 1973. 2. Stankler, L.: *Practitioner 210*:803, June 1973. 3. Domonkos, A.N. (ed.): Andrews' Diseases of the Skin: Clinical Dermatology, ed. 6, Philadelphia, W. B. Saunders Company, 1971, pp. 511-513. 4. Muller, G., *et al: Arch. Dermatol. 107*:70, Jan. 1973. 5. James, B.H.E.: *Br. Med. J. 1*:178, Jan. 15, 1972. 6. Sollman, T.: A Manual of Pharmacology, ed. 8, Philadelphia, W. B. Saunders Company, 1957, p. 178.

SEM Courtesy of J. M. Rower, M.D., Columbus, Ohio.

Reed & Carnrick / Kenilworth, New Jersey 07033

Cream/Lotion

KWELL® gamma benzene hexachloride

THE SCABICIDE OF CHOICE.

An unsurpassed standard of therapy

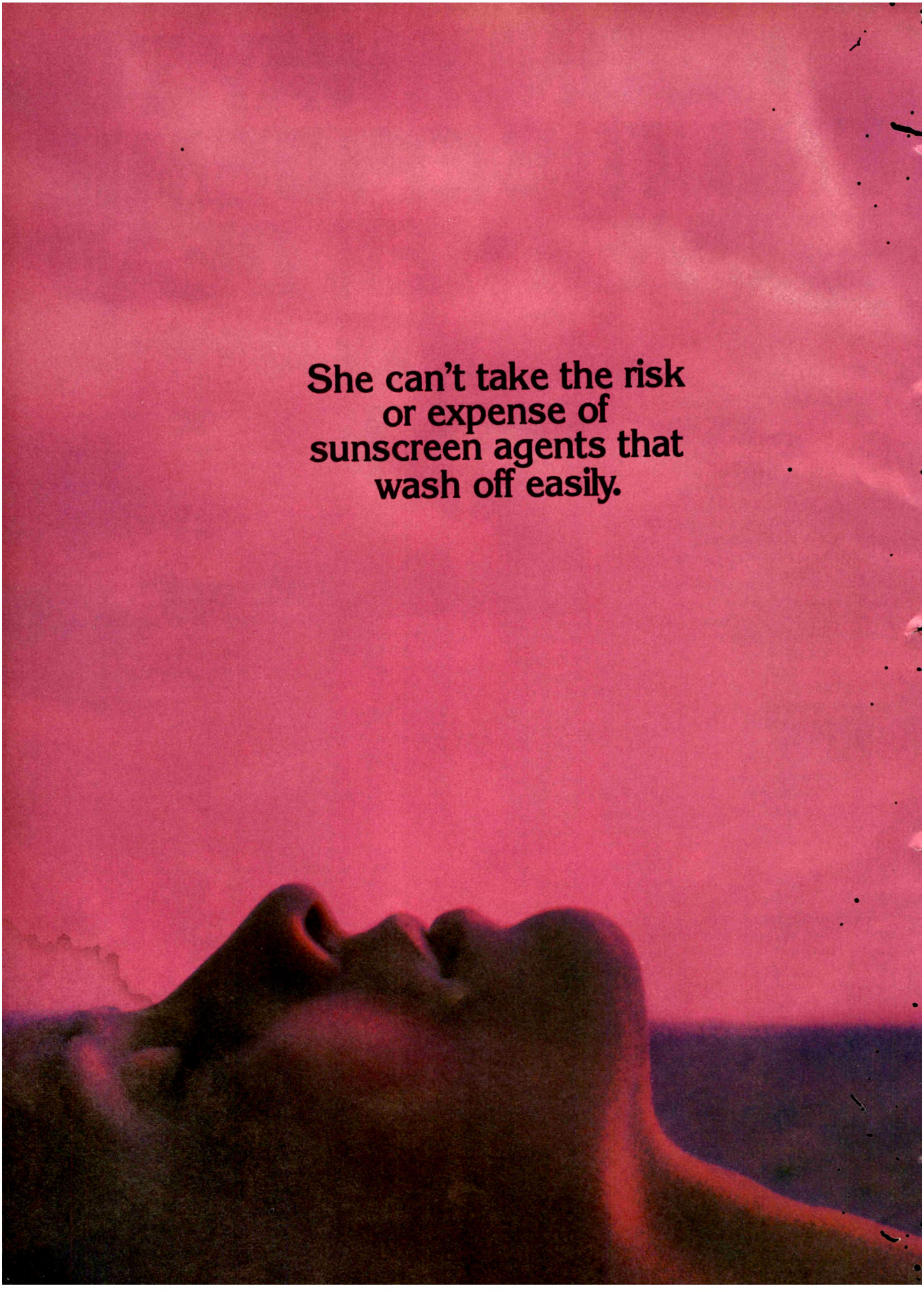
She can't take the risk
or expense of
sunscreen agents that
wash off easily.

Dome

SunGard® Lotion

Effective yet economical, because its excellent durability means fewer applications.

SUNGARD provides more durable protection on the skin than PABA 5% or octyl dimethyl PABA 3.3%* (amount of sunscreen agent remaining on skin after water-wash procedure).

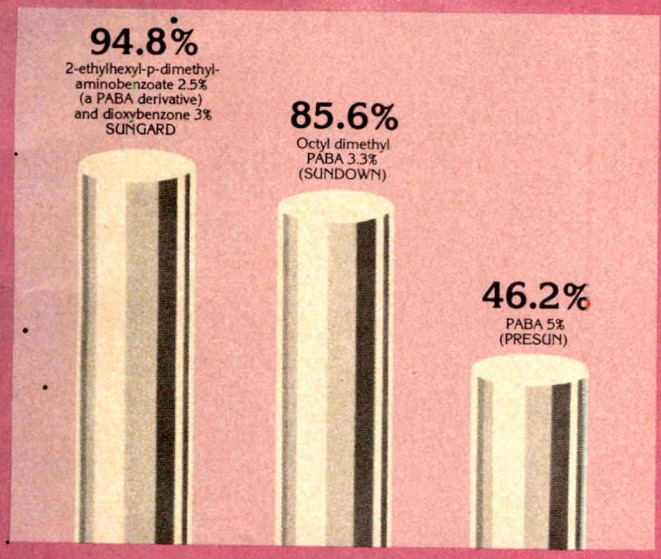

*Data on file at Dome Laboratories.

Broad-range effectiveness
SUNGARD protects against more than just the sunburn (UVB) spectrum—it provides some protection in the photosensitivity (UVA) range as well.

Greater economy from greater substantivity
The more sunscreen remaining on the skin, the better the protection and the fewer applications required to maintain effective protection. As with other sunscreen agents, however, caution your patients about the importance of maintaining continuous protection by reapplying SUNGARD every 3 to 4 hours.

SPF (Sun Protection Factor) 6.3
SUNGARD Lotion is an extra-protection sunscreen product. It allows patients to stay in the sun 6 times as long as before without burning provided there is no heavy perspiration or prolonged swimming.

Yet SUNGARD permits tanning
With SUNGARD, sun-sensitive patients enjoy protection in the erythema range and moderate protection in the photosensitivity range. This permits gradual, natural tanning with repeated exposure to the sun.

SUNGARD...from the company that is a leader in skin-care products.

Dome Laboratories
Division Miles Laboratories Inc MILES
West Haven Connecticut 06516 USA

© 1978 DOME LABORATORIES, DIVISION MILES LABORATORIES, INC. ALL RIGHTS RESERVED. DOM-1694

The good news. The bad news.

American Medical News reports all the news you need to know!

Some of the news about medicine these days is pretty encouraging; some of it is frankly discouraging.

American Medical News prints both kinds of news—good and bad— because you need to know about those developments that could affect the way you practice medicine.

If you want to read just good news and praises of the profession, *American Medical News* isn't your kind of paper. It is a professional newspaper, not a house organ. The AMA Board of Trustees has ordered it to operate that way. That means that *American Medical News* prints both sides of a controversy; it prints what other people say about doctors; it asks discomforting questions; it prints a vast array of stimulating opinions from readers.

Give *American Medical News* just 30 minutes a week; it will give you all the news you need to know about what's happening in the practice of medicine.

Keeping your finger on the pulse of medicine

American Medical
NEWS

An Informed Membership Is Our Greatest Strength

JANUARY 30, 1978

Carter's '79 budget: More aid for children, less money for schools

President Carter's budget for 1979 contains big increases in funding for child health, and Medicare and Medicaid programs, with substantial cuts in capitation grants for medical education. The increase in the total funding of the National Institutes of Health has been limited to 1.5%, which will not keep up with the rate of inflation in 1979, expected to be approximately 6%.

The Carter budget proposed for fiscal year 1979 (Oct. 1, 1978 to Sept. 30, 1979) contains these proposals:

- A $118-million increase in Medicaid for low-income pregnant women to provide pre-natal care and related ser-
- ...ded child health assess- ... million. The ... for health services for adolescents, with emphasis on prevention of unwanted pregnancy.
- A $34-million increase in funding for professional standards review organizations.

PSRO funding at $174 million for 1979 will be sufficient to blanket the country and review all Medicaid, Medicare, and child health procedures, HEW officials say. Instead, greater use of sampling techniques will allow the program to pick target areas, for review. Surgery will likely be the first target.

- A one-third reduction in capitation assistance to medical, osteopathic, and dental schools. Schools of public health will be funded at the 1978 level. Support for most nursing programs will end. HEW officials say the net effect will be ... medical school tuition and fun- ... the national health service corps and related scholarship programs.

The biggest money item in the health budget is Medicare and Medicaid, which together make up 23% of HEW's budget. This is a significant rise from 1973 when the two programs made up 18% of HEW's budget. Medicare hospital insurance payments will rise 15.3% in 1979 and Medicaid payments to physicians (not including the new programs in child health) will rise about 11%.

The Office of Management and Budget anticipates total outlays for these two programs to be $41.5 billion in 1979, if the Administration's hospital cost containment legislation is enacted by July 1.

"If these proposals are not enacted, the 1979 estimate will be $1.1 billion higher," say Health Care Financing Administration officials.

A modest increase was proposed in funding for health maintenance organizations. HEW proposed $5.3 million for 70 new HMO feasibility grants. HEW wants 172 HMOs operating by 1982, and anticipates there will be 5 million people enrolled in these plans by that time.

Funding for health planning agencies will basically keep pace with inflation. A $9-million increase will bring the planning budget to $152 million.

No major changes in the level of health services in the Veterans Administration were proposed. The VA's health budget will increase about 7% to cope with inflation.

Funds for clinical research in 1979 will be tighter. NIH's budget has leveled off and is shrinking slightly due to inflation. The only exception to this is the National Institute of Child Health and

(See Budget . . . . p. 13)

...rikes a possibility
... hospitals

what's best for the care of dry,
or premature aging
or wrinkled skin...
DUE TO EPIDERMA
DEHYDRATION?
DEEP-ACTION MOISTURIZER
formula 405®
DOAK
DEEP-ACTION MOISTURIZER
formula 405®
for the care of dry, aging and wrinkled skin
water-washable
contains no hormone
DOAK
SUPPLIED: 2 OZ. TUBES
WRITE FOR SAMPLES
DOAK PHARMACAL CO., INC. WESTBURY, N.Y. 115
DISTRIBUTOR IN CANADA
TRANS-CANADA DERMAPEUTICS LTD., MONTREAL H4P2B5, QUE

WHEN DERMATOSES TAKE SHAPE

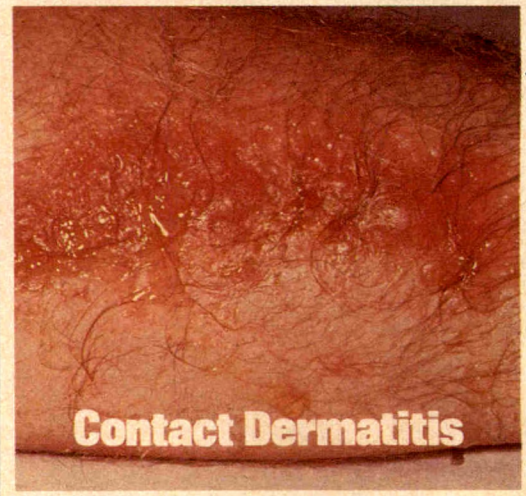

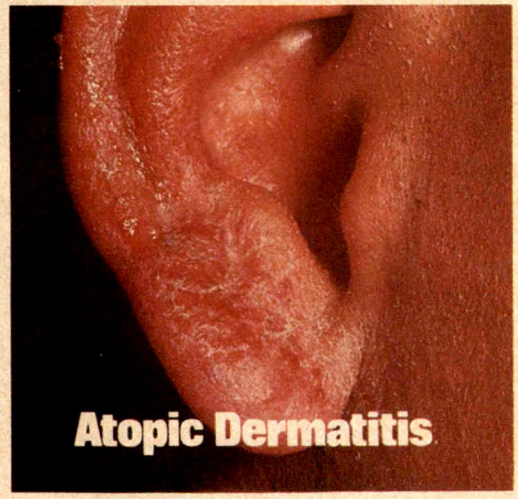

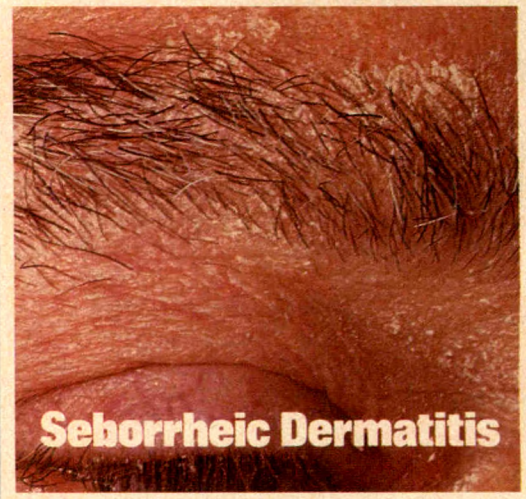

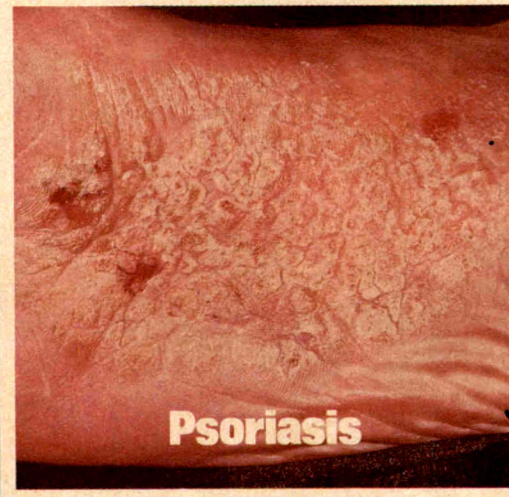

COPYRIGHT © 1977, SCHERING CORPORATION. ALL RIGHTS RESERVED. SLS-866

Schering

DIPROSONE® TAKES CHARGE!

BRAND OF
BETAMETHASONE
DIPROPIONATE

Prompt and Effective Topical Action for Everyday Steroid-Responsive Dermatoses

- Rapid onset of response
- Economy and convenience of b.i.d. dosage
- Occlusive dressings rarely needed
- Sensitivity is unusual



Available for prescribing flexibility in cream, ointment, and lotion. Also available in aerosol, which is indicated for contact dermatitis only.

Please see Clinical Considerations section which follows...

DIPROSONE®
brand of betamethasone dipropionate
Cream 0.05%, Ointment 0.05%, Lotion 0.05% w/w, Aerosol 0.1% w/w
(Potency expressed as betamethasone)
For Dermatologic Use Only

ACTIONS: DIPROSONE **Cream, Ointment, Lotion,** and **Aerosol** are primarily effective because of their anti-inflammatory, antipruritic, and vasoconstrictive actions.

INDICATIONS: DIPROSONE **Cream, Ointment,** and **Lotion** are indicated for the relief of the inflammatory manifestations of corticosteroid-responsive dermatoses.

DIPROSONE **Aerosol** is indicated solely for the adjunctive topical management for the relief of inflammatory manifestations of acute contact dermatitis.

DIPROSONE **Aerosol** has not been shown to be effective in any steroid-responsive dermatosis other than contact dermatitis.

CONTRAINDICATIONS: DIPROSONE **Cream, Ointment, Lotion,** and **Aerosol** are contraindicated in vaccinia and varicella. Topical steroids are contraindicated in those patients with a history of hypersensitivity to any of the components of such preparations.

DIPROSONE **Aerosol** is also contraindicated for use under occlusive dressings.

WARNINGS FOR DIPROSONE AEROSOL: Keep DIPROSONE **Aerosol** away from eyes or other mucous membranes. Use only as directed; intentional misuse by deliberately concentrating or inhaling the contents can be harmful or fatal. Avoid freezing of the tissue by not spraying for more than three seconds, at a distance of not less than six inches. Contents under pressure. Do not puncture. Do not use or store near heat or open flame. Exposure to temperatures above 120° Farenheit may cause bursting. Never throw container into fire or incinerator. Keep DIPROSONE **Aerosol** out of reach of children.

PRECAUTIONS: If irritation develops with the use of DIPROSONE products, treatment should be discontinued and appropriate therapy instituted. In the presence of an infection, the use of an appropriate antifungal or antibacterial agent should be instituted. If a favorable response does not occur promptly, the corticosteroid should be discontinued until the infection has been adequately controlled.

If extensive areas are treated or if the occlusive technique is used, the possibility exists of increased systemic absorption of the corticosteroid and suitable precautions should be taken. Although topical steroids have not been reported to have an adverse effect on pregnancy, the safety of their use in pregnant females has not been absolutely established. Therefore, they should not be used extensively in pregnant patients, in large amounts or for prolonged periods of time. DIPROSONE products are not for ophthalmic use.

ADVERSE REACTIONS: The following local adverse reactions have been reported with topical corticosteroids: burning; itching; irritation; dryness; folliculitis; hypertrichosis; acneiform eruptions; hypopigmentation. Additionally, the following may occur with DIPROSONE **Aerosol** and also may occur more frequently with occlusive dressings than without such therapy: maceration of the skin; secondary infection; skin atrophy; striae; miliaria.

DOSAGE AND ADMINISTRATION: DIPROSONE **Cream** and **Ointment** are applied as a thin film over the affected skin areas twice daily, in the morning and at night. Clinical studies of DIPROSONE have indicated that applications twice a day are generally adequate.

Apply a few drops of DIPROSONE **Lotion** to the affected areas and massage lightly until it disappears. Apply twice daily, in the morning and at night. For the most effective and economical use, apply nozzle to affected area and gently squeeze bottle.

DIPROSONE **Aerosol** may be held upright or inverted during use. The spray should be directed onto the affected area from a distance of not less than six inches and applied for only three seconds. Apply DIPROSONE **Aerosol** sparingly to the affected skin area three times a day.

Aerosol packaged by Aerosol Techniques, Inc., Armstrong Laboratories Division, West Roxbury, MA. 02132.

For more complete details, consult package insert or Schering literature available from your Schering Representative or Professional Services Department, Schering Corporation, Kenilworth, New Jersey 07033.

DECEMBER 1977

Dx: recurrent herpes labialis

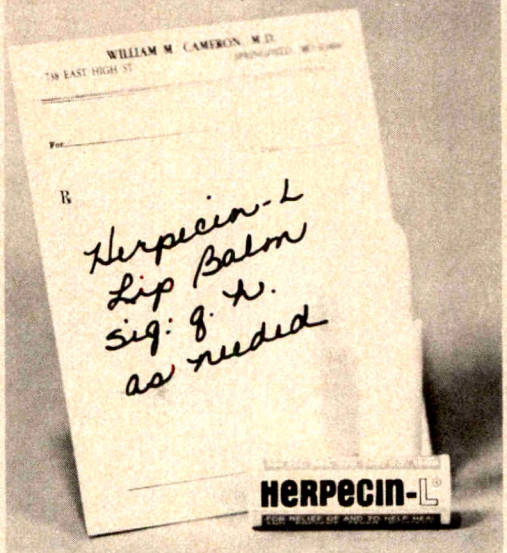

OTC
See PDR for Product Information

For samples, write Dept. J at:

CAMPBELL LABORATORIES, INC.
P.O. Box 812, FDR, N.Y., N.Y. 10022

JOIN US.

AMA
AMERICAN MEDICAL ASSOCIATION

We can do much more together.

now available

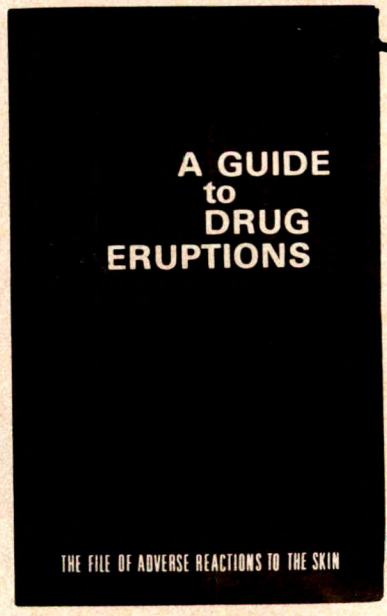

published by
the File of Adverse Reactions to the Skin, department of dermatology, Free University, Amsterdam.

in its completely updated

second edition.

viii+112 pages, 205 lit. refs., numerous tables with incidence figures for the common type of adverse reactions.

reviews:
Arch. Dermatol.: The book is highly recommended as a brief reference.

J. Invest. Derm.: In summary, the Guide can enthousiastically be recommended as a handbook for use when searching for the offending drug in a drug eruption.

Brit. J. Derm.: well worthwhile getting the second edition of this invaluable ready reference book.

get the guide simply

by sending your name and address to:
De Zwaluw, P.O.Box 21, Oosthuizen, The Netherlands.
Enclose $ 15.— (postage included)

de zwaluw
medical publications by mail order

Acne on back and shoulders—within easy reach

BUF™ BODY SCRUB

features BUF-PUF® Nonmedicated Cleansing Sponge on a contoured reusable handle

- **thoroughly cleanses the skin and removes excess oil**
- **helps loosen and remove comedones**
- **aids removal of hyperkeratotic skin**

Also helps manage psoriasis

Clinical investigation* revealed BUF-PUF debrided thick psoriatic scales. The adjunctive use of BUF-PUF to mechanically remove scale build-up may help topical anti-psoriatic agents to better penetrate the stratum corneum. No evidence of any Koebner reaction or other adverse effects was observed.

*Shellow, W. V.R., "The Use of a Polyester Fiber Sponge as an Adjunct in the Treatment of Psoriasis." Submitted for publication.

©1977 **Riker Laboratories, Inc.** NORTHRIDGE, CALIFORNIA 91324 — DIVISION OF 3M



A safe, economical method of permanent hair removal— from face, legs, body

To save valuable office time, you can confidently recommend Perma Tweez to your patients for their home use.

- Battery-operated instrument self-sterilizes when current flows.
- Patented self-correcting needle.
- No-puncture safety feature helps prevent infection.
- Proved clinically safe (report on request).

FOR PHYSICIAN ORDERING

GENERAL MEDICAL CO., Dept D-97
1935 Armacost Ave.
West Los Angeles, CA 90025

30 DAY FREE TRIAL EXAMINATION.
(May be returned with no obligation.)

- ☐ PERMA TWEEZ $19.95
- ☐ ATTACHMENT $3.00 (for treating others)
- ☐ INVOICE AFTER 30 DAYS
- ☐ CHECK ENCLOSED

DR_____

STREET_____

C/S_____ ZIP_____

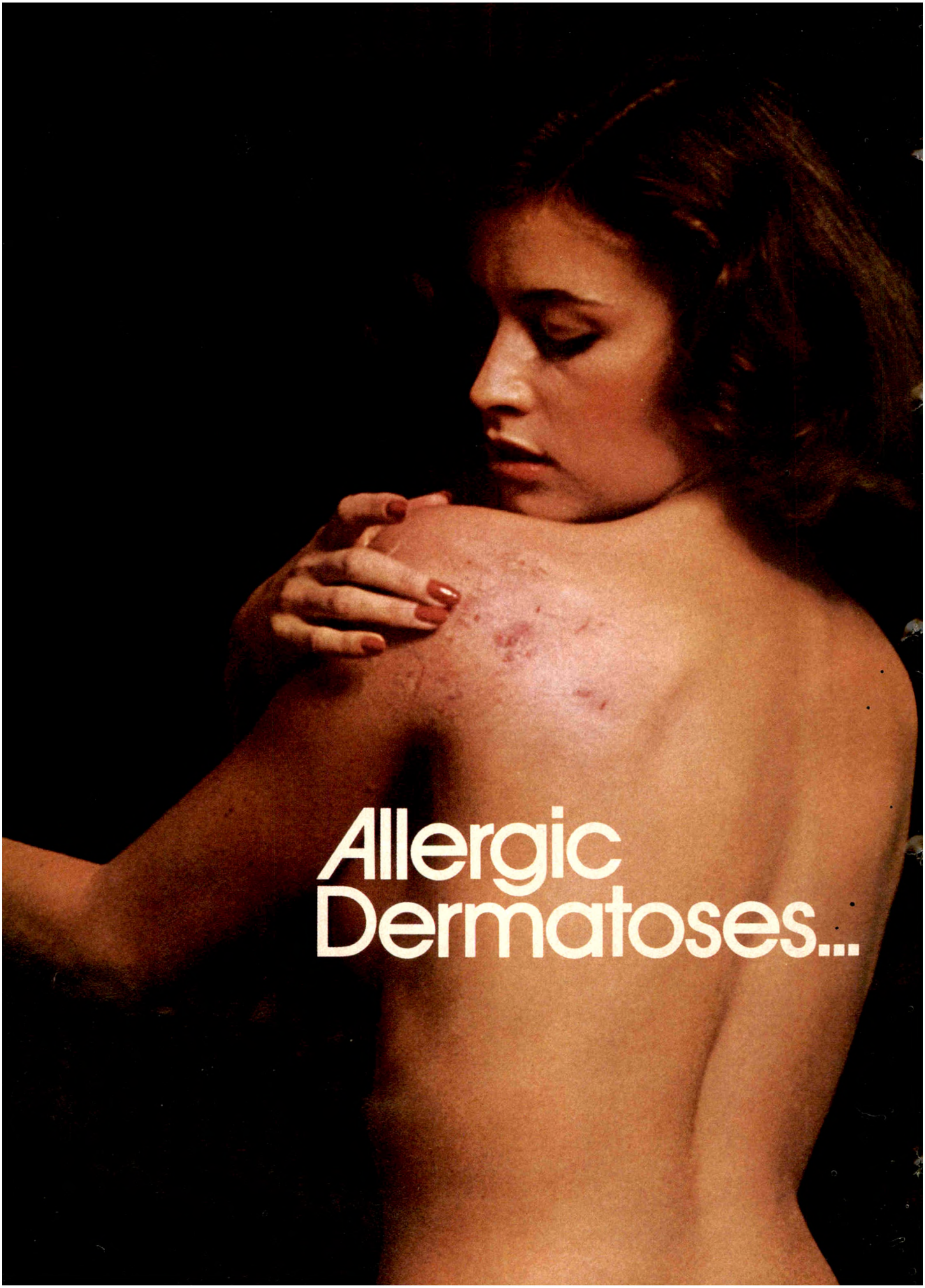
Allergic
Dermatoses...

Contraindications: Hypersensitivity to hydroxyzine. Hydroxyzine, when administered to the pregnant mouse, rat, and rabbit, induced fetal abnormalities in the rat at doses substantially above the human therapeutic range. Clinical data in human beings are inadequate to establish safety in early pregnancy. Until such data are available, hydroxyzine is contraindicated in early pregnancy.

Precautions: Hydroxyzine may potentiate the action of central nervous system depressants such as meperidine and barbiturates. In conjunctive use, dosage for these drugs should be reduced. Because drowsiness may occur, patients should be cautioned against driving a car or operating dangerous machinery.

Adverse Reactions: Drowsiness may occur; if so, it is usually transitory and may disappear in a few days of continued therapy or upon dosage reduction. Dryness of the mouth may occur with higher doses. Involuntary motor activity, including rare instances of tremor and convulsions, has been reported, usually with higher than recommended dosage.

Supply: Tablets, containing 10 mg, 25 mg, or 50 mg hydroxyzine hydrochloride, 100's and 500's; Tablets, containing 100 mg, 100's; Syrup, containing 10 mg per teaspoonful (5 ml) and ethyl alcohol 0.5% v/v, pint bottles.

Before prescribing or administering, see package circular.

with strong emotional overlay

the cause can be obscure

Factors precipitating allergic dermatoses with strong emotional overlay, which can range from allergens to anxiety, can be difficult to identify.

successful treatment often includes

Atarax®
(hydroxyzine HCl)

TABLETS: 10 mg, 25 mg, 50 mg, and 100 mg

- rapid antianxiety action
- demonstrated antihistaminic activity

ROERIG Pfizer
A division of Pfizer Pharmaceuticals
New York, New York 10017

The family for your patients' steroid

Proven clinically effective for prompt relief of mild-to-severe corticosteroid-responsive dermatoses

Valisone® Aerosol 0.15%
For acute contact dermatitis.

Impressive results with Valisone Cream and Ointment in published studies:

contact dermatitis
96% good to excellent results
(81 of 84 patients)*

atopic eczema
92% good to excellent results
(231 of 251 patients)*

psoriasis
85% good to excellent results
(150 of 177 patients)*

Valisone® Cream 0.1%

*Files of Headquarters Medical Research Division, Schering Corporation.

Copyright © 1977, Schering Corporation. All Rights Reserved.

See Clinical Considerations section on opposite page...

# of specialists responsive problems

Schering



Valisone® Lotion 0.1%
Especially useful in seborrheic dermatitis.

Clinical Considerations: Indications: VALISONE Cream, Ointment, and Lotion are indicated for relief of the inflammatory manifestations of corticosteroid-responsive dermatoses. VALISONE Reduced Strength Cream is indicated for the relief of the inflammatory manifestations of corticosteroid-responsive dermatoses. VALISONE Aerosol is indicated, solely, for adjunctive topical management for the relief of inflammatory manifestations of acute contact dermatitis. **Contraindications:** Topical steroids are contraindicated in tuberculosis of the skin and some viral diseases of the skin (varicella and vaccinia). Topical steroids are also contraindicated in those patients with a history of hypersensitivity to any of the components of the preparations. VALISONE Aerosol is contraindicated for use under occlusive dressings. **Warnings for VALISONE Aerosol:** Keep the spray away from eyes and other mucous membranes; avoid inhaling. Avoid freezing of the tissue by not spraying for more than 3 seconds, at a distance not less than 6 inches. Contents are under pressure. Do not puncture. Do not store or use near open flame or heat. Exposure to temperatures above 120°F may cause bursting. Keep out of reach of children. Never throw container into fire or incinerator. **Precautions:** If irritation or sensitization develops with the use of VALISONE products, treatment should be discontinued and appropriate therapy instituted. In the presence of infection, the use of an appropriate antifungal or antibacterial should be instituted. If favorable response does not occur promptly, the corticosteroid should be discontinued until the infection has been adequately controlled. If extensive areas are treated, or if the occlusive technique is used, the possibility exists of sufficient systemic absorption to produce adrenal suppression and systemic corticosteroid effects may occur; suitable precautions should be taken. In a few cases, ulceration has been reported with the use of topical steroids for skin conditions involved with impaired circulation (i.e., stasis dermatitis). Prolonged application of corticosteroid-containing products under occlusion may result in striae or atrophy of the skin or subcutaneous tissues. VALISONE products are not for ophthalmic use. **Usage in Women of Childbearing Age:** The use of any drug during pregnancy and the lactation period or in women of childbearing age requires that the potential benefits of the drug be weighed against the possible hazards to the fetus or infant. Topical corticosteroids have not been reported to have an adverse effect on the fetus, but the safety of their use in pregnant patients has not been definitely established. They should not be used extensively or for prolonged periods of time in pregnant patients, unless the condition requiring treatment warrants the risk. **Adverse Reactions:** The following adverse reactions have been reported with topical corticosteroids: burning, itching, irritation, dryness, folliculitis, hypertrichosis, acneiform eruptions, and hypopigmentation. The following may occur more frequently with occlusive dressings than without such therapy: maceration of the skin, secondary infection, atrophy of the skin or subcutaneous tissues, striae, miliaria. **Dosage and Administration:** VALISONE Cream, Ointment, and Reduced Strength Cream are applied as a thin film over the affected skin areas one to three times a day. Clinical studies of VALISONE have indicated that dosage once or twice a day is often feasible and effective. VALISONE Reduced Strength Cream has an aqueous, hydrophilic base that softens and moisturizes the skin. Although occlusive dressings are required infrequently, they may enhance therapeutic efficacy in certain refractory lesions of psoriasis and other dermatoses that are difficult to treat. Apply a few drops of VALISONE Lotion to the affected area of the scalp and massage lightly until it disappears. Apply twice daily, in the morning and at night. Dosage may be increased in stubborn cases; following improvement, apply once daily. Apply VALISONE Aerosol three to four times a day. The container may be held upright or inverted during use. The spray should be directed onto the affected area from a distance of approximately 6 inches and applied for only 3 seconds. Aerosol packaged by Aerosol Techniques, Inc., Armstrong Laboratories Division, West Roxbury, MA. 02132. **For more complete details, consult package insert or Schering literature available from your Schering Representative or Professional Services Department, Schering Corporation, Kenilworth, New Jersey 07033.**

MARCH 1974 (R)

Valisone® Reduced Strength Cream 0.01%
For low-cost maintenance therapy.

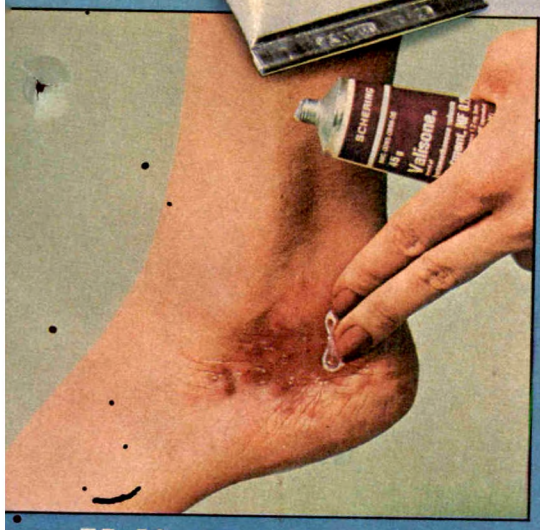

Valisone® Ointment 0.1%
When dryness is a problem.

Valisone®
brand of
betamethasone valerate, NF

It's Here!!

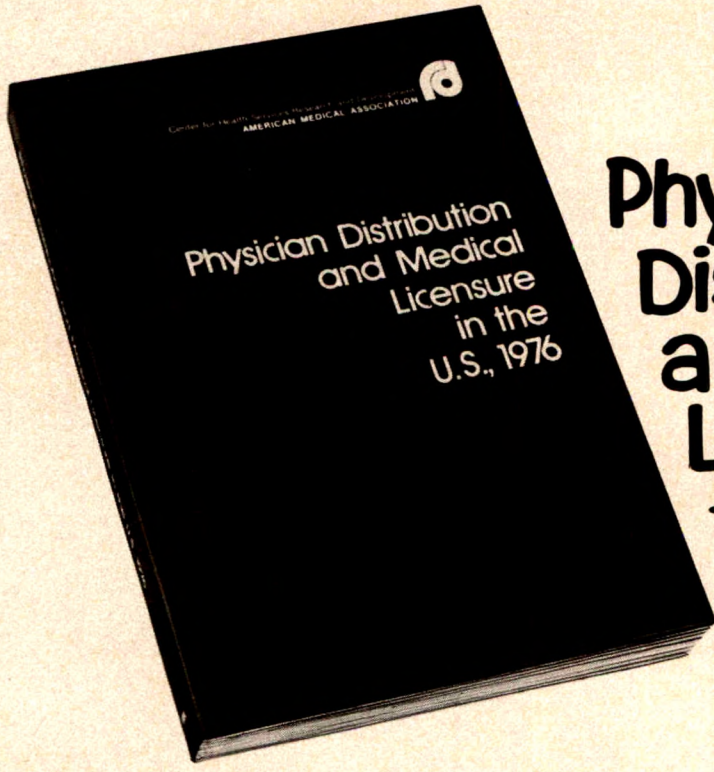

Physician Distribution and Medical Licensure in the U.S., 1976

New Edition from the AMA

When you need comprehensive data on the physician population, turn to the NEW edition of **Physician Distribution and Medical Licensure in the U.S.** Compiled by the American Medical Association's Center for Health Services Research and Development, this informative volume offers you detailed statistical data for comparing regions, divisions, states, and counties with respect to their:

- total number of physicians by specialty and professional activity
- number of hospitals and hospital beds
- number of inhabitants
- physician-population ratios
- counties without physicians
- per capita and per household income

New Sections

This indispensable publication has almost doubled in size. Special sections devoted to women physicians and foreign medical graduates have been added.

Since quantities are limited, please use the coupon to order today. **$15.95**

Order Department
American Medical Association
P.O. Box 821
Monroe, Wisconsin 53566

Please send_____copy(ies) of **Physician Distribution and Medical Licensure in the U.S., 1976** (OP-45) at $15.95 each.

My check for $_____ payable to the AMA is enclosed.

Name _____

Address _____

City/State/Zip_____

When Griseofulvin is indicated...

TINEA PEDIS*

TINEA UNGUIUM*

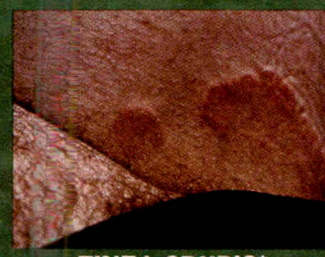

TINEA CRURIS*

TINEA CAPITIS*

*Also *Tinea barbae* and *Tinea corporis* when caused by fungi from genera known to be sensitive to griseofulvin.

Gris-PEG®

(griseofulvin ultramicrosize) Tablets 125 mg

offers effective therapy with 1/2 the dose.†

- Can be taken on an empty stomach
- Absorption nearly complete without fatty meals
- Reduced cost for patients
- Once-a-day or b.i.d. dosage

†250 mg of Gris-PEG® provides plasma levels equivalent to those obtained with 500 mg microsize griseofulvin. This improved absorption permits the oral intake of half as much griseofulvin but there is no evidence, at this time, that this confers any significant clinical difference in regard to safety or efficacy.

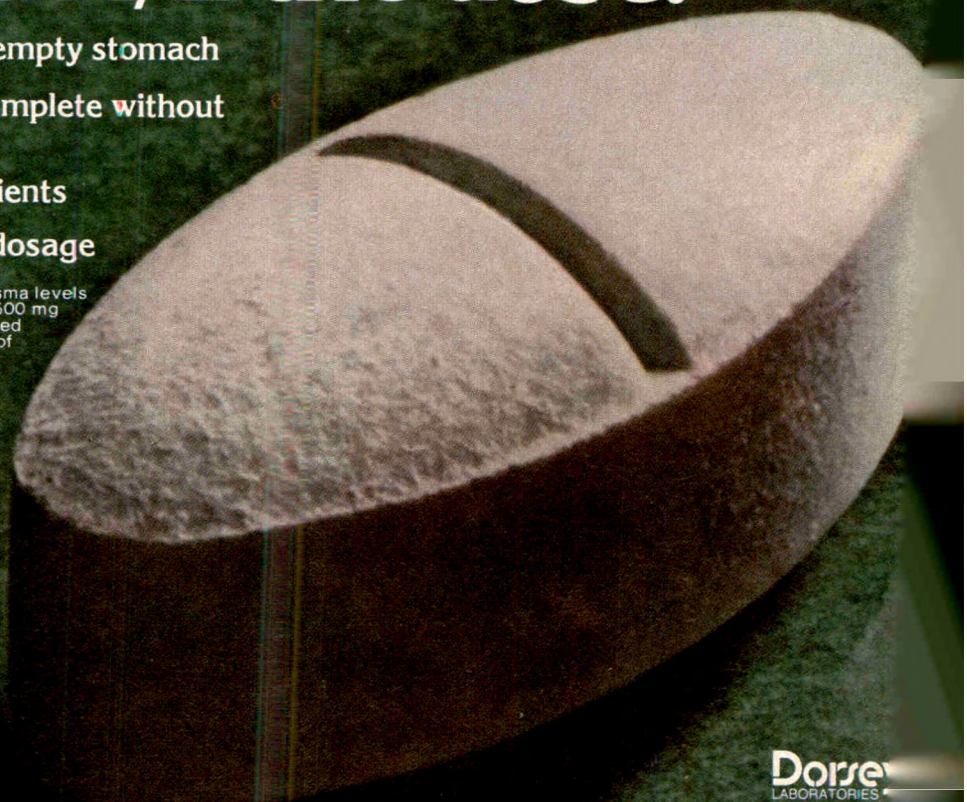

Dorsey LABORATORIES
Division of Sandoz, Inc.
LINCOLN, NEBRASKA

Please see other side for full prescribing inform

Gris-PEG®
(griseofulvin ultramicrosize) Tablets 125 mg
The ½ dose griseofulvin.

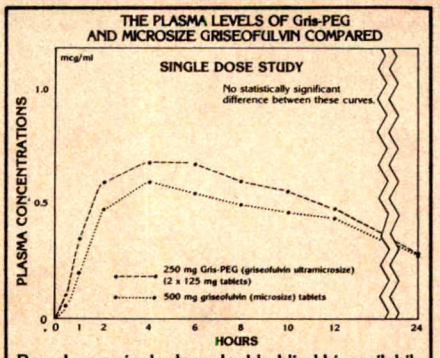

Based on a single dose double-blind bioavailability study conducted in 24 human volunteers comparing the average griseofulvin (microsize) and Gris-PEG plasma levels. There is no significant difference between peak plasma levels, times to peak, and areas under the curve. Gas chromatographic assay.

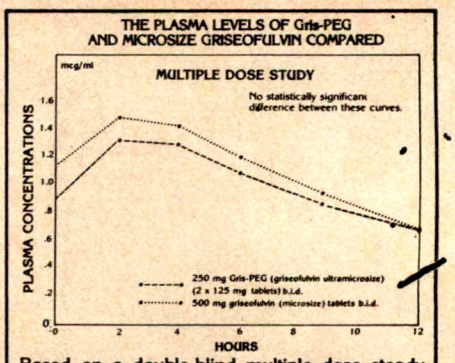

Based on a double-blind multiple dose steady state crossover bioavailability study conducted in 17 human volunteers comparing the average griseofulvin (microsize) and Gris-PEG plasma levels obtained on days 9, 11 and 13. There is no significant difference between times to peak, peak plasma levels, and areas under the curve. Gas chromatographic assay.

DESCRIPTION

Griseofulvin is an antibiotic derived from a species of *Penicillium*.

Gris-PEG is an ultramicrocrystalline solid-state dispersion of griseofulvin in polyethylene glycol 6000.

Gris-PEG Tablets differ from griseofulvin (microsize) tablets USP in that each tablet contains 125 mg of ultramicrosize griseofulvin biologically equivalent to 250 mg of microsize griseofulvin.

ACTION

Microbiology: Griseofulvin is fungistatic with *in vitro* activity against various species of *Microsporum*, *Epidermophyton* and *Trichophyton*. It has no effect on bacteria or other genera of fungi.

Human Pharmacology: The peak plasma level found in fasting adults given 0.25 g of Gris-PEG occurs at about four hours and ranges between 0.37 to 1.6 mcg/ml.

Comparable studies with microsize griseofulvin indicated that the peak plasma level found in fasting adults given 0.5 g occurs at about four hours and ranges between 0.44 to 1.2 mcg/ml.

Thus, the efficiency of gastrointestinal absorption of the ultramicrocrystalline formulation of Gris-PEG is approximately twice that of conventional microsized griseofulvin. This factor permits the oral intake of half as much griseofulvin per tablet but there is no evidence, at this time, that this confers any significant clinical differences in regard to safety and efficacy.

Griseofulvin is deposited in the keratin precursor cells and has a greater affinity for diseased tissue. The drug is tightly bound to the new keratin which becomes highly resistant to fungal invasions.

INDICATIONS

Gris-PEG (griseofulvin ultramicrosize) is indicated for the treatment of the following ringworm infections:

Tinea corporis (ringworm of the body)
Tinea pedis (athlete's foot)
Tinea cruris (ringworm of the thigh)
Tinea barbae (barber's itch)
Tinea capitis (ringworm of the scalp)
Tinea unguium (onychomycosis, ringworm of the nails)

when caused by one or more of the following genera of fungi:

Trichophyton rubrum
Trichophyton tonsurans
Trichophyton mentagrophytes
Trichophyton interdigitalis
Trichophyton verrucosum
Trichophyton megnini
Trichophyton gallinae
Trichophyton crateriform
Trichophyton sulphureum
Trichophyton schoenleini
Microsporum audouini
Microsporum canis
Microsporum gypseum
Epidermophyton floccosum

NOTE: Prior to therapy, the type of fungi responsible for the infection should be identified.

The use of the drug is not justified in minor or trivial infections which will respond to topical agents alone.

Griseofulvin is *NOT* effective in the following:

Bacterial infections
Candidiasis (Moniliasis)
Histoplasmosis
Actinomycosis
Sporotrichosis
Chromoblastomycosis
Coccidioidomycosis
North American Blastomycosis
Cryptococcosis (Torulosis)
Tinea versicolor
Nocardiosis

CONTRAINDICATIONS

This drug is contraindicated in patients with porphyria, hepatocellular failure, and in individuals with a history of sensitivity to griseofulvin.

WARNINGS

Prophylactic Usage: Safety and Efficacy of Griseofulvin for Prophylaxis of Fungal Infections Has Not Been Established.

Animal Toxicology: Chronic feeding of griseofulvin, at levels ranging from 0.5 to 2.5% of the diet, resulted in the development of liver tumors in several strains of mice, particularly in males. Smaller particle sizes result in an enhanced effect. Lower oral dosage levels have not been tested. Subcutaneous administration of relatively small doses of griseofulvin, once a week, during the first three weeks of life has also been reported to induce hepatomata in mice. Although studies in other animal species have not yielded evidence of tumorigenicity, these studies were not of adequate design to form a basis for conclusions in this regard.

In subacute toxicity studies, orally administered griseofulvin produced hepatocellular necrosis in mice, but this has not been seen in other species. Disturbances in porphyrin metabolism have been reported in griseofulvin treated laboratory animals. Griseofulvin has been reported to have a colchicine-like effect on mitosis and cocarcinogenicity with methylcholanthrene in cutaneous tumor induction in laboratory animals.

Usage in Pregnancy: The safety of this drug during pregnancy has not been established.

Animal Reproduction Studies: It has been reported in the literature that griseofulvin was found to be embryotoxic and teratogenic on oral administration to pregnant rats. Pups with abnormalities have been reported in the litters of a few bitches treated with griseofulvin. Additional animal reproduction studies are in progress. Suppression of spermatogenesis has been reported to occur in rats, but investigation in man failed to confirm this.

PRECAUTIONS

Patients on prolonged therapy with any potent medication should be under close observation. Periodic monitoring of organ system function, including renal, hepatic and hematopoietic, should be done.

Since griseofulvin is derived from species of *Penicillium*, the possibility of cross sensitivity with penicillin exists; however, known penicillin-sensitive patients have been treated without difficulty.

Since a photosensitivity reaction is occasionally associated with griseofulvin therapy, patients should be warned to avoid exposure to intense natural or artificial sunlight. Should a photosensitivity reaction occur, lupus erythematosus may be aggravated.

Griseofulvin decreases the activity of warfarin-type anticoagulants so that patients receiving these drugs concomitantly may require dosage adjustment of the anticoagulant during and after griseofulvin therapy.

Barbiturates usually depress griseofulvin activity and concomitant administration may require a dosage adjustment of the antifungal agent.

ADVERSE REACTIONS

When adverse reactions occur, they are most commonly of the hypersensitivity type such as skin rashes, urticaria, and rarely, angioneurotic edema, and may necessitate withdrawal of therapy and appropriate countermeasures. Paresthesias of the hands and feet have been reported rarely after extended therapy. Other side effects reported occasionally are oral thrush, nausea, vomiting, epigastric distress, diarrhea, headache, fatigue, dizziness, insomnia, mental confusion, and impairment of performance of routine activities.

Proteinuria and leukopenia have been reported rarely. Administration of the drug should be discontinued if granulocytopenia occurs.

When rare, serious reactions occur with griseofulvin, they are usually associated with high dosages, long periods of therapy, or both.

DOSAGE AND ADMINISTRATION

Accurate diagnosis of the infecting organism is essential. Identification should be made either by direct microscopic examination of a mounting of infected tissue in a solution of potassium hydroxide or by a culture on an appropriate medium.

Medication must be continued until the infecting organism is completely eradicated as indicated by appropriate clinical or laboratory examination. Representative treatment periods are—*tinea capitis*, 4 to 6 weeks; *tinea corporis*, 2 to 4 weeks; *tinea pedis*, 4 to 8 weeks; *tinea unguium*—depending on rate of growth—fingernails, at least 4 months; toenails, at least 6 months.

General measures in regard to hygiene should be observed to control sources of infection or reinfection. Concomitant use of appropriate topical agents is usually required particularly in treatment of *tinea pedis*. In some forms of athlete's foot, yeasts and bacteria may be involved as well as fungi. Griseofulvin will not eradicate the bacterial or monilial infection.

An oral dose of 250 mg of Gris-PEG (griseofulvin ultramicrosize) is biologically equivalent to 500 mg of griseofulvin (microsized) USP (see ACTION Human Pharmacology).

Adults: A daily dose of 250 mg will give a satisfactory response in most patients with *tinea corporis*, *tinea cruris* and *tinea capitis*. One 125 mg tablet twice per day or two 125 mg tablets once per day is the usual dosage. For those fungal infections more difficult to eradicate such as *tinea pedis* and *tinea unguium*, a divided daily dose of 500 mg is recommended. In all cases, the dosage should be individualized.

Children: Approximately 5 mg per kilogram (2.5 mg per pound) of body weight per day is an effective dose for most children. On this basis the following dosage schedule for children is suggested: Children weighing over 25 kilograms (approximately 50 pounds) 125 mg to 250 mg daily; children weighing 15-25 kilograms (approximately 30 to 50 pounds) 62.5 mg to 125 mg daily; children 2 years of age and younger, dosage has not been established.

Dosage should be individualized, as is done for adults. Clinical experience with griseofulvin in children with *tinea capitis* indicates that a single daily dose is effective. Clinical relapse will occur if the medication is not continued until the infecting organism is eradicated.

HOW SUPPLIED

Gris-PEG (griseofulvin ultramicrosize) Tablets (white) differ from griseofulvin microsized tablets (USP) in that each tablet contains 125 mg of ultramicrosize griseofulvin, biologically equivalent to 250 mg of microsized griseofulvin. Two 125 mg tablets of Gris-PEG are biologically equivalent to 500 mg of microsized griseofulvin. In bottles of 100 and 500 scored, film-coated tablets.

Dorsey
LABORATORIES
Division of Sandoz, Inc. • LINCOLN, NEBRASKA 68501

OY-YB

Cleansing & Moisturizing

New Keri Facial Cleanser is formulated to slow moisture loss from the skin, emulsify oil, and remove dirt and debris as it leaves skin softer and smoother.

Cleansing without drying is a Keri tradition.

Patients who routinely use Alpha Keri® Bath Oil and Alpha Keri® Soap should welcome this new addition to the fine line of Keri skin care products.

New Keri® Facial Cleanser

In 4 oz. plastic bottles. Promoted to physicians only.

WESTWOOD
PHARMACEUTICALS INC.
Buffalo, New York 14213

© 1977 W.P. Inc.

THIRD EDITION

Common Skin Diseases

DIAGNOSIS AND TREATMENT

By HOWARD T. BEHRMAN, M.D., THEODORE A. LABOW, M.D., and JACK H. ROZEN, M.D.

Incorporating recent advances in dermatology and practical applications which have resulted from them, the new edition of this standard manual remains the most convenient guide to the diagnosis and treatment of the common skin disorders. For each disease, common symptoms and signs, the steps in reaching a diagnosis, and the most modern, up-to-date therapeutic measures are presented in a lucid, uncomplicated format. A spectacular feature of the book is the inclusion of 263 easy-to-recognize full-color photographs of the common skin diseases.

Its emphasis on practical management makes *Common Skin Diseases* unique in its field. Special features of the third edition include the addition of much new material relevant to present-day care of skin disorders, discussion of new approaches to psoriasis and acne, new methods and concepts of treatment in both benign and malignant skin growths, and the elimination of many methods no longer considered significant in treatment.

SECTION HEADINGS: Common Skin Diseases. New Growths—Benign. New Growths—Potentially Malignant, Premalignant, and Malignant. Formulary.

1978, 189 pp., 263 full color photographs, $29.50/£19.15 ISBN: 0-8089-1102-3

Send payment with order and save postage plus 50c handling charge. *Prices subject to change without notice.*

U.S. customers please note: On prepaid orders —payment will be refunded for titles on which shipment is not possible within 120 days.

Grune & Stratton

A Subsidiary of Harcourt Brace Jovanovich, Publishers

111 FIFTH AVENUE, N.Y., N.Y. 10003
24-28 OVAL ROAD, LONDON NW1 7DX

Please send me____copies,
Behrman/*et al.*: *Common Skin Diseases*, 3rd Ed.

Check enclosed____ Bill me____

NAME_____
ADDRESS_____
CITY/STATE/ZIP_____

New York residents please add sales tax.
Direct all orders to Mr. Paul Negri, Media Dept. *ArchDerma/5/78*

A New Look for the 1977 Red and Blue Books

Those familiar **Red and Blue Books,** published by the American Medical Association's Center for Health Services Research and Development, now have new size. . .new format. . .new data. As a result, you will find them more useful and convenient than ever. Here's a closer look at the 6th annual edition of these authoritative volumes:

Profile of Medical Practice 1977 (Red Book)
The focus is on characteristics of medical practice such as physicians' work patterns, professional expenses, and net income from medical practice.

Socioeconomic Issues of Health 1977 (Blue Book)
A combination of the latest data on the U.S. health services delivery system and essays on topical health issues.

Quantities are limited, so order today!

S/J

Order Dept.
American Medical Association
535 N. Dearborn
Chicago, IL 60610

_____Profile of Medical Practice (OP-6) $4.50
_____Socioeconomic Issues of Health (OP-5) $4.50

Enclosed is my check for $_____, payable to the American Medical Association.

Name _____

Address _____

City/State/Zip_____

SYNALAR®
(fluocinolone acetonide)
CREAM 0.025%
CREAM 0.01%
OINTMENT 0.025%
SOLUTION 0.01%

Description Synalar (fluocinolone acetonide) has the chemical name 6α, 9α-difluoro-16α-hydroxyprednisolone-16, 17-acetonide.

The cream contains fluocinolone acetonide 0.25 mg./g. or 0.1 mg./g. in a water-washable aqueous base of stearic acid, propylene glycol, sorbitan monostearate and monooleate, polysorbate 60, purified water and citric acid with methylparaben and propylparaben as preservatives.

The ointment contains fluocinolone acetonide 0.25 mg./g. in a white petrolatum U.S.P. vehicle.

The solution contains fluocinolone acetonide 0.1 mg./g. in a water-washable base of propylene glycol with citric acid.

Indications For relief of the inflammatory manifestations of corticosteroid-responsive dermatoses.

Contraindications Topical steroids are contraindicated in vaccinia and varicella.

Topical steroids are contraindicated in those patients with a history of hypersensitivity to any of the components of the preparation.

Precautions If irritation develops, the product should be discontinued and appropriate therapy instituted.

In the presence of an infection the use of an appropriate antifungal or antibacterial agent should be instituted. If a favorable response does not occur promptly, the corticosteroid should be discontinued until the infection has been adequately controlled.

If extensive areas are treated or if the occlusive technique is used, the possibility exists of increased systemic absorption of the corticosteroid and suitable precautions should be taken.

Although topical steroids have not been reported to have an adverse effect on pregnancy, the safety of their use in pregnant females has not absolutely been established. Therefore, they should not be used extensively on pregnant patients, in large amounts, or for prolonged periods of time.

Synalar products are not for ophthalmic use.

Adverse reactions The following local adverse reactions have been reported with topical corticosteroids: burning, itching, irritation, dryness, folliculitis, hypertrichosis, acneform eruptions, hypopigmentation.

The following may occur more frequently with occlusive dressings than without such therapy: maceration of the skin, secondary infection, skin atrophy, striae, miliaria.

How Supplied
Synalar (fluocinolone acetonide)
Cream 0.025% — 15 and 60g. tubes and 120 and 425g. jars.
Cream 0.01% — 15, 45 and 60g. tubes and 120 and 425g. jars.
Ointment 0.025% — 15 and 60g. tubes and 425g. jars.
Solution 0.01% — 20cc. and 60cc. plastic squeeze bottles.

Also Available
Synalar-HP® (fluocinolone acetonide) Cream 0.2% 5g. and 12g. tubes.

SYNTEX
SYNTEX LABORATORIES, INC.
PALO ALTO, CALIFORNIA 94304

AS USEFUL TODAY AS THE
DAY IT WAS INTRODUCED

SYNAL
(FLUOCINOLO
ACETONIDE)

See pr
of pres

SYNTEX

Superior to the most widely used brand of topical steroid in psoriasis and atopic dermatitis.

Based on the evidence.

n double-blind, parallel studies,* Topicort® (desoximetasone) Emollient Cream 0.25% demonstrated greater efficacy than etamethasone valerate cream 0.1% in the two most common orticosteroid-responsive dermatoses.

		NO. OF PATIENTS	Overall Evaluation: EXCELLENT & GOOD	Overall Evaluation: EXCELLENT (CLEARANCE OF DISEASE)
TOPIC DERMATITIS	TOPICORT	39	100%	77%
	BETAMETHASONE VALERATE	41	90%	54%
SORIASIS	TOPICORT	61	84%	43%
	BETAMETHASONE VALERATE	56	63%	21%

hese recently conducted U.S. studies confirm the outstanding worldwide cceptance of Topicort in more than 30 countries for up to 4 years.

*Data on file and available upon request from Hoechst-Roussel Pharmaceuticals Inc., Somerville, New Jersey 08876.

Less than 1% incidence of side effects.
Of 488 patients in the clinical trials, side effects were seen in only 4 (0.8%).* And in 2 of the 4 patients, the relationship of side effects to the drug was uncertain.

The convenience of b.i.d. dosage. And the uniqueness of a preservative-free, emollient cream base.
The specially developed, preservative-free Topicort base combines the emollience of an ointment with the cosmetic acceptability of a cream in a water-in-oil emulsion. This makes Topicort (desoximetasone) especially useful in psoriatic and other dry, scaly dermatoses.

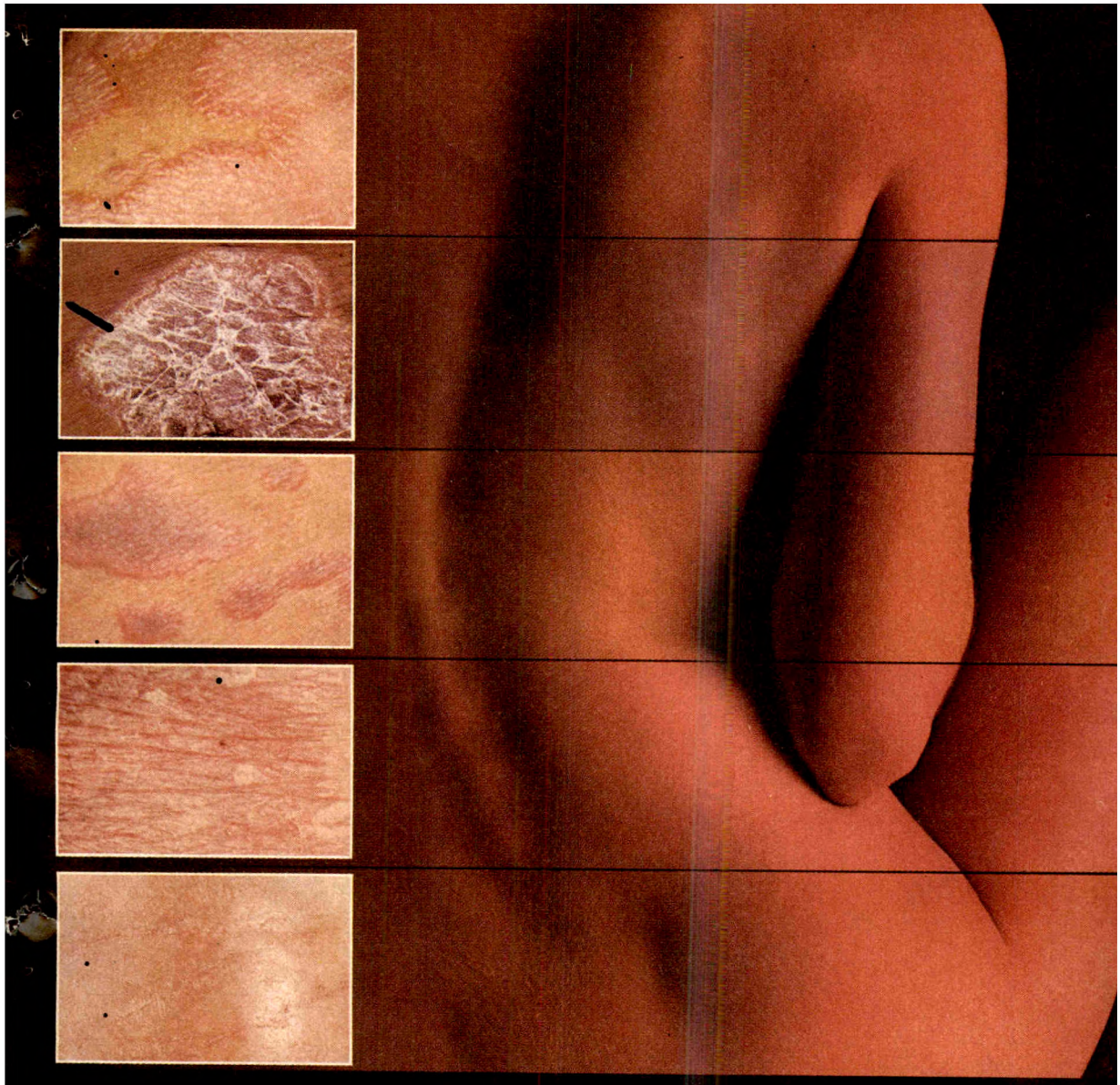

TOPICORT®
(DESOXIMETASONE)
EMOLLIENT CREAM 0

An important innovation from the research laboratories of
Hoechst-Roussel Pharmaceuticals Inc.

Please consult full prescribing information on following page.

TOPICORT® (desoximetasone) EMOLLIENT CREAM 0.25%

Description: Topicort® (desoximetasone) Emollient Cream 0.25% contains the active synthetic corticosteroid desoximetasone. The chemical name of desoximetasone is 9α - fluoro - 11β, 21 - dihydroxy - 16α - methylpregna - 1,4 - diene-3,20-dione. The chemical structure is:

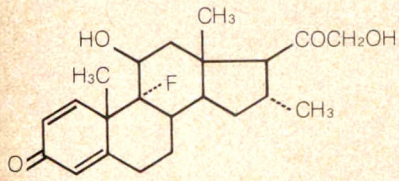

Each gram of Topicort® (desoximetasone) Emollient Cream 0.25% contains 2.5 mg desoximetasone in an emollient cream consisting of isopropyl myristate, cetylstearyl alcohol, white petrolatum, mineral oil, lanolin alcohol and purified water.

Actions: Topicort® (desoximetasone) Emollient Cream is primarily effective because of its anti-inflammatory, antipruritic and vasoconstrictive actions.

Indications: Topicort® (desoximetasone) Emollient Cream is indicated for the relief of inflammatory manifestations of corticosteroid-responsive dermatoses.

Contraindications: Topical steroids are contraindicated in vaccinia, varicella and in those patients with a history of hypersensitivity to any of the components of the preparation. This preparation is not for ophthalmic use.

Precautions: If local infection exists, suitable concomitant antimicrobial or antifungal therapy should be administered. If a favorable response does not occur promptly, application of the corticosteroid should be discontinued until the infection is adequately controlled.

Although systemic side effects associated with absorption of topical corticosteroid preparations are rare, their possible occurrence must be kept in mind when these preparations are used over large areas or for an extended period of time, or if occlusive technique is used.

If irritation or sensitization develops, the preparation should be discontinued and appropriate therapy instituted.

Although topical steroids have not been reported to have an adverse effect on pregnancy, the safety of their use during pregnancy has not been absolutely established; therefore, they should not be used extensively on pregnant patients, in large amounts, or for prolonged periods of time.

Adverse Reactions: The following local adverse reactions have been reported with topical corticosteroids: burning, itching, irritation, striae, skin atrophy, secondary infection, dryness, folliculitis, hypertrichosis, acneform eruptions and hypopigmentation. The following may occur more frequently with occlusive dressings: maceration of the skin, secondary infection, skin atrophy, striae, and miliaria.

Dosage and Administration: Apply a thin film of Topicort® (desoximetasone) Emollient Cream 0.25% to the affected skin areas twice daily. Rub in gently.

How Supplied: Topicort® (desoximetasone) Emollient Cream 0.25% is supplied in 15-gram tubes.

HOECHST-ROUSSEL
PHARMACEUTICALS INCORPORATED
SOMERVILLE, NEW JERSEY 08876

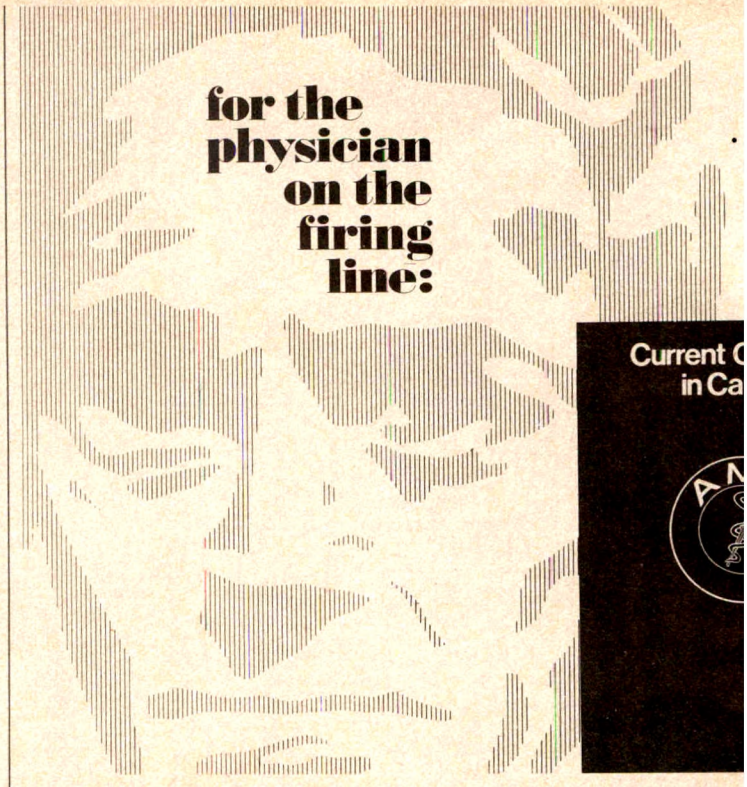

A valuable guide to diagnostic and therapeutic
for the cancer patient

Current Concepts in Ca

While national attention focuses on cancer through spec centers, physicians are aware that the majority of ca are treated in office practices. For most practicing ph cer treatment is not a research objective, but a very p lem in patient management.

Current Concepts in Cancer, a compilation of artic published in the *Journal of the American Medical A* designed to be a guide for the practitioner in the choice and therapeutic procedures for many types of malign sents an objective interdisciplinary view by MDs outsta respective fields, emphasizing principles of diagnosis radiotherapeutic, and chemotherapeutic treatment.

Make this important resource a part of your referen your copy today.

American Medical Association
535 North Dearborn Street
Chicago, Illinois 60610

Please send me _____ copy(ies) of **Current Concepl** (OP-281). Price is $10 per copy. Please enclose you with order.

Please Print

Name _____

Address _____

City _____ State _____

"Doctor, with my delicate skin... what kind of soap should I use?"

Pure mild Ivory is one of the safest possible soaps you can recommend for delicate skin. More doctors recommend Ivory than any other soap.

It makes sense. Ivory's absence of many extra ingredients helps minimize chances of irritation.

Thirty-eight years of laboratory testing—including patch tests and arm immersion experiments—confirm that Ivory is one of the mildest least irritating soaps you can recommend.

And 89 years of safe consumer use support this clinical experience.

Ivory may safely be used as an adjunct to treatment of scabies, seborrhea and impetigo.

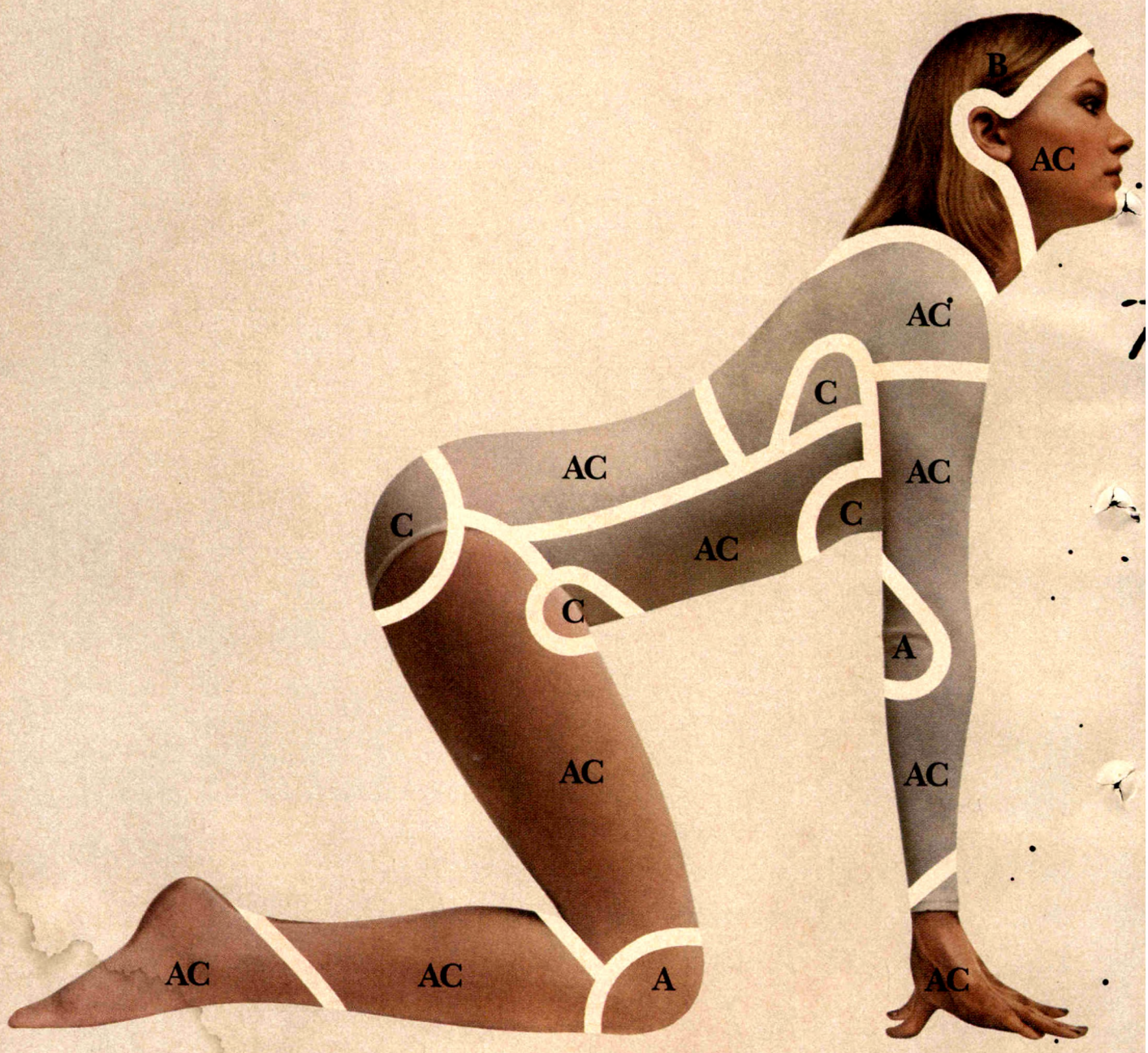

FOR THE ZONES OF DERMATOSES

For dry areas/lesions

A New Halog® Ointment 0.1%

Halcinonide Ointment 0.1%

For scalp lesions

B New Halog® Solution 0.1%

Halcinonide Solution 0.1%

For moist areas/lesions

Full-strength

C Halog® Cream 0.1%

Halcinonide Cream 0.1%

'Maintenance formula'

Quarter-strength

New Halog® Cream 0.025%

Halcinonide Cream 0.025%

Clinical experience

A total of 984 psoriatic patients in US clinical studies were treated with either the Solution, the Creams, or the Ointment. After 2 weeks' therapy,* 151 (78%) of 194 patients improved with Halog Solution, 407 (92.5%) of 440 patients improved with full-strength (0.1%) Halog Cream, 132 (72%) of 184 patients improved with quarter-strength (0.025%) Halog Cream, and 145 (87%) of 166 patients improved with Halog Ointment.

In general, the preferred topical formulations for lesions in specific areas are: solutions for scalp lesions, creams for moist areas/lesions, and ointments for dry areas/lesions. The studies cited above, however, were not limited to lesions in these specific areas.

*Majority of patients evaluated after 2 weeks' therapy. Data on file at Squibb Institute for Medical Research.

See next page for brief summary.

©1977 E.R. Squibb & Sons, Inc. 357-508

HALOG®

HALCINONIDE

SQUIBB®

HALOG® (Halcinonide)
Cream/Ointment/Solution
Halog Cream 0.025% (Halcinonide Cream 0.025%) and Halog Cream 0.1% (Halcinonide Cream 0.1%) contain 0.25 mg. and 1 mg. halcinonide per gram, respectively, in a specially formulated cream base. Halog Ointment (Halcinonide Ointment 0.1%) contains 1 mg. halcinonide (0.1%) per gram in Plastibase® (Plasticized Hydrocarbon Gel), a polyethylene and mineral oil gel base. Halog Solution (Halcinonide Solution 0.1%) contains 1 mg. halcinonide (0.1%) per ml.
CONTRAINDICATIONS: Topical steroids are contraindicated in vaccinia, varicella, and in those patients with a history of hypersensitivity to any of the components of the preparations. These preparations are not for ophthalmic use.
PRECAUTIONS: *General*—If local infection exists, suitable concomitant antimicrobial or antifungal therapy should be administered. If a favorable response does not occur promptly, application of the corticosteroid should be discontinued until the infection is adequately controlled. If extensive areas are treated or if the occlusive technique is used, the possibility exists of increased systemic absorption of the corticosteroid and suitable precautions should be taken. If irritation or sensitization develops, the preparation should be discontinued and appropriate therapy instituted. Although topical steroids have not been reported to have an adverse effect on pregnancy, the safety of their use during pregnancy has not been absolutely established; therefore, they should not be used extensively on pregnant patients, in large amounts, or for prolonged periods of time.
Occlusive Dressing Technique—The use of occlusive dressing increases the percutaneous absorption of corticosteroids; their extensive use increases the possibility of systemic effects. For patients with extensive lesions it may be preferable to use a sequential approach, occluding one portion of the body at a time. The patient should be kept under close observation if treated with the occlusive technique over large areas and over a considerable period of time. Occasionally, a patient who has been on prolonged therapy, especially occlusive therapy, may develop symptoms of steroid withdrawal when the medication is stopped. Thermal homeostasis may be impaired if large areas of the body are covered. Use of the occlusive dressing should be discontinued if elevation of the body temperature occurs. Occasionally, a patient may develop a sensitivity reaction to a particular occlusive dressing material or adhesive and a substitute material may be necessary. If infection develops, discontinue the use of the occlusive dressing and institute appropriate antimicrobial therapy.
ADVERSE REACTIONS: The following local adverse reactions have been reported with topical corticosteroids: burning, itching, irritation, striae, skin atrophy, secondary infection, dryness, folliculitis, hypertrichosis, acneform eruptions, and hypopigmentation. The following may occur more frequently with occlusive dressings: maceration of the skin, secondary infection, skin atrophy, striae, and miliaria. Contact sensitivity to a particular dressing material or adhesive may occur occasionally (see PRECAUTIONS).
For full prescribing information, consult package insert.
HOW SUPPLIED: The 0.025% and 0.1% Cream and the 0.1% Ointment are supplied in tubes of 15 g. and 60 g., and in jars of 240 g. (8 oz.). The 0.1% Solution is supplied in plastic squeeze bottles of 20 ml. and 60 ml.

SQUIBB®

Send us this coupon today and we'll send you a way to slash your claims reporting costs and time

S/J

Return Order Blank To:
American Medical Association
535 North Dearborn
Chicago, Illinois 60610
(312) 751-6000

Type of form		Quantity—in orders of:	Price Including Handling and Postage*
☐ Single Form (One page pads of a hundred)	OP-407	1,000 ☐	$ 18.50
		5,000 ☐	78.00
		10,000 ☐	138.00
☐ Two Forms (Original and one carbon)	OP-408	1,000 ☐	28.00
		5,000 ☐	112.00
		10,000 ☐	210.00
☐ Continuous Form (Original and one carbon) (For Computer Printers)	OP-409	1,000 ☐	28.00
		5,000 ☐	112.00
		10,000 ☐	210.00

TOTAL _____

Name _____
Street Address _____
City _____ State _____ Zip _____

Check or money order must accompany this order and be made payable to the American Medical Association.

The Official AMA Uniform Health Insurance Claim Form

Accepted by Medicare, Commercial Carriers, many Blue Shield Plans, and many states for Medicaid.

Developed by the AMA in cooperation with carriers, government agencies, and other groups, this form is the most current and most widely used claim reporting form available. It significantly reduces the time and cost of claims reporting. **Note:** A number of private firms are marketing an outdated, more expensive version of this form. To be certain you are using the most current and acceptable form to third party insurers, we encourage you to use the official AMA form. Order today.

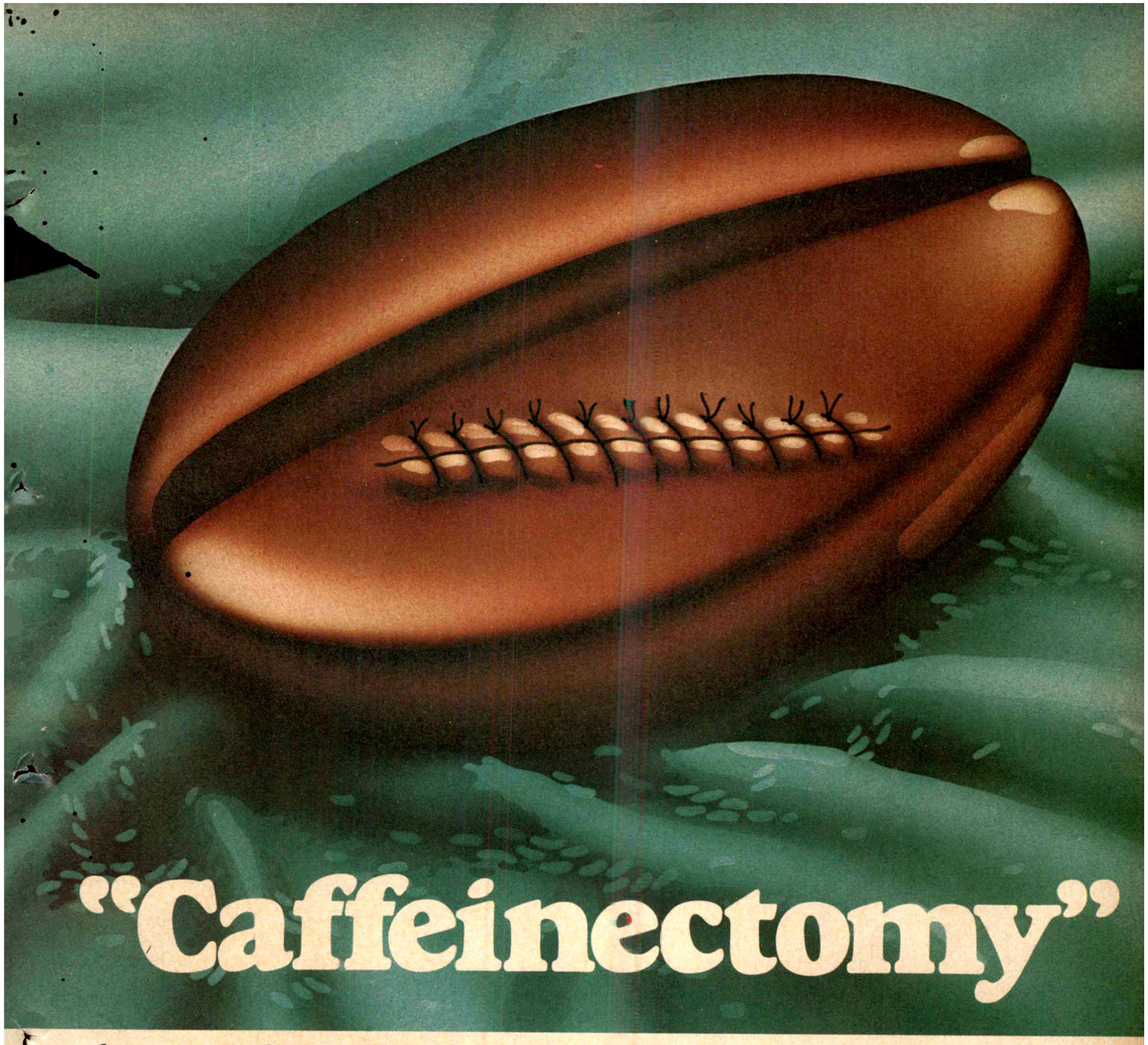

the procedure that benefits millions

Remove 97% of the caffein from 100% pure coffee, and you've got SANKA® Brand Decaffeinated Coffee – the ideal coffee for so many of your patients. SANKA® Brand contains only 3-5 mg of caffein per 6-oz cup (compared to about 50-100 mg in an equivalent cup of regular coffee).

Cardiac patients and hypertensives...insomniacs and anxious patients...patients with caffein-aggravated symptoms of a dermatologic condition...or the housewife overstimulated by caffein – they're just some of the patients who may benefit from your recommendation of SANKA® Brand. It's available in food stores everywhere...in instant, freeze-dried and ground-roast forms. And at restaurants, in convenient single-service packages.

Sanka®
BRAND
97% CAFFEIN-FREE COFFEE
Recommended by more physicians than all other brands of coffee combined

For a FREE Patient Sample Kit, please complete and return the coupon.

GF GENERAL FOODS

Maxwell House Division
General Foods Corporation
Box #3143
Kankakee, Illinois 60901

Please send me a FREE kit with patient samples, an informative booklet, "The No-Coffee Edict," and a special coupon for a FREE jar of SANKA® Brand Freeze-Dried Decaffeinated Coffee.

PHYSICIAN'S NAME _____
(please print)

SPECIALTY: ☐ GP/FP ☐ IM ☐ Surg ☐ DO ☐ OBG ☐ Card ☐ Gastr
☐ Psych ☐ Other (please specify) _____

STREET _____
(please print)

CITY _____ STATE _____ ZIP _____

PHYSICIAN'S SIGNATURE _____

AD-578

Ideal for dry skin care.

For dry skin care on a day-to-day basis, consider the soothing, softening, nondetergent cleansing properties of Alpha Keri Soap.

- Excellent cleansing properties eliminate harshness and irritation
- Contains Alpha Keri® therapeutic bath oil to soothe and soften skin
- Rich lather and delicate scent create outstanding patient acceptance

Alpha Keri® soap

The soothing, smoothing detergent-free cleanser

WESTWOOD
PHARMACEUTICALS INC.
Buffalo, New York 14213

In Canada, Belleville, Ontario K8N5E9

©1976, W.P. Inc.

Speckled (Particulate) Epidermal Nuclear IgG Deposition in Normal Skin

Correlation of Clinical Features and Laboratory Findings in 46 Patients With a Subset of Connective Tissue Disease Characterized by Antibody to Extractable Nuclear Antigen

Stephen D. Prystowsky, MD, Denny L. Tuffanelli, MD

• Clinical and laboratory findings were correlated from 46 patients with IgG localization in epidermal nuclei in a speckled (particulate) pattern on direct immunofluorescence of normal skin. Cutaneous manifestations included lupus erythematosus (LE), swollen hands or sclerodactyly, alopecia, vasculitis, and dyspigmentation. Systemic manifestations included arthritis or arthralgia, Raynaud's phenomenon, serositis, vascular headaches, mild renal disease, myositis, and sicca syndrome.

High titer (mean = 1:142, 800) serum antibody to extractable nuclear antigen (ENA) was found in 81%. Eighty-six percent had antibody to an RNase-sensitive antigenic component of ENA (ribonucleoprotein or RNP); 14% had antibody to an RNase-resistant ENA termed Sm.

Deposition of IgG in a speckled pattern in epidermal nuclei is an immunopathologic marker for a subset of connective tissue disease characterized by antibody to ENA. Those with Sm specificity had systemic LE (SLE). Those with RNP specificity had Raynaud's phenomenon usually associated with overlapping features of SLE, scleroderma, and/or dermatomyositis.

(*Arch Dermatol* 114:705-710, 1978)

Accepted for publication Sept 9, 1977.

From the Department of Dermatology, University of California Medical School, San Francisco.

Reprint requests to Department of Dermatology, University of California Medical School, San Francisco, CA 94143 (Dr Prystowsky).

Patients with overlapping features of systemic lupus erythematosus (SLE), scleroderma, and dermatomyositis have long been described.[1,2] Sharp and co-workers[3-5] recently associated certain of these patients with serum antibody to an RNase-sensitive extractable nuclear antigen (ENA) termed ribonucleoprotein (RNP). The observation that antibody to RNP appears to be an immunologic marker for "mixed connective tissue disease (MCTD)" has been confirmed by other investigators.[6-9]

Direct immunofluorescence on biopsy specimens of normal skin is a useful test for the evaluation of patients with SLE.[10-13] Gilliam et al have recently reported an association between serum antibody to ENA and immunoglobulin localization in epidermal nuclei.[14] On studying the cutaneous immunopathology of patients with connective tissue disease, we have frequently noted the presence of epidermal nuclear IgG deposition in patients with "mixed or overlap" features. The purpose of this article is to correlate the clinical features and laboratory findings from 46 patients with epidermal nuclear IgG localization. Deposition of IgG in a speckled (particulate) pattern appears to correlate with serum antibody to ENA and may be an immunopathologic marker for a subset of connective tissue disease characterized by anti-ENA.

PATIENTS AND METHODS

Sixty-two of 2,400 (3%) biopsy specimens from patients during the past five years demonstrated epidermal nuclear IgG deposition by direct immunofluorescence of clinically normal skin. Forty-six of these 62 patients were studied comprehensively by one of us (S.D.P.), using a pretested clinical research protocol. The remaining 16 patients were lost to follow-up and are not included in this article. Thirty-two of these 46 patients are currently being followed up in our clinic at the University of California; 14 were seen in consultation. Those not currently being observed were brought back and reexamined. Hospital and clinic records were reviewed, and additional test results were obtained when indicated. The presence or absence of the following clinical signs were specifically noted: cutaneous lupus erythematosus (chronic discoid, subacute, acute [malar], or lupus profundus), swollen hands or sclerodactyly, alopecia, periungual telangiectasia, vasculitis, dyspigmentation, photosensitivity, mucous membrane ulceration, acrocyanosis, erythema over joints, facial telangiectasia, cutaneous sclerosis, subcutaneous nodules, livedo reticularis, heliotrope lids, urticaria, calcinosis cutis, "Gottron" papules, arthritis or arthralgia, Raynaud's myalgia, pleurisy or pericarditis, adenopathy, severe headaches, prolonged hoarseness, renal disease, hepatomegaly or splenomegaly, myositis, sicca syndrome, dyspnea, thrombophlebitis, dysphagia, and neurologic disease. The following laboratory values were noted: antinuclear antibody (ANA), ENA, hypergammaglobulinemia, erythrocyte sedimentation rate greater than 30, rheumatoid factor, LE cells, hypocomplementemia, direct Coombs, lupus band test (immunoglobulin deposition at the dermoepidermal junction), anti-nDNA, hemoglobin level less than 11 gm/100 ml, WBC count less than 4,000 cells/cu mm, cryoglobulinemia, biologic false-positive test for syphilis (positive VDRL with a

Table 1.—Cutaneous Manifestation of 46 Patients With Epidermal Nuclear IgG Deposition

Cutaneous Manifestations	No.	%
Cutaneous LE	24	52
Chronic (DLE)	7	15
Subacute	14	30
Acute (malar)	5	11
Lupus profundus	1	2
Swollen hands or sclerodactyly	20	43
Alopecia	19	41
Periungual telangiectasia	19	41
Vasculitis	13	28
Dyspigmentation	10	22
Photosensitivity	10	22
Mucous membrane ulceration	8	17
Acrocyanosis	8	17
Erythema (elbows/knees/knuckles)	7	15
Marked facial telangiectasia	6	13
Cutaneous sclerosis	5	11
Subcutaneous nodules	4	9
Livedo reticularis	4	9
Heliotrope lids	4	9
Urticaria	3	7
Calcinosis cutis	2	4
Gottron's papules	1	2

Table 2.—Systemic Characteristics of 46 Patients With Epidermal Nuclear IgG Deposition

Systemic Characteristics	No.	%
Arthritis/arthralgia	43	93
Raynaud's phenomenon	37	80
Myalgia	26	57
Pleurisy/pericarditis	15	33
Adenopathy	14	30
Severe headaches	14	30
Prolonged hoarseness	11	24
Renal disease	10	22
Hepatomegaly/splenomegaly	10	22
Myositis	9	20
Sicca syndrome	9	20
Dyspnea	6	13
Thrombophlebitis	3	7
Dysphagia	3	7
CNS disease	3	7

negative FTA-absorbed), abnormal pulmonary function test results, and esophageal dysmotility.

The ENA was determined by the hemagglutination method of Sharp et al.[3] This test was performed with ENA-coated sheep erythrocytes before and after ribonuclease (RNase) treatment. A fall in titer of more than four dilutions after treatment was interpreted as RNase-sensitive and indicative of antibody to RNP. No great change in antibody titer after digestion of ENA with RNase (no more than a one-tube dilution decrease) was interpreted as RNase-resistant and termed Sm.

Cutaneous immunoglobulin deposits were detected by direct immunofluorescence of biopsy specimens of normal skin as previously described.[15] Sixty-four biopsy specimens were obtained from the 46 patients. Thirty-two biopsy specimens were from normal, sun-exposed skin (wrist and forearm); 32 were from normal, nonexposed skin (medial forearm near the antecubital fossa, back, or buttock).

The ANA was performed by the method of Holborow et al[16]; total hemolytic complement (CH50) by the method of Kabat and Mayer[17]; the third and fourth components of complement (C3 and C4) were measured by radial immunodiffusion; the C1q component of complement was determined by the method of Agnello et al.[18] Antibody to double-stranded (native) DNA was determined by the filter (M) assay of Ginsberg and Keiser.[19]

Table 3.—Laboratory Findings in 46 Patients With Epidermal Nuclear IgG Deposition

Study	No. Studied	No. Positive	(%)
Antinuclear antibody	46	45	(98)
Extractable nuclear antigen	43	35	(81)
Hypergammaglobulinemia	36	26	(72)
ESR > 30	43	31	(72)
Abnormal pulmonary function test results	25	16	(64)
Esophageal dysmotility	24	14	(58)
Rheumatoid factor	43	21	(49)
LE cells	39	18	(46)
Hypocomplementemia	40	16	(40)
Direct Coombs' test	25	9	(36)
Lupus band test	46	16	(35)
Anti-nDNA	42	10	(24)
Hemoglobin < 11 gm/100 ml	43	9	(21)
WBC count < 4,000/cu mm	43	8	(19)
Cryoglobulinemia	25	4	(16)
Biologic false-positive serology	32	1	(3)

RESULTS

The clinical diagnoses of the 46 patients were as follows: 32 (70%) had MCTD, 12 (26%) had SLE, 1 patient each had procainamide hydrochloride (Pronestyl)-induced LE and dermatomyositis.

There were 36 female and 10 male subjects yielding a sex ratio of 3.6:1. The ages ranged from 14 to 77 years with a mean age of 38 years.

Table 1 shows the cutaneous manifestations of the 46 patients. Cutaneous LE lesions were present in 24 patients (52%). The entire spectrum of cutaneous LE was observed in that 7 patients had persistent destructive discoid lesions, 14 patients had diffuse, nonscarring, poorly demarcated subacute lesions, and 5 patients had an acute malar eruption. One patient had lupus profundus. Swollen hands or sclerodactyly was observed in 20 patients (43%). Most of these patients had puffy fingers without much cutaneous sclerosis; only three patients had tightly bound-down skin with contractures. Persistent, diffuse, nonscarring alopecia occurred in 19 patients (41%). Periungual telangiectasia was observed in 19 patients (41%). Cutaneous vasculitis was present in 13 patients (28%). This group included biopsy proved leukocytoclastic vasculitis manifested clinically by purpuric papules and ulcers on the legs, as well as by patients with transient, painful dermal nodules that often occurred on the hands. Pigmentary disturbances were found in 10 patients (22%) and included focal and diffuse hyperpigmentation, poikiloderma, vitiligo, and hypopigmentation with follicular retention of pigment (the "salt and pepper" depigmentation of scleroderma). Photosensitivity was present in ten patients (22%). Other cutaneous findings included mucous membrane ulceration (17%), acrocyanosis (17%); erythema of the elbows, knees, or knuckles (15%) (as frequently seen in dermatomyositis); facial telangiectasia (13%); cutaneous sclerosis (11%); subcutaneous nodules (9%), livedo reticularis (9%); heliotrope lids (9%); urticaria (7%); calcinosis cutis (4%); and Gottron's papules (2%) (atrophic papules over the knuckles).

Table 2 depicts the systemic clinical features of these 46 patients. Arthritis or arthralgia was present in 43 patients. The arthritis was usually evanescent and nondeforming as usually seen in SLE. Only two patients had a deforming erosive arthritis. Raynaud's phenomenon occurred in 37 (80%) and was frequently the most persistent and bothersome symptom as well as the least responsive to ther-

Table 4.—Cutaneous, Systemic, and Laboratory Manifestations of 30 Patients With Antibody to Ribonucleoprotein

	No.		
	Studied	Positive	(%)
Cutaneous	30	16	(53)
Cutaneous LE			
Periungual telangiectasia	30	15	(50)
Swollen hands/sclerodactyly	30	14	(46)
Alopecia	30	13	(43)
Systemic			
Raynaud's	30	29	(97)
Arthritis/arthralgia	30	27	(90)
Myalgia	30	17	(57)
Adenopathy	30	12	(40)
Severe headaches	30	10	(33)
Pleurisy/pericarditis	30	9	(30)
Prolonged hoarseness	30	8	(27)
Renal disease	30	6	(20)
Myositis	30	6	(20)
Sicca synrome	30	6	(20)
Laboratory			
Anti-RNP antibody	30	30	(100)
Antinuclear antibody	30	30	(100)
Hypergammaglobulinemia	24	19	(79)
Abnormal pulmonary function test results	19	12	(63)
Esophageal dysmotility	21	13	(62)
Rheumatoid factor	29	17	(58)
LE cells	26	13	(50)
Lupus band test	30	9	(30)
Hypocomplementemia	26	7	(27)
Leukopenia (WBC count < 4,000/cu mm)	27	5	(19)
Anemia (hemoglobin < 11 gm/100 ml	27	4	(15)
Elevated anti-nDNA	27	3	(11)

apy. Mild myalgia, fatigue, and weakness were common (57%); moderate to severe myositis with elevated muscle enzyme levels was less frequent (20%). Episodes of pleurisy (15 patients) or pericarditis (three patients) occurred in 33%. Adenopathy was present in 30%. Four patients had lymph node biopsies to rule out a lymphoproliferative malignancy. Frequent, mild-to-moderate, vascular headaches occurred in 14 patients. Six of these patients had classic migraine. Prolonged hoarseness (unassociated with sicca syndrome) was observed in 24%. Renal disease was present in 10 patients, manifested as abnormal renal function test results (2), mesangial or focal glomerulitis (6), membranoproliferative glomerulonephritis (1), and membranous glomerulonephritis (1). Only two of these patients presently have renal insufficiency. Three patients had CNS disease. One patient each had trigeminal neuropathy, paresthesias, and prolonged moderate depression. No patients had seizures, psychoses or strokes.

Table 3 summarizes the laboratory findings in these patients. All patients had epidermal nuclear IgG deposition by direct immunofluorescence of normal skin, the criteria for patient selection. Figure 1 shows the speckled (particulate) immunofluorescence staining pattern that was always observed. Immunoglobulin (Ig) G was present in each biopsy specimen. Immunoglobulin was found in one case; the third component of

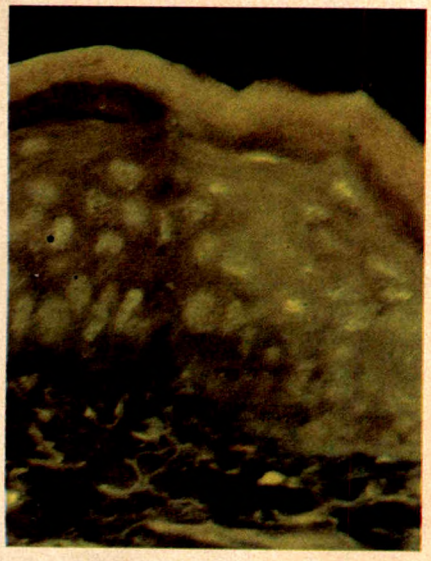

Fig 1.—IgG localization in epidermal nuclei in a speckled (particulate) pattern on direct immunofluorescence of normal skin (original magnification ×450).

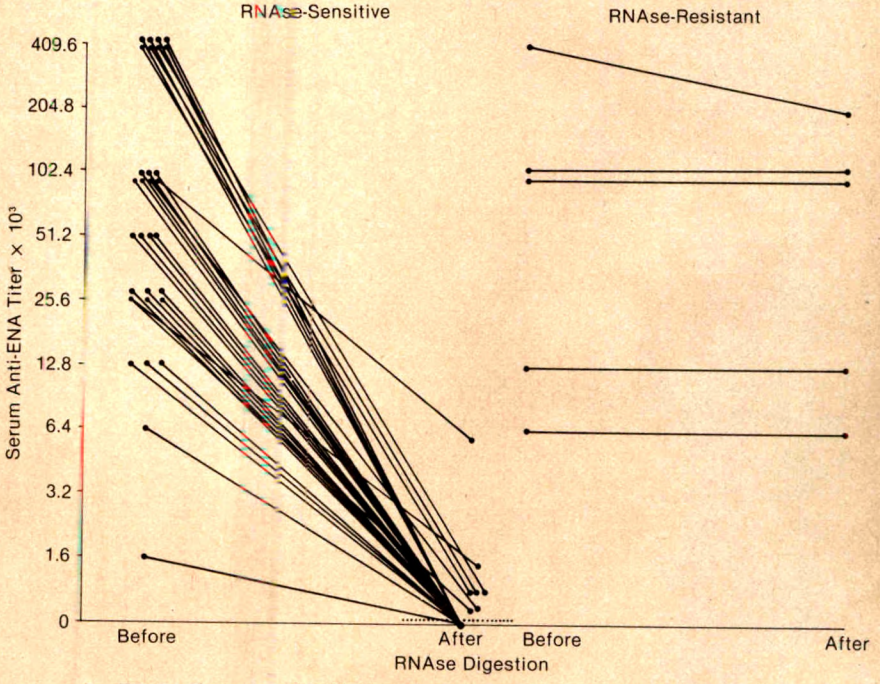

Fig 2.—Serum anti-ENA titers before and after RNase digestion.

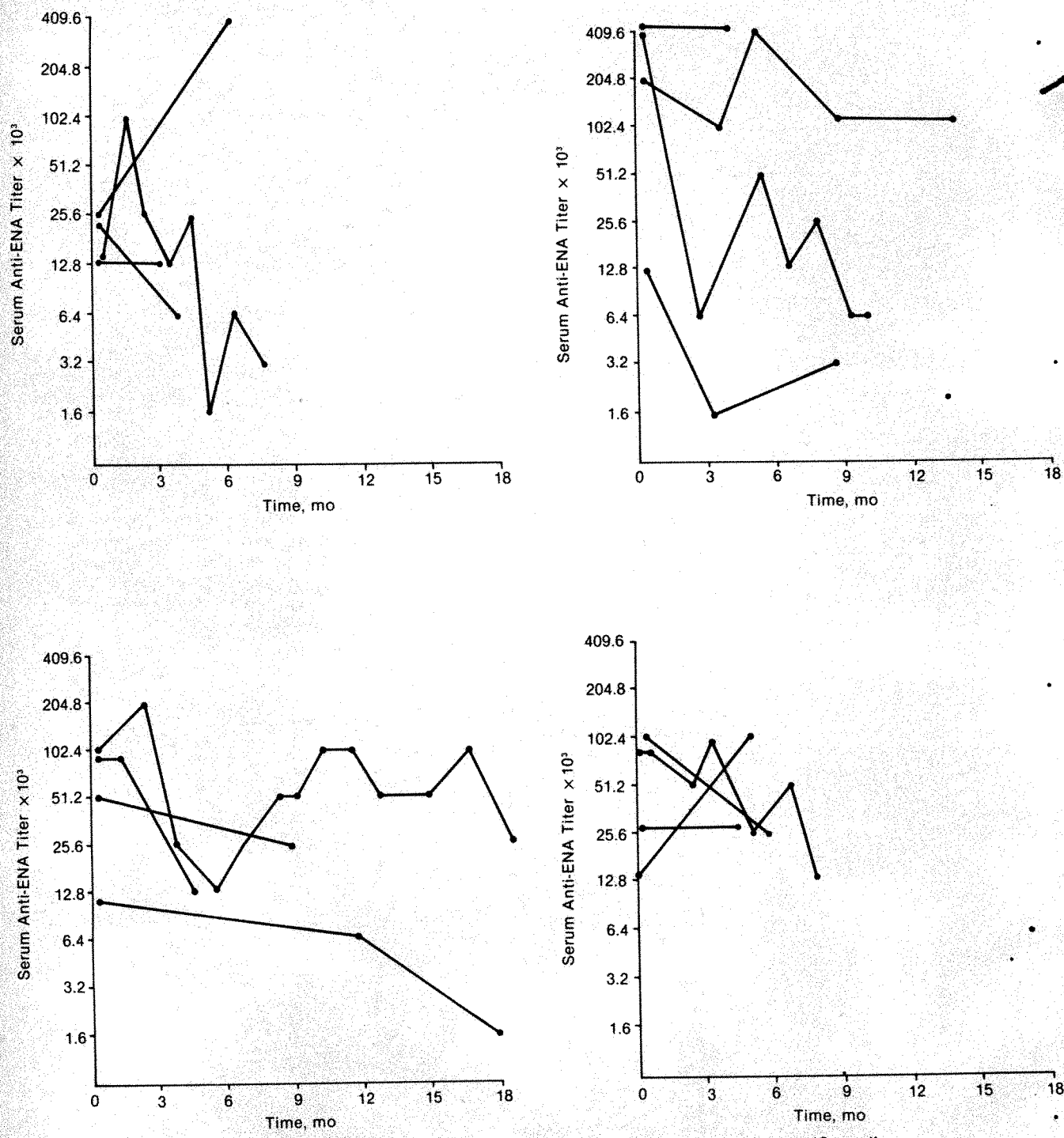

Fig 3.—Serial anti-ENA determinations on 16 patients followed up from four to 18 months.

complement was not observed. Antibody to ENA was present in 35 of the 43 (81%) patients tested. Thirty patients (86%) had RNP specificity; their clinical symptoms were compatible with MCTD. Five patients (14%) had Sm. These patients had typical LE. The serum anti-ENA titer ranged from 1,600 to 409,600 (Fig 2). (The highest antibody titer was recorded for patients with several determinations; sera were not diluted greater than 409, 600). The mean positive titer was 142,800; the median was 102,400. Figure 2 shows anti-ENA titers before and after RNase digestion. The 30 patients designated as RNase-sensitive all had a fall in titer of at least four tube dilutions; 23 of these patients dropped to less than 1:200 after antigen digestion with RNase. The five patients designated as RNase-resistant had a fall in titer of one tube dilution or less. Figure 3 shows serial anti-ENA determinations on 16 patients followed up from four to 18 months. The test results remained positive in all cases; the antibody titer appears to fluctuate widely in certain patients.

Forty-five patients (98%) had a positive ANA, usually in high titer. The immunofluorescent nuclear staining patterns were as follows: speckled (particulate) (73%), homogeneous (49%), and peripheral (16%). The nucleolar staining pattern was not observed. Twenty-nine percent of the patients had two or more patterns. The prevalence of the speckled pattern increases when the 30 patients with anti-RNP are separated. The ANA nuclear staining patterns in the more clearly defined "RNP subset" of patients were as follows: speckled (93%), homogeneous (37%), and peripheral (17%). Thirty-seven percent had two or more patterns. Sixty-three percent had only the speckled (particulate) pattern. High-titer ANA was present in 83%.

Abnormal pulmonary function tests were present in 64% of those studied. Fifty-two percent had a restrictive defect; 32% had a diffusion defect, and 16% had abnormal restrictive and diffusion test results.

Subepidermal immunoglobulins in normal skin (positive lupus band test) were observed in 16 of 46 patients (35%). Six of 32 (19%) were positive on non-sun-exposed skin; 14 of 33 (42%) were positive on sun-exposed skin. Seventeen patients had simultaneous biopsies in both sites: both tests were positive in 4 patients; both tests were negative in 10 patients; 3 patients (18%) had positive test results on sun-exposed sites with simultaneous negative test results on nonexposed skin. (Other abnormal laboratory test results are noted in Table 3.)

Table 4 demonstrates, for comparison, the important cutaneous, systemic, and laboratory features of the 30 patients with antibody to RNP.

COMMENT

Deposition of IgG in epidermal nuclei in a speckled (particulate) pattern on direct immunofluorescence of normal skin is an easily detectable immunopathologic marker for a subset of connective tissue disease characterized by antibody to ENA. The five patients with Sm specificity had classical LE; the 30 patients with RNP specificity were characterized by the Raynaud phenomenon (97%), usually associated with overlapping features of SLE, scleroderma, and/or dermatomyositis.

Extractable nuclear antigen is a saline-soluble (extractable) nuclear antigen with several distinct antigenic sites.[4,20-23] One is a RNP that is sensitive to RNase and trypsin; the other is resistant to RNase and appears to be identical to the previously described Sm antigen.[20]

Gilliam and co-workers[11] have recently reported an association between serum antibody to ENA and immunoglobulin localization in epidermal nuclei. They could not differentiate between anti-RNP and anti-Sm by direct immunofluorescence. Thus, patient populations selected by this immunopathologic marker would be expected to show an admixture of clinical and laboratory features from both groups.

The cutaneous features of our 46 patients with epidermal nuclear IgG deposition show manifestations of SLE, scleroderma, and dermatomyositis. The most striking skin lesions were cutaneous LE (52%), swollen hands or sclerodactyly (43%), and alopecia (41%). There was little difference in cutaneous manifestations between these 46 patients and the 30 patients listed in Table 4 with documented antibody to RNP.

The systemic characteristics listed in Table 2 also show overlapping features of SLE, scleroderma, and dermatomyositis. The most striking symptom was Raynaud's phenomenon present in 37 patients (80%). Muscle weakness was frequently clinically more prevalent than the objective laboratory tests indicated (muscle enzymes, electromyogram, muscle biopsy). Dyspnea was infrequent (13%) even though pulmonary function test results were abnormal in 64% of the patients tested. The major difference between the patients in Tables 2 and 4 is that Raynaud's was present in 29 of 30 patients (97%) with anti-RNP. This association seems to be highly significant and most remarkable.

Prolonged hoarseness (27%) and frequent mild-to-moderate vascular headaches (33%) may be associated with elevated RNP antibody. These symptoms have not been mentioned by previous investigators as part of the MCTD or RNP subset of connective tissue disease. Many patients with prolonged hoarseness had frequent normal ear, nose, and throat examination results. The apparent increase in vascular headaches may be related to Raynaud's phenomenon.

The low prevalence of CNS disease and severe renal disease in the RNP subset has been previously well described.[3,5,6,8,9,22,23] Only one patient had diffuse proliferative glomerulonephritis with progressive renal insufficiency.

Multiple nuclear immunofluorescent staining patterns have been previously reported in connective tissue disease.[24] It is likely that all our patients had high titer speckled antinuclear antibodies at some time during their course since anti-ENA is associated with a speckled pattern, and the pattern observed by direct immunofluorescence of normal skin was also speckled. The homogeneous pattern may have obscured the speckled pattern in certain patients when both were present in high titer. Speckled and particulate have been used interchangeably in this article; however, particulate may be more accurate in that the "fine dot-like speckled pattern" that Burnham has observed in scleroderma and Raynaud's disease was not observed.[23] Newer substrates may be developed in the future that will make it easier to distinguish the subtle differences among the particulate patterns.

Eight of the patients with speckled epidermal nuclear IgG deposition had negative ENA test results when studied. The clinical diagnoses of these patients were as follows: SLE (4), MCTD (3), and dermatomyositis (1). The time interval between the skin biopsy for direct immunofluorescence and the serum ENA determinations in these 8 patients was less than six months (2), six months to one year (3), one to two years (3). These data suggest that a temporal relationship may exist between the immunopathology and the presence of high-titer

serum antibody to ENA. Figure 3 illustrates that anti-ENA antibody does not always stay elevated in high titer for long periods of time. The titers may eventually drop to zero in certain patients.[22] Therefore, if patients are selected with positive speckled epidermal nuclear IgG deposition in biopsy specimens that were performed months (or years) previously, the serum ENA may be negative if studied at a different time. It is also likely that other nuclear antibodies that have similar particulate fluorescence patterns may be present in high enough titer to demonstrate epidermal nuclear staining.[25] We have recently described eight patients with nucleolar IgG deposition that manifested scleroderma-like features with high-titer nucleolar ANA.[26] This may further explain the negative ENA test results in some of these patients. The particulate (speckled) patterns can be distinguished from the nucleolar pattern.

Epidermal nuclear IgG deposition reflects high-titer serum ANAs. These antibodies are usually directed to components of ENA. Anti-RNP may be present in higher titer and remain elevated longer than most other ANAs.[5] Selection bias may account for the apparent high proportion of RNP patients relative to Sm patients in our series.

It is important to emphasize that not all patients with overlap connective tissue disease syndromes have RNP antibody. This is especially true in the absence of Raynaud's phenomenon, which is the most characteristic clinical symptom associated with anti-RNP. However, none of these 46 patients had Raynaud's phenomenon alone without other clinical features. The combination of Raynaud's, nondeforming arthritis, and cutaneous LE appears to be the mildest end of the RNP spectrum. Raynaud's associated with classical scleroderma (cutaneous sclerosis and contractures) is usually not associated with anti-RNP or epidermal nuclear IgG localization.

These findings reemphasize the importance of cutaneous immunopathology in the diagnosis and management of patients with connective tissue disease, particularly those with overlapping clinical features. Deposition of IgG in a speckled (particulate) pattern appears to correlate with high-titered serum antibody to ENA and is an immunopathologic marker for a subset of connective tissue disease.

Elaine Vander-Beugle and Judy Woods gave technical assistance. Dianne Oliver, MD, performed the ENA tests.

References

1. Tuffanelli DL, Winkelmann RK: Scleroderma and its relationship to the "collagenoses": Dermatomyositis, lupus erythematosus, rheumatoid arthritis and Sjogren's syndrome. *Am J Med Sci* 243:133-146, 1962.
2. Dubois EL, Chandor S, Friou GJ, et al: Progressive systemic sclerosis (PSS) and localized scleroderma (morphea) with positive LE cell test and unusual systemic manifestations compatible with systemic lupus erythematosus (SLE). *Medicine* 50:199-222, 1971.
3. Sharp GC, Irvin WS, Tan EM, et al: Mixed connective tissue disease: An apparently distinct rheumatic disease syndrome associated with a specific antibody to an extractable nuclear antigen (ENA). *Am J Med* 52:148-159, 1972.
4. Sharp GC, Irvin WS, Laroque RL, et al: Association of autoantibodies to different nuclear antigens with clinical patterns of rheumatic disease and responsiveness to therapy. *J Clin Invest* 50:350-359, 1971.
5. Sharp GC: Mixed connective tissue disease: Overlapping syndromes. *Clin Rheum Dis* 1:561-572, 1975.
6. Farber SJ, Bole GG: Antibodies to components of extractable nuclear antigen: Clinical characteristics of patients. *Arch Intern Med* 136:425-431, 1976.
7. Hench PK, Edgington T, Tan EM: The evolving clinical spectrum of mixed connective tissue disease (MCTD). *Arthritis Rheum* 18:404, 1975.
8. Gilliam JN, Prystowsky SD: Mixed connective tissue disease syndrome: The cutaneous manifestations of patients with high titer serum antibody to RNase sensitive extractable nuclear antigen (ENA). *Arch Dermatol* 113:583-587, 1977.
9. Leibfarth JH, Persellin RH: Characteristics of patients with serum antibodies to extractable nuclear antigens. *Arthritis Rheum* 19:851-856, 1976.
10. Burnham TK, Fine G: The immunofluorescent "band" test for lupus erythematosus: III. Employing clinically normal skin. *Arch Dermatol* 103:24-32, 1971.
11. Tuffanelli DL: Lupus erythematosus. *Arch Dermatol* 106:553-566, 1972.
12. Gilliam JN, Cheatum DN, Hurd ER, et al: Immunoglobulin in clinically uninvolved skin in systemic lupus erythematosus: Association with renal disease. *J Clin Invest* 53:1434-1440, 1974.
13. Schrager MA, Rothfield NF: Clinical significance of serum properdin levels and properdin deposition in the dermal-epidermal junction in systemic lupus erythematosus. *J Clin Invest* 57:212-221, 1976.
14. Gilliam JN, Smiley JD, Ziff M: Correlation between serum antibody to extractable nuclear antigen and immunoglobulin localization in epidermal nuclei. *Clin Res* 22:611A, 1974.
15. Kay DM, Tuffanelli DL: Immunofluorescent techniques in clinical diagnosis of cutaneous disease. *Ann Intern Med* 71:753-762, 1969.
16. Holborow EJ, Weir DM, Johnson CD: A serum factor in lupus erythematosus with affinity for tissue nuclei. *Br Med J* 2:732-734, 1957.
17. Mayer MM: Complement and complement fixation, in Kabat EA, Mayer MM (eds): *Experimental Immunochemistry*, ed 2. Springfield, Ill, Charles C Thomas Publisher, 1961, p 135.
18. Agnello V, Winchester RJ, Kunkel HG: Precipitin reactions of the C1q component of complement with aggregated gammaglobulin and immune complexes in gel diffusion. *Immunology* 19:909-919, 1970.
19. Ginsberg B, Keiser H: A millipore filter assay for antibodies to native DNA in sera of patients with systemic lupus erythematosus. *Arthritis Rheum* 16:199-207, 1973.
20. Tan EM, Kunkel HG: Characteristics of a soluble nuclear antigen precipitating with sera of patients with systemic lupus erythematosus. *J Immunol* 96:464-471, 1966.
21. Northway JD, Tan EM: Differentiations of antinuclear antibodies giving speckled staining patterns in immunofluorescence. *Clin Immunol Immunopathol* 1:140-154, 1972.
22. Reichlin M, Mattioli M: Correlation of a precipitin reaction to an RNA-protein antigen and a low prevalence of nephritis in patients with systemic lupus erythematosus. *N Engl J Med* 286:908-911, 1972.
23. Parker MD: Ribonucleoprotein antibodies: Frequencies and clinical significance in systemic lupus erythematosus, scleroderma and mixed connective tissue disease. *J Lab Clin Med* 82:769-775, 1973.
24. Dorsch CA, Gibbs CB, Stevens MB, et al: Significance of nuclear immunofluorescent patterns. *Ann Rheum Dis* 28:313-319, 1969.
25. Burnham TK, Bank PW: Antinuclear antibodies: I. Patterns of nuclear immunofluorescence. *J Invest Dermatol* 62:526-534, 1974.
26. Prystowsky SD, Gilliam JN, Tuffanelli DL: Epidermal nucleolar IgG deposition in clinically normal skin. *Arch Dermatol*, 114:536-538, 1978.

Psoralen-UVA-Treated Psoriatic Lesions

Ultrastructural Changes

Ken Hashimoto, MD; Hiromu Kohda, MD, PhD; Masanobu Kumakiri, MD; Steven L. Blender, MD; Isaac Willis, MD

• Psoralen-ultraviolet light (PUVA)-treated psoriatic lesions were studied for ultrastructural changes. In early stages of treatment, sunburn cells in the epidermis and bizarre giant cells in the dermis were more frequently observed. When clinical improvement was apparent, these changes had subsided. Dermal abnormality in long-term therapy consisted of a thick perivascular coat of amorphous substance. No abnormality was found in the epidermal keratinocytes in long-term therapy, except a clustering and giant cell formation of melanocytes, a heavy melanization of keratinocytes, and hyperkeratosis. Low-dose initiation and slow increment of both 8-methoxypsoralen and UVA is probably a reasonable regimen for benign dermatoses such as psoriasis because it will allow enough time for the skin to become more protected, while the therapeutic results are as satisfactory as in a high-dose schedule.

(*Arch Dermatol* 114:711-722, 1978)

Long-wavelength ultraviolet light (UVA, 320 to 400 nm) has been found to be effective for the treatment of psoriasis when the skin is prepared with 8-methoxypsoralen (8-MOP), either systemically or topically. This agent was first used by El Mofty[1] for the treatment of vitiligo. It has been known that UVA immediately oxidizes preexisting melanin (immediate pigment darkening or tanning)[2] and later stimulates neogenesis by melanocytes. The 8-MOP seems to intensify the latter mechanism.

The usefulness of 8-MOP in the treatment of psoriasis is, however, due to its toxic effect on the nuclear DNA and suppression of mitosis. A covalent linkage of 8-MOP to pyrimidine bases, which requires UVA at 365 nm, produces psoralen-DNA photoadducts.[3-5] The DNA replication and mitosis are then suppressed in the lesion.

In spite of a common use of PUVA therapy for psoriasis[6-9] and apparent good results in mycosis fungoides,[10] atopic eczema,[11] and vitiligo,[12] its biologic effects at the ultrastructural level have so far been poorly understood. In this study, fine structural changes in the lesion due to a relatively low dose will be described.

MATERIALS AND METHODS

Patients

Six white psoriatic patients, who were otherwise healthy, were selected because of their consistent participation in the program and lower light-scattering and light-absorbing properties of their skin. Also, erythema and darkening of the skin could be better evaluated in the white skin. The longest treatment given lasted five months.

Biopsy Materials

Clinically and histologically typical plaque-type lesions (Table) and normal skin from the corresponding (symmetrically opposite) areas underwent biopsies. Normal skin adjacent to the lesion was also included in some cases. The same lesions that underwent biopsies before the treatment were operated on again after various lengths of treatment (Table). Biopsies were performed 72 to 96 hours after the last treatment to eliminate acute effects of the irradiation. Specimens were taken with the 4-mm punch with the patient under 1% procaine hydrochloride local anesthesia.

All specimens were fixed with 5% glutaraldehyde and postfixed with 1% osmic acid. Araldite was used for embedding. Thin sections were stained with uranyl acetate and lead citrate. The details of our electron microscopic methods have been published elsewhere.[13]

PUVA Protocol

Our protocol for white patients specified an initial exposure of four minutes at 33 cm (13 inches) bulb-patient distance, two hours after oral administration of 8-MOP. Patients were initially given 10 mg of 8-MOP, which was increased 10 mg per treatment until a maximum dosage of 0.6 mg/kg was reached (ie, 30 or 40 mg). Exposure times remained at four minutes until the maximum 8-MOP dosage was reached and then were increased one minute per treatment. The treatments were given twice a week. The maximum exposure of 30 minutes was reached at the 29th or 30th treatment. All the patients tolerated this schedule. About 80% of the treated patients remained in remission with a continuous twice-a-week regimen. Some patients remained in remission without further treatment for two to three months.

Topical PUVA therapy required an

Accepted for publication Aug 30, 1977.

From the Veterans Administration Hospital and the Division of Dermatology, Department of Medicine, University of Tennessee Center for the Health Sciences, Memphis (Drs Hashimoto, Kohda, Kumakiri, and Blender); and the Division of Dermatology, Department of Medicine, Veterans Administration Hospital, Decataur, Ga (Dr Willis).

Reprint requests to Research Service (151), Veterans Administration Center, 4100 W Third St, Dayton, OH 45428 (Dr Hashimoto).

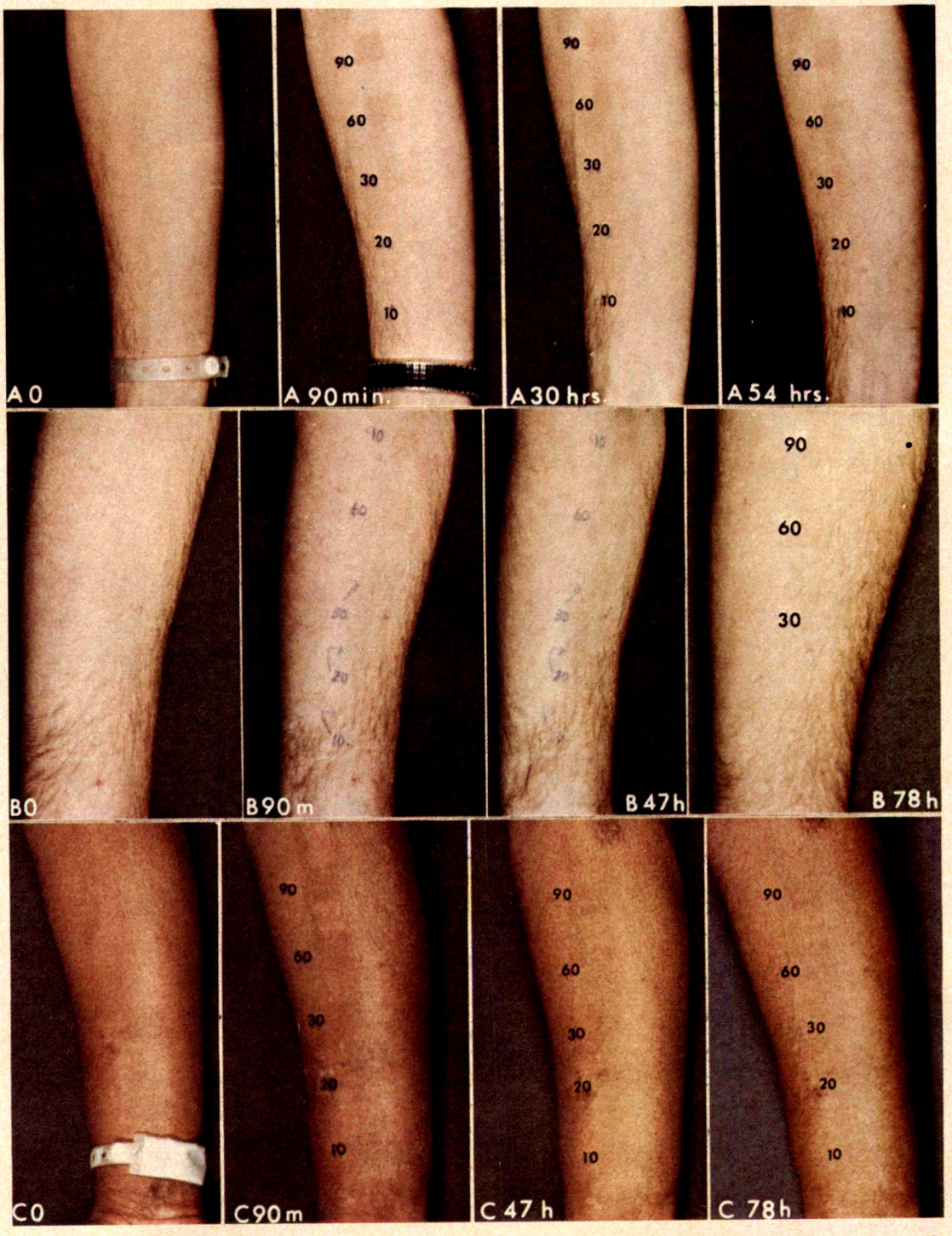

Fig 1.—Three volunteers at 0 time (AO, BO, CO), 90 minutes after exposure (A90m, B90m, C90m). Numbers (10, 20, 30, 60, 90) written on volunteers' arms represent minutes of exposure at those sites. Volunteers were given 8-methoxypsoralen orally (A, 40 mg; B, 50 mg; and C, 40 mg) two hours prior to exposure.

Psoriasis Patients*							
		Patients and Volunteers					
		1 59 yr	2 57 yr	3 58 yr	4 58 yr	5 71 yr	6 45 yr
Location		Leg	Leg	Shoulder blade	Leg	Buttock	Lower back
Joule/sq cm (365 nm)		140.85	118.50	113.85	57.30	55.80	41.10
	A	0.71	0.62	0.31	0.35	0.46	0.41
Epidermal thickness, mm		$\frac{B}{A} = \frac{1}{8}$	$\frac{1}{8}$	$\frac{1}{4}$	$\frac{1}{5}$	$\frac{1}{8}$	$\frac{1}{3}$
	B	0.09	0.08	0.08	0.07	0.06	0.13
	A	+ +	+ +	+	+ +	+ +	+ +
Mitosis							
	B	–	–	–	+	+	–
	A	+ + +	+ + +	+ +	+ +	–	+ +
Intercellular space widening							
	B	–	–	–	–	±	–
	A	+ + +	+ + +	+ +	+ +	±	+ + +
Lipid granule							
	B	+	+	+	–	±	–
	A	+ + +	+ + +	+ +	+ +	±	+ +
Parakeratosis							
	B	–	–	–	–	±	–
	A	–	–	–	–	–	–
Sunburn cell							
	B	–	–	–	±	–	–
	A	+	+	+	+	+	+
Melanogenesis							
	B	+ +	+ +	+ +	+ +	+ + +	+
	A	+	+	+	+	+	+
Transferred melanosome							
	B	+ + +	+ + +	+ + +	+ +	+ + +	+
	A	+	+	+ +		+	–
Basal lamina multiplication							
	B	+ + +	+ +	+ +	+ +	+ +	+
	A	+ +	±	+ +	+	+	+
Perivascular amorphous substance							
	B	+ +	+ +	+ + +	+	+ +	+ +
	A	+	+	–	+	–	+
Connective tissue cell abnormality							
	B	+	+	+	+	+	+ +

*All patients were white men. A indicates pretreatment; B, posttreatment.

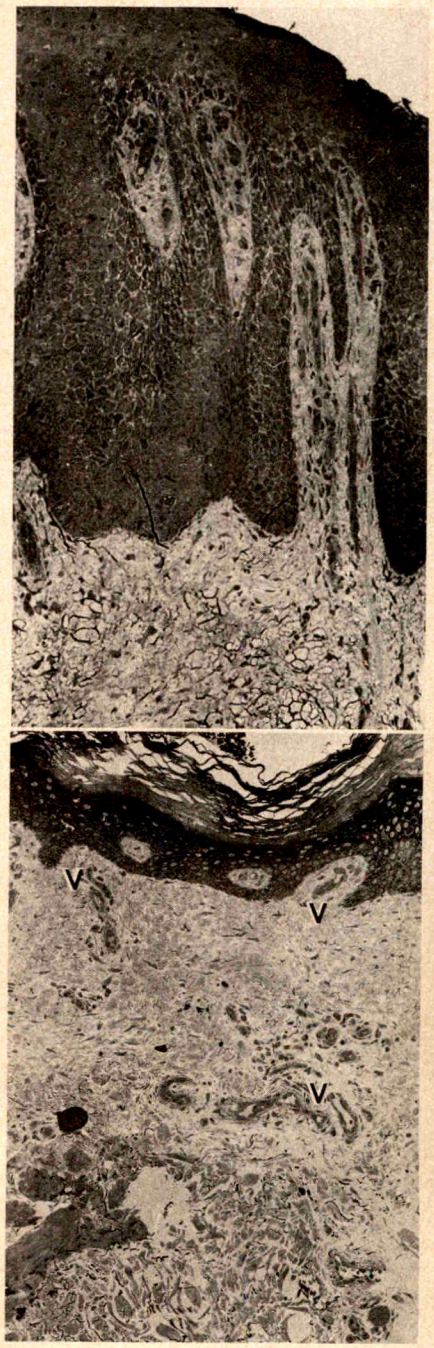

Fig—2. Top, Typical psoriatic lesion before psoralen-ultraviolet light therapy, except that parakeratotic horny layer was desquamated (×110). Bottom, After psoralen-ultraviolet light therapy of 43 treatments during 22 weeks (129.15 joules/sq cm), epidermis is normalized except for severe hyperkeratosis. Vascular wall (V) is thickened (×110).

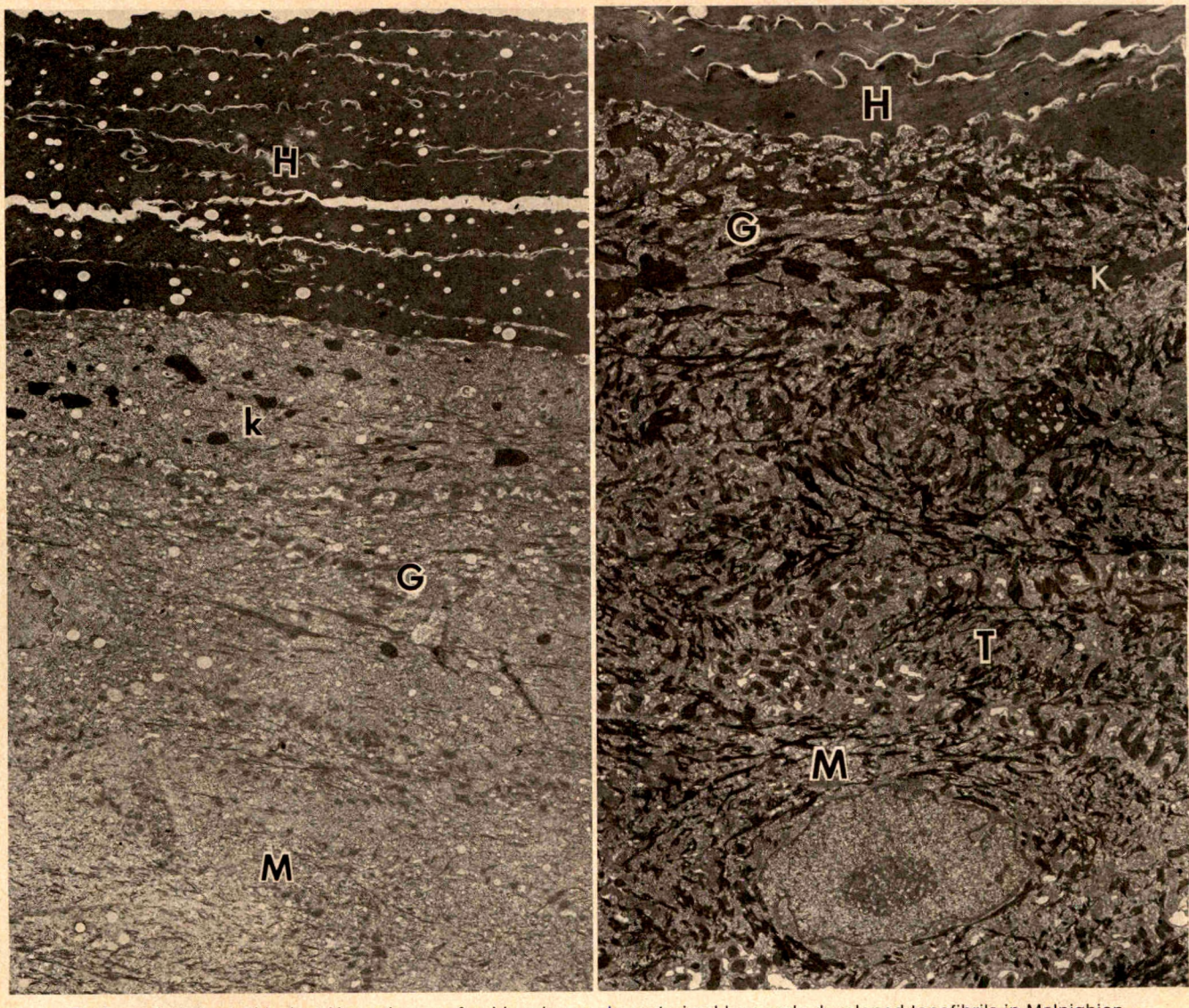

Fig 3.—Left Untreated lesion. Upper layers of epidermis are characterized by poorly developed tonofibrils in Malpighian layer (M); widening of granular layer (G) to several cell layers, small-sized keratohyaline granules (k), loosely attached parakeratotic horny cells (H), and numerous vacuoles, most prominent in horny layer (original magnification ×10,000). Right, Treated lesion (43 treatments; 129.15 joules/sq cm). In contrast to untreated lesion, treated lesion is normalized in all characteristics: well developed, thick tonofibrils (T) in Malpighian layer (M); decreased number of granular cells (G) to one or two cell layers; larger-sized keratohyaline granules (K) (cf, Fig 3, left); authokeratotic horny cells (H), and few or no vacuoles in these cells (original magnification ×10,000).

application of 1% 8-MOP in an acetone-alcohol-propylene glycol base (Oxsoralen lotion, 1%) to the lesion 90 minutes prior to the treatment. The UVA dose and frequency of treatments were similar to those used for systemic treatment.

Light Source

Our light source consisted of two apposed units, each of 12 bulbs. Irradiation could be administered to the patient simultaneously from the front and from the back at a bulb-skin distance of 33 cm (13 inches). The bulbs installed emitted UVA sharply peaking at 365 nm (98.1% of the total output). One small peak was noted at 313 nm (1.9% of the total output). At the distance of 33 cm, this source produced 0.15 joule/sq cm/min; therefore, the initial four-minute irradiation delivered 0.6 joule/sq cm and the maximum 30-minute exposure delivered 4.5 joules/sq cm.

Wavelength Determination and Dosimetry

Our therapeutic unit was measured for wavelength using a spectroradiometer. Power intensity was measured with Eppley Thermopile 13416.

Phototoxic Dose Determination

Three patients were chosen on the basis of their skin color to determine the minimal phototoxic dose[14,15] after oral administration of 8-MOP and UVA light. The same light source as used for PUVA therapy was employed; the light source emitted 0.15 joule for each minute of exposure at a distance of 33 cm.

Patients A and C were being treated for stasis ulcer of the lower extremities and had no dermatoses of the upper extremities. Patient B had psoriasis of the trunk and lower extremities only, and gave no history of previous treatments with either UVA or UVB. Patient A was blond and his complexion was fair. Patient B was a brunette of Mediterranean extraction and patient C was a moderately dark black.

Each patient was given 8-MOP orally two hours before exposure to UVA light in a dosage modified for their weight, ie, patient A, 40 mg; patient B, 50 mg; and patient C, 40 mg. Their eyes were protected with glasses. Pretreatment photographs were taken (Fig 1; A0, B0, and

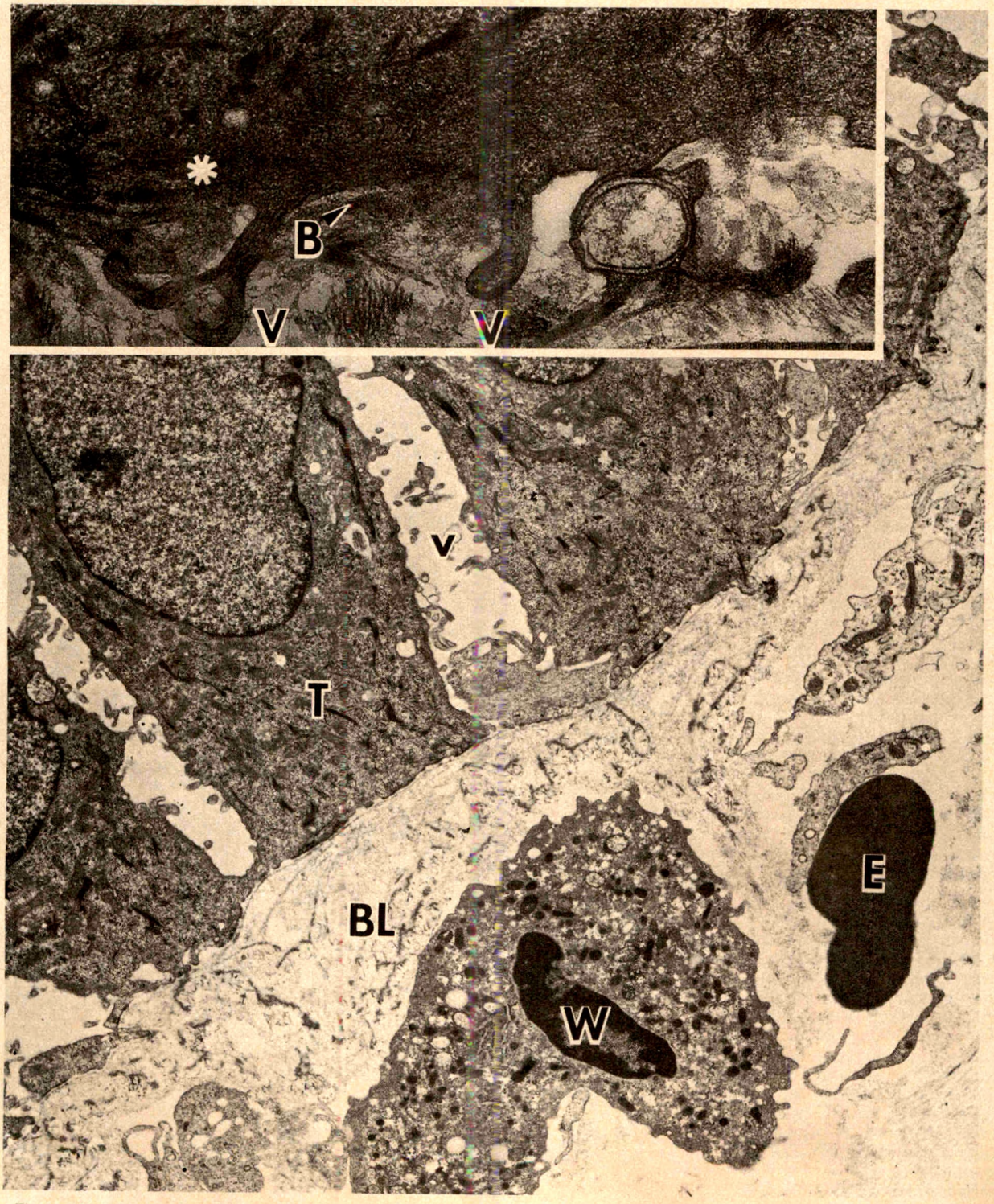

Fig 4.—Untreated lesion. Following features are seen in higher magnification: multiplication of basal lamina (BL), widened intercellular space and villous projections (V) of periphery of keratinocyte, and poorly developed, wispy tonofibrils (T). Erythrocyte (E) and neutrophil (W) are seen in upper dermis. Asterisk indicates intracellular vacuoles (original magnification ×15,000). Inset, Untreated lesion. Villous projections similar to those present on lateral and upper borders of basal cells (cf, main illustration) project through basal lamina (B), which is mostly defective in this area. Along basal border and within pseudopod-like villi (V) of basal cells, thick bundle of actin-like microfilaments (70 A) (asterisk) is present (original magnification ×28,875).

C0). The entire arm being tested was covered by a single-strength aluminum foil except for five 1.5 × 1.5 cm squares on the flexor surface of either the right or left forearm. The most distal square was exposed to 10 minutes (1.5 joules), the next 20 minutes (3.0 joules), the next 30 minutes (4.5 joules), the next 60 minutes (9.0 joules), and the most proximal square 90 minutes (13.5 joules).

During the first 90 minutes of treatment no changes were apparent. This may have been due to the inability to compare adjacent skin since it was covered with aluminum foil. After 90 minutes the aluminum foil was removed. The response was strong in patient A, moderate in patient B, and mild in patient C (Fig 1): No change was noted for the 10- and 20-minute exposures. The 30-minute exposure area showed minimal hyperpigmentation. The 60-minute exposure area showed moderate hyperpigmentation. The pigmentation at 90-minute exposure sites was slightly greater than at 60-minute sites (Fig 1; A90m, B90m, C90m).

Twenty-four hours after the exposure the hyperpigmentation began to fade and it was replaced by mild erythema in 60- and 90-minute exposure sites, or a mild erythema was seen as immediate tanning began to fade: The erythema was barely noticeable and could be abolished by diascopy. Forty-seven hours after exposure, hyperpigmentation and minimal erythema were still present at the 60- and 90-minute exposure sites (Fig 1; B47h, C47h). There was no erythema or hyperpigmentation in the 30-minute exposure site. Seventy-eight hours after exposure, scaliness of the skin was noted; however, no additional erythema was seen. Fading of the hyperpigmentation in 60- and 90-minute exposure sites was beginning (Fig 1; B78h, C78h).

Heat production of our UVA unit was minimal in all experiments and therapeutic procedures. No individual perspired during the procedures.

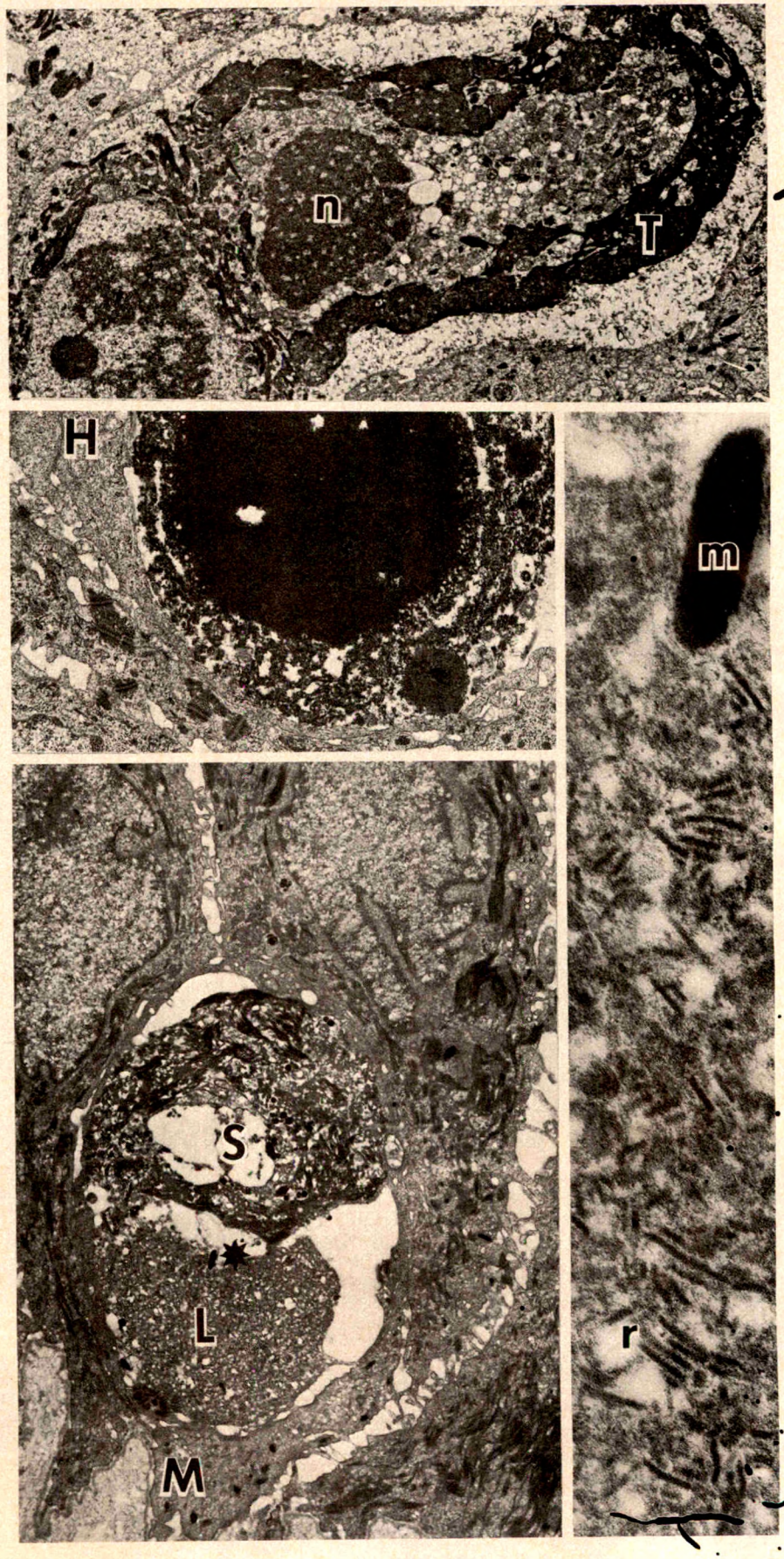

Fig 5.—Top, Treated lesion (43 treatments; 129.15 joules/sq cm). Typical sunburn cell with pyknotic nucleus (n) coagulated tonofibrils (T) is seen just above basal layer (original magnification ×10,000). Center left, Treated lesion (five treatments; 3.15 joules/sq cm). Degenerated and condensed cell, presumably a migrated leukocyte, is seen in basal layer. This cell is partially surrounded by histiocyte (H), (original magnification ×20,000). Bottom left, Treated lesion (43 treatments; 129.15 joules/sq cm). Sunburn cell (S) with aggregated tonofibrils and large vacuole is seen in basal layer. This cell is surrounded by degenerating Langerhans cell (L) (see Fig 5, right and melanocyte [M]). Asterisk indicates area enlarged in Fig 5, bottom right (original magnification ×5,500). Right, Treated lesion (43 treatments; 129.15 joules/sq cm). Enlargement of Langerhans cell shown in Fig 5, bottom left (asterisk) shows numerous abnormal rods (r) and phagocytosed melanosome (m), (original magnification ×78,300).

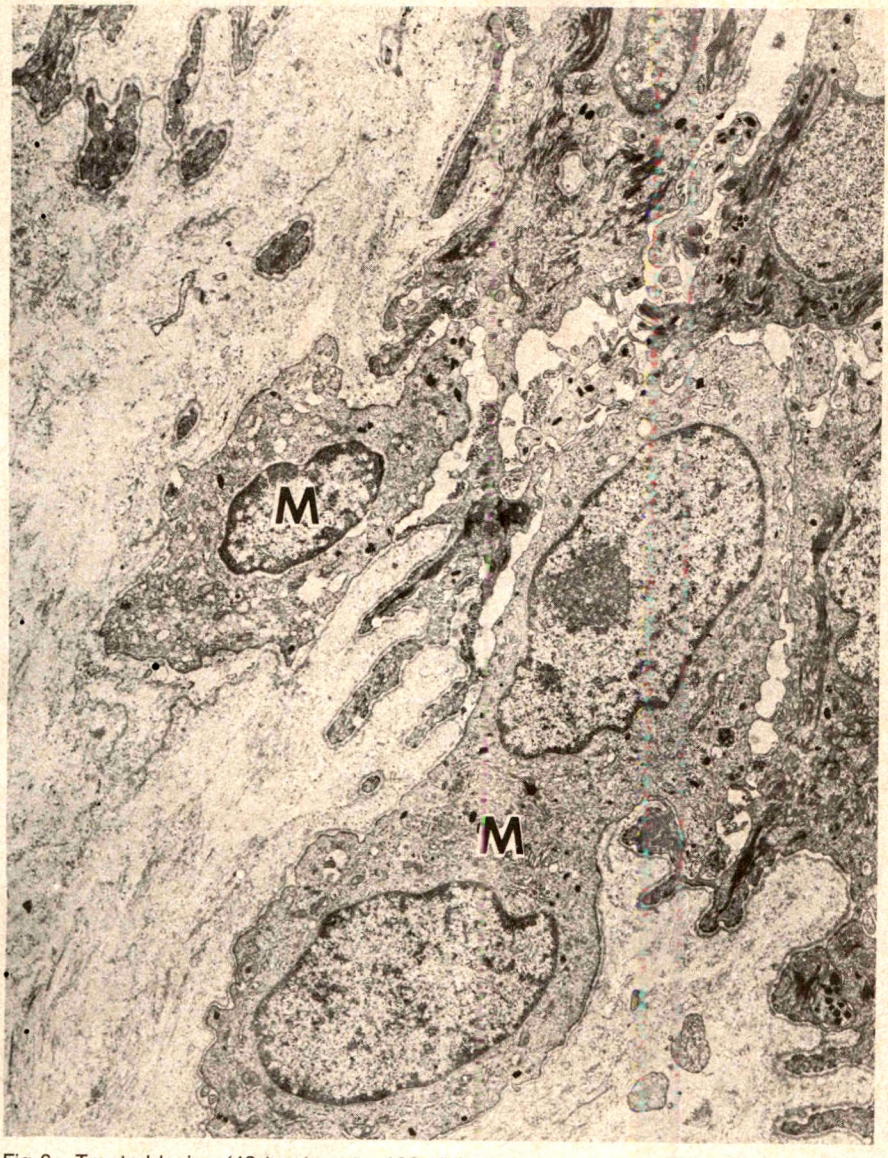

Fig 6.—Treated lesion (43 treatments; 129.15 joules/sq cm). Two melanocytes (M) are clustered in one area. One of these is double-nucleated (original magnification ×4,500).

RESULTS
Psoriatic Lesion

The effects of PUVA therapy were evaluated in two separate categories: improvement of psoriasis-related abnormal parameters and toxic effects of PUVA or PUVA-induced side effects. The observations are summarized in the Table. In topically treated lesions, PUVA-related changes such as sunburn cells, melanocyte stimulation, vascular changes, and the like (see below), were more pronounced than in the lesions treated with systemic medication. Findings in oral and topical administration of 8-MOP were otherwise essentially the same. Therefore, the following description will apply to both.

Improvement of Psoriasis-Related Abnormalities.—*Thickness of the Epidermis.*—In all cases a substantial reduction of elongated rete ridges, both in length and width, was noted (Fig 2, top and bottom). Generally, the epidermis was reduced one third to one eighth of the original thickness (Fig 2; Table). Stratum corneum became orthokeratotic and thickened (Fig 2, bottom).

Mitosis.—Mitotic figures of keratinocytes were detected at various stages (prophase to telophase) before the treatment. These were seen not only in the basal layer of the epidermis but also within several layers above it. In many cells in the lower epidermis signs of hyperactive cells were seen: In the nuclei the rim of heterochromatin was diminished or clumped into nodules, while euchromatin and nucleoli were increased. Tonofibrils were thin and the cytoplasm appeared relatively clear (compare Fig 3; left with 3, right). Golgi apparatus was usually well developed. After PUVA treatment the mitotic figures were either completely absent or very seldom encountered (Table). The heterochromatin/euchromatin ratio increased and nucleoli decreased.

Widening of the Intercellular Spaces.—Interspaces between basal cells and a few cells above the basal layer were widely open and villous projections from the cell periphery were frequent before the treatment (Fig 4). In many places these villous projections perforated the basal lamina (Fig 4, inset), which was often multiplied (Fig 4). Migratory cells were often seen in widened intercellular spaces. In upper layers of the epidermis keratinocytes continued to have a small number of thin tonofibrils before the treatment (Fig 3, left) but the intercellular spaces were closed (Fig 3, left). The granular layer, containing small keratohyaline granules, was increased to form three to four cell layers (Fig 3, left). After PUVA therapy the interspaces of the lower epidermis became much narrower (Table) and an increased number of thicker tonofibrils were seen in the keratinocytes (Fig 3, right). The granular layer contained larger keratohyaline granules. It was reduced to one to two cell layers (Fig 3, right).

Lipid Granules.—Intracellular vacuoles were already present in the basal keratinocytes (Fig 4). These were increased in the middle to upper epidermis (Fig 3, left). In the horny cells most of the vacuoles contained medium-electron dense material compatible with lipids (Fig 3, left). After PUVA treatment these lipid vacuoles were appreciably decreased (Fig 3, right) (Table).

Parakeratosis.—Parakeratotic cells were abundant before the treatment. These cells contained not only nuclei but also cellular debris, either their own or phagocytosed, keratohyaline granules and undigested melanosome complexes. Obviously, these materials were produced or phagocytosed by keratinocytes in the lower layers and carried over to the horny layers. After the treatment these abnormal horny cells were very seldom found.

PUVA-Induced Changes.—*Sunburn Cell.*—Dyskeratotic cells with aggregated tonofibrils were occasionally seen in early stages of treatment (Fig 5, top). However, they were rarely observed after several months of continuous treatment. The occurrence

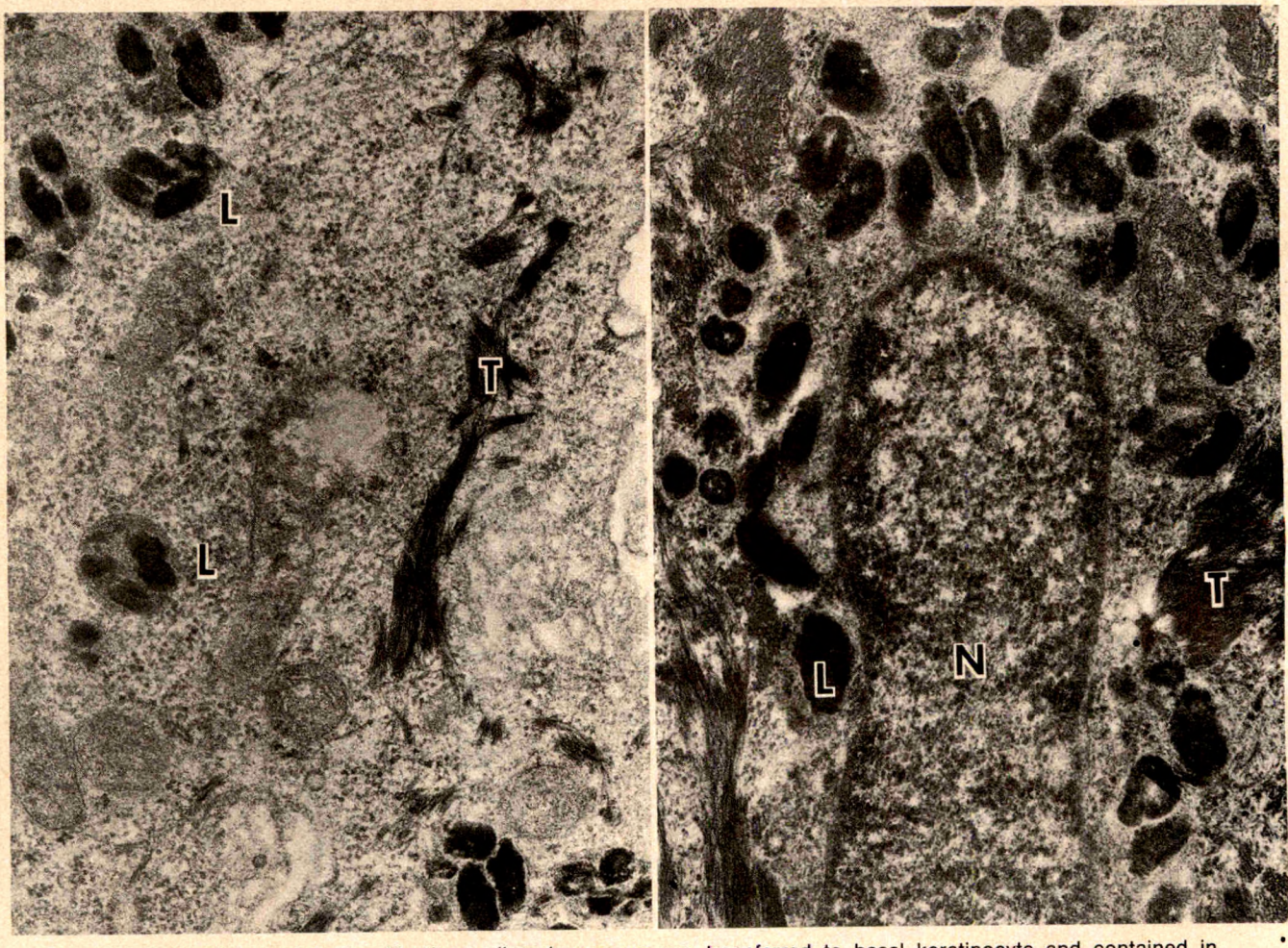

Fig 7.—Left, Untreated lesion. Mostly small melanosomes are transferred to basal keratinocyte and contained in aggregation in membrane-limited lysosomes (L). These melanosomes are randomly distributed in cytoplasm. Host keratinocyte has poorly developed thin bundles of tonofibrils (T) (original magnification ×75,000). Right, Treated lesion (22 treatments; 38.85 joules/sq cm). In contrast to untreated skin, larger melanosomes are transferred to basal keratinocyte and contained singly in lysosomes (L). These melanosomes are mainly distributed to form epinuclear cap. Tonofibrils (T) are numerous and form thick bundles. N indicates nucleus (original magnification ×75,000).

of sunburn cells was therefore not dose related (Table). It was often difficult to differentiate sunburn cells from degenerated cells, either keratinocytes (Fig 5, bottom left), Langerhans cells (Fig 5, right), or connective tissue cells (Fig 5, center left), which had migrated. Some degenerated melanocytes were phagocytosed by keratinocytes.

Melanogenesis.—The melanocyte activity was increased after PUVA therapy when estimated by criteria such as development of endoplasmic reticulum, extension of dendrites, and size of individual melanosomes. Quite often a cluster of two to three melanocytes in one area were observed and, occasionally, double-nucleated melanocytes were detected (Fig 6).

Transferred Melanosomes.—A greatly increased number of transferred melanosomes was seen in the keratinocytes after treatment. These melanosomes were larger in size than those seen in pretreatment specimens and often singly dispersed (Fig 7, left and right). In the pretreatment control a small number of small-sized melanosomes were seen in aggregated dispersion (Fig 7, left).

Basal Lamina Multiplication.—The basal lamina of the epidermis (Fig 4), and that of the perivascular spaces of the upper dermis, was multiplied in most of the psoriatic lesions. After PUVA therapy, this phenomenon was observed more frequently in the basal lamina of the epidermis, partially because of redundancy due to shrinkage of rete ridges.

Perivascular Amorphous Substance.—Perivascular spaces of small venules and lymphatic capillaries in the lesion were edematous and contained various amounts of loosely dispersed, medium-electron-dense amorphous substance. Fine filaments, small collagen fibrils, and other fibrous elements could admix with it. After the PUVA therapy the amorphous material was substantially increased around the dermal blood vessels (Fig 8), including lymphatic vessels in the upper dermis. Cross-banded filamentous aggregations,[16] commonly known as Zebra bodies or Luse bodies,[17] were occasionally seen in this amorphous substance (Fig 9).

Abnormalities of Connective Tissue Cells.—Mast cell degranulation, bizarre nuclei, cerebriform nuclei, pyknosis, mitotic cells (Fig 10, left), and multinucleated giant cells (Fig 10, right) were occasionally observed at early stages of PUVA therapy. An increased number of dermal Langerhans cells were seen at various stages of PUVA therapy.

Others.—*Lymphatic Capillaries.*—Although no systemic survey was carried out, lymphatic capillaries in the upper dermis seemed to be increased, dilated, and discontinuous in the lesion and also in the normal-

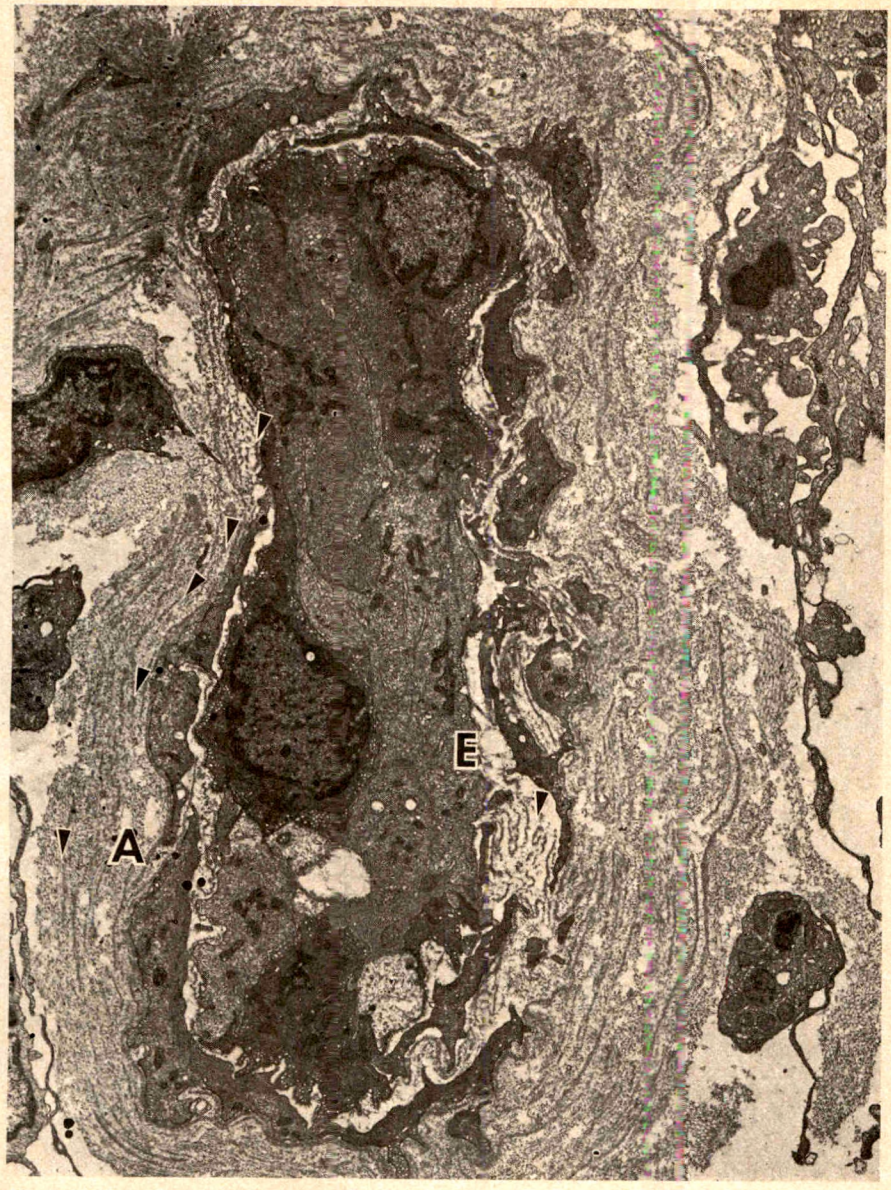

Fig 8.—Treated lesion (24 treatments; 45.9 joules/sq cm). Medium-sized venule is surrounded by thick, medium-dense layer of amorphous substance (A). Basal lamina multiplication is also seen (arrowheads). E indicates endothelial cell (original magnification ×10,000).

appearing skin. Even after PUVA therapy, this phenomenon remained and, on one occasion, mitosis of an endothelial cell of one of these increased lymphatics was observed.

Nerve Endings in the Epidermis.—In some cases an irradiated lesion that became tanned contained a number of nerve endings in the epidermis (Fig 11). A number of unmyelinated nerves were seen in the subepidermal region. This phenomenon was seen both in psoriatic lesions and in the normal skin after the PUVA therapy. In untreated control specimens the intraepidermal nerve endings were only rarely observed. The axon of these intraepidermal nerves was often in contact with the basal melanocytes and keratinocytes (Fig 11). The number of Merkel cells was not increased.

NORMAL SKIN

Normal skin of psoriatic patients did not show any substantial ultrastructural changes except occasional lipid granules in the hyperkeratotic epidermis and vascular changes such as multiple basal lamina and amorphous substance in the upper dermis. A mild degree of basal lamina multiplication was also observed. After PUVA therapy there was an increased activity of melanocytes and, as a consequence, an increase of melanosomes in keratinocytes, often as the single-dispersed type. Perivascular amorphous substance was increased and bizarre connective tissue cells were occasionally observed. Redundancy of the epidermal basal lamina was absent.

COMMENT

While the regimen of Parrish et al[8] and Wolff et al[9] is a high-intensity method that administers 2.4 to 4.8 joules/sq cm,[8] or 1.3 to 12 joules/sq cm[9] as an initial dose; ours is a medium-intensity method that only delivers 0.6 joules/sq cm as an initial dose. Nevertheless, the therapeutic results, ie, 80% remission, were comparable to their rate (76% to 85%).[8,9]

The therapeutic effects were usually obvious after the 17th treatment (27 joules/sq cm); this was verified by histologic examination. After long-term therapy the decrease of the epidermal thickness was dramatic; ie, reduced one third to one eighth depending upon the degree of initial hyperplasia.

Among PUVA-induced changes, the increased melanogenesis and change of melanosome pattern from aggregated to the large single form in the keratinocyte are clearly the result of this therapy. The same phenomena have been observed in caucasoid skin after exposure to various wavelengths of UVA with or without psoralen compound.[18-20] This is interesting because even caucasoid skin under stress can produce large melanosomes that disperse singly like those in nonirradiated dark skin of blacks.[21,22] Melanocytes in the epidermis are usually evenly distributed among the basal keratinocytes. Clustering of melanocytes in one area and the presence of double-nucleated melanocytes may indicate that melanocytes in the irradiated skin underwent proliferation and thus increased in number.

Intraepidermal nerve endings with or without accompanying Schwann cells and their contact with basal melanocytes have never been described in PUVA-treated skin. This finding makes one speculate that activation or regeneration of melanocytes is aided by some influence from these nerves. A similar invasion of nerve endings into the epidermis was found in halo nevus,[23,24] and other depigmenting conditions such as vitiligo, incontinentia pigmenti achromians, and Vogt-Koyanagi disease.[25] It was discussed whether this is related to the cause of the depigmentation or is an attempt at repigmentation.[23-25] In view of the PUVA-induced hyperac-

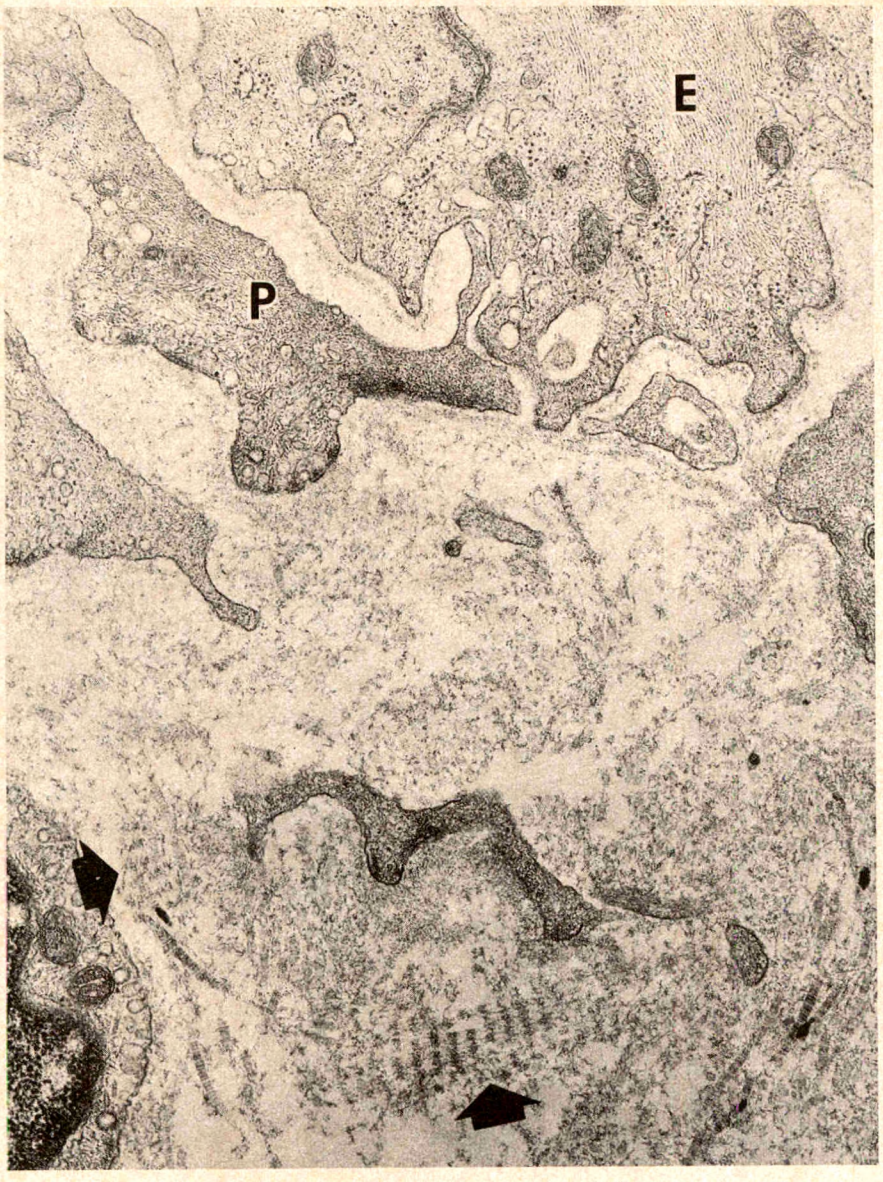

Fig 9.—Treated lesion (43 treatments; 129.15 joules/sq cm). Cross-banded filamentous aggregations (arrows) are seen in perivascular space. E indicates endothelial cells; P, pericyte (original magnification ×42,500).

tivity of the melanocyte, this phenomenon could be related to activation of melanocytes. It may be related to the regeneration of melanocytes because some melanocytes were observed to disintegrate after PUVA therapy. Normal skin does not have any nerve endings in the epidermis[25] except those associated with Merkel cells.[26,27] Psoriatic epidermis contains some, as reported previously by light microscopists,[28] but not in comparable frequency.

Other abnormalities such as multiplication of the basal lamina of both epidermis and perivascular spaces, increased perivascular amorphous substance, and abnormal connective tissue cells were believed to be related to the effect of PUVA treatment; however, these changes have already been seen, though to a lesser degree, in the lesion before treatment (Table). A separate series of experiments was therefore necessary to determine if UVA alone can induce these changes. A high dose of UVA was given repeatedly to the normal skin: Basal lamina multiplication could not be induced, whereas substantial amounts of amorphous substance and abnormalities in connective tissue cells were inducible.[29] In a chronic experiment the amorphous substance has apparently protected the vascular endothelial cells, which were severely damaged in the acute experiment.[29] The number of sunburn cells decreased as the epidermis adjusted to the chronic exposure to UVA. This is in contrast to the dose-related increase of sunburn cells in UVB-treated skin.[30]

After repeated exposure of the normal skin to a high dose of UVA, the epidermis became thickened (Table). In albino inbred mice exposed to a 40 W black light fluorescent lamp (98% UVA and 2% UVB) for 12 hours a day for up to a year, Zigman et al[31] demonstrated that squamous cell carcinoma and fibrosarcoma developed in the hairless ears and tail. It is therefore theoretically possible that tumors develop in the human skin after prolonged periodical, high-dose PUVA therapy. Because of the deep-penetrating power of UVA, connective tissue tumors are also expected to develop. In practice, however, no patient would receive a dose schedule similar to theirs; that is 30 to 34.5 joules/sq cm of UVA plus 0.8 to 1.2 joules/sq cm of UVB every day for more than one year. For example, our maximum dose is 4.45 joules/sq cm of UVA (98.9% of the total dose) and 0.05 joules/sq cm of UVB (1.9%) twice a week. If cumulative dose is important in carcinogenesis, it would take at least 25 years for our dose schedule to deliver an adequate tumorigenic UVA and 38 years if contaminating UVB is the responsible carcinogen. Also, albino mice probably do not develop protective hyperpigmentation as much as human white skin. On the other hand, unknown additive (?) effects of 8-MOP should not be neglected in PUVA therapy.

What did we learn from these studies and experiments for a better management of PUVA therapy? First, it is obvious that the human skin rapidly adapts to injurious UVA irradiation with hyperkeratosis, increase of thick tonofibrils, hypermelanization of the epidermis, and perivascular coating with amorphous substance.[29] Our data suggest that if a psoriatic patient is initiated with a low dose of 8-MOP and UVA and proceeds with a gradual increment of the dose his skin would have been well prepared for a larger dose, which is needed for a maximum result. In the situation where a method that could be potentially hazardous is used for benign skin diseases, one may question our conventional philosophy that skin lesions should be completely cleared for a dermatologist to declare his therapeutic success. In PUVA therapy for psoriasis, in which a potential hazard has not been entirely ruled out, one may consider other

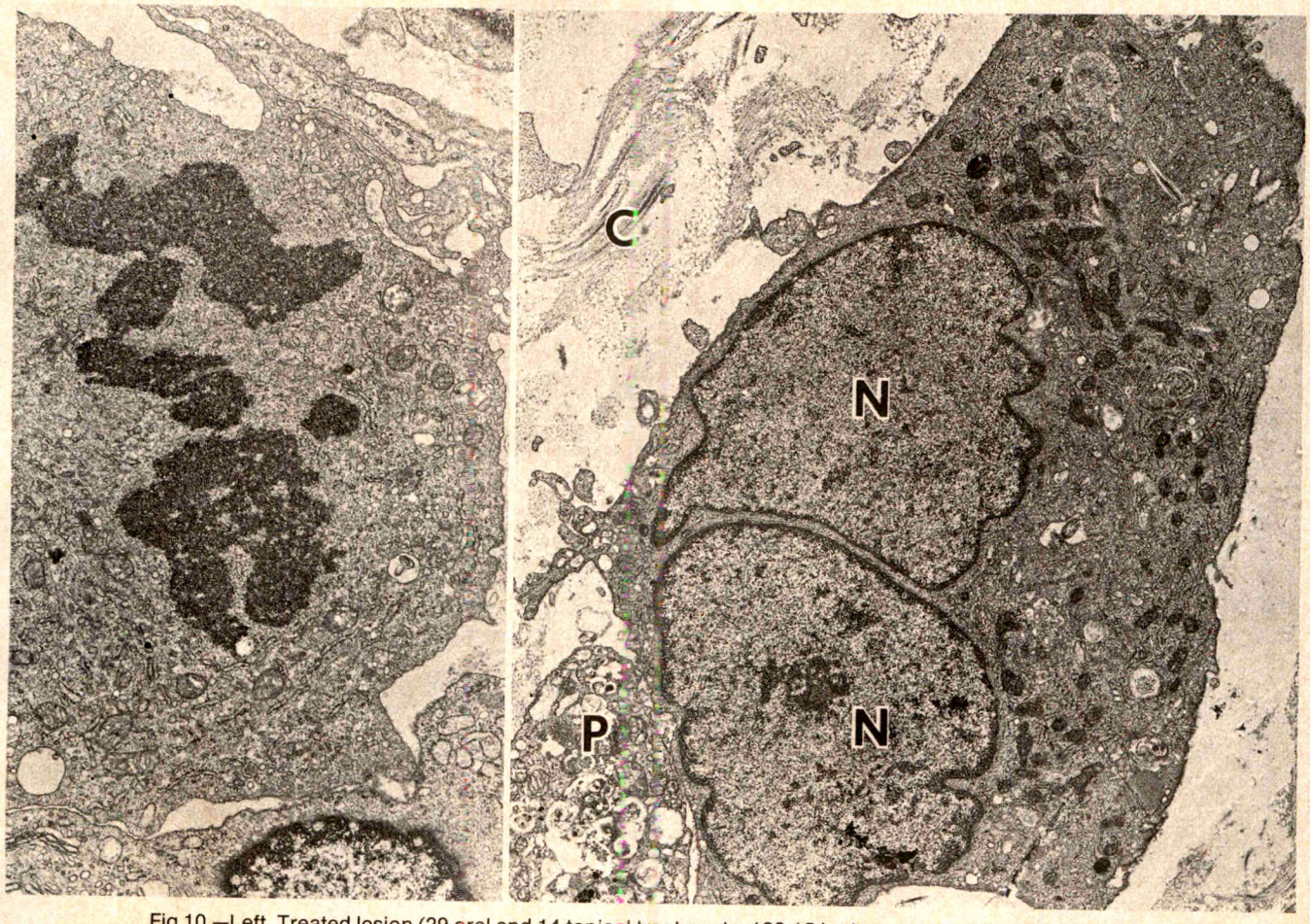

Fig 10.—Left, Treated lesion (29 oral and 14 topical treatments; 129.15 joules/sq cm). Mitotic histiocyte is found in upper dermis (original magnification ×20,000). Right, Treated lesion (five treatments; 3.15 joules/sq cm). Large, double-nucleated (N) cell is present in upper dermis of lesion at early stage of treatment. C indicates collagen; P, phagocyte (original magnification ×18,500).

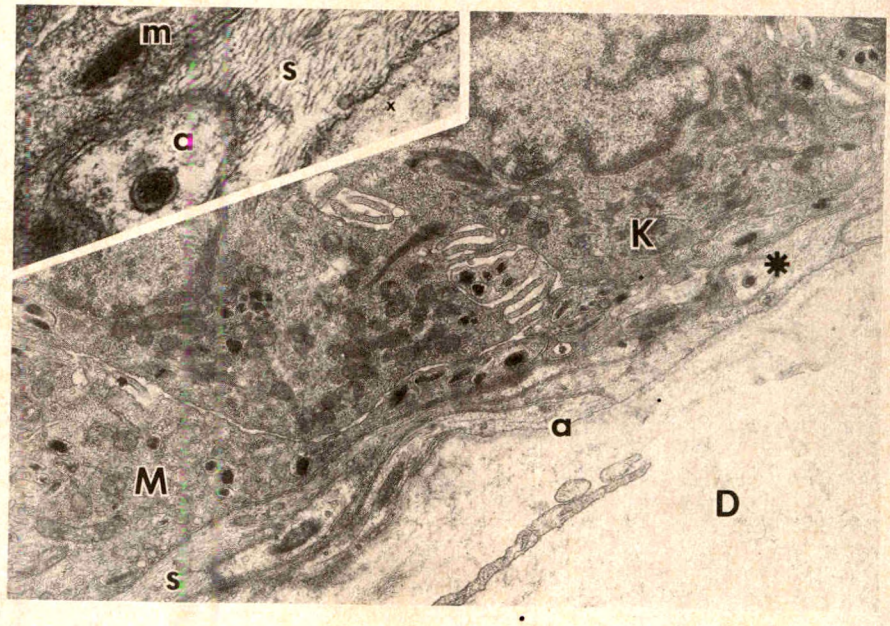

Fig 11.—Treated lesion (24 treatments; 45.9 joules/sq cm). Intraepidermal nerve ending consists of Schwann sheath (s) and unmyelinated axon (a). It is in contact with melanocyte (M) and keratinocyte (K). Area marked with asterisk is enlarged in insert where Schwann-ensheathed (s) axon (a) contains dense granule with halo. D indicates dermis; m, melanosome in basal cell; ×, basal lamina (original magnification ×18,000; Insert, ×60,000).

options such as minimum satisfactory level of therapeutic results, or alternating the regimen between PUVA and resting period maintained by non-PUVA modalities of treatment. Second, our data indicate that for the treatment of malignant conditions such as mycosis fungoides, where the lethal effect of PUVA to the target cells is desirable, an initial bombardment with a large dose may be necessary before the skin becomes less penetrable to UVA due to those protective adaptations. Third, when the psoriatic lesion becomes resistant to PUVA therapy, it is most likely that these protective adaptations are responsible; it would be wise to let the patient withdraw from the program temporarily until these adaptive changes subside, instead of increasing the doses of UVA and/or 8-MOP.

This investigation was supported in part by a medical investigatorship award, Veterans Administration Career Development Program and Component Projects Nos. 3499-01 and 3499-02, and grant CA 17555-02, National Cancer Institute.

Jerome Seyer, PhD, provided technical assistance in the measurement of wavelengths and intensity of the ultraviolet light used in this study.

References

1. El Mofty AM: Preliminary clinical report on treatment of leukodermia with *Ammi majus* Linn. *J R Egypt Med Assoc* 31:651-665, 1948.

2. Pathak MA, Epstein JH: Normal and abnormal reactions of man to light, in Fitzpatrick TB, Arndt KA, Clark WH, et al (eds): *Dermatology In General Medicine*. New York, McGraw-Hill Book Co Inc, 1971, pp 977-1036.

3. Musajo L, Bordin F, Caporale G, et al: Photoreactions at 3655 Angstrom between pyrimidine bases and skin photosensitizing furocoumarins. *Photochem Photobiol* 6:711-719, 1967.

4. Pathak MA, Kramer DM: Photosensitization of skin in vivo by furocourmarins (psoralens). *Biochim Biophys Acta* 195:197-206, 1969.

5. Cole RS: Light-induced cross linking of DNA in the presence of a furocoumarin (psoralen): Studies with phage lambda, *Escherichia coli*, and mouse leukemia cells. *Biochim Biophys Acta* 217:30-39, 1970.

6. Walter JF, Voorhees JJ: Psoriasis improved by psoralen plus black light. *Acta Dermatovener (Stockh)* 53:469-472, 1973.

7. Weber G: Combined 8-methoxypsoralen and black light therapy of psoriasis: Technique and results. *Br J Dermatol* 90:317-323, 1974.

8. Parrish JA, Fitzpatrick TB, Tanenbaum L, et al: Photochemotherapy of psoriasis with oral methoxsalen and longwave ultraviolet light. *N Engl J Med* 291:1207-1211, 1974.

9. Wolff K, Fitzpatrick TB, Parrish JA, et al: Photochemotherapy for psoriasis with orally administered methoxsalen. *Arch Dermatol* 112:943-950, 1976.

10. Gilchrest BA, Parrish JA, Tanenbaum L, et al: Oral methoxsalen photochemotherapy of mycosis fungoides. *Cancer* 38:683-689, 1976.

11. Morison WL: Oral psoralen photochemotherapy of atopic eczema. Read before the 35th annual meeting of the American Academy of Dermatology, Chicago, December 1976.

12. Parrish JA, Fitzpatrick TB, Shea C, et al: Photochemotherapy of vitiligo: Use of orally administered psoralens and a high-intensity long-wave ultraviolet light system. *Arch Dermatol* 112:1531-1534, 1976.

13. Hashimoto K, Lieberman P, Lamkin N Jr: Angiokeratoma corporis diffusum: A lysosomal disease. *Arch Dermatol* 112:1416-1423, 1976.

14. Ying CY, Parrish JA, Pathak MA: Additive erythemogenic effects of middle-(280-320 nm) and long-(320-400 nm) wave ultraviolet light. *J Invest Dermatol* 63:273-278, 1974.

15. Everett MA, Olson RL: Physiological response of human skin to ultraviolet light, in Jadassohn W, Schirren CG (eds): *XIII Congressus Internationalis Dermatologiae*. New York, Springer-Verlag, 1968, pp 988-995.

16. Hashimoto K, Ohyama H: Cross-banded filamentous aggregation in the human dermis. *J Invest Dermatol* 62:106-112, 1974.

17. Hashimoto K, Ohyama H: Cross-banded filamentous aggregation in the human dermis. *J Invest Dermatol* 62:106-112, 1974.

18. Jimbow K, Pathak MA, Szabo G, et al: Ultrastructural changes in human melanocytes after ultraviolet radiation, in Pathak MA, Harber LC, Seiji M, et al (eds): *Sunlight and Man, Normal and Abnormal Photobiologic Responses*. Tokyo, University of Tokyo Press, 1974, pp 195-215.

19. Pathak MA, Kramer DM, Fitzpatrick TB: Photobiology and photochemistry of furocoumarins (psoralens), in Pathak MA, Harber LC, Seiji M, et al (eds): *Sunlight and Man, Normal and Abnormal Photobiologic Responses*. Tokyo, University of Tokyo Press, 1974, pp 335-368.

20. Toda K, Nakayama Y, Morikawa F: Electron microscopic observations in human skin after psoralen photosensitization, in Pathak MA, Harber LC, Seiji M, et al (eds): *Sunlight and Man, Normal and Abnormal Photobiologic Responses*. Tokyo, University of Tokyo Press, 1974, pp 419-430.

21. Olson RL, Nordquist J, Everlett MA: The role of epidermal lysosomes in melanin physiology. *Br J Dermatol* 83:189-199, 1970.

22. Olson RL, Gaylor J, Everett MA: Skin color, melanin and erythema. *Arch Dermatol* 108:541-544, 1973.

23. Hashimoto K: Ultrastructural studies of halo nevus. *Cancer* 34:1653-1666, 1974.

24. Hashimoto K: A case of halo nevus with effete melanocytes. *Acta Dermatovener (Stockh)* 55:87-95, 1975.

25. Morohashi M, Hashimoto K, Goodman T Jr, et al: Ultrastructural studies of vitiligo, Vogt-Koyanagi syndrome and incontinentia pigmenti achromians. *Arch Dermatol* 113:755-766, 1977.

26. Hashimoti K: The ultrastructure of the skin of human embryos: X. Merkel tactile cells in the finger and nail. *J Anat* 111:99-120, 1972.

27. Hashimoto K: Fine structure of Merkel cell in human oral mucosa. *J Invest Dermatol* 58:381-387, 1972.

28. Weddell G, Cowan MA, Palmer E, et al: Psoriatic skin. *Arch Dermatol* 91:252-266, 1965.

29. Kumakiri M, Hashimoto K, Willis I: Biological changes due to long-wave ultraviolet irradiation on human skin: Ultrastructural study. *J Invest Dermatol* 69:392-400, 1977.

30. Olson RL, Gaylor J, Everett MA: Ultraviolet-induced individual cell keratinization. *J Cutaneous Pathol* 1:120-125, 1974.

31. Zigman SK, Fowler E, Kraus AL: Black light induction of skin tumors in mice. *J Invest Dermatol* 67:723-725, 1976.

Intravascular Papillary Endothelial Hyperplasia

A Benign Lesion Mimicking Angiosarcoma

Ronald J. Barr, MD; James H. Graham, MD; Lawrence A. Sherwin, MD

• Observations were made of three cases of intravascular papillary endothelial hyperplasia (IPEH). Lesions of IPEH usually occur on the head and neck area as a subcutaneous red or blue nodule. This papillary proliferation of endothelial and stromal tissue occurs de novo in organizing venous thrombi or in preexisting hemangiomas or phlebectasias. An adequate understanding of this benign vascular disorder is important, since the lesion may be clinically and histologically mistaken for low grade angiosarcoma.

(*Arch Dermatol* 114:723-726, 1978)

Varying degrees of atypical endothelial proliferation may frequently occur in vascular thrombi, whereas florid forms simulating angiosarcoma are unusual. In 1923, Pierre Masson[1] described exuberant papillary and endothelial proliferation in hemorrhoidal tissue and designated this type of hyperplasia as "hémangioendothéliome végétant intravasculaire." Masson considered that the disorder resulted from a benign proliferation of endothelial cells with secondary thrombosis and fibrin deposition. Although occasionally referred to in the literature,[2,3] there has been little written on this subject until recently. The recently written material probably does not reflect an increase in incidence of the lesion, but simply an emphasis on recognition of "pseudomalignant" disorders.

In the past, several names have been given to this cutaneous blood vessel lesion including Masson's pseudoangiosarcoma,[4] intravenous atypical vascular proliferation,[5] and intravascular papillary endothelial hyperplasia.[6] Although there is some disagreement among pathologists, we consider these entities to be identical and prefer to use the latter descriptive name, intravascular papillary endothelial hyperplasia (IPEH). Three additional cases of IPEH are presented herein; we believe that it is important that the dermatologist, the dermatopathologist, and the pathologist recognize this benign disorder and differentiate it from angiosarcoma.

REPORT OF CASES

Case 1.—The patient, a 26-year-old man, had a 1-cm, violaceous, firm, asymptomatic nodule on this right lower lip for three months (Fig 1). There was no previous history of bleeding or trauma. The lesion appeared well-circumscribed, and it "shelled-out" easily with blunt dissection under local anesthesia. There was no evidence of recurrence at four months after excision.

Case 2.—The patient, a 46-year-old man, had had a 5 × 6-mm, purple, soft and elevated papule on the left lower lip for three years. The lesion partially blanched on diascopy. The clinical impression was of phlebectasia (venous lake), and a 3-mm, well-demarcated, red-brown nodule was removed for histopathological study. There was no evidence of recurrence two months after excision.

Case 3.—The patient, a 67-year-old woman, had had a 2 × 2-cm nodule on the volar surface of her right middle finger that began shortly after a pinching injury two years previously. The overlying skin was intact and slightly violaceous. The clinical impression was of a tendon cyst. The lesion was excised under local anesthesia and bled profusely during the procedure. The lesion showed gross evidence of blood vessels. Three months after excision, there was no evidence of recurrence.

MATERIALS AND METHODS

Tissue from the lesions was fixed in 10% neutral, buffered formaldehyde solution, was grossed, processed routinely, and embedded in paraffin; sections were cut for staining with hematoxylin-eosin (H&E). Special procedures that were performed in case 1 included a Wilder's reticulum stain.

MICROSCOPICAL OBSERVATIONS

In case 1, H&E-stained sections showed that the lesion appeared partially surrounded by a fibromuscular structure that was consistent

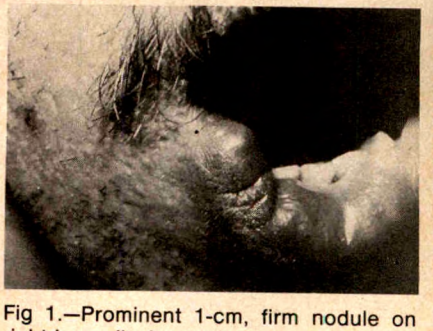

Fig 1.—Prominent 1-cm, firm nodule on right lower lip (case 1).

Accepted for publication Sept 6, 1977.

From the Division of Dermatology, Section of Dermal Pathology and Histochemistry, California College of Medicine, University of California, Irvine, and the Dermatology Section, Veterans Administration Hospital, Long Beach, Calif.

Reprint requests to Section of Dermal Pathology and Histochemistry, University of California Irvine Medical Center, 101 City Dr S, Orange, CA 92668 (Dr Barr).



Fig 2.—Lobules of papillary proliferation within thin-walled blood vessel characteristic of intravascular papillary endothelial hyperplasia (case 1) (hematoxylin-eosin, original magnification ×40).

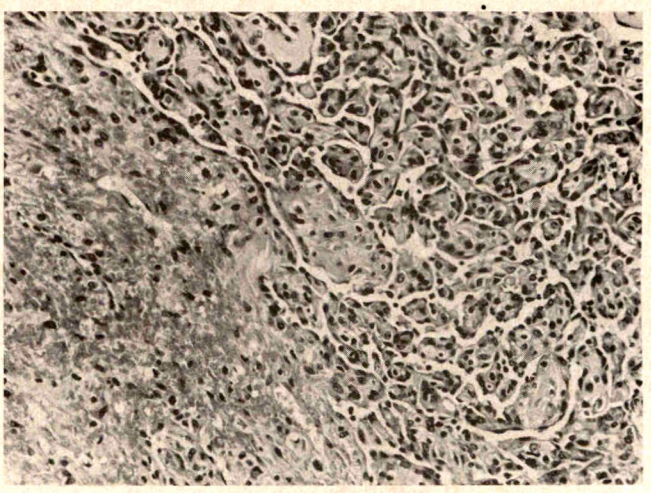

Fig 3.—Hyalinized papillary stalks covered with a single layer of hyperchromatic endothelial cells. Note transition from organization thrombus in left portion of field (case 1) (hematoxylin-eosin, original magnification ×200).

Fig 4.—Papillary proliferation as well as endothelial cells entrapped in fibrohyalinized connective tissue. Structure above is wall of ectatic vein (case 1) (hematoxylin-eosin, ×100).

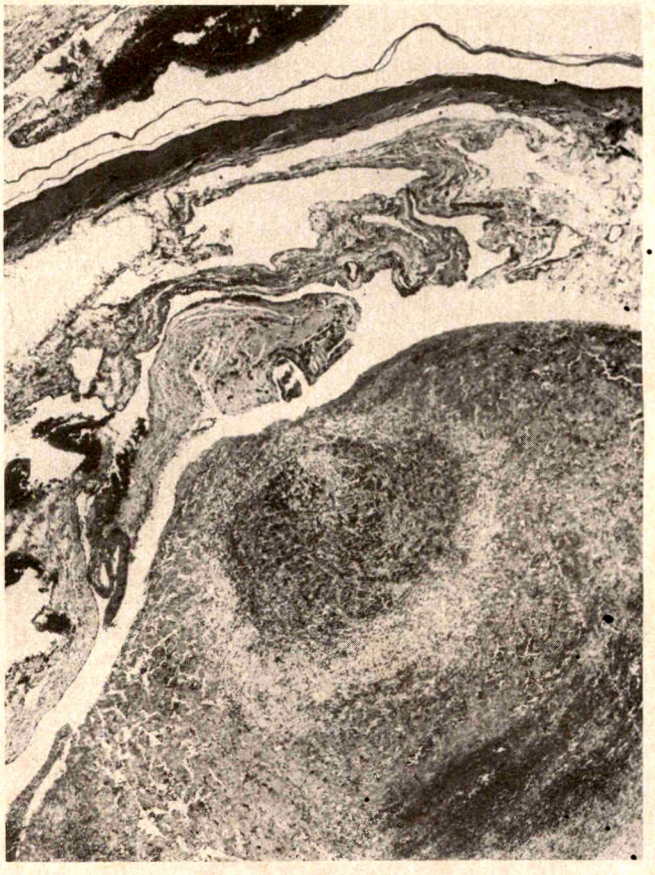

Fig 5.—Stratified squamous mucosa of lip exhibiting focal hyperkeratosis. Large thrombus shows eccentric nodule of organization with surrounding papillary proliferation. Adjacent ectatic vessels are consistent with phlebectasia (case 2) (hematoxylin-eosin, original magnification ×40).



Fig 6.—Three relatively distinct zones from periphery to center: (A) fresh thrombus (B) organizing thrombus, and (C) florid papillary endothelial proliferation. Tangential sectioning creates illusion of irregularly shaped vascular channels (case 3) (hematoxylin-eosin, original magnification ×100).

with an ectatic vein. Within the lumen were several lobules composed of proliferating endothelial cells that covered hyalinized fibrous stroma (Fig 2). The endothelial cells were hyperchromatic and contained rare mitotic figures, but there was overall uniformity of nuclear size and shape. In most areas only a single layer or, at the most, two layers of endothelial cells covered the hyalinized papillary stalks (Fig 3). True papillary fronds of endothelial cells that were devoid of connective tissue stalks were absent. In some areas, the proliferating endothelial cells seemed to be present within large trabeculae of hyalinized connective tissue (Fig 4). Several foci of fresh and organizing thrombi were evident, and these exhibited transitions of forming papillary components (Fig 3). Although some irregular, anastomosing blood-filled vessels were within the proliferating stroma, examination of multiple sections supported the opinion that this feature resulted from tangential cuts of the endothelial-covered papillary tumor lobules, and that therefore, these were not true vascular channels. The reticulum stain showed that the proliferation of endothelial cells was devoid of reticulin fibers.

In cases 2 and 3, the features were identical to those in case 1, although only a small portion of a larger organizing thrombus showed the unusual papillary pattern. In case 2, some sections showed features of ectatic vein that were consistent with the diagnosis of a preexisting phlebectasia (Fig 5). In case 3, three definite zones were identified in the vascular thrombus. In sequence, from periphery to center, there was fresh thrombus formation, typical organizing changes, and endothelial proliferation covering stromal stalks (Fig 6). Several fragments of the blood vessel wall were present that showed elastic lamina compatible with a medium-sized vein.

COMMENT

Occurrence and Nomenclature

In 1974, Rosai and Akerman[5] described three cases of intravenous atypical vascular proliferation. These lesions arose on the head, and in one case, on the lip. The authors considered the lesions to be benign endothelial proliferation that occurred within medium-sized veins. Although the suggestion had been made that the endothelial proliferation might have arisen from a thrombus, Rosai and Akerman believed this lesion to be a variant of angiolymphoid hyperplasia with eosinophilia (Kimura's disease).

In 1976, Kuo et al[4] published an account of 17 cases of a subcutaneous-vascular lesions, which they called "Masson's pseudoangiosarcoma." Five of the tumors arose in preexisting benign vascular lesions, and the other twelve lesions occurred de novo in blood vessels. Ten of the seventeen cases involved the head and neck region; three of these lesions were located on the lip. No age predilection was found, and the female to male ratio was 11:6. The authors pointed out that they considered Masson's pseudoangiosarcoma to be different from intravenous atypical vascular proliferation primarily because the hyperplasia in the latter: (1) was solid instead of papillary; (2) occasionally extended into the vascular wall or beyond; and (3) consisted, in part, of endothelial cells with a histiocytic or an epithelioid appearance. Masson's pseudoangiosarcoma seemed to be associated with thrombus material, and Kuo et al felt that the papillary endothelial proliferation preceded thrombosis, thus supporting Masson's original contention.

Clearkin and Enzinger[6] reported 44 cases of IPEH. Ten lesions in these cases arose in the head and neck region, 14 lesions were on the finger, and seven lesions were on the trunk. There was no age predilection in this series, but there was a slight predominance of cases in female patients. The description of the lesion by these investigators is identical to Masson's pseudoangiosarcoma.

Based on the previous reported observations and case material, we feel that our three cases fit the description of IPEH. We prefer the latter descriptive title because it avoids the use of pseudoangiosarcoma, which may be a source of confusion. Whether IPEH is the same as intravenous atypical vascular proliferation has been disputed. Kuo et al[4] feel that these two disorders are different. We tend to agree with Salyer and Salyer,[7,8] who studied intravenous angiomatosis in 244 thrombi and thromboembolic and felt that the histological changes of intravenous atypical vascular proliferation, as described by Rosai and Akerman,[3] were within the spectrum of IPEH.

We concur with the opinions of Clearkin and Enzinger[6] and Salyer and Salyer[7,8] that IPEH probably results from the organization of a thrombus. Our data for cases 2 and 3, as well as the transitional foci in case 1, support this view. This peculiar organization apparently may occur in preexisting vascular lesions, such as hemangioma, granuloma pyogenicum, and phlebectasia, or de novo in blood vessels, most frequently a vein. Why this florid type of endothelial proliferation occurs so rarely is not known, but certainly this proliferation is not

unusual as a focal microscopical change in many thrombi.

Distinction From Angiosarcoma

The origin of IPEH remains speculative, but the importance of reporting the entity lies in calling attention to its histological distinction from angiosarcoma. Both lesions may exhibit plump endothelial cells, papillary configuration, thrombus formation, and irregular blood-filled spaces. There are, however, several important distinguishing characteristics of IPEH: (1) grossly, the lesion frequently is well-circumscribed or encapsulated; (2) the proliferative process is entirely confined to intravascular spaces, although serial sections may be necessary to confirm this observation; (3) the endothelial cells may be hyperchromatic, but extreme nuclear atypia and frequent mitotic figures are absent; (4) the papillae consist of fibrohyalinized tissue that is covered by no more than two endothelial cell layers; (5) there are no true endothelial fronds; (6) irregular and anastomosing blood vessels are absent in the stroma, although pseudochannels may be present owing to tangential sectioning; and (7) necrosis is unusual.

Two other lesions that may be confused with IPEH are rare variants of angiosarcomas. The first variant is malignant endovascular papillary angioendothelioma, which occurs primarily in infancy although a few cases have been described in adults.[9] This lesion most frequently occurs in the skin and in subcutaneous fat tissue, and is characterized by extensive replacement of the dermis and subcutaneous tissue by communicating vascular channels that are filled with papillary fronds of atypical endothelial cells. Ths lesion may metastasize and usually first involves the lymph nodes.

The second variant of angiosarcoma is intravascular endothelioma, which occurs in adults as multiple, violaceous macules that rapidly develop into plaques and nodules.[10,11] This malignant vascular lesion is characterized by diffuse proliferation of endothelial cells and usually has a progressive downhill course.

IPEH As Benign Lesion

Despite insufficient time for follow-up on our three cases, IPEH seems most certainly to be a benign lesion. Available follow-up data from Kuo et al[4] showed no evidence of metastases and one recurrence that arose in a lesion of IPEH in a preexisting granuloma pyogenicum. Therefore, IPEH may recur if it arises in a primary vascular lesion that by itself is known to regrow if inadequately excised.

In conclusion, IPEH represents a benign proliferating process that results from a peculiar organization of a thrombus. Although this lesion may be confused with angiosarcoma, there are important differences that allow distinction. Because IPEH occurs in the cutis or subcutis, the dermatologist and dermatopathologist should learn to recognize the entity.

James V. O'Connell, MD, referred case 2 to us, and William J. Resnick, MD, referred case 3.

References

1. Masson P: Hémangioendothéliome végétant intravasculairé. *Bull Soc Anat* 93:517-523, 1923.
2. Stout AP, Lattes T: *Tumors of the Soft Tissues*. Atlas of Tumor Pathology, Washington, DC, Armed Forces Institute of Pathology, 1967, series 2, pp 145-149.
3. Kauffman SL, Stout AP: Malignant hemangioendothelioma in infants and children. *Cancer* 14:1186-1196, 1961.
4. Kuo T, Sayer CP, Rosai J: Masson's "vegetant intravascular hemangioendothelioma": A lesion often mistaken for angiosarcoma: Study of seventeen cases located in the skin and soft tissues. *Cancer* 38:1227-1236, 1976.
5. Rosai J, Akerman LR: Intravenous atypical vascular proliferation: A cutaneous lesion stimulating a malignant blood vessel tumor. *Arch Dermatol* 109:714-717, 1974.
6. Clearkin KP, Enzinger FM: Intravascular papillary endothelial hyperplasia. *Arch Pathol Lab Med* 100:441-444, 1976.
7. Salyer WR, Salyer DC: Intravascular angiomatosis: Development and distinction from angiosarcoma. *Cancer* 36:995-1001, 1975.
8. Salyer WR, Salyer DC: Intravenous angiomatosis in cutaneous vessels. *Arch Dermatol* 110:811-812, 1974.
9. de Dulanto F, Armijo-Moreno J: Malignant endovascular papillary hemangioendothelioma of the skin. *Acta Derm Venereol* 53:402-408, 1973.
10. Johnson WC: Pathology of cutaneous vascular tumors. *Int J Dermatol* 15:239-270, 1976.
11. Haber H, Harris-Jones J, Wells A: Intravascular endothelioma (endothelioma in situ, systemic endotheliomatosis). *J Clin Pathol* 17:608-611, 1964.

New Requirement for Authors

Congress recently passed *The Copyright Revision Act of 1976*, effective Jan 1, 1978, which affects the American Medical Association's procedure for reviewing manuscripts submitted for publication.

In view of this law, all transmittal letters accompanying manuscripts submitted for publication should contain the following language: "In consideration of the AMA taking action in reviewing and editing my submission, the author(s) undersigned hereby transfers, assigns, or otherwise conveys all copyright ownership to the AMA in the event that such work is published by the AMA."

Variably Occlusive Tape Systems and the Mitotic Activity of Stripped Human Epidermis

Effects With and Without Hydrocortisone

Louis B. Fisher, PhD; Howard I. Maibach, MD; Ronald J. Trancik, PhD

• This study elaborates on the effect of occlusive, partially occlusive, and nonocclusive tape systems containing hydrocortisone on human epidermal mitotic activity that has been increased by tape stripping. The experimental variables included tape delivery systems affording total, partial (50%), or no occlusion to normal human skin. The test corticosteroid was hydrocortisone at a dose range of 1, 4, and 20 μg/sq cm. Utilizing demecolcine cream, biopsy specimens, were taken and mitotic figures determined. Results suggest that potent antimitotic effects occur equally with semiocclusive and nonocclusive tapes containing hydrocortisone as with total occlusive tapes. Verification of the practicality of this in clinical use will depend on appropriate clinical trials in diseased states.

(*Arch Dermatol* 114:727-729, 1978)

We previously described the effect of corticosteroids on normal and stripped skin with occlusive dressings.[1,2] We recently showed that potent antimitotic effects were observed on normal human skin with hydrocortisone when delivered from nonocclusive, partially occlusive, and semiocclusive tape systems.[3] This report extends these observations by comparing the effect of occlusive, partially occlusive, and nonocclusive tape systems on epidermal mitotic activity of hydrocortisone and nonmedicated tapes on stripped skin.

MATERIALS AND METHODS

The method used for the assay of mitosis has been published.[4] Groups of five healthy adult male volunteers were studied. Several treatments were used simultaneously on each subject and cumulative results are presented in the tables. This technique

Accepted for publication Dec 16, 1977.

From the Division of Dermatology, Scripps Clinic and Research Foundation, La Jolla, Calif (Dr Fisher); the Department of Dermatology, University of California, San Francisco Medical Center (Dr Maibach); and Dermatologicals Project, Riker Laboratories, Inc, 3M Co, St Paul (Dr Trancik).

Reprint requests to Department of Dermatology, University of California, San Francisco Medical Center, San Francisco, CA 94143 (Dr Maibach).

Table 1.—Effect of Nonmedicated Tapes on Mitotic Activity of Stripped Human Skin

Treatment	No.*	Mean Mitotic Index ± SD	% Inhibition	P Value†
Stripped skin control	15	3.95 ± 3.42	...	...
Occlusive tape	15	1.67 ± 1.28	58	<.001
Partially (50%) occlusive tape	15	1.67 ± 0.85	58	<.001
Nonocclusive tape	15	1.73 ± 1.12	56	<.001

*Number of subjects used to determine mitotic index with 12 separate determinations for each subject.
†P values determined in comparison with stripped skin control.

Table 2.—Effect of Variably Occlusive Hydrocortisone Tapes on Mitotic Activity of Stripped Human Skin Compared to Nonmedicated Tape Controls

Treatment	Concentration, μg/sq cm	No.*	Mean Mitotic Index ± SD	% Inhibition	P Value†
Occlusive tapes	...	15	1.67 ± 1.28	...	...
	1	4	2.54 ± 0.88	52‡	<.02
	4	5	1.55 ± 0.20	7	NS
	20	5	0.24 ± 0.24	86	<.001
Partially occlusive tapes	...	15	1.67 ± 0.85	...	...
	1	5	2.03 ± 0.69	22‡	NS
	4	5	1.64 ± 0.44	2	NS
	20	5	0.07 ± 0.08	96	<.001
Nonocclusive tapes	...	15	1.73 ± 1.12	...	...
	1	5	2.82 ± 1.06	63‡	<.001
	4	5	1.82 ± 0.69	5‡	NS
	20	5	0.05 ± 0.05	97	<.001

*Number of subjects used to determine mitotic index with 12 separate determinations for each subject.
†P values determined in comparison with nonmedicated tape controls.
‡Enhanced mitotic activity.

enabled each subject to act as his own control. The drug examined was hydrocortisone. Stripping was accomplished with cellophane tape. The tape was placed on the skin and smoothed with mild digital pressure. This was repeated 10 to 25 times, until the presence of glistening was observed.

Treatments were applied to the upper part of the back daily in the morning for four days. On the morning of the final day the materials were removed and 0.5% demecolcine (Colcemid) in hydrophilic ointment was applied under an occlusive patch. Six hours later biopsy specimens were taken with a 3-mm punch and fixed in Davidson's fixative (30 ml of 95% ethyl alcohol, 20 ml of formaldehyde solution, 10 ml of glacial acetic acid, and 30 ml of distilled water).

Biopsy specimens were dehydrated, embedded, cut at 7 μ, and stained with the Feulgen reaction for DNA. Twelve sections cut from each specimen were scanned for mitoses as previously described.[4] The counts were expressed as the number of mitoses per 1,000 viable cells (mitotic rate). All cells below the granular layer were included in the scan since mitoses frequently appear to occur suprabasally.[4] The use of demecolcine blocked the cells in metaphase, increasing the counts and enhancing the ease and reliability of the procedure. The results were statistically analyzed, using Student's t test.

Hydrocortisone was formulated into tape delivery systems by the following procedure. The drug was solubilized in acetone, which is compatible with the acrylate adhesive. This solution was mixed into the adhesive dispersion and coated on a silicone-release paper (liner), using a knife-edge hand spreader. The desired backing (polyethylene, nonwoven rayon, or microporous film) was laminated to the adhesive/liner, affording a drug-in-tape system of desired occlusivity. The concentration of the drug per unit of tape was regulated by the coated thickness of the adhesive and the weight percentage of drug in the dry adhesive. Hydrocortisone in tape was assayed by extracting drug with methanol, followed by dinitrophenylhydrazine colorimetric analysis of the extracts.[5]

Three tape systems of different occlusivities were employed. The occlusive tape used a polyethylene backing impervious to moisture vapor transmission. The nonocclusive tape had a porous, nonwoven rayon backing, allowing moisture vapor transmission. A microporous film tape afforded approximately 50% occlusion by utilizing an ethylene-vinyl acetate (90:10) film backing rendered microporous by the leachable filler technique, using sodium chloride of 2- to 3-μ particle size.[6] Depending on the amount of sodium chloride and its particle size, the occlusivity of the tape system can be controlled by regulating the porosity of the backing. The degree of occlusivity was determined by measuring the transepidermal water loss (TEWL) of a given skin site and using the equation

$$\% \text{ tape occlusivity} = \frac{\text{TEWL skin} - \text{TEWL skin with tape}}{\text{TEWL skin}} \times 100$$

where TEWL is expressed in micrograms per minute per square centimeter. Thus, the TEWL from any skin site would be entirely transmitted through a tape with 0% occlusivity. An automatic electrolytic moisture analyzer was employed for this. Experimental details of skin TEWL measurements have been described.[7,8]

RESULTS

Appropriate data on stripped skin are presented in Table 1. The stripped skin controls have a mitotic rate of 3.95 ± 3.42, which serves as the baseline. Occlusive tape, partially occlusive tape, and nonocclusive tape decreased mitotic activity by approximately 56% to 58% when compared to the stripped skin control.

Data on the effect of hydrocortisone in the three tape systems when compared to the nonmedicated tape controls are presented in Table 2. With the occlusive tapes, there seemed to be a dose relationship, with 1 μg/sq cm of hydrocortisone producing a significant stimulation, 4 μg/sq cm apparently having no effect, and 20 μg/sq cm producing a significant inhibition. Similar results were observed with partially occlusive and nonocclusive tapes.

COMMENT

The results with hydrocortisone resemble those reported previously with total occlusion on normal skin.[3] The additional information presented here is the dose-response relationships of hydrocortisone tapes and the effect of various degrees of occlusion on stripped human skin.

The baseline data on stripped skin are reasonably consistent with those of previous publications.[1,2,9] We had demonstrated that a nonocclusive tape would produce a significant decrease in mitotic inhibition without the addition of any drug.[1-3] These data suggest that whatever the properties of tape that produce this mitotic inhibition, occlusion is not required, ie, equal decreases in mitotic activity of stripped skin were noted with a completely occlusive, 50% occlusive, or nonocclusive tape system. The present study does not define whether these effects were due to specific ingredients or the tape system as a whole.

A somewhat surprising result was the apparently consistent stimulation shown by 1 μg/sq cm incorporated into all tape systems. In all instances this was a stimulation relative to the tape-

covered control sites but nowhere was this sufficient to return the mitotic indices to the value seen on the uncovered, stripped skin controls. Although inhibition of cellular proliferation is the usually recorded response to steroids, stimulation has been noted in vitro.[10] Stimulation by hydrocortisone seemed to be restricted to human diploid lines, and although the response was most consistent with fetal and neonatal lung and foreskin cells, a similar result was demonstrated with adult skin fibroblasts. It might be interesting to speculate as to the similarity of the response by wounded epidermis and cultured human cells to hydrocortisone. It also could be that small amounts of hydrocortisone are influencing inflammation without influencing mitosis and it might be that the tape is producing a very mild inflammatory response that might in some way decrease mitosis.

The same dose-response relationship was noted with 1, 4, and 20 μg/sq cm of hydrocortisone for all three tape systems—occlusive, partially occlusive, and nonocclusive. Surprisingly, there was no significant difference in the degree of mitotic inhibition observed among the three systems. In other words, the totally occlusive tape did not have a more potent effect than the nonocclusive tape. Even this straightforward experiment has many complexities of interpretation. For instance, how much inhibition is due to the tape itself, how much is due to the corticosteroid, and what is the relationship between the two? From previous data, we demonstrated that the nonocclusive tape system does have an antimitotic effect. Is the decrease in mitotic activity that we see here related to an additive effect with that of the corticosteroid? It is noteworthy that 20 μg of hydrocortisone in tape does not appear to induce tachyphylaxis after three daily applications.[11]

We do not know the effect of these three systems on the percutaneous penetration of hydrocortisone. It is ordinarily assumed, but not documented, that one needs total occlusion to enhance percutaneous penetration—the basis of the plastic occlusive dressings used in clinical dermatology. Would similar results be obtained with less occlusive systems that might be more comfortable to the patient? If the above data are clinically relevant, this may well be the case. To bring this to clinical fruition two further steps are needed. The most direct would be clinical trials of nonocclusive dressings and corticosteroids in diseases compared to fully occlusive systems. An intermediate step would be to measure percutaneous penetration directly with hydrocortisone in these three tape systems rather than a biological effect like mitotic activity.[12] The motivation for using less occlusive systems would be decreased bacterial count, the decreased frequency of folliculitis and furunculoses, the decreased likelihood of miliaria, and enhanced comfort to the patient.

Nonproprietary Name and Trademarks of Drug

Hydrocortisone—*Cort-Dome, Cortef, Cortifan, Cortril, Hydrocortone, Hytone.*

References

1. Fisher LB, Maibach HI: Physical occlusion controlling epidermal mitosis. *J Invest Dermatol* 59:106-108, 1972.
2. Fisher LB, Maibach HI: The effect of occlusive and semipermeable dressings on the mitotic activity of normal and wounded human epidermis. *Br J Dermatol* 86:593-600, 1972.
3. Fisher LB, Maibach HI, Trancik RJ: The effect of variably occlusive tape systems on the mitotic activity of human epidermis: With and without corticosteroids. *Arch Dermatol* 114:384-386, 1978.
4. Fisher LB, Maibach HI: The effect of corticosteroids on human epidermal mitotic activity. *Arch Dermatol* 103:39-44, 1971.
5. Reich H, Samuels BK: The reaction of adrenocortical hormones with 2, 4-dinitrophenylhydrazine. *J Org Chem* 21:65-67, 1956.
6. Sarbach DV: *Method of Making Moisture Vapor Permeable and Water Resistant Rubbery Materials.* US patent 2,826,509 issued March 11, 1958.
7. Baker H, Kligman AM: Measurement of transepidermal water loss by electrical hygrometry. *Arch Dermatol* 96:441-452, 1967.
8. Spruit D: The water-barrier of stripped and normal skin. *Dermatologica* 141:54-59, 1970.
9. Fisher LB, Maibach HI: Topical antipsoriatic agents and epidermal mitosis in man. *Arch Dermatol* 108:374-377, 1973.
10. Grove GL, Houghton BA, Cochran JW, et al: Hydrocortisone effects on cell proliferation: Specificity of response among various cell types. *Cell Biol Int Rep* 1:147-155, 1977.
11. DuVivier A, Stoughton RB: Tachyphylaxis to the action of topically applied corticosteroids. *Arch Dermatol* 111:581-583, 1975.
12. Feldman RJ, Maibach HI: Penetration of ^{14}C hydrocortisone through normal skin: The effect of stripping and occlusion. *Arch Dermatol* 91:661-666, 1965.

Palmar and Plantar Pustulosis Elicited by *Candida* Antigen

Masami Uehara, MD

• Intracutaneous injection of *Candida albicans* was done on the forearm of 30 patients with palmar and plantar pustulosis. This induced an aggravation of pustular eruptions on the palms and soles in 11 (37%) of the 30 patients. The aggravation occurred only in those patients who had a positive delayed skin reaction to the *Candida* antigen. It is suggested that a delayed hypersensitivity inflammatory reaction somewhere in the body is attended with an aggravation of palmar plantar pustulosis.

(*Arch Dermatol* 114:730-731, 1978)

Palmar and plantar pustulosis is a recalcitrant pustular dermatosis of unknown cause. Various authors[1-3] have considered that there is a close correlation between palmar and plantar pustulosis and psoriasis. However, morphologically, palmar and plantar pustulosis has an eczematous vesicle,[4-7] indicating that this condition and psoriasis are different etiological entities. Studies of HLA typing[8,9] show that palmar and plantar pustulosis has normal frequency of HLA-B13 and HLA-B17 antigens that occur much more frequently in psoriasis than in normal control subjects. This supports the view that these two conditions are etiologically different.

Other investigators[4,5] have regarded palmar and plantar pustulosis as dependent on a focus of infection and curable by removal of the infected focus. But, more recently, authors[1,10] believe the association with infection to be fortuitous.

A feature of palmar and plantar pustulosis is that it is aggravated by a variety of factors. Possibly, then, clues to the pathogenesis of this disease might be furnished by elucidating the aggravating mechanisms. This article reports that delayed-type hypersensitive skin reactions to *Candida albicans* are sometimes accompanied by aggravations of palmar and plantar pustulosis.

PATIENTS AND METHODS

Selection of Patients

Thirty patients with palmar and plantar pustulosis, 20 women and 10 men, were included in this study. They ranged in age from 31 to 75 years, mean 50.2 years. The disease had been present for 1 to 16 years, mean 3.2 years, with periods of remission. The subjects had pustules, deep-seated vesicles, and scaling erythema on the palms and soles. In all patients, potassium hydroxide examinations of scrapings of the palms and soles showed no hyphae or spores. There was no evidence of active *Candida* infections of the skin or mucous membranes in the history of these patients. Patients with present or previous patches of well-defined psoriasis elsewhere were excluded from this study. Physical and roentgenographic examinations demonstrated that fifteen (50%) of the 30 patients had a septic focus: 13 suffered from alveolar pyorrhea or apical dental abscesses, and 2 had chronic tonsillitis. Moderate leukocytosis was seen in two of the 30 patients. Antistreptolysin-O titer was elevated only in one patient suffering from chronic tonsillitis. All patients were then treated with topical applications of corticosteroids and oral antibiotics. When possible, treatment of a suspected focus of infection was done.

Skin Tests With *Candida albicans*

At the time of remission of the disease, each patient was injected intracutaneously with 0.02 ml of a solution of *C albicans* (1:10,000). The test sites were the flexor surfaces of the forearms. Readings were made 15 minutes and 48 hours after injection. The immediate reaction was recorded as positive if the wheal was greater than 9 mm in diameter. Delayed reaction was recorded as positive if the indurated erythema was larger than 10 mm in diameter.

Aggravations of Skin Lesions Due to *Candida albicans* Injections

In order to see if the injections of *C albicans* could have any influence on pustular eruptions of the palms and soles, all patients were observed at two days, four days, and, if possible, seven days after the skin testings.

RESULTS

Intracutaneous Reactions to *Candida albicans*

Immediate intracutaneous reactions to *C albicans* occurred in 12 (40%) of 30 patients with palmar and plantar pustulosis (Table). Delayed intracutaneous reactions to the *Candida* antigen occurred in 15 (50%) of the 30 patients. Thus, the incidence of positive, immediate as well as delayed, intracutaneous reactions to *C albicans* in the patients with palmar and plantar pustulosis was almost the same as the incidence in normal controls.[11]

Aggravations of Skin Lesions by Injections of *Candida albicans*

Intracutaneous injections of *C albicans* induced aggravations of pustular eruptions on the palms and soles in 11 (37%) of the 30 patients (Table). On the night of the test day, slight to moderate itching occurred on the palms and soles. One or two days later, many pustules and deep-seated vesicles developed on the affected skin areas. Seven days later, brown spots and scales were present on the palms and soles. All of the 11 patients who showed aggravations had a positive delayed skin reaction to *C albicans* (Table). The aggravations usually occurred in those patients who had a strongly positive delayed skin reaction to the *Candida* antigen (Figure).

COMMENT

The present study demonstrated that aggravations of palmar and plantar pustulosis were sometimes elicited by skin injections of *C albicans*. The aggravations occurred usually in those patients who had a strongly positive delayed skin reaction to the *Candida* antigen. But, it is not likely that patients with this condition are specifically sensitized with *C albicans*, since the patients examined in the present study had a normal incidence of positive, immediate as well as delayed, skin reactions to the *Candida* antigen.

It is well known that palmar and plantar pustulosis is often aggravated

Accepted for publication Nov 23, 1977.

From the Department of Dermatology, Faculty of Medicine, Kyoto University, Kyoto, Japan. Dr Uehara is now at Shiga University of Medical Science, Otsu, Japan.

Reprint requests to Department of Dermatology, Shiga University of Medical Science, School of Medicine, Seta, Tsukinowa-cho, Otsu 520-21, Japan (Dr Uehara.).

Relationship Between Skin Reactions to *Candida albicans* and Aggravation of Skin Lesion

Patient/Age, yr/Sex	Skin Reactions to *C albicans*		Aggravation of Skin Lesions
	Immediate	Delayed	
1/61/F	+	+	+
2/46/F	+	+	+
3/37/M	+	+	+
4/36/F	+	+	+
5/51/F	+	+	+
6/57/F	+	+	+
7/45/F	–	+	+
8/33/M	–	+	+
9/60/F	–	+	+
10/31/M	–	+	+
11/53/M	–	+	+
12/50/F	+	+	–
13/55/M	+	+	–
14/49/F	+	+	–
15/56/F	+	–	–
16/50/M	+	–	–
17/48/F	+	–	–
18/63/F	–	+	–
19/55/F	–	–	–
20/53/M	–	–	–
21/53/F	–	–	–
22/45/F	–	–	–
23/75/F	–	–	–
24/59/F	–	–	–
25/58/M	–	–	–
26/42/F	–	–	–
27/32/F	–	–	–
28/50/F	–	–	–
29/40/M	–	–	–
30/31/M	–	–	–

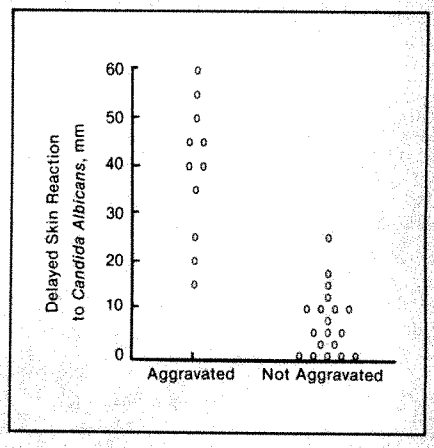

Delayed skin reactions to *Candida albicans* in 30 palmar and plantar pustulosis patients, divided into those aggravated by *Candida* antigen and those not aggravated.

by acute tonsillitis,[4] skin injections of staphylococcal and streptococcal substances,[12-14] and eczematous dermatitis.[15,16] Thus, this condition seems to be aggravated by inflammatory processes from a different cause. From a review of the literature, however, it was not clear whether an inflammatory reaction that aggravated palmar and plantar pustulosis was allergic in nature or not. In the present study, the aggravations that were induced by skin injections of *C albicans* did occur only in those patients who had a positive delayed skin reaction to the *Candida* antigen. It has been reported that, in patients with palmar and plantar pustulosis who suffer from allergy to a metal, patch tests with the metal on the forearm or the back produce not only an eczematous lesion at the skin site tested but also an aggravation of pustular eruptions on the palms and soles.[6] These findings would indicate that a delayed-type hypersensitive inflammatory reaction somewhere in the body is accompanied with an aggravation of palmar and plantar pustulosis. The mechanisms by which a delayed-type hypersensitive inflammatory reaction aggravates palmar and plantar pustulosis are speculative. An antigenic substance that is intranasally or subcutaneously applied tends to accumulate at inflammatory skin sites.[17] Therefore, in patients with palmar and plantar pustulosis, an antigen applied intracutaneously or epicutaneously may also accumulate at the affected palms and soles. This would then aggravate the eczematous reaction that occurs in the early phase of palmar and plantar pustulosis, after which secondary pustule formation quickly follows.[4-7]

It remains to be determined if other types of allergic reaction or nonallergic inflammatory processes could aggravate palmar and plantar pustulosis.

References

1. Everall J: Intractable pustular eruptions of the hands and feet: A review of 70 patients. *Br J Dermatol* 69:269-272, 1957.
2. Ingram JT: Pustular psoriasis. *Arch Dermatol* 77:314-318, 1958.
3. Enfors W, Molin L: Pustulosis palmaris et plantaris: A follow-up study of a ten-year material. *Acta Derm Venereol* 51:289-294, 1971.
4. Andrews GC, Machacek GF: Pustular bacterids of the hands and feet. *Arch Dermatol Syphilol* 32:837-847, 1935.
5. Veltman G, Schuermann H: Das Bakteriid von Andrews: Pustulosis palmaris et plantaris. *Arch Klin Exp Dermatol* 215:326-361, 1962.
6. Lampe P, Undeutsch W: Cytochemische Untersuchungen zur Morphogenese des pustulösen Bakteriids. *Arch Dermatol Forsch* 244:550-553, 1972.
7. Uehara M, Ofuji S: The morphogenesis of pustulosis palmaris et plantaris. *Arch Dermatol* 109:518-520, 1974.
8. Svejgaard J, Nielsen LS, Svejgaard E, et al: HL-A in psoriasis vulgaris and in pustular psoriasis: Population and family studies. *Br J Dermatol* 91:145-153, 1974.
9. Zachariae H, Petersen HO, Nielsen FK, et al: HL-A antigens in pustular psoriasis. *Dermatologica* 154:73-77, 1977.
10. Hellgren L, Mobacken H: Pustulosis palmaris et plantaris: Prevalence, clinical observations and prognosis. *Acta Derm Venereol* 51:284-288, 1971.
11. Kabe J: Fungal allergy and asthma. *Jpn J Allergy* 21:511-530, 1972.
12. Ofuji S, Matsubara T, Watanabe S: Pustulosis palmaris et plantaris. *Acta Derm (Kyoto)* 53:385-395, 1958.
13. Tachibana K: Clinical investigations on focal infections in several skin diseases. *Acta Derm (Kyoto)* 56:161-194, 1961.
14. Shelly WB, Wood MG, Beerman H: Pustular psoriasis elicited by streptococcal antigen and located to the sweat pore. *J Invest Dermatol* 65:466-471, 1975.
15. Ashurst PJC: Relapsing pustular eruptions of the hands and feet. *Br J Dermatol* 76:169-180, 1964.
16. Nakayama H, Murata M, Nakano N, et al: Pustulosis palmaris et plantaris from a viewpoint of metal allergy. *Rinsho Derma (Tokyo)* 16:313-329, 1974.
17. Strauss JS, Kligman AM: The relationship of atopic allergy and dermatitis. *Arch Dermatol* 75:806-811, 1957.

Origin of Familial Malignant Melanomas From Heritable Melanocytic Lesions

'The B-K Mole Syndrome'

Wallace H. Clark, Jr, MD; Ronald R. Reimer, MD; Mark Greene, MD; Ann M. Ainsworth, MD; Michael J. Mastrangelo, MD

• Distinctive melanocytic moles are described in 37 patients from six melanoma families. Among the family members examined by the authors, 15 of 17 patients with melanoma and 22 of 41 nonmelanoma relatives had the unique moles. The clinical and histological features of these moles have been designated the "B-K mole syndrome." The clinical features of the syndrome include the presence of < 10 to > 100 moles prominent on the upper trunk and extremities, and variability of mole size (5 mm to 15 mm), outline, and color combination. Histologically, B-K moles show atypical melanocytic hyperplasia, lymphocytic infiltration, delicate fibroplasia, and new blood vessels that occur within a compound nevus or de novo. The transformation of two B-K moles into malignant melanomas was documented photographically.

(*Arch Dermatol* 114:732-738, 1978)

Accepted for publication Nov 16, 1977.

From the Departments of Pathology and Dermatology, and the Fels Research Institute, Temple University School of Medicine, Philadelphia (Drs Clark and Ainsworth); the Environmental Epidemiology Branch, National Cancer Institute, Bethesda, Md (Drs Reimer and Greene); and the Fox Chase Cancer Center, Philadelphia (Dr Mastrangelo).

Presented at the American Academy of Dermatology, Dec 8, 1976.

Reprint requests to Department of Dermatology, Hospital of the University of Pennsylvania, 36th and Spruce St, Philadelphia, PA 19104 (Dr Clark).

This report describes a distinctive syndrome occurring in families affected by familial malignant melanoma. The combination of clinical appearance and histological features of certain cutaneous pigmented lesions forms what we have called the "B-K mole syndrome." The syndrome is named for two young patients who have been unusually helpful in accumulating some of the data for this report and who have had together seven primary melanomas. We have photographically documented the transformation into malignant melanoma of two moles in two different patients and, during examination of other family members, have diagnosed six unsuspected new primary cutaneous malignant melanomas. The moles of the syndrome are, therefore, formal histogenetic precursors of some primary familial malignant melanomas. The objective of this paper is to delineate the syndrome so that it may be recognized. Such recognition should lead to the diagnosis of familial melanoma at a curable stage and thus result in partial control of malignant melanomas that arise within a familial matrix.

MATERIALS AND METHODS

The family pedigrees of six families affected by familial melanoma were compiled. There were 69 members in the six families in either three or four generations. We examined 58 family members, 17 of whom were affected by melanoma, 41 who were nonmelanoma relatives, and ten spouse controls. We histologically documented the melanomas and classified them as to biologic type, level of invasion, thickness, and host cellular response, according to previously published criteria.[1,2] We histologically examined at least one B-K mole in 15 of the 17 melanoma patients examined, and 22 of the 41 nonmelanoma relatives examined. In most patients, we examined three or more B-K moles by serial paraffin blocks and hematoxylin-eosin stains. The B-K mole syndrome was not diagnosed without histological confirmation. The face, trunk, and extremities of the patients were photographed, and the majority of the B-K moles were photographed at magnifications of ×0.3, ×0.5, and ×1.0.

RESULTS

Incidence of Melanoma and the B-K Mole Syndrome

Twenty-five persons from the six families in our study had one or more primary cutaneous malignant melanomas. Of the 17 persons with melanoma who were examined, 15 had the B-K mole syndrome. Nine of the 25 melanoma patients died of metastatic melanoma; two others had metastases to lymph nodes, while still another two had level III melanomas of the superficial spreading type that were > 1.50 mm in thickness. Thus, substantial numbers of the melanomas evolving from the B-K mole syndrome were biologically aggressive. We examined 41 family members who were not affected by malignant melanoma. Of these 41 examined members, 22 had the B-K mole syndrome. None of the ten spouse controls of melanoma patients had the syndrome. The details of the various families comprising this report are given in Table

Table 1.—Family Background of Histologically Cor alignant Melanoma Patients

Family/ No. of Persons	Malignant Melanoma Patients: No. Examined*	Cases of B-K Mole Syndrome	No. With Multiple Primaries	Relatives: No Examined	No. With B-K Mole Syndrome
R/11†	4	4	1	7	3
K/5	4	4	3 (1-3 primaries, 1-2 primaries, 1-2 primaries)	11	6
B/3	3	3	2 (1-2 primaries, 1-5 primaries)	6	4
M/2	2	1	1 (4 primaries)	4	3
W/2	2	1	1 (3 primaries)	9	6
G/2	2	2	2 (1-2 primaries, 1-2 primaries)	4	2‡
Totals 25	17	15	10	41	22

*Patients examined clinically.
†Includes three cases of death certificate diagnosis.
‡Histologically, there were two atypical nevi, not entirely characteristic of B-K mole; these were not included in the total.

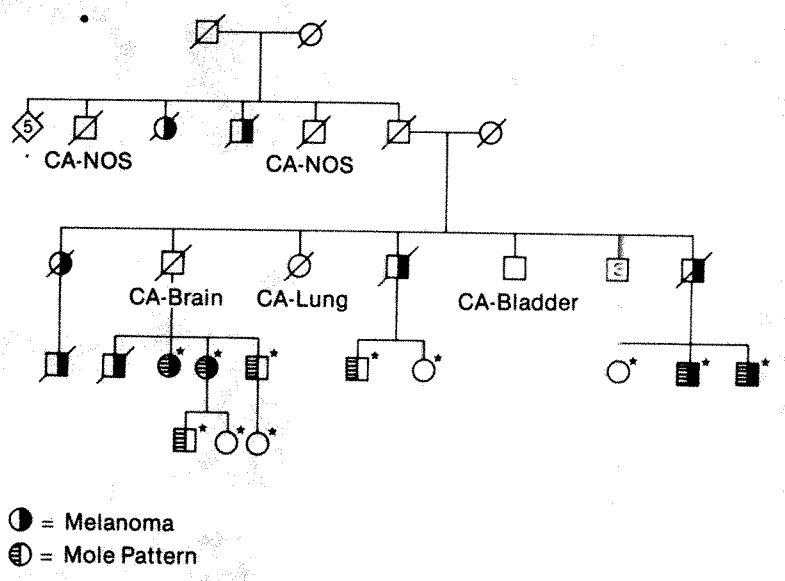

Fig 1.—Representative pedigree of family R. CA indicates cancer; NOS, not otherwise specified. Number inside shape indicates number of relatives for whom information is unknown; slash through shape indicates deceased person. Star indicates persons examined.

1. A representative family pedigree is shown in Fig 1.

Clinical Features of the Syndrome

The affected patient may have fewer than ten B-K moles or he or she may have 100 or more moles. The patient with a large number of moles has them on every cutaneous surface, from scalp to feet. The lesions are most prominent on the trunk and are readily observed on the upper back, arms, and chest above the breasts (Fig 2 and 3). The pattern and distribution in family members may be quite similar (Fig 4, left and right). The moles are sparse on nonexposed surfaces and on the lower extremities, but, in these sites, they are more numerous than are acquired melanocytic nevi in people without the syndrome. A patient may have the syndrome with fewer than ten B-K moles.

A single prototypic B-K mole is about 10 mm in diameter, is irregular in outline, and is a haphazard mixture of tan, brown, black, and pink. While seemingly flat on inspection, the B-K mole commonly has a small palpable dermal component. If one views four or five B-K moles as a group, there is striking variability from one mole to the next (Fig 3). The differences between B-K moles and ordinary acquired melanocytic nevi are summarized in Table 2. If one observes numerous large, variable moles as illustrated in Fig 2 and 4 or only a few, scattered, large, variable moles as illustrated by Fig 5 and 6, a presumptive diagnosis of the B-K mole syndrome should be made, and representative moles should be biopsied.

Histological Features of the Syndrome

Histology is required for diagnosis of B-K moles. Microscopically, one sees a compound melanocytic nevus. The intraepidermal component is similar to that of ordinary melanocytic nevi. The dermal component is uniformly cellular, is limited to the papillary dermis, and does not show evidence of neurotization (Fig 7 and 8). Some of the large moles, usually those with pink areas and an irregular outline, will show the microscopic changes distinctive for the B-K mole syndrome. Such changes are superimposed on the compound melanocytic nevus and include atypical melanocytic hyperplasia, mesenchymal changes in the papillary dermis, and a lymphocytic infiltrate. The term "atypical melanocytic hyperplasia," as used by us, is synonymous with "melanocytic dysplasia," ie individual melanocytes or small clusters of melanocytes that have some of the structural features of malignant melanocytes, but whose potential for development into obvious melanoma is obscure. The situation is precisely analogous to cervical dysplasia and senile keratoses: foci of squamous cells have some of the structural features of malignancy, but may remain indolent, regress completely, or progress to obvious carcinoma. The atypical melanocytes may be isolated in the basilar epidermal area or may be disposed in irregular, ellipsoidally shaped nests, the long axis of which tends to parallel the dermal-epidermal interface; the melanocytes may also be seen in the upper part of the papillary dermis (Fig 7 through 10). The individual atypical melanocytes are large and relatively pale; mitotic figures may be observed. The cells are frequently spindled in form, but they may be large and epithelioid. The cytoplasm is abundant and filled with fine, "dusty" melanin granules. In foci where one sees atypical melanocytes, mesenchy-

Fig 2

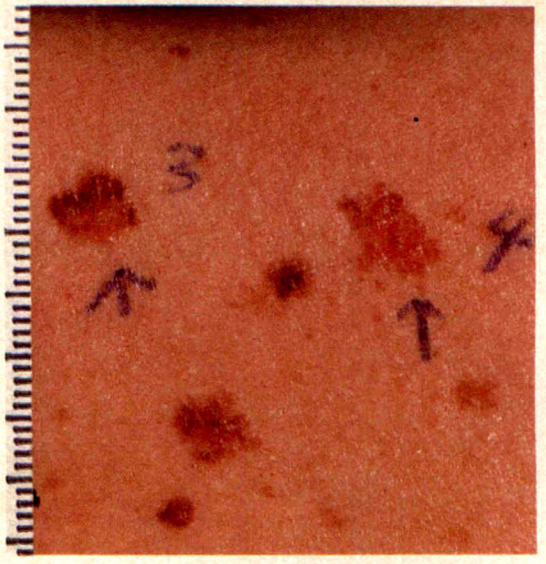

Fig 3

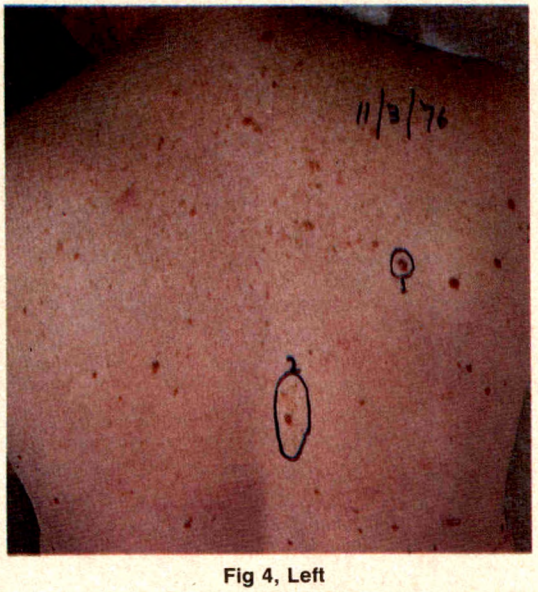

Fig 4, Left

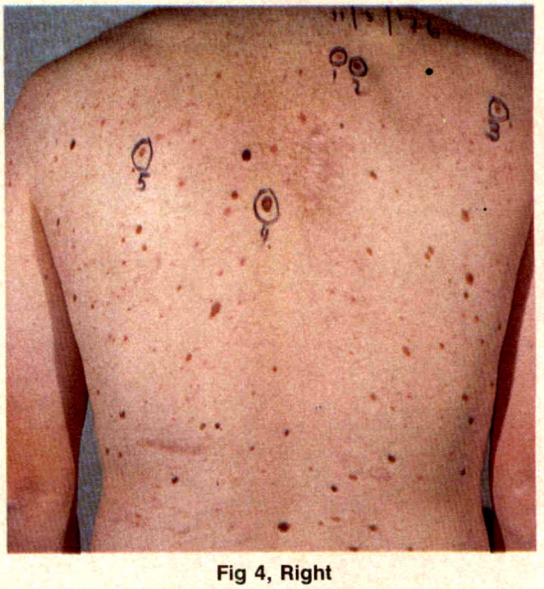

Fig 4, Right

Fig 5

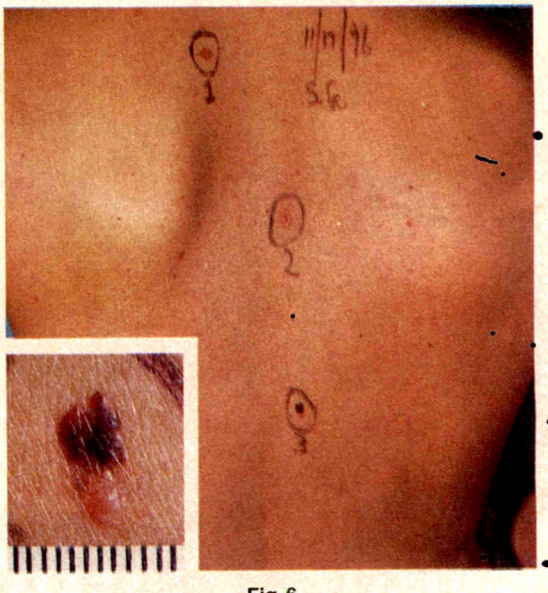

Fig 6

Fig 2.—Back of 27-year-old woman who had four primary malignant melanomas. Pattern and appearance of moles in patient with numerous lesions. Compare with Fig 6 for appearance of B-K moles sparse in number. Proband, family M.

Fig 3.—Constellation of moles from right posterior shoulder of patient shown in Fig 2. Variability in form from lesion to lesion is shown.

Fig 4.—Left and Right. Backs of two brothers, both of whom had malignant melanoma. Two sisters also had mole pattern almost identical to pattern illustrated in right figure.

Fig 5.—Back of 27-year-old woman in April 1972. Note lesion in black circle. Compare with lesion No. 3 in Fig 6 and with Fig 6, inset, which show lesion 4½ years later. Proband, family G.

Fig 6 and Inset.—Same patient as in Fig 5. Photograph taken November 1976. Transformation of B-K mole into malignant melanoma. Lesion indicated as No. 3 and, in closer view, in inset, is malignant melanoma of superficial spreading type. Histology of transformed lesion is shown in Fig 12, 13, and 14. Proband, family G.

Table 2.—Comparison of B-K Mole Syndrome With Acquired Melanocytic Nevi Occurring in People With the Syndrome

Characteristics	Acquired Melanocytic Nevi	B-K Moles
Time of life when lesions first appear	6 mo-1 yr	Not known; possibly later in childhood
Time of life when lesions cease to appear	Not known; probably 25-30 yr	Not known; lesions continue to appear beyond 35th year
Number of lesions	Stated to be 15-25 average number in affected individuals	< 10-> 100
Distribution of lesions on body surface	Sparse on lower extremities; virtually absent on bathing-trunks area	Numerous on "horse-collar" area of trunk and upper extremities; present on bathing-trunks area and lower extremities
Size of lesions	Usually < 5 mm	Frequently 5-10 mm; may be > 10 mm
Appearance of individual lesion	Regular in outline; uniformly colored	Irregular in outline; haphazardly colored; areas of pink and depigmentation
Histology of intraepidermal melanocytic component	Nests of melanocytes and individual melanocytes orderly in structure	Nests of melanocytes and individual melanocytes orderly in structure, plus quite atypical melanocytes
Histology of dermal component	Variable and may show neurotization	Remarkably uniform and cellular dermal component without neurotization

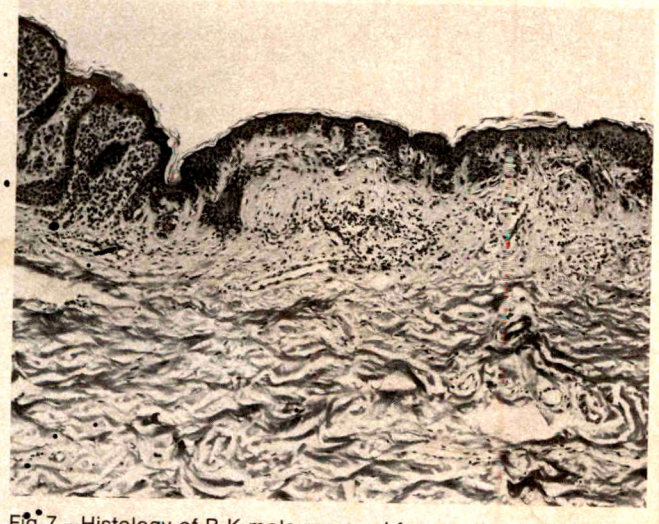

Fig 7.—Histology of B-K mole removed from patient illustrated in Fig 2 and 3. Both kinds of histological elements of B-K mole are illustrated. Nevic tissue is on left, and combination of atypical melanocytic hyperplasia, fibroplasia of papillary dermis, and lymphocytic infiltration is in right two thirds of photomicrograph. Proband, family M (hematoxylin-eosin, ×76).

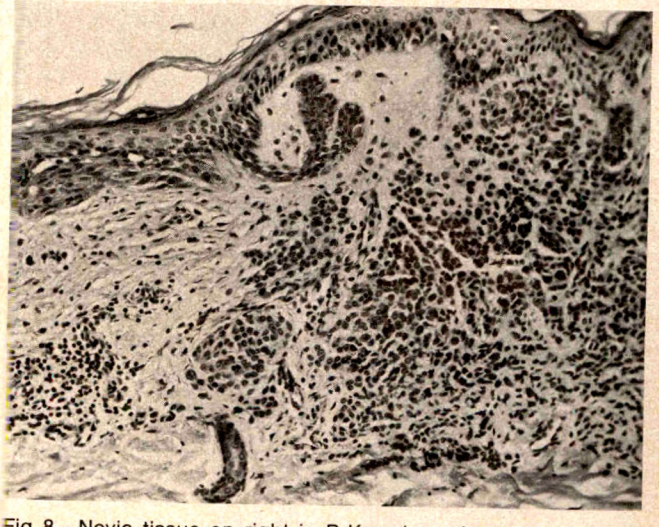

Fig 8.—Nevic tissue on right in B-K mole and atypical melanocytes, fibroplasia, and lymphocytic infiltration on left. Patient was 24-year-old woman with B-K mole syndrome, but without malignant melanoma. Sister of proband of family M, whose various lesions are illustrated in Fig 2, 3, 7, 9, and 10 (hematoxylin-eosin, ×152).

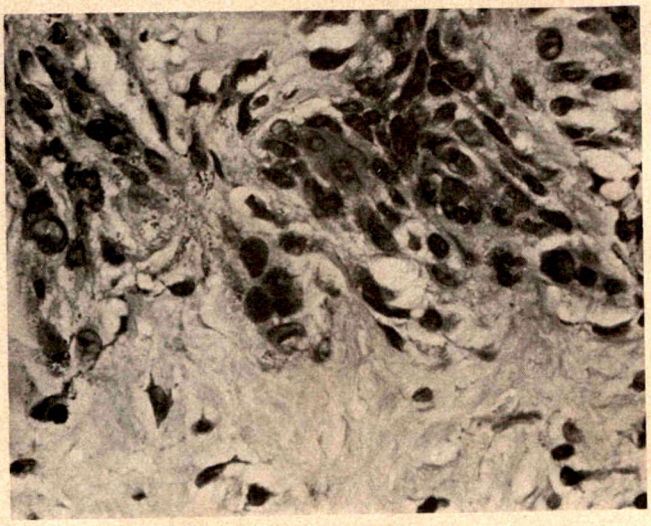

Fig 9.—Atypical melanocytic hyperplasia at dermoepidermal interface. Higher magnification of area near right margin of Fig 7 (hematoxylin-eosin, ×608).

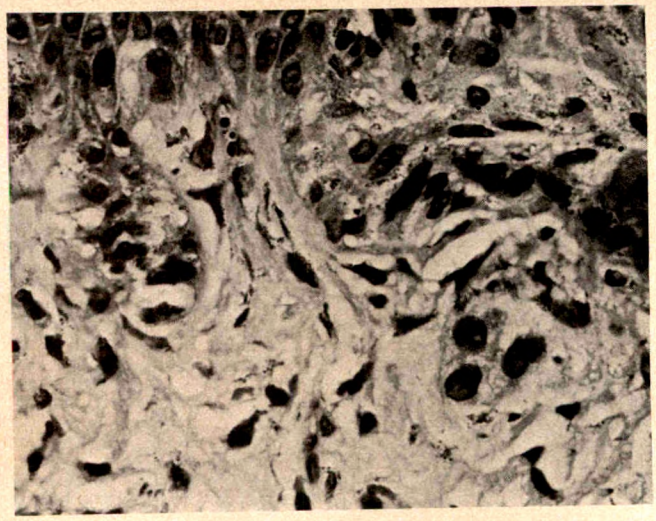

Fig 10.—Atypical melanocytic hyperplasia with three atypical melanocytes in dermis immediately deep to epidermis. Area is higher magnification of extreme right edge of Fig 7 (hematoxylin-eosin, ×608).

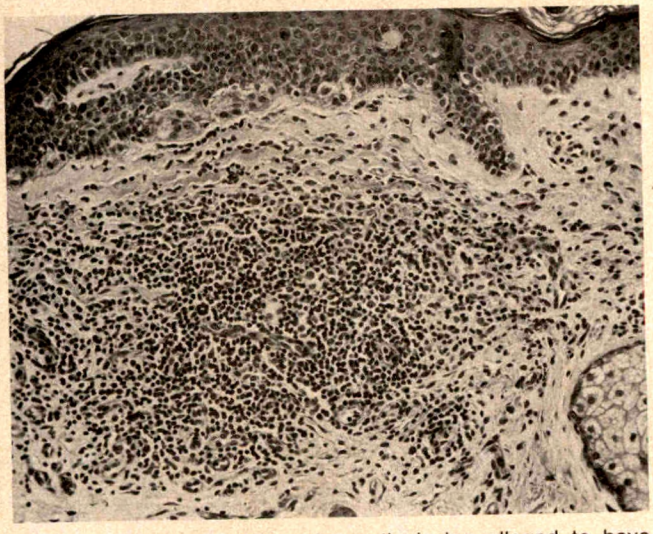

Fig 11.—Histology of B-K melanocytic lesion alleged to have appeared de novo on left breast of patient, whose back is shown in Fig 5 and 6. No nevic tissue was found in this lesion. Atypical melanocytic hyperplasia at dermoepidermal interface in upper left is shown, and below this, lymphocytic infiltration and fibroplasia are shown. Patient had two primary malignant melanomas. Proband, family G (hematoxylin-eosin, ×152).

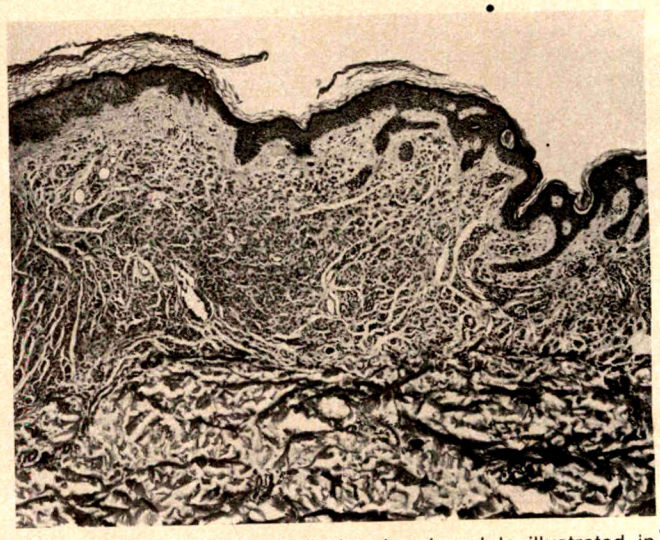

Fig 12.—Histology of small flesh-colored nodule illustrated in lower portion of Fig 6, inset. Nevic component of B-K mole that gave rise to malignant melanoma as illustrated in Fig 5 and 6. Histology of melanoma arising in this lesion is shown in Fig 13 and 14. Proband, family G (hematoxylin-eosin, ×61).

mal changes and an infiltrate of lymphocytes and macrophages are also observed (Fig 7 and 8). The papillary dermis is widened because of delicate fibroplasia and new blood vessel formation. In this new mesenchymal tissue are clusters of lymphocytes and varying numbers of melanophages. The dermal histology is virtually indistinguishable from the histology of regression commonly seen in malignant melanoma of the superficial spreading type and in the halo of halo nevi. The B-K moles present on a melanoma patient are similar to those present on their nonmelanoma bearing relatives (Fig 7 and 8).

Occasionally one sees a B-K mole that only has atypical melanocytes, mesenchymal changes, and a lymphocytic infiltrate. No features of a compound melanocytic nevus are demonstrated (Fig 11). Such observations suggest the de novo appearance of atypical melanocytes, lymphocytic infiltration, and fibroblasts. The various features that distinguish the B-K moles from malignant melanomas are listed following:

Clinical Features:

The B-K moles showed a notable degree of stability. None of the 22 relatives with the B-K mole syndrome gave a history of change or itching (a common symptom of malignant melanoma) in the moles. Serial photographs of some of the B-K moles that were taken during periods of two to five years gave no evidence of growth.

Histological Features:

1. The B-K moles showed multiplicity; histological documentation indicated the atypical melanocytic hyperplasia in five to 29 B-K moles in six different patients. One does not generally think of malignant melanoma presenting with 29 new primary lesions.

2. The atypical melanocytes of B-K moles are present focally within nevi. Multiple sections may be necessary to demonstrate them.

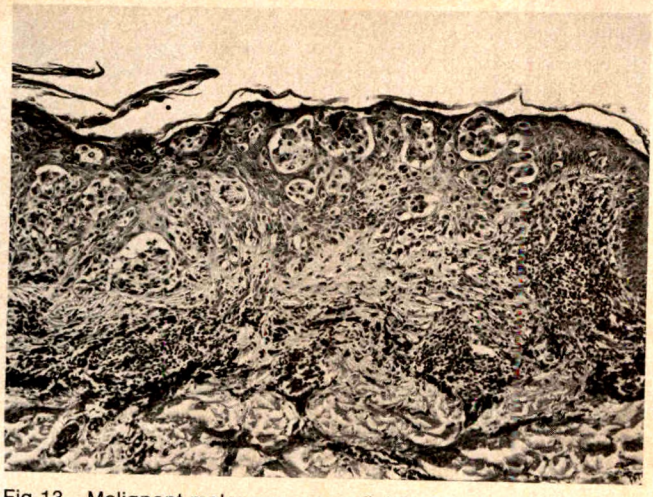

Fig 13.—Malignant melanoma, superficial spreading type, arising from B-K mole. Histology is taken from section plane through dark brown-black area forming upper part of lesion illustrated in Fig 6, inset. Proband, family G (hematoxylin-eosin, ×95)

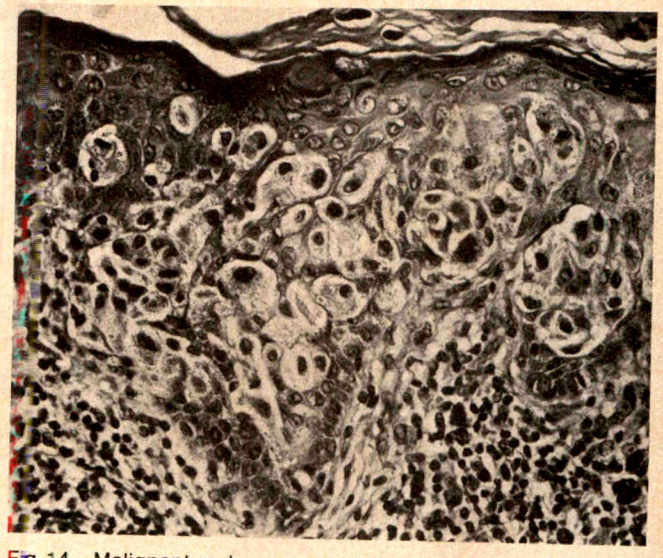

Fig 14.—Malignant melanoma, superficial spreading type. Same general area as in Fig 13 (hematoxylin-eosin, ×304).

3. Atypical melanocytes tend to be located near the dermal-epidermal interface in B-K moles. The nests of melanocytes that bridge the entire thickness of the epidermis and the individual melanocytes that grow in a pagetoid fashion characteristic of superficial spreading melanoma are not observed in B-K moles.

4. The lymphocytic infiltrate is limited and patchy in B-K moles. Commonly, the infiltrate is diffuse and copious in superficial spreading melanoma.

5. The delicate fibroplasia and new blood vessel formation are focal and present early in B-K moles, but are extensive and appear as the regressive phenomenon rather late in the developmental biology of malignant melanomas of the superficial spreading type.[1]

Evidence for Origin of Malignant Melanoma From B-K Moles

After completing the examination of our first two families, we began reexamination of patients and their families who, historically, had familial malignant melanoma. In one of these families, both of the only two siblings of a given generation had malignant melanoma. One of these sisters, who was 27 years old, was examined by us in April 1972. At that time she had a malignant melanoma of the superficial spreading type, invasive to level III, with ulceration. The melanoma, present in the right upper quadrant of the abdomen, was photographed, and the patient's back was also photographed at that time (Fig 5). In April 1972 when we first saw the patient, she had four or five large, irregular, flat moles on her back. Reexamination of the original photograph of the moles indicated that the clinical features of the B-K mole syndrome were present (Fig 5). The patient was seen by us again in November 1976, and the lowermost mole on her back had changed. A slightly elevated, black extension had appeared at the cephalad margin of the mole (Fig 6). Histologically, the black extension was overt malignant melanoma of the superficial spreading type, invasive to level II (Fig 12 through 14).

Another patient, also a 27-year-old woman with the B-K mole syndrome manifested by hundreds of moles, had previously had three primary melanomas removed. One mole was noted in comparison photographs, during a period of 4½ months to have developed a small nodule that proved histologically to be malignant melanoma. The patient noted that during the 4½ month time interval the lesion had begun to itch and had become scaly.

Our observations and the photographic evidence of the malignant evolution of these lesions demonstrate that the large moles of the B-K mole syndrome may be formal precursors of malignant melanoma.

COMMENT

There are at least three explanations of the nature of B-K moles: (1) The lesions are atypical melanocytic lesions that occur in melanoma patients; (2) the complete B-K mole syndrome appears in childhood; and (3) the B-K moles are the result of focal transformation that occurs within heritable, distinctive melanocytic nevi.

The atypical changes in nevi of some patients with sporadic melanoma have been referred to as activation of melanocytic nevi.[3] While the cause of such atypical lesions is completely unknown, one could suggest that the B-K moles are but a part of a spectrum of "melanoma-associated atypical melanocytic lesions." Such a concept is invalidated by the occurrence of the B-K mole syndrome in 21 of 36 family members who have not had malignant melanoma. The atypical moles are, therefore, familial and are not just observed in melanoma-bearing patients.

The B-K moles could appear in childhood, with all of the distinctive clinical and histological features present and fully evolved at the time of their first appearance. While there seems to be little question that the basic nevic component of the B-K mole usually appears in childhood, the other histological features would seem to be superimposed changes. The evidence that the changes are superimposed is inferential and is as follows: the atypia involves only a small portion of the nevus and is associated with a lymphocytic infiltrate, delicate fibroplasia and new blood vessel formation. That this histological combination would appear as such in childhood and persist unchanged into adult life seems unlikely.

As a third explanation, the basic nevic component of B-K moles could be inherited, and the atypia may be a subsequent event, a result of one or more additional inductive forces that act on the inherited melanocytic nevus. It is proposed that the inherited nevic component of the B-K mole is more susceptible to neoplastic transformation than common acquired melanocytic nevi. At present, we feel that this interpretation is the

most likely explanation for the pigmented lesions of the B-K mole syndrome. The lymphocytic infiltrate and other evidence to be subsequently reported suggest that at least one of the additional inductive mechanisms is related to the cell-mediated immune system (R. R., unpublished data). We emphasize that the fully developed B-K mole syndrome is not a necessary prerequisite for the development of malignant melanoma in these families. Two family members without the syndrome did develop malignant melanoma, apparently de novo.

In our study of the literature related to familial melanoma, we found several references to pigmented lesions in patients bearing malignant melanomas, which are doubtless identical to the lesions reported here. In Cawley's original report of the first cases of familial melanomas,[4] two of the three patients had their melanomas arise in nevi and had multiple moles. Anderson and his co-workers and, later, Anderson, alone, suggested that heritable melanomas occur in patients with a multiplicity of nevi on the trunk.[5,6] Schoch,[7] in his excellent study of familial melanoma, obviously encountered the problem of histological atypia of melanocytes in a nevus, and that lesion could well have been a B-K mole. Munro[8] has made observations similar to those of our report and similar to those of Schoch. Turkington[9] observed "many brown nevi" in one of his patients. He also stated,"the inheritance of large numbers of nevi might predispose certain families to a greater risk of melanoma." Katzenellenbogen and Sandbank[10] reported melanomas in twins, both of whom had multiple freckles, lentigines, and nevi dispersed over their skins. St Arneault et al[11] did not describe features of the B-K mole syndrome in reporting melanomas in identical twins. However, in the study made by these authors, the melanomas arose from a precursor lesion that had been present in both twins for as long as they could remember, on the left chest anteriorly. The report of St Arneault et al establishes that melanomas may arise in heritable pigmented lesions. Frichot[12] has confirmed the B-K mole syndrome as one phenotype associated with familial melanoma.

There are doubtless other phenotypes associated with familial melanoma and a number of additional studies need to be done before the nature of the presently reported syndrome is understood. We should therefore like to avoid sweeping conclusions at this time. Present evidence does suggest that the B-K mole syndrome is inherited as an autosomal dominant. The clinico-pathologic features are distinctive, and patients with the syndrome in a familial melanoma family are at extremely high risk for the development of malignant melanoma. Such patients should be carefully followed by serial photography, for the recognition of the developing malignant melanoma within the B-K moles should result in prompt diagnosis and therapy. Because the proper treatment of superficially invasive melanomas (level II, < 0.76 mm in thickness) results in cure,[1,2] therapy for early melanomas that develop in the B-K mole syndrome should result in prevention of death from some familial melanomas.

This investigation was supported by research grants CA-11511, CA-13669, and CA-13456 from the National Cancer Institute, National Institutes of Health.

Madgi S. Kodsi, MD, Leonard I. Goldman, MD, William Cohen, MD, Curtis Lamp, MD, William Terry, MD, Kenneth Kraemer, MD, and Hunter Neal, MD, were helpful in many aspects of this study.

Mr William Witmer was responsible for much of the clinical photography and for photographic processing; Mr Gerald Pearlman also took clinical photographs. Mrs Dorothy Campbell prepared the histologic specimens; Mrs Vida Rupert and Mrs Susan Dunn prepared the manuscript; Evelina Bernardino, MD, gave valuable clinical assistance; family pedigrees and other clinical minutiae were detailed by Ms Isabel Matozza.

References

1. Clark WH, Ainsworth AM, Bernardino EA, et al: The developmental biology of primary human malignant melanomas. *Semin Oncol* 2:83-103, 1975.

2. Breslow A: Tumor thickness, level of invasion and node dissection in stage 1 cutaneous melanoma. *Ann Surg* 182:572-574, 1975.

3. Hertel BF, Rosai J, Aranha G: Activation of melanocytic nevi in patients with malignant melanoma. *Lab Invest* 36:12, 1977.

4. Cawley EP: Genetic aspects of malignant melanoma. *Arch Dermatol* 65:440-450, 1952.

5. Anderson DE, Smith JL, McBride CM: Hereditary aspects of malignant melanoma. *JAMA* 200:81-86, 1967.

6. Anderson DE: Clinical characteristics of the genetic variety of cutaneous melanoma in man. *Cancer* 28:721-725, 1971.

7. Schoch EP Jr: Familial malignant melanoma: A pedigree and cytogenetic study. *Arch Dermatol* 88:445-456, 1963.

8. Munro DD: Multiple active junctional nevi with family history of malignant melanoma. *Proc R Soc Med* 67:594-595, 1974.

9. Turkington RW: Familial factor in malignant melanoma. *JAMA* 192:85-90, 1965.

10. Katzenellenbogen I, Sandbank M: Malignant melanoma in twins. *Arch Dermatol* 94:331-332, 1966.

11. St Arneault G, Nagel G, Kirkpatrick D, et al: Melanoma in twins. *Cancer* 25:672-677, 1970.

12. Frichot BC: New cutaneous phenotype in familial malignant melanoma. *Lancet* 1:864-865, 1977.

Scalpel Excision of Basal Cell Carcinomas

Robert S. Bart, MD; David Schrager; Alfred W. Kopf, MD; Judith Bromberg, MS; Neil Dubin, PhD

• A total of 468 coded, histologically proved basal cell carcinomas were excised from 446 patients in the Skin and Cancer Unit of New York University Medical Center from 1955 to 1967. The five-year cumulative recurrence rate was 6.8%. The highest recurrence rates, in areas in which sufficient data were available, were for the periocular regions, the scalp, and the nose and paranasal areas. Following re-treatment of recurrences, 464 of the 468 lesions (99.1%) were cured at the time of the most recent examination. After the second postoperative year, at least 70% of results were recorded as cosmetically good or excellent at the time of last follow-up. The most common complication was hypertrophic scars. There was a tendency for increasing incidence of such scars with increasing diameters of the lesions.

(*Arch Dermatol* 114:739-742, 1978)

This is the third in a series of studies from the Oncology Section of the Skin and Cancer Unit, New York University Medical Center, on the results of treatment of basal cell carcinomas. This article concerns the results of excision. The others concerned those achieved by x-ray therapy[1] and curettage-electrodesiccation.[2]

MATERIALS AND METHODS

Clinical Material

Of the 3,033 histologically proved basal cell carcinomas coded in the Oncology Section from 1955 to 1967, a total of 468 lesions were excised from 446 patients in the Skin and Cancer Unit. There were 444 white patients, 1 black patient, and 1 Oriental. Twenty patients in this series had more than one coded basal cell carcinoma treated by scalpel excision (Table 1). Two hundred twenty-nine lesions were removed from 221 male patients and 239 from 225 female patients. Ages when seen for first coded basal cell carcinomas ranged from 14 to 88 years, with a mean of 60 years.

Scalpel excision was the third most frequently used method of treatment for basal cell carcinomas at the clinic from 1955 to 1967. Of 3,033 histologically proved, coded basal cell carcinomas treated during the years 1955 to 1967, 51.6% were treated by curettage-electrodesiccation, 25.7% by x-radiation, and 15.4% were treated by scalpel excision. The remaining 7.3% of basal cell carcinomas were treated by various other modalities.

The following method of excision is the one generally used at the Skin and Cancer Unit. Gentian violet is used to outline the planned excision, allowing a margin of 3 to 5 mm of normal-appearing skin beyond the edge of the lesion. An effort is made to place the long axis of an excision in the direction of skin creases. A local anesthetic agent is injected around the lesion. The incision is made, following the predetermined lines, with a No. 15 scalpel blade held perpendicular to the surface of the skin. The incision is brought down through the full thickness of the skin into the subcutaneous fat. If necessary, bleeding vessels are clamped and tied with catgut or electrocoagulated. Wound closure is with interrupted sutures. Wide, undermining, vertical mattress sutures or buried sutures or both are sometimes required.

The majority of excisions were done by resident physicians under the supervision of senior attending physicians.

Excised specimens were not routinely examined for adequacy of all surgical margins.

Statistical Methods

The five-year cumulative recurrence rates were calculated utilizing the life-table method of Cutler and Ederer.[3] The value of this method lies in its ability to use follow-up information on lesions that have been observed for varying lengths of time. Where numbers were insufficient to employ this method, such as lesions in a particular site or with a particular range of diameters, a raw recurrence rate was determined by dividing the number of all known recurrences, including those three discovered after five years, by the total number of lesions treated in that category or subgroup.

RESULTS

Recurrences

After surgical excision of the 468 basal cell carcinomas there were 27 recurrences, 19 of which were histologically confirmed and 8 of which were diagnosed clinically. Thus, the raw recurrence rate was 5.8%. Twenty-four of the recurrences were diagnosed within five years after excision. The five-year cumulative recurrence rate was 6.8% (Table 2).

Table 3 gives the raw recurrence rates, by site, of the 468 basal cell carcinomas treated by excision. Although the recurrence rates for the ear and for the lips appear to be very high, the figures are not meaningful

Table 1.—Histologically Verified Basal Cell Carcinomas Treated by Scalpel Excision

No. of Lesions per Patient	No. of Patients	Total No. of Lesions
1	426	426
2	18	36
3	2	6
Total	**446**	**468**

Accepted for publication Dec 16, 1977.

From the Oncology Section, Skin and Cancer Unit, New York University Medical Center and the Departments of Dermatology (Drs Bart and Kopf and Mr Schrager) and Environmental Medicine (Ms Bromberg and Dr Dubin), New York University School of Medicine.

Reprints not available.

Table 2.—Cumulative Recurrence Rate After Excision of Basal Cell Carcinomas

Time Since Treatment, mo	No. of Lesions at Risk at Beginning of Year	No. Lost in Year	No. of Recurrences in Year	Recurrence Rate in Year*	Rate of No Recurrence in Year†	Cumulative Rate of No Recurrence‡	Cumulative Rate of Recurrence§‖
0-11	468	83	8	.0188	.9812	.9812	.0188
12-23	377	48	7	.0198	.9802	.9618	.0382
24-35	322	35	6	.0197	.9803	.9429	.0571
36-47	281	54	3	.0118	.9882	.9318	.0682
48-59	224	29	0	.0000	1.0000	.9318	.0682

*Recurrence rate in year equals the number of recurrences in the year divided by the number of lesions at risk at the beginning of the year less half the number lost in the year.
†Rate of no recurrence in year equals 1 minus the recurrence rate in year.
‡Cumulative rate of no recurrence equals the rate of no recurrence times the cumulative rate of no recurrence in the previous year.
§Cumulative rate of recurrence equals 1 minus the cumulative rate of no recurrence.
‖$SE_{5\ yr}$ = .0137.

Table 3.—Recurrences After Excision of Basal Cell Carcinomas by Site

Site	No. (%) of Lesions	No. of Recurrences	Raw Recurrence Rate, %
Scalp	19 (4.1)	2	10.5
Cheek	85 (18.1)	3	3.5
Forehead	68 (14.5)	2	2.9
Ear	9 (1.9)	3	33.3
Periocular	23 (4.9)	3	13.0
Nose & paranasal	98 (20.9)	7	7.1
Lips	5 (1.1)	2	40.0
Neck	30 (6.4)	1	3.3
Trunk	66 (14.1)	1	1.5
Upper extremities	16 (3.4)	1	6.3
Lower extremities	19 (4.1)	0	0
Not stated	30 (6.4)	2	6.7
Total	**468 (100.0)**	**27**	5.8

Table 4.—Recurrences After Excision of Basal Cell Carcinomas by Size*

Greatest Diameter, mm	No. (%) of Lesions	No. of Recurrences	Raw Recurrence Rate, %
0-5	101 (22.0)	5	5.0
6-10	185 (40.3)	13	7.0
11-15	95 (20.7)	6	6.3
16-20	33 (7.2)	0	0.0
> 20	45 (9.8)	3	6.7
Total	**459 (100.0)**	**27**	5.9

*Excludes the nine lesions for which size was not stated.

because of the small number of lesions at those locations, nine and five, respectively, and should be interpreted cautiously. The highest observed recurrence rates excluding these sites was 13% in the periocular tissues. The recurrence rate was 10.5% for the scalp lesions, 7.1% for lesions excised from the nose and paranasal areas, and 6.3% from the upper extremities. Recurrence rates less than 4% were found on the forehead, cheek, neck, trunk, and lower extremities.

Table 4 summarizes the recurrence rates by greatest diameters of lesions. In this series, recurrence rate seems to be unrelated to lesion diameter.

Thirty-four lesions had been previously treated elsewhere with radiation or one of the surgical modalities before being excised at the Skin and Cancer Unit (Table 5). Of these, three recurred after excision for a raw recurrence rate of 8.8%, a higher recurrence rate than for previously untreated lesions (5.5%). Nevertheless, 34 lesions are too few on which to base conclusions. The inclusion of previously treated lesions in this series did not significantly increase the recurrence rate. As can be seen in Table 5, if the 34 previously treated lesions are excluded from the series, the raw recurrence rate decreases from 5.8% to 5.5%.

Re-Treatment of Recurrences

Table 6 outlines how the recurrences were re-treated and the results at final examination. These data can be summarized as follows:

1. Of 468 lesions, there were 27 recurrences (5.8% raw rate).
2. Of the 13 lesions for which excision was the method of re-treatment, six (46%) recurred at least once more.
3. Of the six lesions for which x-radiation was the method of re-treatment, one (17%) recurred.
4. Of the five lesions re-treated with curettage-electrodesiccation or excision plus x-radiation, none recurred.
5. Three patients did not return for re-treatment.
6. The overall incidence of second recurrences was 29% (seven of 24 which had been retreated).
7. Of the seven second recurrences, all but one were cured at the time of the last examination.
8. Of the 468 lesions, only four persisted at the time of the last visit. This includes those in the three patients who did not return for re-treatment of their recurrences. Thus, 464 of 468 lesions (99.1%) were cured at the time of the most recent examination.

Cosmetic Results

The cosmetic appearance of each excision site was evaluated during each return visit to the clinic and designated as excellent, good, fair, or poor. When a treated area was not easily found, the result was considered excellent. A poor result was an unsightly alteration of the skin. Fair and good refer to results intermediate in appearance between these extremes. The cosmetic results used for

Table 5.—Previous Therapy of Basal Cell Carcinomas Treated by Surgical Excision

Previous Treatment	No. of Lesions	No. of Recurrences	Raw Recurrence Rate, %
Curettage or electrodesiccation or both	21	1	4.8
Excision	7	1	14.3
Radiation	4	1	25.0
Radiation & surgery	2	0	0
All previously treated	34	3	8.8
No previous therapy	434	24	5.5
All lesions	468	27	5.8

Table 6.—Results of Re-Treatment of 24 Recurrent Basal Cell Carcinomas*

		First Re-Treatment		Final Results of Further Treatments of the Seven Lesions That Recurred a Second Time	
Re-Treatment Method	No. Re-Treated	No. (%) of Recurrences	No. (%) of Recurrences	Tumor Absent Last Exam	Tumor Present Last Exam
Excision	13	7 (54)	6 (46)	6	0
X-radiation	6	5 (83)	1 (17)	0	1
Curettage-electro-desiccation	4	4 (100)	0	0	0
Excision & X-radiation	1	1 (100)	0	0	0
Total	**24**	**17** (71%)	**7** (29)	**6**	**1**

*Excludes three recurrent lesions not presented for re-treatment. Of the 468 lesions excised at the Skin and Cancer Unit, 464 or 99.1% were cured at the time of last examination.

Table 7.—Cosmetic Result vs Length of Follow-Up*

Length of Follow-up	No. of Lesions	Cosmetic Results, %				
		Excellent	Good	Fair	Poor	Not Stated
0-11 mo	83	7.2	20.5	7.2	2.4	62.7
12-23 mo	48	10.4	45.8	20.8	0	22.9
24-35 mo	34	29.4	50.0	2.9	2.9	14.7
36-47 mo	54	42.6	44.4	1.9	0	11.1
48-59 mo	29	37.9	31.0	13.8	0	17.2
60-71 mo	32	25.0	50.1	9.4	3.1	12.5
72-83 mo	46	37.0	34.8	2.2	2.2	23.9
84-95 mo	19	47.4	26.3	15.8	0	10.5
8 yr	11	36.4	63.6	0	0	0
9 yr	19	36.8	47.4	10.5	5.3	0
10-15 yr	45	20.0	60.0	8.9	0	11.1
> 15 yr	21	28.6	33.3	23.8	4.8	9.5
Total study	**441**	26.1	39.9	9.1	1.6	23.4

*Excludes 27 lesions that recurred.

Table 8.—Occurrence of Thickened Scars* After Excision vs Greatest Diameter of Excised Basal Cell Carcinomas

Diameter, mm	No. of Thickened Scars	No. of Excisions†	% With Thickened Scars
0-5	4	101	4.0
6-10	14	185	7.6
11-15	11	95	11.6
16-20	5	33	15.2
> 20	4	45	8.9
Total	**38**	**459**	8.3

*Includes 1 keloid, 4 hypertrophic scars/keloids, and 33 hypertrophic scars. See text for definitions.

†Excludes nine lesions for which size was not stated.

analysis were those recorded at the time of last examination of a particular lesion. These data are summarized in Table 7. Starting after the second postoperative year until the 15th postoperative year, at least 70% of results were recorded as good or excellent at the time of last follow-up in each year.

Complications and Sequelae

Complications and sequelae occurred in 10.5% of the 468 lesions treated by surgical excision. The most common complication was thickened scars, ie, hypertrophic scars and keloids.

The term "keloid" is here arbitrarily defined to mean a postoperative thickened scar that failed to spontaneously involute during a period of follow-up of at least three years. By "hypertrophic scar" is meant a thickened scar that spontaneously involuted within three years after surgery. Those thickened scars followed up for less than three years without involution are included in the category "hypertrophic scar/keloid" in the following tabulation.

Complication	No. (%)
Hypertrophic scars	33 (7.1)
Keloid	1 (0.2)
Hypertrophic scar/keloid	4 (0.9)
Atrophic scars	3 (0.6)
Hypopigmentation	6 (1.3)
Hyperpigmentation	2 (0.4)
Total	**49** (10.5)

The data on Table 8 suggest that there is an increasing incidence of thickened scars with increasing diameter of the lesions. The overall rate of thickened-scar formation was 8.3%. The only definite keloid occurred on the arm of a 15-year-old girl, the only black in this series.

Other complications included atrophic (spread) scars and hypopigmentation and hyperpigmentation.

COMMENT

The cumulative five-year recurrence rate after radiation therapy of histologically proved basal cell carcinomas at the Skin and Cancer Unit was 7.9%[1]; that after curettage-electrodesiccation varied from 5.7% to 18.8%, depending on the group of patients studied[2]; and that after scalpel excision in the present study was 6.8%. Any comparison of recurrence rates among the various treatment modalities must take into consideration certain differences in the lesions treated. For example, of the lesions treated with x-radiation, 99% were on the head and neck; for those treated by curettage-electrodesicca-

tion, 83% were on the head and neck; and of the lesions that were excised, 78% were on these anatomical sites. Recurrence rates tend to be lower on the trunk. Also, there was a tendency for larger lesions to be treated by x-radiation: about 48% of lesions treated by radiation were more than 1 cm in greatest diameter, whereas 32% of lesions treated by curettage-electrodesiccation and about 37% of those treated with excision were more than 1 cm in greatest diameter.

The recurrence rate of 13% for basal cell carcinomas excised from the periocular tissues contrasts with the 4% rate of recurrence after radiation of 50 such lesions.[4]

Initially the cosmetic results after radiation therapy and both surgical procedures were similar, with about 70% of all treatment sites appearing good to excellent. However, the cosmetic results after radiation tended to deteriorate with time, whereas the cosmetic results after curettage-electrodesiccation and after scalpel excision tended to improve with time. Good to excellent results during the second and third year were seen in 75% after irradiation,[1] in 73% after curettage-electrodesiccation,[2] and in 70% after excision; the corresponding percentages in the ninth year and beyond are 49%,[1] 79%,[2] and 77%.

Scalpel excision has several advantages: healing is generally rapid and is complete in one to two weeks, depending on location; the scar is narrow and is often cosmetically preferable; it provides a specimen for histologic verification of completeness of tumor removal; the procedure is suitable for basal cell carcinomas of all histologic types; it is suitable in most anatomic locations; and the cosmetic results tend to improve with the passage of time whereas the results after irradiation tend to worsen with time.

Disadvantages of scalpel excision include the following: variable amounts of normal tissue must be sacrificed for proper coaptation of wound margins; excision of large lesions may necessitate the use of skin grafting; it usually requires more time for the physician to become proficient at scalpel excision than with other techniques; it is not suitable for the removal of many lesions on one area (eg, numerous superficial basal cell carcinomas); the operating time is longer than with some other surgical techniques (eg, curettage-electrodesiccation, cryotherapy); this method is often not appropriate for tumors that are attached to or involve bone or cartilage; it is contraindicated in certain patients receiving anticoagulant therapy; because of the difficulty in preserving normal anatomic contours and therefore in providing good function and satisfactory cosmetic results, this approach is less suited for lesions located on the tip of the nose, nasal alae, eyelid margins, vermilion borders of the lips, and oral commissures.

Some workers, for example Epstein,[5] so favor simple surgical excision that they recommend curettage-electrodesiccation be abandoned for the treatment of basal cell carcinomas. We consider that there is a need for scalpel surgical excision, curettage-electrodesiccation, radiotherapy, cryosurgery, Mohs' surgery, and, in very special circumstances, topical chemotherapy. For some basal cell carcinomas any of the modalities could be used with equally gratifying results, but in particular instances certain methods are better than others. There is no doubt that for some lesions, excision is to be preferred to curettage-electrodesiccation. It is equally true that for others curettage-electrodesiccation, x-radiation, or cryosurgery, in properly trained and experienced hands, is preferable. Each lesion must be carefully analyzed and the best method for treatment chosen if we are to achieve the ultimate goals of lowest recurrence rates and best cosmetic results.

In previously published articles,[6-20] recurrence rates after excision of basal cell carcinomas were reported as low as 0.9% and as high as 19.5%. However, we have found it impossible to compare the results of any of these series in the literature with each other and with ours. This is due to a lack of display of the data presented by others as well as differences in statistical methods.

During the years from which our series of cases was collected, multiple-block techniques for the microscopic assessment of the adequacy of all surgical margins were not used routinely; nevertheless, a five-year cumulative recurrence rate of 6.8% was achieved. It would seem prudent, however, when doubt exists, if not routinely, that excised specimens be carefully studied histologically for adequacy of excision.

References

1. Bart RS, Kopf AW, Petratos MA: X-ray therapy of skin cancer: Evaluation of a "standardized" method for treating basal cell epitheliomas, in *Sixth National Cancer Conference: Proceedings of the American Cancer Society.* Philadelphia, JB Lippincott, 1970, pp 559-570.
2. Kopf AW, Bart RS, Schrager D, et al: Curettage-electrodesiccation treatment of basal cell carcinomas. *Arch Dermatol* 113:439-443, 1977.
3. Cutler SJ, Ederer F: Maximum utilization of the life table method in analyzing survival. *J Chronic Dis* 8:699-712, 1958.
4. Green R, Kopf AW, Bart RS: X-irradiation of basal cell epitheliomas of the eyelids and canthi, in McCarthy WH (ed): *Proceedings of the International Cancer Conference, Sydney, 1972; Melanoma and Skin Cancer.* Sydney, Australia, VCN Blight Publishers, 1972, pp 333-342.
5. Epstein E: Cosmetic results after treatment of basal cell carcinoma. *Cutis* 14:825-830, 1974.
6. Grifith BH, McKinney P: An appraisal of the treatment of basal cell carcinoma of the skin. *Plast Reconstr Surg* 51:565-571, 1973.
7. Huriez C, Benoit M, Lebeurre R: On 1002 cases of malignant cutaneous tumors observed in six years at the Clinique Dermatologique of Lille. *Lille Med* 6:134-142, 1961.
8. Battle RJV, Chir M, Patterson TJS: The surgical treatment of basal cell carcinoma. *Br J Plast Surg* 13:118-135, 1960.
9. Ferrara RJ: The private dermatologist and skin cancer. *Arch Dermatol* 81:225-234, 1960.
10. Freeman RG, Knox JM, Heaton CL: The treatment of skin cancer. *Cancer* 17:535-538, 1964.
11. Hayes H: Basal cell carcinoma: The East Grinstead experience. *Plast Reconstr Surg* 30:273-280, 1962.
12. Jackson R: The treatment of basal cell carcinoma. *Cutis* 5:1231-1234, 1969.
13. Knox JM, Freeman RG, Duncan WC, Heaton CL: Treatment of skin cancer. *South Med J* 60:241-246, 1967.
14. Macomber WB, Wang MKH, Sullivan JG: Cutaneous epithelioma. *Plast Reconstr Surg* 24:545-562, 1959.
15. McCallum DL, Kinmont PDC: Basal cell carcinoma: An analysis of cases seen at a combined clinic. *Br J Dermatol* 78:141-146, 1966.
16. Modlin JJ: Cancer of the skin. *Mo Med* 51:364-367, 1954.
17. Rintala A: Surgical therapy of basal cell carcinoma. *Scand J Plast Reconstr Surg* 5:87-90, 1971.
18. Sharnoff LB, Spira M, Hardy B: Basal cell carcinoma: A statistical approach to rational management. *Plast Reconstr Surg* 39:619-624, 1967.
19. Taylor AG, Barisoni D: Ten years' experience in the surgical treatment of basal cell carcinoma. *Br J Surg* 60:522-525, 1973.
20. Thomas P: Treatment of basal cell carcinoma of the head and neck. *Rev Surg* 27:293-294, 1970.

Multiple Hamartoma Syndrome (Cowden's Disease)

Col Donald D. Nuss, MC, USA; Col John L. Aeling, MC, USA; Maj Donald E. Clemons, MC, USA; Maj Wallace N. Weber, MC, USA

• The four male patients with multiple hamartoma syndrome (Cowden's disease) in this report, have most of the previously reported findings associated with this syndrome and several important unreported findings that include multiple cutaneous trichilemmomas, cafe-au-lait spots, cutaneous squamous cell carcinoma, pathologic fracture, craniomegaly, probable malignant lung tumor, retinal glioma, drusens of the optic disk and retina, pseudotumor cerebri, mediastinal mass, and multiple small papillomatous lesions of the esophagus, stomach, and duodenum.

(*Arch Dermatol* 114:743-746, 1978)

In 1963, Lloyd and Dennis reported the case of a patient with a combination of ectodermal, mesodermal, and endodermal anomalies that did not fit into any acceptable disease category. They proposed the new classification of Cowden's syndrome, which was named after the propositus. This was later amended to multiple hamartoma syndrome by Weary et al, and to date 17 cases of this syndrome have been reported.[1-7]

Recognition of this syndrome is based on the characteristic mucocutaneous findings that include cobblestoning of the oral mucosa and gingiva and verrucous hyperkeratotic papules occurring on the face and acral extremities. It is important to recognize this syndrome because of the high prevalence of associated malignancies and hamartomas of other organ systems.

REPORT OF CASES

Case 1.—A 27-year-old man was initially seen with a 14-year history of multiple asymptomatic subcutaneous tumors and multiple hyperkeratotic papules of the face, trunk, and extremities. There was no family history of similar problems. His mother, father, and sister were examined and there was no evidence suggesting Cowden's syndrome. Previous excisional biopsy specimens from other hospitals were reported as eosinophilic granuloma from a mass of the forearm, keratoacanthoma from the dorsum of the left hand, inverted squamous papilloma of the nose, squamous papilloma of the left cheek, and giant pore of the right ear lobe.

Physical examination showed adenoid facies (Fig 1) and multiple hyperkeratotic verrucous and smooth papular cutaneous lesions that were most prominent on the face and distal upper extremities (Fig 2 and 3). These lesions varied in diameter from 0.1 to 1.0 cm. Several of the larger lesions were extremely hyperkeratotic and resembled cutaneous horns (Fig 4). Punctate waxy papules were noted on the palms and soles. The gingival, buccal, and lingual mucosa had a striking cobblestone appearance (Fig 5). Small skin tags were present on the lateral portion of the neck and cafe-au-lait spots were noted on the left shoulder (4 × 7 cm) (Fig 6) and on the right forearm (2 × 4 cm). A poorly defined tender soft-tissue mass (16 × 10 cm) was present on the volar aspect of the left forearm (Fig 7). Smaller nontender subcutaneous soft-tissue masses were noted on the dorsal aspect of the left forearm, the left thenar eminence, and the abdominal wall.

Results of a complete blood count (CBC), urinalysis, 18-channel chemical battery (SMA-18), rapid plasma reagent test, and chest roentgenogram were normal. Roentgenograms of the left forearm showed a soft-tissue mass with no underlying bony abnormality and the left thumb view showed a soft swelling with underlying periosteal reaction. Upper gastrointestinal tract roentgenographic series showed a small sliding hiatal hernia without reflux. Endoscopy revealed multiple, small, smooth-surfaced, mucosal elevations of the esophagus (Fig 8), stomach, and duodenal bulb as well as adenomatous polyps of the gastric antrum. The nasopharynx and larynx were shown to be normal by indirect laryngoscopy. Results of Weber-Rene, Schwaback, and caloric tests showed normal eighth-nerve function. Results of thyroid scan, bone survey, barium enema, EEG, psychometric, and IQ testing were normal.

Biopsy specimens of lesions in various locations showed: fibrovascular hamartoma of the left forearm, lipoma of abdominal wall, focal acanthosis of the gingiva, polyp of the gastric antrum, normal mucosa of the esophagus, cutaneous horn of the left hand, skin tag of the right side of the neck, and squamous papilloma of the upper lip.

Case 2.—A 58-year-old man, the father of cases 3 and 4, had noted asymptomatic verrucous lesions of the face and hands since the age of 25. Historically, no other family members had any manifestations of Cowden's syndrome. They were not available for clinical examination. Previous skin biopsy specimens were reported as dermatofibroma, seborrheic keratosis, squamous cell carcinoma, hemangioma, pyogenic granuloma, skin tags, and verrucous papillomas. At age 34, a 3 × 5-cm mass was removed from between the middle and lower lobes of the right lung. This tumor was unusual histologically. Reviewing pathologists have differed in their diagnosis. Diagnoses included a reactive inflammatory lesion and an unusual hamartoma, but most pathologists favored the diagnosis of a low-grade adenocarcinoma.

Physical examination showed small hyperkeratotic lesions over the face, ears (Fig 9), and upper extremities. The axillary skin was minimally thickened, suggesting acanthosis nigricans. Dupuytren's contracture, varicocele, a right deltoid mass consistent with lipoma, and numerous cherry hemangiomas were noted. The labial, buccal, and gingival mucosa had a cobblestone appearance.

Review of cutaneous biopsy specimens showed multiple trichilemmomas (Fig 10).

Case 3.—The 24-year-old son of case 2 had craniomegaly at birth and has had metopic cranial sutures repeatedly. Subcutaneous lipomas were excised at age 2 and 14. He sustained a pathologic fracture through a bone cyst in the proximal right fibula at age 11. At age 13, an arteriovenous fistula was excised from the fifth finger of the right hand, and a neuroma was excised from the right clavicular area. A hemangioma was excised from the left occipital area at age 14. At age 15, right-sided intention tremors were noted. He was hospitalized at age 16 for pseudotumor cerebri; an EEG was abnormal with biparietal and occipital sharp waves. Although the patient did graduate from high school, he experienced some scholastic difficulty that necessitated his repeating the sixth grade.

Physical examination showed hyperkeratotic papules on the extremities and punctate waxy keratosis on the palms and soles. Retinal and optic nerve drusens were seen in both eyes. A hamartoma, most probably a glioma, was seen on the inferior nasal aspect of the retina of the right eye (Fig 11). He has lost his military dependent status, so no further evaluation of his condition has been possible.

Case 4.—The 13-year-old son of case 2 was born by cesarean section of his 41-year-old mother. He had respiratory distress and physiologic jaundice of the newborn, both of which cleared spontaneously.

Physical examination showed his condition to be normal at age 13 days. Truncal lipomas were noted at age 4. During early childhood, he had symptoms of atopy manifested by conjunctivitis and eczema. A

Accepted for publication Dec 21, 1977.

From the Dermatology Service, Fitzsimons Army Medical Center, Denver. Dr Clemons is now with Second General Hospital, New York, and Dr Weber is now with Munson Army Hospital, Fort Leavenworth, Kan. Dr Nuss is in private practice.

The opinions or assertions contained herein are the private views of the authors and are not to be construed as official or as reflecting the views of the Department of the Army or the Department of Defense.

Reprint requests to Dermatology Service, Fitzsimons Army Medical Center, Denver, CO 80240 (Dr Aeling).

Fig 1

Fig 2

Fig 3

Fig 4

Fig 5

Fig 6

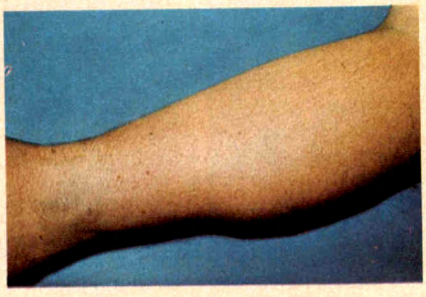

Fig 7

Fig 8

Fig 9

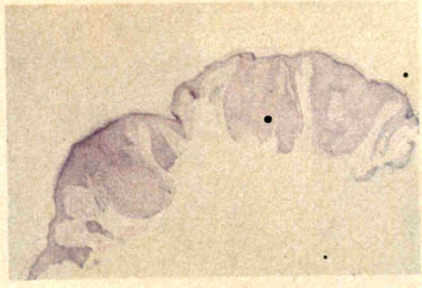

Fig 10

Fig 11

Fig 12

Fig 1.—Mildly adenoid facies and multiple small facial papules, case 1.

Fig 2.—Close-up of facial papules, case 1.

Fig 3.—Hyperkeratotic lesions on dorsum of hand, case 1.

Fig 4.—Cutaneous horn, case 1.

Fig 5.—Cobblestone mucosa of lower lip, case 1.

Fig 6.—Cafe-au-lait spot on left shoulder, case 1.

Fig 7.—Large soft-tissue tumor on left forearm, case 1.

Fig 8.—Small esophageal mucosal lesions, case 1.

Fig 9.—Small hyperkeratotic postauricular lesions, case 2.

Fig 10.—Multiple trichilemmomas from posterior auricular skin biopsy specimen, case 2 (hematoxylin-eosin, ×4).

Fig 11.—Retinal glioma, case 3.

Fig 12.—Bone cyst of tibia, case 4.

paraspinous stripe was noted on chest x-ray film at age 12. Review of previous roentgenograms confirmed a widening of the right posterior mediastinum since age 7. Serial chest roentgenograms have shown no major change.

Physical examination showed verrucous, papular skin lesions predominantly on the extensor aspects of the extremities. There was a 2 × 5-cm cafe-au-lait spot on the right lower portion of the abdomen; the gingival mucosa had a cobblestone appearance. The palms and soles were hyperkeratotic with increased markings and a few waxy punctate papules. There was a 1 × 1-cm mass in the right lower pole of the thyroid gland. A 0.5 × 1.0-cm subcutaneous mass was noted on the dorsum of the right foot.

Results of the following laboratory examinations were normal: CBC, urinalysis, serum catecholamines, SMA-18, and barium swallow. A long bone survey revealed a cyst in the right tibia (Fig 12) and in one vertebral body.

COMMENT

Table 1 lists all of the previously reported abnormalities.[1-7] Ten of the 17 cases appear to have an autosomal dominant inheritance pattern.[1-7] Six patients are men and 11 are women.

The characteristic mucocutaneous lesions that should lead the physician to suspect the diagnosis of this syndrome include smooth or verrucous hyperkeratotic papular lesions that are most prominent on the midface and acral extremities and papular lesions of the oral mucosa, often with a cobblestone appearance.

The diagnosis is confirmed if these

Table 1.—Abnormalities Associated With Multiple Hamartoma Syndrome

Abnormalities	No. of Cases Previously Reported	No. of Cases, Present Study	Total
General			
Unusual facies, predominantly adenoid	4	1	5
Skin			
Multiple hyperkeratotic verrucous papular lesions with acral distribution	16	4	20
Punctate keratoderma of palms and soles	3	4	7
Thyroglossal duct cyst	1	0	1
Malignant melanoma	1	0	1
Vitiligo	1	0	1
Pseudoacanthosis nigricans	1	1	2
Necrobiosis lipoidica diabeticorum	1	0	1
Facial hypertrichosis	1	0	1
Dermal fibroma	2	2	4
Multiple smooth papular lesions, predominantly face	9	1	10
Trichilemmoma	1	1	2
Musculoskeletal			
Scoliosis	2	0	2
Pectus excavatum	2	0	2
Bone cysts	2	2	4
Supernumerary digits	1	0	1
High arched palate	6	0	6
Herniated nucleus pulposus	1	0	1
Bilateral tarus mandibularis	2	0	2
Soft tissue			
Lipoma	7	3	10
Hemangioma	3	3	6
Respiratory			
Laryngeal papules	1	0	1
Oral mucosa			
Multiple papules, many with cobblestone appearance	12	3	15
Enlarged tongue	4	0	4
Gastrointestinal			
Polyps of colon	3	1	4
Polyps of stomach	1	0	1
Adenocarcinoma of colon	1	0	1
Epithelioid leiomyoma of sigmoid colon	1	0	1
Cholecystitis	2	0	2
Hepatic hamartoma	1	0	1
Diverticulitis	1	0	1
Breast, female			
Fibrocystic disease	8	0	8
Carcinoma	4	0	4
Breast, male			
Gynecomastia	1	0	1
Reproductive system, female			
Menstrual irregularities	3	0	3
Ovarian cyst	2	0	2
Retroverted uterus	1	0	1
Abortion	1	0	1
Gartner's duct cyst, vagina	1	0	1
Uterus leiomyoma	1	0	1
Reproductive system, male			
Hydrocele	1	0	1
Thyroid			
Goiter, adenoma	8	1	9
Carcinoma	3	0	3
Thyroiditis	3	0	3
Hyperthyroid	1	0	1
Eye			
Glaucoma	1	0	1
Cataracts	2	0	2

Table 1.—Abnormalities Associated With Multiple Hamartoma Syndrome—continued

Abnormalities	No. of Cases Previously Reported	No. of Cases, Present Study	Total
Nervous system			
Neuroma	7	1	8
Intention tremor	1	1	2
EEG abnormality	1	1	2
Meningioma	1	0	1
Hearing loss	2	0	2
Subarachnoid hemorrhage	1	0	1
Cardiovascular			
Atrial septal defects	1	0	1
Arteriovenous malformations	2	1	3
Mitral insufficiency	1	0	1
Aortic stenosis	1	0	1
Cardiopulmonary problem	1	0	1
Hypertension	1	0	1
Metabolic			
Diabetes mellitus	3	0	3
Hyperlipemia	1	0	1

Table 2.—Previously Unreported Abnormalities Seen in our Patients

Abnormalities	No. of Patients	Case No.
Cafe-au-lait spots	2	1 and 4
Pyogenic granuloma	1	2
Squamous cell carcinoma, cutaneous	1	2
Pathologic bone fracture	1	3
Craniomegaly	1	3
Dupuytren's contracture	1	2
Lung tumor	1	2
Papillomatous hamartomas of esophagus, duodenum, and stomach	1	1
Varicocele	1	2
Retinal glioma	1	3
Drusen tumor, eye	1	3
Pseudotumor cerebri	1	3
Atopy	1	4
Mediastinal mass	1	4

characteristic cutaneous lesions are associated with hamartomas of multiple organ systems. The most commonly associated hamartomas are: lipomas, hemangiomas, fibrocystic disease of the breast, thyroid adenomas, and neuromas. Many other abnormalities and disease processes have been reported.

It is important to recognize this syndrome because of the high prevalence of associated malignancies: breast cancer (four), thyroid carcinoma (three), colon carcinoma (one), and melanoma (one). It appears that the malignant potential is very high in women. Six of the ten reported cases of women had a carcinoma of the breast, thyroid, or colon, and another had atypical fibrocystic disease suggestive of in-situ lobular carcinoma.[6] The first patient, a 20-year-old woman, had two carcinomas, breast and thyroid.[1] Another woman had two breast carcinomas and a carcinoma of the cecum.[4] The only reported malignancy in a man is a melanoma.[5]

Noteworthy new pathologic abnormalities in our four patients are listed in Table 2. The papillomatous lesions of the esophagus and duodenum (case 1) are similar to the previously described papular cobblestone appearance of the oral mucosa. The lung tumor (case 2) is histologically a pleomorphic atypical malignant lesion for which no specific diagnosis has been made. The squamous cell carcinoma (case 2) is the first reported. Bone cysts have been reported,[1,6] but not with an associated pathologic fracture (case 3). Multiple nervous system abnormalities have been reported; pseudotumor cerebri, retinal glioma, and the drusen tumor of the eye (case 3) may be other manifestations. Case 4 had an undiagnosed posterior inferior mediastinal mass reported as a paraspinous stripe on a chest x-ray film. Lesions in this location commonly represent neural tumors. The pyogenic granuloma, Dupuytren's contracture, varicocele, and atopy are probably coincidental.

We feel that the above findings most likely represent a further expression of this syndrome. However, it is conceivable that some may be coincidental. As more cases of this syndrome are reported, a better understanding of the phenotypic findings in Cowden's disease will unfold.

Several similarities exist between Cowden's disease and neurocutaneous syndromes.[8] Two of our patients (cases 1 and 4) have cafe-au-lait spots greater than 1.5 cm in diameter. Cafe-au-lait spots represent a characteristic cutaneous marker of neurofibromatosis and are also seen in tuberous sclerosis and ataxia telangiectasia. One of our patients (case 3) had a retinal glioma; this lesion is found in all of the neurocutaneous syndromes. Bone cysts found in cases 3 and 4 are also reported in tuberous sclerosis and neurofibromatosis. Other neural tumors are quite common in patients with Cowden's disease. Including our patients, there have been eight neuromas reported. Mesodermal tumors are quite common in the neurocutaneous syndromes, including reports of renal angiomyolipomas and cardiac rhabdomyomas in patients with tuberous sclerosis; bony lesions are quite common in neurofibromatosis. To date, including our cases, there are ten lipomas, six hemangiomas, and one leiomyoma of the colon reported in Cowden's syndrome.

Cowden's disease is probably more common than previously thought and has an apparent dominant inheritance pattern and equal sex distribution. Multiple hamartoma syndrome is an appropriate name as multiple hamartomas have been reported. Certainly the lung tumor, papillomatous lesions of the esophagus and duodenum, and retinal glioma are new hamartomas of this syndrome. The drusens may be a manifestation of the syndrome, and also cafe-au-lait spots may represent another cutaneous manifestation of Cowden's disease. The case of trichilemmoma is the second reported.

Patients with Cowden's disease should be examined carefully for associated malignancies (particularly females for breast and thyroid carcinoma) and given appropriate genetic counseling.

Virginia Wekluk edited and typed this manuscript. William Gentry, MD, gave advice and reviewed this manuscript.

References

1. Lloyd KM, Dennis M: Cowden's disease: A possible new symptom complex with multiple system involvement. *Ann Intern Med* 58:136-142, 1963.
2. Weary PE, Gorlin RJ, Gentry WC Jr, et al: Multiple hamartoma syndrome (Cowden's disease). *Arch Dermatol* 106:682-690, 1972.
3. Gentry WC Jr, Eskritt NR, Gorlin RJ: Multiple hamartoma syndrome (Cowden disease). *Arch Dermatol* 109:521-525, 1974.
4. Burnett JW, Goldner R, Calton GJ: Cowden's disease: Report of two additional cases. *Br J Dermatol* 93:329-336, 1975.
5. Siegel JM: Cowden's disease: Report of a case with malignant melanoma. *Cutis* 16:255-258, 1975.
6. Gentry WC, Reed WB, Siegel JM: Cowden disease: *Birth Defects* 11:137-141, 1975.
7. Greer RO Jr, Popper HA, Demento FJ: Cowden's disease (multiple hamartoma syndrome). *J Periodontal* 47:531-534, 1976.
8. Adams RD, Reed WB: Cutaneous manifestations of diseases in other organ systems, in Fitzpatrick TB, Arndt KA, Clark WA, et al (eds): *Dermatology in General Medicine*. New York, McGraw-Hill Book Co, 1971, pp 1379-1434.

The Epidemiology of Scabies in Denmark, 1900 to 1975

Jette Christophersen, MD

• Denmark is the only country in which scabies has been reported for many decades. The present study is based on 850,629 cases reported between 1900 and 1975. The incidence of scabies showed pronounced peaks around 1918 and 1945. Since the end of the 1960s, a new increase in incidence has been observed. The rates were high and rather uniform among infants, children, and young adults. Before puberty, the rate for girls was on an average 1.4 times higher than for boys.

Scabies showed the same incidence in the capital as in the provinces, and marked seasonal variations occurred, with a winter maximum and a summer minimum.

No single factor could be identified to explain the cyclic occurrence in time, the sex and age pattern, and the seasonal variation. These patterns probably have a multifactorial genesis!

(*Arch Dermatol* 114:747-750, 1978)

Scabies occurs all over the world and in all age groups. In the course of time, it has appeared with varying incidence, and epidemics have been observed at 30-year intervals. Our knowledge of the epidemiology of the disease is fragmentary, based on studies of patients referred to hospitals or dermatological clinics.

Few countries have an obligatory nationwide reporting system of scabies[1]; only one country, Denmark, has used such a system over a period of many decades.[2] The present article reviews the epidemiology of the disease since 1900, with particular emphasis on variations in time, age, and sex.

MATERIALS AND METHODS

Reporting System

Since 1888, all general practitioners, specialists, and medical officers in the armed forces have been obliged to report the diagnosed cases of scabies on the weekly reports to the National Health Service. These reports are sent first to the district Medical Officer of Health who, in turn, submits them to the Department of Medical Statistics of the National Health Service where they are examined. The data are published annually in the *Medical Reports for Denmark*.[3]

Period and Groups

The study is based on the total number of cases reported in Denmark during the years 1900 to 1975, excluding Greenland and the Faroe Islands. Throughout this period, the population grew from 2.4 million to 5.0 million. For the years 1938 to 1942, data are only available for Copenhagen, and the curve for all Denmark for these years (Fig 1) is based on the figures for Copenhagen.

The number of cases diagnosed for each month of the year is known from 1899 to 1908 and since 1943. The distribution of the cases by age and sex has been given since 1943; a detailed age grouping was first available in 1963.

The Table summarizes the case material. The number of reported cases has varied between 37,000 and 361,000 during the different decades.

Incidence

The incidence of scabies is calculated from the reported number of cases within one year and the size of the general population. The rates by age, sex, and residence have been calculated on the basis of a corresponding numerator and denominator.

The population figures in the different years have been based on the five-year census; since 1968, the population figures have been published annually by the Central Population Register.

RESULTS

Figure 1 shows the incidence of scabies, year by year, for all of Denmark. The curve had an irregular course. Two pronounced peaks were observed around 1918 and 1945, when the rates were seven cases and 17 cases per 1,000 population; between these years, the rate was around two cases per 1,000. After World War II, the rate dropped to 0.5 per 1,000; it started to increase in 1968 and, in 1975, reached a level of two per 1,000, the same as at the turn of the century.

To examine whether the incidence was different between the capital and the provinces, the rates have been compared for the two regions for the period 1963 to 1974. No systematic difference was observed (Fig 2).

Figure 3 shows the incidence according to age and sex for two periods, 1963 to 1969 and 1970 to 1975. The rates are more or less the same for infants, preschool children, school children, and young adults (15 to 44 years old). The rate then fell and reached a minimum in old age. The age patterns were rather uniform in the two periods apart from the level, which was considerably higher in 1970 to 1975. In the groups over 65 years of age, no increase in the incidence level was observed.

Figure 4 shows a systematic difference in the rates for boys and girls from birth up to puberty; the rate in girls was, on the average, 1.4 times higher. The difference then disappeared; it was not possible to pinpoint

•Accepted for publication Dec 21, 1977.

From the Dermatological Department, Københavns Amts Sygehus in Gentofte, Denmark, and the Danish Institute for Clinical Epidemiology, Copenhagen.

Reprint requests to The Danish Institute for Clinical Epidemiology, 25, Svanemøllevej, DK-2100 Copenhagen Ø, Denmark (Dr Christophersen).

the exact age at which this happened because the first adult age group covered a broad interval (15 to 44 years). The time trend was the same for men and women. Among children and young adults, the rate was high in the beginning of the 1960s; it fell to a minimum and then increased steadily. The rates among the middle-aged and old persons were constant over the period.

Figure 5 shows the number of cases reported during each month of the year; curves are given for two periods—1899 to 1908 and 1960 to 1969. The course of the curves was the same in the two periods. They showed a sine-shaped form with a maximum in the winter months (November to February) and a minimum in the summer months (May to August).

COMMENT

The present article is based on the medical reports of the patients who saw a physician for treatment. Hence, the material will suffer from deficits in the reporting system itself and from deficits by undiagnosed cases and patients treating themselves with ointment purchased without a prescription "over the counter."

It is often claimed that the data obtained from the weekly reports from the physicians to the National Health Service are incomplete. However, a special study[4] showed that there was good agreement between the number of patients visiting the physicians and the reported number of cases. The scabies notification is "disease-recording," ie, every case of the disease is reported. This fact might bias the incidence; if a person has several attacks in the course of one year, that person will be included that number of times in the numerator, but only once in the denominator. This error is hardly of significance, as relapsing of scabies within one year is rare.[5]

Normally, scabies causes such intense itching that the patient has to seek a physician's help. There are, admittedly, some patients who do not develop itching in spite of pronounced exanthema, but they are rare.[5] Most of the scabies patients' contacts are treated without being examined for the disease. Among these contacts, therefore, there are cases that are not diagnosed and not reported. The number of such cases will probably vary in proportion to the number of recognized cases. Thus, this deficit has had the same effect throughout the years covered by the study.

Throughout the period 1900 to 1975,

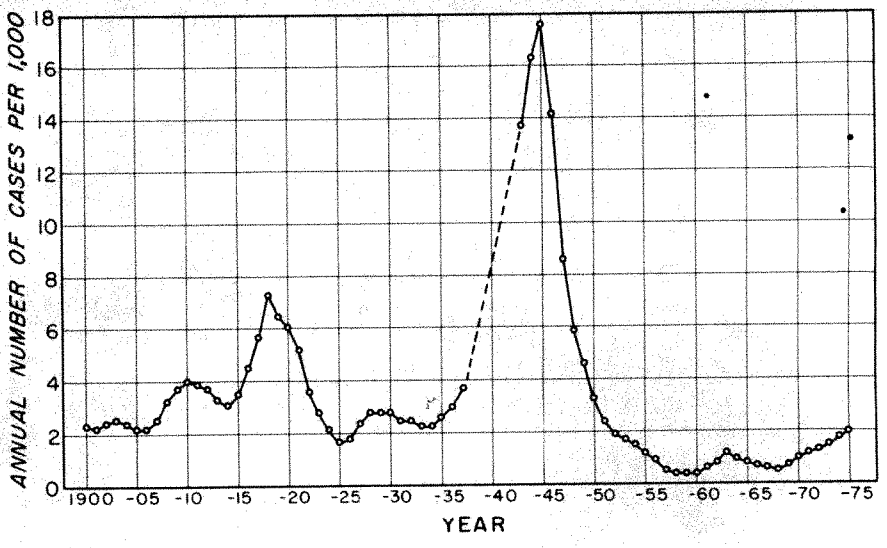

Fig 1.—Incidence of scabies in Denmark, 1900 to 1975.

Reported Cases of Scabies in Danish Male and Female Subjects, 1900 to 1975

	No. of Cases						
	Age, yr						
Period	0	1-6	7-14	15-44	45-64	65+	Total
1900-1901	65,452						65,452
1910-1919	131,924						131,924
1920-1929	104,339						104,339
1930-1937	79,050						79,050
1943-1952	4,072	108,951		244,812		3,432	361,267
1953-1962	471	12,472		24,570		408	37,921
1963-1975	1,344	9,618	11,174	43,354	4,317	869	70,676

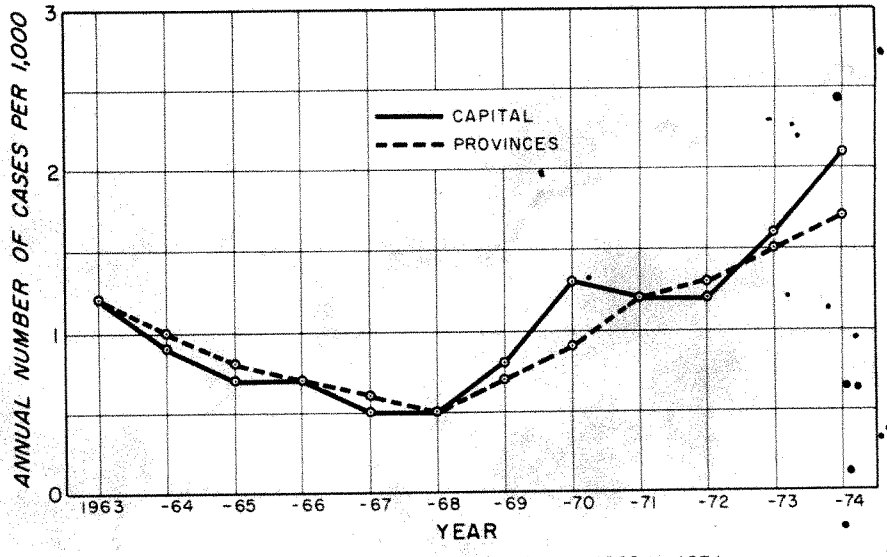

Fig 2.—Incidence of scabies in the capital and provinces, 1963 to 1974.

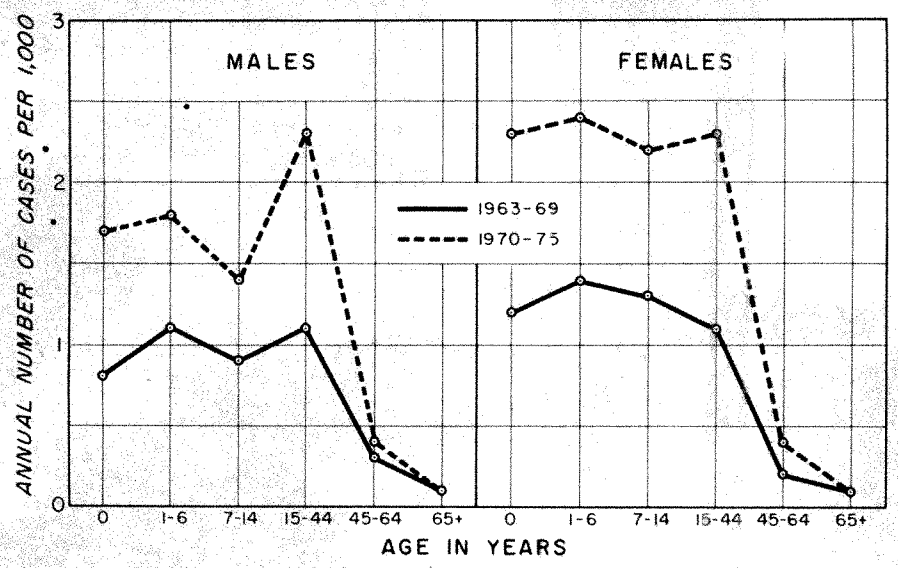

Fig 3.—Age pattern of scabies, 1963 to 1969 and 1970 to 1975.

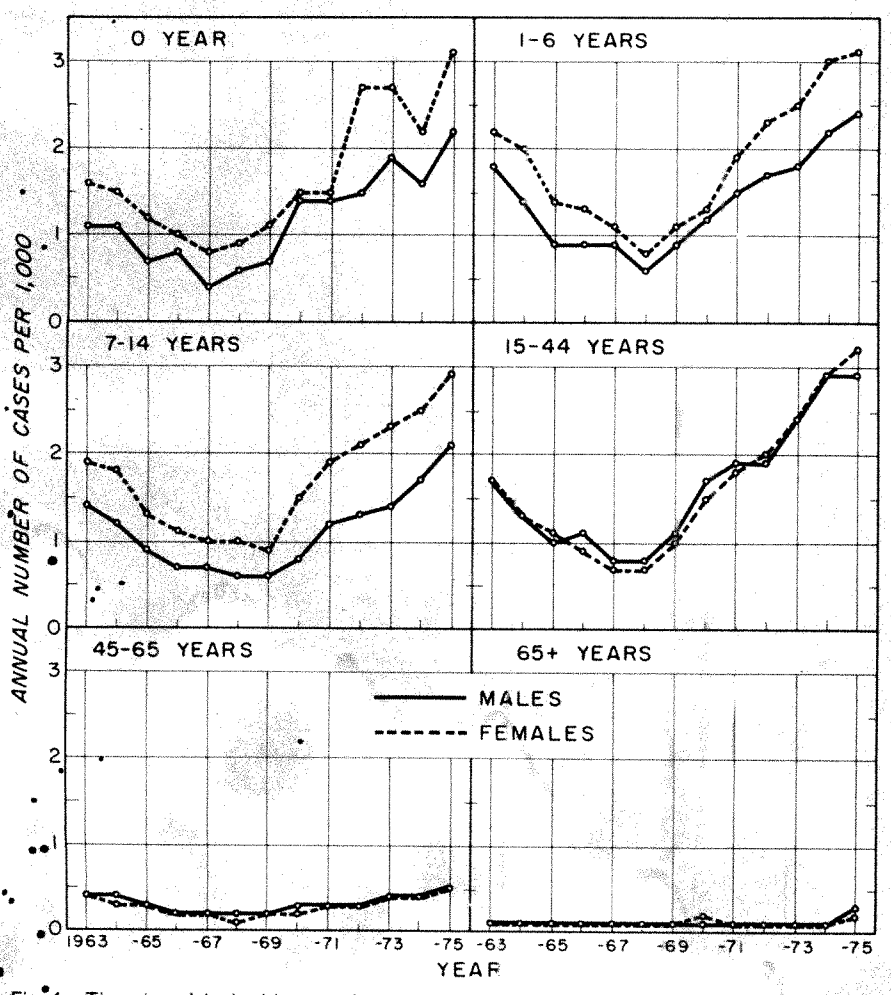

Fig 4.—Time trend in incidence of scabies by sex and age, all of Denmark, 1963 to 1975.

scabies ointment could be purchased without prescription over the counter; however, an inquiry among chemists in 1976 showed that this sale was negligible. The reason for the low volume of over-the-counter sales is twofold: (1) there is easy access to free medical service in Denmark and (2) the patient is reimbursed by the national compulsory insurance when a prescription is presented. Additionally, chemists are obliged to instruct scabies patients to obtain medical treatment, since the disease is reportable.

In sum, it may be concluded that the number of reported cases is a reliable expression of the actual number of cases.

The incidence of scabies during the period 1900 to 1975 presents two striking facts: First, the rate in 1975 was almost the same as the rate at the turn of the century; a significant lower incidence was expected in view of the considerable improvement that has taken place in the population's general state of health and standard of living since 1900. For example, the life expectancy has increased in all age groups, children, middle aged, and old persons, and the mortality from acute and chronic epidemic diseases has almost been eliminated.[6] Second, the two major peaks in the scabies incidence curve abated at the time when World War I and II ended. This fact suggests that the wars were a major cause for the epidemics. However, it should be noted that the peaks started before the World Wars began; that a decline in the case load was also reported in the countries that were neutral during World War II[7]; and, third, that a worldwide increase in scabies has been reported during the past decade in which no war scourged the whole world.[8-9]

The upward trend of scabies in Denmark during the past eight years is modest compared with the wartime periods. Since the epidemics generally have lasted about 15 years, with the peak around midperiod, the present outbreak can be characterized as a minor one; in fact, the data for 1976 (9,375 cases corresponding to 1.9 per 1,000) indicates that the decline in the curve has begun. It would be of great interest to document if the worldwide epidemic resurgence of scabies is of the same minor character as the Danish one. Unfortunately, incidence data based on a well-defined background population are lacking. Hence, comparisons with the results of the present work are not possible.

During an infection with scabies

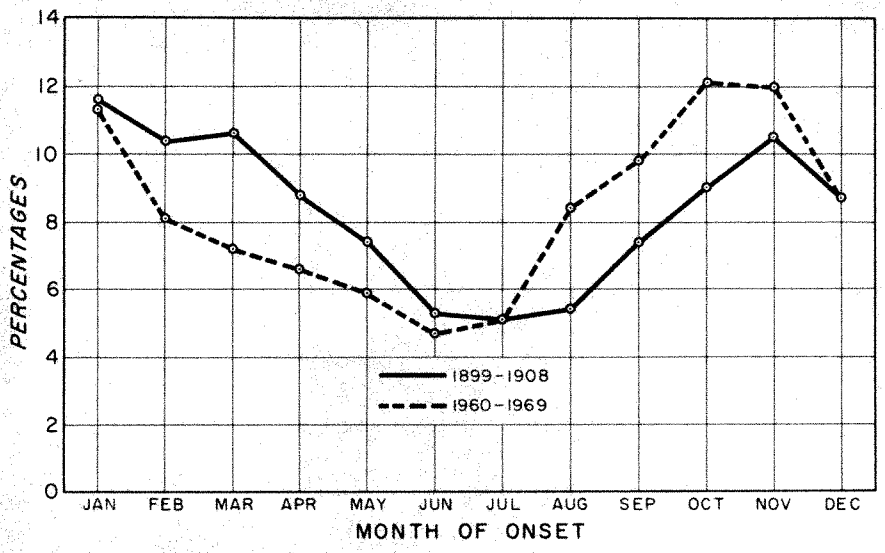

Fig 5.—Cases of scabies distributed by month of onset, all of Denmark.

mites, most patients develop some degree of delayed hypersensitivity and a partial immunity to reinfection; if reinfection occurs, an accelerated reaction is provoked.[5] Based on these observations, theories on "herd immunity" in the population have been launched to explain the cyclic occurrence of scabies by time, especially the outbreaks of major epidemics at an interval of 25 to 30 years.[5-10] If this were the case, however, fluctuations at intervals of about 60 years would be expected. The major epidemics themselves last for about 15 years, and it takes about 45 years to build up a nonsensitized population. The estimate of 45 years, quoted here, is based on the observations in the study that showed that the rate of scabies in the population is uniform in all age groups up to 45 years.

Previous studies state that scabies is most common among the young.[10-11] These studies are based on patient material collected from dermatological departments. As the population background is not known, the age-incidence could neither be calculated nor estimated. This procedure was, however, possible in the present study. Roughly speaking, the incidence in the age group 15 to 44 years was the same as among infants and children; this finding as well as the fact that reinfections do occur[12] militates against the existence of a specific, lifelong immunity. If acquired immunity had played a significant role, a high rate of infection should have been expected in children and a low rate should have been expected in adults—the pattern observed in many other infectious diseases. The cause of the cyclic fluctuations in scabies prevalence seems just as obscure as in other diseases with a periodic occurrence.

As scabies almost always results from intimate contact between persons, there was an obvious need to compare its epidemiology with that of venereal diseases. Comparison with the incidence of gonorrhea showed agreement in one aspect—the rate in the 1970s was almost the same as at the beginning of the century. In the intervening years, however, the incidence of gonorrhea has fluctuated with peaks at 15-year intervals.[3] These peaks have, therefore, been more frequent and did not coincide with those of scabies. The seasonal variations of gonorrhea also are different: gonorrhea reaches its maximum incidence during summer and minimum during winter.[11] Finally, the two diseases show different age patterns. Gonorrhea shows a maximum morbidity after puberty,[13] while scabies shows high rates in infants, children, and young persons. However, the analysis is marred by the fact that it was not possible to subdivide the age group 15 to 44 years. It may well be that, in reality, the rate of scabies is higher for the 15 to 29-year-old group than for the 30 to 44-year-old group, such as clinical experience indicates.[10-11]

The higher rate of scabies in girls was striking, since boys are generally reported to be more susceptible to infectious diseases.[14] Previous studies explain this fact by behavioral factors; girls are claimed to share a bed more often than boys.[5] However, Fig 4 showed that the sex difference already was present in infancy; therefore, factors other than behavior must be sought.

The cyclic occurrence of scabies, its age and its sex pattern, apparently result from a multifactorial basis. Further research on the mode of infection and the immunology could be done by epidemiological procedures. A detailed reporting of each case with full demographic and clinical information, for example contacts and previous attacks, seems reasonable. Such research must be based on all cases diagnosed in a well-defined population during a given period of time. Based on such material, representing the entire spectrum of the disease, the development of immunity might be followed by repeated intracutaneous tests, just as allergy in tuberculosis can be studied by the Mantoux test. However, the difficulty in preparing a specific allergen[12] has still not been overcome.

References

1. *World Health Statistics Annual: Notifiable Diseases in Various Countries 1963.* Geneva, World Health Organization, 1967, vol 2, pp 222-239.
2. Johansson B: *Den danske sygdoms-og dodsarsagsstatistik.* Copenhagen, E Munksgaard, 1946.
3. *Medicinalberetning: Annual 1900-1975.* Copenhagen, Sundhedsstyrelsen, 1976.
4. Horwitz O, Grunfeld K, Lasgaard-Hansen B, et al: The epidemiology and nature history of measles in Denmark. *Am J Epidemiol* 100:136-149, 1974.
5. Mellanby K: *Scabies.* Hampton, Middlesex, England, EW Classey Ltd, 1972.
6. Horwitz O, Bach Pedersen E: *Dodelighed og sygelighed i den danske befolkning i perioden 1840-1972.* Copenhagen, Danish Institute for Clinical Epidemiology, 1976.
7. Epstein E: Incidence of scabies. *Dermatologica.* 110:126-132, 1955.
8. Orkin M: Resurgence of scabies. *JAMA* 217:593-597, 1971.
9. Orkin M: Today's scabies. *JAMA* 233:882-885, 1975.
10. Shrank AB, Alexander SL: Scabies: Another epidemic? *Br Med J* 1:669-671, 1967.
11. Hjorth N, Roed-Petersen J: Trends in the incidence of scabies and gonorrhoea in denmark, in Orkin M, Maibach HI (eds): *Scabies and Pediculosis.* Philadelphia, JB Lippincott Co, 1977, pp 73-77.
12. Heilesen B: Studies on *Acarus scabiei* and scabies. *Acta Derm Venereol* 26(suppl 14):370, 1946.
13. Lind I: Incidence of gonorrhoea in Denmark, 1957-1971. *Br J Vener Dis* 49:454-459, 1973.
14. Bonnevie P: *Hygiejne: Praeventic of social-medicin.* Copenhagen, Nordisk Forlag, 1974.

Tumbleweed Dermatitis

Ralph F. Powell, MD, Edgar B. Smith, MD

• Russian thistle (*Salsola kali*), the most common plant referred to as "tumbleweed" in the western United States, can cause a dermatitis in persons who come into direct contact with it. Tests were conducted to determine the mechanism of this dermatitis. Mechanical contact with plant branches, as well as scratch, patch, and photopatch tests with Russian thistle extract and scratch tests with 1.5% potassium nitrate, a plant constituent, were employed. These tests, along with transparent adhesive tape preparations and a skin biopsy, showed that in nonsensitized persons, dermatitis was due only to mechanical irritation of plant floral bracts. In sensitized individuals, Russian thistle floral bracts pierced the skin and stimulated an urticarial reaction.

(*Arch Dermatol* 114:751-754, 1978)

Tumbleweeds are globular plants, which on withering in the autumn, break away from their roots and are driven about by the wind. They frequently occur in arid regions, especially in the western United States, where they are found along roadsides, in waste places, and on cultivated ground. One of the most common of a number of species known as "tumbleweeds" is the Russian thistle (*Salsola kali, S pestifer*) (Fig 1).[1] Frequently, we have heard complaints of itching and burning from persons who work in their yards or in the fields where they remove these weeds. The pruritus occurs on those portions of the body, which have actually come into contact with the weed, usually the hands, arms, and legs. After seeing several patients with this problem, we became interested in the mechanism of the dermatitis caused by tumbleweeds. Because of the widespread distribution of these plants, we wish to describe the skin condition produced by Russian thistle and our findings regarding its mechanism.

Accepted for publication Jan 20, 1978.

From the Veterans Administration Hospital and Division of Dermatology, University of New Mexico School of Medicine, Albuquerque.

Reprint requests to Division of Dermatology, University of New Mexico School of Medicine, Albuquerque, NM 87131 (Dr Smith).

REPORT OF CASES

Case 1.—A 28-year-old woman worked in her yard for several hours and removed tumbleweeds. Within an hour after exposure, she noticed pruritic red papules that were scattered over her wrists and forearms. Papules and small wheals were present on areas that had come directly into contact with the weeds. No plant spines were puncturing the skin. Eyelids, face, and neck were spared. The rash resolved in several days with cool compresses and application of 0.05% flurandrenolide cream three times daily. The patient reported a similar pruritic eruption to have occurred repeatedly on her legs as a child after bicycling through patches of tumbleweeds. She has hay fever every spring.

Case 2.—After exposure to tumbleweeds, a 74-year-old woman noted red, hard bumps on her legs and forearms, which felt like "needles sticking beneath the skin." Green weeds reportedly caused more trouble than dried ones. Her skin remained itchy for several weeks, and at the time of examination, she had eczematous plaques over the legs and forearms. Treatment with an emollient and 0.05% flurandrenolide cream three times daily and avoidance of tumbleweeds cleared the rash in three weeks. She had a past history of hay fever between the months of June and September.

MATERIALS AND METHODS

Volunteers with and without a history of a rash similar to those of the previously described patients were obtained. All testing was performed with the informed consent of each subject. The character and severity of the rash when applicable and any history of allergic rhinitis were recorded. The forearms of each volunteer were rubbed for five minutes with branches of Russian thistle. Results were read immediately, and at eight, 24, and 48 hours, the presence of "scratches," papules, and/or wheals were noted. The site of any eruption was brushed free of any visible plant particles and stripped several times with transparent adhesive tape. The tape was then applied to a clear glass slide for microscopic examination. Scratch testing was performed with *S kali* extract dilution (1:20), a 1.5% solution of potassium nitrate (KNO_3), glycerin, saline solution, and histamine controls. Results were read after 20 minutes as follows: negative, no reaction; ±, erythema less than 10-mm diameter; 1+, erythema equal or greater than 10-mm diameter and no wheal; 2+, wheal with surrounding erythema; 3+, wheal less than 10-mm diameter with pseudopod; and 4+, wheal equal or greater than 10-mm diameter with pseudopod.

In selected subjects, we performed patch tests and photopatch tests to *S kali* extract. For photopatch testing, 0.1 ml of *S kali* extract was applied to duplicate sites on the intrascapular regions with the use of aluminum patches under nonallergenic tape. At 24 hours, one patch test site was irradiated with a hot quartz lamp for 20 minutes at 60 cm under window glass. Both patch test sites were examined at 48 and 72 hours. A 4-mm punch biopsy specimen of a typical urticarial lesion that was produced by stroking the forearm with a branch of Russian thistle was obtained one hour after onset of the rash. A hematoxylin-eosin preparation was examined under the light microscope with and without polarized light. Branches of the Russian thistle were observed under dissecting and scanning electron microscopes.

RESULTS

Thirteen patients were tested; the

Fig 1.—Russian thistle (*S kali*). Mature plant with globular form, prickly branches, and weedy habitus.

Test Results in 13 Subjects With or Without History of Rash Similar to Tumbleweed Dermatitis

	History			Lesions* and Reactions	
Subject	Rash After Contact With Tumbleweed	Urticaria on Contact With Tumbleweed	Hay Fever	Wheals	Scratch Tests With Plant Extract
1 (case 1)	Severe	Yes	Spring	Yes	4+
2 (case 2)	Severe	Yes	Summer	Yes	4+
3	Severe	Yes	Spring, summer	Yes	2+
4	Moderate	No	Spring	Yes	4+
5	Moderate	No	Spring, fall	Yes	3+
6	Moderate	No	Spring, summer	Yes	3+
7	Mild	No	Summer	Yes	2+
8	None	No	Summer, fall	Yes	2+
9	None	No	Summer	Yes	2+
10	Mild	No	Spring	No	0
11	None	No	No	No	2+
12	None	No	No	No	±
13	None	No	No	No	±

*Scratches and papules were produced in all 13 subjects.

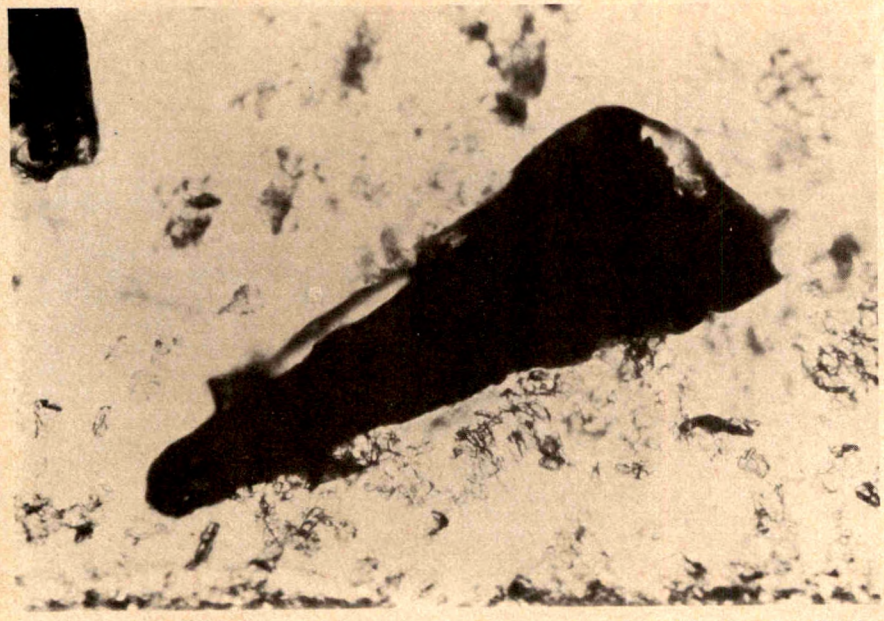

Fig 2.—Transparent adhesive tape preparation of rash produced by Russian thistle, showing wedge-shaped floral bract (original magnification, ×400).

results of these tests are summarized in the Table. In general, patients with a history of a moderate or severe rash after exposure to tumbleweeds, including some patients with wheals, had moderately to markedly positive reactions on scratch testing with Russian thistle extract, and when their forearms were rubbed with plant branches, a papular and urticarial rash was produced.

These patients had histories of hay fever in the summer or fall (the time of pollination by Russian thistle) or hay fever at other times. Subject 4 had a positive Russian thistle scratch test as a child but only recent, mild springtime hay fever (Table). The reactions of patients with no previous eruption or with a history of only a mild rash after weed exposure were negative or mildly reactive to scratch testing, and only "scratches" or red papules without wheals were produced after rubbing with branches. Allergic rhinitis was either not present or occurred at times other than summer or fall.

Wheals, when produced, subsided within four to 12 hours, while "scratches" and papules remained for 24 to 48 hours. We found Russian thistle spines on light microscopic examination of transparent adhesive tape skin strippings in eight of 13 subjects, including persons in whom wheals could not be produced by branch contact (Fig 2). Scratch tests with 1.5% KNO_3 were all negative or equivocal. Patch tests in ten patients and photopatch tests in four patients were uniformly negative. A biopsy specimen of a lesion produced by Russian thistle on subject 3 (Table) showed mild hyperkeratosis, spongiosis, and a perivascular infiltrate that consisted primarily of polymorphonuclear leukocytes with some eosinophils and was consistent with an allergic dermatitis (Fig 3). Polariscopic examination showed a doubly refractile, wedge-shaped foreign body that pierced the epidermis with surrounding hemorrhage. This was interpreted to be the tip of a Russian thistle floral bract. Examination of plant branches with dissecting and scanning electron microscopes did not show any dermatitis-producing organisms but did illustrate the sharp character of the floral bracts (Fig 4).

COMMENT

The Russian thistle or *S kali* belongs to the goosefoot family (Chenopodiaceae).[2] It is closely related to the lamb's quarter (*Chenopodium album*), the greasewood (*Atriplex canescens*), and to the true tumbleweed (*Cycloloma platphyllum*). It is more distantly related to the pigweeds (*Amaranthus* sp).[3] *Salsola kali* is common in Eurasia and native to Russia. The seeds of this plant were mixed with a small quantity of flax seed brought by some Russian immigrants to Bonhomme County, SD about 1873.[4] In the next 25 years, Russian thistle spread rapidly over a wide portion of the United States. When mature, the dry globe-shaped plant breaks off at the ground and rolls or tumbles with the wind, thereby sowing thousands of its seeds. Masses of these plants often pile up against fences, which limit their dispersion in the more urbanized eastern United States. The plant's rapid spread was partly due to trains that dragged the weeds along the

tracks to irrigation ditches, which facilitated the spread of seeds of mature plants growing on their banks, and to sacks of grain contaminated with tumbleweed seeds.[4,5]

The Russian thistle is an annual plant as are all tumbleweeds.[1] It occurs from July to October, mostly in noncultivated soil. The plants seem particularly adapted to bright sunlight and dry soil and are tolerant of alkali.[6] The water required for growth of Russian thistle was the lowest of the number of important weeds and plants studied in the northern Great Plains area.[7] These characteristics make Russian thistle common in regions of low rainfall, especially in the plains and western states where it occurs on rangeland and in waste areas. Both young and old plants are eaten by livestock.[8] The young plants have been mowed and used as emergency hay crop, while good ensilage can be made from mature plants that are otherwise unpalatable.[9] Young succulent plants are edible and can be prepared as a potherb ("greens"), such as one would prepare spinach.[10] They have served as part of the diet of the Navajo Indians.[11]

The Russian thistle is not a true thistle, and hence, its name is misleading.[5] The plant resembles a thistle only in being spiny. Each maturing branch contains many slender, spine-tipped true leaves, numerous compact, sharp floral bracts, and modified scale-like leaves, which envelop the plant's tiny flowers. The stem and main branches are often red-striped. Young plants are soft and succulent, while older plants are stiff and woody. The true leaves eventually fall off; their function is served by the bracts that remain behind. Each flower produces its seed, then increases in size, and ultimately becomes a wing or sail for the seed. Mature flowers with seeds that are enclosed are held within bracts by minute tufts of coiled hairs, which prevent the seeds from falling all at once when the plant begins to roll. At maturity, the plant forms a typical ball-like tumbleweed. Each rigid branch then possesses multitudes of flowers with seeds surrounded by wedge-shaped spiny bracts that account for the prickliness of these plants.[3,12] Figure 5 depicts many features of the Russian thistle.

The Russian thistle has been occasionally shown to contain toxic levels of nitrate.[13] Plants that contain more than 1.5% nitrate (as KNO_3, dry weight) may prove lethal to livestock. Sublethal nitrate poisoning may occur with concentrations of 0.5% to 1.5% KNO_3. A few cases of poisoning have been reported to the US Department of Agriculture.[14] In Australia, *Salsola* has been found to contain potentially lethal concentrations of soluble oxalates.[15] Several cases of poisoning of livestock have occurred in that country in which this plant was suspected.

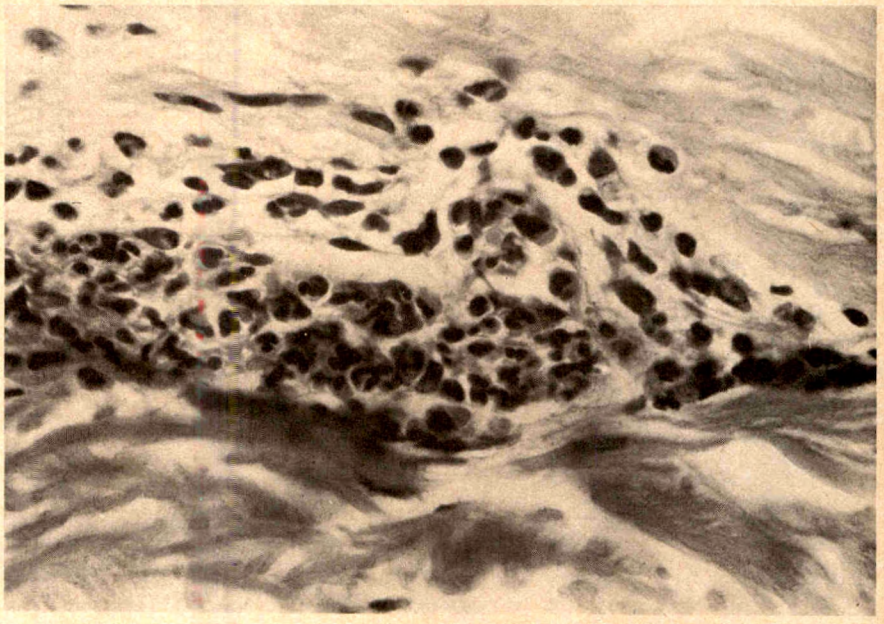

Fig 3.—Tumbleweed dermatitis at one hour. Perivascular infiltrate consisting of polymorphonuclear leukocytes with some eosinophils, which accompanied mild spongiosis and hyperkeratosis (hematoxylin-eosin, original magnification ×700).



Fig 4.—Russian thistle floral bract. Blunt bract tips shown are sharp to touch. No dermatitis-producing organisms were seen (gold-palladium, original magnification ×20).

The pollen of the Russian thistle is a common cause of allergic rhinitis occurring in the summer and fall months. Pollen grains are 20 to 30 μ in diameter and have a characteristic "golf ball" appearance due to multiple pores at their surface. These grains

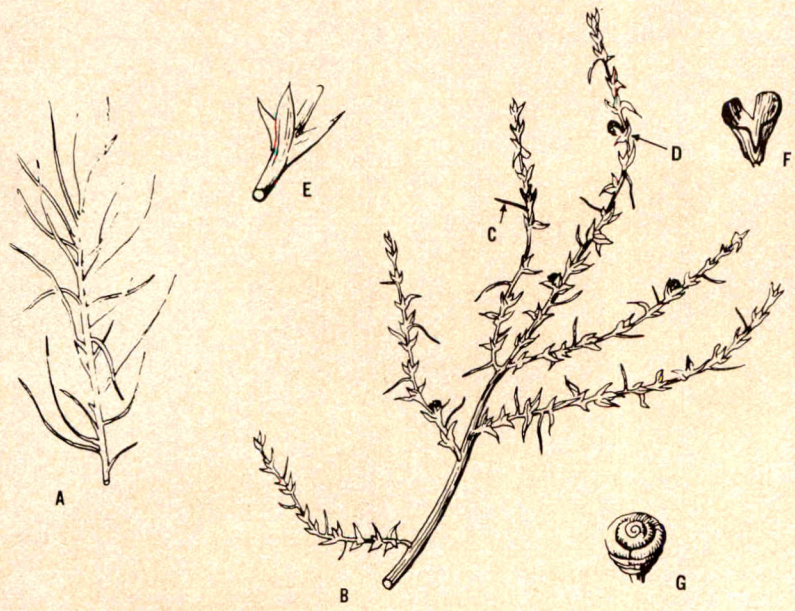

Fig 5.—Features of Russian thistle: (A) very early seedling—plants edible at this stage; (B) maturing branch with spiny appendages; (C) true leaf; (D) floral bract (modified leaf) with flower; (E) floral bract, enlarged; (F) flower, enlarged; and (G) seed, enlarged.

are of important allergenic significance in the western United States and of some significance in the midwestern states.[16]

In considering the mechanism of tumbleweed dermatitis, the prevalence of Russian thistle and lack of reports of contact dermatitis made a delayed contact sensitization unlikely, and our negative patch tests results substantiated this. Primary irritation from plant chemicals and KNO_3 was also excluded by the patch and scratch tests that were employed. Since Russian thistle is a member of the goosefoot family, some of which produce furocoumarins,[17] phytophotodermatitis was possible. However, the eruption was not worsened by light exposure, and photopatch tests were negative. Pseudophytophotodermatitis due to certain arthropods that infest the plants was deemed unlikely, and investigation revealed no organisms. Mechanical irritation certainly occurs and explains the mild eruption that develops on contact in many persons with Russian thistle. Allergic mechanisms apparently play a role in those cases that describe a more severe eruption. Those subjects tended to have markedly positive scratch tests to Russian thistle plant extract, history of allergic rhinitis at the time of pollination of Russian thistle, and the tendency to form papules and wheals after branch contact. While subjects 1 and 4 (Table) did not give histories of hay fever coincident with Russian thistle pollination, both had been exposed to the plant or its extract as children. We thought that these results support our hypothesis that, in sensitized individuals, tumbleweed dermatitis is in effect a "natural" scratch test produced by the Russian thistle; first, there is penetration of the skin by sharp floral bracts followed by wheal formation. Furthermore, we postulate that previous sensitization must occur from either past direct contact with the Russian thistle or from inhalation of weed pollens. This seems most consistent with the histories and test results we obtained. Further testing is needed to determine the exact antigen that produces the allergic response in tumbleweed dermatitis.

Treatment of the dermatitis that is produced by Russian thistle requires awareness of a patient's exposure to this weed, which a good history will provide.

The avoidance of direct contact with these plants is tantamont to its prevention and treatment. Protective clothing and gloves should be worn by gardeners. The city and state highway departments in the Southwest often employ various types of gas torches to destroy these plants without handling them directly. Treatment of eczema and secondary infection is with appropriate topical steroids, cultures, and antibiotics. Since the spines of the Russian thistle are located very superficially in the skin, they are usually removed by gentle scrubbing of the involved areas. Exfoliative agents are sometimes used to remove thorns from certain plants, which lodge in the epidermis,[18] but we have not found these necessary. Cool compresses and a steroid cream provide symptomatic relief, and the condition usually resolves within one to two days.

This investigation was supported, in part, by grants from the Allergy Foundation of America and the New Mexico Dermatology Foundation.

References

1. Nelson RA: *Handbook of Rocky Mountain Plants.* Tucson, Ariz, Dale Stewart King Publisher, 1969.
2. Isely D: *Weed Identification and Control.* Ames, Iowa, Iowa State University Press, 1960, p 50.
3. Wooton EO: The Russian thistle. *New Mexico Agric Exp Station Bull,* 1895, p 16.
4. Robbins WW, Crafts AS, Raynor RN: *Weed Control: A Textbook and Manual.* New York, McGraw-Hill Book Co Inc, 1952.
5. Georgia AE: *A Manual of Weeds.* New York, Macmillan Co, 1928, p 117.
6. Wooton EO, Standley PC: *Flora of New Mexico.* Washington, DC, US Government Printing Office, 1915.
7. King LJ: *Weeds of the World—Biology and Control.* New York, Interscience Publishers, 1966, p 181.
8. Steere WC (ed): *Wild Flowers of the United States.* New York, McGraw-Hill Book Co Inc, 1970, vol 4, pt 1, p 102.
9. Kearney JH, Peebles RH: *Arizona Flora.* Berkeley, Calif, University of California Press, 1951, p 264.
10. Harrington DD: *Edible Native Plants of the Rocky Mountains.* Albuquerque, NM, University of New Mexico Press, 1967, p 93.
11. Carpenter TM, Steggerda M: The food of the present-day Navajo Indian of New Mexico and Arizona. *J Nutr* 18:297-305, 1939.
12. Buckholtz KP, Grigsby BH, Lee OC, et al (eds): Weeds of the north central states. *University of Illinois Agric Exp Station Circular* No. 718, February 1954, p 47.
13. Kingsbury JM: *Poisonous Plants in the United States and Canada.* Englewood Cliffs, NJ, Prentice-Hall Inc, 1964, p 240.
14. Huffman WT, Moran EA, Binns W: *Poisonous Plants.* Washington, DC, USDA Yearbook of Agriculture, 1956, p 118.
15. Mathams RH, Sutherland AK: The oxalate content of some Queensland pasture plants. *Queensland J Agric Sci* 9:317, 1952.
16. Patterson R (ed): *Allergic Diseases Diagnosis and Management.* Philadelphia, JB Lippincott Co, 1972.
17. Fitzpatrick TB, Arndt KA, Clark WH, et al (eds): *Dermatology in General Medicine.* New York, McGraw-Hill Book Co Inc, 1971, p 1015.
18. Fisher AA: *Contact Dermatitis.* Philadelphia, Lea & Febiger, 1973, p 248.

Sister Chromatid Exchanges In Bloom's Syndrome

Charles H. Dicken, MD; Gordon Dewald, PhD; Hymie Gordon, MD

• The importance of chromosome instability in Bloom's syndrome is reviewed, and the recently developed technique for demonstrating sister chromatid exchanges (SCE) is described. In Bloom's syndrome, but not in other heritable syndromes associated with chromosome instability, there is a nine- to ten-fold increase in the frequency of spontaneous SCE. We present a case of Bloom's syndrome in which this test facilitated the diagnosis. In four obligate heterozygotes (the parents of children with Bloom's syndrome), however, an increase in the frequency of spontaneous SCE was not observed.

(*Arch Dermatol* 114:755-760, 1978)

In 1954, David Bloom[1] reported the first case of a syndrome that now appropriately carries his name. His subsequent experience enabled him to define the "cardinal" clinical features of this syndrome as congenital telangiectatic erythema, which occurs mainly on the butterfly area of the face, sensitivity of the skin lesions to sunlight, and growth retardation.[2] Other less consistent developmental anomalies may be present, of which café au lait pigmentation and hypogonadism in males are the most common.[3]

In 1960, Dr Bloom requested a chromosome analysis be done for one of his patients, thus bringing this syndrome to the attention of James German.[3] The resulting collaboration between dermatologist and cytogeneticist has greatly expanded our knowledge of Bloom's syndrome and continues to generate new ideas about this syndrome and about some fundamental problems in human biology.

By 1965, the mendelian basis of Bloom's syndrome had been established.[4] In some families, more than one sibling was affected; several instances of consanguineous parentage were recorded; and about half of the known cases were in Ashkenazi Jews with recent ancestry in the central European area of western Poland and eastern Russia. These observations indicated the autosomal-recessive pattern of inheritance: patients with Bloom's syndrome are homozygous for a mutant autosomal gene with recessive effect.

At the same time, German et al[4] reported that these patients had abnormal chromosomal instability, which was characterized by chromosome breaks and rearrangements (acentrics, dicentrics, and so forth). Most of these anomalies are nonspecific, occurring in other mendelian syndromes (Fanconi's panmyelopathy and ataxia-telangiectasia) or after exposure to radiation, viruses, mycoplasmas, or cytotoxic chemicals; but one unusual anomaly, ie, the quadriradial configuration, is seen in almost all chromosome preparations from patients with Bloom's syndrome but is rarely seen in other persons. The quadriradial configuration results from the exchange of material between chromatids of homologous chromosomes (Fig 1A).

The importance of chromosome instability was amplified by the observation that patients with Bloom's syndrome have an increased risk for malignant disease, especially leukemia, lymphoma, and carcinoma of the alimentary tract. Among a cohort of 44 patients under German's surveillance, cancers have developed in eight patients, sometimes at an unusually

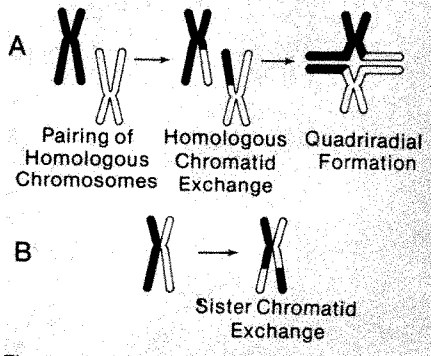

Fig 1.—A. Mechanism for production of quadriradial configuration by exchange of material between chromatids from homologous chromosomes. B. Sister chromatid exchange resulting from interchange of material from sister chromatids of one chromosome.

Accepted for publication June 20, 1977.

From the Departments of Dermatology (Dr Dicken) and Medical Genetics (Drs Dewald and Gordon), Mayo Clinic and Mayo Foundation, Rochester, Minn.

Reprint requests to Mayo Clinic, 200 First St SW, Rochester, MN 55901 (Dr Dicken).

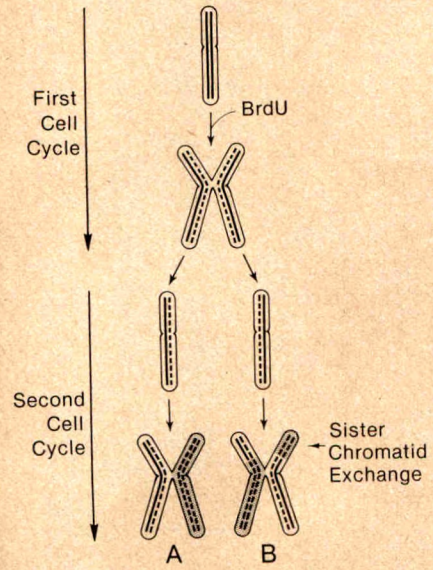

Fig 2.—Sister chromatid exchange (SCE) by exposing cells to bromodeoxyuridine (BrdU) through two cell cycles. During S phase of first cycle, BrdU is incorporated in DNA strand (broken line) of each daughter chromatid. In second cell cycle, one sister chromatid contains substituted DNA (left chromatid of chromosome A); other sister chromatid (right, chromosome A) contains DNA with BrdU in both strands. In chromosome B, SCE has occurred in short arms, hence, doubly substituted segment of DNA appears in right chromatid; short arms of this chromosome will fluoresce differentially.

Fig 3.—Distribution of erythosquamous eruption on patient's face.

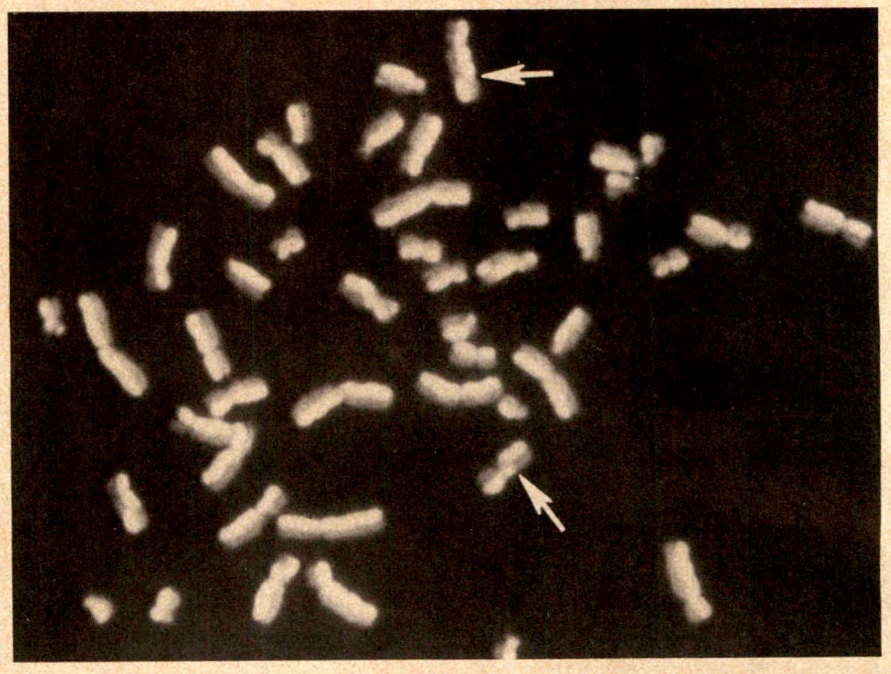

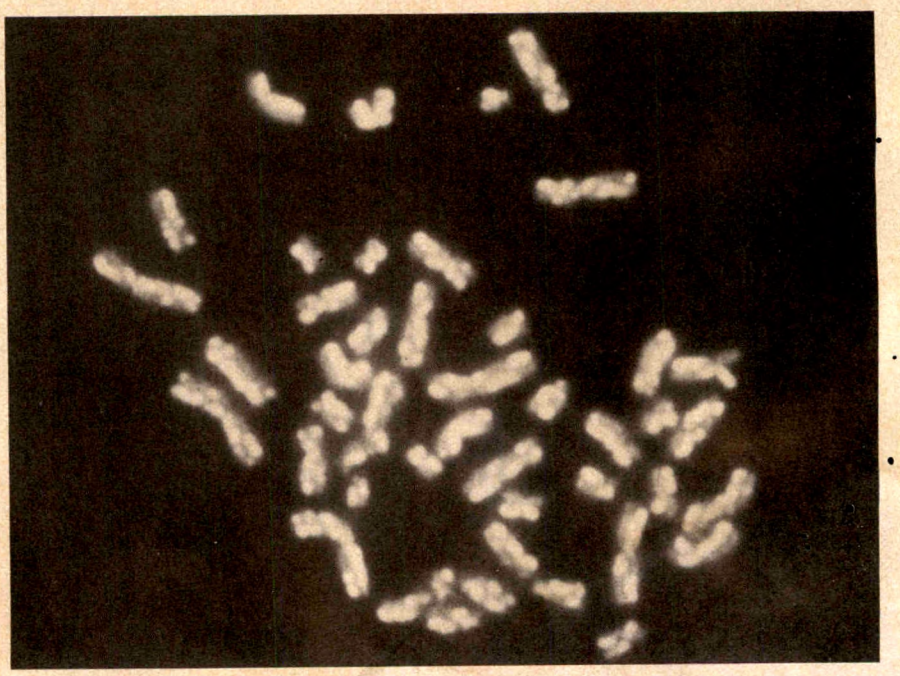

Fig 4.—Top, Normal metaphase of BrdU-treated preparation stained with acridine orange, showing differential fluorescence of sister chromatids. Thirteen SCE are present, two are indicated by arrows. Bottom, Similarly prepared metaphase from patient with Bloom's syndrome. One hundred twenty-four SCE are present.

early age for these tumor types.[5] The association of cancer susceptibility and chromosome instability in Bloom's syndrome naturally has led to much speculation about the possible meaning of this association in the pathogenesis of neoplasia. Such speculation has been stimulated further by the recognition of immune deficiency in some patients with Bloom's syndrome.[6]

Recently, the Cornell team made another important contribution by their demonstration that another type of chromosome instability, ie, sister chromatid exchanges (SCE), occurs with a very high frequency in patients with Bloom's syndrome but not in the other syndromes associated with chromosome instability.[7] Sister chromatid exchanges are produced when breaks occur in both chromatids of a chromosome at homologous or nearly homologous loci, followed first by interchange of the affected segments and then by repair processes to restore the continuity of the chromatid (Fig 1B). This phenomenon was first demonstrated in 1957 when Taylor[8] used autoradiography with tritiated thymidine to label the replicating DNA of the chromatids. This technique is cumbersome, and the degree of resolution that can be achieved with it is inadequate for the clear delineation of the extent of the SCE on a given metaphase chromosome.

Fortunately, a simpler fluorescent-dye technique has been introduced with which SCE can be observed much more readily and clearly.[9,10] This technique depends on the fact that DNA, which contains the thymidine analog bromodeoxyuridine (BrdU) instead of thymidine, will fluoresce less brightly under ultraviolet light after treatment with fluorochromes such as acridine orange or Hoechst 33258. If BrdU is present in both strands of the DNA molecule, the fluorescence will be even less than when the BrdU is present in only one strand. If cells in culture are exposed to BrdU for two cell cycles, then, as expected from the semiconservative nature of DNA replication, chromosomes will be produced in which one chromatid will have thymidine replaced by BrdU in only one strand of DNA, whereas the other chromatid will have BrdU instead of thymidine in both strands of DNA. This will result in differential fluorescence of the sister chromatids: the chromatid with the BrdU in only one strand will fluoresce more brightly than the chromatid with BrdU in both strands. If a SCE is present, it will appear as an interchange between the sister chromatids of brightly and dully fluorescent segments. This is illustrated diagrammatically in Fig 2.

Using this technique, Chaganti et al[7] investigated three patients with Bloom's syndrome. These authors found an average of 89.0 SCE per cell in these patients, compared with an average of 6.9 SCE per cell in seven normal controls. The frequency of SCE was within normal limits in patients with the Fanconi pancytopenia syndrome and with ataxia-telangiectasia. The high frequency of SCE in patients who have Bloom's syndrome has been confirmed in one patient each by Sperling et al[11] and Shiraishi et al,[12] and in two more patients by Bartram et al.[13]

In this paper, we report the clinical and laboratory findings in a new case of Bloom's syndrome and our experience with the SCE technique.

REPORT OF A CASE

The patient's mother had used an oral contraceptive agent (ethynodiol diacetate with mestranol; Ovulen) for three years until about one month before she became pregnant with this patient. Because the mother did not menstruate between the time she stopped taking the contraceptive and the beginning of the pregnancy, the exact duration of the pregnancy is not known. Labor began almost three weeks later than was expected and was uncomplicated. The patient's birth weight was 2,600 gm. She was regarded as normally developed, but her weight gain during the first two months was slow.

At age 7 months, after the child had been out in the sun for several hours, the parents observed small blisters around her lips. The blisters broke and healed slowly but completely. Red patches then appeared on the cheeks and on the bridge of the nose. The lesions apparently did not itch or cause any other discomfort. At first eczema was diagnosed, but treatments with various topical corticosteroid preparations did not help. By age 10 months, similar lesions had appeared on the back of the left hand and on the forearms of the patient.

Throughout this time, the patient's general health remained good except for infrequent minor episodes of fever. She ate well but remained small. In other respects, her development was normal: she stood unaided at 9 months; by age 10 months she was walking with considerable agility; and by age 11 months she began to speak her first words. She was friendly and sociable.

When she was examined at the Mayo Clinic at age 11 months, the following measurements were recorded: length, 67.0 cm (just below the third percentile); weight, 6,200 gm (much below the third percentile); and head circumference, 40.7 cm (below the third percentile); all the other somatic measurements were in proportion to her general smallness.

A prominent, confluent, erythrosquamous eruption was apparent on the butterfly area of the face, with a few tiny spots elsewhere on the face (Fig 3). There were similar but more papular lesions on the forearms and on the back of the left hand.

The results of the rest of the physical examination were normal. The patient was lively, and she responded appropriately during the examination.

General Investigations

The hemoglobin level, RBC indices, sedimentation rate, urinalysis results, values of serum immunoglobulins, antinuclear antibody titer, results of lupus erythematosus clot test, results of tests for urinary uroporphyrin, coproporphyrin, and porphobilinogen, and the results of tests for red cell porphyrin and protoporphyrin all were normal. There were 47% T-lymphocytes, which is abnormally low (normal, 72% ± 4%), and 17% B-lymphocytes, which is within normal limits (11% ± 6%). The lymphoblastic response to stimulation with phytohemagglutinin (PHA) was normal.

Skin Biopsies

In the biopsy specimen from the left cheek, epidermal atrophy, severe degeneration of the basal cell layer, and inflammatory cell infiltration of the dermis were evident. Cytoid bodies showing direct immunofluorescence staining for IgG, IgM, C3, and fibrin were present, and there was weak deposition of fibrin granules at the dermo-epidermal junction. These findings were regarded as suggestive, but not diagnostic, of systemic lupus erythematosus (SLE). The specimen from the back of the left hand showed chronic nonspecific dermatitis, cytoid bodies that stained for IgM, and fibrin deposition at the dermo-epidermal junction.

Family History

There was no knowledge of shortness of stature, developmental anomalies, or neoplastic diseases in the patient's only sibling (older sister) or in the parents, the four maternal uncles, the one maternal aunt, the two paternal uncles, the one paternal aunt, the four grandparents, or the 14 first cousins. A maternal first cousin was stillborn. The paternal-maternal great-great-grandfather died at age 63 years of "brain cancer." The father was 27 years old when the patient was born; he is of mixed German, French, Irish, and English descent. The mother was 23 years old when the patient was born; she is of German descent. The parents are not known to be consanguineous, and neither parent has any known Jewish ancestry.

Progress

Maxafil cream (4% cinoxate and 5% methyl anthranilate in a water-in-oil cream base) was prescribed as a sunscreen to be applied to the eruption, and the parents were advised to keep the patient out of the sun as much as possible. During

the subsequent two months, the intensity of the erythema decreased but the eruption persisted in the originally affected areas.

CHROMOSOMAL METHODOLOGY

Duplicate cultures of the peripheral blood lymphocytes from the patient, each parent, a female patient with SLE, and four normal persons were established on chromosome medium. After 48 hours of incubation, BrdU (30 μg/ml) was added to one culture from each subject. The cultures were incubated for another 24 hours (approximately two cell cycles) in opaque containers. After a total of 72 hours of incubation, all the cultures were harvested, by using demecolcine (Colcemid [Britain]; no comparable US product) (0.5 μg/ml for 1 hour) and warm hypotonic potassium chloride solution (0.075M for 10 minutes), and fixed with cold methanol-acetic acid (3:1). The prepared slides were dried at room temperature.

Following the procedure of Kato,[10] we stained the slides from the BrdU culture with 0.01% acridine orange, rinsed them with deionized water, and mounted them in Sörensen's buffer (pH 6.8). The fluorescence preparations were examined with a microscope that was equipped with an incident light system in which a 200-W mercury light source, a 490-nm blue light excitor filter, and a 510-nm barrier filter were used. Metaphases in which the chromatids were adequately differentiated were photographed, the film was developed, and 8 × 10-in enlargements were printed from each negative. The number of SCE per metaphase was determined by counting from these photographs.

Slides prepared from the cultures that had not been treated with BrdU were stained in a conventional (nonbanded) manner with Giemsa. These slides were studied through the microscope; 100 metaphases were scrutinized in each case to determine the frequency of gaps, breaks, and other structural abnormalities. Other slides (from the cultures not pretreated with BrdU) were stained to produce G bands, after trypsinization. These also were examined for structural anomalies and were used to prepare three karyotypes for each subject.

CHROMOSOMAL FINDINGS

On the G-banded preparations, no consistent chromosome anomaly of structure or number was seen for any of the subjects. With the conventional stain, broken (acentric) chromosomes were present in 6% of the metaphases of the patient with Bloom's syndrome, and chromatid breaks or gaps were present in 18% of her metaphases. In the parents of this patient, no broken chromosomes were seen; in each, chromatid breaks or gaps were seen in 6% of their metaphases. The findings in the parents were not appreciably different from the normal standard in our laboratory, based on 14 healthy subjects in whom chromosome breaks occurred in an average of 0.4% of metaphases (range, 0% to 2%) and chromatid breaks and gaps occurred in an average of 3.7% of metaphases (range, 1% to 9%).

Frequency of Sister Chromatid Exchanges

Subject	No. of Metaphases Examined	Total SCE* Observed	SCE per Metaphase Mean	SCE per Metaphase Range
Bloom's syndrome				
Patient	40	3,948	98.7	66-127
Mother	34	345	10.1	4-23
Father	40	439	11.0	3-22
SLE† patient	40	462	11.5	2-19
Controls				
Female	50	527	10.5	3-19
Male	30	319	10.6	4-16
Male	37	330	8.9	4-24
Female	37	408	11.0	5-18

*SCE indicates sister chromatid exchanges.
†SLE indicates systemic lupus erythematosus.

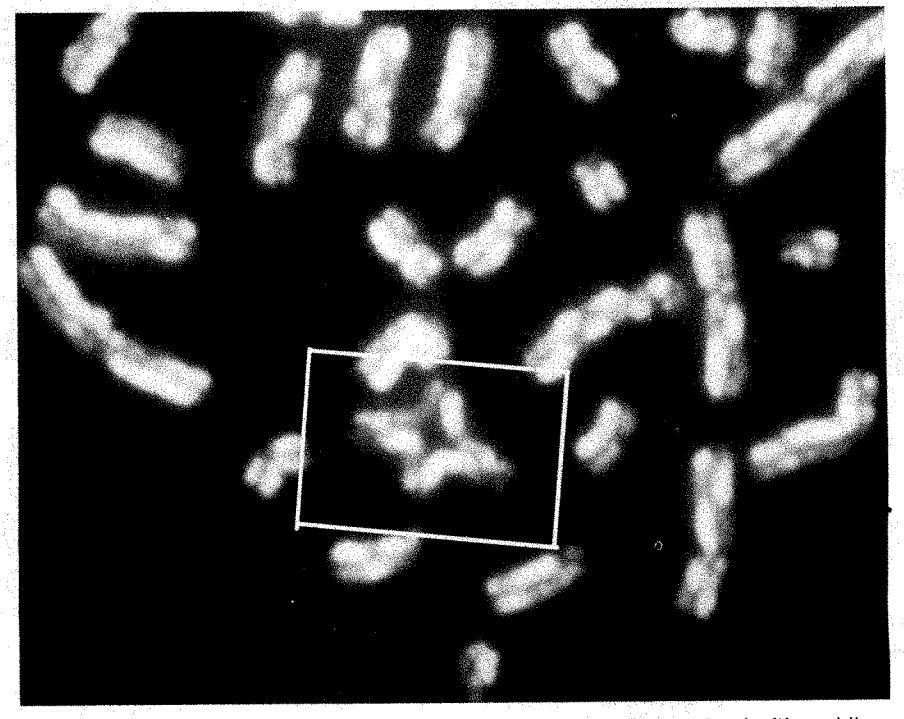

Fig 5.—Quadriradial configuration from BrdU-treated preparation, stained with acridine orange, from patient with Bloom's syndrome.

The frequencies of SCE that were observed with the BrdU technique are shown in the Table. In the four control subjects, this frequency varied from three to 24 per metaphase (mean, 9.7). An example of a normal BrdU-treated metaphase is shown in Fig 4, top. The findings in the patient with SLE were similar: from two to 19 exchanges per metaphase were observed (mean, 11.5). In the patient with Bloom's syndrome, the frequency of exchanges was ten times greater than in the controls, ranging from 66 to 127 per metaphase (mean, 98.7). In the parents, the frequency of exchanges was no different from the controls, ranging from three to 23 per metaphase with a mean of 10.1 and 11.0 exchanges per metaphase in the mother and father, respectively. The lowest number of exchanges seen in a metaphase from the patient with Bloom's syndrome was 66, which is almost three times greater than the highest number of exchanges (24) seen in any of the 308 metaphases from the other seven subjects. An example of a metaphase from the patient with Bloom's syndrome is shown in Fig 4, bottom.

No quadriradial chromosomes were seen in the standard or G-banded preparations, but one typical quadriradial configuration was observed in the BrdU preparation from the patient with Bloom's syndrome (Fig 5).

COMMENT

Diagnosis of Bloom's Syndrome

This patient has all three cardinal signs of Bloom's syndrome. Although her birth weight was somewhat greater than that for most babies with this syndrome, her weight, height, and other somatic measurements at 11 months were below the third percentile. She has erythrosquamous lesions on the butterfly area of the face; her parents associate the first appearance of this eruption with a period of prolonged exposure to the sun. Unlike many other children with Bloom's syndrome, this patient has no other developmental anomalies and no known Jewish ancestry.

Bloom's original paper[1] was entitled "Congenital Telangiectatic Erythema Resembling Lupus Erythematosus in Dwarfs," and in our patient, SLE was seriously considered in the initial differential diagnosis. This diagnosis also was suggested by several physicians when the patient's case was presented at a meeting of the Minnesota Dermatologic Society; even on skin biopsy, this diagnosis still was suspected. The specific laboratory tests for SLE were negative, but the diagnosis of Bloom's syndrome was not unanimously accepted until the high frequency of SCE was demonstrated.

Frequency of SCE

In our patient, the frequency of SCE (an average of 98.7 per metaphase; range, 66 to 127 SCE per metaphase) is similar to that observed by Chaganti et al[7] in three patients (mean, 89.0 per metaphase; range, 45 to 162 SCE per metaphase) and by Bartram et al[13] in two patients (mean 90.6 per metaphase; range, 58 to 114 SCE per metaphase). In our patient, the mean frequency of SCE was ten times greater than in four normal subjects (mean, 9.7). Even in the metaphases from the patient with the fewest SCE, the frequency was almost three times greater than in those metaphases from the controls that had the greatest number of SCE. This corroborates the experience of other investigators; Bartram et al[13] even have theorized that examination of merely a single metaphase from a patient with Bloom's syndrome might be adequate for making the diagnosis.

In the other genetic syndromes in which there is spontaneous chromosome breakage, such as the Fanconi pancytopenia syndrome and ataxia-telangiectasia, an abnormally high frequency of SCE has not been observed.[7,13] The presence of a quadriradial configuration does not necessarily mean that there will be an increased frequency of SCE, because in the Fanconi and the ataxia-telangiectasia syndromes, some types of quadriradial configuration rarely may be seen. These, however, are not the type of quadriradial configuration that occurs in patients who have Bloom's syndrome, which characteristically consists of exchanges between the chromatids of homologous chromosomes. This suggests that the kind of chromosome instability that occurs in patients with Bloom's syndrome is different from that in the other syndromes.

In persons with xeroderma pigmentosum, spontaneous chromosome breakage is not observed; however, in some, but not all, types of this condition, an abnormal number of chromosome breaks can be produced by exposing the cell cultures to ultraviolet light.[13] Interestingly, Bartram et al[13] observed up to a two-fold increase in SCE in the ultraviolet irradiated cells from six of eight patients with xeroderma pigmentosum but no increase in the other two patients. This is consistent with the clinical and biochemical evidence of genetic heterogeneity in xeroderma pigmentosum.

The technique for demonstrating SCE must be carefully standardized. Increases in SCE can be obtained in normal cells by varying the concentration of BrdU[10] or by exposing the cultures to ultraviolet light[14] or to certain chemicals.[15]

Because of the question of SLE in the differential diagnosis of our patient, we examined the chromosomes of an untreated patient in whom SLE had been confirmed. Her chromosomes, in respect to both chromosome breakage and SCE, were within normal limits.

Genetic Factors

The parents of a patient with Bloom's syndrome presumably are heterozygous in respect to the autosomal mutation that causes this syndrome. Because this mutant gene has a recessive effect, it has no clinically recognizable expression in the heterozygote. We examined the chromosomes of our patient's parents to see whether there was any cytogenetic evidence of their "carried" state, but the findings, including SCE, were within normal limits.

We also have examined the chromosomes of another set of parents, Ashkenazi Jews, two of whose five children almost certainly have Bloom's syndrome. Their oldest daughter had been seen at the Mayo Clinic in 1953; she was described as "tiny and elflike," one leg was shorter than the other, and there were multiple café au lait spots on her trunk. When the child was 3½ years old, a malignant retroperitoneal lymphoblastic lymphoma appeared, and she died soon thereafter of its metastatic effects. Another sibling in this family, a man who is now 20 years old, is short (his height is 155 cm); he has no facial lesions. At age 12 years, a lymphoblastoma appeared in his cervical glands and was treated successfully with irradiation and cytotoxic drugs. Recent examination of his chromosomes showed the male karyotype, 46,XY, with at least one broken chromosome in 26.6% of 102 metaphases. In another 40 metaphases that were treated with BrdU, there was a mean of 100.4 SCE per metaphase (range, 72 to 130 SCE per metaphase). This patient probably is the same individual reported on by Shiraishi et al.[12] The parents of these two patients have normal karyotypes: in the father, the mean SCE frequency is 10.2 per metaphase (range, 5 to 22 SCE per metaphase); in the mother, the mean SCE frequency is 11.1 per metaphase (range, 4 to 18 SCE per metaphase).

Thus, we have not been able to detect any increase in SCE in four persons who are presumed to be heterozygous for Bloom's syndrome. This also has been the experience of others.[7,13] Perhaps, as in some cases of xeroderma pigmentosum, there is no spontaneous increase in SCE but a moderate increase occurs after ultraviolet irradiation. We hope to test this hypothesis soon.

Immune Deficiency

Unlike some other patients with Bloom's syndrome, our patient has not experienced more than occasional minor infections. The only indication of immune deficiency in our patient is a low proportion of T-lymphocytes. In other patients, laboratory evidence of immune deficiency, when present, has been inconsistent.[6,13,16] Some such patients have partial or complete deficiencies of one or more immunoglobulins, some patients have impaired humoral or cellular responses to antigenic challenges, and some patients have partial dysfunction of T-lymphocytes. For example, Hütteroth et al[16] found that in the one-way mixed lymphocyte culture test, lymphocytes from patients with Bloom's syndrome

behaved normally as stimulators but poorly as responders, which indicates impaired T-lymphocyte function; in contrast, the response to PHA stimulation was satisfactory, which paradoxically indicates saitisfactory T-lymphocyte function. Possibly because of the short life-span of the cytogenetically unstable lymphocytes in Bloom's syndrome, their general efficiency in immune surveillance is impaired, but a consistent or specific immune defect has not yet been characterized.

Conclusions

The most important biological discussion that has been generated by these studies of Bloom's syndrome concerns the possible interaction of the chromosome instability, the immune deficiency, and the increased susceptibility to cancer. One may well wonder what is the sequence of the pathogenical process in these patients. One may also ask whether Bloom's syndrome is primarily a genetic defect in the immune system, in which defective immune surveillance allows cells with unstable chromosomes to proliferate and to produce cancers. Or, perhaps the primary defect in the chromosomes with breaks at one or more specific sites is disturbing the normal regulation of gene replication and causing neoplastic proliferation of cells. If the latter is correct, then the impairment of immune function might be no more than a nonspecific effect of the rapid turnover of unstable cells.

At present, we tend to favor the possibility of a primary chromosomal defect. We do so because some of the chromosome anomalies in Bloom's syndrome, ie, the quadriradial configuration and the high frequency of SCE, suggest a certain degree of specificity. This is in contrast to the apparently random breakages that occur in the other syndromes of chromosome instability and in malignant tissues generally and that can be explained by a failure of immune surveillance. In fact, the investigations of German et al[17] indicate that certain chromosomes and certain loci on those chromosomes are particularly susceptible to the breaks and exchanges that cause the quadriradial configurations. For example, the number 1 chromosomes often are involved in quadriradial formation but the number 2 chromosomes are not. Sister chromatid exchanges occur more frequently in the A, B, C, and D groups of chromosomes than in the E, F, and G groups, even after allowance is made for the relatively greater length of the former.

Much more must be learned about the possible pathogenical interactions of chromosome instability and immune surveillance in causing cancer. Whichever hypotheses eventually are proved to be correct, studies of patients with the rare Bloom's syndrome will have made important contributions.

References

1. Bloom D: Congenital telangiectatic erythema resembling lupus erythematosus in dwarfs. *Am J Dis Child* 88:754-758, 1954.
2. Bloom D: The syndrome of congenital telangiectatic erythema and stunted growth. *J Pediatr* 68:103-113, 1966.
3. German J: Bloom's syndrome: I. Genetical and clinical observations in the first twenty-seven patients. *Am J Hum Genet* 21:196-227, 1969.
4. German J, Archibald R, Bloom D: Chromosomal breakage in a rare and probably genetically determined syndrome of man. *Science* 148:506-507, 1965.
5. German J: *Chromosomes and Cancer.* New York, John Wiley & Sons Inc, 1974, pp 601-617.
6. Landau JW, Sasaki MS, Newcomer VD, et al: Bloom's syndrome. *Arch Dermatol* 94:687-694, 1966.
7. Chaganti RSK, Schonberg S, German J: A manyfold increase in sister chromatid exchanges in Bloom's syndrome lymphocytes. *Proc Natl Acad Sci USA* 71:4508-4512, 1974.
8. Taylor JH: Sister chromatid exchanges in tritium-labeled chromosomes. *Genetics* 43:515-529, 1958.
9. Latt SA: Microfluorometric detection of deoxyribonucleic acid replication in human metaphase chromosome. *Proc Natl Acad Sci USA* 70:3395-3399, 1973.
10. Kato H: Spontaneous sister chromatid exchanges detected by a BrdU-labelling method. *Nature* 251:70-72, 1974.
11. Sperling K, Goll U, Kunze J, et al: Cytogenetic investigations in a new case of Bloom's syndrome. *Hum Genet* 31:47-52, 1976.
12. Shiraishi Y, Freeman AI, Sandberg AA: Increased sister chromatid exchange in bone marrow and blood cells from Bloom's syndrome. *Cytogenet Cell Genet* 17:162-173, 1976.
13. Bartram CR, Koske-Westphal T, Passarge E: Chromatid exchanges in ataxia telangiectasia, Bloom syndrome, Werner syndrome, and xeroderma pigmentosum. *Ann Hum Genet* 40:79-86, 1976.
14. Kato H: Photoreactivation of sister chromatid exchanges induced by ultraviolet irradiation. *Nature* 249:552-553, 1974.
15. Perry P, Evans HJ: Cytological detection of mutagencarcinogen exposure by sister chromatid exchange. *Nature* 258:121-125, 1975.
16. Hütteroth TH, Litwin SD, German J: Abnormal immune responses of Bloom's syndrome lymphocytes in vitro. *J Clin Invest* 56:1-7, 1975.
17. German J, Crippa LP, Bloom D: Bloom's syndrome: III. Analysis of the chromosome aberration characteristic of this disorder. *Chromosoma* 48:361-366, 1974.

Keratosis Follicularis Spinulosa Decalvans

An Infant With Failure to Thrive, Deafness, and Recurrent Infections

Helen Britton, MD; James Lustig, MD; Brenda J. Thompson, MD; Steven Meyer, MD; Nancy B. Esterly, MD

• A 10-month-old male infant had keratosis follicularis spinulosa decalvans, an X-linked dominant disorder. His cutaneous abnormalities consisted of generalized hyperkeratosis, spiny follicular papular lesions, universal alopecia, and hypoplastic nails. Ocular changes characteristic of the disease were also present. Unusual findings included deafness, failure to thrive, predisposition to bacterial infections without demonstrable immune defect, and transient hepatomegaly with abnormal liver function studies.

(*Arch Dermatol* 114:761-764, 1978)

Keratosis follicularis spinulosa decalvans (KFSD) is a rare inherited disorder of keratinization that affects both the skin and the eye. Although it was delineated as a distinct disease in 1925 by Siemens,[1] very few patients have been reported since the original description. A 10-month-old infant with striking cutaneous changes is described in this report. In addition to the expected ocular manifestations, he has persistent right upper lobe atelectasis, and has experienced recurrent infections of the skin, eyes, and urinary tract associated with intermittent hepatomegaly and abnormal liver function studies.

*Accepted for publication May 19, 1977.

From the Departments of Pediatrics (Drs Britton, Lustig, and Thompson) and Ophthalmology (Dr Meyer), University of Chicago Hospitals and Clinics, and the Division of Dermatology, Department of Pediatrics (Dr Esterly), Michael Reese Hospital and Medical Center, Chicago.

Reprint requests to Department of Pediatrics, Michael Reese Hospital and Medical Center, 29th St and Ellis Ave, Chicago, IL 60616 (Dr Esterly).

REPORT OF A CASE

This male infant was first admitted to the Wyler Children's Hospital at 4 weeks of age with failure to thrive and a peculiar skin disorder. He had been delivered by cesarean section at an estimated seven months gestation because of a placenta previa. Birth weight was 2,500 gm. At birth, he was noted to have thickened coarse skin and almost total absence of scalp hair. He remained hospitalized for two weeks because of poor feeding, a problem that continued after discharge. By 4 weeks of age, he had gained only 100 gm.

The family history disclosed only hand eczema in the patient's mother. A sister, age 3 years, has always been healthy. The paternal family history was unknown.

Physical Examination

At the time of admission, the patient appeared to be slightly malnourished but normally proportioned: his weight was 2,600 gm, his length 50 cm, and his head circumference 34 cm. Temperature was 38 C. The skin over the entire body was thickened and hyperkeratotic with coarse markings and furrows, most noticeable in the flexural and perioral areas. A prominent follicular pattern was evident over the entire integument, but plugging was pronounced on the scalp and ear lobes and over the nose, where spiny filiform projections protruded from the pilosebaceous orifices (Fig 1 and 2). There was a peculiar pattern on the palms and soles resulting from the hyperkeratosis (Fig 3). The scalp hair was absent, and no body hair was detectable. The nails were hypoplastic on all of the fingers and toes. There was a malodorous purulent discharge from the eyes and nose, the auditory canals were filled with dry crusty material, and several pustules were present on the face and scalp. The patient did not seem to respond to sound. Despite vigorous crying, there were no tears on ophthalmic examination. The eyelids were thickened and hyperkeratotic. The eyebrows and cilia were absent. The conjunctivas were mildly injected, and there were no cilia present on either caruncle. His cornea, anterior chamber, iris, lens, and fundus were normal bilaterally. The pulmonary, cardiovascular, and central nervous systems were unremarkable. There was neither hepatosplenomegaly nor lymphadenopathy, but bilateral inguinal hernias were present.

Laboratory Data

The WBC count was 10,400/cu mm, with 45% polymorphonuclear leukocytes, 49% lymphocytes, and 6% monocytes. Hemoglobin level was 11.1 gm/100 ml, platelet count was 290,000/cu mm, and reticulocyte count was 3.3%. Values for serum electrolytes, BUN, creatinine, glucose, calcium, and phosphorus were normal as were values for urinary and blood amino acids, a free thyroxin index, and total thyroxin. Total serum protein level was 5.9 gm/100 ml and albumin value was 3.5 gm/100 ml. A chest roentgenogram disclosed right upper lobe atelectasis. Skull roentgenograms demonstrated normal tooth buds. Pyuria was found on urinalysis, and culture of urine revealed > 100,000 colonies/cu ml of *Escherichia coli*. *Pseudomonas aeruginosa* and *Staphylococcus aureus* grew from

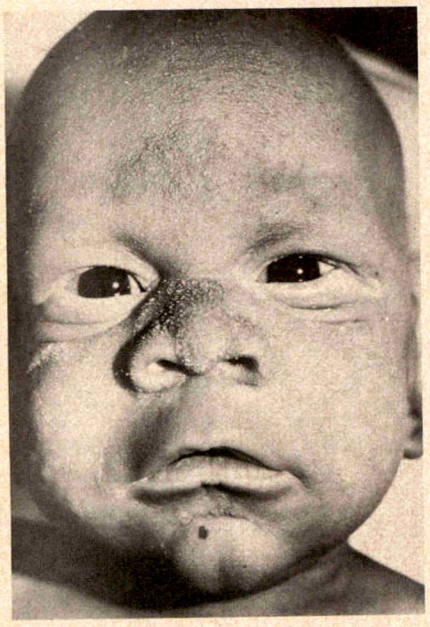

Fig 1.—Facial appearance at 4 weeks of age. Note thickened scaly skin, furrowing on chin, and total alopecia.

Fig 2.—Close view of face showing spiny projections on nose.

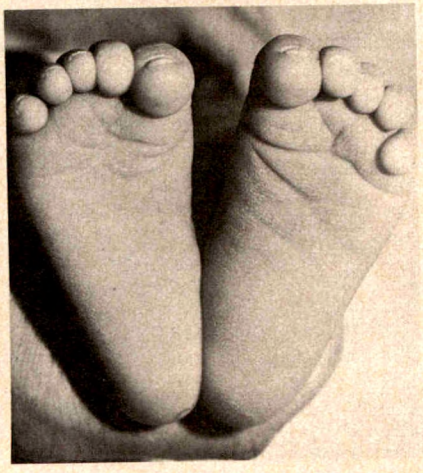

Fig 3.—Hyperkeratosis involving both soles.

Table 1.—Immunologic Evaluation

Immunoglobulins (2 mo)		
IgA	52 mg/100 ml	
IgG	950 mg/100 ml	
IgM	132 mg/100 ml	
IgE	100 IU/100 ml	
Anti-streptolysin O titer	80 units (normal, 12-200)	
Blood type A+: anti-B titer	1:15	
Total hemolytic complement	196 units (normal, 180-330)	
Complement immune adherence	2,000 units (normal, 2,000)	
Formazan slide test[20] (% cells reducing dye)	Unstimulated, 91%; stimulated, 99%	
β-cell surface immunoglobulins* (with polyvalent antiserum)	22% (normal, 12%-25%)	
T-rosettes[21] × 3	38% (normal, 68% ± 4%)	
Lymphocyte cultures[22]		
PBS	3,766 dpm†	...
PHA	1,059,504 dpm	281.0 SI‡
Pokeweed	525,211 dpm	139.0 SI
Candida	63 dpm	0.05 SI
Purified protein derivative	68 dpm	0.05 SI
Streptokinase-streptodornase	227 dpm	0.20 SI
Neutrophil chemotaxis[23]	Control 57/10 high-power field (hpf) (normal, 23-58)	
	Zymosan 165/10 hpf (normal, 128-170)	
	Ag-Ab 138/10 hpf (normal, 132-154)	

*Fluorescein-conjugated antiserums to human immunoglobulin.
†dpm indicates disintegrations per minute.
‡Stimulation index = dpm-stimulated culture/dpm unstimulated culture.

cultures from the conjunctival sac, and *P aeruginosa*, *S aureus*, and *Proteus mirabilis* grew from skin cultures. Nasotracheal aspirates showed mixed flora (nonpathogens). All cultures were negative for viruses. Serum antibody titers to herpesvirus, cytomegalic inclusion virus, rubella virus, and toxoplasma were not elevated. A VDRL was nonreactive. Immunologic studies are given in Table 1.

Histopathology

Skin biopsy specimens were obtained from the scalp, thigh, and palm. The stratum corneum was thickened and had a basket-weave pattern. The epidermis was papillomatous in appearance but of normal thickness, with an intact granular layer. All of the pilosebaceous orifices were dilated and filled with plugs of keratinous material, and normally formed hairs were absent (Fig 4). Sebaceous glands were normal in number and appearance. Well-developed eccrine glands were present in all three specimens. The dermis was moderately cellular.

Biopsy specimens also were obtained from the lid and the conjunctiva. There was hyperkeratosis and papillomatosis of the epidermis as well as a thickened granular layer. No hair was visible. The dermal collagen was normal, an observation confirmed by electron microscopy. The conjunctival changes included focal thickening, absence of goblet cells, and intercellular edema. The superficial layers of cells appeared to have sloughed in some areas.

Hospital Course

During his initial hospitalization, the eye infection responded to antibiotic and methylcellulose eye drops. The skin improved with 10% urea in an emulsion ointment base (Eucerin) cream. The right upper lobe atelectasis resolved with frequent postural drainage. Prompt clearing of the urinary tract infection occurred after a course of oral ampicillin. A subsequent intravenous pyelogram was normal.

During the next six months, the patient had three hospital admissions. Right upper lobe atelectasis recurred and persisted despite postural drainage. Viral and bacte-

Fig 4.—Skin biopsy specimen from thigh demonstrating hyperkeratosis, papillomatosis, and plugs of keratinous material distending pilosebaceous canals.

rial cultures remained unremarkable, and there was only occasional evidence of mild respiratory distress with tachypnea. Barium swallow revealed evidence of repeated aspirations with swallowing. He has had two subsequent urinary tract infections, both of which cleared with antibiotic therapy. Immunologic studies have been repeated but have been unchanged. Concomitant with the first and third urinary tract infections, mild hepatomegaly and abnormal liver function tests were noted. In both instances, liver size and enzyme levels returned to normal within a two-week period. Urine cultures for cytomegalovirus were negative. Hepatitis-associated antigen was not detected.

Growth and development are retarded for his chronological age. His growth curve falls below, but parallels, the third percentile for both height and weight. His motor and social development at 7 months approximated those of a 5-month-old. Formal audiometry was performed at 4 months, and there was no observable response to sound. Electrocochleography was done and revealed profound sensorineural hearing loss on the right. The left ear canal was infected and, therefore, not studied.

COMMENT

The cutaneous abnormalities detectable in this patient conform both histologically and clinically to those of a rare skin disorder, keratosis follicularis spinulosa decalvans, which has also been called spiny hyperkeratosis[2] and ichthyosis follicularis.[3] Affected individuals have generalized hyperkeratosis with marked plugging of the follicular orifices.[2,4] Distinct keratinous spicules project from the pilosebaceous openings, particularly in the paranasal area, and there is perioral furrowing as observed in this infant. Partial or complete alopecia involving eyebrows, lashes, and body hair, as well as scalp hair, is also considered characteristic for severely affected patients. These children have a rather unusual appearance and may bear striking resemblance to one another. The disorder is thought to be inherited as an X-linked trait, with full expression in males and inconstant minor abnormalities in heterozygous females.[4,5]

The differential diagnosis includes a group of diseases that are clinically similar but histologically distinct, and another group of diseases that are histologically similar but reveal a wide spectrum of associated physical defects. The alopecia and nail hypoplasia of this infant were initially interpreted as evidence for an ectodermal dysplasia[6]; however, the presence of normal eccrine glands on skin biopsy specimens and normal tooth buds on skull roentgenograms made a diagnosis of hypohidrotic ectodermal dysplasia untenable. The generalized hyperkeratosis, alopecia, hypoplastic nails, and recurrent infections also suggested the possibility of combined immunodeficiency disease. A similar constellation of findings has been described in some of these infants,[7] but erythroderma and redundant skin are frequently present, the alopecia is usually progressive from birth, and the histological changes are distinct from those found in KFSD. Furthermore, an evaluation of our patient's immune system failed to disclose a significant defect (Table 1). The depression of T-rosettes was compatible with active infection[8,9] and not with severe combined immunodeficiency. The results of the lymphocyte stimulation studies that showed a response to nonspecific mitogens, but not to specific antigens, could be attributed to the patient's age.

Other clinically similar diseases are X-linked ichthyosis, epidermolytic hyperkeratosis, and lamellar ichthyosis.[10] X-linked ichthyosis, which may be present at birth or during early infancy, usually spares most of the face, certain of the flexural areas, and does not result in alopecia. Epidermolytic hyperkeratosis, although characterized by generalized scaling, is associated with the formation of bullae during the early years of life and is distinguishable on skin biopsy specimen because of specific epidermal changes. Lamellar ichthyosis is most likely to cause confusion since the hyperkeratosis is generalized, involves palms and soles, and may cause a moderate degree of alopecia, particularly on the scalp, because of plugging of the follicles with thick scales. Patients with severe disease may also have ocular changes, particularly ectropion.[11] Nevertheless, despite certain clinical similarities, the distinc-

Table 2.—Associated Defects in Patients With Possible Keratosis Follicularis Spinulosa Decalvans

Source	Alopecia	Eye Defects	Deafness	Growth Retardation	Mental Retardation	Microcephaly	Recurrent Infections	Aminoaciduria	Hereditary	Nail Abnormality
Siemens[1]	+*	+	...	...	...	...	...	...	+	...
Zeligman and Fleisher[3]	+	+	...	...	+	...	*†	...	...	+
Kuokkanen[4]	+	+	...	...	...	...	...	...	+	...
Franceschetti et al[16]	Eyebrows only	+	...	...	...	...	...	...	+	...
Cantu et al[18]	+	...	...	+	+	+	...	...	+	...
Adler and Nyhan[5]	+	+	...	+	+	...	...	+	...	+
Morris et al[2]	+	+	+	...	...	...	...	...	...	...
Rycroft et al[19]	+	+	+	...	...	...	+	...	...	+
Present study	+	+	+	+	...	...	+	...	...	+

*The plus sign indicates defect present.
†The asterisk indicates one patient died at age 8 years of hepatic abscess.

tive spiny keratoses of KFSD do not occur in lamellar ichthyosis, and the histological features on the skin biopsy specimen are quite different. Pityriasis rubra pilaris and keratosis pilaris are also keratinizing disorders but are not usually present at birth, are not associated with severe alopecia, and have other distinguishing characteristics. Atrichia with papular lesions[12,13] is also characterized by alopecia and hyperkeratotic papules; however, histologically, the malformed hair follicles have a cystic appearance. Schafer's syndrome[14] (follicular hyperkeratosis, mental retardation, cataracts, alopecia, and thickened nails) and Fairbank's syndrome in association with follicular hyperkeratosis, cataracts, and dystrophic nails[15] might also cause confusion clinically.

In the group of patients histologically identified as having KFSD, spiny hyperkeratosis, ichthyosis follicularis, and atypical ichthyosiform erythroderma multiple associated physical defects have been reported (Table 2). Eye involvement is usual in patients with KFSD. Ophthalmologic manifestations include photophobia, inflammation of the lids, defective lacrimation, conjunctival protuberances, and corneal erosions and cloudiness.[2,4,16,17] The patient described by Adler and Nyhan[5] had, in addition, lenticular cataracts, asymmetry of the globes, and nonprogressive glaucoma. Our patient had several of these findings, including inflammation and hyperkeratosis of the lids, conjunctival changes, and defective tear formation. In a syndrome recently described by Cantu et al,[18] keratosis follicularis is associated with microcephaly and dwarfism. Our patient does fall below the third percentile in height and weight, but his head circumference is proportional to his height. One other patient assumed to have KFSD also had mental retardation, aminoaciduria, and arachnodactyly.[5] Our patient has no aminoaciduria, and his psychomotor development at this time is only slightly delayed.

This infant most closely resembles several older patients reported recently. A 5-year-old boy described by Morris et al[2] was identical in appearance and was also deaf but did not suffer recurrent infections. Two males, ages 9 and 20 years, reported by Rycroft et al[19] and designated as atypical ichthyosiform erythroderma were deaf and had similar histological findings. One had recurrent infections with a normal immunologic evaluation. Whether these individuals represent examples of a separate syndrome or whether the full spectrum of defects in KFSD has not been appreciated cannot be determined until more patients are thoroughly investigated.

Dr Lustig received support in part by grant A1-07854 from the National Institutes of Health.

References

1. Siemens HW: Ueber einen, in der menschlichen Pathologie noch nicht beobachteten Vererbungsmodus: Dominant-geschlechtsgebundene Vererbung. *Arch Rass Gesell Biol* 17:47-61, 1925.
2. Morris J, Ackerman AB, Koblenzer PJ: Generalized spiny hyperkeratosis, universal alopecia, and deafness: A previously undescribed syndrome. *Arch Dermatol* 100:692-698, 1969.
3. Zeligman I, Fleisher TL: Ichthyosis follicularis. *Arch Dermatol* 80:413-420, 1959.
4. Kuokkanen K: Keratosis follicularis spinulosa decalvans in a family from northern Finland. *Acta Derm Venereol* 51:146-150, 1971.
5. Adler RC, Nyhan WL: An oculocerebral syndrome with aminoaciduria and keratosis follicularis. *J Pediatr* 75:436-442, 1969.
6. Smith DW: *Recognizable Patterns of Human Malformation.* Philadelphia, WB Saunders Co, 1970, pp 178-186.
7. Gotoff SP, Esterly NB, Gottbrath E, et al: Granulomatous reaction in an infant with combined immunodeficiency disease and short-limbed dwarfism. *J Pediatr* 80:1010-1017, 1972.
8. Wara DW, Goldstein AL, Doyle NE, et al: Thymosin activity in patients with cellular immunodeficiency. *N Engl J Med* 292:70-74, 1975.
9. Wybran J, Fudenberg HH: Thymus-derived rosette-forming cells in various human disease states: Cancer, lymphoma, bacterial and viral infections and other diseases. *J Clin Invest* 52:1026-1035, 1973.
10. Esterly NB: The ichthyosiform dermatoses. *Pediatrics* 42:990-1004, 1968.
11. Jay B, Blach RK, Wells RS: Ocular manifestations of ichthyosis. *Br J Ophthalmol* 52:217-226, 1968.
12. Damsté TJ, Prakken JR: Atrichia with papular lesions: A variant of congenital ectodermal dysplasia. *Dermatologica* 108:114-121, 1954.
13. Loewenthal LJA, Prakken JP: Atrichia with papular lesions. *Dermatologica* 122:85-89, 1961.
14. Schafer E: Zur Lehre von der kongenitalen Dyskeratosen. *Arch Dermatol Syphilol* 148:425-432, 1925.
15. Marks R, Gold SC: Follicular hyperkeratosis and ocular abnormalities associated with the Fairbank's syndrome. *Br J Dermatol* 79:118-119, 1967.
16. Franceschetti A, Rossaro R, Jadassohn W, et al: Keratosis follicularis spinulosa decalvans (Siemens). *Dermatologica* 112:512-514, 1956.
17. Franceschetti A, Jadassohn W, Paillard R: Keratosis follicularis spinulosa decalvans (Siemens). *Dermatologica* 114:269-270, 1957.
18. Cantu JM, Hernandez A, Larracilla J, et al: A new X-linked recessive disorder with dwarfism, cerebral atrophy and generalized keratosis follicularis. *J Pediatr* 84:564-567, 1974.
19. Rycroft RJG, Moynahan EJ, Wells RS: Atypical ichthyosiform erythroderma, deafness and keratitis. *Br J Dermatol* 94:211-217, 1976.
20. Ochs HD, Igo RP: The NBT slide test: A simple screening method for detecting chronic granulomatous disease and female carriers. *J Pediatr* 83:77-82, 1973.
21. Jondal M, Holm G, Wigzell H: Surface markers on human T and B lymphocytes: I. A large population of lymphocytes forming nonimmune rosettes with sheep red blood cells. *J Exp Med* 136:207-215, 1972.
22. Reiger CH, Kraft SC, Rothberg RM: Alteration of T cell function in healthy persons with a history of thymic X-irradiation. *J Allergy Clin Immunol* 56:273-281, 1975.
23. Miller ME: Chemotactic function in the human neonate: Humoral and cellular aspects. *Pediatr Res* 5:487-492, 1971.

Hyperimmunoglobulin E Syndrome

John Stanley, MD; Daniel Perez, MD; Irma Gigli, MD; Ira Goldstein, MD; Rudolf L. Baer, MD

• A 24-year-old woman had the major features of the hyperimmunoglobulin E syndrome: recurrent staphylococcal skin infections (from the age of 6 months), an extremely elevated serum immunoglobulin E level (25,000 units/ml), and defective neutrophil chemotaxis. This patient also had peripheral blood eosinophilia and cutaneous candidiasis. There was a family history of asthma, but the patient herself did not have a history of asthma or hay fever, and, on examination, had no evidence of atopic dermatitis. The patient has not had any systemic infections. Results of the skin biopsy showed dermal edema and a perivascular infiltrate with eosinophils and an increased number of mast cells.

The clinical spectrum of the hyperimmunoglobulin E syndrome may include atopic dermatitis, mucocutaneous candidiasis, systemic infections, and/or the features of Job's syndrome.

(*Arch Dermatol* 114:765-767, 1978)

In the last several years there have been a number of reports of patients who display a syndrome consisting of recurrent staphylococcal skin infections, extreme elevations of the serum immunoglobulin E level, and impaired neutrophil chemotaxis. Often, these patients have a family or personal history of atopy, including atopic dermatitis. Most of these patients also have a peripheral blood eosinophilia. This syndrome has been called the hyperimmunoglobulin E syndrome.[1]

Because these patients may come to medical attention because of their dermatologic manifestations, this syndrome should be of great interest to the dermatologist. The following report illustrates the major features of this syndrome.

REPORT OF A CASE

A 24-year-old woman was seen in the private practice of one of us (R.L.B.) with a complaint of recurrent skin infections since age 6 months. Shortly after birth the patient was noted to have a red, scaly, and crusted pruritic rash, thought to be "eczema." At age 6 months, the patient developed a scalp abscess; when treated with penicillin, the entire eruption cleared. Since that time, she has had recurrent skin infections, including abscesses, furuncles, erysipelas, cellulitis, and impetigo. These infections have required eight hospitalizations. She has had intermittent pruritus in the antecubital and popliteal fossae, axillae, and groin, especially when these areas were infected. There was no history of systemic infection. At age 17, while in Israel, the patient was treated every other week for nine months with γ-globulin injections and a vaccine made from her staphylococcal and streptococcal skin flora. Her skin cleared completely for one year.

The family history showed that her mother and brother have asthma, but have no tendency to skin infections.

Physical examination disclosed abnormalities only of the skin. There were erythematous macules with thick yellow crusts in the malar regions (Fig 1). In the intertriginous areas there were pink to erythematous follicular papules and plaques with excoriations, crusting, and oozing (Fig 2). There were scattered excoriated follicular papules on the trunk and arms. There was no lichenification. There were numerous scars from previous incisions and drainages of abscesses.

On the basis of the recurrent severe pyogenic skin infections and in the absence of physical signs of atopic dermatitis to account for an altered anatomic barrier, a workup for an immunologic or neutrophil function anomaly was undertaken.

Part of the laboratory data is summarized in Table 1. In addition, the hematocrit was 35%, with normochromic, normocytic indexes; the sedimentation rate was 46 mm/hr. Values for the following were negative or normal: urinalysis, platelets, electrolytes, protein, albumin, serum protein electrophoresis (except for a slightly decreased α_1 fraction), calcium, fasting blood glucose, cholesterol, uric acid, BUN, creatinine, SGOT, latic dehydrogenase, alkaline phosphatase, bilirubin, VDRL, antinuclear antibody, and two stool specimens for ova and parasites.

Scratch tests were negative to wheat, egg yolk, egg white, cow's milk, dog dander, timothy, giant ragweed, and house dust-mite antigen. *Candida* antigen elicited an immediate wheal and flare reaction in a scratch test, and a 10-mm area of induration and erythema in an intradermal skin test at 48 hours. A purified protein derivative intradermal skin test was negative at 48 hours.

A biopsy specimen of a pink papule from the right antecubital fossa showed edema of the papillary dermis with a sparse perivascular lymphohistiocytic infiltrate with many eosinophils and an increase in the number of mast cells (Fig 3 and 4).

The patient was treated with dicloxacillin orally, saline compresses, and potassium permanganate baths. She improved greatly.

METHODS AND MATERIALS

Neutrophil Function Studies

Leukocytes were obtained from heparinized venous blood by standard methods of dextran sedimentation and hypotonic lysis of erythrocytes. Cells were washed and suspended in phosphate (10 mM)-buffered

Accepted for publication Aug 24, 1977.

From the Departments of Dermatology (Drs Stanley, Gigli, and Baer) and Medicine (Drs Perez and Goldstein), New York University School of Medicine.

Dr Goldstein is a career scientist award recipient from the Irma T. Hirschl Trust.

Reprints not available.

Fig 1.—Erythema and crusting in malar area.

Fig 2.—Excoriated follicular papules in axilla.

Fig 3.—Edema of papillary dermis and perivascular cellular infiltrate.

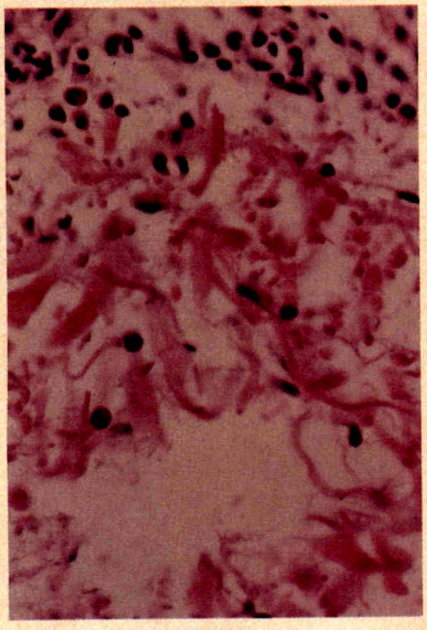

Fig 4.—Close-up showing infiltrate with numerous eosinophils.

Table 1.—Laboratory Data

Test	Date	Result
Skin culture Malar region	1/20/77	*Staphylococcus aureus*
Malar region	2/8/77	*S aureus*
External ear canal	2/8/77	*S aureus & Pseudomonas aeruginosa*
Fungal cultures		
Groin	1/20/77	*Candida albicans*
Axilla	1/20/77	*C albicans*
WBC count	12/30/76	10,200/cu mm, 19% eosinophils
	3/3/77	7800/cu mm, 14% eosinophils
Immunoglobulin E level	1/10/77	25,000 units/ml* (normal, 25-150 units/ml)
Other immunoglobulin levels	1/17/77	IgG 2,306 mg/100 ml IgA 158 mg/100 ml IgM 313 mg/100 ml
Complement levels	1/20/77	CH50 260 (200 ± 20) C4 340,000 (96,000-280,000) C2 18,000 (4,000-9,000) C3 12,000 (6,500-12,000)

*One unit is approximately 2 ng.

140 mM sodium chloride, pH 7.4, containing 0.6 mM calcium chloride and 1.0 mM magnesium chloride. The final cell suspension contained approximately 2.5×10^6 neutrophils/ml.

Chemotaxis was assessed by the "leading front" method of Zigmond and Hirsch.[2] Aliquots of cell suspension were added to the upper compartments of modified Boyden chambers. These were separated from the lower compartments by 3-μm (pore diameter) micropore filters. The chemotactic stimulus was generated by incubating fresh serum with zymosan (1.0 mg/ml) at 37 C for 15 minutes. The activated serum was rendered free of particles by centrifugation (3,000 g) and diluted 1:10 with buffer before being added to the lower compartments of the chambers. The chambers containing cells and chemoattractant were incubated at 37 C for 90 minutes. The filters were then removed, fixed in methanol, stained with hematoxylin, dehydrated in ethanol, and cleared in xylene. Stained filters were examined as previously described.[2] The response of neutrophils to the chemotactic stimulus is reported as the distance the leading front of cells migrated into the micropore filter (μm/90 min).

Other neutrophil functions that were examined included selective lysosomal enzyme (β-glucuronidase and lysozyme) release and superoxide anion generation in response to exposure of cells to serum-treated zymosan particles.[3]

Measurement of Serum Levels of IgE

Serum levels of IgE were determined by radioimmunoassay, employing IgE test kits.

Table 2.—Chemotaxis Studies

Upper Compartment	Lower Compartment	Migration*
Normal neutrophils	Activated serum (normal)	107.6 ± 10.0
	Activated serum (patient)	99.6 ± 10.0
Patient's neutrophils	Activated serum (normal)	59.0 ± 11.5
	Activated serum (patient)	53.6 ± 9.5

*Migration is μm/90 min; mean ± SD; n = 3.

RESULTS

Results of three chemotaxis studies are summarized in Table 2. Regardless of the source of the zymosan-activated serum, the patient's neutrophils migrated toward the chemoattractant significantly less than normal cells. Despite the abnormal chemotactic responsiveness of the patient's cells, they responded to serum-treated zymosan by releasing lysosomal enzymes and by generating superoxide anion comparably to normal cells.

The level of IgE in the patient's serum was severely elevated by 25,000 units/ml (normal range, 25 to 150 units/ml). Serum from the patient's mother and brother contained 130 and 1,300 units/ml, respectively.

COMMENT

There are four major features of the hyperimmunoglobulin E syndrome.[1] One is recurrent pyogenic skin infections. These are usually staphylococcal, but streptococcal infections have also been reported.[1] These infections usually start in infancy and include abscesses, cellulitis, suppurative lymphadenitis, as well as more ill-defined lesions, described as "small superficial pustules" and "excoriated, crusted papulosquamous plaques."[4] Another feature is extreme elevations of serum IgE. These are usually 10 times, and often 100 times, that of normal values. A third characteristic is defective neutrophil chemotaxis, and a fourth, personal or family history of atopy. Many patients have atopic dermatitis. Others are described as having "eczema" but the skin findings are not further delineated, and it is not clear if these patients really have atopic dermatitis, other forms of eczema or, like our patient, chronic infections of the skin mistakenly diagnosed as "eczema."

Our patient had a family history of atopy, but did not have a personal history of asthma or hay fever and, on examination, had no manifestations of atopic dermatitis.

Most patients with the hyperimmunoglobulin E syndrome have a peripheral blood eosinophilia. In addition, patients may have other abnormalities. At least three patients have been reported with hyperimmunoglobulin E syndrome and mucocutaneous candidiasis.[5,6] Others had only oral candidiasis.[7,8] Some of these yeast infections may be due to the long-term use of antibiotics. Our patient had cutaneous candidiasis without evidence of oral or paronychial involvement.

"Job's syndrome" has been used to describe a subgroup of patients with the hyperimmunoglobulin E syndrome.[9] They are women who, in addition to displaying the major features of the hyperimmunoglobulin E syndrome, develop "cold" staphylococcal abscesses. In addition, they may have red hair and/or hyperextensible joints, but these last two features are not invariably present.

Many of the patients with hyperimmunoglobulin E syndrome (including those with Job's syndrome and mucocutaneous candidiasis) develop deep infections in addition to skin infections.[4,7,10] These infections include pneumonia, acute otitis media, osteomyelitis, pyogenic arthritis, and peritonitis.

Weston et al[8] described a patient with the features of hyperimmunoglobulin E syndrome, except that the in vitro neutrophil chemotaxis was normal. However, when tested in vivo, the neutrophil chemotaxis was abnormal.

The pathogenesis of the defective neutrophil chemotaxis in patients with the hyperimmunoglobulin E syndrome remains obscure. Hill and Quie[1] have postulated that histamine is responsible. In vitro, histamine increases cyclic adenosine 3′-5′monophosphate (cyclic AMP) in the neutrophil through an H2 receptor. This results in decreased chemotaxis, whereas IgE has no direct effect on chemotaxis.

Skin biopsy specimens from patients with the hyperimmunoglobulin E syndrome have been reported to show chronic nonspecific dermatitis or psoriasiform dermatitis.[10] The histologic findings in our case are consistent with the possibility that histamine is being released in the dermis. There are increased mast cells, dermal edema (which could be secondary to histamine from mast cells), and eosinophils (which could be secondary to eosinophilic chemotactic factor from mast cells).

In summary, we view the hyperimmunoglobulin E syndrome not as a specific disease, but as a constellation of features seen in different subgroups of patients. We stress that neither atopic dermatitis nor systemic infections have to be present to make this diagnosis.

This investigation was supported in part by Public Health Service grants 1 RO1 AI 13809-01 and AI 11103 from the National Institute of Allergy and Infectious Diseases, and by grant AM-18531.

References

1. Hill HR, Quie PG: Defective neutrophil chemotaxis associated with hyperimmunoglobulinemia E, in Bellanti JA, Dayton DH (eds): *The Phagocytic Cell in Host Resistance.* New York, Raven Press, 1975, pp 249-266.

2. Zigmond SH, Hirsch JG: Leukocyte locomotion and chemotaxis: New methods for evaluation, and demonstration of a cell-derived chemotactic factor. *J Exp Med* 137:387-410, 1973.

3. Goldstein IM, Roos D, Kaplan HB, Weissmann G: Complement and immunoglobulins stimulate superoxide production by human leukocytes independently of phagocytosis. *J Clin Invest* 56:1155-1163, 1975.

4. Hill HR, Quie PG: Raised serum-IgE levels and defective neutrophil chemotaxis in three children with eczema and recurrent bacterial infections. *Lancet* 1:183-187, 1974.

5. Clark RA, Root RM, Kimball HR, et al: Defective neutrophil chemotaxis and cellular immunity in a child with recurrent infections. *Ann Intern Med* 78:515-519, 1973.

6. Van Scoy RE, Hill HR, Ritts RE, et al: Familial neutrophil chemotaxis defect, recurrent bacterial infections, mucocutaneous candidiasis, and hyperimmunoglobulinemia E. *Ann Intern Med* 82:766-771, 1975.

7. Buckley RH, Wray BB, Belmaker EZ: Extreme hyperimmunoglobulinemia E and undue susceptibility to infection. *Pediatrics* 49:59-70, 1972.

8. Weston WL, Humbert JR, August CS, et al: A hyperimmunoglobulin E syndrome with normal chemotaxis in vitro and defective leukotaxis in vivo. *J Allergy Clin Immunol* 59:115-119, 1977.

9. Hill HR, Quie PG, Pabst HF, et al: Defect in neutrophil granulocyte chemotaxis in Job's syndrome of recurrent "cold" staphylococcal abscesses. *Lancet* 2:617-619, 1974.

10. Dahl MV, Greene WH, Quie PG: Infection, dermatitis, increased IgE, and impaired neutrophil chemotaxis. *Arch Dermatol* 112:1387-1390, 1976.

Childhood Pemphigus Treated With Gold

Robert L. Paltzik, MD, Teresita A. Laude, MD

• A case of childhood pemphigus is reported. The natural history of this rare entity and past methods of treatment are reviewed. We also report on what is to our knowledge the first known use of gold in the treatment of childhood pemphigus. This modality appears to have been of benefit in our patient to date.

(*Arch Dermatol* 114:768-769, 1978)

Pemphigus vulgaris is characteristically a chronic vesiculobullous disease affecting middle-aged people and only rarely appearing in childhood.[1,2] Until the advent of immunofluorescence techniques, precise evaluation of previous reports of pemphigus in children has been hindered by the early usage of the term pemphigus to include a multitude of unrelated vesiculobullous diseases. These include erythema multiforme bullosum, toxic epidermal necrolysis, dermatitis herpetiformis, bullous pemphigoid, and chronic bullous dermatosis of childhood.[3]

As of 1976, only eight patients with childhood pemphigus vulgaris, proved by biopsy, and six others with pemphigus foliaceus have been reported.[3-16] Only the most recent four patients reported with pemphigus vulgaris and only the most recent two with pemphigus foliaceus had confirmatory immunofluorescence studies. The male-female ratio in the eight cases of pemphigus vulgaris was equal, but five of the six patients with pemphigus foliaceus were females. The youngest documented patient with pemphigus vulgaris was a 3½-year-old boy,[11] whereas an 18-month-old girl with pemphigus foliaceus has been described.[3]

REPORT OF A CASE

A 4-year-old girl was healthy until August 1975 when a blister was noted on the dorsum of her right foot. The blister was soon followed by crops of clear vesicles that appeared on her lower legs and ankles. The eruption was diagnosed as "bullous impetigo" and treated with bacitracin ointment by her pediatrician but to no avail. Two weeks later, after the blisters had spread to involve the trunk, arms, and face, she was hospitalized. *Staphylococcus aureus* grew from culture of the bullae fluid and she was treated with soaks and erythromycin. She improved partially and was discharged after two weeks. The lesions recurred a month later and she was admitted to Kings County Hospital.

On initial examination, the child appeared well nourished, slightly apprehensive, but in no acute distress. Blood pressure was 98/70 mm Hg, height was 108 cm (50th percentile), and weight was 17.7 kg (48th percentile). There were some intact as well as numerous ruptured bullae with raw oozing surfaces scattered about her scalp, back, abdomen, and extremities (Figure). The oral and vaginal mucosa were not involved. Nikolsky sign was positive. Otherwise, the results of the examination were within normal limits. Aspirate from a bulla was sterile and *S epidermidis* grew from a skin culture. A skin biopsy was performed and revealed an acantholytic vesicle located in the lower malpighian layers, which was interpreted as pemphigus vulgaris. Direct immunofluorescence performed on skin from the edge of a vesicle was positive for antibodies to intercellular substance (ICS) of epithelial tissues. Indirect immunofluorescence for ICS antibodies was positive at a 1:320 serum dilution before any corticosteroid therapy was begun.

During the next two months, varying doses of daily oral corticosteroids were necessary to control her disease. However, each time her dose of prednisone was reduced to less than 40 mg orally every day, she had an exacerbation of her pemphigus. Finally, prednisone was increased to 50 mg orally every day and the first dose of aurothioglucose (Solganal) 2.5 mg intramuscularly, was administered. At this time, the patient's weight was >>97th percentile, while height had remained unchanged at 108 cm (50th percentile) since the institution of corticosteroid therapy. To date, she has received 480 mg of gold for a period of 32 weeks (15 mg intramuscularly weekly). Findings from weekly blood counts, serum electrolytes, liver function tests, and urinalyses have been normal. After six to seven weeks, she became less cushingoid and her weight had decreased by 6 kg. During this time, we were able to decrease the prednisone therapy to 2.5 mg every other day with only occasional occurrence of an isolated vesicle on the legs. Intercellular substance antibody titers were negative during this period of remission.

COMMENT

Several of the eight children with pemphigus vulgaris previously described had a severe and progressive course and required aggressive treatment with large doses of corticosteroids for control. Exacerbations were common. Two patients died from

Photograph of patient before any treatment.

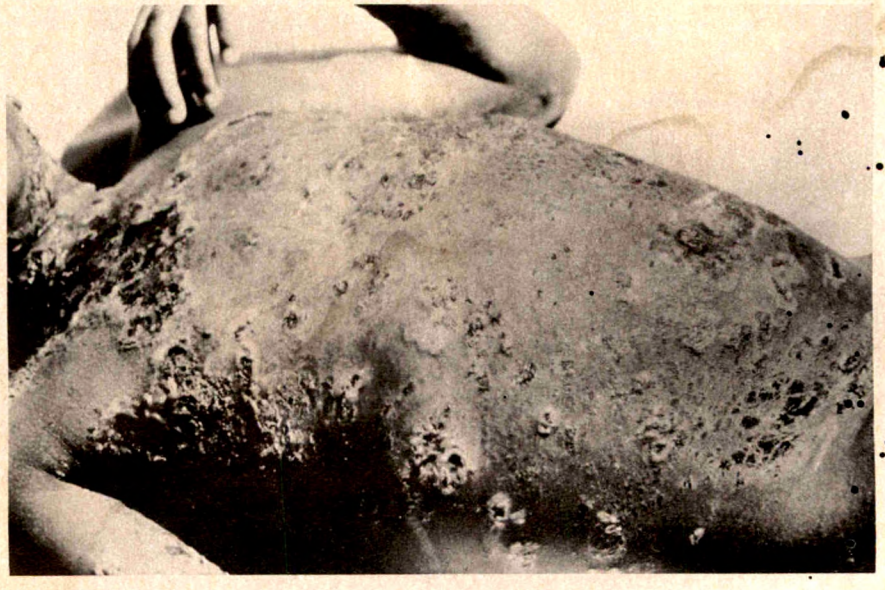

Accepted for publication Feb 16, 1977.

From the Division of Dermatology (Dr Paltzik), and the Department of Pediatrics (Dr Laude), State University of New York Downstate Medical Center, Brooklyn. Dr Paltzik is now in private practice in Williston Park, NY.

Presented before the Section on Dermatology, New York Academy of Medicine, New York, May 4, 1976.

Reprint requests to Division of Dermatology, State University of New York Downstate Medical Center, 450 Clarkson Ave, Box 46, Brooklyn, NY 11203 (Dr Paltzik).

septicemia within one year of onset of symptoms while receiving very high doses of corticosteroids. All of the undesirable corticosteroid side effects seen in adults occurred,[4-12] but in addition, growth retardation was a disturbing problem in younger patients who could not be maintained on alternate-day therapy.[17-18]

In contrast, the six children with pemphigus foliaceus seemed to follow a less fulminant course. An 18-month-old girl obtained regression of her lesions with application of 0.5% triamcinolone acetonide cream, without occlusion, six times a day.[3] Others have noted that such therapy is efficacious but only under occlusion.[14-16]

However, the favorable responses in these children with topical steroid therapy alone may have been due to the benign remitting course of childhood pemphigus foliaceus noted by others. Finally, a note of caution is certainly indicated because of a recent report of a 3-year-old boy with pemphigus foliaceus who required prednisone, 140 mg orally daily, for effective control and whose conditioned flared when steroid treatment was discontinued.[13]

There has been no report of the use of immunosuppressants in children for the treatment of pemphigus although methotrexate, cyclophosphamide, and azathioprine have been helpful in controlling pemphigus in some adult patients. We thought that the well-documented potentially toxic effects of these agents made them unwise choices for long-term use in our patient.[20-26] Of special significance mitigating against the use of cyclophosphamide in children have been recent reports in the pediatric literature linking its use in patients with steroid-resistant nephrotic syndrome to azoospermia and oligospermia in boys and amenorrhea in girls. In some of these children, this effect persisted months to years after cessation of drug therapy. Also, a slight increase in the incidence of tumors has been documented in animals after prolonged administration.[24] Azathioprine may be associated with an increased incidence of lymphoproliferative disorders in children. This effect has been seen in children given azathioprine after renal transplantation.[26]

Recently, Penneys and his co-workers[27,28] reported that 14 of 18 adults with pemphigus vulgaris have been successfully managed with gold, the youngest a 19-year-old woman. As of February 1976, 56% are in remission of up to four years requiring no treatment, while the remaining patients are receiving just maintenance gold.[27-28] Gold in comparable doses has been used for years without serious problems in children and adults with rheumatoid arthritis. Although the toxic effect of gold, manifested most commonly by various skin eruptions, nephrotic syndrome, and suppression of hematological factors can occur, it is almost always reversible.[29-30] The dosage of gold administered to children is simply calculated as a proportion of the adult dose, governed chiefly by body weight.

Although the exact mechanism of action of gold is unknown, it has been demonstrated that gold inhibits prostaglandin synthesis as well as some human epidermal enzymes in vitro.[31] Phagocytic activity of macrophages and neutrophils has been found to be suppressed in patients receiving gold, but gold itself has not been shown to alter immunologic mechanisms.[32-33] Therefore, gold may act in pemphigus by interrupting the inflammatory cycle and by inhibiting degradative lysosomal enzymes involved in blister formation.[31]

It must be emphasized that in patients already suppressed with steroids, a lag time of at least six to eight weeks is required before a reduction in steroids can be considered.[28] Our patient has now received chrysotherapy for 32 weeks with a total dose of 480 mg of gold having been administered. Although she has responded very favorably, it is still impossible to draw conclusions from this single case. Additional studies certainly will be needed to shed further light on this mode of therapy.

The biopsy specimens and immunofluorescence procedures were performed and interpreted by Dr Louis Pertschuk.

References

1. Lever WF: Pemphigus, in Fitzpatrick T, Arndt KA, Clark WH, et al (eds): *Dermatology in General Medicine*. New York, McGraw-Hill Book Co, 1971, pp 644-659.
2. Rook A, Wilkinson DS, Ebling F (eds): *Textbook of Dermatology*. Oxford, England, Blackwell Scientific Publications, 1972.
3. Kahn G, Lewis HM: True childhood pemphigus: Pemphigus foliaceus in an 18-month-old child: Immunofluorescence as a diagnostic aid. *Am J Dis Child* 121:253-256, 1971.
4. Mintzer IJ, Rubin Z: Pemphigus vulgaris in a 13-year-old girl. *NY State J Med* 55:1903-1907, 1955.
5. Pemphigus vulgaris, SOCIETY TRANSACTIONS. *Arch Dermatol* 73:619-621, 1956.
6. Lehman R, Landau TW, Newcomer VD: Pemphigus vulgaris in a 12-year-old male. *J Pediatr* 67:264-269, 1965.
7. Petkov I, Georgiewa A: Uber Pemphigus vulgaris in Kindersalter. *Hautarzt* 17:256, 1966.
8. Jordon RE, Ihring JJ, Perry HO: Childhood pemphigus vulgaris: Report of a case. *Arch Dermatol* 99:176-179, 1969.
9. Murphy PJ, Harrell ER: Pemphigus vulgaris in childhood. *Am J Dis Child* 123:70-71, 1972.
10. Elias PM, Jarrat M, Zalitas IE, et al: Childhood pemphigus vulgaris. *N Engl J Med* 287:758-760, 1972.
11. Berger BW, Maier HS, Kantor I, et al: Pemphigus vulgaris in a 3½-year-old boy. *Arch Dermatol* 107:433-434, 1973.
12. Bean SF, Jordan RE, Winkelmann RK, et al: Chronic nonhereditary blistering disease in children. *Am J Dis Child* 122:137-141, 1971.
13. Schroeter A, Sams WM Jr, Jorden RE: Immunofluorescence studies of pemphigus foliaceus in a child. *Arch Dermatol* 100:736-740, 1969.
14. Petratos MA, Andrade R: Pemphigus erythematosus: Report of a case in a child less than 6 years of age. *Am J Dis Child* 133:394-397, 1967.
15. Perry HO, Brunsting LA: Pemphigus foliaceus: Further observations. *Arch Dermatol* 91:10-23, 1965.
16. Tye MJ, Blumental G, Lever WF: Pemphigus erythematosus: Favorable response to topical therapy. *Arch Dermatol* 90:307-309, 1964.
17. Rabhan NB, Kopf AW: Alternate-day prednisone therapy for pemphigus vulgaris: Preliminary report. *Arch Dermatol* 103:615-622, 1971.
18. Soyka LF, Saxena KM: Alternate-day corticosteroid therapy for nephrotic children. *JAMA* 192:225-230, 1965.
19. Lever WF, White H: Treatment of pemphigus with corticosteroids: Results obtained in 46 patients over a period of 11 years. *Arch Dermatol* 87:12-26, 1963.
20. Lever WF, Goldberg HS: Treatment of pemphigus vulgaris with methotrexate. *Arch Dermatol* 100:70-78, 1969.
21. Lever WF: Methotrexate and prednisone in pemphigus vulgaris: Therapeutic results obtained in 36 patients between 1961-1970. *Arch Dermatol* 106:491-497, 1972.
22. McKelvey EM, Hasegawa J: Cyclophosphamide and pemphigus vulgaris. *Arch Dermatol* 103:198-200, 1971.
23. Ehringer A, MacKay IR: Pemphigus vulgaris successfully treated with cyclophosphamide. *Ann Intern Med* 71:125-127, 1969.
24. Penso J, Lippe B, Ehrlich R, et al: Testicular function in prepubertal and pubertal male patients treated with cyclophosphamide for nephrotic syndrome. *J Pediatr* 84:831-836, 1974.
25. Burton JL, Greaves MW, Marks J, et al: Azathioprine in pemphigus vulgaris. *Br Med J* 3:84-86, 1970.
26. Roenigk HH Jr, Deodhar A: Pemphigus treatment with azathioprine: Clinical and immunologic correlation. *Arch Dermatol* 107:353-357, 1973.
27. Penneys NS, Eaglstein W, et al: Gold sodium thiomalate treatment of pemphigus. *Arch Dermatol* 108:56-59, 1973.
28. Penneys NS, Eaglstein WH, Frost P: Management of pemphigus with gold compounds. *Arch Dermatol* 112:185-187, 1976.
29. Soler-Bechara J, Kammerer WD, Rogoff B, et al: Maintenance gold therapy for rheumatoid arthritis: Analysis in 167 patients. *Arthritis Rheum* 8:469-470, 1965.
30. The Research Subcommittee of the Empire Rheumatism Council: Gold therapy in rheumatoid arthritis: Final report of a multicentre controlled trial. *Ann Rheum Dis* 20:315, 1961.
31. Penneys NS, Ziboh V, et al: Inhibition of prostaglandin synthesis and human epidermal enzymes by aurothioglucose in vitro. *J Invest Dermatol* 63:356-361, 1974.
32. Jessop JD, Roberts V, Harris J: Effects of gold salts and prednisone on inflammatory cells. *Ann Rheum Dis* 32:294-307, 1973.
33. Persellin RH, Hess Ev, Ziff M: Effect of a gold salt on the immune response. *Arthritis Rheum* 10:99-105, 1967.

Unilateral Segmental Hyperhidrosis

Response to 20% Aluminum Chloride Solution and Plastic Wrap

Aaron Dworin, MD, Arthur J. Sober, MD

• A young woman had unilateral dermatomal hyperhidrosis documented by a starch-iodine technique. Evaluation failed to reveal any associated causative conditions. She was treated with 20% aluminum chloride hexahydrate solution in absolute alcohol (Drysol) with a favorable response. With recurrent use, however, she developed miliaria following exertion. Aluminum chloride hexahydrate was shown to be an effective agent to treat this unusual condition, but miliaria with exertion secondary to its use may be a limiting factor.

(*Arch Dermatol* 114:770-771, 1978)

Problems of increased sweating can be a difficult challenge to the physician. The usual patient complains of increased sweating of the palms, soles, or axillae. We wish to report a case where the complaint was truncal hyperhidrosis and in which a favorable response to a new therapeutic formulation, 20% aluminum chloride hexahydrate in absolute alcohol (Drysol), was noted.

REPORT OF A CASE

A healthy, 23-year-old woman complained of increased sweating on the right side of her torso during hot weather, with exertion, or while eating hot foods. The problem had been present for the previous two years. She related that the sweat would saturate her clothing. Her major complaint was social embarrassment. She denied feeling excessively anxious at these times and denied noting increased sweating in other areas. She had no problems with her hair, teeth, nails, or skin. Past history was unremarkable. Specifically, she had no history of diabetes or of orthopedic injuries and voiced no neurological complaints. Her mother had had a malignant melanoma treated surgically. There was no family history of similar problems with abnormal sweating.

On physical examination her skin, hair, and nails were normal as were results of neurological examination. It was noted that her sweat soaked the white paper cover of her gown and the examining table sheet only on the right side. Further study with starch iodine, using a previously described technique[1,2] revealed increased sweating unilaterally involving the eighth thoracic right-sided dermatome (Fig 1 and 2). Starch iodine testing was also performed on other areas, including the axillae, the palms, and the soles in order to rule out the possibility that her abnormality was a form of compensatory hyperhidrosis secondary to hypohidrosis elsewhere. This testing confirmed uniform sweat gland function, except for the marked increase in the areas illustrated. Spine films were normal and neurological consultation revealed no abnormalities.

Repeated testing confirmed the stable nature of the defect. Oral anticholinergics, glycopyrrolate (Robinul), were tried without relief and subsequently a 20% aluminum chloride solution in absolute alcohol was used. The trunk was treated initially without occlusion to avoid irritation. However, after one week no response was noted. When used with plastic wrap, sweating was greatly diminished after three consecutive nightly applications. Once effective, the response could be maintained by weekly treatments. For the first several weeks no irritation, discomfort, heat intolerance, or alteration in sweat pattern in nontreated areas occurred. However, following exercise the patient noted the development of tiny whitish nonpruritic "bumps" over the treated area that resembled miliaria clinically and that resolved with discontinuation of the medication. She would then note recurrence of the same unilateral sweating pattern.

COMMENT

The palms, soles, and axillae are the most frequent sites of involvement in patients complaining of hyperhidrosis.[3] The problem can be socially embarrassing or occupationally hazardous. Various therapeutic techniques have been developed for treating the palms and soles, including treatment with methenamine in stick form,[4] topical glutaraldehyde,[5] anticholinergics orally, topically and by aerosol,[6] as well as by iontophoresis.[7,8] In addition, behavior therapy, utilizing techniques of systematic desensitization and assertiveness training,

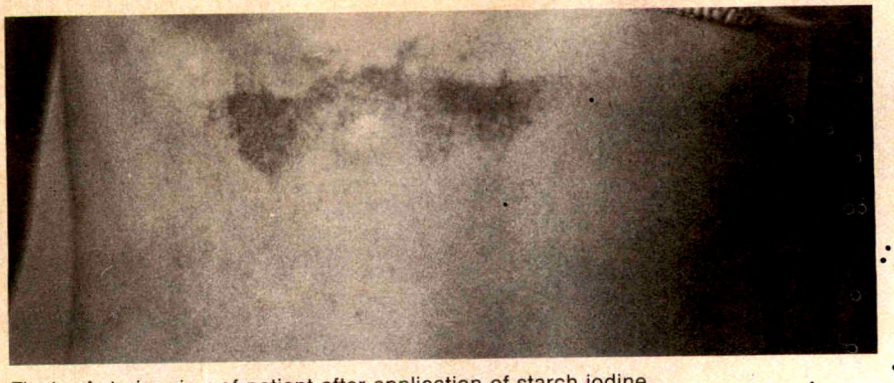

Fig 1.—Anterior view of patient after application of starch iodine.

Accepted for publication July 27, 1977.

From the Departments of Dermatology, Massachusetts General Hospital and Harvard Medical School, Boston. Dr Dworin is now with the Department of Internal Medicine, University of Michigan Medical Center, Ann Arbor.

Reprints not available.

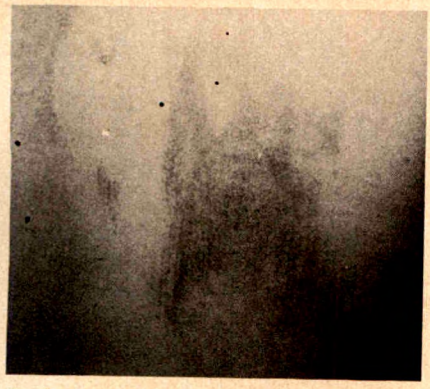

Fig 2.—Posterior view showing delineation of hyperhidrosis along T8 dermatome (following application of starch iodine).

has been claimed useful.[9] In extreme cases sympathectomy has been used, with good results. However, sympathectomy has both perioperative and postoperative complications, prominent among which is compensatory hyperhidrosis in other locations.[10]

Most of the above modalities have been less effective for axillary hyperhidrosis. Surgical excision of axillary skin (both large procedures and smaller elliptical excisions) has been shown to be useful.[11,12] Recently, 20% aluminum chloride hexahydrate in absolute alcohol has been shown to be effective for hyperhidrosis of the axillae, palms, and soles.[13,14] Its mechanism of action is unknown. However, Shelley and Hurley[13] postulate that the effect is mediated through the aluminum ion entering by capillarity and reflux into the terminal sweat pore, combining with intraductal keratin and producing functional closure of the duct. Furthermore, they suggest that because of aluminum's antibacterial action miliaria does not develop.

The problem of localized hyperhidrosis is less common, and experience with the above therapies is correspondingly less. The majority of cases of localized or unilateral hyperhidrosis have been reported with organic nervous system disease, eg, neuritis, myelitis, syringomyelia, and tabes dorsalis.[15,16] In addition, there have been reports of multisegmental hyperhidrosis associated with pleural and presumably intercostal nerve spread of bronchogenic carcinoma.[17,18] Pool has reported a case caused by an osteoma of the tenth thoracic vertebra,[19] and postulated that the abnormality was caused by irritation of anterior root(s). A case has also been reported in association with a cervical rib.[20] Additional reports have appeared of involvement of dermatomes affected by an intramedullary glioma and below the level of traumatic hemisection of the spinal cord.[20] Other causes of unilateral hyperhidrosis have been of an essential or idiopathic nature,[21,22] the category to which our case corresponds. The origin of this condition is unclear. Normally, sweating on the back has been found to be symmetrical.[23,24] However, in cases of idiopathic unilateral hyperhidrosis one could postulate either an increased responsiveness to sympathetic stimuli or an increase in the stimuli themselves. Histological study of areas of localized hyperhidrosis has shown both normal and increased number and size of glands, but, of course, it is unknown whether an increase in size and number of glands is primary or secondary to increased sympathetic stimulation.

A further unusual feature of this case is the involvement of a solitary dermatome. As Pool[19] has stated, stimulation of a single anterior root usually results in sympathetic effects over the distribution of numerous sympathetic ganglia. Furthermore, there is a dermatomal overlap of sympathetic innervation. Therefore, abnormality over the distribution of a solitary dermatome is distinctly unusual and difficult to explain physiologically. In Pool's case hyperhidrosis began along the T10 dermatome but evolved rapidly over five months to involve the left trunk from the axilla to T12. In one year of follow-up our patient has shown no change in her sweating pattern.

We have presented a case of a rather uncommon entity—idiopathic unilateral segmental truncal hyperhidrosis. In addition, we report its response to 20% aluminum chloride hexahydrate in absolute alcohol. As noted, the exact mechanism of action of this medication in unknown. "Functional" poral closure has been postulated and miliaria was said not to occur because of the antibacterial action of aluminum. However, our case suggests that miliaria formation can indeed occur. Thus, exercise leading to increased sweat production in the face of a blocked or partially blocked duct could predispose to the development of miliaria. Disappearance of the lesions with discontinuation of the medication further supports this thesis. Thus, we wish to point out this medication's potential for miliaria formation when it is used under occlusion.

References

1. Wada M: Sudorific action of adrenalin. *Science* 111:376-377, 1950.
2. Muller SA, Kierland RR: The use of a modified starch-iodine test for investigating local sweating responses to intradermal injection of methacholine. *J Invest Dermatol* 32:126-128, 1959.
3. Rook A, Wilkinson DS, Ebling FJG: *Textbook of Dermatology*, ed 2. Oxford, England, Blackwell Scientific Publications, 1972, p 1517.
4. Cullen SI: Topical methenamine therapy for hyperhidrosis. *Arch Dermatol* 111:1158-1160, 1975.
5. Gordon H: Hyperhidrosis: Treatment with glutaraldehyde. *Cutis* 9:375-378, 1972.
6. Frankland JC, Seville RH: The treatment of hyperhidrosis with topical propantheline: A new technique. *Br J Dermatol* 85:577-581, 1971.
7. Abell E, Morgan K: The treatment of idiopathic hyperhidrosis by glycopyrronium bromide and tap water iontophoresis. *Br J Dermatol* 91:87-91, 1974.
8. Grice K, Sattar H, Baker H: Treatment of idiopathic hyperhidrosis with iontophoresis of tap water and poldine methosulphate. *Br J Dermatol* 86:72-78, 1972.
9. Bar L, Kuypers B: Behaviour therapy in dermatological practice. *Br J Dermatol* 88:591-598, 1973.
10. Shelley WB, Florence R: Compensatory hyperhidrosis after sympathectomy. *N Engl J Med* 263:1056-1058, 1960.
11. Munro D, Verbov JL, O'Gorman DJ, et al: Axillary hyperhidrosis: Its quantification and surgical treatment. *Br J Dermatol* 90:325-329, 1974.
12. Gillespie JA, Kane SP: Evaluation of a simple surgical treatment of axillary hyperhidrosis. *Br J Dermatol* 83:684-689, 1970.
13. Shelley WB, Hurley HJ: Studies on topical antiperspirant control of axillary hyperhidrosis. *Acta Derm Venereol* 55:251-260, 1975.
14. Abramowitz M, ed: The new antiperspirant. *Med Lett Drugs Ther* 19:20, 1977.
15. Goldstein N: Ephidrosis (local hyperhidrosis) nevus sudoriferous. *Arch Dermatol* 96:67-68, 1967.
16. Sulzberger MD, Kerrman F: *The Clinical Significance of Disturbances in the Delivery of Sweat*. Springfield, Ill, Charles C Thomas Publisher, 1954, p 39.
17. Walsh JC, Low PA, Allsop JL: Localized sympathetic overactivity: An uncommon complication of lung cancer. *J Neurol Neurosurg Psychiatry* 39:93-95, 1976.
18. Middleton WG: Bronchial carcinoma with pleural spread causing unilateral thoracic hyperhidrosis. *Br Med J* 2:563, 1976.
19. Pool JL: Unilateral thoracic hyperhidrosis caused by osteoma of the tenth dorsal vertebra. *J Neurosurg* 13:111-115, 1956.
20. Telford ED: Cervical rib and hyperhidrosis. *Br Med J* 2:96, 1942.
21. Champion RH, Herxheimer A: Unilateral hyperhidrosis of the trunk. *Acta Med Scand* 168:17-20, 1960.
22. Cunliffe WJ, Johnson CE, Williamson DM: Localized unilateral hyperhidrosis: A clinical and laboratory study. *Br J Dermatol* 86:374-378, 1972.
23. Coggins JH, Griffin TB: Evaluation of the symmetry of sweating on the back. *J Invest Dermatol* 55:282-283, 1970.
24. Gibinski K, Giec L, Zmudzinski J, et al: Body side related asymmetry in sweat gland function. *J Invest Dermatol* 57:190-192, 1971.

The Sézary Syndrome

A Case With Fetal-type Glycogen and Lymphocytic Lymphoma

Max G. Menefee, MD, PhD; David C. Zellner, MD; Robert C. Wright, MD

• A patient had Sézary syndrome and lymphocytic lymphoma. Cytoplasmic inclusions within the Sézary cells were demonstrated by histochemistry and electron microscopy to be composed of fetal-type glycogen. Results of tests for the presence of virus were negative. It is suggested that the Sézary cell represents a reversion of metabolic systems to more youthful types. Previously reported differences in diastase reactivity of the PAS-positive cytoplasmic inclusions are probably based on whether the glycogen is in fetal or mature configuration.

(*Arch Dermatol* 114:772-774, 1978)

Hallopeau and Besnier,[1] in 1892 at the Second International Congress on Dermatology and Syphilography, described an erythroderma that they believed was a variant of mycosis fungoides and that was characterized by thickening of the skin, severe pruritus, and adenopathy. In 1938, Sézary and Bouvrain presented a case report, which they entitled "Erythroderma with the presence of large cells in the skin and blood."[2] In recent years, these large cells have been studied immunologically and ultrastructurally, and they have been found to have immunologic markers for T-lymphocytes[3-5] and a characteristic morphology with a convoluted nucleus and relatively sparse cytoplasm.[6-8] PAS-positive cytoplasmic inclusions were among the first characteristics described; they were variously indicated to be diastase soluble[7] or diastase resistant.[6] The following report describes unusual glycogen inclusions in the Sézary cells of a patient with the Sézary syndrome and lymphocytic lymphoma.

REPORT OF A CASE

In 1969, erythroderma developed in a 61-year-old man. Generalized lymphadenopathy developed in 1972. He had a mild leukocytosis from 1972 until 1974, with WBC counts ranging from 10,000 to 11,800/cu mm. In June 1974 the erythroderma appeared more severe, and thickening of the skin was noted.

Accepted for publication July 29, 1977.

From the Departments of Pathology (Dr Menefee), Hematology (Dr Zellner), and Dermatology (Dr Wright), College of Medicine, University of Cincinnati.

Reprint requests to Department of Pathology, College of Medicine, University of Cincinnati, Cincinnati, OH 45267 (Dr Menefee).

He was hospitalized in November 1974 because of progressive pruritus, adenopathy, and edema of the skin. At that time, he had erythematous, thick, and folded skin (Fig 1). Generalized lymphadenopathy was present, with most of the nodes enlarged to a diameter of approximately 2 cm. There were two nodes measuring 5 cm in diameter in the left inguinal region. No evidence of hepatomegaly or splenomegaly was noted.

Laboratory values at the time of admission included a complete blood cell count with the following results: hematocrit, 39.7%; hemoglobin, 13.0 g/dl; and WBCs, 106,500/cu mm, most of which were atypical lymphocytes. Some of these cells had large convoluted nuclei with sparse cytoplasm and contained PAS-positive inclusions in the cytoplasm. These inclusions showed minimal decrease in PAS staining after diastase digestion. The erythrocyte sedimentation rate was 6 mm/hr. The uric acid level was 8.1 mg/dl (normal, 2.5 to 8 mg/dl). The serum lactic dehydrogenase concentration was greater than 600 units/ml, with an isoenzyme pattern consistent with destruction of WBCs. Measurement of the immunoglobulins showed a decrease in the IgA level to 95 mg/dl (normal, 115 to 424 mg/dl); the IgG level, 610 mg/dl (normal, 804 to 1,684 mg/dl); and the IgM level, 45 mg/dl (normal, 50 to 190 mg/dl). Normal results were obtained for serum protein electrophoresis, routine urinalysis, and 24-hour urine excretion of catecholamines and hydroxyindoleacetic acid. The plasma histamine level was normal; however, the whole blood histamine level was increased. An intravenous pyelogram was normal. Chest x-ray films showed a mass in the superior mediastinum. Bipedal lymphangiograms resulted in a diffuse foamy appearance of both the iliac and periaortic nodes, many of which were enlarged, indicating involvement of these nodes by lymphoma. A biopsy specimen of an axillary node was interpreted as malignant lymphoma, diffuse lymphocytic type (Fig 2 and 3). Liver biopsy showed infiltration of the portal tracts with lymphoid cells.

A skin biopsy specimen demonstrated a dense infiltrate of atypical lymphoid cells in the upper portion of the dermis. Touch preparations taken at the time of biopsy showed atypical lymphoid cells, some of which resembled Sézary cells with sparse cytoplasm and large folded nuclei. Spontaneous rosette formation occurred with 51% of the patient's lymphocytes when they were exposed to sheep erythrocytes.

Systemic therapy with chlorambucil, 2 mg twice daily, and prednisone, 10 mg four times daily, was begun in November 1974. The condition initially responded with decreasing pruritus and adenopathy. A plateau was reached in January 1975, at which time a program of weekly intravenous injections of 2 mg of vincristine sulfate was instituted. The patient's condition continued to improve, with further decrease in pruritus, adenopathy, and erythroderma. A skin biopsy performed in February 1975 showed a decrease in the cellular infiltrate in the skin.

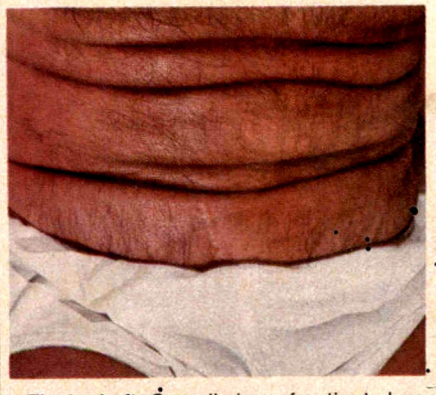

Fig 1.—Left, Overall view of patient shows generalized erythema and skin folds. Right, Erythema and thickening of skin.

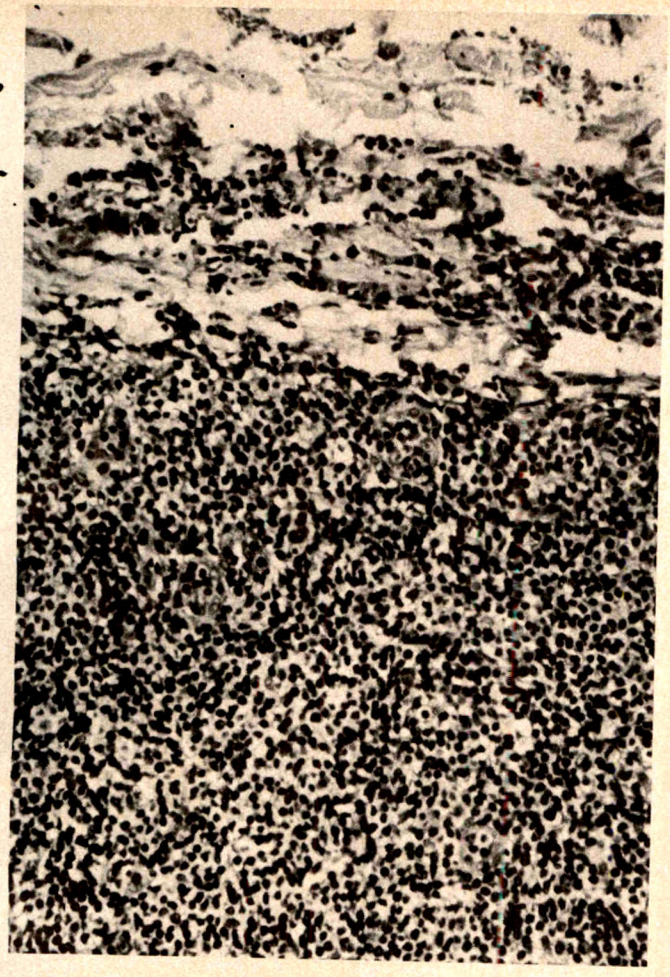

Fig 2.—Portion of lymph node exhibits loss of architecture and infiltration of capsule (original magnification ×240).

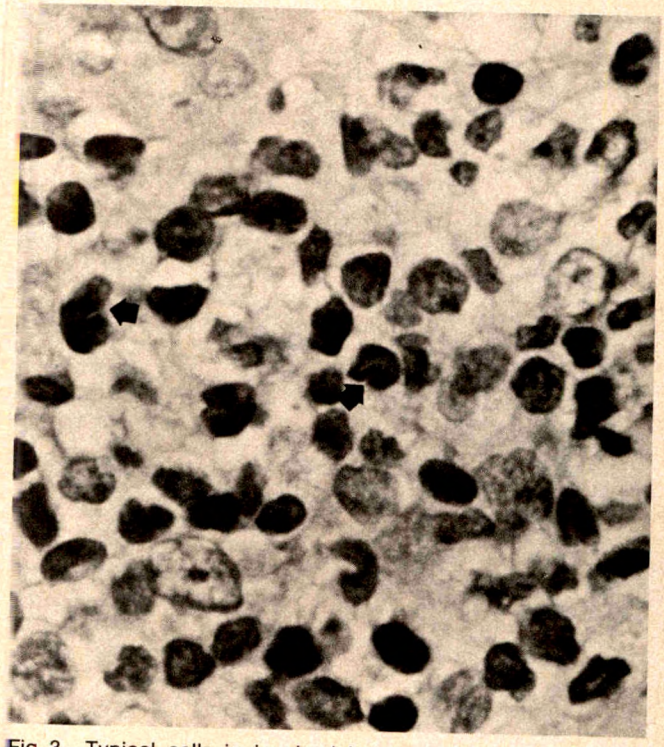

Fig 3.—Typical cells in involved lymph node. Arrows indicate Sézary cells with folded nuclei (original magnification ×1,600).

MATERIALS AND METHODS

Peripheral blood was drawn and immediately processed for electron microscopy by the technique of Watanabe et al[9] and was embedded in epoxy resin. Thin sections were stained with lead citrate and uranyl acetate, or were stained with lead hydroxide alone or uranyl acetate alone. Electron micrographs were made at operating voltages of 60 or 80 kV.

For study of possible virus infection, the buffy coat was separated from a whole-blood specimen and was inoculated into the following cell cultures: primary monkey kidney (rhesus and African Green), Vero monkey kidney, human fibroblastic lung (W1-38), and HeLa. All cultures were observed for cytopathic effects and were tested for hemadsorption with guinea pig erythrocytes and for interference with coxsackievirus. The patient's WBCs were also inoculated into suckling mice and embryonated eggs. Primary leukocyte cultures were established from buffy coat and tested for the presence of Epstein-Barr virus by the fluorescent antibody technique.

RESULTS

Electron microscopy of sections from a pellet composed of buffy coat cells demonstrated that the atypical lymphocytes had a serpentine nuclear outline characteristic of the Sézary cell (Fig 4). In addition, unusual cytoplasmic glycogen inclusions were noted (Fig 4 and 5). The inclusions were composed of aggregates of particles with diameters of 220 to 330 A. This arrangement constitutes the beta form of glycogen. Each particle was composed of short filaments of 30 A in diameter (gamma particles) embedded in a less dense matrix (Fig 6). The particles were stained with lead hydroxide but not with uranyl acetate. The aggregates were not enclosed by any membrane and occasionally were associated with cytoplasmic organelles (Fig 5). Results of all the viral studies were negative.

The erythroderma, pruritus, skin edema, and circulating atypical lymphocytes demonstrated in this case were typical of the Sézary syndrome.[10] The abnormal findings on lymphangiogram and from lymph node biopsy substantiated the additional diagnosis of lymphocytic lymphoma. With the sheep erythrocyte rosette test, 51% of the lymphocytes were identified as T cells. Since the normal proportion of T cells is of the order of 70%, and since the Sézary cell seems to be a T-lymphocyte, a higher value might have been expected for this test. However, if the Sézary cells are thymus-derived but possess deficient metabolic systems that are unable to produce the membrane receptors needed to attach to sheep erythrocytes in order to form rosettes, then the

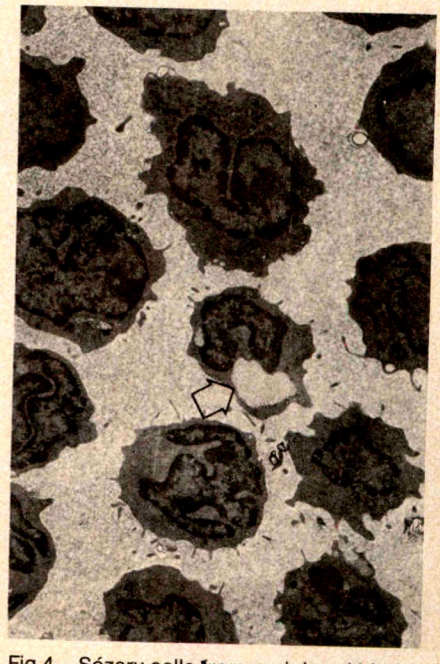

Fig 4.—Sézary cells from peripheral blood. Arrow indicates characteristic inclusion (original magnification ×3,900).

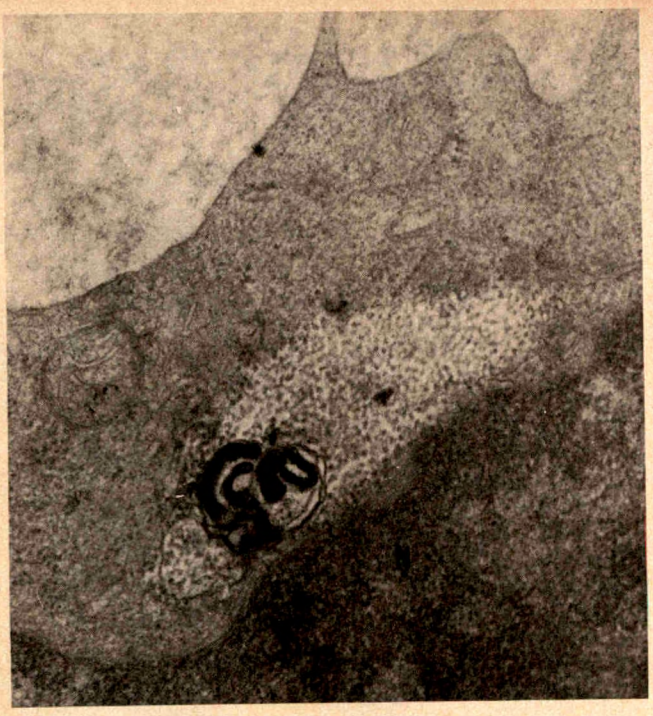

Fig 5.—Typical inclusion above nucleus (N). Beta configuration of particles is seen. Myelin figure looks like artifact (original magnification ×33,800).

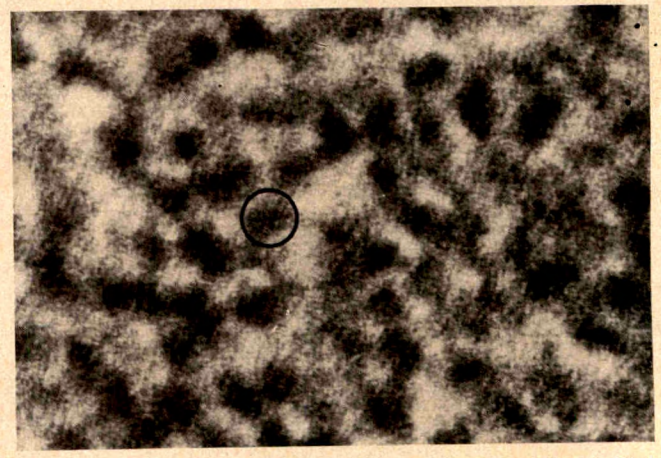

Fig 6.—Detail of substructure of typical beta particle (circle); 30 A gamma particles are seen within larger granules (original magnification ×270,400).

finding of only 51% reactive cells would not be surprising.

COMMENT

PAS-positive inclusions were among the first abnormalities described in the cytoplasm of the Sézary cells. Some workers reported them to be diastase-soluble,[7,11] whereas others reported diastase-resistant inclusions.[6] Lutzner and Jordan described the ultrastructure of two types of cytoplasmic inclusions—"glycogen-aggregates" and "electron dense granules"—that they believed could account for the difference in diastase digestion.[12] The glycogen aggregates demonstrated by the latter authors were of the alpha-type and the electron dense granules were lysosomes. Lysosomes have never been reported to be PAS-positive, although the alpha glycogen would stain with the PAS procedure and would be digested by diastase. It would seem more likely that the basis of the differing diastase reactivity reported by the various workers lies in differing configurations of glycogen. The glycogen observed in this patient is morphologically similar to fetal glycogen. Since fetal glycogen is resistant to the action of diastase (Mary Bell, oral communication, November 1976) and the glycogen of the present case is also resistant, we believe we are justified in referring to the glycogen content of the Sézary cells described here as "fetal glycogen." The fact that it appears in the present patient may reflect a return to a more developmentally primitive metabolic process in these cells.

Zucker-Franklin described membrane-bound inclusions with electron-dense particles that she compared with structures seen in virus-infected tissue culture cells.[8] She also noted vesicles with electron-dense inner membranes and unusual intranuclear particles that were about 400 A in diameter and that formed imperfect crystalline arrays. We found no such structure in the lymphocytes of this patient.

All attempts to demonstrate virus in this patient produced negative results. Unfortunately, the blood cells for the studies were obtained after therapy had been initiated.

The presence of Sézary-like cells in the inflammatory infiltrate of a variety of benign dermatoses,[13] in normal skin explants,[14] and following pokeweed-mitogen and phytohemagglutinin stimulation,[15] suggests that they may represent a reactive proliferation.

Calvin C. Linnemann Jr, MD, Department of Medicine (Clinical Virology), University of Cincinnati, College of Medicine, performed the viral studies.

Patrick Coughlin and William Turner prepared the tissue and sections for electron microscopy.

Nonproprietary Name and Trademark of Drug

Vincristine sulfate—*Oncovin*.

References

1. Hallopeau H, Besnier F: On the erythrodermia of mycosis fungoides. *Cutaneous and Genito-Urinary Disease* 10:453, 1892.

2. Sézary A, Bouvrain Y: Erythrodermie avec présence de cellules monstrueuses dans le derme et le sang circulant. *Bull Soc Fr Dermatol Syph* 45:254-260, 1938.

3. Winkelmann RK: T cell erythroderma (Sézary syndrome). *Arch Dermatol* 108:205-206, 1973.

4. Brouet JC, Flandrin G, Seligmann M: Indications of the thymus-derived nature of the proliferating cells in six patients with Sézary syndrome. *N Engl J Med* 289:341-344, 1973.

5. Lutzner MA, Edelson RS, Smith RW, et al: Two varieties of Sézary syndrome, both bearing T-cell markers. *Lancet* 2:207, 1973.

6. Taswell HF, Winkelmann RK: Sézary syndrome: A malignant reticulemic erythroderma. *JAMA* 177:465-472, 1961.

7. Flandrin G, Brouet JC: The Sézary cell; Cytologic, cytochemical, and immunologic studies. *Mayo Clin Proc* 49:575-583, 1974.

8. Zucker-Franklin D: Properties of the Sézary lymphoid cell: An ultrastructural analysis. *Mayo Clin Proc* 49:567-574, 1974.

9. Watanabe I, Donague S, Hoggatt N: Method for electron microscopic studies of circulating human leucocytes and observations on their fine structure. *J Ultrastruct Res* 20:366-382, 1967.

10. Winkelmann RK: Clinical studies of T-cell erythroderma in the Sézary syndrome. *Mayo Clin Proc* 49:519-525, 1974.

11. Clendenning WE, Brecher G, Van Scott EJ: Mycosis fungoides: Relationship to malignant cutaneous reticulosis and the Sézary syndrome. *Arch Dermatol* 89:785-792, 1964.

12. Lutzner MA, Jordan HW: The ultrastructure of an abnormal cell in Sézary's syndrome. *Blood* 31:719-726, 1968.

13. Flaxman BA, Zelazny G, Van Scott EJ: Nonspecificity of characteristic cell in mycosis fungoides. *Arch Dermatol* 104:141-147, 1971.

14. Flaxman BA, Van Scott EJ, Goldman LI: Sézary-like cells in culture of normal human skin. *Arch Dermatol* 109:577-578, 1974.

15. Yeckley JA, Weston WL, Thorne EG, et al: Production of Sézary-like cells from normal human lymphocytes. *Arch Dermatol* 111:29-32, 1975.

Universal Acquired Melanosis

The Carbon Baby

Ramón Ruiz-Maldonado, MD; Lourdes Tamayo, MD;
Jorge Fernández-Diez, MD

A Mexican child was born white and progressively became black. At the age of 21 months, the whole integument was deep black in the absence of other alterations. Electron microscopy showed a Negroid pattern in the epidermal melanosomes. Among the different forms of progressive mucocutaneous pigmentations previously described in the literature, we were unable to find a similar case.

(*Arch Dermatol* 114:775-778, 1978)

Increased pigmentation of the skin is a common sign in a variety of conditions. Hyperpigmentation may be congenital or acquired, hereditary or nonhereditary, localized to universal, light brown to black, of known or unknown origin, etc. To our knowledge, the combination of acquired, universal, and deep-black melanosis in the absence of other evident alterations has not been previously reported. The association of these fully developed alterations in the patient whose case is presented here is unique.

REPORT OF A CASE

The patient, a Mexican boy who was 3 years and 2 months old at this writing, was first seen in January 1974 at the age of 6 months because of a progressive dark black pigmentation that started on the face and limbs at the age of 15 days. The patient was the product of the second uneventful pregnancy of a 22-year-old mother; the mother had taken four 15-mg tablets of oxazepam in the third month. The father was 30 years old. Both parents are Mexican; they were in good health, not consanguineous, and had light brown skin (Fig 1). A 5-year-old brother and a 10-month-old brother are normal with light brown skin color. The patient received two doses of Sabin and diphtheria-pertussis-tetanus vaccines.

At this writing, the skin and the occular and oral mucous membrane pigmentation of the boy was completely black, sparing only small areas of the palms and soles. After one hour of wearing his white underwear, the garments become gray in contact with the child's skin. The ophthalmologic examination showed severe melanosis oculi of sclera and conjunctiva with normal fundus. The scalp hair was black, fine, and sparse, contrasting with the normal amount of hair of the older brother.

When the patient first came to the IMAN Children's Hospital, Mexico City, at age 6 months, a black pigmentation was noted on the face, axillary folds, nipples, diaper area, knuckles of hands, feet, and gingivae. The child had fine, straight hair and none of the characteristics of a Negro (Fig 2, left, center, and right). The mother had a color photograph of the child at age 8

Fig 1.—Patient at 16 months of age with his father, mother, and 5-year-old brother.

Accepted for publication July 25, 1977.

From the Department of Pediatric Dermatology, Hospital Del Niño DIF, Mexico City (Drs Ruiz-Maldonado and Tamayo), and the Department of Pathology, Hospital General IMSS, Mexico City (Dr Fernandez-Diez).

Reprint requests to Dermatology Service, Hospital Del Niño DIF, IMAN, Insurgentes Sur 3700, Mexico 22, DF (Dr Ruiz-Maldonado).

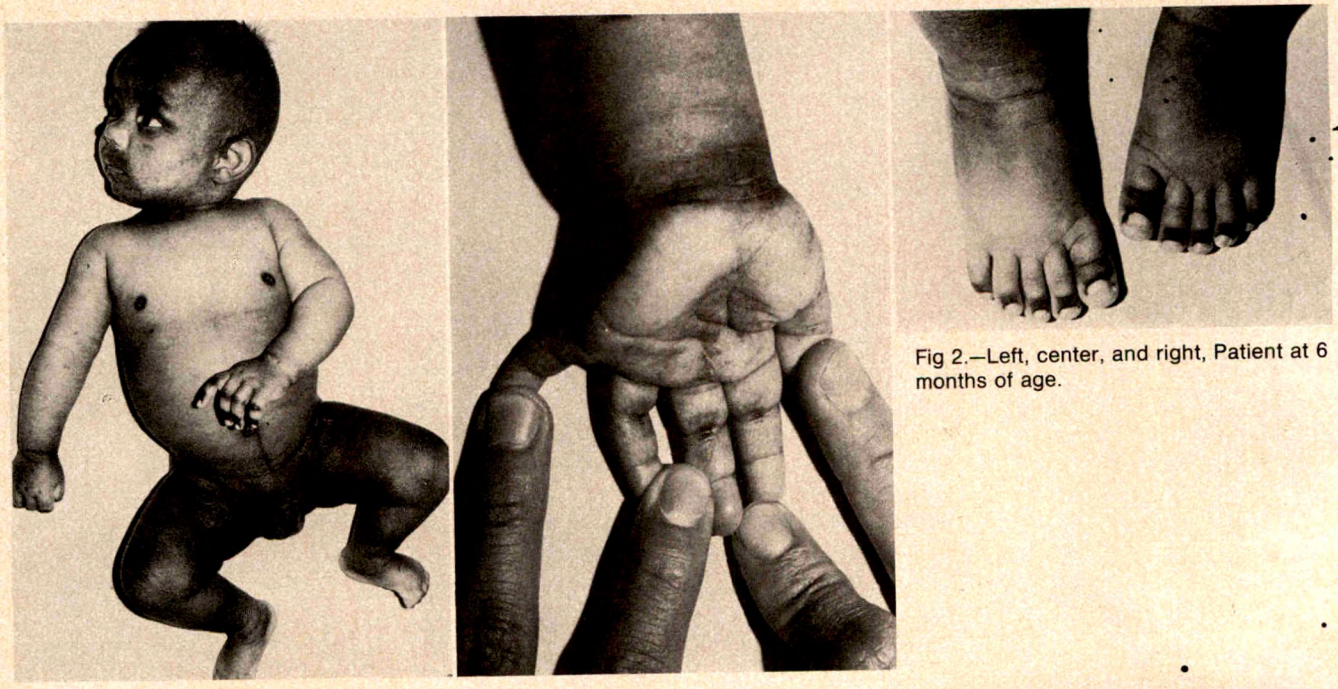

Fig 2.—Left, center, and right, Patient at 6 months of age.

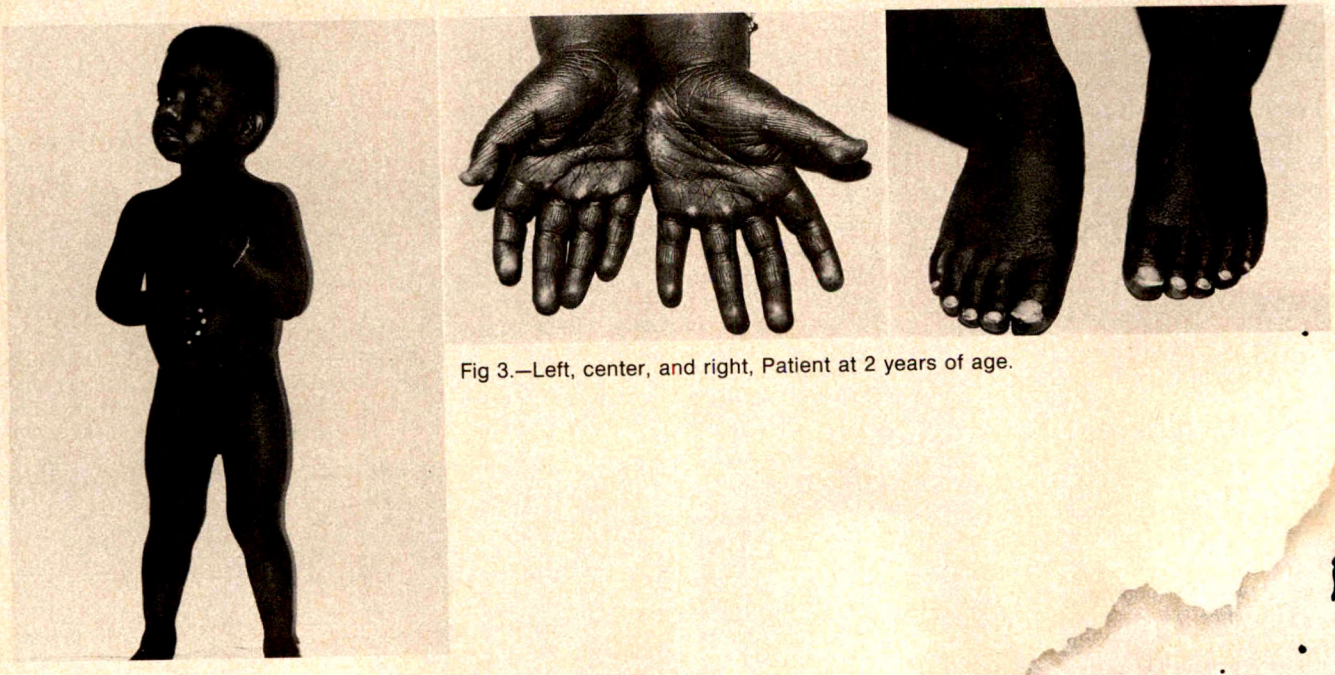

Fig 3.—Left, center, and right, Patient at 2 years of age.

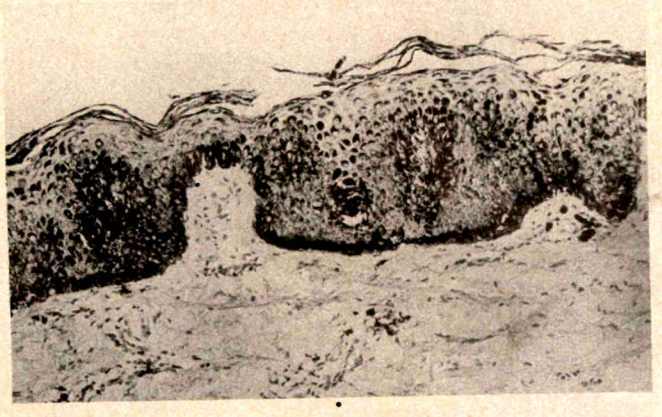

Fig 4.—Skin biopsy specimen of lower arm showing heavy hyperpigmentation of all epidermal layers and some pigment-loaded histocytes in papillary dermis (hematoxylin-eosin, ×30).

Fig 5.—Melanocyte in basal layer; nucleus (n) is round, mitochondria (m) are abundant and are dispersed throughout cytoplasm. Endoplasmic reticulum (rough and smooth) and Golgi complex are well developed. Melanosomes 2, 3, and 4 are increased in number, and their internal fine structure, size, and form are normal. Keratinocite is indicated by k, papilary dermis, d (×5,125).

days showing his face and lower limbs. From the print, one could see that the child's skin color had been white at that time.

In July 1974, when the patient was 1 year old, the pigmentation had increased, especially on the lower limbs. In December 1974, the child's skin was almost completely black, including the palms and soles. In May 1975, at age 21 months, the whole skin was deep black except for some small dark brown patches on the palms and soles. The skin pigmentation was an even dark black. The skin was of normal consistency with a smooth surface. The nails also showed black pigmented lines along their longitudinal axis (Fig 3, left, center, and right). The patient's physical and mental development was normal, and he looked perfectly well except for his skin color. In January 1977, no changes in the generalized deep pigmentation were observed. The child's development continued to be normal.

A skin biopsy specimen from the lower arm, which was taken when the child was 1 year old, showed excessive hyperpigmentation of the epidermal basal layer with migration of pigment through the prickle-cell layer into the stratum corneum. Some pigment-loaded histiocytes were present on the superficial dermis (Fig 4). The 3, 4-dihydroxyphenylalanine (DOPA) reaction showed a normal number of melanocytes, increased pigmentation of the epidermis from the basal layer to the stratum corneum, and some dermal melanophages.

Electron microscopy of the pigmented skin showed the number of melanocytes to be within normal limits. A great number of melanosomes, normal in shape and size, were evenly distributed in the melanocytes' cytoplasm. The melanosomes II, III, and IV were increased in number but were normal in shape, size, and fine inner-structure. The Langerhans' cells were normal in number, size, and activity. The keratinocytes had free granules of melanin (melanosomes III to IV) in their cytoplasm but not inside the phagosomes, in a Negroid pattern. Otherwise, keratinocytes were normal. Collagen appeared normal. In the superficial dermis, a number of melanophages were found inside the phagosomes. Most cells were of normal aspect. Vessels and nerves were also normal (Fig 5).

The results of the following examinations were within normal limits: two serum and urine screenings for abnormal amino acids; two hemograms and ESR; two urinalyses; liver function tests; a karyotype; morning and evening tests for vanillylmandelic acid; tests for serum adrenocorticotrophic hormone and cortisol; and films of the skull, sella turcica, and bones. The blood groups of the family (Rh_0D, C, E, e, c, M, N, S, s, R, Le, P, Fy^a, Jk^a, Diego, and Cellano) were not informative.

COMMENT

The first thought that comes to mind is that the child is in fact a Negro. Against this hypothesis we have absence of Negro ancestors; reasonable, acceptable paternity; absence of Negro characteristics except for the skin color and Negroid distribution of melanosomes; pigmentation not present at birth but rapidly progressive; and heavy pigmentation of palms, soles, and mucous membranes, unusual in the Negroes—particularly at an early age.[1]

Furuya and Mishima in 1962[2] reported the case of a Japanese child with a progressive pigmentary disorder. This patient started to be hyperpigmented at age 3 months. When first observed by one of the authors at age 6 months, the distal phalanges of all fingers and toes, the popliteal fossae, inner aspects of thighs, perianal area, and the scrotum were involved. At 4 years, the child was slightly mentally retarded and only partially pigmented with most of the head, chest, and upper limbs uninvolved, and the lower limbs not completely involved. Palms and soles were not involved. No mention was made of ocular or mucous pigmentation. Histologically, Furuya and Mishima's patient showed hyperkeratosis and papillomatosis, and proliferation of melanocytes at the epidermal-dermal junction. There were a few melanocytes and inflammatory cells in the dermis. No electron microscopical examination was done.

Although the patient of Furuya and Mishima shares with ours the progressive character and, in part, the clinical aspect of the pigmentation, our patient had a much faster evolution that ended in total skin pigmentation, including eyes and mucous membranes. Histologically, the pigmented skin of our patient showed a heavy hyperpigmentation of the basal layer, stratum malpighii, and stratum corneum, and only a few melanophages in the upper dermis, but no other alterations. The patient of Furuya and Mishima presented hyperkerato-

sis, papillomatosis, and proliferation of melanocytes. The electron microscopy and the DOPA reaction in our patient showed a normal number of melanocytes. Although it is difficult to count melanocytes exactly, our impression was that they were not increased in number. This would be in accordance with an excessive production of melanin and against a nevoid condition. The Negroid pattern of melanosomes does not necessarily mean that the child's condition is genetically related to the Negro.[3] The condition is probably owing to overproduction of melanin, of unknown cause.

Our patient has been physically and mentally normal for his age, whereas the patient of Furuya and Mishima was mentally retarded. Furuya and Mishima compared their patient's pigmentation with that described by Thomas as achropigmentation.[4] This rare disorder is confined to the skin surrounding the finger nails and toe nails. Pigmentation is not black but brown, and is not progressive.

Another condition that must be taken into consideration was first described by Chernosky et al[5] as familial progressive hyperpigmentation. Familial progressive hyperpigmentation is genetically determined, pigmentation is bizarrely-shaped, is sometimes sharply marginated, is present at birth, and many areas of normally pigmented skin are present. The histological picture of the patient of Chernosky et al was similar to the one observed for our patient.

Some epidermal nevi can be pigmented and involve the entire body surface; they are slightly raised, their surface is not smooth, and histologically, they show some degree of hyperkeratosis, acanthosis, papillomatosis, and hyperpigmented basal layer. Some pigmented nevus can involve portions of the skin. These lesions are usually present at birth, are not progressive, are slightly raised, and are hairy. Histologically, the presence of nevus cells provides the diagnosis. Melanocytic pigmented nevi show an increased number of melanocytes in the epidermal basal layer or in the dermis. Other conditions, such as nevus spilus, Addison's disease, erythema dyschromicum perstants, and neuro-cutaneous melanosis are distinctive enough not to be confused with our patient's condition.

Furuya and Mishima[2] interpreted their patient's condition as "an epidermal melanocytosis," that is, a nevoid condition with an increased number of melanocytes. This could not apply to our case, in which there was no evidence of excess melanocytes. β-Melanocyte stimulating hormone was not determined in our patient. The hormone has been found increased only in hyperpigmented patients with associated pituitary-adrenal pathology, such as Addison's disease, hyperthyroidism, xeroderma pigmentosum, and Hodgkin's disease. Levels of tyrosinase, the enzyme that catalyzes tyrosine and DOPA for the synthesis of melanin, were not measured.

With a normal sella turcica, with no evidence of pituitary adrenal abnormality, and with no evidence of systemic disease, we can speculate that our patient's pigmentation could be the result of a not yet described isolated, excessive production of β-melanocyte stimulating hormone, or to a central nervous system tumor that is not yet symptomatic, or to abnormally sensitive melanocytes to endocrine or nervous stimuli, or finally, to a genetic mutation that is not detectable at the chromosomal level.

References

1. Lewis MG: Malignant melanoma in Uganda. (Relationship between pigmentation and malignant melanoma of the soles of the feet). *Br J Cancer* 21:483, 1967.
2. Furuya T, Mishima Y: Progressive pigmentary disorder in Japanese child. *Arch Dermatol* 86:412-418, 1962.
3. Konrad J, Koenigsmann H: Riesenmelanosome in Navuszellnaevi und in normaler Menschlicher Epidermis. *Wien Klin Wochenschr* 87:173-177, 1975.
4. Thomas E: Uber das Spitzenpigment des Kleinkinder. *Munch Med Wochenschr* 70:1102, 1923.
5. Chernosky ME, Anderson DE, Chang JP, et al: Familial progressive hyperpigmentation. *Arch Dermatol* 103:581-598, 1971.

Cicatricial Pemphigoid (Brunsting-Perry Type)

Case Report and Immunofluorescence Findings

W. David Jacoby, Jr, MD; Charles W. Bartholome, MD; Subash C. Ramchand, MD; Everett B. Simmons, MD; Thomas K. Burnham, MD, BS (Lond)

• We describe clinical and immunofluorescence findings of a patient with Brunsting-Perry-type cicatricial pemphigoid. Direct immunofluorescence showed tissue-fixed basement membrane zone antibodies similar to those characteristic of bullous pemphigoid. Circulating antibodies to the basement membrane zone were not found. Brunsting-Perry-type cicatricial pemphigoid probably represents a clinical variation midway in the cicatricial pemphigoid-bullous pemphigoid spectrum of disease. Management with intralesional corticosteroids was successful in controlling the skin lesions.

***(Arch Dermatol* 114:779-781, 1978)**

In 1957 Brunsting and Perry described seven patients with a unique form of cicatricial pemphigoid.[1] In contrast to classic cicatricial pemphigoid, which results in conjunctival and other mucous membrane involvement as well as scarring, this condition was characterized by localized chronic scarring herpetiform plaques involving the skin of the head and neck region, with occasional transient mucous membrane involvement, but significantly no mucous membrane scarring. Usually one primary plaque evolved and slowly enlarged with the formation of small bullae at the advancing margin. Occasionally, smaller secondary blistering plaques were observed. These cutaneous lesions healed with superficial scarring. In this report, we present a case of this unusual type of cicatricial pemphigoid, describe the immunofluorescence findings, and report on the management with intralesional corticosteroids.

Accepted for publication Sept 20, 1977.

From the Department of Dermatology, Henry Ford Hospital, Detroit. Dr Jacoby is now with the Department of Internal Medicine, Division of Dermatology, Arizona Medical Center, and in private practice, Tucson; Dr Bartholome in private practice in Muncie, Ind; Dr Ramchand in Niagara Falls, NY; and Dr Simmons in Detroit.

Reprint requests to Department of Dermatology, Henry Ford Hospital, 2799 W Grand Blvd, Detroit; MI 48202 (Dr Burnham).

REPORT OF A CASE

In March 1974, a 50-year-old man noted a slowly enlarging, persistent cutaneous ulceration on his right forehead. The patient stated that this lesion began after being struck with a minute piece of flying steel while at work. In the six-month period following the injury, this lesion was treated by the plant physician with various topical agents. The affected area continued to enlarge and the patient was referred for consultation.

When first seen at the Henry Ford Hospital, Department of Dermatology, in September 1974, a 7-×4-cm lesion was noted on the right side of the forehead (Fig 1). This lesion exhibited a 3-×2-cm central erythematous glistening ulceration. Small vesicles were noted at the margins of the plaque. A small, 1 cm in diameter, erythematous scarred area was seen on the left anterior part of the neck. The patient thought that this neck lesion had been present for one month but could not remember whether a blister had preceded it.

An excisional biopsy specimen was taken from the margin of the active border including adjacent clinically normal skin. The biopsy specimen was bisected and the clinically normal skin adjacent to the plaque was immediately frozen in liquid nitrogen and stored at −76 C for subsequent direct immunofluorescence. Pertinent laboratory studies were initiated.

The specimen for light microscopy showed a large subepidermal bulla (Fig 2). In the dermis a polymorphous perivascular infiltrate was observed. Numerous eosinophils and polymorphonuclear leukocytes were present. The histologic picture was that of pemphigoid, cicatricial or bullous.

Bacterial and fungal cultures from the lesion were negative. The following laboratory studies were normal: complete blood cell count and differential cell count, urinalysis, VDRL, FTA-ABS, serum creatinine, BUN, calcium phosphate, lactic dehydrogenase, creatine phosphokinase, SGPT, SGOT, alkaline phosphatase, serum bilirubin, serum triglycerides, uric acid, total serum protein, serum albumin, and blood glucose. The following laboratory studies were abnormal: serum cholesterol, 316 mg/100 ml (normal, 150 to 300 mg/100 ml) and a weakly positive antinuclear antibody (ANA) test, showing small, speckle-like threads.[2]

Initial therapy consisted of aluminum sulfate (Domeboro) compresses and topically applied betamethasone benzoate (Banisone Gel), 025%. By November 1974, the central ulcerated area had reepithelialized and healed with scarring and hypopigmentation. However, new small vesicles continued to appear at the margins as the plaque slowly enlarged (Fig 3). That month a tense hemorrhagic bulla was noted on the buccal mucosa. This healed without scarring in two weeks. In December 1974, a

Fig 1.—Initial appearance of plaque. Note central ulceration and small vesicles at margin (10 o'clock).

Fig 2.—Skin biopsy specimen shows subepidermal bullae (hematoxylin-eosin, original magnification ×86).

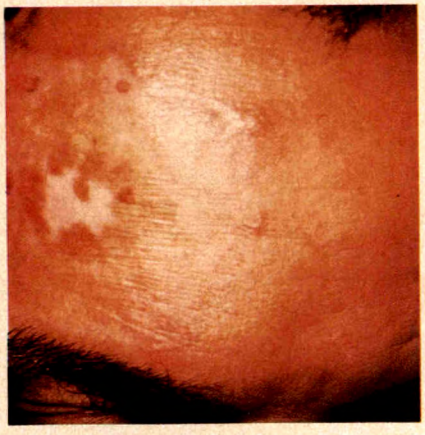

Fig 3.—Note small bullae at 2 o'clock. Original ulcerated area has healed with hypopigmentation.

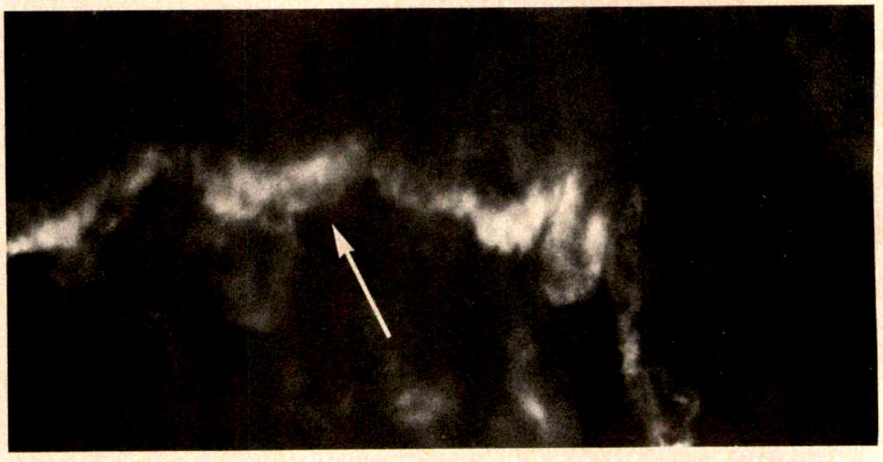

Fig 4.—Tubular band at dermal-epidermal junction in clinically normal skin adjacent to original plaque of right temple, incubated with fluorescein-conjugated goat anti-human IgG. Two dark-centered convolutions (arrow). Epidermis in upper part of photograph (×95 fluorite oil immersion objective, ×10 ocular, original magnification ×3).

new small, 1 cm in diameter, scarred area appeared, apparently without a preceding bulla, on the left cheek. After December 1974, the base of all new bullae and any erythematous areas were injected intradermally with triamcinolone acetonide (Kenalog), 5 mg/ml. The total dose employed ranged from 0.1 to 1.0 ml at any given treatment. It was found with monthly intradermal injections that denudation and subsequent scarring were prevented. When the patient was last examined in March 1977, the original large plaque on the right side of the forehead was inactive and healed. However, two smaller, similarly active plaques with peripheral bullae formation were noted on the scalp. Intralesional injections of triamcinolone, as described above, resulted in healing of these lesions. At no time has the conjunctiva been involved. Consultants have found no evidence of ocular, pharyngeal, or laryngeal involvement. An esophagram showed only a small sliding hiatus hernia. Esophagoscopy was not performed.

IMMUNOFLUORESCENCE STUDIES

Materials and Methods

The skin for direct immunofluorescence was treated, as described above, and sectioned on the cryostat at 4 μ within one week. Serum specimens were obtained on two separate occasions for the indirect immunofluorescence studies.

The direct fluorescence antibody technique was employed, as described previously,[3,4] but modified in that 4-μ thick cryostat sections were used instead of 6-μ thick sections.

Indirect immunofluorescence studies also used 4-μ thick cryostat sections of human normal skin, as described previously,[5,6] but only fluorescein-conjugated goat antihuman IgG and anti-B_1C/B_1A were employed.

Results

Direct immunofluorescence of the clinically normal skin adjacent to the plaque demonstrated IgG and complement (B_1C/B_1A) at the dermal-epidermal junction. An almost continuous strong tubular band (Fig 4) was seen with the anti-IgG and anti-IgS conjugates, while a discontinuous tubular band of medium intensity with overlying stipples was demonstrated with the anti-B_1C/B_1A conjugate. Inconclusive results were obtained with the anti-IgA and anti-IgM conjugates. Clinically, normal skin from the medial aspect of the flexor surface of the right forearm was negative with all conjugates. On two occasions indirect immunofluorescence was negative for the band and epidermal intercellular fluorescence. However, on both occasions upper epidermal cytoplasmic fluorescence[7] was noted. The clinical significance, if any, of this finding is not known.

COMMENT

Cicatricial pemphigoid is a rare condition. The Brunsting-Perry type is extremely rare, and most authorities consider it a variant of cicatricial pemphigoid. Its recognition as a

distinct clinical variant is important, as these patients seem to be spared the considerable morbidity associated with classic cicatricial pemphigoid. To be fair, since the appearance of cutaneous lesions may precede the occurrence of scarring mucosal membrane lesions in cicatricial pemphigoid by (rarely) as many as 20 years, it may be that if these patients with Brunsting-Perry type were followed up or lived long enough, they too would get mucosal membrane scarring. The skin was the initial site of involvement in only seven of 81 patients with cicatricial pemphigoid described by Hardy et al.[8] Only 19 of these patients had skin involvement, yet 55 developed serious ocular involvement with scarring. Therefore, it seems reasonable to suspect that initial skin involvement, especially if it was a characteristic single large plaque, suggests a more benign process. Clearly, more long-term follow-up studies are needed to clarify this issue.

Because of the similar immunofluorescence findings in cicatricial and bullous pemphigoid, Bean et al[9] have proposed that these two diseases are related and represent a spectrum of disease analogous to that seen in lupus erythematosus (LE). At one end of the spectrum is cicatricial pemphigoid, which, like discoid LE (DLE), shows principally tissue-fixed antibodies in the form of a band at the dermal-epidermal junction and only occasionally circulating antibodies.[10,11] The latter are represented by antibasal zone antibodies for cicatricial pemphigoid and ANA for DLE, respectively. Cicatricial pemphigoid results in scarring as does DLE. At the other end of the spectrum is bullous pemphigoid, which, analogous to systemic LE, often demonstrates both tissue-fixed and circulating antibodies. Bullous pemphigoid rarely results in scarring and systemic LE is also most often associated with nonscarring skin lesions. In our patient, we were able to demonstrate tissue-fixed antibasal zone antibodies but no circulating antibodies. These findings in the Brunsting-Perry type are similar to those reported recently by Michel et al.[12] We think that this type of cicatricial pemphigoid represents a variant midway in the cicatricial pemphigoid-bullous pemphigoid spectrum of disease. Whether these patients with Brunsting-Perry-type cicatricial pemphigoid will tend to "lock in" to a fixed position in this spectrum, as do patients with LE,[13] or progress to classic cicatricial pemphigoid, remains to be seen.

Donald S. Bolstad, MD, and Wayne A. Quie, MD, Henry Ford Hospital, performed the ophthalmologic and ear, nose, and throat examinations, respectively.

Nonproprietary Name and Trademarks of Drug

Betamethasone benzoate—*Benisone Gel, Flurobate.*

References

1. Brunsting LA, Perry HO: Benign pemphigoid? *Arch Dermatol* 75:489-501, 1957.
2. Burnham TK, Bank PW: Antinuclear antibodies: I. Patterns of nuclear immunofluorescence. *J Invest Dermatol* 62:526-534, 1974.
3. Burnham TK, Neblett TR, Find G: The application of the fluorescent antibody technique to the investigation of lupus erythematosus and various dermatoses. *J Invest Dermatol* 41:451-456, 1963.
4. Burnham TK, Fine G: The immunofluorescent "band test" for lupus erythematosus: III. Employing clinical normal skin. *Arch Dermatol* 103:24-32, 1971.
5. Burnham TK, Fine G: Indirect cutaneous immunofluorescence: I. Morphologic observations in bullous diseases, malignancies and connective tissue diseases. *Arch Dermatol* 205:52-58, 1972.
6. Burnham TK: Indirect cutaneous immunofluorescence: II. Clinical significance. *J Clin Pathol* 26:268-272, 1973.
7. Burnham TK: Two epidermal cytoplasmic immunofluorescent patterns by indirect immunofluorescence. *J Invest Dermatol* 62:100-105, 1974.
8. Hardy KM, Perry HO, Pingree GC, et al: Benign mucous membrane pemphigoid. *Arch Dermatol* 104:467-475, 1971.
9. Bean SF, Waisman M, Michel B, et al: Cicatricial pemphigoid. *Arch Dermatol* 106:195-199, 1972.
10. Bean SF: Cicatricial pemphigoid: Immunofluorescent studies. *Arch Dermatol* 110:552-555, 1974.
11. Tagami H, Immamura S: Benign mucous membrane pemphigoid: Demonstration of circulating and tissue bound membrane antibodies. *Arch Dermatol* 109:711-713, 1974.
12. Michel B, Bean SF, Clorzelski T, et al: Cicatricial pemphigoid of Brunsting-Perry. *Arch Dermatol* 113:1403-1405, 1977.
13. Prystowski SD, Gilliam JN: Discoid lupus erythematosus as a part of a larger disease spectrum: Correlation of clinical features with laboratory findings in lupus erythematosus. *Arch Dermatol* 111:1448-1452, 1975.

Aggressive Basal Cell Carcinoma of the Scalp

Daniel E. Gormley, MD, Paul Hirsch, MD

• Three examples of an unusually aggressive form of basal cell carcinoma in the skin of the scalp were treated surgically. The extent of each tumor was verified with gross and microscopic examination. The tumors invaded fat, muscle, fascia, and bone. Dural involvement was seen in one case. Light microscopy showed a marked variation in growth patterns and cytologic types from one portion of the tumor to another. Characteristics included a diffusely infiltrating pattern with a fibrotic stromal response, rare intraepidermal tumor nests, formation of occasional duct-like structures, poor cellular cohesion with single-file invasion through dermal collagen, perineural invasion, and pleomorphism with varying nuclear cytoplasmic ratios. Basaloid populations with peripheral palisading were seen in each tumor. These malignancies may be representative of an unusual basal cell carcinoma variant unique to the scalp.

(*Arch Dermatol* 114:782-783, 1978)

During the past 15 years, we have observed three examples of a particularly aggressive form of basal cell carcinoma associated with a specific site. The observed tumors were more invasive and extensive than most cutaneous carcinomas and exhibited unusual histologic features.

Accepted for publication Aug 10, 1977.

From the Department of Dermatology, University of California, Los Angeles (Dr Gormley) and the Department of Dermatology, University of Southern California School of Medicine, Los Angeles (Dr Hirsch).

Reprint requests to 210 S Grand Ave, Suite 307, Glendora, CA 91740 (Dr Gormley).

REPORT OF CASES

Case 1.—A 36-year-old white man had a growing 9 × 6-mm nodular lesion in the skin of the scalp for a year, which was slightly above the occipital ridge and a little to the right of the midline, when he was first seen by one of us (D.E.G.). There had been a history of irradiation to the skin of the scalp for treatment of tinea capitis at the age of 5 years. The nodule was asymptomatic, unpigmented, covered with normal-appearing epithelium, symmetrical, slightly raised, firm, and mobile. There were no palpable lymph nodes. The patient delayed biopsy for seven months. During this time, the lesion doubled in size and became multilobulated. The histologic findings that were noted after incisional biopsy were those of an aggressive basal cell carcinoma. The tumor was excised with 25-mm peripheral margins with the level of dissection carried down to the periosteum of the occipital bone. The wound was repaired with a split thickness skin graft. Seventeen months later, a nodule appeared in the center of the operative site. Roentgenograms showed a lytic lesion that measured 28 mm in diameter in the occipital bone deep to the superficial lesion. Exploratory craniotomy revealed that the tumor had penetrated the occipital bone and attached itself to the dura over an area that measured 20 mm in diameter. The deep dural surface, subdural space, and cerebrum were examined through a dural incision and found to be free of gross evidence of tumor. Because the tumor was attached to a point over the confluence of the great dural sinuses (torcular Herophili), the lesion was considered inoperable. Results of histologic examination of the bony and dural neoplasm showed it to be a basal cell carcinoma.

Case 2.—A 65-year-old white woman had undergone excision of a basal cell carcinoma on the left side of the occipital nuchal region 20 years previously. Ten years later, she was again treated surgically for a recurrence. When first seen by one of us (P.H.), she had a 20-mm subcutaneous mass over the left side of the nape. Biopsy specimen disclosed a diffusely infiltrating basal cell carcinoma. Chemosurgical ablation revealed that the true dimensions of the tumor were 45 × 38 mm. There had been invasion into the subcutaneous fat and striated musculature. Forty-three months posttreatment, the patient was clinically well and free of evidence of recurrence or metastasis.

Case 3.—A 47-year-old white man had had a malignant lesion in the skin on the right side of the occipital nuchal area, which had been treated five years previously. Excision and grafting had been done, and this was followed by radiation therapy. A nodule had been present in the treated area for 18 months when the patient was first seen by one of us (P.H.). A 20-mm mass was noted in the region of the attachments of the right sternocleidomastoid muscle. The lesion, which proved to be a basal cell carcinoma, was treated chemo-

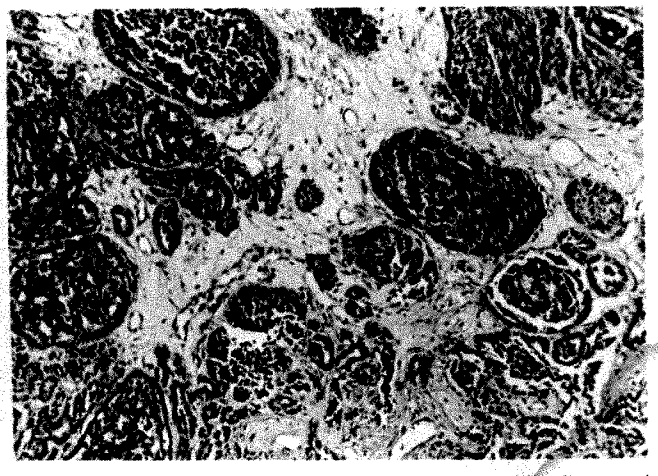

Fig 1.—Cell populations exhibiting peripheral palisading and invading into occipital bone that was decalcified before sectioning (case 1).

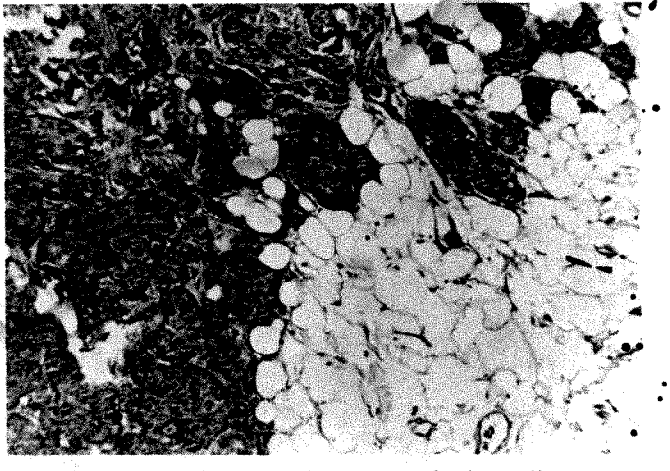

Fig 2.—Tumor invasion into subcutaneous fat (case 1).

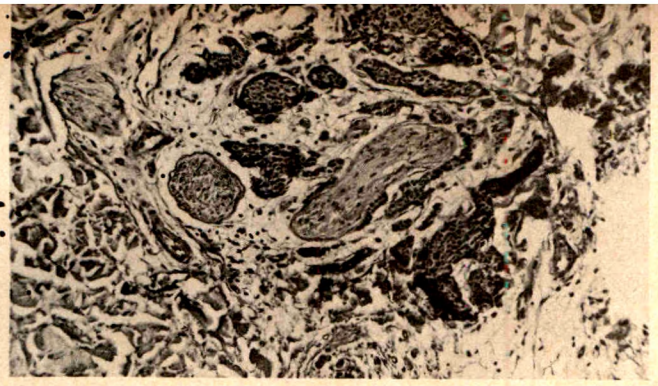

Fig 3.—Perineural invasion (case 1).

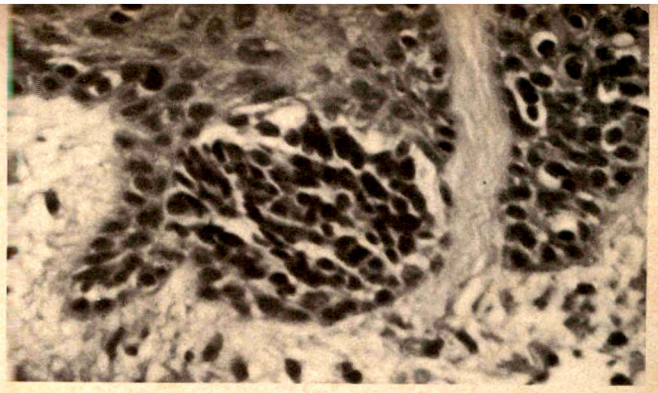

Fig 4.—Intraepidermal cluster of tumor cells (case 1).

Fig 5.—Duct-like tumor cell groupings found in association with overlying epidermis (case 1).

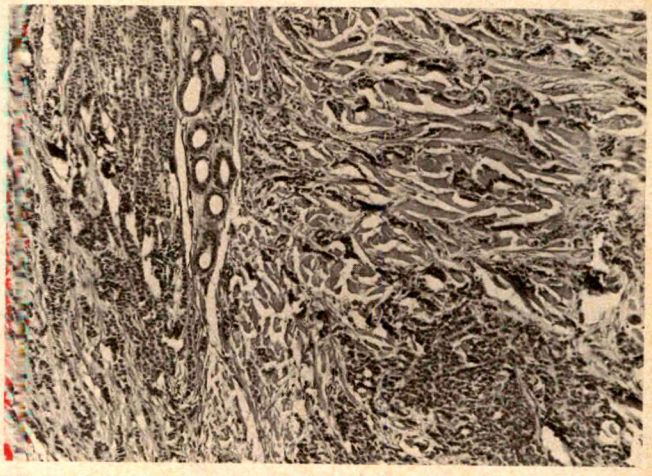

Fig 6.—Fibrotic stromal response seen in many areas. Tumor cells can also be seen migrating in thin strands and columns through dermis (case 1).

surgically. The tumor was found to have extended from the midline to the mastoid process and right external ear. Carcinoma was found to have invaded the sternocleidomastoid muscle and auricular perichondrium. Twelve years postchemosurgical ablation, the patient died of a metastasizing anaplastic carcinoma of unknown origin. There was no clinical evidence of recurrence of the tumor in the occipital nuchal region.

RESULTS

Tumor Properties

Examination of the features that were shown by the tumors in these three patients showed a pattern consistent enough to suggest a specific tumor type.

1. Site: all tumors originated in the occipital nuchal region of the scalp.

2. A history of aggressive growth: the tumors showed a propensity for invasion through collagen, fat, fascia, muscle, and bone. No metastases were found.

3. Histologic features: light microscopic examination showed a tumor that displayed a wide range of histologic features. Portions of the tumor had the attributes of a basal cell carcinoma with peripheral palisading of nuclei (Fig 1). Strands and sheets of tumor cells invaded dermal collagen and subcutaneous structures (Fig 1 and 2). Perineural tumor invasion was seen (Fig 3). Occasionally carcinoma cells were found intraepidermally (Fig 4) or could be seen forming duct-like structures in continuity with the epidermis (Fig 5). A fibrotic stromal response was elicited (Fig 6). Significant inflammation was not seen. In some areas, the tumor cells exhibited poor cohesion and formed single-file columns among the dermal collagen fibers (Fig 6). Cellular shapes varied from cuboidal to fusiform and exhibited variation in nuclear cytoplasmic ratios.

COMMENT

Problem basal cell carcinomas have been recorded in a variety of sites, including the scalp, the region of the external ear, periocular area, nasal labial fold, skin of the nose, and most recently in the skin of the trunk.[1-3]

Nodular lesions, especially those which are growing, must be regarded with respect and suspicion when they appear in the scalp. This series suggests that there is additional reason for concern, if these findings are noted in a comparatively young patient. In case 1, the epidermis overlying the lesion was initially intact. This imparted an innocuous appearance to the tumor during earlier stages of its growth. Therefore, we believe that biopsy must be considered whenever a growing nodule is found in the scalp. Because the microscopic appearance of the aggressive basal cell carcinoma of the scalp can vary from one portion of the tumor to another, an adequate biopsy specimen is essential for accurate diagnosis. If, after careful sectioning and study of the biopsy specimen, the tumor is found to be an "ordinary" basal cell carcinoma, standard therapeutic techniques should suffice. If the findings of aggressive basal cell carcinoma of the scalp are seen, en bloc excision with wide margins is recommended.

References

1. Jackson R, Adams RH: Horrifying basal cell carcinoma: A study of 33 cases and a comparison with 435 nonhorror cases and a report on four metastatic cases. *J Surg Oncol* 5:431-463, 1973.

2. Mohs FE: *Chemosurgery in Cancer, Gangrene and Infections.* Springfield, Ill, Charles C Thomas Publisher, 1956, pp 50, 62.

3. Curry MC, Montgomery H, Winkelmann RK: Giant basal cell carcinoma. *Arch Dermatol* 113:316-319, 1977.

Essential IgG Cryoglobulinemia With Purpura and Cold Urticaria

Hiromu Koda, MD; Akiko Kanaide, MD; Masakazu Asahi, MD; Harukuni Urabe, MD

• An 80-year-old woman with essential cryoglobulinemia developed recurrent, widespread, purpuric lesions with superficial skin ulcers and cold urticaria. No disorders of other organ systems were recognized.

Attempts to transfer the cold sensitivity passively by serum and isolated cryoprecipitate of the patient were successful. Immunochemical studies showed that the cryoglobulin was composed of IgG only. It was suggested that the cryoprecipitate might not be due to immune complex formation in this case.

(*Arch Dermatol* 114:784-786, 1978)

Despite the increasing number of clinical reports on the occurrence of cryoglobulins in association with various diseases, association of cold urticaria and purpura with cryoglobulinemia is a rare phenomenon. An 80-year-old woman offered a unique opportunity to investigate the relationship between the cold sensitivity or purpuric lesions and the cryoprecipitate.

The purpose of the present case report is to describe our observations of the patient and comment on the mechanisms of the occurrence of purpuric lesions and urticaria in cryoglobulinemia.

REPORT OF A CASE

An 80-year-old woman had been healthy until she experienced an onset of urticaria in the winter of 1942 (average temperature is about 6°C in this season) at the age of 50. Since then, she suffered from cold urticaria every winter for about 30 years. Furthermore, purpuric lesions started to appear on her extremities from the winter of 1963 at the age of 71. Although those purpuric lesions disappeared in the warm seasons for several years, they persisted all year long since 1971.

She was first seen by us in the summer of 1972 because of long-persisting ulcerations on her legs. Physical examination demonstrated reticular, dark-red, macular, purpuric lesions with superficial necrotic ulcerations on both hands, forearms, lower legs, and ears (Fig 1 and 2). She had several egg-sized deep ulcers on the lower portions of both legs. No gingival lesions were observed.

Accepted for publication Sept 12, 1977.

From the Department of Dermatology, Faculty of Medicine, Kyushu University, Fukuoka, Japan.

Reprint requests to Department of Dermatology, Faculty of Medicine, Kyushu University, 3-1-1 Maidashi, Higashi-ku, Fukuoka 812, Japan (Dr Koda).

Laboratory Studies

Urinalysis showed normal levels of protein and glucose with no Bence-Jones reaction. The RBC count was 2.45 million/cu mm; hemoglobin level, 9.6 g/dl; WBC count, 5,400/cu mm, with 55% polymorphonuclear leukocytes, 37% lymphocytes, 5% monocytes, and 3% eosinophils. The platelet count was 176,000/cu mm. Bleeding time was three minutes. The ESR was 22 mm/hr at room temperature. Blood pressure was 130/70 mm Hg; BUN level, 10.5 mg/dl; uric acid level, 3.2 mg/dl; serum cholesterol level, 195 mg/dl; alkaline phosphatase level, 70 mU/ml; SGOT value, 50 mU/ml; serum calcium level, 9.2 mg/dl, antistreptolysin O titer, 12 Todd units; and C-reactive protein, 6+. Rheumatoid factors, lupus erythematosus cells, and antinuclear antibodies were not present, and results of serological tests for syphilis were negative. Total protein concentration was 6.9/dl. Results of serum electrophoresis showed the following values (normal ranges are in parentheses): albumin, 60% (56% to 60%); α_1-globulin, 5.0% (2% to 5%); α_2-globulin, 13.7% (5% to 12%); β-globulin, 8.7% (7% to 13%); γ-globulin, 12.5% (11% to 21%); cold agglutinin titer, 1:4. Immunoglobulin values were as follows (normal values in parentheses): IgA, 34 mg/dl; (130 to 300); IgG, 1,520 mg/dl (800 to 1,800); IgM, 18 mg/dl (100 to 220); cryoglobulin, 0.5 g/dl. General skeletal x-ray films showed no abnormalities. Results of bone marrow examination were within normal range.

Cryoglobulin Studies

Blood was collected in warm syringes and allowed to clot at 37°C to obtain serum. Separation of the cryoprecipitate was accomplished by chilling the patient's serum at 4°C overnight. This precipitate was soluble at room temperature. The serum taken from the patient was separated into five aliquots and kept at 35°, 30°, 25°, 20°, and 15°C for two hours. No precipitate was obtained at 35°, 30°, 25°, and 20°C. Obvious precipitate was found at 15°C.

The cryoprecipitate was washed three times with phosphate buffered cold saline, pH 7.1, at 4°C and finally redissolved in phosphate buffered saline of the original serum volume at 37°C. This redissolved solution was centrifuged and subjected to immunoelectrophoresis and immunodiffusion studies. On immunoelectrophoresis, redissolved cryoprotein demonstrated single arc with the horse antihuman serum, and the cryoprotein was identified as IgG (Fig 3). Dissolved cryoprecipitate was examined by agar gel double diffusion with rabbit antisera monospecific for IgG, IgA, IgM, or C3. Cryoprecipitate was confirmed as IgG. No precipitation arc was observed with anti-IgA, IgM, or C3 antiserum. The CH50 titer (the 50% hemolytic unit of complement) of the patient's original serum was 29 and decreased to 15 after removal of precipitate. Inactivation of the complement by heating the serum at 56 C for 30 minutes did not prevent the formation of cryoprecipitate.

Passive Transfer Studies

Whole serum and isolated cryoprecipitate were warmed at room temperature and injected intradermally on the volar side of the arms of two normal volunteers. Following the injection of whole serum, wheal formation was observed 9 mm in diameter at 5 minutes, 11 mm at 10 minutes, 14 mm at 15 minutes, 16 mm at 20 minutes (maximum size), and disappeared at 120 minutes (Fig 4). A similar reaction was observed by injection of isolated cryoprecipitate. Warming the forearm at 41°C immediately after injection of whole serum or isolated cryoprecipitate prevented the wheal formation. However, urticaria appeared in ten minutes after chilling the warmed forearms. Injection of cryoprotein-free serum elicited urticaria on the forearms; maximum size was 14 mm in diameter. No urticaria reappeared on the forearms by challenging with cold at one hour or 24 hours after disappearance of urticaria that was passively transferred by cryoprecipitate.

Histologic Findings

A biopsy specimen was obtained from a newly formed purpuric lesion on the left arm. A perivascular infiltrate consisted mainly of mononuclear cells, and a few neutrophils in the upper part of the dermis were observed. A few erythrocytes were scattered in the dermis (Fig 5). There was endothelial swelling of vessels that were filled with eosinophilic materials (Fig 6).

Clinical Course

The patient was followed up in our outpatient clinic for two years. Prevention of ulceration and formation of purpuric lesions were managed by the wearing of heavy clothing and keeping the room warm. She was treated systemically with glutathione, vitamin E, pyridinol carbamate, and corticosteroid. Topical treatment with gualenic acid ointment and steroid ointment seemed beneficial for the ulcerated lesions. Newly formed erythema and purpuric eruptions cleared without developing necrotic ulcerations by topical treatment with Hirudoid ointment, which contains 3% antithrombin material.

COMMENT

Since no significant primary disorders were detected in this patient, the diagnosis of essential cryoglobulinemia was established. Some abnormalities such as microcytic and hypochromic anemia might be due to the widespread purpuric eruptions, and the high titer of C-reactive protein might possibly be related to the inflammatory lesions following purpura.

Several speculations have been reported about the mechanism of production of purpuric eruptions in cryoglobulinemia. Some have proposed that production of purpura is due to stasis of blood induced by in vivo precipitation of cryoproteins.[1-5] Others speculated that deposition of circulating immune complexes might be an important factor for vessel damage.[6-10] The idea that the cryoglobulin in mixed cryoglobulinemia is an immune complex supports the latter speculation.[7,8,11,12] From the histological findings in our patient, it might be possible that the eosinophilic material in the vessels is cryoglobulin and causes stasis of blood followed by the swelling of endothelium of blood vessels and extravasation of erythrocytes.

Association of cold urticaria and cryoglobulinemia is a rare phenomenon. Many attempts to relate cold sensitivity and the serum cryoglobulin were unsuccessful.[13,14] Our results, which demonstrated that the cryoprecipitate containing whole serum as well as the isolated cryoprecipitate were able to transfer the cold urticaria to normal recipients, suggest that the cryoprecipitate may be responsible for the formation of cold urticaria. However, the production of cold urticaria by injection of "cryoprecipitate-free" serum seems to deny the exclusive role of cryoprecipitate in the formation of a wheal. This discrepancy was also noted by Rawnsley and Shelley.[13] Meltzer and Franklin[15] suggested that the cryoprecipitate might be protein-

Fig 1.—Reticular purpuric lesions with superficial necrotic ulcerations on left hand.

Fig 2.—Purpuric lesions on right ear.

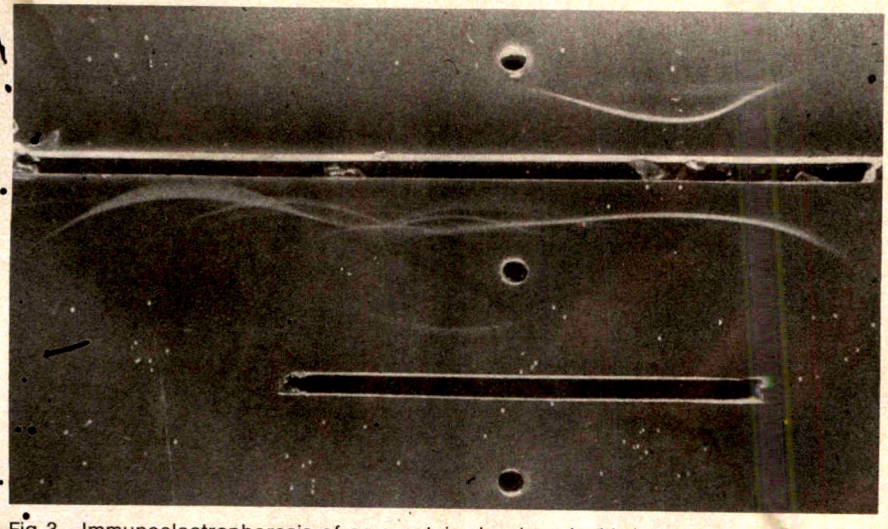

Fig 3.—Immunoelectrophoresis of cryoprotein developed with horse antihuman serum showing IgG component. Upper well, cryoglobulin; upper trough, horse antihuman serum; center well, normal human serum; lower trough, rabbit anti-C3 serum; lower well, cryoglobulin.

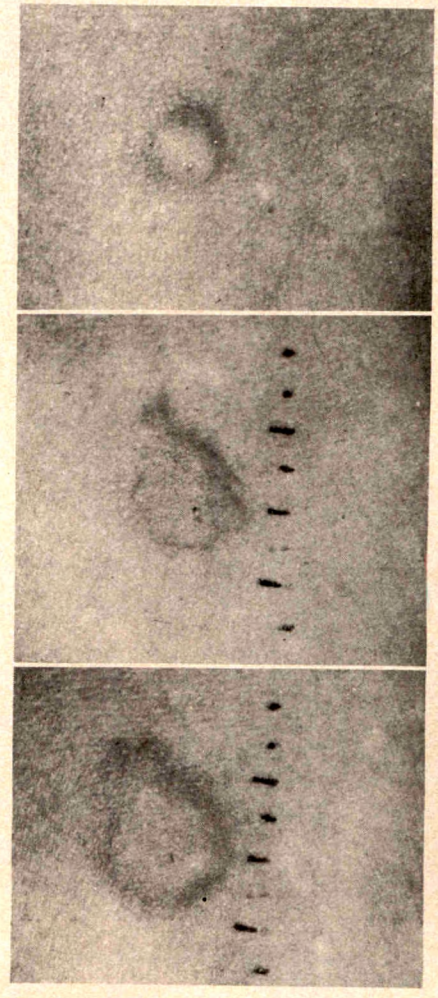

Fig 4.—Urticaria elicited at site of intradermal injection of isolated cryoprecipitate. Top, 30 seconds after injection; center, 10 minutes after injection; bottom, 30 minutes after injection.

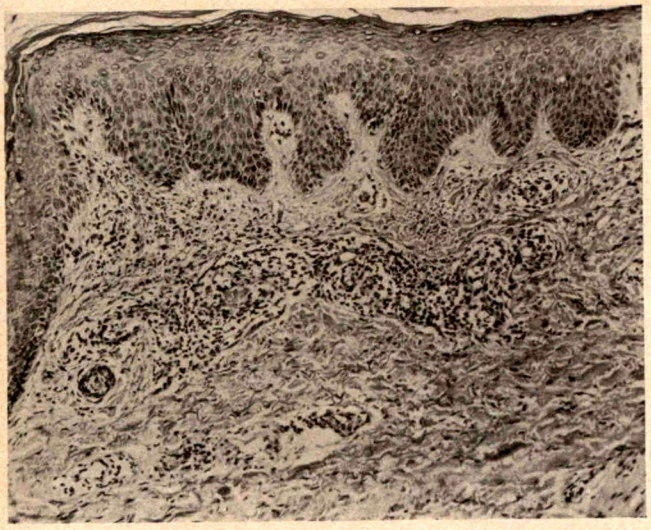

Fig 5.—Biopsy specimen of arm lesion showing lymphocytic infiltration around vessels in upper dermis.

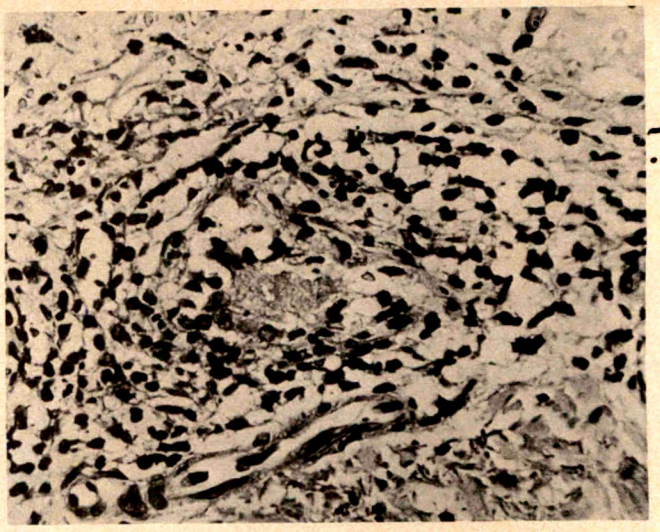

Fig 6.—Higher magnification of Fig 5 shows that capillary spaces in upper dermis are occluded by eosinophilic material (original magnification ×300).

protein complexes associated with the formation of weak, noncovalent bonds that dissociate easily. We agree with this opinion because loss of small amounts of cryoglobulin was observed in each washing. Thus, small amounts of released cryoprotein might remain in the supernatant, which was apparently thought to be cryoprecipitate-free, and in consequence these small amounts might show an ability to elicit cold urticaria. On the surface our results seem to differ somewhat from Rawnsley and Shelley's experiment, which demonstrated that precipitation of the cryoglobulin is essential for the formation of cold urticaria.[13] However, it is possible that such "remaining" cryoglobulin might precipitate in the transferred area and produce urticaria in our experiment. Nevertheless, the possibility that two factors are involved in the production of urticaria, viz, cryoglobulin and a factor in the cryoprecipitate-free serum, can not be excluded rigorously. The lack of urticaria formation at 41° C after transfer of cryoprecipitate and its appearance with chilling also support the relation of the cryoprecipitate to the formation of urticaria.

Costanzi and Coltman[14] demonstrated that the most severe reactions occurred when the cold challenge was applied less than six hours but more than 30 minutes after the cryoprotein or the whole serum injection. In our experiment, the reaction occurred much faster than theirs, and no reaction was observed after two hours. This rapid appearance of urticaria suggests the role of histamine in the formation of the wheal—a concept proposed by others.[13,16,17]

No urtication was observed by chilling at one hour and at 24 hours after the disappearance of wheals in the passive transfer test. This might be due to the exhaustion of histamine in the test area.

Immunoelectrophoresis and immunodiffusion studies of the cryoprecipitate showed that it was composed of IgG only. The depression of complement in the cryoglobulin-free serum suggests the association of complement with the precipitated globulin. However, no C3 component was observed in the cold precipitate on the immunodiffusion test. Perhaps other complement components than C3 are bound to the cryoprecipitate, or complex formation results in partial inactivation of complement. As the heat-inactivation of serum had no effect on the precipitability of cryoglobulin, it was possible that activated complement was not necessary for formation of precipitate. These results suggest that the cryoprecipitate might not be due to immune complex formation in this case.

Arnold E. Powell, PhD, Department of Surgery, and Beno Michel, MD, Department of Dermatology, Case Western Reserve University, Cleveland, reviewed and commented on this article.

References

1. Lerner AB, Barnum CP, Watson CJ: Studies of cryoglobulins: II. Spontaneous precipitation of protein from serum at 5°C in various disease states. *Am J Med Sci* 214:416-421, 1947.
2. Lerner AB, Watson CJ: Studies of cryoglobulins: I. Unusual purpura associated with the presence of a high concentration of cryoglobulin (cold precipitable serum globulin). *Am J Med Sci* 214:410-415, 1947.
3. Pillsbury DM, Shelley WB, Kligman AM: *Dermatology*. Philadelphia: WB Saunders Co, 1956, p 1094.
4. Steinhardt MJ, Fisher GS: Essential cryoglobulinemia. *Ann Intern Med* 43:848-858, 1956.
5. Ellis FA: The cutaneous manifestation of cryoglobulinemia. *Arch Dermatol* 89:690-697, 1964.
6. Cream JJ: Peripheral vascular disease and annular erythema with selective IgA deficiency and mixed cryoglobulinemia. *Br J Dermatol* 85:546-550, 1971.
7. Peetoom F, Loghem-Langereis E: IgM-IgG (β2M-7Sγ) cryoglobulinemia: An autoimmune phenomenon. *Vox Sang* 10:281-292, 1965.
8. Wager O, Mustakallio KK, Rasanen JA: Mixed IgA-IgG cryoglobulinemia: Immunological studies and case report of three patients. *Am J Med* 44:179-187, 1968.
9. Gokcken M: Cryoglobulins behaving as cold autoantibodies. *Postgrad Med* 39:68-78, 1966.
10. Nir MA, Pick AI, Schreibman S, et al: Mixed IgG-IgM cryoglobulinemia with follicular pustular purpura. *Arch Dermatol* 109:539-542,1974.
11. Lospalluto J, Dorward B, Miller W, et al: Cryoglobulinemia based on interaction between a gamma macroglobulin and 7S gamma globulin. *Am J Med* 32:142-147, 1962.
12. Grey HM, Kohler PF, Terry WD, et al: Human monoclonal γG cryoglobulins with anti-γ-globulin activity. *J Clin Invest* 47:1875-1884, 1968.
13. Rawnsley HM, Shelley WB: Cold urticaria with cryoglobulinemia. *Arch Dermatol* 98:12-17, 1968.
14. Costanzi JJ, Coltman CA Jr: Kappa chain cold precipitable immunoglobulin G (IgG) associated with cold urticaria: I. Clinical observations. *Clin Exp Immunol* 2:167-168, 1967.
15. Meltzer M, Franklin EC: Cryoglobulinemia: A study of 29 patients: I. IgG and IgM cryoglobulins and factors affecting cryoprecipitability. *Am J Med* 40:828-836, 1966.
16. Beall GN: Urticaria: A review of laboratory and clinical observations. *Medicine* 43:131-151, 1964.
17. Henderson LL, Code CF, Roth GM, et al: Increased blood histamine in thermal intolerance: Report of a patient with cryoglobulinemia. *J Allergy* 29:122-129, 1958.

AVEENO®
Colloidal Oatmeal
bath for sensitive skin

When you treat inflammatory diseases, such as wet dermatitis (including allergic, atopic and contact), intertrigo or wet pruritus, a colloidal oatmeal bath may prove valuable, adjunctive therapy.

Soak Away The Discomfort With AVEENO COLLOIDAL OATMEAL.

- **Cleans naturally**—a soap-free way to absorb dirt and excess oil.
- **Comforts gently**—soothingly soaks hard-to-reach and widespread problem areas.
- **Long-lasting protection**—colloidal oatmeal film continues to protect after bathing.
- **Helps restore normal skin pH.**

Available in 1 lb. and 4-lbs. boxes.

Cooper Laboratories, Inc., Wayne, N.J. 07470 Cooper

Still the only oral antipruritic with q12h convenience

**efore prescribing, see complete prescribing information in SK&F litera-
ıre or *PDR*. The following is a brief summary.**

Indications

Based on a review of this drug by the National Academy of Sciences—National Research Council and/or other information, FDA has classified the indications as follows:

Effective: For symptomatic relief of pruritic symptoms in urticaria.

Possibly effective: For relief of pruritic symptoms in neurodermatitis, allergic dermatitis, contact dermatitis, atopic dermatitis, chickenpox, pruritus ani and vulvae.

Final classification of the less-than-effective indications requires further investigation.

ontraindications: Comatose patients; presence of large amounts of C.N.S. epressants; bone marrow depression; idiosyncrasy or hypersensitivity to this rug or other phenothiazines; in newborn or premature children; in nursing nothers; in acutely ill and/or dehydrated children.

Varnings: May impair mental and/or physical ability required for potentially azardous tasks (driving vehicles, operating machinery); may impair mental lertness in children. Concomitant use with alcohol or other C.N.S. depressants may have additive effect. Warn patients accordingly.

Use with extreme caution in patients with asthmatic attack, narrow-angle glaucoma, prostatic hypertrophy, stenosing peptic ulcer, pyloroduodenal obstruction, bladder neck obstruction, patients receiving MAO inhibitors.

Do not use in women of childbearing potential. There are reported instances of jaundice and prolonged extrapyramidal symptoms in infants whose mothers received phenothiazines during pregnancy.

Use with caution in children, as administration may result in excitation; overdosage may produce hallucinations, convulsions, sudden death.

Elderly patients (60 or older) are more prone to develop the following phenothiazine side effects: hypotension, syncope, toxic confusional states, extrapyramidal symptoms (especially parkinsonism), excessive sedation.

Precautions: May increase, prolong or intensify sedative action of C.N.S. depressants (when administered concomitantly, narcotic or barbiturate dosage should be reduced to ¼ or ½); lead to restlessness and motor hyperactivity in patient with pain being treated with narcotics; block or reverse the pressor effect of epinephrine. Use cautiously in persons (particularly children) with acute or chronic respiratory impairment, as it may suppress cough reflex; in persons with cardiovascular disease, liver function impairment, or history of ulcer disease. The drug's slight antiemetic action may obscure signs of intestinal obstruction, brain tumor, toxic drug overdose.

Adverse Reactions: (Note: May produce adverse reactions attributable to both phenothiazines and antihistamines, although not all the following have

Controls the itching* promptly ...while you treat the cause

Temaril® Spansule®

Each 'Spansule' capsule contains trimeprazine tartrate equivalent to 5 mg. of trimeprazine.

brand of sustained release capsules

been reported with 'Temaril'. There have been occasional reports of sudden death in patients receiving phenothiazine derivatives chronically.) Drowsiness, extrapyramidal reactions (opisthotonos, dystonia, akathisia, dyskinesia, parkinsonism), particularly with high doses, hyperreflexia in newborn (when used during pregnancy), dizziness, headache, lassitude, tinnitus, incoordination, fatigue, blurred vision, euphoria, diplopia, nervousness, insomnia, tremors and grand mal seizures, excitation, catatonic-like states, neuritis and hysteria, oculogyric crises, disturbing dreams/nightmares, pseudoschizophrenia, intensification and prolongation of action of C.N.S. depressants, atropine, heat, organophosphorus insecticides.

Also postural hypotension, reflex tachycardia, bradycardia, faintness, cardiac arrest, ECG changes, anorexia, nausea, vomiting, epigastric distress, diarrhea, constipation, dry mouth, increased appetite and weight gain, urinary frequency and dysuria, urinary retention, early menses, induced lactation, gynecomastia, decreased libido, inhibition of ejaculation, false positive pregnancy tests, thickening of bronchial secretions, tightness of chest, wheezing, nasal stuffiness, urticaria, dermatitis, asthma, laryngeal edema, angioneurotic edema, photosensitivity, lupus erythematosus-like syndrome, anaphylactoid reactions, leukopenia, agranulocytosis, pancytopenia, hemolytic anemia, elevation of plasma cholesterol levels, thrombocytopenic purpura, jaundice, erythema, peripheral edema, stomatitis, high or prolonged glucose tolerance curves, glycosuria, elevated spinal fluid proteins, reversed epinephrine effects.

After prolonged phenothiazine administration at high dosage, the following have occurred: skin pigmentation, ocular changes (the appearance of lenticular and corneal opacities, epithelial keratopathies, pigmentary retinopathy). Vision may be impaired.

Drug Interactions: MAO inhibitors and thiazide diuretics prolong and intensify anticholinergic effects. Combined use of MAO inhibitors and phenothiazines may result in hypertension and extrapyramidal reactions. Phenothiazines potentiate C.N.S. depressant and analgesic effects of narcotics. Phenothiazine effects may be potentiated by oral contraceptives, progesterone, reserpine, hylidrin HCl.

Supplied: 'Spansule' capsules — in bottles of 50. Syrup — Each 5 ml. teaspoonful contains trimeprazine tartrate equivalent to 2.5 mg. of trimeprazine and alcohol 5.7%, in 4 fl. oz. bottles. Tablets — Each tablet contains trimeprazine tartrate equivalent to 2.5 mg. of trimeprazine, in bottles of 100 and 1000. Tablets and 'Spansule' capsules also available in Single Unit Packages (SUP) of 100, intended for institutional use only.

Smith Kline & French Laboratories
Division of SmithKline Corporation
Philadelphia, Pa.

SK&F
a SmithKline company

...safe for your patients to use, ...effective and less traumatic than cryosurgery or curettage[1]

Pet remedies for warts are almost as common as warts themselves. However, one specific formulation has again clinically proven its value.

R. B. Rees reported, *"My favorite wart remedy is . . . equal parts of salicylic acid and lactic acid in four parts of flexible collodion (Duofilm)".*[2]

Bunney and associates find the Duofilm formula, used at home, at least as effective as, and less traumatic than, cryotherapy and curettage.[1]

Arndt[3], in a double-blind controlled study of patients with multiple warts, confirmed Bunney's findings.

Duofilm is safe and simple to use. Special patient instruction pads and supplies of Duofilm for your treatment table are available on request.

Duofilm®

(Salicylic Acid, USP, 16.7% and Lactic Acid, USP, 16.7% in Flexible Collodion, USP)

for warts

Composition: Salicylic Acid, USP, 16.7% and Lactic Acid, USP, 16.7% in Flexible Collodion, USP.

Indications: DUOFILM is indicated as a keratolytic agent for the removal of benign epithelial tumors such as common warts.

Dosage and Administration: Prior to the application of DUOFILM, soak the affected area in hot water for at least five minutes. Dry thoroughly with a clean towel.

Apply DUOFILM directly to the wart using the plastic applicator. Each drop should be permitted to dry before re-application of the liquid. Care should be taken to see that DUOFILM is not applied to the surrounding skin. A Band-Aid® or similar bandage should then be applied lightly.

Treatment should take place once daily and continue as directed by physician.

Contraindications: Diabetics or patients with impaired blood circulation should not use DUOFILM. Do not use on moles, birthmarks or unusual warts with hair growing from them.

Precautions: For external use only.

DUOFILM is highly flammable and should be kept away from fire or flame. Keep bottle tightly capped when not in use. Store at controlled room temperature.

If spilled on mucous membranes or in eyes, flush with water, remove precipitated collodion, and flush with water for an additional 15 minutes.

Keep this and all medication out of the reach of children.

How Supplied: DUOFILM is available in ½ oz. bottles with plastic applicators.

Caution: Federal law prohibits dispensing without a prescription.

1. Bunney, M.H.; Nolan, M.W.; Williams, D.A.: An assessment of methods of treating viral warts by comparative treatment trials based on a standard design. *Brit. J. Derm.* **94**, 667, 1976.
2. Rees, R.B.: Post-graduate course in Dermatology, sponsored by Cleveland Clinic and U. of Cal., San Fran., Nov. 5-10, 1976, Maui, Hawaii.
3. Arndt, K.A.: Double-blind study of salicylic and lactic acid lotion in treating warts. Study on file at Stiefel Research Institute.

STIEFEL
Logical Dermatologicals since 1847

Stiefel Laboratories, Inc.,
Oak Hill, N.Y. 12460
Stiefel Laboratories (Canada) Ltd.,
St. Laurent, Quebec, Canada H4R 1E1

9-1085

Short Report

Alopecia Mucinosa of the Face Associated With Mycosis Fungoides

Alan N. Binnick, MD; Fredrick D. Wax, MD; William E. Clendenning, MD

Alopecia mucinosa is classified into two categories.[1] One is the idiopathic or primary variety, which is benign and without associated disease. The second is the form seen in association with lymphoma, usually mycosis fungoides.

Reviews of series of patients with alopecia mucinosa[2,3] suggest that when small numbers of lesions are present, and particularly when these are limited to the head and neck, the course will be benign. We report a case in which this was not so.

Report of a Case

A 41-year-old woman was seen in April 1976 because of three enlarging facial plaques of nine months' duration. In 1973 she had been hospitalized for a generalized eczematous dermatitis. Patch tests at that time showed 2+ reactions to nickel, chrome, balsam of Peru, and a caine mixture. It was also believed that she had atopic dermatitis. That episode of eczematous dermatitis was controlled with fluocinolone acetonide and avoidance of contactants. She had done well in the intervening period.

Examination showed dull red, infiltrated plaques involving the tip of the nose, the upper lip, and the left preauricular area. There was alopecia of the lateral parts of the eyebrows (Fig 1 and 2). Her skin, in general, was dry and there was mild flexural subacute eczematous dermatitis.

A biopsy specimen taken from the preauricular plaque showed alopecia mucinosa with severe mucinous degeneration of follicular structures (Fig 3). Alcian blue stain of the mucinous material was positive at pH 4.5 and negative at pH 2.5. A dense diffuse and perifollicular infiltrate was present consisting primarily of lymphocytes with an admixture of eosinophils, histiocytes, plasma cells, and mast cells. Small collections of lymphocytes were present in the epidermis, which also showed spongiosis. Many lymphocytes had hyperconvoluted nuclear membranes and hyperchromatic nuclei, which raised the question of associated mycosis fungoides. Results of general physical and laboratory examinations were normal.

The preauricular and upper lip plaques showed good resolution with repeated intralesional injections of triamcinolone acetonide. However, the nasal lesion failed to respond to injections or to 225 rads of superficial radiation. Surface erosions developed and there were several episodes of secondary bacterial cellulitis. Therefore, the patient was hospitalized in September 1976 for a surgical shave procedure to the nose similar to that used in the treatment of rhinophyma. At this time, several mildly infiltrated, erythematous plaques on her trunk and lower extremities were noted. There was axillary lymphadenopathy and no hepatosplenomegaly.

Histopathological examination of the skin from the nose taken at surgery showed a moderate amount of mucinous degeneration of the hair follicles. There were epidermal exocytosis of pleomorphic lymphocytes forming Pautrier's microabscesses and a dense dermal infiltrate of atypical lymphocytes that extended into the subcutaneous tissue. Electron microscopy showed many lymphocytes with hyperconvoluted nuclear membranes and prominent nucleoli. Excisional biopsy specimens of plaques from the back and thigh showed the pathological findings of mycosis fungoides. An axillary lymph node biopsy specimen showed dermatopathic lymphadenopathy. A further lymphoma workup, including bone marrow biopsy, liver-spleen scan, and lymphangiogram, was negative.

The nose was treated with 1,000 rads of electron beam radiation with considerable

Fig 1.—Clinical presentation in April 1976 showing nasal and upper lip plaques as well as eyebrow alopecia.

From the Section of Dermatology, Hitchcock Clinic and Dartmouth Medical School, Hanover, NH.

Reprint requests to Hitchcock Clinic, 2 Maynard St, Hanover, NH 03755 (Dr Clendenning).

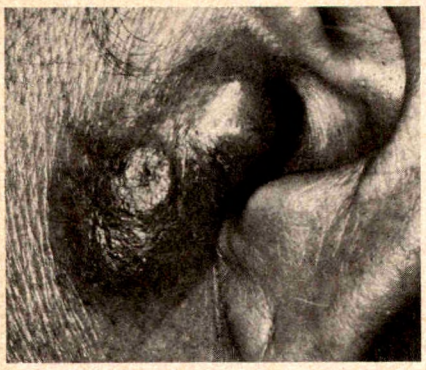

Fig 2.—Preauricular plaque from which biopsy specimen was taken.

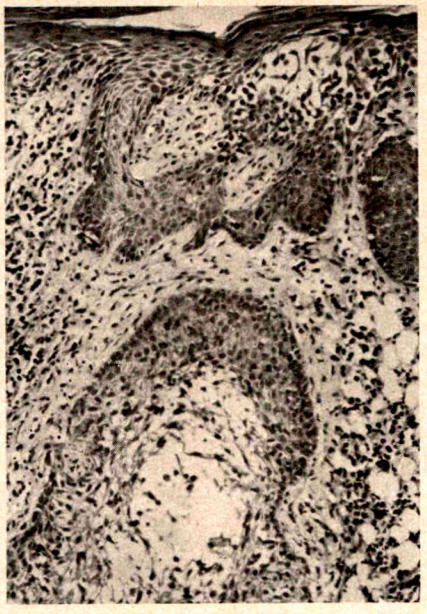

Fig 3.—Initial biopsy specimen showing follicular mucinosis and dermal infiltrate composed mainly of lymphocytes that infiltrate epidermis (hematoxylin-eosin, original magnification ×200).

improvement. The patient was then randomized to a protocol of the National Mycosis Fungoides Cooperative Study consisting of a course of total body electrons (2,000 rads) followed by six courses of a four-drug chemotherapy regimen (cyclophosphamide, doxorubicin hydrochloride (Adriamycin), vincristine sulfate, and prednisone). There was complete resolution of the cutaneous disease. In June 1977 she died suddenly of a myocardial infarction and an autopsy showed no residual mycosis fungoides.

Comment

Although prior isolated reports of alopecia mucinosa can be found in the literature, its recognition as a distinct entity dates from Pinkus' paper on six patients published in 1957.[4] Shortly after Pinkus' article, Braun-Falco reported two cases in which alopecia mucinosa occurred in association with cutaneous reticulosis.[5] In 1962 the association of alopecia mucinosa with reticulosis was strengthened when Kim and Winkelmann reported ten cases of alopecia mucinosa, five of which had associated reticulosis.[6]

Emmerson studied 47 cases of alopecia mucinosa, eight of which had an associated reticulosis, and found that in none of 26 patients in whom lesions were confined to the head and neck was there an associated reticulosis.[2] Emmerson further commented that when alopecia mucinosa follows a benign course, the histological infiltrate, no matter how dense, always consists of benign-appearing cells. When there is associated mycosis fungoides, atypical lymphocytes are present.

Coskey and Mehregan followed the clinical course of 50 patients with alopecia mucinosa, seven of whom had an associated reticulosis, and also reviewed 156 cases of alopecia mucinosa reported in the literature.[3] All of the patients with associated reticulosis had generalized infiltrated plaques of alopecia mucinosa. They agreed with Emmerson that "alopecia mucinosa is a benign and self-limited skin disease . . . when lesions are few and are limited to the head and neck." Other clinical features of alopecia mucinosa that usually indicate a benign course are appearance before age 40 and lesions that morphologically appear as grouped follicular papules rather than as plaques or nodules.

Thus, this patient represents an exception to previously reported cases and demonstrates that, when lesions of alopecia mucinosa are few in number and limited to the head and neck, mycosis fungoides may be an associated feature.

Katherine S. Connolly performed the electron microscopy.

Nonproprietary Name and Trademark of Drug

Vincristine sulfate—*Oncovin*.

References

1. Pinkus H: The relationship of alopecia mucinosa to malignant lymphoma. *Dermatologica* 129:266-270, 1964.

2. Emmerson RW: Follicular mucinosis: A study of 47 patients. *Br J Dermatol* 81:395-413, 1969.

3. Coskey RJ, Mehregan AH: Alopecia mucinosa: A follow-up study. *Arch Dermatol* 102:193-194, 1970.

4. Pinkus H: Alopecia mucinosa. *Arch Dermatol* 76:419-426, 1957.

5. Braun-Falco O: Mucophanerosis intrafollicularis et seboglandularis. *Dermatol Wochenschr* 136:1289-1303, 1957.

6. Kim R, Winkelmann RK: Follicular mucinosis (alopecia mucinosa). *Arch Dermatol* 85:490-498, 1962.

Comes on strong

Against inflammatory dermatoses

Aristocort®-A

TRIAMCINOLONE ACETONIDE

0.5% Cream and Ointment

INDICATIONS: For relief of inflammatory manifestations of corticosteroid-responsive dermatoses.

CONTRAINDICATIONS: Viral skin diseases, such as varicella and vaccinia; hypersensitivity to any component (not for ophthalmic use); when circulation is markedly impaired.

WARNINGS: Safety of use in pregnancy has not been absolutely established. Do not use extensively, in large amounts, or for prolonged periods of time in pregnant patients.

PRECAUTIONS: If irritation develops, discontinue use and institute appropriate therapy. In infections, use appropriate antifungal or antibacterial agents; if a favorable response does not occur promptly, discontinue the corticosteroid until the infection is adequately controlled. If extensive areas are treated or the occlusive technique is used, increased systemic absorption of the corticosteroid may occur; take suitable precautions.

ADVERSE REACTIONS: (local) Burning sensations, itching, irritation, dryness, folliculitis, secondary infection, skin atrophy, striae, hypertrichosis, acneform eruption and hypopigmentation.

ARISTOCORT A CREAM: Each gram contains 5 mg. (0.5%) of the highly active steroid, Triamcinolone Acetonide (a derivative of triamcinolone) in AQUATAIN, a specially formulated base composed of emulsifying wax NF, isopropyl palmitate, glycerin USP, sorbitol solution USP, lactic acid, 2% benzyl alcohol and purified water. AQUATAIN is non-staining, water-washable, paraben-free, spermaceti-free and has a light texture and consistency.

ARISTOCORT A OINTMENT: Each gram contains 5 mg. (0.5%) of the highly active steroid, Triamcinolone Acetonide (a derivative of triamcinolone) in a specially formulated base composed of emulsifying wax NF, white petrolatum, and propylene glycol.

Lederle LEDERLE LABORATORIES, A Division of American Cyanamid Company, Pearl River, New York 10965 067-7

Readers are advised that in view of The Copyright Revision Act of 1976, *all Book Reviews submitted for publication must contain on the transmittal letter the following language: "The person(s) undersigned hereby grant the American Medical Association permission to publish this Book Review and in addition, hereby assigns all copyright ownership therein to the AMA."*

Atlas Der Dermatologie und Venerologie, by Gernot Rassner, 200 pp, 228 color illus, Munich, Urban & Schwarzenberg, 1978.

Rassner, of the Department of Dermatology, University of Ulm, West Germany, prepared a colored atlas of dermatology and venerology. The short first part of this atlas offers a condensed description of structure and function of the skin, as well as a brief review of etiology, pathogenesis, and general therapy of dermatoses. The second and largest part contains 221 photographs of important dermatoses, one of acute gonorrhea, and six of syphilis. Each chapter briefly describes symptoms, clinical characteristics, and differential diagnosis of the illustrated diseases.

Illustration 47 shows the early inflammatory stage of acrodermatitis chronica atrophicans. The accompanying text states that the patient remembers previous tick bites and that these parasites probably transmit a yet unknown causative agent. German dermatologists suspect that a tick bite *(Ixodes ricinus)* may be responsible for the appearance of acrodermatitis chronica atrophicans, erythema chronica migrans, and lymphadenosis cutis benigna.

The color illustrations, which are presented on heavy, glossy paper, are on the whole of very good quality. A few, such as the illustrations of Bowen's disease (110), neurofibromatosis (195), and condylomata lata (226), are not satisfactory. Instead of an illustration (223) of the rarely occurring multiple syphilitic chancres, a picture of the generally seen single chancre would have been more instructive.

An index makes it possible to find quickly the illustration of the disease in question. This atlas is particularly helpful for the novice in dermatology, but will also aid all physicians who are interested in quick pictorial information about skin diseases. Although the short text cannot be used unless one is conversant in German, the main part containing the color illustrations will nevertheless be useful since one will easily understand the medical terms of the illustrations.

ALFRED HOLLANDER, MD
Springfield, Mass

Fortschritte der praktischen Dermatologie und Venerologie, vol 8, edited by O. Braun-Falco and S. Marghescu, 469 pp, with illus, $37.80, Berlin, Springer-Verlag, 1976.

Postgraduate courses in dermatology are held at regular intervals every three years at the Department of Dermatology, University of Munich, West Germany. During the years, this course has set standards in updated teaching of dermatology and its subspecialties; these proceedings have been published as a book. The eight postgraduate courses of one week's duration in July 1976 attracted more than 700 German-speaking dermatologists from this country, Scandinavia, Austria, Switzerland, England, East European countries, and as far as Japan and the United States. Within the same year, the proceedings were available as a book of 469 pages.

There are eight chapters that deal with the following topics: (1) dermatosis in childhood; (2) treatment modalities for basal cell carcinoma, squamous cell carcinoma, and keratoacanthoma; (3) diagnosis of allergies; (4) immune dermatoses; (5) a chapter that leads from symptoms to diagnosis (eyes, nails, pigment, tongue, hemorrhagic skin lesions); (6) acne; (7) therapeutic suggestions for the practicing physician; and (8) venereal diseases. The volume closes with a section entitled "What's New in Dermatology?" This section was compiled by the host and organizer of the course and senior editor of this book, Professor Braun-Falco. The 55 communications are well written, furnished with key references, and illustrated with black-and-white photographs and tables. The multiplicity of themes accounts for the hybrid nature of this volume; thus, it stands between a book and the volume of a journal. Though the book is written in German, authors of many nationalities have made their contributions. Among them are H. Bardach, H. Ebner, H. Kresbach, G. Niebauer, and K. Wolff from Austria; A. Kint from Belgium; N. Hjorth from Denmark, M. Blaszczyk, T. Chorzelski, and S. T. Jablonska from Poland; L. Juhlin and N. Thyresson from Sweden; H. Storck, A. L. de Weck, and R. Wüthrich from Switzerland; and R. L. Baer and H. Goldschmidt from the United States.

I know of no better opportunity for physicians who treat dermatological problems, ie, practitioners, pediatricians, gynecologists, and dermatologists to name but a few specialties, to find a similarly condensed, practice-oriented, and updated source of information. For this reason, the newest edition of what one could call a "three-year book in dermatology" can be highly recommended to all physicians who are confronted with dermatological and venereological problems.

GERD PLEWIG, MD
Munich, West Germany

When cleanliness requires more than soap— in the hospital, office or home

BETADINE® Skin Cleanser

Degerms as it cleanses

☐ **For routine handwashing**—for physicians and nurses in the hospital and office—hospital personnel and patients—for those caring for infants and the sick at home.

☐ **For skin degerming**—in patients with common pathogens, including *Staph. aureus*—postoperative skin care in the hospital and home—in skin infections—for general hygiene, when skin degerming is indicated.

☐ **In infected acne pimples**—when it is important to prevent autoinoculation of new sites.

☐ **To degerm face, hands and body with prompt, broad-spectrum microbicidal action**—BETADINE Skin Cleanser cleanses thoroughly and gently with a rich golden lather—virtually nonirritating* to skin and mucosa—nonstaining to skin and natural fabrics.

Supplied in 4 fl. oz. plastic bottles.

*In the rare instance of local irritation or sensitivity, discontinue use by the individual.

Purdue Frederick

© Copyright 1978, The Purdue Frederick Company/Norwalk, CT 06856

A9035 202078

Open New Doors for your Alcoholic Patients

To assist you in treating persons afflicted with alcoholism, the American Medical Association has updated and revised its **Manual on Alcoholism.** Incorporating, for the first time, the **Medical Complications of Alcohol Abuse** (out of print), this new edition provides the current authoritative information which is essential for helping you to recognize, as well as treat, alcoholism.

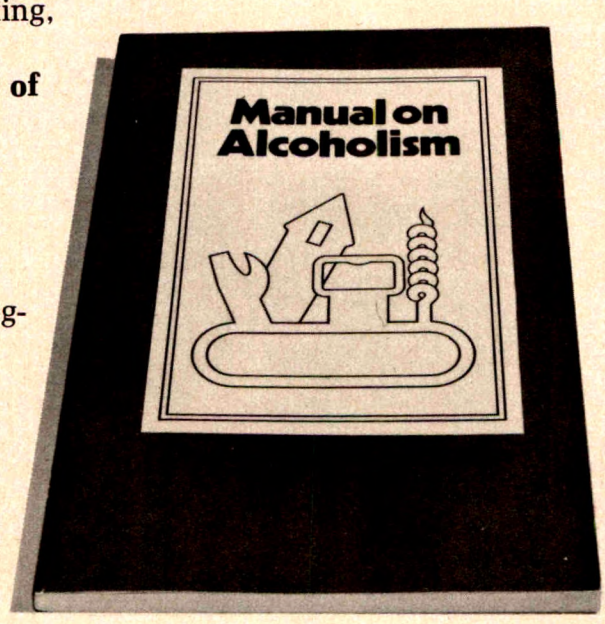

The section on diagnosis and treatment has been greatly expanded as a result of the integration of the material on medical complications. With the addition of other data compiled from recent research and clinical experience, this new **Manual on Alcoholism** is designed to present major considerations involved in helping patients with drinking problems.

Now that alcoholism is classified as a disease, your role will be increasing. **Manual on Alcoholism** should prove to be useful in your endeavors. Order this valuable reference today! $2.50

Manual on Alcoholism provides a concise overview of this complex illness. Its purpose is to give you a better understanding of:

- your alcoholic patients
- important factors in the development of alcoholism
- diagnosis and treatment
- more frequent complications

Order Dept. OP-185 S/J
American Medical Association
535 N. Dearborn
Chicago, IL 60610

Please send_____copy(ies) of Manual on Alcoholism, OP-185, at $2.50 each. I enclose $_____, payable to the AMA.

Name_____

Address _____

City/State/Zip _____

SUNDOWN PASSED THE TOUGHEST WATER RESISTANCE TEST EVER GIVEN A SUNSCREEN.

After an hour of swimming
In both fresh and salt water
And 3 hours of sunbathing
At the hottest time of the day
In both dry and humid climates
SUNDOWN still gave significant sunscreen protection*

By making this a tough test, we demonstrated conclusively that SUNDOWN resists water wash-off to provide significant protection for your sun-sensitive patients.
SUNDOWN has other reasons for recommendation: ▫ Only one active ingredient, 3.3% Padimate O (octyl dimethyl PABA), with low sensitization potential ▫ Screens out 99.6% of erythemal radiation under laboratory conditions ▫ Non-drying to the skin — with a low alcohol content of only 8.6% ▫ Polymer-containing base dries quickly to an invisible water-resistant film ▫ Won't stain unless applied directly to clothing ▫ Compatible with Retin-A Brand tretinoin therapy ▫ Easily removed with soap and water.

Contains: octyl dimethyl PABA (Padimate O), alcohol 8.6%, water, ammonium acrylate/acrylate copolymer, isopropyl myristate, benzyl alcohol, ammonium isostearate, stearyl alcohol, fragrance, xanthan gum and carbomer 961.

*Tested in Bradenton, Florida, 90° temperature, very high humidity; in Phoenix, Arizona, 100° temperature, 5% humidity; in Holmes Beach, Florida, 85° temperature, 68% humidity — winds 20 mph. Data on file, Johnson & Johnson.
Based on available published data on file at Johnson & Johnson.

Johnson & Johnson
New Brunswick, New Jersey 08903

Johnson & Johnson
BRAND **SUNDOWN**
HIGHLY PROTECTIVE SUNSCREEN



PROTECTION THAT DOESN'T STOP AT THE WATER'S EDGE

Letters to the Editor

Readers are advised that in view of The Copyright Revision Act of 1976, *all Letters to the Editor submitted for publication must contain on the transmittal letter the following language: "The person(s) undersigned hereby grant the American Medical Association permission to publish this Letter and in addition, hereby assigns all copyright ownership therein to the AMA."*

Diagnosis of Scabies

To the Editor.—Identification of the scabies mite by scrapings from the skin or biopsy was described in the September ARCHIVES by Goldman (113:1296, 1977) and in an earlier issue by Orkin (111:1431, 1975). Prof G. Lomholt taught the following procedure as was earlier described by Heilesen[1] and also Mellanby[2]: Use magnifying glasses on spectacles, a powerful light-source, and a sewing needle mounted on a holder. Find a burrow (at least 90% are located near the hands[2,3]) and look for a dark point at one end. This will be the mite. The roof of the burrow is lifted off by-side-to-side movements of the needle, and the needlepoint should be directed toward the mite, which can be easily seen as a glistening, rounded little spot clinging to the needle. Transfer the *Sarcoptes* to a glass slide, and it can be visualized by low-power light microscopy. The *Sarcoptes scabiei* can be preserved for later study by adding colophonium and a cover slide.

GUNNAR KAVLI, MD
Tromsø, Norway

1. Heilesen B: Studies on *Acarius scabiei* and scabies. *Acta Dermatovenerol*, suppl 14, vol 26, 1946.
2. Mellanby K: *Scabies*, ed 2. Middlesex, England, E. W. Classey Ltd, 1972.

Condyloma Acuminatum

To the Editor.—The misspelling "condyloma acuminata" continues to appear in medical literature.[1-3] Although *condyloma* looks as though it might be a feminine singular or neuter plural form in Latin, it is actually the singular form of a third declension neuter noun. So the correct spelling is "condyloma acuminatum." If your patient has more than one of these lesions, call them "condylomata acuminata," which is the correct plural form.[4]

ARTHUR W. GULICK, MD
Ann Arbor, Mich

1. Powell LC Jr, Pollard M, Jinkins JL: Treatment of condyloma acuminata *(sic)* by autogenous vaccine. *South Med J* 63:202-205, 1970.
2. Curtis WW, Ablin RJ: Immunotherapy of condyloma acuminata *(sic)*. *JAMA* 225:994, 1973.
3. Storrs FJ: Spread of condyloma acuminata *(sic)* to infants and children. *Arch Dermatol* 133:1294, 1977.
4. *Dorland's Illustrated Medical Dictionary*, ed 24. Philadelphia, WB Saunders Co, 1965, p 335.

Human Wart Virus

To the Editor.—Human wart virus (HWV) production and accumulation is hampered by the failure of conventional culture methods. We offer a partial solution to this problem where the site is appropriate.

Desquamations from extensive warts of the hands of one patient were collected by saline lavage. Surgical gloves filled with 50 ml of saline were worn for one hour.

The wart virus was easily found in our lavages by transmission electron microscopy, by the negative stain technique. Concentration of HWV by high-speed centrifugation and further purification by density-gradient ultracentrifugation was then performed. From the total 100 ml of lavage solution, there was a yield of approximately 2×10^{11} virus particles. Uninvasive detection, morphology, quantitation, and treatment assessment were thus made possible. This technique afforded a means of accumulating single-donor wart antigen (pure virion).

R. D. WILKINSON, MD
PETER GILL, PhD
ROB MILLER, MD
JOHN KOSIUK
Montreal

Systemic Absorption of Topical Clindamycin

To the Editor.—Although Algra et al were unable to detect clindamycin in the serum following topical application of a hydroalcoholic solution of clindamycin hydrochloride (ARCHIVES 113:1390-1391, 1977), The Upjohn Company has observed clindamycin concentrations of up to 0.7 μg/ml in the urine of four of nine subjects who were receiving topical applications of 20 mg of clindamycin daily for one to seven weeks, which indicates that some systemic absorption does occur.

In addition, The Upjohn Company has received three reports of diarrhea associated with topical clindamycin therapy for acne. Proctoscopy in one of these cases showed markedly inflamed mucosa, which resolved following cessation of clindamycin. In another patient, the diarrhea cleared with discontinuation of topical clindamycin and reappeared following resumption of this topical medication. In the third case, diarrhea occurred following topical application of clindamycin in a patient who had previously experienced diarrhea with oral clindamycin (H. W. Woodward, The Upjohn Co, written communication, May 27, 1977).

DAVID A. VORON, MD
Arcadia, Calif

In Reply.—Because the kidney can serve a concentrating function, it is conceivable that clindamycin hydrochloride could be detected in urine but not in serum after topical application. Nonetheless, by our assay we were unable to detect clindamycin in serum.

We, too, are concerned about the reports of diarrhea associated with topical clindamycin therapy. Richard Stoughton, MD (verbal communication, November, 1977), informed us that there have been no cases of pseudomembranous colitis or ulcerated rectal mucosa associated with topical application of clindamycin. The patient to which Dr Voron refers had, according to Dr Stoughton, only rectal edema and petechiae.

RONALD J. ALGRA, MD
THEODORE ROSEN, MD
MARGARET WAISMAN, MD
Houston

Hydrocortisone vs High-Potency Corticosteroid Ointments

To the Editor.—The new high-potency glucocorticosteroids have largely replaced hydrocortisone in topical preparations for treating skin diseases. In a recent review, Stoughton[1] has listed more than 20 commercial preparations from which the physician may choose. Eczema and psoriasis are the two major diseases that are treated with such preparations, and in many cases,

occlusion is used to increase absorption.[2] Atrophy[3] has been reported with use of these agents, particularly where absorption is high, such as on the face and in intertriginous areas. This problem can be more generalized when occlusion is used. No such effects have been described with hydrocortisone.

It has become a common practice to combine topical corticosteroids with tar and ultraviolet-B (UV-B) therapy to hasten clearing in psoriasis. We have recently observed that 1% hydrocortisone appears to be as effective as the more potent corticosteroids in this regimen when occlusion with a plastic dressing is used.

Eleven patients were treated with the following regimen: (1) Corticosteroids were applied to the skin at night and the patient was wrapped with a plastic dressing. (2) The wraps were removed in the morning and the patient was bathed. (3) A tar gel (Estar) was then applied to the lesions. (4) The patient was exposed to increasing doses of UV-B on a daily basis two hours later. (5) A gel containing salicylic acid (Keralyt Gel) was applied in the afternoon, and the patient was wrapped with a plastic dressing for two to four hours.

An ointment containing 1% hydrocortisone was applied to half of the body, and a high-potency corticosteroid was applied to the other half in all the patients. Betamethasone 17-valerate fluocinolone acetonide, fluocinonide halcinonide, triamcinolone acetonide, betamethasone diproprionate were all used for treating at least one patient as examples of the high-potency preparations. The ointment form of the drug was used unless it was not commercially available. The patients were evaluated by three persons on a daily basis, two of whom did not know to which sides the corticosteroids had been applied.

The patients were at least 90% improved within two weeks, and no consistent and substantial difference was observed between the two sides during this time. In three patients, small areas were not treated with topical medication, and these patients lagged behind in their improvement.

In four patients, the hydrocortisone was dissolved in the salicylic acid gel at a concentration of 1%, and a single application was used at night on one side while the high-potency corticosteroid and salicylic acid gel were used in sequence, as mentioned, on the other side. No difference was observed between the two sides except for some dryness on the hydrocortisone side that was corrected by use of a lubricant during the day.

We have observed these same results with two patients with atopic dermatitis (with tar and UV-B) and one with lichen planus (without tar and UV-B), which suggests that hydrocortisone and occlusion may be of value in other disorders. When hydrocortisone and a high-potency corticosteroid are compared without occlusion, the former is clearly inferior, as might be expected. Interestingly, Stoughton[1] indicated that the difference between various high-potency corticosteroids may be impossible to discern when occlusion is used.

Considering the lack of adverse effect and the difference in cost, hydrocortisone may be the drug of choice when occlusion is used. We have not firmly established that the salicylic acid gel is necessary for the effect, but we have used it based on our earlier observation that the gel increased the efficacy of corticosteroids.

HOWARD P. BADEN, MD
Boston

Nonproprietary Names and Trademarks of Drugs

Betamethasone diproprionate–*Diproderm, Diprosone.*
Fluocinonide–*Lidex, Topsyn.*
Halcinonide–*Halog.*

1. Stoughton RB: Perspectives in topical glucocorticosteroid therapy. *Prog Dermatol* 9:7-11, 1975.
2. Sulzberger MB, Witten VH: Thin pliable plastic films in topical dermatologic therapy. *Arch Dermatol* 84:1027-1028, 1961.
3. Rook A: Disorders of connective tissue, in Rook A, Wilkinson DS, Ebling FJG (eds): *Textbook of Dermatology.* Philadelphia, FA Davis Co, 1972, vol 2, p 1462.

Seroepidemiologic Search for Cause of Psoriasis

To the Editor.–As a follow-up to our short report, "Search for a Causal Agent of Psoriasis by Seroepidemiologic Methods," (ARCHIVES 113:1287-1288, 1977), we report the results of testing 24 psoriatic serums and 24 matched control serums for antibodies to antinuclear factor (ANF). With a 2% suspension of mouse liver nuclei as antigen and radioimmunoassay as our test system, we find that the psoriatic serum has less antibodies ($P = .01$ to .025 as determined by χ^2 analysis with the Yates correction) than do the matched controls. This could be interpreted as ANF antibodies being removed from the serum of psoriasis patients as a result of complexing with an antigen of as yet undetermined nature. This finding supports the idea that psoriasis is an immune-complex disease.

JOAN J. RATNER, MD
KENDALL O. SMITH
San Antonio, Tex

Curious Comedo Genesis

To the Editor.–During the past few months, I have been using a solution of 5% lincomycin hydrochloride monohydrate in 70% isopropyl alcohol for selected cases of acne vulgaris. The papular and cystic lesions have responded to this medication, in the opinions of both the patients and myself. However, recently, in several cases numerous comedones were noted to have developed, after only several months of therapy. The extent of comedonal involvement was quite striking, and caused me to believe that the therapy might have been playing a role as a causative factor. I am most curious to know whether others have had a similar experience.

JOSEPH M. SCHERZER, MD
Scottsdale, Ariz

Nonproprietary Name and Trademark of Drug

Lincomycin hydrochloride monohydrate–*Lincocin.*

Clotrimazole vs Haloprogin in the Treatment of Tinea Cruris

To the Editor.–The choice of clotrimazole vs haloprogin, which VanDersarl and Sheppard (ARCHIVES 113:1233-1235, 1977) used to treat tinea cruris at Keesler Air Force Base, is a matter of amusement and concern to me. A similar study was done at the same government facility several years ago (*JAMA* 230:72-75, 1974) and showed miconazole nitrate cream (Mica Tin) to be 100% effective in tinea cruris, with 95% of the patients being truly cured (no relapse or recurrence). One wonders why the US Air Force has not been using this effective agent on the base and why Maj VanDersarl did not compare clotrimazole and miconazole.

CHRISTOPHER M. PAPA, MD
New Brunswick, NJ

In Reply.–I appreciate Dr Papa's interest in our article and his comments. Perhaps clotrimazole would also have been "100% effective in tinea cruris, with 95% of the patients being truly cured" if we had used a four-week treatment program as Mandy and Garrott did (*JAMA*

230:72-75, 1974) rather than a two-week regimen. We alluded to this possibility in our "Comment."

Haloprogin was chosen for comparison with clotrimazole simply because haloprogin was a topical antifungal preparation frequently prescribed by physicians, and because we were interested in comparing the two.

Undoubtedly, the results of a study comparing the efficacy of clotrimazole against miconazole in dermatophytosis would be interesting. Hopefully, such an evaluation is being done and the results will be forthcoming.

LT COL JULES V. VANDERSARL, MC, USAF,
Madrid, Spain

Nonproprietary Names and Trademarks of Drugs

Clotrimazole–*Lotrimin.*
Haloprogin–*Halotex.*

Bacitracin-Induced Anaphylaxis

To the Editor.–Bacitracin has been reported to cause eczematous[1] and anaphylactic[2,3] allergic reactions on contact with the skin. We are presenting an additional case of anaphylaxis after the application of bacitracin ointment to a skin-graft donor site.

Report of a Case.–A 50-year-old obese woman had an eight-year history of venous insufficiency and stasis dermatitis. She had had recurrent ulcerations over the right medial malleolus. After she had been on a regimen of oral penicillin, she had developed an erythematous, generalized eruption. Previous treatment for the ulcer included silver nitrate soaks and various topical antibiotics.

During her most recent hospitalization, at which time a skin graft was performed, she applied gentamicin sulfate (Garamycin) ointment and an ointment that contained polymyxin B sulfate and bacitracin zinc (Polysporin) to the ulcer and applied the polymyxin B-bacitracin ointment to the graft donor site for five days. Application of both ointments was discontinued because the patient said that she had been allergic to them previously, although no clinical evidence of allergic reaction was seen.

Several days later, bacitracin ointment was applied to the graft donor site. Within ten minutes, intense erythema at the site and a generalized, erythematous, and pruritic maculopapular eruption developed, as well as wheezing and dyspnea. Her blood pressure fell from her usual reading of 110/70 to 85/55 mm Hg. Her pulse rate was 100 beats per minute and her respiratory rate rose to 36 breaths per minute. An ECG and chest roentgenogram were unchanged.

Her condition responded rapidly to treatment with subcutaneous epinephrine, nasal oxygen, and intravenous hydrocortisone, and she was free of symptoms within 20 minutes. Studies of myocardial enzymes were performed serially, and results were within normal limits. There was no evidence of pulmonary embolus.

Comment.–Bacitracin and polymyxin B-bacitracin ointments are available without prescription. The latter ointment contains 500 units/g of bacitracin zinc and 10,000 units/g of polymyxin B sulfate in petrolatum. Bacitracin ointment contains 500 units/g of nonsterile, micronized bacitracin, USP, in white petrolatum, USP, and heavy mineral oil, USP. Neither of the ointments contain added preservatives.

The patient's anaphylactic reaction was presumed to result from the systemic absorption of bacitracin applied to the donor site. Initial sensitization to bacitracin probably occurred prior to the hospitalization. Clinically apparent reaction probably required levels of skin sensitizing antibodies higher than those present earlier in the hospitalization. The patient declined patch testing. Intradermal testing with bacitracin has been reported previously to result in a nearly fatal reaction.[2] An examination for anti-bacitracin reagins might have been of value,[3] but such a test was not performed.

Although bacitracin is considered to be an innocuous medication, is sold over-the-counter, and is often self-prescribed by patients, it may cause severe, life-threatening reactions.

MICHAEL A. VALE, MD
ADRIAN CONNOLLY, MD
ALLEN M. EPSTEIN, MD
MARGO R. VALE, MD
New York

1. Epstein S, Wenzel FJ: Sensitivity to neomycin and bacitracin: Cross sensitization or coincidence? *Acta Derm Venereol* 43:1, 1963.
2. Comaish JS, Cunliffe WJ: Absorption of drugs from varicose ulcers: A cause of anaphylaxis. *Br J Clin Pract* 21:97-98, 1967.
3. Roupe G, Strannegård O: Anaphylactic shock elicited by topical administration of bacitracin. *Arch Dermatol* 100:450-452, 1969.

Nonproprietary Name and Trademark of Drug

Bacitracin ointment–*Baciguent.*

Resistant Condylomata Acuminata in Diabetics

To the Editor.–Condylomata acuminata are verrucous lesions of varying sizes that usually occur in the genital or anal area, and, rarely, in the axillae. During the past 18 months, 14 women between the ages of 19 and 46 years have sought therapy for recalcitrant genital condylomata of 8 to 14 months' duration. In all cases, coexisting insulin-dependent diabetes mellitus was present. All of the affected women had received varying concentrations of podophyllum resin in tincture of benzoin or alcoholic bases with poor results. A cryosurgical approach was instituted. In only 50% of these cases was it possible to achieve complete clearing, and this response was accomplished only after three months of biweekly treatments. Also, I am fully aware that spontaneous involution may have played a role in the cases that responded. I would be interested in finding out whether other practitioners examined diabetic women with unusually resistant genital condylomata acuminata, and whether any explanations for this difficult therapeutic problem have been published.

LAWRENCE E. SKURATON, MD
Bowie, Md

Essential Fatty Acid Deficiency

To the Editor.–The presentation of the case by Skolnik et al., "Human Essential Fatty Acid Deficiency," in the July 1977 ARCHIVES (113:939-941) emphasizes the nutritional need for essential fatty acids (EFA) during total parenteral nutrition. Their patient's clinical signs of dermatitis and alopecia cleared in one to three months with linoleic acid supplementation. A difficulty encountered in monitoring the status of EFA in such patients is that the triene-tetraene ratio and 20:3N-9 markers for EFA deficiency become abnormal within two weeks of starting total parenteral nutrition, while body EFA stores are still quite high.[1] These parameters, although very sensitive for detection, may not be valid guides for monitoring the severity of EFA deficiency.

We have reported a case of dermatitis and alopecia in a patient who had been receiving total parenteral nutrition for five months and who was deficient in zinc. The cutaneous manifestations in this case cleared rapidly after four weeks of zinc supplementation.[2] Our patient had many clinical findings similar to those reported in EFA deficiency, yet EFA supplementation was not necessary for alleviation of his signs and symptoms. We did not make EFA determinations, which undoubtedly would have been indicative of EFA deficiency after such prolonged parenteral nutrition. Evaluation of clinical, as well as laboratory, parameters in zinc and EFA deficiency have led us to postulate a role of zinc in the metabolism of EFA

to prostaglandins, a subject under current investigation. In a recent report on patients with clinical features very similar to those reported by Skolnik et al,[3] levels of both zinc and EFA were found to be low.

We would recommend for patients in whom clinical signs of alopecia or dermatitis develop while they are receiving total parenteral nutrition that both EFA and zinc determinations be made. Our experience suggests that in such cases, supplementation with zinc, with or without linoleic acid, may resolve the cutaneous manifestations more rapidly than can be achieved with linoleic acid alone.

ARNOLD L. SCHROETER, MD
STEPHEN B. TUCKER, MD
Rochester, Minn

1. Wene JD, Connor WE, DenBesten L: The development of essential fatty acid deficiency in healthy men fed fat-free diets intravenously and orally. *J Clin Invest* 56:127-134, 1975.

2. Tucker SB, Schroeter AL, Brown PW Jr, et al: Acquired zinc deficiency: Cutaneous manifestations typical of acrodermatitis enteropathica. *JAMA* 235:2399-2402, 1976.

3. Fleming CR, Smith LM, Hodges RE: Essential fatty acid deficiency in adults receiving total parenteral nutrition. *Am J Clin Nutr* 29:976-983, 1976.

Simultaneous Occurrence of Familial Benign Chronic Pemphigus (Hailey-Hailey Disease) and Syringoma on the Vulva

To the Editor.—Hailey-Hailey disease and syringomas both occur in the vulva and are associated with pruritus. Recently we encountered a patient who had both these lesions in the vulva. We report this case to illustrate the need for both the dermatologist and the pathologist to be aware that these two pathological entities can coincidentally occur in the same area.

Report of a Case.—The patient was a 39-year-old woman who was seen in 1972 at the Harbor General Hospital Gynecology Clinic, Torrance, Calif, complaining of a vaginal discharge and vulvar pruritus of three days' duration. Physical examination showed a white exudate in the vagina and on the labia majora. *Monilia* was identified in a hanging drop preparation. The symptoms soon resolved after treatment with nystatin ointment and vaginal suppositories.

The patient remained asymptomatic until 1976 when a severe pruritus of the vulva again developed. Examination revealed a white vaginal discharge and erythematous, oozing, crusting maculopapular lesions on the labia majora that were extremely tender. Although the symptoms resolved after treatment with nystatin ointment and vaginal suppositories, at a follow-up visit, multiple papulovesicular lesions remained on the labia majora, and a punch biopsy of the left labium majus was performed. Microscopic sections (Figure) showed a suprabasillar and intraepidermal bulla. Within the overlying detached stratum malpighii, many cells showed loss of intercellular bridges. The bulla itself contained numerous acantholytic cells. In addition, a number of elongated dermal papillae that were covered with epidermal cells protruded into the bulla. The dermis contained numerous small ducts lined by two rows of epithelial cells, some of which were notably flattened. A few of these ducts displayed small comma-like strands of epithelial cells. The histological diagnoses of Hailey-Hailey disease and syringoma were made in consultation with Drs James H. Graham and Ronald J. Barr, University of California, Irvine. The patient denied the presence of similar lesions in any family members.

Comment.—Familial benign chronic pemphigus, which was first described by Hailey and Hailey in 1939,[1] is manifested by recurrent vesiculobullous lesions that usually occur on the neck, axilla, and intertriginous areas such as the inguinal, genitocrural, perianal, inframammary, and antecubital areas.[2] The basic defect appears to be a detachment of the tonofilaments from their desmosomes, resulting in a degeneration of the intercellular bridges.[2] The acantholytic process can be initiated by friction, such as rubbing or scratching, and by environmental factors, such as heat, perspiration, and infection with *Staphylococcus aureus*[3] or *Candida albicans*.[4] In our patient, the eruptions appear to have been precipitated by monilial vulvovaginitis.

Syringomas represent an adenoma of the eccrine sweat gland and are usually located on the lower eyelids, cheeks, axillae, and abdomen.[5] Syringomas are only rarely reported on the vulva, but are probably more common in that area than is generally recognized.[6] Although syringomas may be associated in the same individual or in other members of the same family with trichoepitheliomas, sebaceous gland adenomas, pigmented nevi, hemangiomas,[7] and palmar keratoses,[8] we could find no previously documented occurrence with Hailey-Hailey disease. The coexistence of these two entities in the same area is probably coincidental. Nonetheless, the clinician and histopathologist should be alerted so that the possibility of such an association can be evaluated in future patients.

DONALD T. KING, MD
FRANK M. HIROSE, MD
Torrance, Calif
LAURA A. KING, MD
Irvine, Calif

Punch biopsy specimen of left labium majus showing suprabasilar and intraepidermal bulla.

References

1. Hailey H, Hailey H: Familial benign chronic pemphigus. *Arch Dermatol Syph* 39:679-685, 1939.

2. Lever WF: *Pemphigus and Pemphigoid.* Springfield, Ill, Charles C Thomas Publisher, 1965, pp 122-132.

3. Loewenthal LJA: Familial benign chronic pemphigus: The role of pyogenic bacteria. *Arch Dermatol* 80:318-326, 1959.

4. Burns RA, Reed WB, Swatek FE, et al: Familial benign chronic pemphigus: Induction of lesions by *Candida albicans. Arch Dermatol* 96:254-258, 1967.

5. Lever WF, Schaumburg-Lever G: *Histopathology of the Skin,* ed 5. Philadelphia, JB Lippincott, 1975, p 513.

6. Carneiro SJC, Gardner HL, Knox JM: Syringoma of the vulva. *Arch Dermatol* 103:494-496, 1971.

7. Lund HZ: *Tumors of the Skin.* Atlas of Tumor Pathology, Armed Forces Institute of Pathology, 1957, pp 80-81 and pp 86-89.

8. Baden HP: Hereditary syringomas. *Arch Pathol Lab Med* 113:1133, 1977.

Graft-vs-Host Reaction

To the Editor.—In the June 1977 ARCHIVES (113:806-812), Grogan et al said that, in the one case of lichen-planus-like eruption (LPLE) after bone marrow transplantation that we have described,[1] there was no mention of satellite cell necrosis (SCN). They have quoted our first report of one case, but not a subsequent one of four cases of LPLE,[2] in which SCN is illustrated in figure 3 of the report. We did not emphasize the picture of SCN because, according to Lerner et al,[3] we have found, in 17 cases of graft-vs-host reaction (GVHR) after bone marrow transplantation in adults, that epidermal cell necrolysis (ECN) without a satellite mononuclear cell

was much more frequent. After reading the report by Grogan et al, we reviewed the slides of our LPLE and found that SCN was actually seen in every case; however, ECN was more frequent. The presence of SCN in cases of LPLE is additional evidence that LPLE is a manifestation of chronic GVHR.[4] Whether SCN actually illustrates the direct killing of epidermal cells by grafted lymphocytes has yet to be established. Streilein and Billingham[5] have shown that the epidermis was likely to be damaged indirectly in GVHR (the innocent-bystander hypothesis).

As in the case of Grogan et al, we have not found substantial deposits of immunoglobulins in the early skin lesions of 17 cases of GVHR, by the use of direct immunofluorescence.[6] In cases of LPLE there were only globular deposits of IgM in the upper part of the dermis, very similar to those of idiopathic lichen planus. These findings support the view of most investigators that the skin lesions of GVHR are not antibody-mediated.[7]

JEAN-H SAURAT, MD
ELIANE GLUCKMAN, MD
Paris

1. Saurat JH, Didier JL, Gluckman E, et al: Graft-versus-host reaction and lichen-planus-like eruption in man. *Br J Dermatol* 92:591-592, 1975.
2. Saurat JH, Gluckman E, Bussel A, et al: The lichen planus-like eruption after bone marrow transplantation. *Br J Dermatol* 92:675-681, 1975.
3. Lerner KG, Kao GF, Storb R, et al: Histopathology of graft-versus-host reaction in human recipients of marrow from HLA-matched sibling donors. *Transplant Proc* 6:367, 1974.
4. Saurat JH, Gluckman E: Lichen-planus-like eruption: A manifestation of the graft-versus-host disease. *Clin Exp Dermatol*, to be published.
5. Streilein WJ, Billingham RE: An analysis of the graft-versus-host disease in Syrian hamster: The epidermolytic syndrome: Studies on its pathogens. *J Exp Med* 132:181-197, 1970.
6. Saurat JH, Bonnetblanc JM, Gluckman E, et al: Skin antibodies in bone marrow transplanted patients. *Clin Exp Dermatol* 1:377, 1976.
7. Grebe SC, Streilein WJ: Graft-versus-host reactions: A review. *Adv Immunol* 22:119-124, 1976.

In Reply.—Our article was written before we received the excellent paper by Saurat et al.[1] Unfortunately, the procedure of submittal, review, revision, and final acceptance of a manuscript sometimes entails several months. I apologize for not having had the opportunity to acknowledge and refer to the article by Saurat et al. I feel compelled to disclose to Saurat et al that their article was actually published in volume 93 (p 675) of the *British Journal of Dermatology*, even though the journal incorrectly has the volume number as 92.

Most importantly, the comments by Saurat and Gluckman are appreciated and indeed relevant. Their finding of satellite cell necrosis in each of their 17 cases of GVHR after bone marrow transplantation, even though epidermal cell necrolysis without a satellite mononuclear cell was more frequent, is an important, helpful, and distinguishing histopathological feature. I concur that the direct killing of epidermal cells by grafted lymphocytes remains to be established. We intended only to lend support to the direct-interaction theory. The direct immunofluorescence results in their cases with early GVHR and those with lichen planus-like eruptions are most noteworthy. The constructive criticism and additional information provided by Saurat and Gluckman is gratefully recognized.

LT COL RICHARD B. ODUM, MC, USA
San Francisco

1. Saurat JH, Gluckman E, Bussel A, et al: The lichen planus-like eruption after bone marrow transplantation. *Br J Dermatol* 93:675-681, 1975.

Penile Cysts and Canals

To the Editor.—We read with interest the article of Powell et al (ARCHIVES 113:1250-1251, 1977), entitled "Apocrine Cystadenoma of the Penile Shaft." In Fig 3, the authors describe columnar epithelium with decapitation secretion; however, their photomicrograph appears to show transitional epithelium. We are in the process of reporting our experience with seven cysts and one epithelial-lined canal of the penis, which were seen during the past three years. The lesions were lined by transitional epithelium in six of our cases and by stratified squamous epithelium in two cases. We feel that these lesions correspond to what has previously been reported as "congenital canals and cysts of the genitoperineal raphe."[1] These lesions, which are usually midline and ventral, may occur anywhere from the urethral meatus to the anus. Cysts and canals of the median raphe represent defects in the embryological development of the genitalia and may be lined by epithelium of either endodermal or ectodermal differentiation. The cysts that are frequently translucent and contain a clear, watery fluid are usually first noted during childhood. Two of our cases, however, were not diagnosed until after the persons were over 50 years of age. Secondary infection with *Neisseria gonorrhoeae* may occur.[2-4] Surgical excision is curative.

LOREN E. GOLITZ, MD
RICHARD ASARCH, MD
WILLIAM SAUSKER, MD
GEORGE M. KREYE, MD
Denver

1. Neff JH: Congenital canals and cysts of the genitoperineal raphe. *Am J Surg* 31:308-315, 1935.
2. Sowmini CN, Vijayalakshmik, Chellamuthiah C, et al: Infections of the median raphe of the penis. *Br J Venereal Dis* 49:469-474, 1972.
3. Bernfeld WK: Gonorrhea in the median raphe of the penis: Case report and a survey of the literature. *Br J Venereal Dis* 37:210-213, 1961.
4. Rupel E: Epikerman canals infected with gonococcus. *Surg Gynecol Obstet* 39:636-638, 1924.

In Reply.—We are grateful to Golitz et al for their reminder of the median raphe cyst, a lesion that we should have included in the differential diagnosis. However, we do not believe that our patient had a median raphe cyst. In most areas, the cyst excised from our patient was clearly lined by a double layer of cells: an inner layer of cuboidal to columnar secretory cells and an outer layer of myoepithelium. Transitional epithelium does not have a myoepithelial layer, nor does it exhibit a cuboidal or columnar architecture. In addition, the cytoplasm of the secretory cells contain PAS-positive, diastase-resistant granules that are characteristic of apocrine epithelium and that are not found in transitional epithelium. These findings are more consistent with our diagnosis of apocrine cystadenoma than with that of median raphe cyst.

RALPH F. POWELL, MD,
CHARLES H. PALMER, MD
EDGAR B. SMITH, MD
Albuquerque, NM

Erythema Elevatum Diutinum

To the Editor.—The case of erythema elevatum diutinum that responded to dapsone, which was reported by Fort and Rodman (ARCHIVES 113:819-822, 1977) prompts us to report another case, in which lesions of erythema elevatum diutinum were responsive to dapsone and coexisted with other vasculitic lesions that did not respond to dapsone but responded to prednisone.

Report of a Case.—A 65-year-old man was admitted to the Brooklyn (NY) Veterans Administration Hospital in 1975. He was well until ten months prior to this admission, when he developed rheumatoid arthritis.

Fig 1.—Erythema elevatum diutinum lesions on arms.

Fig 2.—Erythema elevatum diutinum lesions on palms.

Fig 3.—Lesions of vasculitis on legs.

One month later, erythematous, infiltrated plaques and nodules developed over the extensor surfaces of the patient's arms, and small petechiae appeared on his anterior legs. The plaques were asymptomatic and increased in size during the next nine months. Ulcers developed on both legs. One week prior to admission, a ring-shaped skin lesion appeared on the left palm and gradually increased in size.

Results of physical examination on admission were within normal limits except for the following:

1. Lungs: Scattered rhonchi, bilaterally
2. Abdomen: Liver enlarged 2 finger breadths below the right costal margin
3. Joints:
   a. Swollen ankle and knee joints
   b. Enlargement of the metacarpophalangeal joints with ulnar deviation
4. Skin:
   a. Violaceous, infiltrated, smooth-surfaced plaques, with superficial pustules and sharp borders over the extensor surfaces of the arms (Fig 1) and in the left axilla
   b. Purple, scaly, annular plaques with sharp, elevated, nodular borders and depressed centers over the palms and interphalangeal joints of the first and second fingers (Fig 2)
   c. Numerous, discrete, purple papules over the buttocks and upper thighs
   d. Small, infiltrated ulcers and petechiae on the anterior legs (Fig 3)

The laboratory workup demonstrated the following pertinent findings: WBC, 13,700/cu mm with a normal differential; ESR, 31 mm/hr; rheumatoid factor positive, 1:10,224. Skin biopsy specimens showed a dense, diffuse neutrophilic infiltrate around blood vessels and were compatible with erythema elevatum diutinum.

Course.—The elbow lesions improved with intralesional and topical steroids. A regimen of dapsone (100 mg/day) resulted in complete clearing of the hand lesions, but the leg ulcers worsened. A regimen of prednisone (60 mg/day) was started, and dapsone therapy was discontinued. The leg ulcers improved, but within three days, lesions reappeared on the hands, and pustules developed over the elbows. Dapsone therapy was reinstituted, and hand and elbow lesions disappeared.

With the combination of dapsone and prednisone therapy, the leg ulcers healed, and the patient has remained free of all skin lesions for the past 1½ years while prednisone therapy was slowly tapered and then stopped. His rheumatoid arthritis, which was controlled by the prednisone therapy, remains in remission. His rheumatoid factor dropped to zero.

Comment.—Erythema elevatum diutinum is a form of leukocytoclastic vasculitis. It is characterized by an abundant infiltrate of neutrophils. The suppressive effect of dapsone may be mediated by stabilization of lysosomes.

FLOYD R. TANZER, MD
YELVA L. LYNFIELD, MD
Brooklyn, NY

Topical Sulfadiazine Silver for Bullous Pemphigoid

To the Editor.—In the past year we have used sulfadiazine silver (Silvadene) for topical treatment of stubborn bullous pemphigoid lesions with very good results. Sulfadiazine silver is a water-miscible cream that has broad antimicrobial activity against Gram-negative and Gram-positive bacteria as well as yeast. It is supplied in 50- and 400-g jars.[1]

We have been applying sulfadiazine silver twice daily following Burrow's compresses and are impressed with the superiority of this regimen compared with other topical treatments, such as gentian violet. All lesions that have been treated have healed exceedingly quickly with a minimum of secondary infection. In addition, we have had two patients with localized bullous pemphigoid for which systemic treatment was not indicated and treatment with sulfadiazine silver alone resulted in complete remission.

The question arises whether the therapeutic effect of sulfadiazine silver is due to its broad antimicrobial activity or to a local effect of sulfadiazine on blister formation. One also has to consider whether the silver is a noncompetitive (irreversible) inhibitor of sulfhydryl containing proteolytic enzymes[2] (epidermal, dermal, or polymorphonuclear leukocyte) that may be related to blister formation.[3]

Sulfadiazine silver should be used with caution in persons with glucose-6-dehydrogenase deficiency, previous hypersensitivity, and sulfonamide hypersensitivity. Owing to substantial absorption of sulfadiazine silver, we recommend that no more than 10% to 20% of a patient's surface area be covered at one time on a twice daily schedule.[1]

We have had no experience with sulfadiazine silver for other bullous dermatoses, such as dermatitis herpetiformis.

JOHN M. CHADWICK, MD
THOMAS F. DOWNHAM II, MD
Detroit

Nonproprietary Name and Trademarks of Drug

Sulfadiazine silver—*CF-100, Silvadene.*

1. *Physicians' Desk Reference.* Oradell, NJ, Medical Economics Co, 1977, p 1018.
2. White A, Handler P, Smith EL: *Principles of Biochemistry.* New York, McGraw-Hill Book Co Inc, 1964, p 237.
3. Remay W, Bockendahl H, Stuttgen G: Induction of autoantibody formation in pemphigoid by proteolytic enzymes? *Hautarzt* 27:344-346, 1976.

Primary Acquired Cold Urticaria

To the Editor.—Wanderer and his colleagues (ARCHIVES 113:1375-1377, 1977) demonstrated that cyproheptadine hydrochloride is a useful drug in the management of patients with primary acquired cold urticaria. However, I think that they denigrated the method of what is termed "cold desensitization" as a means of treatment. It is quite true that if this type of therapy is carried out carelessly then systemic reactions can occur. On the other hand, when the therapy is used with care for a few days, it can main-

tain patients in a completely symptom-free state.

We reported our use of this method with one patient a few years ago.[1] Since then, a number of other cases also have been treated successfully. Spontaneous remission is well recognized in the physical urticarias, and it is perhaps advisable to leave a small area of skin untreated. This can be used from time to time as a test site for the appropriate stimulus to ensure that spontaneous remission has not occurred.

Far from discouraging cold desensitization, as suggested by Wanderer et al, I would urge dermatologists to use this method. A similar procedure has been used with success in the rare condition of localized heat urticaria[2] and in the more common solar urticaria.[3] I would stress that, when used carefully, this method can relieve symptoms in the majority of patients with a physical urticaria and it removes the need for long-term systemic drug therapy.

COLIN A. RAMSAY, MD, MRCP
Toronto

1. Leigh IM, Ramsay CA, Calnan CD: Cold urticaria—"desensitization." *Trans St John's Hosp Derm Soc* 60:40-42, 1974.
2. Leigh IM, Ramsay CA: Localized heat urticaria treated by inducing tolerance to heat. *Br J Dermatol* 92:191-194, 1975.
3. Ramsay CA: Solar urticaria treatment by inducing tolerance to artificial radiation and natural light. *Arch Dermatol* 113:1222-1225, 1977.

In Reply.—My reply to Dr Ramsay's comment is based primarily on the well-observed fact that acquired cold urticaria may induce serious anaphylactoid reactions. In one series, Horton et al[1] described a 50% incidence of systemic reactions with syncope; 40% occurred while the persons were swimming and 18% of the persons had to be rescued during aquatic activities. Since cold urticaria must be viewed as a disorder with potential risk, it is imperative that the choice of treatment be predicated on answers to the following questions.

First, is the treatment dependable and is its suppressive effect on cold sensitivity predictable? In regard to cold desensitization, more studies are required to answer this question, since most available data are either anecdotal or based on a very small sample of cases. For practical reasons, it is also important to know whether cold sensitivity can recur spontaneously during and after completion of the cold-desensitization method.

Second, are there any significant risk factors associated with the treatment modality? I suggest that cold desensitization may have substantial risk factors, namely, the inadvertent induction of anaphylactoid reactions. Systemic reactions have been observed even in controlled conditions after application of a cold stimulus to a single anatomical site.[2,3]

Third, is the treatment conducive to patient compliance? Currently, there has been no objective comparison; however, it would be my conjecture that patients would prefer an oral medication, ie, cyproheptadine hydrochloride, which has minimal side effects, over a time-consuming technique, ie, cold desensitization, which has potential serious reactions.

ALAN A. WANDERER, MD
Denver

1. Horton B, Brown G, Roth G: Hypersensitiveness to cold with local and systemic manifestations of a histamine-like character: Its amenability to treatment. *JAMA* 107:1263-1269, 1936.
2. Rose B: Histamine, hormones and hypersensitivity. *J Allergy* 25:168-182, 1954.
3. Kierland R: Physical allergies. *Arch Dermatol Syphilol* 68:61-68, 1953.

Epidermotropic Mycosis Fungoides

To the Editor.—We have read Dr Lever's case report of "Localized Mycosis Fungoides With Prominent Epidermotropism: Woringer-Kolopp Disease" (ARCHIVES 113:1254-1256, 1977) with great interest because of the dearth of information available in the English language on the disorder. Dr Lever correctly credits the French physicians Woringer and Kolopp with the original description of the localized form of this rare variant of mycosis fungoides.

We would like to call attention to a long neglected paper that we believe represents the first report of the generalized form of Woringer-Kolopp disease. In 1931 (eight years prior to Woringer and Kolopp's original description), Ketron and Goodman of the Johns Hopkins Medical School reported the case of a 59-year-old bricklayer under the title, "Multiple Lesions of the Skin Apparently of Epithelial Origin Resembling Clinically Mycosis Fungoides."[1] The well-documented histopathologic findings in this case are indistinguishable from what we know today as Woringer-Kolopp disease.

JAMES WARREN STEGER, MD
San Diego
DANIEL SANTA CRUZ, MD
St Louis

1. Ketron LW, Goodman MH: Multiple lesions of skin apparently of epithelial origin resembling clinically mycosis fungoides: Report of a case. *Arch Dermatol Syphilol* 24:758-777, 1931.

Chlor-Trimeton® 12 Mg.
brand of chlorpheniramine maleate, USP
Repetabs® Tablets, brand of repeat-action tablets

Clinical Considerations:
INDICATIONS

Based on a review of this drug by the National Academy of Sciences—National Research Council and/or other information, FDA has classified the indications for CHLOR-TRIMETON REPETABS Tablets as follows: "Probably" effective: For perennial and seasonal allergic rhinitis; vasomotor rhinitis; allergic conjunctivitis due to inhalant allergens and foods; mild, uncomplicated allergic skin manifestations of urticaria and angioedema; amelioration of allergic reactions to blood or plasma; dermatographism; as therapy for anaphylactic reactions adjunctive to epinephrine and other standard measures after the acute manifestations have been controlled.
Final classification of the less-than-effective indications requires further investigation.

CONTRAINDICATIONS Use in Newborn or Premature Infants: This drug should not be used in newborn or premature infants.
Use in Nursing Mothers: Because of the higher risk of antihistamines for infants generally and for newborns and prematures in particular, antihistamine therapy is contraindicated in nursing mothers.
Use in Lower Respiratory Disease: Antihistamines should not be used to treat lower respiratory tract symptoms, including asthma.
Antihistamines are also contraindicated in the following conditions: hypersensitivity to chlorpheniramine maleate and other antihistamines of similar chemical structure; monoamine oxidase inhibitor therapy.
WARNINGS Antihistamines should be used with considerable caution in patients with: narrow angle glaucoma; stenosing peptic ulcer; pyloroduodenal obstruction; symptomatic prostatic hypertrophy; bladder neck obstruction.
Use in Children: In infants and children especially, antihistamines in overdosage may cause hallucinations, convulsions or death.
As in adults, antihistamines may diminish mental alertness in children. In the young child particularly, they may produce excitation.
Use in Pregnancy: Experience with this drug in pregnant women is inadequate to determine whether there exists a potential for harm to the developing fetus.
Use with CNS Depressants: Chlorpheniramine maleate has additive effects with alcohol and other CNS depressants (hypnotics, sedatives, tranquilizers, etc.).
Use in Activities Requiring Mental Alertness: Patients should be warned about engaging in activities requiring mental alertness, such as driving a car or operating appliances, machinery, etc.
Use in The Elderly (approximately 60 years or older): Antihistamines are more likely to cause dizziness, sedation, and hypotension in elderly patients.
PRECAUTIONS Chlorpheniramine maleate has an atropine-like action and therefore should be used with caution in patients with: a history of bronchial asthma; increased intraocular pressure; hyperthyroidism; cardiovascular disease; hypertension.
ADVERSE REACTIONS Slight to moderate drowsiness occurs relatively infrequently with chlorpheniramine maleate. Other possible side effects common to antihistamines in general include:
General: urticaria, drug rash, anaphylactic shock, photosensitivity, excessive perspiration, chills, dryness of mouth, nose, and throat.
Cardiovascular System: hypotension, headache, palpitations, tachycardia, extrasystoles.
Hematologic System: hemolytic anemia, thrombocytopenia, agranulocytosis.
Nervous System: sedation, dizziness, disturbed coordination, fatigue, confusion, restlessness, excitation, nervousness, tremor, irritability, insomnia, euphoria, paresthesias, blurred vision, diplopia, vertigo, tinnitus, acute labyrinthitis, hysteria, neuritis, convulsions.
Gastrointestinal System: epigastric distress, anorexia, nausea, vomiting, diarrhea, constipation.
Genitourinary System: urinary frequency, difficult urination, urinary retention, early menses.
Respiratory System: thickening of bronchial secretions, tightness of chest and wheezing, nasal stuffiness.
11046240 February 1977
For more complete details, consult package insert or Schering literature available from your Schering Representative or Professional Services Department, Schering Corporation, Kenilworth, New Jersey 07033.

Purity & Quality*

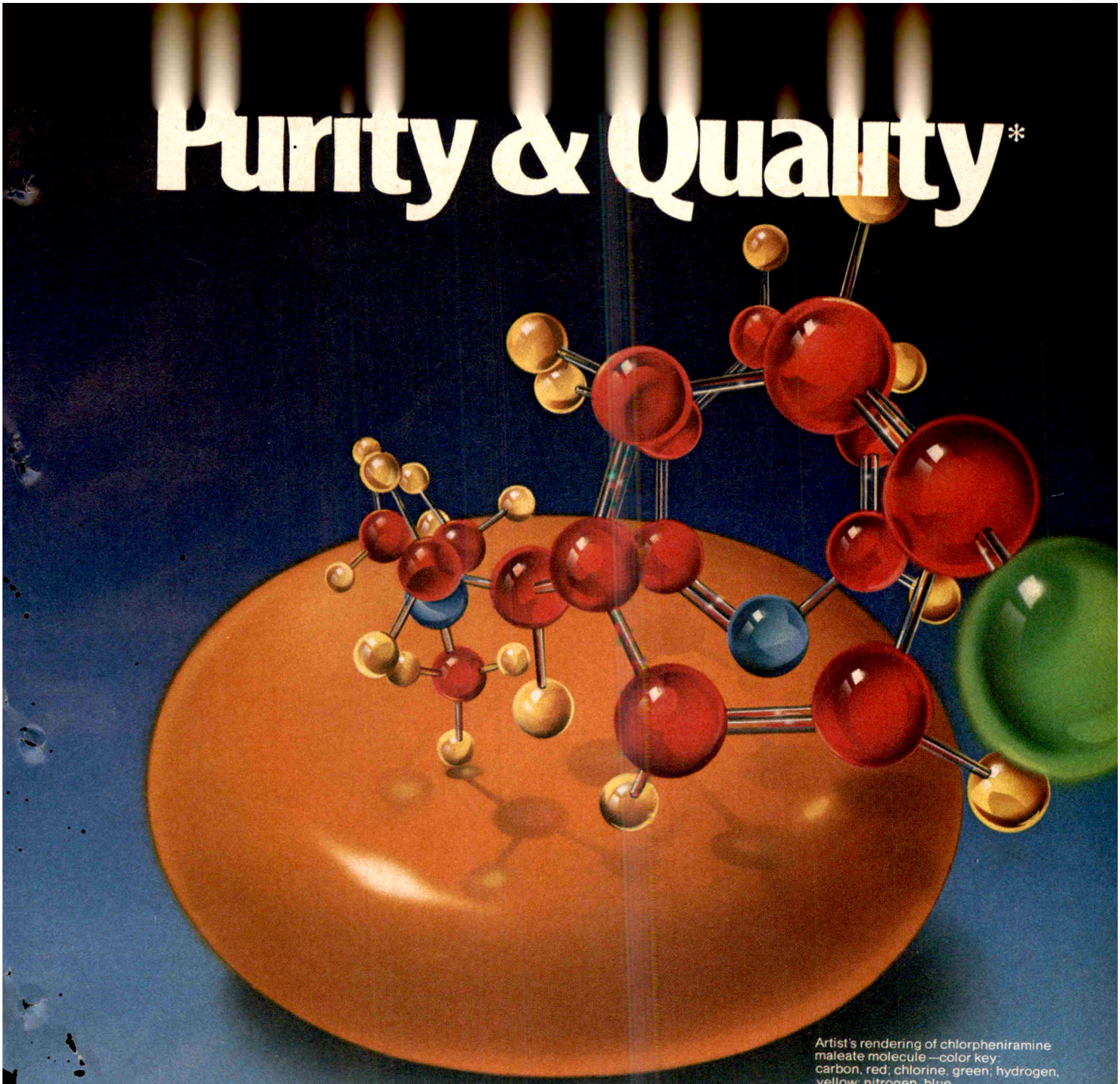

Artist's rendering of chlorpheniramine maleate molecule—color key: carbon, red; chlorine, green; hydrogen, yellow; nitrogen, blue.

Chlor-Trimeton® 12mg.

brand of
chlorpheniramine maleate, USP

Repetabs® Tablets, brand of repeat-action tablets

Available on prescription only.

An original Schering research discovery

*This drug has been evaluated as "probably" effective.
See Clinical Considerations section on opposite page.

COPYRIGHT © 1978, SCHERING CORPORATION. ALL RIGHTS RESERVED

SLS-177

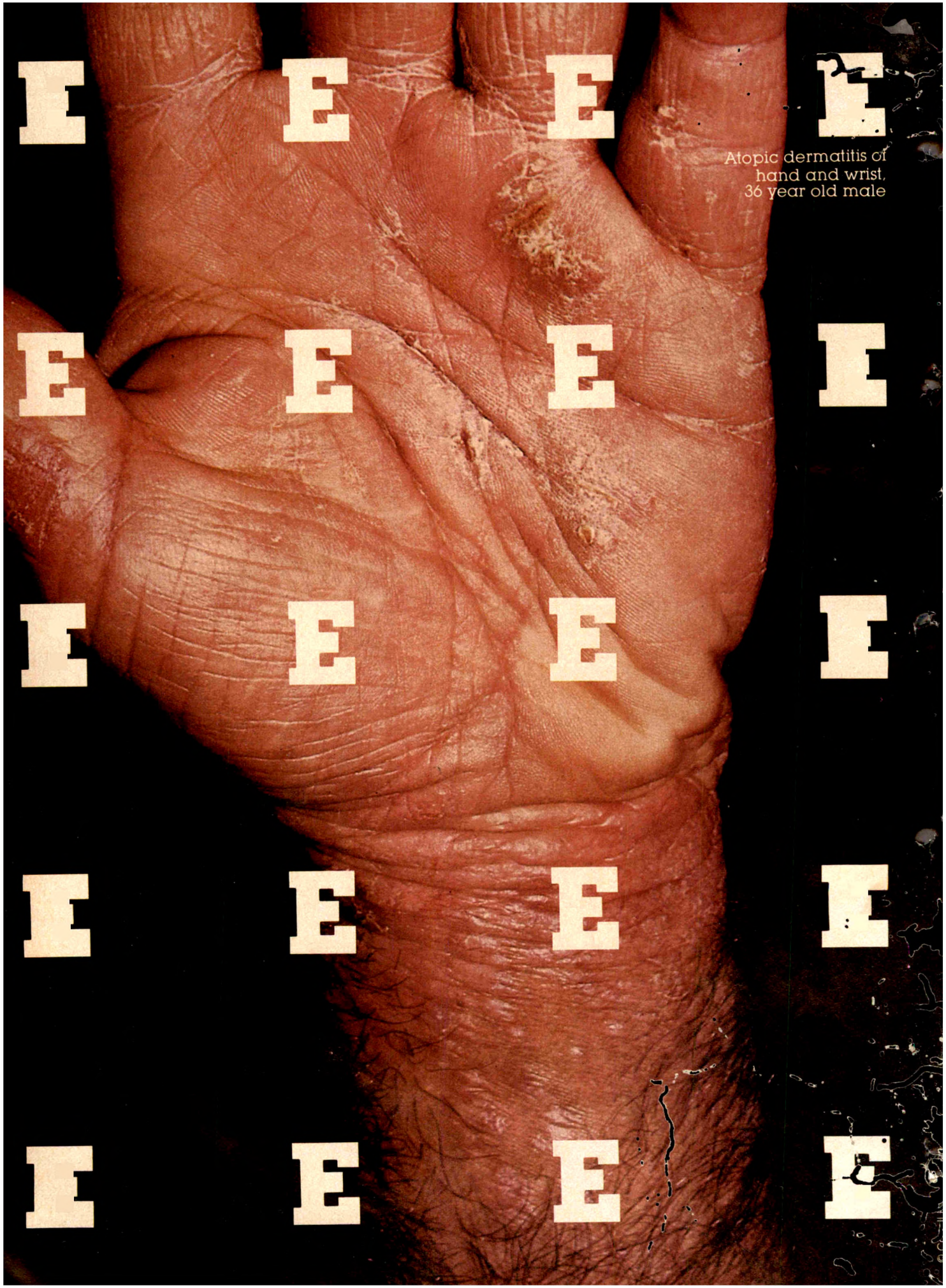

Atopic dermatitis of hand and wrist, 36 year old male

Added versatility in dermatology

new Lidex®-E (fluocinonide) 0.05%

The established potency of fluocinonide, in a soothing emollient base.

Less drying than a cream, with the lubricating qualities of an ointment—cosmetically acceptable to patients.

Especially useful wherever a soothing topical steroid is indicated, as in atopic dermatitis.

Available in 15g and 60g tubes.

SYNTEX

Please see following page for summary of prescribing information

new
Lide® E
(fluocinonide)
Cream 0.05%

Prescribing Information

Description LIDEX-E cream 0.05% contains the active compound fluocinonide. Fluocinonide, which is the 21-acetate ester of fluocinolone acetonide, has the chemical formula 6α, 9-difluoro-11β, 16α, 17, 21-tetrahydroxypregna-1, 4-diene-3, 20-dione, cyclic 16, 17-acetal with acetone, 21-acetate.

The cream contains fluocinonide 0.5 mg./g. in a water-washable aqueous emollient base of stearyl alcohol, cetyl alcohol, mineral oil, propylene glycol, sorbitan monostearate, polysorbate 60, citric acid and purified water.

Actions Topical steroids are primarily effective because of their anti-inflammatory, antipruritic and vasoconstrictive actions.

Indications For relief of the inflammatory manifestations of corticosteroid-responsive dermatoses.

Contraindications Topical steroids are contraindicated in vaccinia and varicella.

Topical steroids are contraindicated in those patients with a history of hypersensitivity to any of the components of the preparation.

Precautions If irritation develops, the cream should be discontinued and appropriate therapy instituted.

In the presence of an infection, the use of an appropriate antifungal or antibacterial agent should be instituted. If a favorable response does not occur promptly, the corticosteroid cream should be discontinued until the infection has been adequately controlled.

If extensive areas are treated, the possibility exists of increased systemic absorption and suitable precautions should be taken.

Although topical steroids have not been reported to have an adverse effect on pregnancy, the safety of their use in pregnant females has not absolutely been established. Therefore, they should not be used extensively on pregnant patients, in large amounts or for prolonged periods of time.

This product is not for ophthalmic use.

Adverse reactions The following local adverse reactions have been reported with topical corticosteroids: burning sensations, itching, irritation, dryness, secondary infection, folliculitis, acneform eruptions, hypopigmentation, striae, skin atrophy.

Dosage and Administration A small amount should be gently massaged into the affected area three or four times daily, as needed.

How Supplied LIDEX®-E (fluocinonide) cream 0.05% — 15g. and 60g. tubes.

SYNTEX
SYNTEX LABORATORIES, INC.
PALO ALTO, CALIFORNIA 94304

News and Notes

Tropical Dermatology.—The International Society of Tropical Dermatology will hold an Interim-Congress in Israel and London, Nov 1-16, 1978. The scientific program is under the direction of Drs Sigfrid A. Muller and Jacob Sheskin, for the Israel part, and of Drs Arthur Rook and R.M.M. Harman, for the London meetings. CME credit category I, accorded to our previous meetings, is pending. A group flight will depart from New York, Nov 1. Those interested should contact Coleman Jacobson, MD, arrangements chairman, 3600 Gaston Ave, Dallas, TX 75246.

European Ski Biology Conference.—The European Society for Comparative Skin Biology Conference will be held on Sept 19-22, 1978, at the University College Hospital Medical School, London. This conference will include short papers submitted in the fields of cell structure and function, permeability and barrier function, and control mechanisms. Discussion group sections will include keratins and keratinization, and cell growth and proliferation. There will be a poster exhibition and a special lecture by Prof N. A. Mitchison, FRS, "The Skin in Immunology." Further details may be obtained from the local secretary, Dr P. A. Riley, Department of Biochemical Pathology, University College Hospital Medical School, London WC1E 6JJ, England.

Fellowship in Cutaneous Oncology and Mohs' Chemosurgery.—A fellowship in cutaneous oncology and Mohs' chemosurgery will be awarded for a one-year period beginning on July 1 of each year. Preference will be given to applicants who have completed postgraduate medical specialty training that is pertinent to Mohs' chemosurgery (dermatology, surgery, etc), and to those applicants who come from areas in the United States or from foreign countries where the procedure is not now available but where there is a substantial number of patients who are likely to benefit from Mohs' chemosurgery. Preference will be given to those persons who intend to establish a cutaneous oncology and chemosurgery division affiliated with a medical center department of dermatology and who have the endorsement of that department's chariman. The stipend will be $15,000 per year or commensurate with the applicant's level of training. Applications with supporting information should be addressed to Henry Menn International Fellowship, Department of Dermatology, University of Miami School of Medicine, POB 520875, Miami, FL 33152.

Graduate Course in Immunology.—The American Dermatologic Society for Allergy and Immunology announces its third annual graduate course, Basic and Clinical Immunology. The guest of honor and recipient of the society's award this year is Dr Robert A. Good, Sloan Kettering Institute, who will serve as keynote speaker for the meeting, discussing the topic, "Immunodermatology and Cancer Therapy." The society also has among its distinguished faculty, the new president of the American Academy of Dermatology, Dr Robert Goltz, who will talk on "Skin Manifestations of the Immune Deficiency Diseases." A host of other faculty members include Drs Peter Lynch, Michael Fellner, Hermann Pinkus, Aaron Lerner, and Philip Brunell.

The meeting will be held at the Airport Hilton Hotel in Denver. The meeting is certified for 9 hours of Continuing Medical Education, category 1 credit to the American Academy of Dermatology. Meeting will begin Thursday morning, Sept 28 and end Saturday, Sept 30. Before- and after-meeting activities are in the planning stage and further information can be obtained by writing to Dr Michael Fellner.

Leprosy Congress.—The Eleventh International Leprosy Congress will be held in Mexico City Nov 13-18, 1978. The main scientific themes are as follows: epidemiology and control; experimental leprosy; clinical aspects; microbiology; immunology; social aspects; experimental chemotherapy; clinicopathological aspects; and therapy and rehabilitation. The scientific program incorporates main themes, free papers and poster communications sessions, and case presentations. There will be a social program, a program for accompanying persons and a general assembly of the Inter-

[illegible] Leprosy Association. Registration fees in US dollars are as follows: before July 31—participants, $125; accompanying persons, $40; after July 31—participants, $150; accompanying persons, $50. The address of the organizing committee is Dr Vertiz, 464, Mexico 7, DF. Hotel accommodations, sightseeing, and tours before and after the congress are being arranged by Mundus Tours de Mexico, SA, which is the official travel agency of the congress, and the agency may be contacted by writing to Paseo de la Reforma 379, Mexico 5, DF. The preliminary program was distributed in February and is available. Leprologists, dermatologists, general practitioners, and other medical specialists are invited to attend.

Symposium on Plastic and Reconstructive Surgery.—The Third International Symposium on Plastic and Reconstructive Surgery of the Head and Neck and the Fifth Annual Clinical and Scientific Meeting of the American Society for Dermatologic Surgery will be held April 29-May 4, 1979 at the New Orleans Hilton Hotel, New Orleans. The course moderator will be George Farber, MD. For information write to George Farber, MD, 144 Elk Pl, Suite 1604, New Orleans, LA 70112.

This meeting will substitute for the Clinical and Scientific Meeting to be held in the Princess Hotel of the Bahamas, March 28—April 1, 1979.

Medical Mycology Course.—An intensive four-day course in the basics and recent advances in medical mycology is being offered to physicians and microbiologists at Temple University Health Sciences Center, June 19-22, 1978.

The course, with an international faculty, is designed to emphasize the clinical aspects of various mycoses, but will include an introduction to general mycology and a review of fungi causing diseases in man.

Directors of the course are Drs Helen Buckley, Carroll F. Burgoon, Jr, James C. Gentles, and Hillel Levine. The faculty includes Drs Frederick Urbach, Jack Bennett, Chapman Binford, and Chester F[illegible]ons.

[illegible] th[illegible] $75 [illegible]pants [illegible]r the [illegible] of the [illegible] or [illegible].2 [illegible]e ob-[illegible]ne, Office for Continuing Medical Education, Temple University School of Medicine, Broad and Ontario Streets, Philadelphia, PA 19140; telephone number is 221-4787.

Course in Dermal Pathology.—The 20th Annual Postgraduate Course in Dermal Pathology will be held Aug 20-25, 1978, at the Newporter Inn, Newport Beach, Calif. This course is designed primarily for pathologists and dermatologists interested in cutaneous pathology and physicians preparing for such boards as the Examination for Certification of Special Competence in Dermatopathology and those given by the American Boards of Pathology and Dermatology. Emphasis will be placed on reviewing the basic and modern concepts of dermal pathology. This year increased emphasis has been placed on workshop and self-assessment approaches. Microscopes will be provided. Registration is limited. The course has the approval of the Office of Continuing Medical Education, California College of Medicine, University of California, Irvine (UCI) and is accredited by the American Medical Association's Council on Medical Education for category I credit toward the Physicians Recognition Award of the AMA and of the California Medical Association. For further information contact Margaret Frederick, executive secretary, Memorial Hospital Medical Center—UCI Center for Health Education, 2801 Atlantic Ave, PO Box 1428, Long Beach, CA 90801; telephone (213) 595-3823.

Medical Mycology—Dermatomycology.—A continuing education course in medical mycology—dermatomycology, with special one-day self-assessment workshop, will be held Aug 16-19, 1978, at the Newporter Inn, Newport Beach, Calif. This course is designed for those interested in developing or updating their knowledge of medically important fungi. Emphasis will be placed on a workshop approach supplemented with didactic material presented by a group of experts in the field. The last day of the scientific program, will be devoted entirely to a self-assessment workshop, designed in part, for those preparing for specialty examination. Although given in conjunction with the course, the self-assessment workshop may be taken separately. Microscopes will be provided. Course registration is limited. The program has the approval of the Office of Continuing Medical Education, California College of Medicine, University of California, Irvine (CCM-UCI), and is accredited by the American Medical Association's Council on Medical Education for category I credit toward the Physicians Recognition Award of the AMA and of the California Medical Association. For further information contact Margaret Frederick, executive secretary, Memorial Hospital Medical Center—UCI Center for Health Education, 2801 Atlantic Ave, PO Box 1428, Long Beach, CA 90801; telephone (213) 595-3823.

Third Regional Conference of Dermatology.—The third Regional Conference of Dermatology will be held on Nov 23-27, 1978 in Bali, Indonesia. The scientific program includes education courses, guest lectures and free papers. Participants who wish to present a paper are requested to send a preliminary title no later than June 1, 1978 and abstracts, not exceeding 200 words, no later than August 1, 1978. The official language will be English. The registration fee is $75 for delegates and $37.50 for associates. For further information contact A. Kosasih, MD, 55A, Jl. Moh. Yamin SH, Jakarta, Indonesia.

European Symposium on Psoriasis.—A European symposium on psoriasis will be held in Trieste, Italy, on Oct 20 and 21, 1978 under the auspices of the European Society for Dermatological Research and Società Italiana di Dermatologia e Sifilografia. It is being organized by Professor C. Scarpa, Director of the Dermatological Clinic of Trieste University.

Official speakers will be invited and the symposium will be held at the Savoy-Excelsior Palace Hotel. Participants will also be accommodated in this hotel.

The scientific program comprises four sessions: (1) genetics and immunology; (2) biochemistry and histochemistry; (3) microscopy—light and electronic; and (4) clinical varieties.

Confirmation of attendance is requested by June 15. The final program will be issued in August. The official language of the symposium is English. The confirmation fee is $50 for participants and $25 for guests who accompany them.

Further information, together with a copy of the preliminary program, can be obtained by writing to Professor Carmelo Scarpa, Dermatological Clinica, c/o Ospedale Maggiore, 34129 Trieste, Italy.

Vectrin® Capsules

(minocycline hydrochloride capsules, USP)

50 and 100 mg

effective adjunctive treatment in severe acne

Before Treatment | **After Treatment**

84 DAYS
Vectrin, 50 mg, twice daily

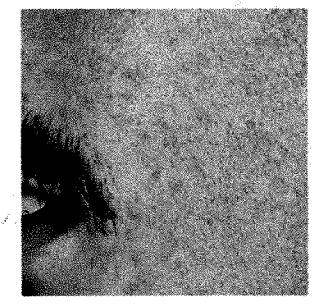

91 DAYS
Vectrin, 50 mg, twice daily

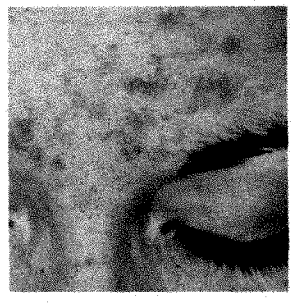

40 DAYS
Vectrin, 100 mg, once daily

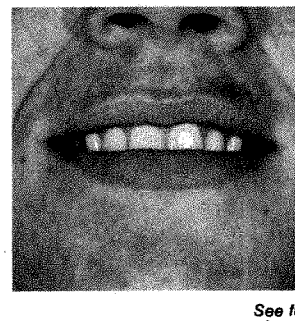

84

o[redacted]

See followi[redacted]
of prescrib[redacted]

[illegible]RIN Capsules, 50 and 100 mg
[illegible]cycline HCl capsules, USP
[illegible]mmary of Prescribing Information

[illegible] in sev[illegible] as adjunctive therapy. Consult pac[illegible] insert for complete prescribing information.

Contraindication: Hypersensitivity to any tetracycline.

Warnings: When need for intensive treatment outweighs potential dangers, perform renal and liver function tests before and during therapy; also follow serum concentrations. In renal impairment, usual doses may lead to excessive accumulation and liver toxicity. Under such conditions, use lower total doses, and, in prolonged therapy, determine serum levels. The use of tetracyclines during tooth development (last half of pregnancy, infancy, and childhood to the age of 8 years) may cause permanent discoloration of the teeth (yellow-gray-brown). This is more common during long-term use but has been observed following repeated short-term courses. Enamel hypoplasia has also been reported. Tetracyclines, therefore, should not be used in this age group unless other drugs are not likely to be effective or are contraindicated. Photosensitivity manifested by an exaggerated sunburn reaction has been observed in some individuals taking tetracyclines. Advise patients apt to be exposed to direct sunlight or ultraviolet light that such reaction can occur, and discontinue treatment at first evidence of skin erythema. Studies with minocycline HCl indicated that photosensitivity did not occur. However, reports have been received. In patients with significantly impaired renal function, the antianabolic action of tetracycline may cause an increase in BUN leading to azotemia, hyperphosphatemia, and acidosis. **CNS side effects:** (light-headedness, dizziness, vertigo) have been reported, may disappear during therapy, and always disappear rapidly when drug is discontinued. Caution patients who experience these symptoms about driving vehicles or using hazardous machinery while taking this drug. **Pregnancy:** In animal studies, tetracyclines cross the placenta, are found in fetal tissues, and can have toxic effects on the developing fetus (often related to retardation of skeletal development). Embryotoxicity has been noted in animals treated early in pregnancy. The safety of minocycline HCl for use during pregnancy has not been established. **Newborns, infants, and children:** All tetracyclines form a stable calcium complex in any bone-forming tissue. Prematures, given oral doses of 25 mg/kg every six hours, demonstrated a decrease in fibula growth rate, reversible when drug was discontinued. Tetracyclines are present in the milk of lactating women who are taking a drug in this class.

Precautions: Use may result in overgrowth of nonsusceptible organisms, including fungi. If superinfection occurs, antibiotics should be discontinued and appropriate therapy instituted. In venereal diseases when coexistent syphilis is suspected, darkfield examination should be done before treatment is started and blood serology repeated monthly for at least four months. Patients on anticoagulant therapy may require downward adjustment of such dosage. Test for organ system dysfunction (eg, renal, hepatic, and hemopoietic) in long-term use. Treat all group A beta-hemolytic streptococcal infections for at least 10 days. Avoid giving tetracycline in conjunction with penicillin.

Adverse Reactions: GI: Anorexia, nausea, vomiting, diarrhea, glossitis, dysphagia, enterocolitis, inflammatory lesions (with monilial overgrowth) in anogenital region. **Skin:** Maculopapular and erythematous rashes. Exfoliative dermatitis (uncommon). Photosensitivity is discussed above. (See Warnings.) **Renal toxicity:** Rise [illegible]BUN, dose-related. (See Warnings.) **Hypersensitivity [illegible]ctions:** Urticaria, angioneurotic edema, anaphylaxis, [illegible]aphylactoid purpura, pericarditis, exacerbation of [illegible]stemic lupus erythematosus. In young infants, bulging fontanels have been reported following full therapeutic dosage, disappearing rapidly when drug was discontinued. **Blood:** Hemolytic anemia, thrombocytopenia, neutropenia, eosinophilia. **CNS:** (See Warnings.) When given over prolonged periods, tetracyclines may produce brown-black microscopic discoloration of thyroid glands; no abnormalities of thyroid function studies are kn[illegible]ccur.

NOTE [illegible]ant [illegible]ing [illegible]tion; [illegible]dies [illegible]no- [illegible] by [illegible]uest

Society Transactions

The Society Proceedings are edited by Dr Harry L. Arnold, Jr, Straub Clinic, Honolulu, HI 96813. Transactions and photographs should be sent, in duplicate, directly to him.

LOS ANGELES DERMATOLOGICAL SOCIETY

Oct 13, 1976

Arnold W. Gurevitch, MD, Recorder

Mycosis Fungoides. Presented by JAMES L. WIEGERINK, MD

A 52-year-old man noted onset of a few nonpruritic erythematous lesions in 1966. A biopsy specimen was interpreted as parapsoriasis in plaques. In subsequent years, he noted increasing pruritus and increasing numbers of lesions. A repeated biopsy specimen in 1972 was again read as parapsoriasis in plaques. He was treated with a bath oil, moisturizing cream, and topical steroids, with some relief. Because of severe pruritus, he was placed on a regimen of prednisone, 40 mg every other day, for approximately six weeks, but with no change.

In July 1976, two additional biopsy specimens were interpreted as suggestive of mycosis fungoides. Since then, there has been increasingly severe pruritus and thickening of the plaques. Another biopsy, performed on Sept 15, 1976, is presented. Currently, the patient is not taking internal medication, but is using an emulsion ointment base (Cetaphil) topically. Other than the cutaneous findings, the physical examination results were normal. A complete blood count, urinalysis results, liver function test results, and liver scan were normal. Blood was drawn for lymphocyte culture and identification.

Discussion

LEO INDIANER, MD: Clinically, this patient has mycosis fungoides. Microscopically, there is irregular parakeratosis and acanthosis, a dense infiltrate, in the upper portion of the dermis, of lymphocytes and histiocytes, and small cells with crenated nuclei that resemble Sézary cells. The microscopic diagnosis is hyperplastic reticulosis, compatible with premycotic mycosis fungoides or parapsoriasis in plaques. There are no Pautrier's abscesses. Mycosis fungoides is regarded as a T-cell abnormality, with abnormal cells in the skin, spleen, and liver. These abnormal cells occur in clusters. The diagnostic cells are not the small cerebriform cells, but are rather large, atypical, mycosis cells.

STANLEY M. BIERMAN, MD: This patient has mycosis fungoides, in spite of a lack of definitive histopathological changes. The plaques are getting thicker, and a biopsy specimen should be taken from these thicker areas. I would consider therapy with topical nitrogen mustard or the electron beam. He has tolerated this disease for ten years, but he is now experiencing clinical relapse. There is need for treatment.

A PHYSICIAN: I would consider PUVA, a less dangerous form of therapy.

LYON ROWE, MD: At a recent meeting at Stanford Medical School, PUVA therapy was recommended. If this patient does not have systemic involvement, he would be a good candidate for this therapy. He should be given 40 mg of psoralen two hours before each treatment with ultraviolet-A. The exposures should be increased to a maximum of 30 to 40 minutes, depending on the type of light-box. Twenty to 30 treatments are needed. We are trying this currently for a patient with parapsoriasis, with signs of improvement.

DR INDIANER: The patient may have systemic involvement, but we may have to do a node biopsy or laparotomy to find it. Blood studies of T cells are important. In addition, a buffy-coat analysis may be worthwhile.

JAMES L. WIEGERINK, MD: The induration of this patient's skin lesions varies from week to week. The two most recent biopsy specimens were indeed taken from the most indurated lesions at that time. Clinically he has mycosis fungoides.

NOTE: Two additional biopsies were performed on October 20, 1976. These specimens revealed a polymorphous infiltrate of lymphoreticular cells in the upper portion of the dermis, which included occasional large, atypical-appearing cells. In some areas, the infiltrate appeared to extend into the lower portion of the epidermis. Focally, within the epidermis, aggregates of atypical cells were present, compatible with Pautrier's microabscesses. The biopsy specimens were interpreted as mycosis fungoides.

For Skin That Needs Your Special Skills...
Neutrogena...
for exceptional patient compliance.*

For Skin without Water

Neutrogena® Dry-Skin Soap**
Neutrogena® Rainbath® Bath Gel**
Neutrogena® Hand Cream**

Neutrogena®
Dedicated to Sensitive Skin Care.

Neutrogena Corp., 5755 West 96th Street, Los Angeles, California 90045

*Journal reprints on clinical evaluation describing patient compliance are available on request.
**Available as unscented formulas.

INDEX TO ADVERTISERS

A

Abbott Laboratories 642-643

B

Barnes-Hind Pharmaceuticals 668-669

C

Campbell Laboratories, Inc. 682
Cooper Laboratories, Inc. 664, 787

D

Dermik Laboratories ..... 3rd Cover
De Zwaluw 682
Doak Pharmacal Company 679
Dome Laboratories 645, 662-663, 676-677
Dorsey Laboratories 691-692

G

General Foods 703
General Medical Company 685
Grune & Stratton 694

H

Herbert, G.S., Laboratories, Division of Allergan Pharmaceuticals 673
Hoechst-Roussel Pharmaceuticals 696-698

J

Johnson & Johnson 648-649, 797

L

Lederle Laboratories, Division of American Cyanamid Company 683-684, 793

N

Neutrogena Corporation 812

O

Owen Laboratories, Inc. 641

P

Parke-Davis & Company 810-811
Pharmacia Diagnostics 639
Procter & Gamble Company .. 653-654, 692A-692F, 699, 796A-796B
Purdue Frederick Company 795

R

Reed & Carnrick 674-675
Riker Laboratories, Inc. ..... 667, 6[illegible]5
Roche Laboratories, Division of Hoffmann-LaRoche, Inc. ..... 657-[illegible]59
Roerig, J.B., Company Division of Pfizer, Inc. 686-687

S

Schering Corporation ..... 670-672, [illegible]80-682, 688-689, 804-805
Smith Kline & French Laboratories 788-789
Squibb, E.R., & Sons, Inc. ..... 700-70[illegible]
Stiefel Laboratories, Inc. ..... [illegible]
Stuart Pharmaceuticals Div. of ICI Americas Inc. ..... [illegible]
Syntex Laboratories, Inc. ..... [illegible]

Westwood Pharmaceuticals, Inc. ..... 6[illegible]

While every precaution is taken to insure accuracy, we cannot guarantee against th[illegible] occasional change or omission in the preparation of this index.

ACNE'S ANXIETY

BENZAGEL® 5% Acne Gel 10% Acne Gel

(5% or 10% benzoyl peroxide, 6% polyoxyethylene lauryl ether, 40% alcohol)

Early visible improvement helps to relieve anxiety and promotes patient cooperation—Simple and pleasant to use

- Benzoyl peroxide in a special alcohol gel base—Reliable and predictable, imparts a pleasant cooling sensation with controlled drying of sebaceous oils. Accelerates desquamation.
- "BP base/bond" for uniform therapeutic deposition of benzoyl peroxide—Reduces burning sensation on application, for greater patient acceptance.
- Effective antibacterial and comedolytic action—Rapid improvement is seen, often within two weeks.

BENZAGEL® a basic component of acne therapy

Descripti [illegible] or 10% benzoyl peroxide, 6% [illegible] ether and 40% alcohol in an [illegible] colloidal magnesium aluminum [illegible] ethylcellulose, citric acid, fragrance [illegible]

[illegible] desquamative and antiseptic [illegible]

[illegible] treatment of acne.

[illegible] tion: Wash affected areas prior to [illegible] more daily or as directed

Contraindications: Should not be used by patients having known sensitivity to either benzoyl peroxide or polyoxyethylene lauryl ether.

Precautions: For External Use Only. Not for ophthalmic use. Keep away from eyes and mucosae. Very fair individuals should begin with a single application at bedtime allowing overnight medication. May bleach colored fabrics. Keep this and all other medications out of the reach of children.

Caution: Federal law prohibits dispensing without prescription.

How Supplied: Plastic tubes, 1½ oz. and 3 oz.

[illegible] For Patient Starters [illegible] Free (800) 523-6674

Dermik

Dermik Laboratories, Inc.
Fort Washington, Pa. U.S.A. 19034

You've made PreSun® (5% PABA) number one*

Now, a major clinical sunscreen study confirms PreSun's premier sunscreen position.

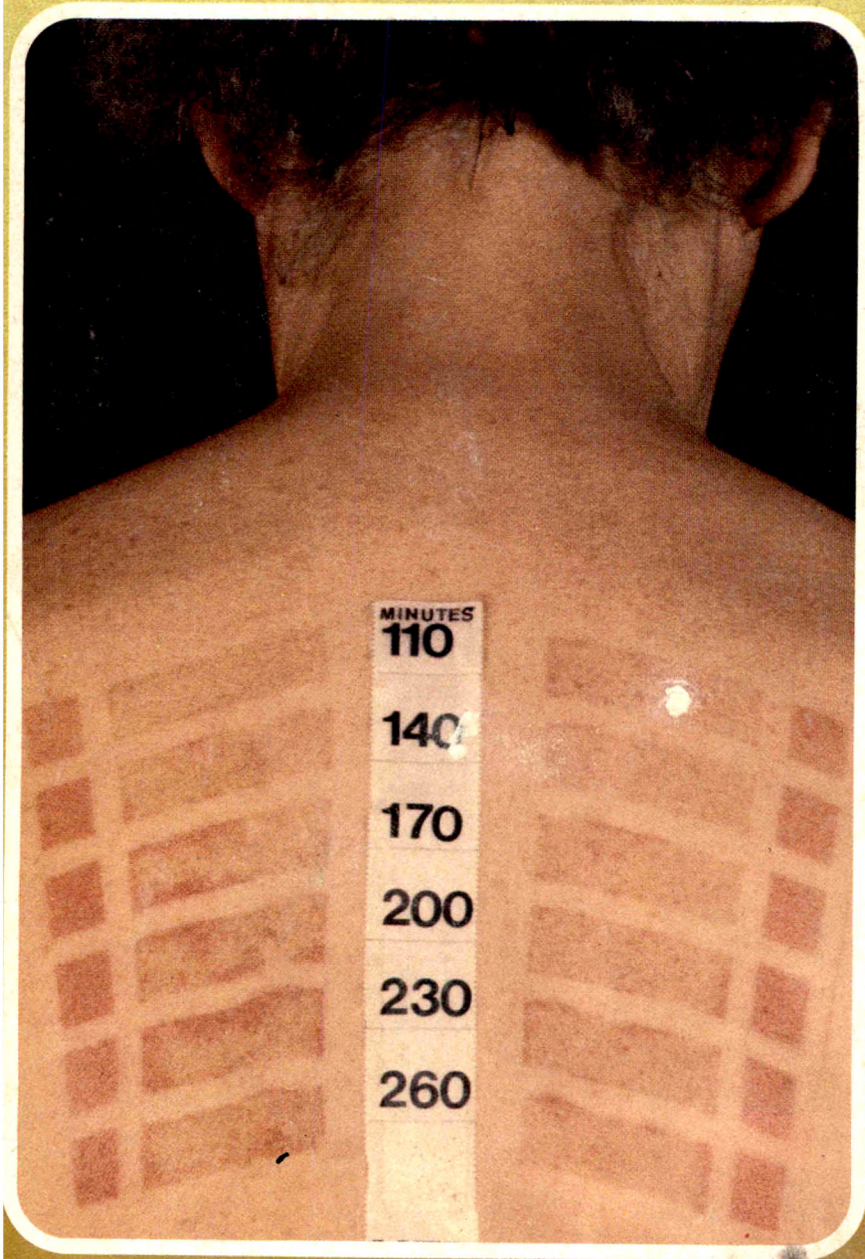

Unretouched photo of subject's back, PreSun® applied (right) and another sunscreen product (left).

Westwood designed its most rigidly controlled sunscreen study to date; 68 sun-sensitive volunteers were exposed to increasing amounts of southern California sunlight up to 4 hours. This complex investigation demonstrated important differences between the degree of protection that sunscreen products afford. PreSun® was shown to afford maximum sunscreen protection. On an average, PreSun allowed the sun-sensitive individual to withstand the sun *over eight times longer* before acquiring a slight, painless reddening, than he could unprotected.** PRESUN CONTINUES TO SET THE SUNSCREEN STANDARD. DON'T JEOPARDIZE THE SKIN OF YOUR SUN-SENSITIVE PATIENTS WITH JUST ANY FORMULA.

PreSun® may also help prevent premature aging and skin cancer caused by the sun.

*Based on retail sales of ethically promoted sunscreens.

**Information on file at Westwood Pharmaceuticals Inc.

Wes
PHARM
Buffalo,
In Canada,

29.11.78

Published by the American Medical Association

June 1978
Volume 114, Number 6

archives of Dermatology

Prognostic Index in Malignant Melanoma ..... *C. Schmoeckel, O. Braun-Falco* 871

Psoriasis in an Unselected Series of Twins ..... *F. Brandrup, M. Hauge, K. Henningsen, B. Eriksen* 874

Chronic Urticaria-like Lesions in Systemic Lupus Erythematosus .. *S. O'Loughlin, A. L. Schroeter, R. E. Jordon* 879

Salabrasion of Tattoos ..... *W. A. Koerber, Jr, N. M. Price* 884

Successful Use of Cyclophosphamide and Prednisone for Initial Treatment of Pemphigus Vulgaris *M. J. Fellner, J. M. Katz, J. B. McCabe* 889

Speckled Lentiginous Nevus ..... *D. M. Stewart, J. Altman, A. H. Mehregan* 895

Nosocomial Outbreak of Scabies ..... *J. J. Gooch, S. R. Strasius, B. Beamer, M. D. Reiter, G. W. Correll* 897

Bullous Pemphigoid in Children ..... *J. W. Robison, R. B. Odom* 899

Bullous Pemphigoid and Ovarian Cystadenocarcinoma ..... *M. V. Dahl, S. Ristow* 903

Pyoderma Gangrenosum ..... *D. A. Norris, W. L. Weston, E. G. Thorne, J. R. Humbert* 906

Sarcoidosis Associated With Mycosis Fungoides ..... *J. P. McFarland, Y. C. Kauh, H. A. Luscombe* 912

Mycosis Fungoides Evolving to Myelomonocytic Leukemia ..... *R. K. Lofgren, J. C. Wiltsie, R. K. Winkelmann* 916

α_1-Antitrypsin Deficiency Associated With Persistent Cutaneous Vasculitis ..... *F. Brandrup, P. A. Østergaard* 921

Columnar Epidermal Necrosis ..... *H. Tagami, K. Uragami, M. Yamada, T. Aoshima* 925

Cutaneous Manifestations of Noonan's Syndrome ..... *H. W. Wyre, Jr* 929

Hereditary Congenital Hypopigmented and Hyperpigmented Macules ..... *W. Westerhof, F. A. Beemer, R. H. Cormane, J. W. Delleman, W. R. Faber, J. G. Y. de Jong, W. W. van der Schaar* 931

Acrodermatitis and Acquired Zinc Deficiency ..... *R. I. Ecker, A. L. Schroeter* 937

Monosymptomatic Hypochondriacal Psychosis Manifesting as Delusions of Parasitosis ..... *A. Munro* 940

Giant Cell Tumor of the Tendon Sheath Involving Skin *D. T. King, A. J. Millman, A. W. Gurevitch, F. M. Hirose* 944

Dapsone-Induced Jaundice ..... *S. P. Stone, R. M. Goodwin* 947

Mucocutaneous Lymph Node Syndrome (Kawasaki's Disease) *G. Kahn* 948

AMA AMERICAN MEDICAL ASSOCIATION

When they first consult you for seborrheic dermatitis, they've tried everything but magi

Only you can work the magic of a Capitrol® Rx.

(chloroxine 2%)

EFFECTIVENESS

In a recent clinical study, 76% of patients reported clinical improvement with Capitrol®*

Two treatments a week are usually sufficient.

Contains an effective antibacterial.

ELEGANCE

Cosmetically elegant, contains no tar or heavy metals.

SAFETY

The most commonly reported adverse effect has been discoloration of light-colored hair (e.g. blond, gray or bleached). Some itching, burning and dryness have been reported.*

* Information on file at Westwood Pharmaceuticals, Inc.

Caution: Federal law prohibits dispensing without prescription.

Description: Capitrol® shampoo provides 2% chloroxine (each gram contains 20 mg. chloroxine) suspended in a shampoo base containing: sodium octoxynol-3 sulfonate, PEG-6 lauramide, dextrin, stearyl alcohol/ceteareth-20, sodium lauryl sulfoacetate, dioctyl sodium sulfosuccinate, magnesium aluminum silicate, PEG-14M, EDTA, citric acid, water, color and fragrance. The pH of the shampoo is 7.0.

The chemical name of chloroxine is 5,7-dichloro-8-hydroxyquinoline.

Actions: Chloroxine is a synthetic antibacterial compound. It has a structural similarity to a number of substituted 8-hydroxyquinolines that have been in therapeutic use for some years.

Indications: Capitrol® is indicated in the treatment of dandruff and mild to moderately severe seborrheic dermatitis of the scalp.

Contraindications: Capitrol® (chloroxine) may produce allergic contact sensitization reactions in patients who are sensitive to hydroxyquinolines or EDTA. This shampoo should not be used on acutely inflamed (exudative) lesions of the scalp.

Precautions: Patients should be advised to exercise care not to allow Capitrol to enter the eyes. For external use only. Keep this and all drugs out of the reach of children.

Adverse Reactions: Irritation and burning of the scalp and adjacent areas have been reported. Allergic type skin eruptions may occur in patients who are sensitive to any component of the shampoo. As with any medicated shampoo, chemical conjunctivitis may result if Capitrol enters the eyes. Discoloration of light-colored hair (e.g. blond, gray or bleached) may follow use of this preparation. Dryness of the scalp and increased itching have been reported.

Dosage and Administration: Capitrol® (chloroxine) should be massaged thoroughly into the wet scalp, avoiding contact with the eyes. Lather should remain on the scalp for approximately three minutes, then rinsed. The application should be repeated and the scalp rinsed thoroughly. Two treatments per week are usually sufficient.

How Supplied: Capitrol (chloroxine shampoo) is supplied in 85 g plastic tubes.

WESTWOOD
PHARMACEUTICALS INC.
Buffalo, New York 14213

© 1978, W.P.

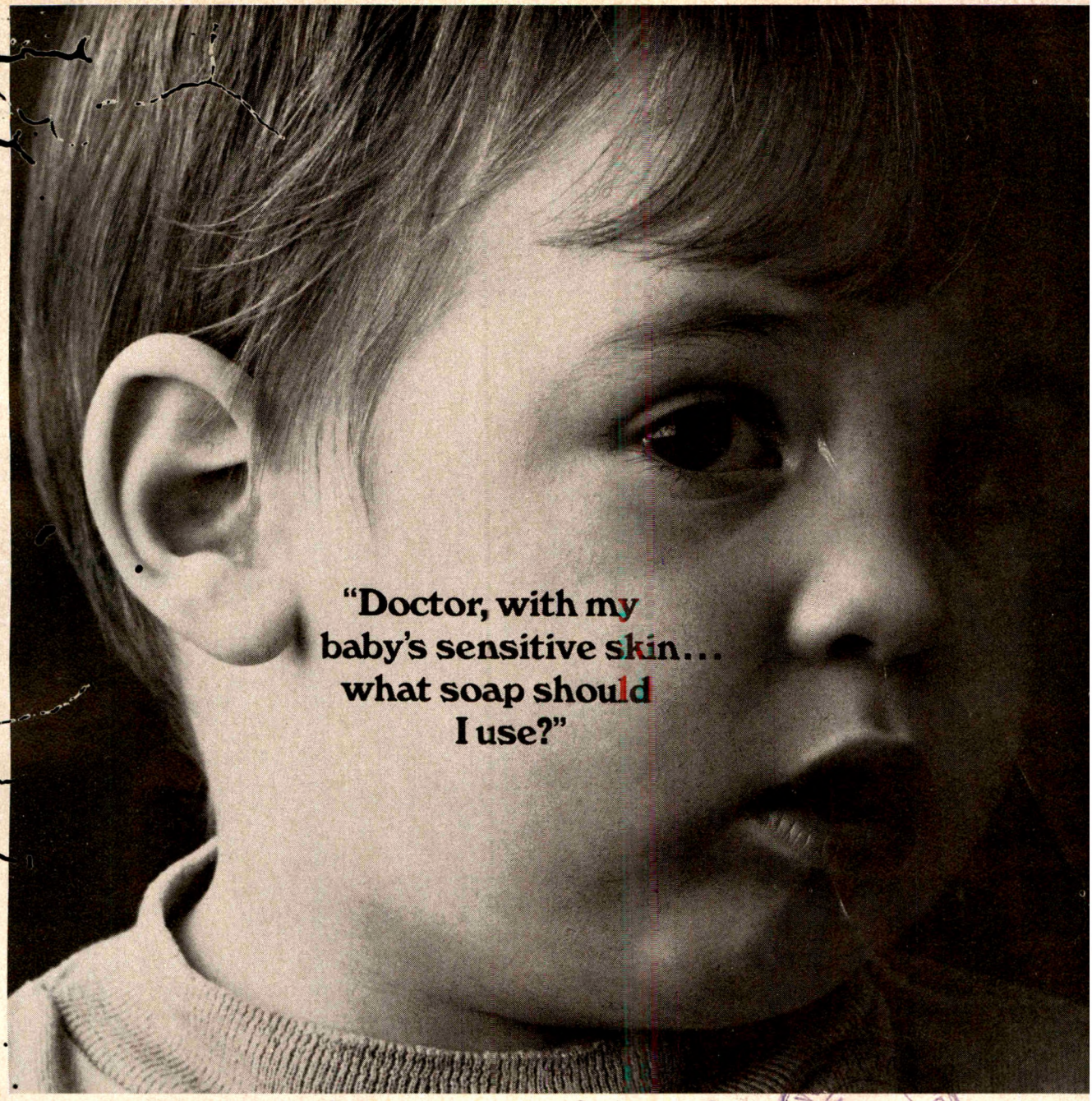

Pure mild Ivory is one of the safest possible soaps you can recommend for sensitive skin. More doctors recommend Ivory than any other soap.

UNIV. OF MISSOURI LIBRARY

It makes sense. Ivory's absence of many extra ingredients helps minimize chances of irritation.

Thirty-eight years of laboratory testing—including patch tests and arm immersion experiments—confirm that Ivory is one of the mildest, least irritating soaps you can recommend.

And 89 years of safe consumer use support this clinical experience.

Ivory may safely be used as an adjunct to treatme of cradle cap, scabies, impetig and seborrhea.



Archives of DERMATOLOGY

Copyright © 1978 by the AMERICAN MEDICAL ASSOCIATION

VOL 114, NO. 6 JUNE 1978

ORIGINAL CONTRIBUTIONS

Prognostic Index in Malignant Melanoma
Christian Schmoeckel, MD, Otto Braun-Falco, MD, Munich, West Germany 871

Psoriasis in an Unselected Series of Twins
Flemming Brandrup, MD; Mogens Hauge, MD, Odense, Denmark; Klavs Henningsen, MD; Birthe Eriksen, MD, Copenhagen 874

Chronic Urticaria-Like Lesions in Systemic Lupus Erythematosus
Sean O'Loughlin, MD; Arnold L. Schroeter, MD; Robert E. Jordon, MD, Rochester, Minn 879

Salabrasion of Tattoos
Walter A. Koerber, Jr, MD, Norman M. Price, MB, ChB, Palo Alto, Calif 884

Successful Use of Cyclophosphamide and Prednisone for Initial Treatment of Pemphigus Vulgaris
Michael J. Fellner, MD; James M. Katz, MD; Jonathan B. McCabe, Roosevelt Island, NY 889

Speckled Lentiginous Nevus
Daniel M. Stewart, DO; Jules Altman, MD; Amir H. Mehregan, MD, Detroit 895

Nosocomial Outbreak of Scabies
James J. Gooch, DPH; Stanley R. Strasius, MD; Betty Beamer, RN; Michael D. Reiter, PharmD; Gene W. Correll, Ann Arbor, Mich 897

CASE REPORTS

Bullous Pemphigoid in Children
Maj J. Wendall Robison, MC, USA, Lt Col Richard B. Odom, MC, USA, Presidio of San Francisco, Calif 899

Bullous Pemphigoid and Ovarian Cystadenocarcinoma
Mark V. Dahl, MD, Sandra Ristow, PhD, Minneapolis 903

Pyoderma Gangrenosum
David A. Norris, MD; William L. Weston, MD; E. George Thorne, MD; James R. Humbert, MD, Denver 906

Sarcoidosis Associated With Mycosis Fungoides
Joseph P. McFarland, MD; Young C. Kauh, MD; Herbert A. Luscombe, MD, Philadelphia 912

Mycosis Fungoides Evolving to Myelomonocytic Leukemia
R. Kurt Lofgren, MD; John C. Wiltsie, MD; R. K. Winkelmann, MD, PhD, Rochester, Minn 916

α_1-Antitrypsin Deficiency Associated With Persistent Cutaneous Vasculitis
Flemming Brandrup, MD, Poul Aa. Østergaard, MD, Odense, Denmark 921

Columnar Epidermal Necrosis
Hachiro Tagami, MD, Hamamatsu, Japan; Kozo Uragami, MD, Kansai, Japan; Mizuho Yamada, MD; Tadahiro Aoshima, MD, Hamamatsu, Japan 925

Cutaneous Manifestations of Noonan's Syndrome
Lt Comdr H. W. Wyre, Jr, MC, USNR, Bethesda, Md 929

(Continued on page 816)

EDITORIAL BOARD

Chief Editor
John H. Epstein, MD
450 Sutter Street
San Francisco 94108

Assistant Chief Editor
Kimie Fukuyama, MD
San Francisco

Assistant Chief Editor
Denny L. Tuffanelli, MD
San Francisco

Donald C. Abele, MD
Augusta, Ga

Harry L. Arnold, Jr, MD
Honolulu

Walter C. Lobitz, Jr, MD
Portland, Ore

Frederick D. Malkinson, MD
Chicago

Sigfrid A. Muller, MD
Rochester, Minn

W. Mitchell Sams, Jr, MD
Chapel Hill, NC

John S. Strauss, MD
Iowa City

Gerald D. Weinstein, MD
Miami

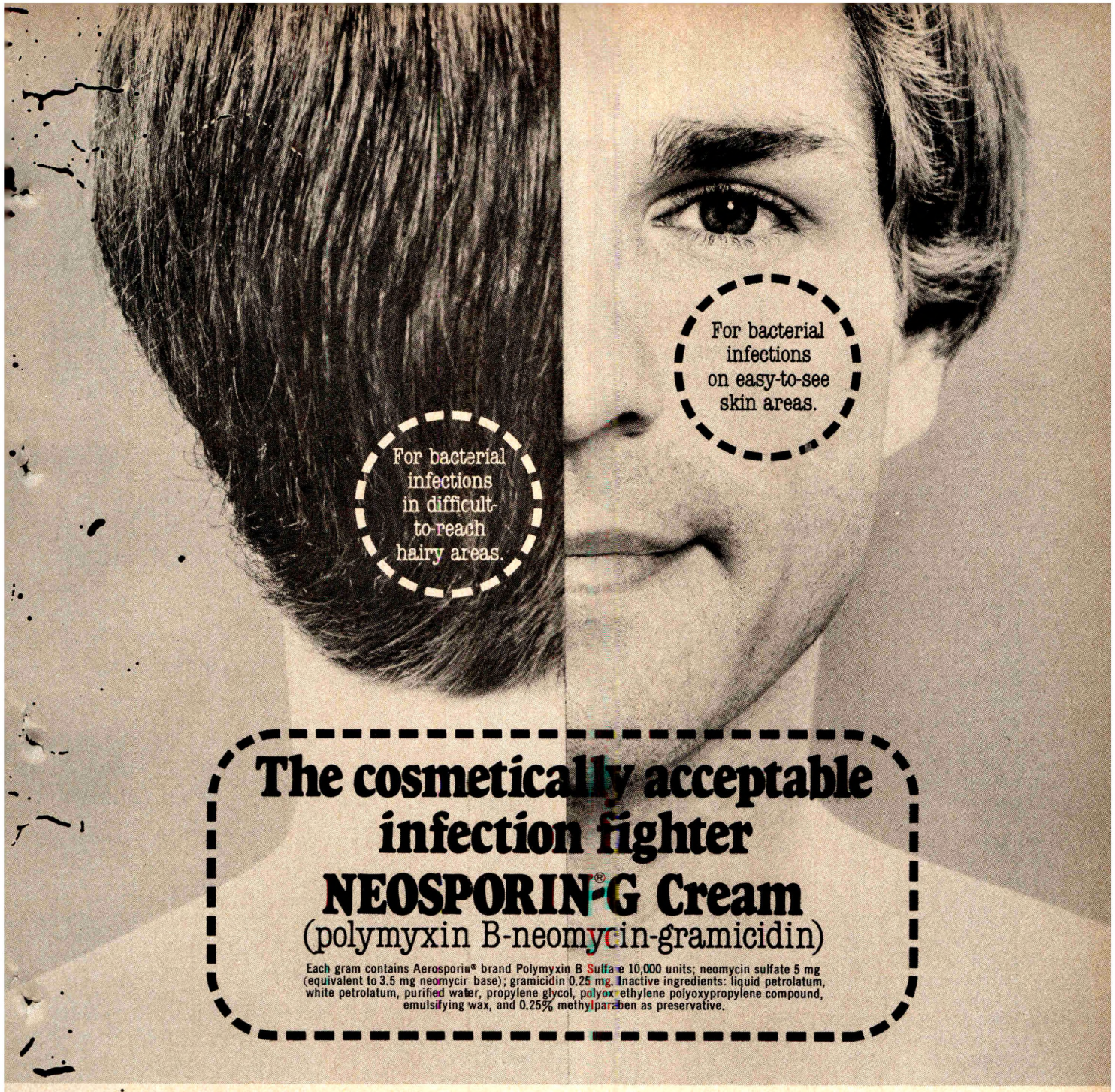

The cosmetically acceptable infection fighter

NEOSPORIN®-G Cream

(polymyxin B-neomycin-gramicidin)

Each gram contains Aerosporin® brand Polymyxin B Sulfate 10,000 units; neomycin sulfate 5 mg (equivalent to 3.5 mg neomycin base); gramicidin 0.25 mg. Inactive ingredients: liquid petrolatum, white petrolatum, purified water, propylene glycol, polyoxyethylene polyoxypropylene compound, emulsifying wax, and 0.25% methylparaben as preservative.

NEOSPORIN®-G Cream

(polymyxin B-neomycin-gramicidin)

When topical infection invades hairy areas, facial skin or intertriginous areas, Neosporin®-G Cream provides broad antibacterial coverage. It contains three antibiotics that combat virtually all pathogenic bacteria found topically.*

These antibiotics are seldom used systemically, so the patient is spared the possibility of sensitization to those antibiotics which might later be required systemically.

Smooth vanishing cream base leaves no greasy residue on skin, no stains on fabric.

Wellcome

Burroughs Wellcome Co.
Research Triangle Park
North Carolina 27709

*INDICATIONS: Based on a review of this drug by the National Academy of Sciences—National Research Council and/or other information, FDA has classified the indications as follows:

"Possibly" effective: For topical administration for the treatment of the listed localized infections or for suppressive therapy in such conditions: • primary pyodermas (impetigo, ecthyma, sycosis vulgaris, paronychia) • secondary infected dermatoses (eczema, herpes, and seborrheic dermatitis) • traumatic lesions (inflamed or suppurating as a result of bacterial infection).

Final classification of the less-than-effective indications requires further investigation.

CONTRAINDICATIONS: Not for use in the eyes or in the external ear canal if the eardrum is perforated. This product is contraindicated in those individuals who have shown hypersensitivity to any of its components.

WARNING: Because of the potential hazard of nephrotoxicity and ototoxicity due to neomycin, care should be exercised when using this product in treating extensive burns, trophic ulceration and other extensive conditions where absorption of neomycin is possible. In burns where more than 20 percent of the body surface is affected, especially if the patient has impaired renal function or is receiving other aminoglycoside antibiotics concurrently, not more than one application a day is recommended.

When using neomycin-containing products to control secondary infection in the chronic dermatoses, such as chronic otitis externa or stasis dermatitis, it should be borne in mind that the skin in these conditions is more liable than is normal skin to become sensitized to many substances, including neomycin. The manifestation of sensitization to neomycin is usually a low grade reddening with swelling, dry scaling and itching; it may be manifest simply as failure to heal. During long-term use of neomycin-containing products, periodic examination for such signs is advisable and the patient should be told to discontinue the product if they are observed. These symptoms regress quickly on withdrawing the medication. Neomycin-containing applications should be avoided for that patient thereafter.

PRECAUTIONS: As with other antibacterial preparations, prolonged use may result in overgrowth of nonsusceptible organisms, including fungi. Appropriate measures should be taken if this occurs.

ADVERSE REACTIONS: Neomycin is a not uncommon cutaneous sensitizer. Articles in the current literature indicate an increase in the prevalence of persons allergic to neomycin. Ototoxicity and nephrotoxicity have been reported (see Warning section).

HOW SUPPLIED: Tube of 15 g.

Complete literature available on request from Professional Services Dept. PML.

CONTENTS—Continued

Hereditary Congenital Hypopigmented and Hyperpigmented Macules
Wiete Westerhof, MD; Frits A. Beemer, MD; Rudi H. Cormane, MD; Jan W. Delleman, MD; William R. Faber, MD; Joop G. Y. de Jong, MD; Wouter W. van der Schaar, PhD, Amsterdam 931

Acrodermatitis and Acquired Zinc Deficiency
Richard I. Ecker, MD, Arnold L. Schroeter, MD, Rochester, Minn 937

Monosymptomatic Hypochondriacal Psychosis Manifesting as Delusions of Parasitosis
Alistair Munro, MD, Toronto 940

Giant Cell Tumor of the Tendon Sheath Involving Skin
Donald T. King, MD; Arlen J. Millman, MD; Arnold W. Gurevitch, MD; Frank M. Hirose, MD, Torrance, Calif 944

Dapsone-Induced Jaundice
Stephen P. Stone, MD, Robert M. Goodwin, MD, Springfield, Ill 947

SELECTED REVIEW OF THE LITERATURE

Edited by Philip M. Catalano, MD, Miami
Mucocutaneous Lymph Node Syndrome (Kawasaki's Disease)
Guinter Kahn, MD, Miami 948

REGULAR DEPARTMENTS

Short Reports 953

Glaucoma Induced by Application of Corticosteroids to the Periorbital Region Niels V. Nielsen, MD, Per N. Sørensen, MD, Nykøbing Falster, Denmark . . . **Aggressive Chondroid Syringoma** Jan B. C. Botha, MB, ChB, MMed (Anat Path), FF Path (SA), Leonard B. Kahn, MB, BCh, MMed (Path), MRC Path, Cape Town, South Africa . . . **Recurrent Aphthous Stomatitis** Susanne Ullman, MD, Robert J. Gorlin, DDS, Minneapolis . . . **Usual Scabies With Nail Infestation** Takao Saruta, MD, Yoshio Nakamizo, MD, Beppu, Japan . . . **Idiopathic Calcinosis of the Scrotum** Benjamin K. Fisher, MD, Israel Dvoretzky, MD, Tel-Hashomer, Israel

Letters to the Editor 961

Dermatologists for the Nation: Perspectives Edmund D. Lowney, MD, Columbus, Ohio . . . **Diagnosis and Prognosis of New World Leishmaniasis** Pamela L. Moriearty, PhD, Candido Pereira, MD, Salvador, Brazil . . . **Treatment of Hallopeau's Acrodermatitis With Triamcinolone Acetonide** Harry L. Arnold, Jr, MD, Honolulu . . . **Woronoff's Ring in Goeckerman Treatment of Psoriasis** Roy S. Rogers III, MD, Rochester, Minn . . . **Fixed Drug Eruption Owing to Sulfamethoxazole** Julian Verbov, MD, MRCP, Liverpool, England . . . **Congenital Pigment Formation** André Dupré, PhD, Toulouse, France, Grange S. Coffin, MD, Berkeley, Calif . . . **Coexistence of Malignancies With Bullous Pemphigoid** T. P. Chorzelski, MD; S. Jablonska, MD; E. Maciejowska, MD, Warsaw; Ernst H. Beutner, PhD, Buffalo, NY; L. Wronkowski, Warsaw . . . **Lichen Striatus With Nail Dystrophy** Mark Meyers, MD; William Storino, MD; Sidney Barsky, MD, Chicago . . . **Red Poster Paint Tattoo Granuloma** Henning Schmidt, MD, H. E. Christensen, MD, Odense, Denmark . . . ***Mycobacterium marinum* Infections** Francis D. Pien, MD, Honolulu . . . **Treatment of Psoriasis With Dialysis** Phillip C. Anderson, MD, Columbia, Mo . . . **The Lady and the Flea** Leon Goldman, MD, Betty Stix, Cincinnati . . . **Peculiar Pruritus** Morris Waisman, MD, Tampa, Fla, Ira Leo Schamberg, MD, Elkins Park, Pa . . . **Balance Beam Alopecia** P. Haines Ely, MD, Roseville, Calif

News and Notes 971

Society Transactions 975

Index to Advertisers 972

Instructions for Authors 824

IMPROVED

SELSUN® ℞

(SELENIUM SULFIDE LOTION, U.S.P.)

- **Nicer fragrance**
- **Lighter color**
- **Richer sudsing**
- **Same efficacy and safety**

as the formula proved in millions of cases for over a quarter century

BRIEF SUMMARY

Contains: Selenium sulfide, 2½%, w/v; bentonite; lauric diethanolamide; ethylene glycol monostearate; titanium dioxide; amphoteric—2; sodium lauryl sulfate; sodium phosphate (monobasic); glyceryl monoricinoleate; citric acid; captan; perfume; and water.

Indications: For the treatment of dandruff and seborrheic dermatitis of the scalp.

Contraindications: Should not be used by patients allergic to any of its components.

Warnings: Safety for use on infants has not been established.

Precautions: Cutaneous sensitization of the scalp or adjacent areas has been reported; if sensitivity reactions should occur, discontinue use. Chemical conjunctivitis may result if product enters the eyes. Do not use when acute inflammation or exudation is present as an increase in absorption may occur.

Adverse Reactions: As with other shampoos, oiliness or dryness of the hair and scalp may occur following use; there have been occasional reports of an increase in the amount of normal hair loss. Hair discoloration may occur; can be avoided or minimized by thorough rinsing.

8033233



IMPROVED

Selsun®... the sweet smell of success.

(SELENIUM SULFIDE LOTION, U.S.P.) ℞



- Nicer fragrance
- Lighter color
- Richer sudsing
- Same efficacy and safety

ABBOTT

Please see opposite page for Brief Summary.

Archives of Dermatology

James H. Sammons, MD
Executive Vice-President

Thomas F. Hannon
Group Vice-President,
Publishing Operations

William R. Barclay, MD
Group Vice-President,
Scientific Publications

Norman D. Richey
Director, Publication
Production Division

John T. Baker
Director, Marketing Division

Helen R. Mazur
Director, Circulation-Fulfillment

John T. Baker, General Sales Manager; **Robert Corcoran,** Eastern Sales Manager; **Fred Bauman, Richard M. Johnson,** Eastern Sales Representatives; **Alice Harvey, William J. Healy,** Midwest Sales Representatives; **Thomas J. Carroll,** West Coast/Northern Sales Representative

PUBLICATION STAFF

Offices: 535 N Dearborn St
Chicago, IL 60610

Robert W. Mayo
Executive Editor and Director,
Scientific Publications Division

Sandra Williamson
Administrative Assistant

Marlene M. Hinsch, Production Manager

Diana A. Morgan, Editorial Processing Manager

Copy Editing: Rosanne Schulenberg (Supervisor), Kathy Swartz, Elizabeth Warden

Proofreading: Lorraine L. Kruse (Supervisor), Verna Coffman, Patricia Coyne, Elizabeth Petrikenas, Mary Kay Tinerella, Dorothy Troy, Patricia Zawadski

Production Supervisors: Julia Bero (Layout), Thomas J. Handrigan (Illustrations), Marlene M. Hinsch (Editorial), James P. Bagniewski (Advertising)

Art and Senior Production Assistants: Betty Frigerio, Floriana Hayes, Shirley Latronica, Donna Pender, Nancy Keyes, Marilyn Moroney, Susan Routhier, JoAnne Weiskopf

Production Assistants: Karen Branham, E. Linda Eisenberg, Anna Goins, Lucille Kuznicki

Manuscript Records: Denise Henderson

Indexing: Phyllis H. O'Donnell (Supervisor), Jane P. Mauldin, Helen F. Topel

Please address communications concerning accepted or published communications to: AMA Specialty Journals, 535 N Dearborn St, Chicago, IL 60610.

Conditions for Acceptance of Color Illustrations

Illustrations in full color are accepted for publication in ARCHIVES OF DERMATOLOGY if the editor believes that color will add significantly to the published manuscript.

When color illustrations are accepted, the American Medical Association will pay part of the expense of reproduction and printing, the remainder to be borne by the author or the institution with which he is affiliated. After deducting AMA's contribution, the author's share is $275 for up to six square finished illustrations. Additional illustrations and special effects, such as outlining, opaquing, or surprinting, will be billed to the author at cost.

Color transparencies must be submitted for evaluation. Do not send color prints unless accompanied by original transparencies. If transparencies are mounted in frames or glass, the material should be carefully packed in gauze and sent with the manuscript in a separate container or between two pieces of pressboard.

Advertising and Subscription Information

ADVERTISING OFFICES: 535 N Dearborn St, Chicago, IL 60610, Area Code 312, 751-6000; and 600 Third Ave, New York, NY 10016, Area Code 212-867-6640.

ADVERTISING PRINCIPLES: Each advertisement in this issue has been reviewed and complies with the principles governing advertising in AMA scientific publications. A copy of these principles is available on request.

CHANGE OF ADDRESS: Please notify the publisher at least six weeks in advance, including both old and new address, and a mailing label taken from the most recent copy. Include your new zip code number.

AVEENO®
Colloidal Oatmeal
bath for sensitive skin

When you treat inflammatory diseases, such as wet dermatitis (including allergic, atopic and contact), intertrigo or wet pruritus, a colloidal oatmeal bath may prove valuable, adjunctive therapy.

Soak Away The Discomfort With AVEENO COLLOIDAL OATMEAL.

- **Cleans naturally**—a soap-free way to absorb dirt and excess oil.
- **Comforts gently**—soothingly soaks hard-to-reach and widespread problem areas.
- **Long-lasting protection**—colloidal oatmeal film continues to protect after bathing.
- **Helps restore normal skin pH.**

Available in 1 lb. and 4 lbs. boxes.

Cooper Laboratories, Inc., Wayne, N.J. 07470 Cooper

Atopic dermatitis o
hand and wrist
36 year old male

Added versatility in dermatology

Lidex®-E

(fluocinonide) 0.05%

The established potency of fluocinonide, in a soothing emollient base.

Less drying than a cream, with the lubricating qualities of an ointment–cosmetically acceptable to patients.

Especially useful wherever a soothing topical steroid is indicated, as in atopic dermatitis.

Available in 15g and 60g tubes.

SYNTEX

Please see following page for summary of prescribing information

Lide® E
(fluocinonide) Cream 0.05%

Prescribing Information

Description LIDEX-E cream 0.05% contains the active compound fluocinonide. Fluocinonide, which is the 21-acetate ester of fluocinolone acetonide, has the chemical formula 6α, 9-difluoro-11β, 16α, 17, 21-tetrahydroxypregna-1, 4-diene-3, 20-dione, cyclic 16, 17-acetal with acetone, 21-acetate.

The cream contains fluocinonide 0.5 mg./g. in a water-washable aqueous emollient base of stearyl alcohol, cetyl alcohol, mineral oil, propylene glycol, sorbitan monostearate, polysorbate 60, citric acid and purified water.

Actions Topical steroids are primarily effective because of their anti-inflammatory, antipruritic and vasoconstrictive actions.

Indications For relief of the inflammatory manifestations of corticosteroid-responsive dermatoses.

Contraindications Topical steroids are contraindicated in vaccinia and varicella.

Topical steroids are contraindicated in those patients with a history of hypersensitivity to any of the components of the preparation.

Precautions If irritation develops, the cream should be discontinued and appropriate therapy instituted.

In the presence of an infection, the use of an appropriate antifungal or antibacterial agent should be instituted. If a favorable response does not occur promptly, the corticosteroid cream should be discontinued until the infection has been adequately controlled.

If extensive areas are treated, the possibility exists of increased systemic absorption and suitable precautions should be taken.

Although topical steroids have not been reported to have an adverse effect on pregnancy, the safety of their use in pregnant females has not absolutely been established. Therefore, they should not be used extensively on pregnant patients, in large amounts or for prolonged periods of time.

This product is not for ophthalmic use.

Adverse reactions The following local adverse reactions have been reported with topical corticosteroids: burning sensations, itching, irritation, dryness, secondary infection, folliculitis, acneform eruptions, hypopigmentation, striae, skin atrophy.

Dosage and Administration A small amount should be gently massaged into the affected area three or four times daily, as needed.

How Supplied LIDEX®-E (fluocinonide) cream 0.05% — 15g. and 60g. tubes.

SYNTEX
SYNTEX LABORATORIES, INC.
PALO ALTO, CALIFORNIA 94304



A safe, economical method of permanent hair removal— from face, legs, body

To save valuable office time, you can confidently recommend Perma Tweez to your patients for their home use.

- Battery-operated instrument self-sterilizes when current flows.
- Patented self-correcting needle.
- No-puncture safety feature helps prevent infection.
- Proved clinically safe (report on request).

FOR PHYSICIAN ORDERING

GENERAL MEDICAL CO., Dept D-98
1935 Armacost Ave.
West Los Angeles, CA 90025
30 DAY FREE TRIAL EXAMINATION.
(May be returned with no obligation.)

☐ PERMA TWEEZ $19.95
☐ ATTACHMENT $3.00
(for treating others)
☐ INVOICE AFTER 30 DAYS
☐ CHECK ENCLOSED

DR_____

STREET_____

C/S_____ ZIP_____

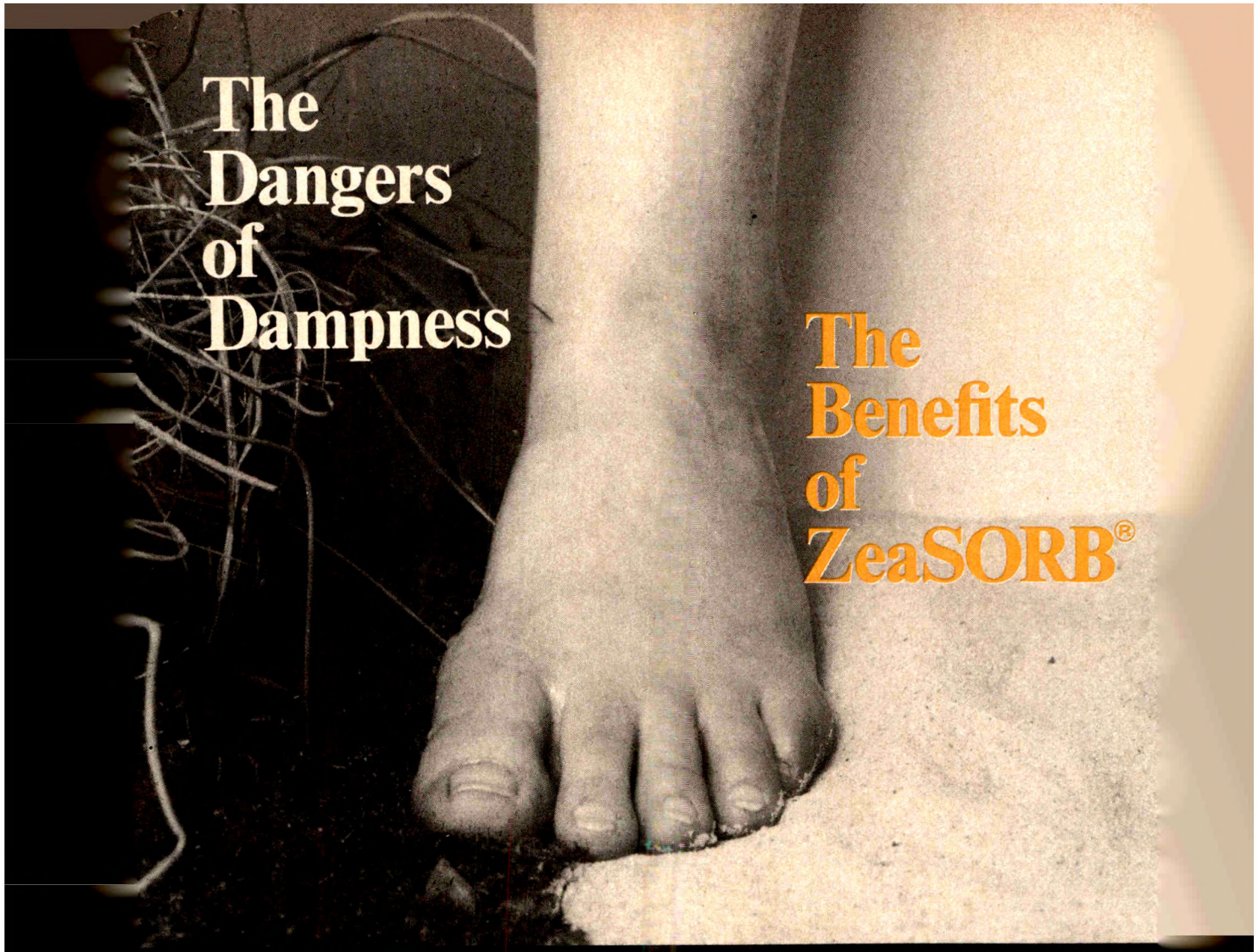

In the moist environment of hyperhidrosis, pathogenic fungi and bacteria can proliferate, causing malodor and infection. This wetness can also cause excessive maceration.

A dry climate is an excellent way to prevent fungus infections, hyperhidrosis, excessive maceration and intertrigo. For the patient prone to these problems, the prophylactic use of ZeaSORB keeps the skin dry and helps inhibit the proliferation of pathogenic fungi and bacteria.

ZeaSORB's unique formulation absorbs 2.6 times its weight in moisture...25% to 100% more absorbent than five leading powders.[1]

ZeaSORB is far more absorbent than simple talc and unlike cornstarch will not support fungal or bacterial growth. Used alone prophylactically or in conjunction with specific antifungal agents, ZeaSORB is a therapeutically sound way to keep patients' skin dry and comfortable . . . to create a hostile environment for microorganisms . . . to help treat and prevent the dangers of dampness.

[1]Data on file at Stiefel Research Institute

ZeaSORB®

Super Absorbent Powder

Active ingredients: microporous cellulose 45%*, p-chloro-m-xylenol 0.5%, aluminum dihydroxy allantoinate 0.2%.
Contains no starch or boric acid.
How Supplied: 2 oz. sifter top plastic cans and 8 oz. sifter containers.

STIEFEL
Logical Dermatologicals

Stiefel Laboratories, Inc.
2801 Ponce de Leon Blvd.
Coral Gables, Fla. 33134

*Stiefel's brand of a patented ultra-absorptive cellulose derivative. U.S. Pat. Nos. 2890151, 3278383.

2-1434A

Instructions for Authors

Send manuscripts by first-class mail to the Chief Editor, John H. Epstein, MD, 450 Sutter St, San Francisco, CA 94108. Manuscripts are received with the understanding that they are not under simultaneous consideration by another publication. Accepted manuscripts become the permanent property of the ARCHIVES and may not be published elsewhere without permission from the publisher (AMA).

In addition, in view of *The Copyright Revision Act of 1976*, effective Jan 1, 1978, transmittal letters to the editor should contain the following language: "In consideration of the American Medical Association taking action in reviewing and editing my submission, the author(s) undersigned hereby transfers, assigns, or otherwise conveys all copyright ownership to the AMA in the event that such work is published by the AMA." We regret that transmittal letters not containing the foregoing language signed by all authors of the submission will necessitate delay in review of the manuscript.

Author Responsibility.—All accepted manuscripts are subject to copy editing. The author will receive an edited typescript rather than galley proofs for approval. The author is responsible for all statements in his work, including changes made by the copy editor.

Designate one author as correspondent and provide his address and telephone number. Order reprints at the time the typescript is returned after editorial processing. Specify address to which requests for reprints should be sent.

Manuscript Preparation.—Submit an original typescript and two high-quality copies of the entire manuscript. All copy (including references, legends, and tables) must be typed double-spaced on 22 × 28-cm (8½ × 11-inch), heavy-duty white bond paper. Ample margins should be provided.

Refer to patients by number (or, in anecdotal reports, by fictitious given names). Real names or initials should not be used in the text, tables, or illustrations.

Titles.—Titles should be short, specific, and clear. They should not exceed 42 characters per line, including punctuation and spaces, and be limited to two lines, if possible. The title page should include the full names and academic affiliations of all authors, the address to which requests for reprints should be sent, and, if the manuscript was presented at a meeting, the name of the organization, place, and date on which it was read.

Style of Writing.—The style of writing should conform to acceptable English usage and syntax. Slang, medical jargon, obscure abbreviations, and abbreviated phrasing are to be avoided.

Informed Consent.—Manuscripts reporting the results of experimental investigations of human subjects must include a statement to the effect that informed consent was obtained after the nature of the procedure(s) had been fully explained.

Abstract.—Provide an abstract (135-word maximum) of the article, including statements of the problem, method of study, results, and conclusions. The abstract replaces the summary.

References.—List references in consecutive numerical order (not alphabetically). Once a reference is cited, all subsequent citations should be to the original number. All references must be cited in the text or tables. Unpublished data and personal communications should not be listed as references. References to journal articles should include (1) author(s), (2) title, (3) journal name (as abbreviated in *Index Medicus*), (4) volume number, (5) inclusive page numbers, and (6) year, in that order. References to books should include (1) author(s), (2) chapter title (if any), (3) editor (if any), (4) title of book, (5) city of publication, (6) publisher, and (7) year. Volume and edition numbers, specific pages, and name of translator should be included when appropriate. The author is responsible for the accuracy and completeness of the references and for their correct text citation.

Metrication.—All measurements must be in metric units. English units may also be given parenthetically if the measurements were originally done in English units.

Illustrations.—Use only those illustrations that clarify and augment the text. Submit illustrations in duplicate, unmounted and untrimmed. Do not send original artwork. Send high-contrast glossy prints (not photocopies). Figure number, name of senior author, and arrow indicating "top" should be typed on a gummed label and affixed to the back of each illustration. All lettering must be legible after reduction to column size. Artwork submitted for publication may be relettered to achieve uniformity of lettering style throughout the journal. Magnification and stain should be provided when pertinent. Illustrations should preferably be in a proportion of 12.5 × 18 cm (5 × 7 inches).

An experienced medical illustrator should be employed whenever possible for the preparation of all artwork. Template lettering or preset type is preferred to hand-lettered labels. If halftone artwork with labels is submitted, affix type and leaders to a clear acetate overlay registered to the base drawing. Labels and leaders should be applied directly to the drawing board surface if the artwork consists only of line ink technique.

Illustrations in full color are accepted for publication if the editors believe that color will add significantly to the published manuscript. The ARCHIVES will pay part of the expense of reproduction and printing color illustrations, the remainder to be borne by the author or his sponsor. After deducting the ARCHIVES contribution, the author's share is $275.00 for up to six square-finished illustrations that can be arranged on a one-page layout. Any additional illustrations or special effects will be billed to the author at cost. Positive color transparencies (35 mm preferred) must be submitted for an evaluation. Do not send color prints unless accompanied by original transparencies. All transparencies should be carefully packed and sent with the manuscript.

Legends.—Legends should be typed double-spaced, beginning on a separate sheet of paper. Length should be limited to a maximum of 40 words.

Photographic Consents.—A letter of consent must accompany all photographs of patients in which a possibility of identification exists. It is not sufficient to cover the eyes to mask identity.

Acknowledgments.—Illustrations from other publications must be acknowledged. Include the following when applicable: author(s), title of article, title of journal or book, volume number, page(s), month, and year. The publisher's permission to reprint should be submitted to the ARCHIVES after the manuscript has been formally accepted.

Statistical Review.—Manuscripts containing statistical evaluations should include the name and affiliation of the statistical reviewer.

Tables.—Each table should be typed double-spaced, including all headings, on a separate sheet of 22 × 28-cm (8½ × 11-inch) paper. Do not use larger size paper. If a table must be continued, use a second sheet and repeat all heads and stubs. Each table must have a title.

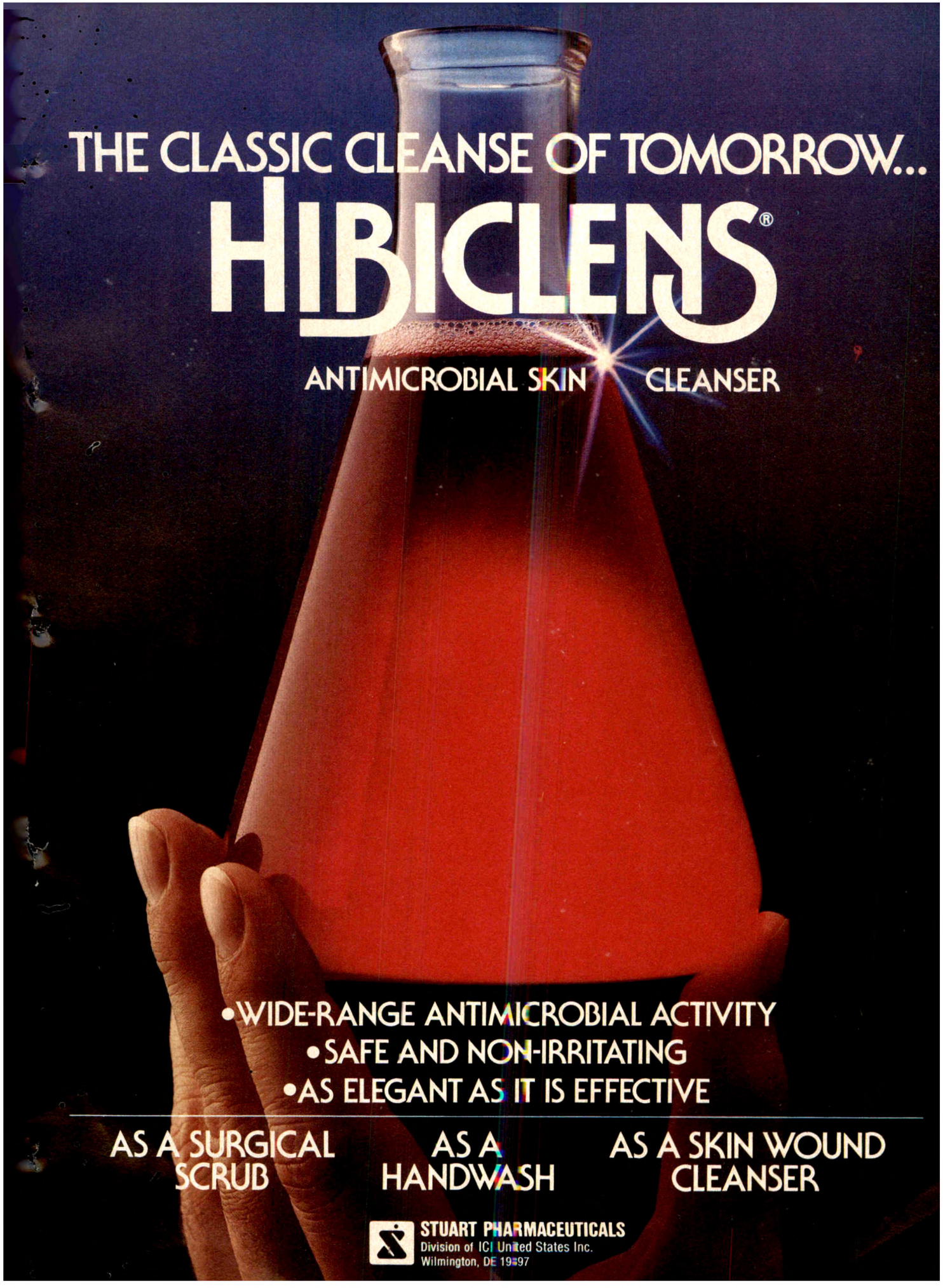
THE CLASSIC CLEANSE OF TOMORROW...
HIBICLENS®
ANTIMICROBIAL SKIN CLEANSER
•WIDE-RANGE ANTIMICROBIAL ACTIVITY
•SAFE AND NON-IRRITATING
•AS ELEGANT AS IT IS EFFECTIVE
AS A SURGICAL SCRUB
AS A HANDWASH
AS A SKIN WOUND CLEANSER
STUART PHARMACEUTICALS
Division of ICI United States Inc.
Wilmington, DE 19897

Whenever epidermabrasion is needed...

Many skin conditions can benefit from epidermabrasion—the controlled removal of the stratum disjunctum and other keratin excrescences of the stratum corneum. BUF-PUF offers a pleasant, easy-to-use method for patients to achieve thorough cleansing and smoother, healthier skin from head to toe.

Acne
BUF-PUF loosens comedones while it cleans and helps remove excess oil.

Psoriasis
Used wet or dry, BUF-PUF debrides scales from psoriatic lesions without manifesting a Koebner reaction.

Hyperkeratosis
Rapid, often dramatic results can be seen when BUF-PUF is used to remove the upper layers of toughened or scaly skin.

Keratosis pilaris
BUF-PUF is particularly helpful here because its abrasive action concentrates on the elevated areas of the skin surface.

Tinea versicolor
The gently abrasive action of BUF-PUF helps remove the scales, allowing better penetration of topical therapeutic agents.

BUF-PUF®
Nonmedicated Cleansing Sponge

Riker Laboratories, Inc. SUBSIDIARY OF 3M COMPANY
NORTHRIDGE, CALIFORNIA 91324

© 1978, Riker Laboratories, Inc.

When cleanliness requires more than soap— in the hospital, office or home

BETADINE® Skin Cleanser

Degerms as it cleanses

☐ **For routine handwashing**—for physicians and nurses in the hospital and office—hospital personnel and patients—for those caring for infants and the sick at home.

☐ **For skin degerming**—in patients with common pathogens, including *Staph. aureus*—postoperative skin care in the hospital and home—in skin infections—for general hygiene, when skin degerming is indicated.

☐ **In infected acne pimples**—when it is important to prevent autoinoculation of new sites.

☐ **To degerm face, hands and body with prompt, broad-spectrum microbicidal action**—BETADINE Skin Cleanser cleanses thoroughly and gently with a rich golden lather—virtually nonirritating* to skin and mucosa—nonstaining to skin and natural fabrics.

Supplied in 4 fl. oz. plastic bottles.

*In the rare instance of local irritation or sensitivity, discontinue use by the individual.

Purdue Frederick

© Copyright 1978, The Purdue Frederick Company/Norwalk, CT 06856

A9035 102078

PREDICTION:

There will be 3 Eclipses in 1978.

INTRODUCING NEW ECLIPSE® GEL:

Non-comedogenic, it provides superior protection from sun damage for your patients with acne or oily skin.

INTRODUCING NEW ECLIPSE® LIP AND FACE PROTECTANT:

Convenient stick form moisturizes while it protects against burning, chapping and drying effects of sun, wind and cold.

ORIGINAL ECLIPSE® LOTION:

Combines the superior efficacy of two PABA esters with the moisturizing Aquacare® base to protect your patients with dry to normal skin.

THE ECLIPSE® FAMILY OF SUNSCREENS:

- Provide maximum skin protection. Absorb more than 99% of burning rays.
- Lotion and Gel contain 6% PABA esters... superior to 5% PABA formulations.
- Continue to protect after swimming with superior wash-off resistance.
- Do not develop unsightly and uncomfortable peeling of formulation.
- Protect immediately upon application. Patient does not have to wait before exposure.
- Are formulated to protect every patient skin type in every type of weather.

Herbett Laboratories, Dermatology Division of Allergan Pharmaceuticals, Inc., Irvine, CA 92713, U.S.A.

"Caffeinectomy"

the procedure that benefits millions

Remove 97% of the caffein from 100% pure coffee, and you've got Sanka® Brand Decaffeinated Coffee—the ideal coffee for so many of your patients. Sanka® Brand contains only 3-5 mg of caffein per 6-oz cup (compared to about 50-100 mg in an equivalent cup of regular coffee).

Cardiac patients and hypertensives... insomniacs and anxious patients... patients with caffein-aggravated symptoms of a dermatologic condition...or the housewife overstimulated [illegible] they're just some of the patients who may benefit from your recommendation of Sanka® Brand Decaffeinated Coffee. Sanka® Brand Decaffeinated Coffee is available in food stores everywhere...in instant, freeze-dried and ground-roast forms. And at restaurants, in convenient single-service packages.

Sanka® BRAND

97% CAFFEIN-FREE COFFEE

GF GENERAL FOODS

Recommended by more physicians than all other brands of coffee combined

anywhere on potency without fluorination

The potency of Tridesilon—*nonfluorinated* antiinflammatory topical corticoid—has again been confirmed. In a recently published clinical study,[1] desonide 0.05% was compared with fluocinonide (in identical concentration) for various dermatologic disorders including contact dermatitis, nummular eczema, lichen simplex chronicus, seborrheic dermatitis, and atopic eczema.

The desonide group showed better improvement scores in erythema and scaling after the first week; the two-week scores were not significantly different. "...desonide demonstrated potency and efficacy equivalent to those of the fluorinated compound in the disorders treated, and no adverse effects were noted with the former."[1]

This is added corroboration that with topical steroids potency and efficacy do not always depend on fluorination. Desonide, though nonfluorinated, has shown clinical comparability with the most widely prescribed fluorinated topical steroids.[2]

*Not for ophthalmic use.

References: 1. Barsky S: Clinical comparison of desonide cream with fluocinonide cream in steroid-responsive dermatologic disorders. *Cutis* 18:826, 1976. **2.** Reprints available on request.

Contraindications: Tridesilon (desonide) 0.05% Creme and Ointment, topical steroids, are contraindicated in vaccinia and varicella, and in those patients with a history of hypersensitivity to any of the components of the preparation.
Precautions: If irritation develops, the drug should be discontinued and appropriate therapy instituted.
In the presence of an infection, the use of an appropriate antifungal or antibacterial agent should be instituted. If a favorable response does not occur promptly, the corticosteroid should be discontinued until the infection has been adequately controlled.
If extensive areas are treated or if the occlusive technique is used, the possibility exists of increased systemic absorption of the corticosteroid and suitable precautions should be taken.
Although topical steroids have not been reported to have an adverse effect on pregnancy, the safety of their uses in pregnant females has not absolutely been established. Therefore, they should not be used extensively on pregnant patients, in large amounts, or for prolonged periods of time.
These products are not for ophthalmic use.
Adverse Reactions: The following local adverse reactions have been reported with topical corticosteroids: burning sensations, itching, irritation, dryness, folliculitis, hypertrichosis, acneform eruptions, hypopigmentation.
The following may occur more frequently with occlusive dressings than without such therapy: maceration of the skin, secondary infection, skin atrophy, striae, miliaria.
Dosage and Administration: Apply a thin film of Tridesilon (desonide) to the affected skin and massage lightly. The usual dosage is two or three times daily.
Depot Stocked: *DPSC:* 15 gm: NSN 6505-00-148-6969; 60 gm: NSN 6505-00-148-6968; 5 lb: NSN 6505-01-004-9217. *VA:* 30 gm: SN 6505-00-136266A; 5 lb: SN 6505-01-012-4486A.



Tridesilon®
(desonide) 0.05% creme and ointment

adjunctive therapy in acute and chronic steroid-responsive dermatoses

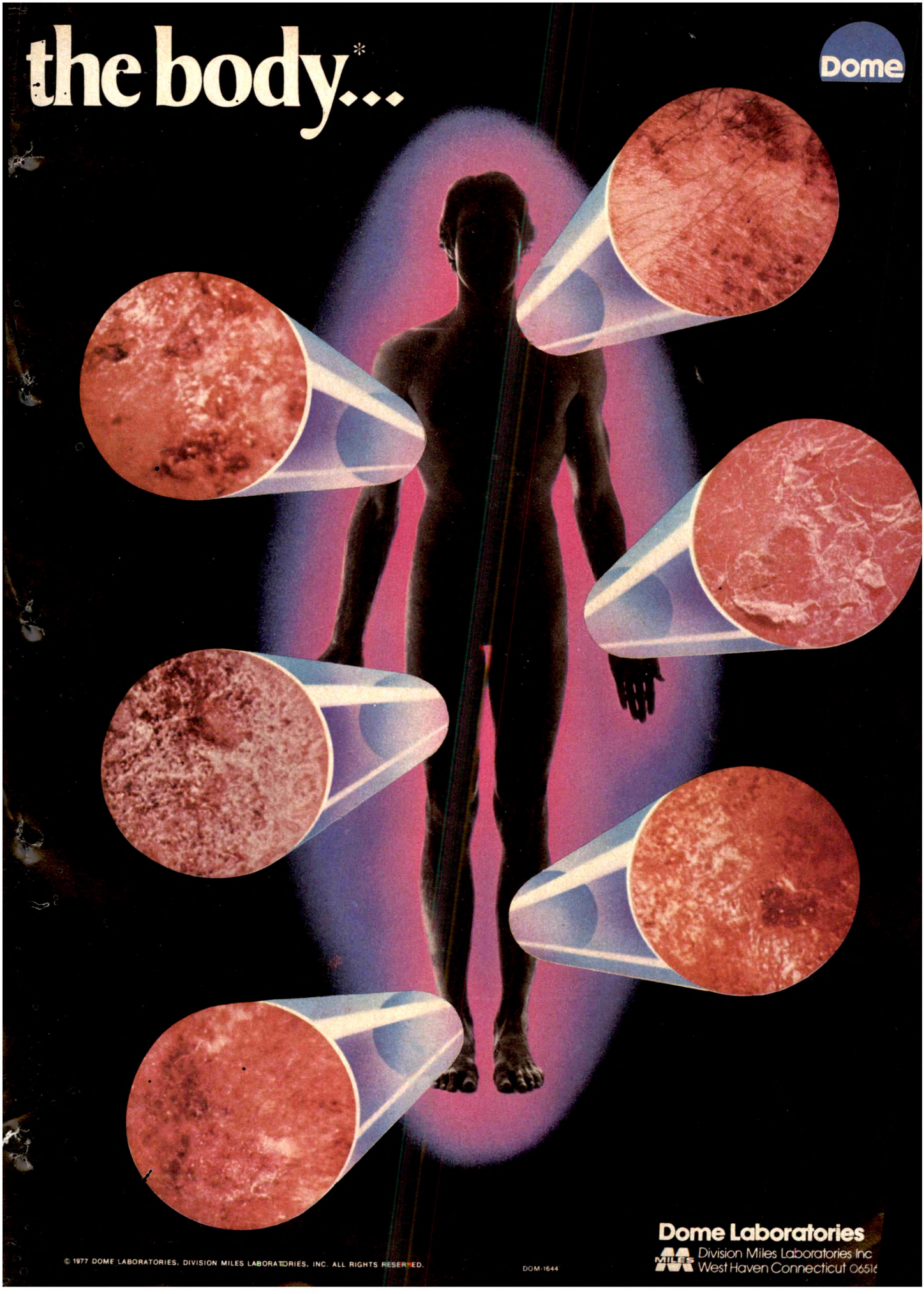
the body*...
Dome
Dome Laboratories
Division Miles Laboratories Inc
West Haven Connecticut 06516
© 1977 DOME LABORATORIES, DIVISION MILES LABORATORIES, INC. ALL RIGHTS RESERVED.
DOM-1644

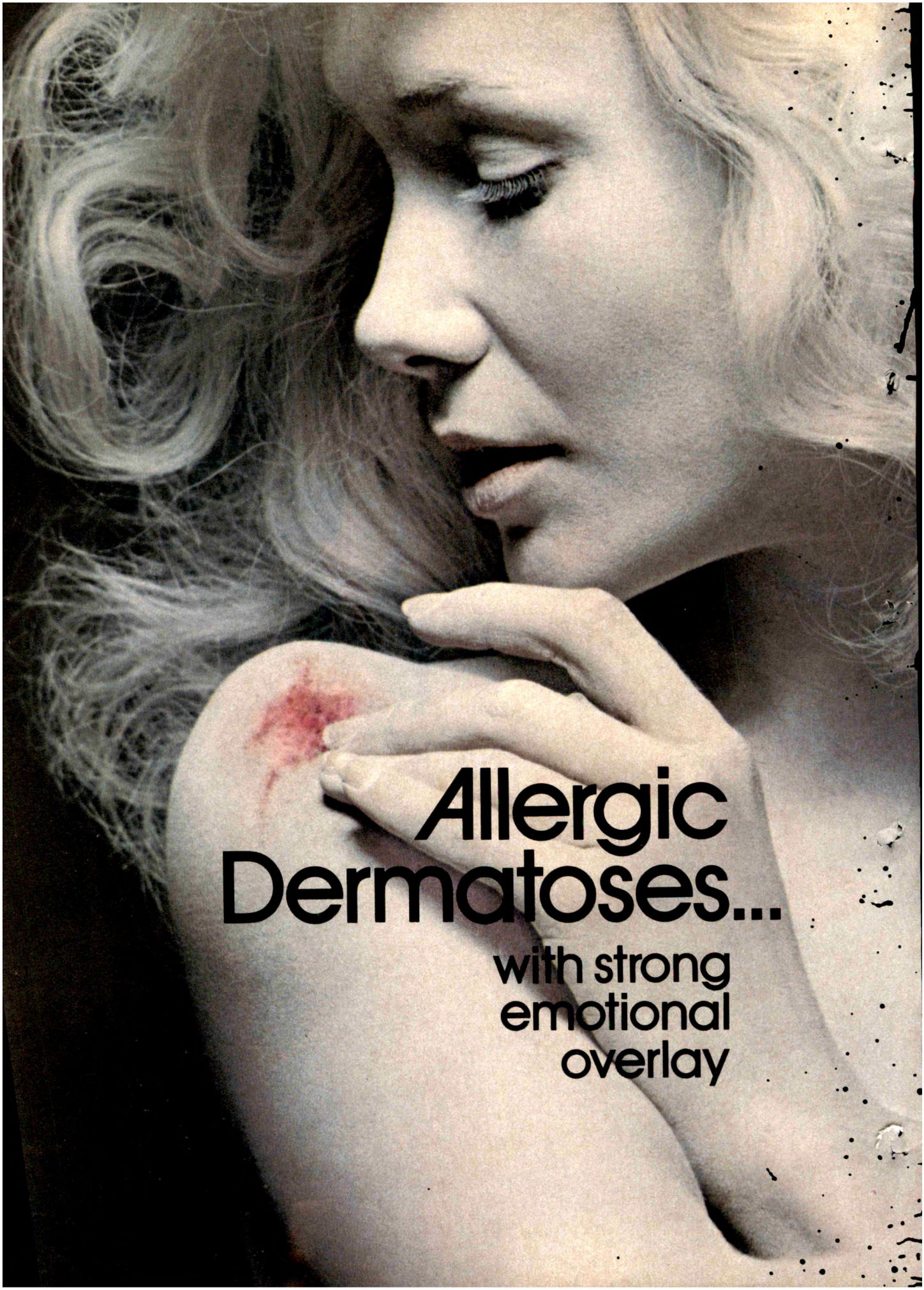
Allergic
Dermatoses...
with strong
emotional
overlay

Contraindications: Hypersensitivity to hydroxyzine. Hydroxyzine, when administered to the pregnant mouse, rat, and rabbit, induced fetal abnormalities in the rat at doses substantially above the human therapeutic range. Clinical data in human beings are inadequate to establish safety in early pregnancy. Until such data are available, hydroxyzine is contraindicated in early pregnancy.

Precautions: Hydroxyzine may potentiate the action of central nervous system depressants such as meperidine and barbiturates. In conjunctive use, dosage for these drugs should be reduced. Because drowsiness may occur, patients should be cautioned against driving a car or operating dangerous machinery.

Adverse Reactions: Drowsiness may occur; if so, it is usually transitory and may disappear in a few days of continued therapy or upon dosage reduction. Dryness of the mouth may occur with higher doses. Involuntary motor activity, including rare instances of tremor and convulsions, has been reported, usually with higher than recommended dosage.

Supply: Tablets, containing 10 mg hydroxyzine hydrochloride, 100's and 500's; Tablets, containing 25 mg or 50 mg, 100's, 500's, and Unit Dose (10 x 10's); Tablets, containing 100 mg, 100's and Unit Dose (10 x 10's); Syrup, containing 10 mg per teaspoonful (5 ml) and ethyl alcohol 0.5% v/v, pint bottles.

Before prescribing or administering, see package circular.

ROERIG Pfizer
A division of Pfizer Pharmaceuticals
New York, New York 10017

as adjunctive therapy

Atarax®
(hydroxyzine HCl)

TABLETS: 10 mg, 25 mg, 50 mg, and 100 mg SYRUP: 10 mg per 5 ml, ethyl alcohol 0.5% v/v

- rapid antianxiety action
- demonstrated antihistaminic/antipruritic activity

THE ONLY WAY TO END THE EPIDEMIC IS OVER HER DEAD BODY.

Kill the female itch mite (*sarcoptes scabiei*) and you've stopped the current scabies epidemic. Because when she burrows deep into the stratum corneum, she defies diagnosis and resists removal by surface-acting medications and cleansers. Her success has been making headlines around the country—with reports of scabies outbreaks in rural and suburban areas as well as in the cities.

A quick and simple diagnosis. Scabies can mimic a number of dermatological conditions,[1-3] such as urticaria, furunculosis and dermatitis—as well as syphilis with which it may coexist. But there's an almost foolproof way to recognize it. Even in the absence of the fierce nocturnal itching[3] and the lesion distribution characteristic of the disease (hands, wrists and elbows in 9 out of 10 cases),[1] a quick microscopic look can confirm your scabies diagnosis.

To demonstrate the itch mite, look for an unscratched, inhabited burrow (wherever the patient says he itches at that very moment is a likely spot). Use a strong light, a magnifying glass and a surgical blade to which a drop of mineral oil is added. Scrape several sites. Transfer the material to a slide, cover and examine under low power magnification.[1,3,4] (If you don't spot any parasites in egg, larvae or adult stages, look for their red fecal compactions. They can be just as diagnostic.)

Kwell: penetrating action to kill mites, their eggs and larvae. Once you've found scabies, there's a positive way to eradicate it. Kwell (1% gamma benzene hexachloride) Lotion or Cream. It penetrates to reach the scabietic burrows, kills the female mites and, of course, the less tenacious males, as well as their eggs and any larvae that may have hatched. In fact, Kwell works so consistently and well against scabies that it has been the most widely prescribed scabicide for three decades.

Nearly 100% effective. The clinical record of Kwell has never been surpassed by any other pediculicide. It is "nearly 100% effective,"[1] and often works with a single application (a second or third application may be made at weekly intervals, if needed). Your patients will appreciate the low risk of sensitization and irritation.[5,6] And you will appreciate that Kwell works so predictably that it serves to confirm your diagnosis of scabies. Not many pharmaceutical preparations can match *that* record of dependability.

Contraindications: Kwell is contraindicated in individuals who develop hypersensitivity to the product or to any of its components.

Precautions: If accidental ingestion occurs, prompt institution of gastric lavage will rid the body of large amounts of the toxicant. However, since oils favor absorption, saline cathartics for intestinal evacuation should be given rather than oil laxatives.

Central nervous system manifestations can be antagonized by the administration of pentobarbital or phenobarbital in sufficiently large doses to the limit of their therapeutic effectiveness. It is not desirable to depress the patient to the point of hypnosis. However, persons poisoned with stimulants may tolerate large doses of barbiturate without undue depression and with great benefit. Intravenous calcium gluconate may be used in conjunction with the barbiturates. Epinephrine should not be used because ventricular fibrillation may result.

If accidental contact with eyes occurs, flush with water. If irritation or sensitization occurs, discontinue the product and consult physician.

Adverse Reactions: Eczematous eruptions due to sensitization of this product have been reported.

Available on prescription as Kwell Lotion in 2 and 16 fl. oz. bottles, and as Kwell Cream in 2 oz. and 1 lb. jars. See package insert for complete prescribing information.

References: 1. *Patient Care* 7:94, Nov. 1, 1973. 2. Stankler, L.: *Practitioner* 210:803, June 1973. 3. Domonkos, A.N. (ed.): Andrews' Diseases of the Skin: Clinical Dermatology, ed. 6, Philadelphia, W. B. Saunders Company, 1971, pp. 511-513. 4. Muller, G., *et al*: *Arch. Dermatol.* 107:70, Jan. 1973. 5. James, B.H.E.: *Br. Med. J.* 1:178, Jan. 15, 1972. 6. Sollman, T.: A Manual of Pharmacology, ed. 8, Philadelphia, W. B. Saunders Company, 1957, p. 178.

SEM Courtesy of J. M. Rower, M.D., Columbus, Ohio.

Reed & Carnrick / Kenilworth, New Jersey 07033

UNIVERSITY COLLEGE OF MEDICINE LIBRARY

Cream/Lotion

KWELL® gamma benzene hexachloride

THE SCABICIDE OF CHOICE.

An unsurpassed standard of therapy

Superior to the most widely used brand of topical steroid in psoriasis and atopic dermatitis.

Based on the evidence.

In double-blind, parallel studies,* Topicort® (desoximetasone) Emollient Cream 0.25% demonstrated greater efficacy than betamethasone valerate cream 0.1% in the two most common corticosteroid-responsive dermatoses.

		NO. OF PATIENTS	Overall Evaluation: EXCELLENT & GOOD	Overall Evaluation: EXCELLENT (CLEARANCE OF DISEASE)
ATOPIC DERMATITIS	TOPICORT	39	100%	77%
	BETAMETHASONE VALERATE	41	90%	54%
PSORIASIS	TOPICORT	61	84%	43%
	BETAMETHASONE VALERATE	56	63%	21%

These recently conducted U.S. studies confirm the outstanding worldwide acceptance of Topicort in more than 30 countries for up to 4 years.

*Data on file and available upon request from Hoechst-Roussel Pharmaceuticals Inc., Somerville, New Jersey 08876.

Less than 1% incidence of side effects.
Of 488 patients in the clinical trials, side effects were seen in only 4 (0.8%).* And in 2 of the 4 patients, the relationship of side effects to the drug was uncertain.

The convenience of b.i.d. dosage. And the uniqueness of a preservative-free, emollient cream base.
The specially developed, preservative-free Topicort base combines the emollience of an ointment with the cosmetic acceptability of a cream in a water-in-oil emulsion. This makes Topicort (desoximetasone) especially useful in psoriatic and other dry, scaly dermatoses.

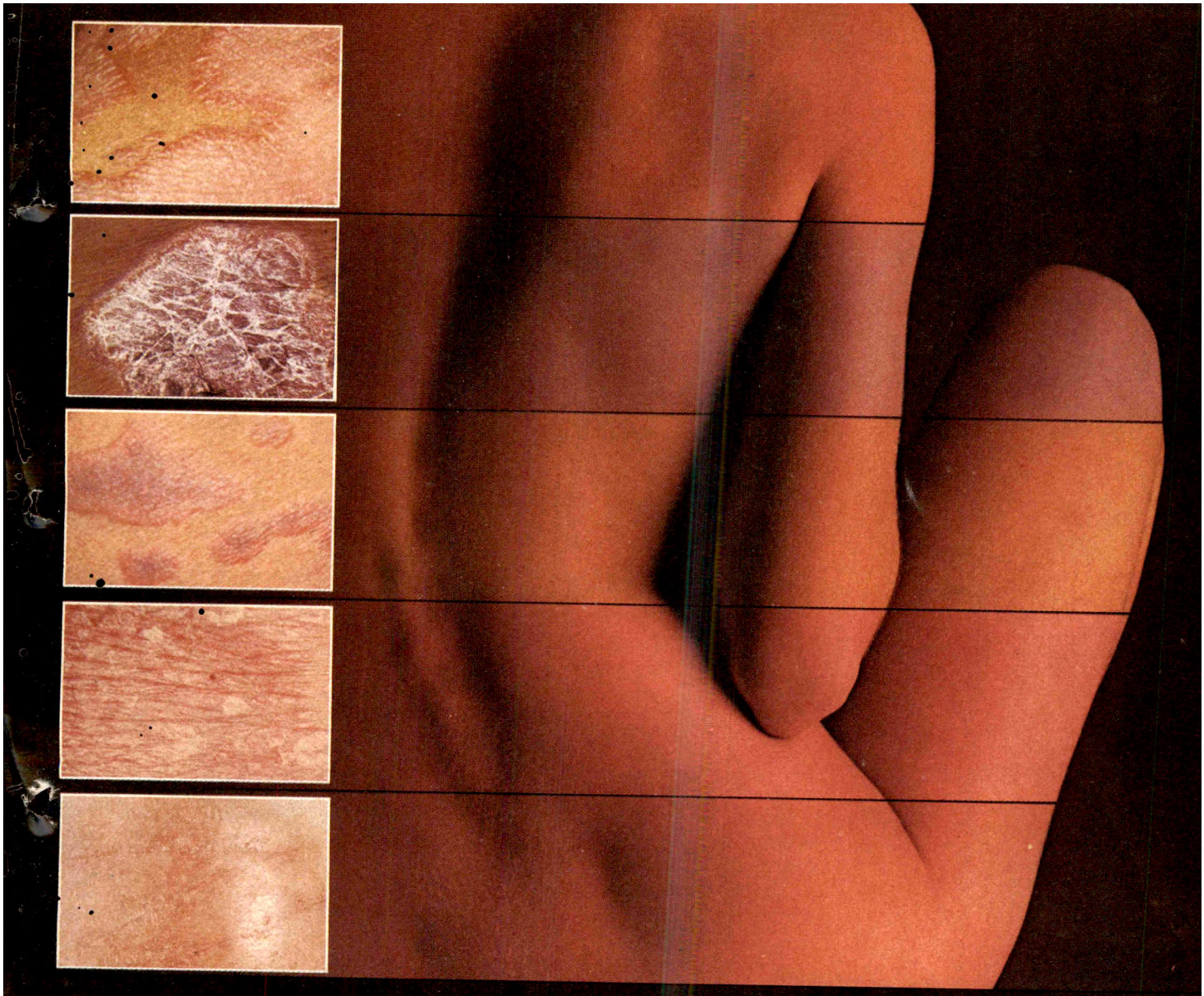

TOPICORT®
(DESOXIMETASONE)
EMOLLIENT CREAM 0.25%

An important innovation from the research laboratories of
Hoechst-Roussel Pharmaceuticals Inc.

Please consult full prescribing information on following page.

TOPICORT®(desoximetasone) EMOLLIENT CREAM 0.25%

Description: Topicort® (desoximetasone) Emollient Cream 0.25% contains the active synthetic corticosteroid desoximetasone. The chemical name of desoximetasone is 9α - fluoro - 11β, 21 - dihydroxy - 16α - methylpregna - 1,4 - diene-3,20-dione. The chemical structure is:

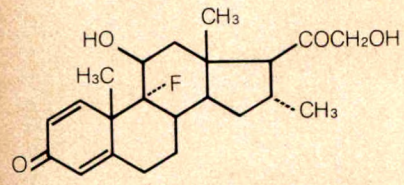

Each gram of Topicort® (desoximetasone) Emollient Cream 0.25% contains 2.5 mg desoximetasone in an emollient cream consisting of isopropyl myristate, cetylstearyl alcohol, white petrolatum, mineral oil, lanolin alcohol and purified water.

Actions: Topicort® (desoximetasone) Emollient Cream is primarily effective because of its anti-inflammatory, antipruritic and vasoconstrictive actions.

Indications: Topicort® (desoximetasone) Emollient Cream is indicated for the relief of inflammatory manifestations of corticosteroid-responsive dermatoses.

Contraindications: Topical steroids are contraindicated in vaccinia, varicella and in those patients with a history of hypersensitivity to any of the components of the preparation. This preparation is not for ophthalmic use.

Precautions: If local infection exists, suitable concomitant antimicrobial or antifungal therapy should be administered. If a favorable response does not occur promptly, application of the corticosteroid should be discontinued until the infection is adequately controlled.

Although systemic side effects associated with absorption of topical corticosteroid preparations are rare, their possible occurrence must be kept in mind when these preparations are used over large areas or for an extended period of time, or if occlusive technique is used.

If irritation or sensitization develops, the preparation should be discontinued and appropriate therapy instituted.

Although topical steroids have not been reported to have an adverse effect on pregnancy, the safety of their use during pregnancy has not been absolutely established; therefore, they should not be used extensively on pregnant patients, in large amounts, or for prolonged periods of time.

Adverse Reactions: The following local adverse reactions have been reported with topical corticosteroids: burning, itching, irritation, striae, skin atrophy, secondary infection, dryness, folliculitis, hypertrichosis, acneform eruptions and hypopigmentation. The following may occur more frequently with occlusive dressings: maceration of the skin, secondary infection, skin atrophy, striae, and miliaria.

Dosage and Administration: Apply a thin film of Topicort® (desoximetasone) Emollient Cream 0.25% to the affected skin areas twice daily. Rub in gently.

How Supplied: Topicort® (desoximetasone) Emollient Cream 0.25% is supplied in 15-gram tubes.

HOECHST-ROUSSEL
PHARMACEUTICALS INCORPORATED
SOMERVILLE, NEW JERSEY 08876

U.V. PHOTOTHERAPY RADIOMETER for PHOTOCHEMOTHERAPY of PSORIASIS

Features:
- Direct readout in milliwatts/cm².
- Spectral response to match the photosensitization of skin.
- Sensitivity from 0.3 to 100 milliwatts/cm², full scale.
- Wide field of view to match the cosine receiving function of human skin.
- Small, rugged and battery operated for full portability and safety.
- L.E.D. battery status indicator lamp.
- Silicon photodiode detector for maximum stability..

Write Dept. A

international light INC
Specialists in Light Measurement
DEXTER INDUSTRIAL GREEN
NEWBURYPORT, MA. 01950 617 465 5923

DISEASES DUE TO IMMUNE MECHANISMS

December 9-13, 1978
Diplomat Hotel and Country Club
Hollywood, Florida
Sponsored by the
Section on Allergy-Clinical Immunology
University of Pittsburgh School of Medicine
and the
Veterans Administration Hospital
Pittsburgh, Pennsylvania

A distinguished faculty will present recent advances in this field.

ADDRESS INQUIRIES TO: Leo H. Criep, M.D., Course Director, Allergy-Clinical Immunology, Veterans Administration Hospital, Pittsburgh, PA 15240. Telephone: 412/281-0355

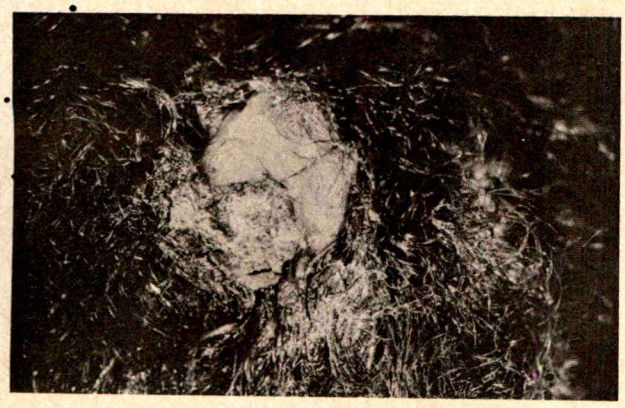

Saunders takes a closer look at dermatologic problems.

Kopf, Bart & Andrade
ATLAS OF TUMORS OF THE SKIN

This vivid atlas depicts all types of cutaneous tumors, both benign and malignant. In many cases, several variants of the same type of tumor are included. For instance, a variety of photographs of basal-cell carcinomas emphasize the variability of clinical morphology of this very common type of skin cancer.

For ease of reference, photographs are arranged alphabetically and designations are cross-referenced in the index.

The following information is provided for each lesion when available: sex, age at time of consultation, duration stated by patient, site of photographed lesion, and whether the diagnosis was histologically verified.

By **Alfred W. Kopf,** MD, Prof., Dept. of Dermatology, New York Univ. School of Medicine; Head, Oncology Section, Skin and Cancer Unit, Univ. Hospital, New York Univ. Medical Center; **Robert S. Bart,** MD, Assoc. Prof., Dept. of Dermatology, New York Univ. School of Medicine; Assoc. Head, Oncology Section, Skin and Cancer Unit, Univ. Hospital, New York Univ. Medical Center; and **Rafael Andrade,** MD, Prof. and Chairman, Dept. of Dermatology, LaSalle Medical Center, LaSalle Univ. of Mexico; Consultant in Dermatology and Chief, Section of Dermatology, Depts. of Dermatology and Pathology, General Hospital S.S.A. of Mexico City. About 335 pp., 910 ill. Many color. About $62.50
Ready July 1978. **Order #5487-8.**

Solomon, Esterly & Loeffel:
ADOLESCENT DERMATOLOGY—Major Problems in Clinical Pediatrics, 19

A wealth of practice applicable material is presented in this new monograph. Dealing with the tough, demanding skin problems of adolescents, the authors thoroughly examine everything from acne to hirsutism, from veneral disease to lupus erthyematosus and much more. Additional help is yours in the chapters on understanding the adolescent, and diagnostic procedures.

Edited by **Lawrence M. Solomon,** MD, Prof. and Head of Dermatology, College of Medicine, Abraham Lincoln School, Univ. of Illinois; **Nancy B. Esterly,** MD, Prof. of Pediatrics and Dermatology, Northwestern Univ. Medical School; and **E. Dorinda Loeffel,** MD, Asst. Prof. of Dermatology, College of Medicine, Abraham Lincoln School, Univ. of Illinois. About 495 pp., 175 ill. (including some color plates). About $20.00. Ready June 1978. **Order #8492-0.**

Korting, Curth & Curth
DISEASES OF THE SKIN IN CHILDREN AND ADOLESCENTS—3rd Edition

The new edition of this beautiful color atlas covers the entire range of common and uncommon skin problems in children and adolescents. All the important changes and recent developments in the field of pediatric dermatology are included.

By **G.W. Korting,** MD, Director, Dept. of Dermatology, Univ. Hospital, Mainz, Germany. Translated by **William Curth,** MD, and **Helen Ollendorff Curth,** MD. About 250 pp., 410 ill. (Mostly all in color). About $40.00. Ready Soon. **Order #5491-6.**

Morton
GONORRHOEA—Major Problems in Dermatology, Vol. 9

From its history to its treatment, **Morton** provides you with a detailed review of gonorrhoea including: the latest advances in the field since the mid 1960's; recent epidemiological data; advisable therapeutic regimens for clinical examination, laboratory methods, epidemiological follow-up of sex contacts, and control measures; and clinical variations of the disease in male, female and pediatric patients. Explicit illustrations and a helpful bibliography supplement the text.

By **R.S. Morton,** Consultant Venereologist, Royal Infirmary, Sheffield. 292 pp. Illustd. $25.00 Jan. 1978. **Order #6563-2.**

To order titles on 30-day approval, AD 6/78

☐ **Kopf, Bart & Andrade #5487-8**
☐ **Solomon # 8492-0**
☐ **Korting #5491-6**
☐ **Morton #6563-2**

FULL NAME

POSITION AND AFFILIATION (IF APPLICABLE)

ADDRESS

CITY STATE ZIP

☐ check enclosed ☐ bill me Prices subject to change.

W.B. Saunders Co.
West Washington Square Philadelphia, PA 19105

8/15/68—The patient was a 29-year-old woman who had undergone multiple excisions of basal cell carcinomas since 1958, which accounts for the scar tissue seen in these photographs. Two superficial, scaly, reddish patches were present on the right shoulder. A 1-mm punch biopsy performed on one of the lesions confirmed a diagnosis of superficial basal cell carcinoma. Treatment with twice daily applications of Efudex (fluorouracil) 5% Cream was begun on 9/5/68.

NOW... CLINICALLY PROVEN TOPICAL TREATMENT FOR SUPERFICIAL BASAL CELL CARCINOMA...

in patients with multiple lesions or difficult treatment sites

93% Success Rate on 113 Lesions in 54 Patients

Before prescribing, please consult complete product information, a summary of which follows:

Indications: Multiple actinic or solar keratoses. In 5% strength, superficial basal cell carcinoma when conventional methods are impractical, such as with multiple lesions or difficult treatment sites. Establish diagnosis before treating, as this method has not been proven effective in other types of basal cell carcinomas. Conventional techniques preferred for isolated, easily accessible lesions, as success rate is nearly 100%. Success rate with Efudex is about 93%.

Contraindications: Patients with known hypersensitivity to any of its components.

Warnings: If occlusive dressing is used, may increase inflammatory reactions in adjacent normal skin. Avoid prolonged exposure to ultraviolet rays. Safe use in pregnancy not established.

Precautions: If applied with fingers, wash hands immediately. Apply with care near eyes, nose and mouth. Solar keratoses failing to respond should be biopsied. Warn patients that treated area may be unsightly during therapy and sometimes for several weeks after. Perform follow-up biopsies in superficial basal cell carcinoma.

Adverse Reactions: Local—pain, pruritus, hyperpigmentation and burning at application site most frequent; also dermatitis, scarring, soreness, tenderness, suppuration, scaling and swelling. Also reported—insomnia, stomatitis, irritability, medicinal taste, photosensitivity, lacrimation, telangiectasia, leukocytosis, thrombocytopenia, toxic granulation and eosinophilia.

Dosage and Administration: When Efudex is applied erythema occurs, then vesiculation, erosion, ulceration, necrosis, epithelization. *Actinic or solar keratosis*—apply sufficient quantity to cover lesions, twice daily. Usual length of therapy is 2 to 4 weeks. *Superficial basal cell carcinomas*—apply sufficient quantity **(only 5% strength recommended)** to cover lesions, twice daily. Continue treatment for at least 3 to 6 weeks, but possibly as long as 10 to 12.

How Supplied: Solution, 10-ml drop dispensers containing 2% or 5% fluorouracil on a weight/weight basis. Cream, 25-Gm tubes containing 5% fluorouracil in a vanishing cream base.

ROCHE

Roche Laboratories
Division of Hoffmann-La Roche Inc.
Nutley, New Jersey 07110

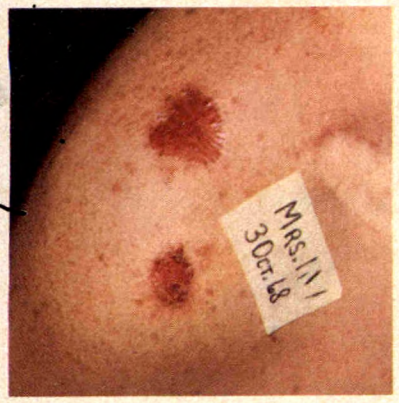

10/3/68—The typical inflammatory response appeared promptly, and treatment was discontinued after four weeks when gross examination indicated that no further malignancy was present.

12/19/68—Complete healing, with excellent cosmetic results, had occurred within the ten weeks following termination of therapy. Biopsy revealed no further evidence of malignancy.

3/13/73—Follow-up examination more than four years after discontinuation of therapy indicated no recurrence of malignancy. Cosmetic results with Efudex (fluorouracil) 5% Cream were acceptable.

Efudex (fluorouracil) 5% Cream

■ effective topical therapy for multiple lesions or difficult treatment sites
However, conventional methods are preferred for single lesions or those in easily accessible locations.

■ cosmetically desirable final results, with minimal if any scarring
Patients should be told that the lesion, and possibly some of the surrounding skin, may become temporarily inflamed during therapy.

■ a proven cytotoxic agent, with no systemic toxicity when used properly

■ *b.i.d.* application is convenient and economical for your patient

Efudex® 5% Cream
fluorouracil/Roche

ROCHE

THE TOPICAL ALTERNATIVE FOR SUPERFICIAL BASAL CELL CARCINOMA

New from Westwood Pharmaceuticals

WestCort™

(HYDROCORTISONE VALERATE) CREAM, 0.2%

For prompt clinical improvement in corticosteroid-responsive dermatoses

89% of patients with atopic dermatitis on WestCort™ therapy showed clinical improvement: 44% of all patients cleared.

Eight double blind, bilateral controlled clinical trials* were conducted involving 126 patients with atopic dermatitis. Duration of treatment varied from 7 to 28 days and dosage was 2 to 3 times daily. Studies compared WestCort to various agents, including placebo.

Pruritus and erythema reduced in 94% of patients

The most important symptoms to the patient are usually pruritus and erythema. In separate studies involving 31 patients with atopic dermatitis, 94% experienced a reduction in these symptoms after approximately two weeks of therapy.

Photographed object is an artistic interpretation of the manifestation of skin diseases.

• Effective
• Elegant
• Economical

Unique all-purpose cre vehicle enhances steroid release and optimizes epidermal penetration

- Effective for corticosteroid-responsiv dermatoses.
- Emollient cream is light-textured, wa miscible, and non-greasy.
- Formulated with the patient in mind; paraben-free.
- Less expensive than many of the mos frequently prescribed fluorinated and non-fluorinated corticosteroids availa
- Packaged in convenient and economi 15, 45 and 60 g. tubes.

*Information on file at Westwood Pharmaceuticals Inc

Please see following page for complete prescribing information.

WESTWOOD
PHARMACEUTICALS INC
Buffalo, New York 14213
In Canada, Belleville, Ontario K8N 5E9

© 1978, W.P. Inc.

CAUTION: Federal law prohibits dispensing without prescription.

WestCort™

(HYDROCORTISONE VALERATE) CREAM, 0.2%

DESCRIPTION: Westcort Cream contains hydrocortisone valerate, an active, non-fluorinated ester of the corticosteroid hydrocortisone. It has the following chemical name: 11 β,21-dihydroxy-17α-valeryloxy-4-pregnene-3, 20-dione.

The structural formula is:

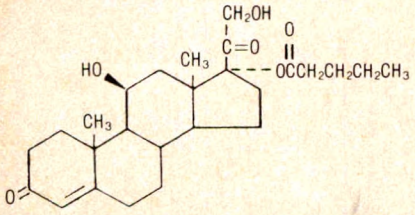

Each gram of Westcort Cream contains 2.0 mg. hydrocortisone valerate in a hydrophilic base composed of white petrolatum, stearyl alcohol, propylene glycol, amphoteric-6, carbomer 940, sodium phosphate, sodium lauryl sulfate, sorbic acid (as preservative) and water.

ACTIONS: Westcort (hydrocortisone valerate) Cream is effective primarily because of its anti-inflammatory, anti-pruritic, and vasoconstrictive actions.

INDICATIONS: Westcort Cream is intended for the relief of the inflammatory manifestations of corticosteroid responsive dermatoses.

CONTRAINDICATIONS: Topical steroids are contraindicated in viral diseases of the skin, such as vaccinia and varicella. Topical steroids are contraindicated in those patients with a history of hypersensitivity to any of the components of the preparation. Westcort Cream is not for ophthalmic use.

PRECAUTIONS: If irritation develops, use of the product should be discontinued and appropriate therapy instituted.

In the presence of infection, an appropriate antifungal or antibacterial agent should be administered concomitantly. If a favorable response does not occur promptly, the steroid should be discontinued until the infection has been adequately controlled.

If extensive areas are treated, or if occlusive dressings are used, the possibility exists of increased systemic absorption of the steroid, and suitable precautions should be taken.

Although topical steroids have not been reported to have an adverse effect on the fetus, the safety of their use during pregnancy has not been definitely established. Therefore, they should not be used extensively, in large amounts, or for prolonged periods of time on pregnant patients.

ADVERSE REACTIONS: The following local adverse reactions have been reported with the use of topical corticosteroids: burning sensations, itching, irritation, dryness, folliculitis, secondary infection, skin atrophy, striae, hypertrichosis, acneiform eruptions, and hypopigmentation.

If occlusion is used, it should be noted that the following side effects have been reported with topical steroids used in this manner: maceration of the skin, secondary infection, skin atrophy, striae, and miliaria.

DOSAGE AND ADMINISTRATION: A small amount should be massaged gently into the affected areas 2 to 3 times daily, as needed.

HOW SUPPLIED: Westcort (hydrocortisone valerate) Cream, 0.2% is supplied in 15 g., NDC 0072-8100-15; 45 g., NDC 0072-8100-45; and 60 g., NDC 0072-8100-60 tubes.

WESTWOOD
PHARMACEUTICALS INC.
Buffalo, New York 14213
In Canada, Belleville, Ontario K8N 5E9

A New Look for the 1977 Red and Blue Books

Those familiar **Red and Blue Books,** published by the American Medical Association's Center for Health Services Research and Development, now have new size. . .new format. . .new data. As a result, you will find them more useful and convenient than ever. Here's a closer look at the 6th annual edition of these authoritative volumes:

Profile of Medical Practice 1977 (Red Book)
The focus is on characteristics of medical practice such as physicians' work patterns, professional expenses, and net income from medical practice.

Socioeconomic Issues of Health 1977 (Blue Book)
A combination of the latest data on the U.S. health services delivery system and essays on topical health issues.

Quantities are limited, so order today!

S/J

Order Dept.
American Medical Association
535 N. Dearborn
Chicago, IL 60610

_____Profile of Medical Practice (OP-6) $4.50
_____Socioeconomic Issues of Health (OP-5) $4.50

Enclosed is my check for $_____, payable to the American Medical Association.

Name _____

Address _____

City/State/Zip_____

Dx: sun-induced herpes labialis

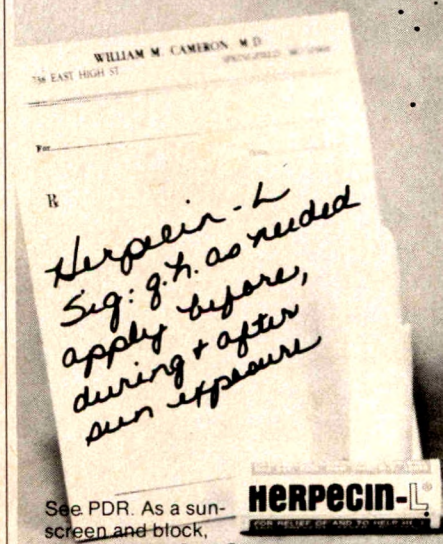

See PDR. As a sunscreen and block, HERPECIN-L Cold Sore Lip Balm provides protection in the 290 nm-visible range.* Available OTC.

For Samples, write Dept. N at:

CAMPBELL LABORATORIES, INC.
P.O. Box 812, FDR, N.Y., N.Y. 10022

*Ref: Bennett, R. G. and Robbins, P. On the Selection of a Sunscreen, J. Dermatol. Surg. & Oncol. 3:2, 208, 1977.

computers and medicine:

the publication that tells you how physicians have put computers to work -- in practical, valuable ways

This bi-monthly publication reports on ways computer potential has been harnessed and used clinically and administratively in private practice, clinics, hospitals, and medical societies.

It describes medical-computer systems in use now, those still in the developmental and experimental stages, and tells you whom to contact for more details.

Let COMPUTERS AND MEDICINE start bringing you ideas. Order a subscription now! $5 for 1 yr.; $8 for 2 yrs. (U.S. and U.S. Possessions only). Send a check or money order to Subscriber Services. AMA, 535 N. Dearborn St., Chicago, Ill. 60610.

There are two faces of severe acne vulgaris

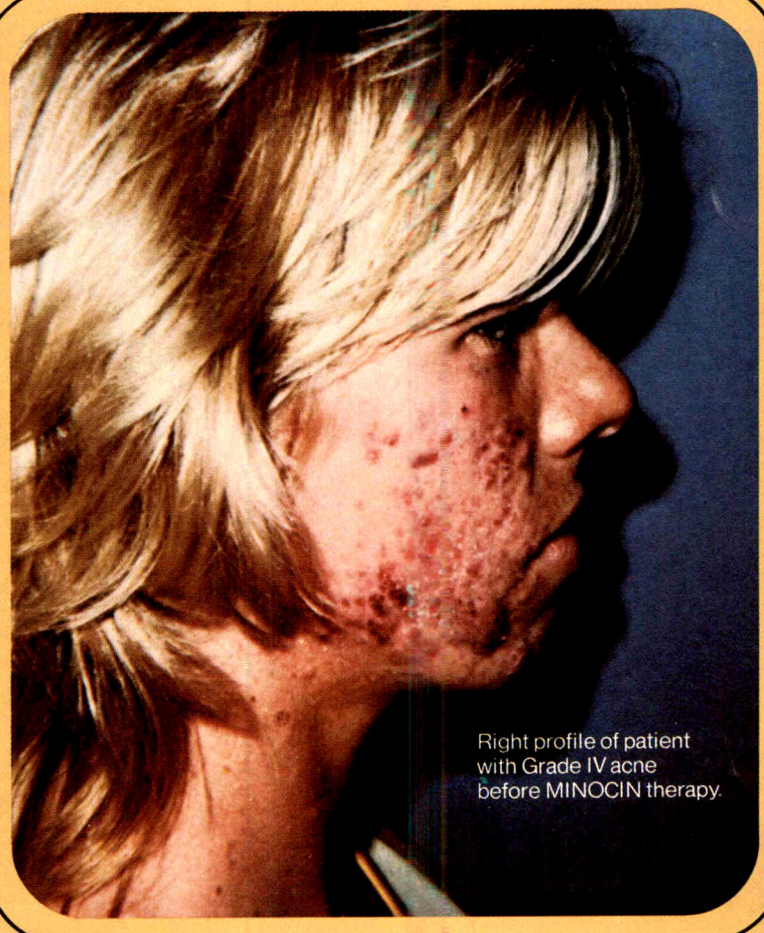

Right profile of patient with Grade IV acne before MINOCIN therapy.

BEFORE adjunctive

MINOCIN®

MINOCYCLINE HCl

CAPSULES 50 mg and 100 mg
SYRUP 50 mg/5 ml

200 mg initially, 100 mg *b.i.d.* or
100 or 200 mg initially, 50 mg *q.i.d.*

MINOCIN Minocycline HCl
Oral and Intravenous Brief Summary

Contraindications: Hypersensitivity to any tetracycline.

Warnings: Intravenous use, particularly in pregnancy, in daily doses exceeding 2 grams has been associated with deaths through liver failure. When need for intensive treatment outweighs potential dangers, perform renal and liver function tests before and during therapy; also follow serum concentrations. In renal impairment, usual doses may lead to excessive accumulation and liver toxicity. Under such conditions, use lower total doses, and, in prolonged therapy, determine serum levels. This hazard is of particular importance in I.V. use in pregnant or postpartum patients with pyelonephritis. In such cases, the blood level should not exceed 15 mcgm/ml. and liver function tests should be made at frequent intervals. Do not prescribe other potentially hepatotoxic drugs concomitantly. The use of tetracyclines during tooth development (last half of pregnancy, infancy and childhood to the age of 8 years) may cause permanent discoloration of the teeth (yellow-gray-brown). This is more common during long-term use but has been observed following repeated short-term courses. Enamel hypoplasia has also been reported. Tetracyclines, therefore, should not be used in this age group unless other drugs are not likely to be effective or are contraindicated. Photosensitivity manifested by an exaggerated sunburn reaction has been observed in some individuals taking tetracyclines. Advise patients apt to be exposed to direct sunlight or ultraviolet light that such reaction can occur, and discontinue treatment at first evidence of skin erythema. Studies to date indicate that photosensitivity is rarely reported with MINOCIN *Minocycline HCl*. In patients with significantly impaired renal function, the antianabolic action of tetracycline may cause an increase in BUN leading to azotemia, hyperphosphatemia, and acidosis. CNS side effects (lightheadedness, dizziness, vertigo) have been reported, may disappear during therapy, and always disappear rapidly when drug is discontinued. Caution patients who experience these symptoms about driving vehicles or using hazardous machinery while taking this drug. **Pregnancy:** In animal studies, tetracyclines cross the placenta, are found in fetal tissues, and can have toxic effects on the developing fetus (often related to retardation of skeletal development). Embryotoxicity has been noted in animals treated early in pregnancy. **Newborns, infants and children:** All tetracyclines form a stable calcium complex in any bone-forming tissue. Prematures, given oral doses of 25 mg./kg. every 6 hours, demonstrated a decrease in fibula growth rate, reversible when drug was discontinued. Tetracyclines are present in the milk of lactating women who are taking a drug in this class.

(cont'd)

There are two faces of severe acne vulgaris



Right profile of patient with acne vulgaris clearing after 6 weeks of MINOCIN therapy.

AFTER adjunctive

MINOCIN®

MINOCYCLINE HCl

CAPSULES 50 mg and 100 mg
SYRUP 50 mg/5 ml

200 mg initially, 100 mg *b.i.d.* or
100 or 200 mg initially, 50 mg *q.i.d.*

MINOCIN Minocycline HCl
Oral and Intravenous Brief Summary (continued)

Precautions: Use may result in overgrowth of nonsusceptible organisms, including fungi. If superinfection occurs, institute appropriate therapy. In veneral diseases when coexistent syphilis is suspected, darkfield examination should be done before treatment is started and blood serology repeated monthly for at least four months. Patients on anticoagulant therapy may require downward adjustment of such dosage. Test for organ system dysfunction (*e.g.*, renal, hepatic and hemopoietic) in long-term use. Treat all group A beta-hemolytic streptococcal infections for at least 10 days. Avoid giving tetracycline in conjunction with penicillin.

Adverse Reactions: GI: (with both oral and parenteral use): anorexia, nausea, vomiting, diarrhea, glossitis, dysphagia, enterocolitis, inflammatory lesions (with monilial overgrowth) in anogenital region. **Skin:** maculopapular and erythematous rashes. Exfoliative dermatitis (uncommon). Photosensitivity is discussed above ("Warnings"). **Renal toxicity:** rise in BUN, dose-related (see "Warnings"). **Hypersensitivity reactions:** urticaria, angioneurotic edema, anaphylaxis, anaphylactoid purpura, pericarditis, exacerbation of systemic lupus erythematosus. In young infants, bulging fontanels have been reported following full therapeutic dosage, disappearing rapidly when drug was discontinued. **Blood:** hemolytic anemia, thrombocytopenia, neutropenia, eosinophilia. **CNS:** (see "Warnings"). When given in high doses, tetracyclines may produce brown-black microscopic discoloration of thyroid glands: no abnormalities of thyroid function studies are known to occur.

NOTE: Concomitant therapy: Antacids containing aluminum, calcium, or magnesium impair absorption; do not give to patients taking oral minocycline. Studies to date indicate that absorption of MINOCIN *Minocycline HCl* is not notably influenced by foods and dairy products.

CNS side effects including light-headedness, dizziness, or vertigo have been reported with MINOCIN. Patients who experience these symptoms should be cautioned about driving vehicles or using hazardous machinery while on minocycline therapy.

Lederle

LEDERLE LABORATORIES
A Division of American Cyanamid Company
Pearl River, N.Y. 10965

Printed in U.S.A. April 1978

410-8R

what's best for the care of dry or premature aging or wrinkled skin... DUE TO EPIDERMA DEHYDRATION?

SUPPLIED: 2 OZ. TUBES

WRITE FOR SAMPLES

DOAK PHARMACAL CO., INC. WESTBURY, N.Y. 115

DISTRIBUTOR IN CANADA

The family for your patients' steroid

Proven clinically effective for prompt relief of mild-to-severe corticosteroid-responsive dermatoses

Valisone® Aerosol 0.15%
For acute contact dermatitis.

Impressive results with Valisone Cream and Ointment in published studies:

contact dermatitis
96% good to excellent results
(81 of 84 patients)*

atopic eczema
92% good to excellent results
(231 of 251 patients)*

psoriasis
85% good to excellent results
(150 of 177 patients)*

Valisone® Cream 0.1%

*Files of Headquarters Medical Research Division, Schering Corporation.

Copyright © 1977, Schering Corporation. All Rights Reserved.

See Clinical Considerations section on opposite page.

# of specialists responsive problems

Schering

Valisone® Lotion 0.1%
Especially useful in seborrheic dermatitis.

Clinical Considerations: Indications: VALISONE Cream, Ointment, and Lotion are indicated for relief of the inflammatory manifestations of corticosteroid-responsive dermatoses. VALISONE Reduced Strength Cream is indicated for the relief of the inflammatory manifestations of corticosteroid-responsive dermatoses. VALISONE Aerosol is indicated, solely, for adjunctive topical management for the relief of inflammatory manifestations of acute contact dermatitis. **Contraindications:** Topical steroids are contraindicated in tuberculosis of the skin and some viral diseases of the skin (varicella and vaccinia). Topical steroids are also contraindicated in those patients with a history of hypersensitivity to any of the components of the preparations. VALISONE Aerosol is contraindicated for use under occlusive dressings. **Warnings for VALISONE Aerosol:** Keep the spray away from eyes and other mucous membranes; avoid inhaling. Avoid freezing of the tissue by not spraying for more than 3 seconds, at a distance not less than 6 inches. Contents are under pressure. Do not puncture. Do not store or use near open flame or heat. Exposure to temperatures above 120°F may cause bursting. Keep out of reach of children. Never throw container into fire or incinerator. **Precautions:** If irritation or sensitization develops with the use of VALISONE products, treatment should be discontinued and appropriate therapy instituted. In the presence of infection, the use of an appropriate antifungal or antibacterial should be instituted. If favorable response does not occur promptly, the corticosteroid should be discontinued until the infection has been adequately controlled. If extensive areas are treated, or if the occlusive technique is used, the possibility exists of sufficient systemic absorption to produce adrenal suppression and systemic corticosteroid effects may occur; suitable precautions should be taken. In a few cases, ulceration has been reported with the use of topical steroids for skin conditions involved with impaired circulation (i.e., stasis dermatitis). Prolonged application of corticosteroid-containing products under occlusion may result in striae or atrophy of the skin or subcutaneous tissues. VALISONE products are not for ophthalmic use. **Usage in Women of Childbearing Age:** The use of any drug during pregnancy and the lactation period or in women of childbearing age requires that the potential benefits of the drug be weighed against the possible hazards to the fetus or infant. Topical corticosteroids have not been reported to have an adverse effect on the fetus, but the safety of their use in pregnant patients has not been definitely established. They should not be used extensively or for prolonged periods of time in pregnant patients, unless the condition requiring treatment warrants the risk. **Adverse Reactions:** The following adverse reactions have been reported with topical corticosteroids: burning, itching, irritation, dryness, folliculitis, hypertrichosis, acneiform eruptions, and hypopigmentation. The following may occur more frequently with occlusive dressings than without such therapy: maceration of the skin, secondary infection, atrophy of the skin or subcutaneous tissues, striae, miliaria. **Dosage and Administration:** VALISONE Cream, Ointment, and Reduced Strength Cream are applied as a thin film over the affected skin areas one to three times a day. Clinical studies of VALISONE have indicated that dosage once or twice a day is often feasible and effective. VALISONE Reduced Strength Cream has an aqueous, hydrophilic base that softens and moisturizes the skin. Although occlusive dressings are required infrequently, they may enhance therapeutic efficacy in certain refractory lesions of psoriasis and other dermatoses that are difficult to treat. Apply a few drops of VALISONE Lotion to the affected area of the scalp and massage lightly until it disappears. Apply twice daily, in the morning and at night. Dosage may be increased in stubborn cases; following improvement, apply once daily. Apply VALISONE Aerosol three to four times a day. The container may be held upright or inverted during use. The spray should be directed onto the affected area from a distance of approximately 6 inches and applied for only 3 seconds. Aerosol packaged by Aerosol Techniques, Inc., Armstrong Laboratories Division, West Roxbury, MA. 02132. **For more complete details, consult package insert or Schering literature available from your Schering Representative or Professional Services Department, Schering Corporation, Kenilworth, New Jersey 07033.**

MARCH 1974 (R)

Valisone® Reduced Strength Cream 0.01%
For low-cost maintenance therapy.

Valisone® Ointment 0.1%
When dryness is a problem.

Valisone®
brand of
betamethasone valerate, NF

SLS-914

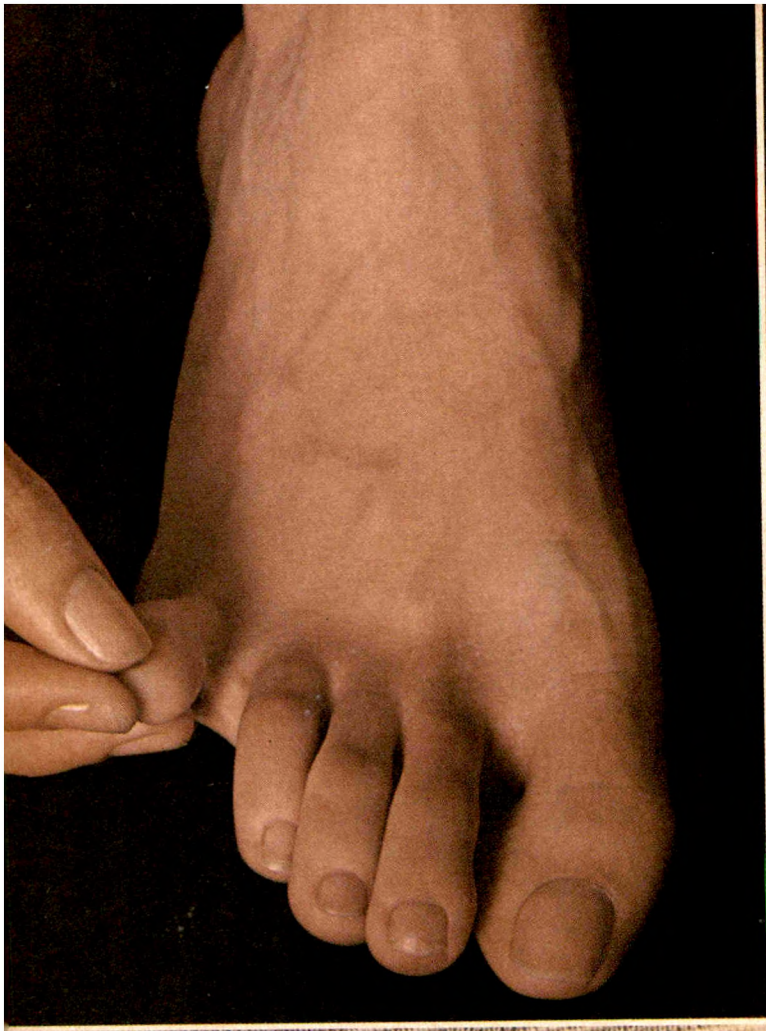

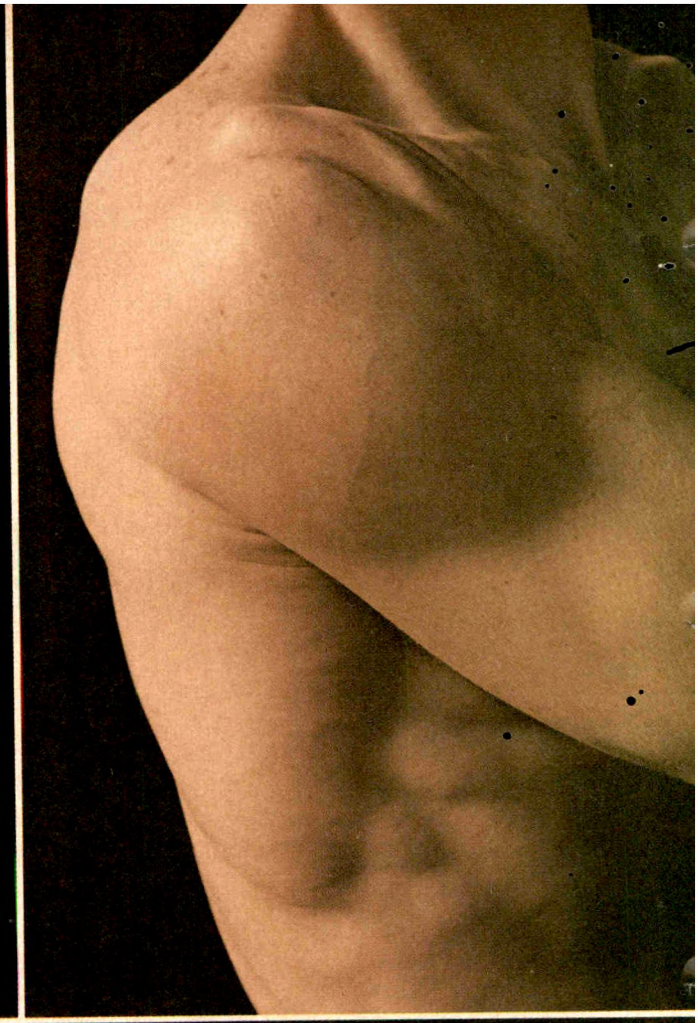

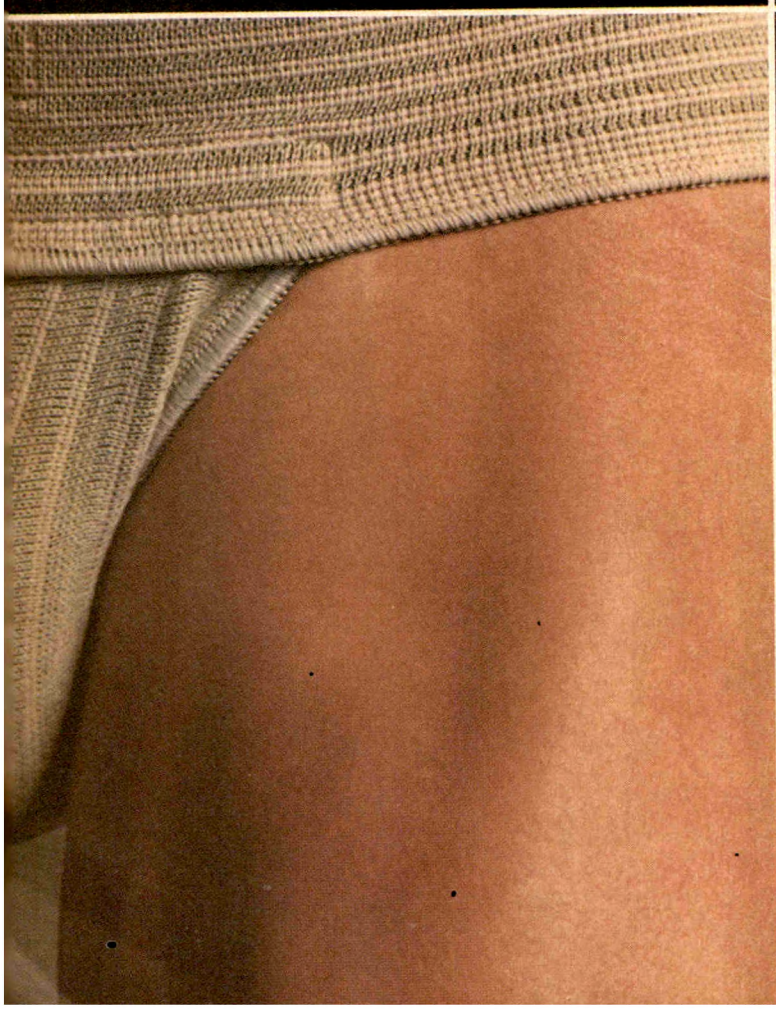

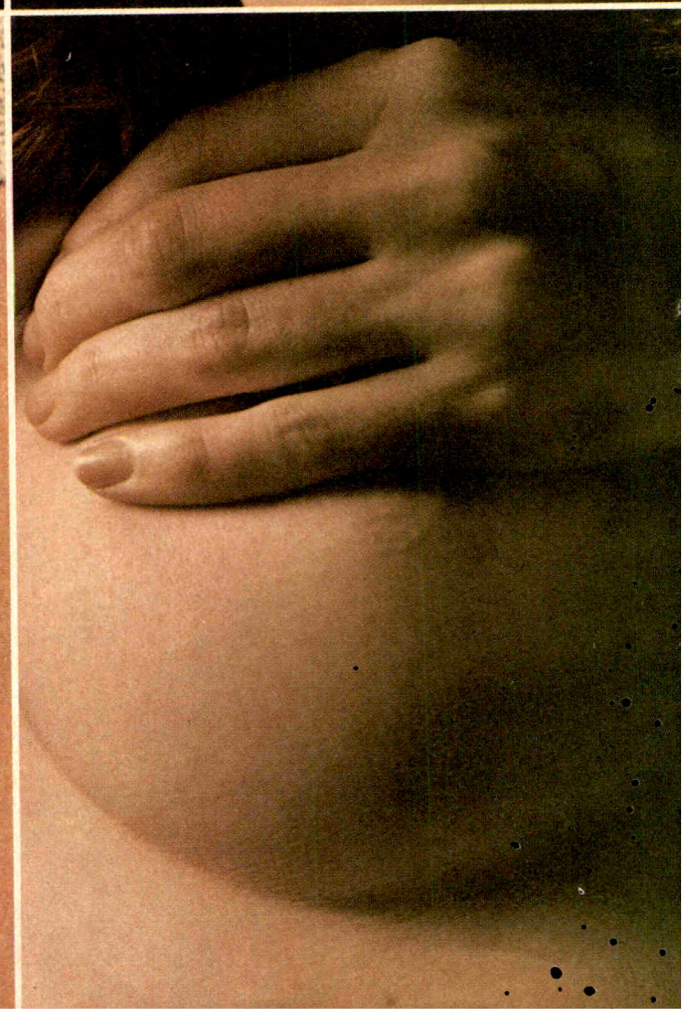

What can a month of follow-up tell you about this antifungal?

MicaTin makes it clear.

MicaTin can clear the most common fungal infections. More than that, it can keep them clear. Over 90% of patients successfully treated with MicaTin were found to be free of the original infection up to one month (median) after cessation of therapy.

MicaTin—a high rate of clearance demonstrated in extensive studies*

MicaTin provided clinical clearance or improvement in 88-94% of patients treated for tinea pedis,† tinea corporis,† tinea cruris,† candidiasis and tinea versicolor.

And most infections remained clear at follow-up

The patients in these studies were then evaluated to determine if MicaTin was effective in keeping these fungal infections clear. Of the 121 patients who were clear of tinea pedis, tinea corporis and tinea cruris at the end of treatment and available for follow-up, 92% showed no clinical or mycological recurrence of the original infection one month (median) later. And of the 34 patients cleared of cutaneous candidiasis and available for follow-up, 91% were still clear two weeks (median) later.

MicaTin—for the fungal infections you see every day

MicaTin is effective against the most prevalent fungal pathogens and provides fast symptomatic relief—usually within 72 hours for a majority of the patients.

MicaTin also has a low incidence of side effects. Reports of "burning" sensation, irritation and maceration with MicaTin have been few and isolated. It should not be used in patients with known hypersensitivity to any of its ingredients.

And MicaTin is economically priced—its retail cost is usually lower than that of other prescription antifungals.

·MicaTin. So effective the first time around, it's seldom needed a second.

*Data on file, Johnson & Johnson. T. corporis, T. cruris, and candidiasis should be treated B.I.D. for 2 weeks, T. versicolor once daily for 2 weeks, and T. pedis B.I.D. for one month.

† When infecting organisms are Trichophyton rubrum, Trichophyton mentagrophytes and Epidermophyton floccosum.

Before prescribing, please consult complete product information, a summary of which follows:

Indications: For topical application in the treatment of tinea pedis (athlete's foot), tinea cruris, and tinea corporis caused by Trichophyton rubrum, Trichophyton mentagrophytes, and Epidermophyton floccosum, in the treatment of cutaneous candidiasis (moniliasis), and in the treatment of tinea versicolor.

Contraindications: MicaTin has no known contraindications.

Precautions: If a reaction suggesting sensitivity or chemical irritation should occur, use of the medication should be discontinued.

For external use only. Avoid introduction of MicaTin brand miconazole nitrate cream 2% and lotion 2% into the eyes.

Adverse Reactions: There have been isolated reports of irritation, burning, and maceration associated with application of MicaTin.

How Supplied: MicaTin brand cream 2% containing miconazole nitrate at 2% strength is supplied in 3 oz., 1 oz. and 15 g. tubes. MicaTin brand lotion 2% containing miconazole nitrate at 2% w/w strength is supplied in polyethylene squeeze bottles in quantities of 12 and 30 ml.

AN ETHICAL SPECIFIC FROM
THE DERMATOLOGICAL DIVISION OF

Johnson & Johnson
NEW BRUNSWICK, NEW JERSEY 08903

MicaTin
BRAND
miconazole nitrate 2%
Cream/Lotion
by prescription only

© Johnson & Johnson 1978



Hymenoptera Allergy

Phadebas RAST provides an accurate means of documenting IgE mediated allergic sensitivity to stinging insects.

Phadebas RAST®

the *in vitro* alternative

Pharmacia Diagnostics AB
Uppsala, Sweden

Pharmacia Diagnostics

Argentina Laboratorios Dr. Gador y Cia., S.A.C.I. Casilla de Correo 4041 1006 BUENOS AIRES. **Australia** Pharmacia (South Seas) Pty. Ltd. P.O. Box 175 4 Byfield Street NORTH RYDE N.S.W. 2113. **Austria** Pharmacia Gesellschaft m.b.H. Rathausplatz 4 A-1010 WIEN. **Belgium** N.V. Pharmacia Belga S.A. Bld. Gen. Jacqueslaan 26 B-1050 BRUSSELS. **Brazil** Emprêsa Medimex Importação e Comércio Ltda. Rua Cardoso Marinho, 40 Caixa Postal 33-ZC-00 RIO DE JANEIRO. **Canada** Pharmacia (Canada) Ltd. 2044 boul. St. Régis Blvd. DORVAL, Québec H9P 1H6. **Denmark** Pharmacia AS, Herredsvejen DK-3400 HILLERÖD. **Finland** Pharmacia OY Norrskensvägen 6, SF-02100 ESBO. **France** Pharmacia France S.A. Rue de Marly Parly 2 F-78150 LE CHESNAY. **German Federal Rebublic** Deutsche Pharmacia G.m.b.H. Munzinger Strasse 9 Postfach 5480 D-7800 FREIBURG. **Great Britain** Pharmacia (G.B.) Ltd. Paramount House 75 Uxbridge Road LONDON W5 5SS. **Greece** G.A. Kambanis Imports-Exports-Representations 3 Iridanou Street ATHENS 612. **Italy** Importex Chimici Farmaceutici S.p.A. P.O. Box 467 Via Flavia 122/124 I-34100 TRIESTE. **Mexico** Internacional Cientifica S.A. Apartado Postal 2-807 Angel del Campo 17-A MEXICO 12 D.F. **The Netherlands** Gist-Brocades N.V. Diagnostics Dept. P.O. Box 324 Frijdastraat 7–9 RIJSWIJK (Z H) 2109. **Norway** Norsk Pharmacia A/S Postboks 2005 Grünerløkka OSLO 5. **Portugal** J.A. Baptista D'Almeida Lda. Apartado 1339 LISBOA 1. **Spain** Atom, Paseo del Monte 34 BARCELONA 12. **Sweden** Pharmacia Norden AB Diagnostics Dept. Box 159 751 04 UPPSALA 1. **Switzerland** Pharmacia -pdf- (Schweiz) A.G. 214 Seefeldstrasse CH-8034 ZUERICH. **USA** Pharmacia Diagnostics Division of Pharmacia Inc. 800 Centennial Avenue PISCATAWAY New Jersey 08854. **Other countries** Pharmacia Diagnostics AB Box 17 S-751 03 UPPSALA 1 Sweden.

ACNE'S ANXIETY

BENZAGEL® 5% Acne Gel 10% Acne Gel

(5% or 10% benzoyl peroxide, 6% polyoxyethylene lauryl ether, 40% alcohol)

Early visible improvement helps to relieve anxiety and promotes patient cooperation—Simple and pleasant to use

- Benzoyl peroxide in a special alcohol gel base—Reliable and predictable, imparts a pleasant cooling sensation with controlled drying of sebaceous oils. Accelerates desquamation.
- "BP base/bond" for uniform therapeutic deposition of benzoyl peroxide—Reduces burning sensation on application, for greater patient acceptance.
- Effective antibacterial and comedolytic action—Rapid improvement is seen, often within two weeks.

BENZAGEL® a basic component of acne therapy

Description: 5% or 10% benzoyl peroxide, 6% polyoxyethylene lauryl ether and 40% alcohol in an astringent gel containing colloidal magnesium aluminum silicate, hydroxypropyl methylcellulose, citric acid, fragrance and purified water.

Action: Provides drying, desquamative and antiseptic activity.

Indication: An aid in the treatment of acne.

Dosage and Administration: Wash affected areas prior to application. Apply once or more daily or as directed by physician.

Contraindications: Should not be used by patients having known sensitivity to either benzoyl peroxide or polyoxyethylene lauryl ether.

Precautions: For External Use Only. Not for ophthalmic use. Keep away from eyes and mucosae. Very fair individuals should begin with a single application at bedtime allowing overnight medication. May bleach colored fabrics. Keep this and all other medications out of the reach of children.

Caution: Federal law prohibits dispensing without prescription.

How Supplied: Plastic tubes, 1½ oz. and 3 oz.

For Patient Starters
Call Toll-Free (800) 523-6674

Dermik

Dermik Laboratories, Inc.
Fort Washington, Pa. U.S.A. 19034

Is Atopic Dermatitis a place for water?

The most important factor in the management of patients with atopic dermatitis is keeping the skin moist, according to members of a panel discussing the disease at a conference on dermatologic practice held at the University of North Carolina School of Medicine.[1]

Aristocort® A

Cream with AQUATAIN™ Hydrophilic Base

TRIAMCINOLONE ACETONIDE

Our Aquatain base is 74.3% water

- May help keep treatment areas supple and smooth during atopic therapy.
- A hydrophilic vehicle that patients like. 77-100% of the 134 patients in 4 different studies commented favorably on the non-drying effect of ARISTOCORT® A.*
- A proven steroid. Excellent or moderate response in 83 of 86 atopic patients treated in 4 double-blind studies.*
- A wide choice of potency, vehicle and package size.

Is your topical steroid working with or against your regimen?

*Data on file, Dept. of Medical Research Lederle Laboratories 1. Skin and Allergy News, November, 1977.

INDICATIONS: For relief of inflammatory manifestations of corticosteroid-responsive dermatoses.

CONTRAINDICATIONS: Viral skin diseases, such as varicella and vaccinia; hypersensitivity to any component (not for ophthalmic use); when circulation is markedly impaired.

WARNINGS: Safety use in pregnancy has not been absolutely established. Do not use extensively, in large amounts, or for prolonged periods of time in pregnant patients.

PRECAUTIONS: If irritation develops, discontinue use and institute appropriate therapy. In infections, use appropriate antifungal or antibacterial agents; if a favorable response does not occur promptly, discontinue the corticosteroid until the infection is adequately controlled. If extensive areas are treated or the occlusive technique is used, increased systemic absorption of the corticosteroid may occur; take suitable precautions.

ADVERSE REACTIONS: (local) Burning, itching, irritation, dryness, folliculitis, hypertrichosis, acneform eruption and hypopigmentation.

ARISTOCORT A CREAM: Each gram of ARISTOCORT A contains 0.25 mg. (0.025%), 1 mg. (0.1%) or 5 mg. (0.5%) of the highly active steroid, Triamcinolone Acetonide (a derivative of triamcinolone) in AQUATAIN, a specially formulated base composed of emulsifying wax NF, isopropyl palmitate, glycerin USP, sorbitol solution USP, lactic acid, 2% benzyl alcohol and purified water. AQUATAIN is non-staining, water-washable, paraben-free, spermaceti-free and has a light texture and consistency.

LEDERLE LABORATORIES,
A Division of American Cyanamid Company
Pearl River, New York 10965

Lederle

449-8

Wet dressings may need no introduction to you, but Aluwets™ do because they provide

A new dimension in wet dressing therapy:

Potent Antibacterial Action

AluWets™

aluminum chloride hexahydrate, N.F.)

Wet Dressing Crystals

In *in vivo* tests, **Aluwets** provided substantially greater antibacterial action against resident flora than a commonly-used aluminum acetate (Burow's) solution.[1]

May potentiate steroid and antibiotic activity

When used in combination with topical steroids or steroid-antibiotic combinations, **Aluwets** Wet Dressings—because of their anti-inflammatory and antibacterial effects—may enhance your therapy by reducing the dependency on topical steroids and antibiotics.

1. Kligman, A.M.: Report on file at Stiefel Research Institute.

Contains: Each packet contains 12.9 grams aluminum chloride hexahydrate, N.F.

Available: Boxes of six packets each.

Directions: Thoroughly dissolve contents of one packet in approximately 12 oz. of cool or lukewarm water to make a 2% aluminum chloride solution.

Soak clean dressing or bandage in solution and apply loosely on the inflamed skin.

Remove, re-moisten and reapply dressings every 10-15 minutes. DO NOT LET DRESSINGS DRY OUT. Continue this procedure for 4 to 8 hours or as needed.

Dressing material and used solution should be discarded *daily* and not reused.

CAUTION: FOR EXTERNAL USE ONLY. Avoid contact with the eyes. Keep this and all medications out of the reach of children. If irritation occurs or persists, discontinue use.

Another First from Stiefel

STIEFEL
Dermatological Dermatologicals since 1847

Stiefel Laboratories, Inc.,
Oak Hill, N.Y. 12460
Stiefel Laboratories (Canada) Ltd.,
St. Laurent, Quebec, Canada H4S 1E1



Cosmetically Elegant In Its Class

Prolonged action as shown by Wood's light

WESTWOOD
PHARMACEUTICALS INC.
Buffalo, New York 14213
In Canada, Belleville, Ontario K8N 5E9

© 1978 WP

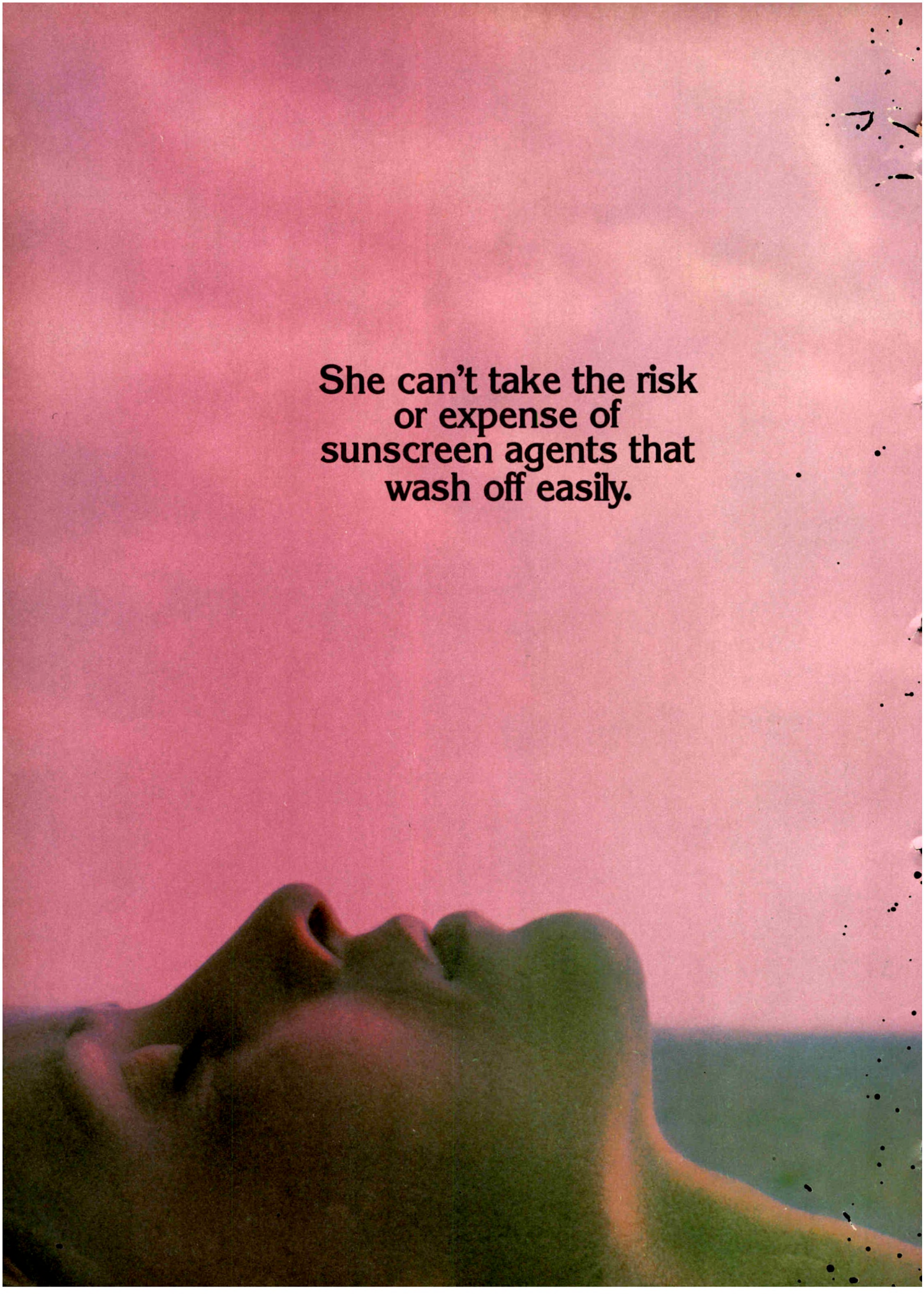
She can't take the risk
or expense of
sunscreen agents that
wash off easily.

Dome

SunGard® Lotion

Effective yet economical, because its excellent durability means fewer applications.

SUNGARD provides more durable protection on the skin than PABA 5% or octyl dimethyl PABA 3.3%* (amount of sunscreen agent remaining on skin after water-wash procedure).

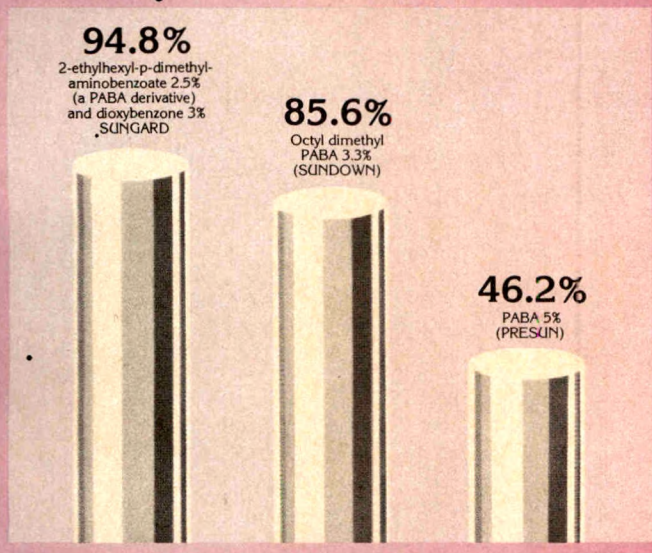

*Data on file at Dome Laboratories.

Broad-range effectiveness
SUNGARD protects against more than just the sunburn (UVB) spectrum—it provides some protection in the photosensitivity (UVA) range as well.

Greater economy from greater substantivity
The more sunscreen remaining on the skin, the better the protection and the fewer applications required to maintain effective protection. As with other sunscreen agents, however, caution your patients about the importance of maintaining continuous protection by reapplying SUNGARD every 3 to 4 hours.

SPF (Sun Protection Factor) 6.3
SUNGARD Lotion is an extra-protection sunscreen product. It allows patients to stay in the sun 6 times as long as before without burning provided there is no heavy perspiration or prolonged swimming.

Yet SUNGARD permits tanning
With SUNGARD, sun-sensitive patients enjoy protection in the erythema range and moderate protection in the photosensitivity range. This permits gradual, natural tanning with repeated exposure to the sun.

SUNGARD...from the company that is a leader in skin-care products.

Dome Laboratories
Division Miles Laboratories Inc MILES
West Haven Connecticut 06516 USA

©1978 DOME LABORATORIES, DIVISION MILES LABORATORIES, INC. ALL RIGHTS RESERVED. DOM-1694

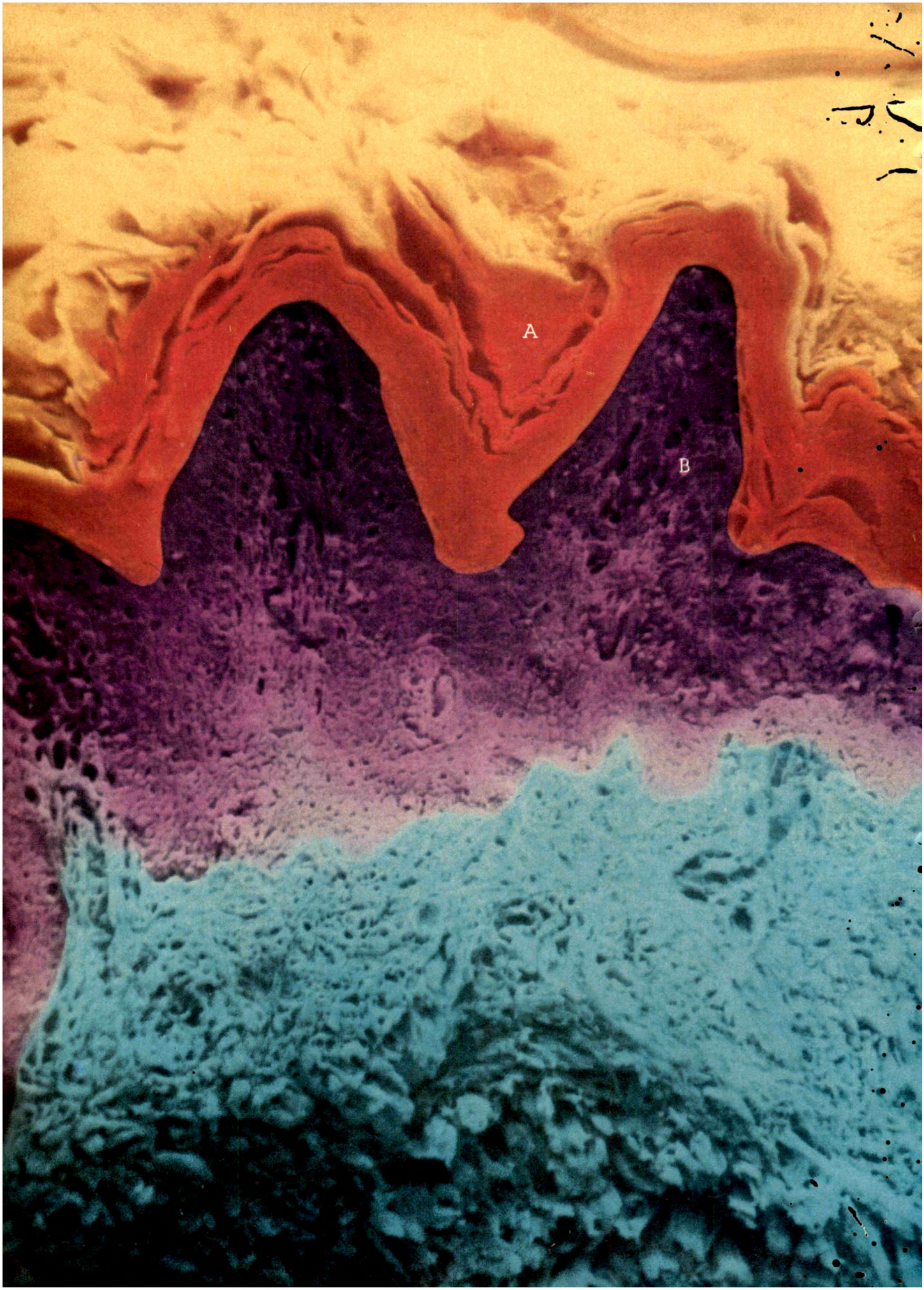
A
B

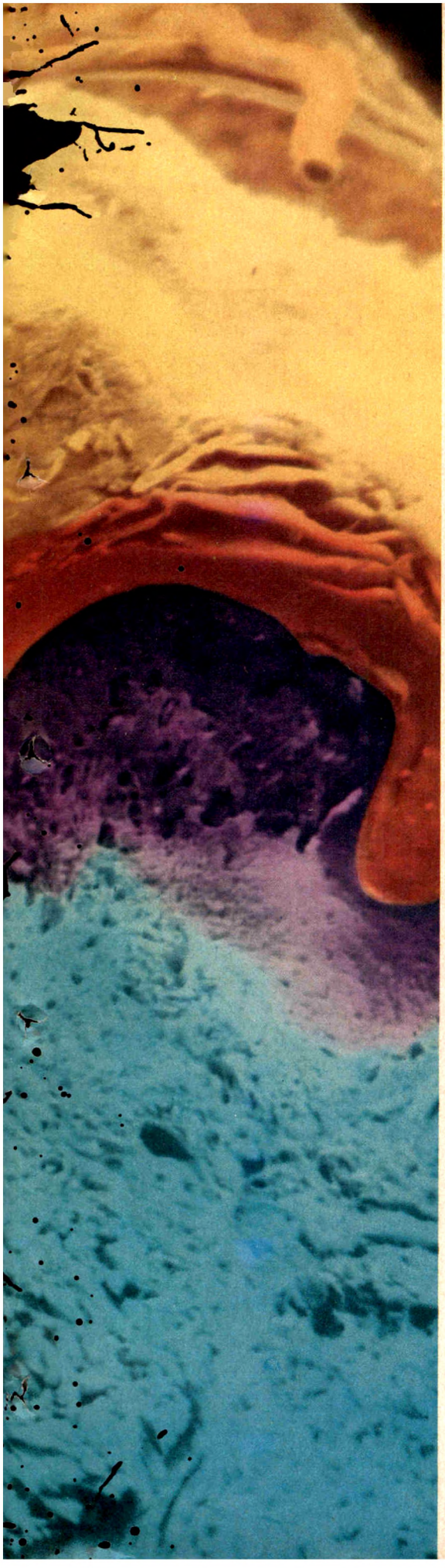

Potency in lichen simplex chronicus

Lichen simplex chronicus — with its circumscribed, lichenifi pruritic lesions — remains an erratic, often difficult to contro dermatosis. **Accordingly, Lidex represents an excellent choice in the treatment of its inflammatory manifestati**

Fluocinonide is 100% dissolved in the Lidex base for optimo lesion penetration. It offers anti-inflammatory, vasoconstrictive, antipruritic actions and is backed by a proven record of performance in dermatology.

Available in a variety of forms and sizes to suit the needs of the individual patient. Cream, ointment, Topsyn® (fluocinonid gel 0.05%, and Lidex®-E (fluocinonide) 0.05% — a soothing emollient cream.

The photomicrograph at left shows a cryofractured cross section of a lichen simplex chronicus lesion. Extensive hyperkeratosis (A) and acanthosis (B) are evident. Nuclei o keratinocytes appear in empty oval depressions. Note diso ganized desquamation of superficial corneocytes. (Technic color imposed on photomicrograph, magnified 130X.)

Lidex®

(fluocinonide) 0.05%

See following page for summary of prescribing information.

SYNTEX

SYNTEX LABORATORIES, INC.
PALO ALTO, CALIFORNIA 94304

LIDEX® (fluocinonide)
Cream and Ointment 0.05%
LIDEX®-E (fluocinonide)
Cream 0.05%
TOPSYN® (fluocinonide)
Gel 0.05%

Summary of prescribing information

Description LIDEX cream 0.05%, LIDEX ointment 0.05%, LIDEX-E cream 0.05%, and TOPSYN gel 0.05% contain the active compound fluocinonide. Fluocinonide, which is the 21-acetate ester of fluocinolone acetonide, has the chemical formula 6α, 9-difluoro-11β, 16α, 17, 21-tetrahydroxypregna-1, 4-diene-3, 20-dione, cyclic 16, 17-acetal with acetone, 21-acetate.

LIDEX cream contains fluocinonide 0.5 mg/g in FAPG® cream, a specially formulated cream base consisting of stearyl alcohol, polyethylene glycol 6000, propylene glycol, 1,2,6-hexanetriol and citric acid. This white cream vehicle is greaseless, non-staining, anhydrous and completely water miscible. The base provides emollient and hydrophilic properties. In this formulation, the active ingredient is totally in solution.

LIDEX ointment contains fluocinonide 0.5 mg/g in a specially formulated ointment base consisting of Amerchol CAB (mixture of sterols and higher alcohols), white petrolatum, propylene carbonate and propylene glycol. It provides the occlusive and emollient effects desirable in an ointment. In this formulation the active ingredient is totally in solution.

LIDEX-E cream contains fluocinonide 0.5 mg/g in a water-washable aqueous emollient base of stearyl alcohol, cetyl alcohol, mineral oil, propylene glycol, sorbitan monostearate, polysorbate 60, citric acid and purified water.

TOPSYN gel contains fluocinonide 0.5 mg/g in a specially formulated gel base consisting of propylene glycol, propyl gallate, disodium edetate, and Carbopol 940 (carboxypolymethylene) with NaOH and/or HCl added to adjust the pH. This clear, colorless, thixotropic vehicle is greaseless, non-staining and completely water miscible. In this formulation, the active ingredient is totally in solution.

Indications For relief of the inflammatory manifestations of corticosteroid-responsive dermatoses.

Contraindications Topical steroids are contraindicated in vaccinia and varicella. Topical steroids are contraindicated in those patients with a history of hypersensitivity to any of the components of the preparation.

Precautions If irritation develops, the cream, ointment or gel should be discontinued and appropriate therapy instituted.

In the presence of an infection, the use of an appropriate antifungal or antibacterial agent should be instituted. If a favorable response does not occur promptly, the corticosteroid cream, ointment or gel should be discontinued until the infection has been adequately controlled.

If extensive areas are treated, the possibility exists of increased systemic absorption and suitable precautions should be taken.

Although topical steroids have not been reported to have an adverse effect on pregnancy, the safety of their use in pregnant females has not absolutely been established. Therefore, they should not be used extensively on pregnant patients, in large amounts or for prolonged periods of time.

These products are not for ophthalmic use.

Adverse reactions The following local adverse reactions have been reported with topical corticosteroids: burning sensations, folliculitis, itching, acneform eruptions, irritation, hypopigmentation, dryness, miliaria, secondary infection, skin atrophy.

Dosage and administration A small amount should be gently massaged into the affected area three or four times daily, as needed.

How supplied

LIDEX Cream 0.05%—15g, 30g and 60g tubes
LIDEX Ointment 0.05%—15g, 30g and 60g tubes
LIDEX-E Cream 0.05%—15g and 60g tubes
TOPSYN Gel 0.05%—15g and 60g tubes



a quick reference to the AMA's large collection of medical films

and its yours free with the coupon below

You'll find nearly 100 pages of medical motion picture titles and descriptions in this new catalog—well over 300 titles and many of them brand new! All are available on loan basis for a slight service charge.

American Medical Association
535 N. Dearborn St.
Chicago, Ill. 60610
ATTN: Dept. of Audio Visual
Self Learning Programs.

S/J

Please send me your catalog:
AMA Medical Health Film Library 1976

Name _____
Title _____
Organization _____
Address _____
City _____
State/Zip _____

SUNDOWN PASSED THE TOUGHEST WATER RESISTANCE TEST EVER GIVEN A SUNSCREEN.

After an hour of swimming
In both fresh and salt water
And 3 hours of sunbathing
At the hottest time of the day
In both dry and humid climates
SUNDOWN still gave significant sunscreen protection*

By making this a tough test, we demonstrated conclusively that SUNDOWN resists water wash-off to provide significant protection for your sun-sensitive patients.
SUNDOWN has other reasons for recommendation: ▫ Only one active ingredient, 3.3% Padimate O (octyl dimethyl PABA), with low sensitization potential ▫ Screens out 99.6% of erythemal radiation under laboratory conditions ▫ Non-drying to the skin — with a low alcohol content of only 8.6% ▫ Polymer-containing base dries quickly to an invisible water-resistant film ▫ Won't stain unless applied directly to clothing ▫ Compatible with Retin-A Brand tretinoin therapy ▫ Easily removed with soap and water.

Contains: octyl dimethyl PABA (Padimate O), alcohol 8.6%, water, ammonium acrylate/acrylate copolymer, isopropyl myristate, benzyl alcohol, ammonium isostearate, stearyl alcohol, fragrance, xanthan gum and carbomer 961.

*Tested in Bradenton, Florida, 90° temperature, very high humidity; in Phoenix, Arizona, 100° temperature, 5% humidity; in Holmes Beach, Florida, 85° temperature, 68% humidity — winds 20 mph. Data on file, Johnson & Johnson.
Based on available published data on file at Johnson & Johnson.

Johnson & Johnson
New Brunswick, New Jersey 08903

Johnson & Johnson
SUNDOWN BRAND
HIGHLY PROTECTIVE SUNSCREEN

PROTECTION THAT DOESN'T STOP AT THE WATER'S EDGE

Admit it, most women will never give up their cosmetics.

Your patient's cosmetics should care as much about her skin as you do. Because you'll never convince most women not to wear makeup. Allercreme does care. That's why we go to such great lengths to make sure our hypo-allergenic cosmetics and skin care products are as safe and pure as we can make them.

We analyze everything.

We will never use a known irritant in any of our products. In fact, we don't take any ingredient for granted. Even those considered to be tried and proven.

Our cosmetic chemists and medical staff review every single ingredient in all Allercreme products for safety and purity. And before we market any new product, we test it on human skin for irritation and sensitivity potential. If there is the least hint of irritation or sensitization, the product will never leave our laboratories.

We come to you.

You never have to go out of your way to see us. We call on dermatologists and other interested physicians in person to answer any questions, supply you with formulas, research, technical information and samples of Allercreme products.

If any of your patients ever has the slightest indication of sensitivity to any of our products, we will provide patch test kits; we'll work directly with you to identify the offending ingredient and recommend substitute products free of it.

We show we care.

You can be sure that any product with the Allercreme name on the label will always care as much about your patients' skin as you do. Because Allercreme will constantly be researching new hypo-allergenic cosmetics and skin care products that can live up to our high standards for purity, fashion and performance. And that's a promise.

HYPO-ALLERGENIC
Allercreme®

We care about your patients' skin.

Announcing: Improved Formula Super Shade 15

The highest degree of sunburn protection available for sun-sensitive patients.

SUPER SHADE 15 VS 5% PABA

Hairless Mouse Skin 2μl/cm² SUNSCREEN

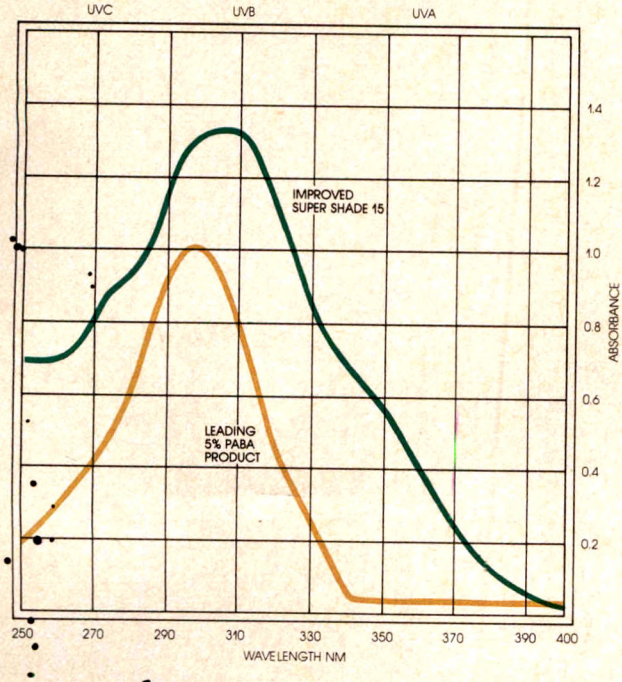

The Food and Drug Administration's Advisory Panel on sunscreens has indicated that sunscreen products with a Sun Protection Factor of 15 provide the highest degree of sunburn protection available for highly sun-sensitive skin.

Improved SUPER SHADE 15 with Padimate O and Oxybenzone is superior to the leading 5% PABA product.

- Provides higher sunburn protection than 5% PABA. Super Shade 15 allows your patient to stay in the sun 15 times longer than with no protection.
- Protects more effectively in both the sunburn range (UVB) and the important drug photosensitivity range (UVA) of ultraviolet light.
- Provides greater protection after swimming than 5% PABA products...more resistant to wash-off by water and perspiration.
- Is virtually non-staining and contains no drying alcohol—unlike PABA products.

Liberal and regular use of SUPER SHADE 15 may help reduce chances of skin cancer due to long-term overexposure to the sun.

Patients who require ultra protection will appreciate your recommendation of Super Shade 15.

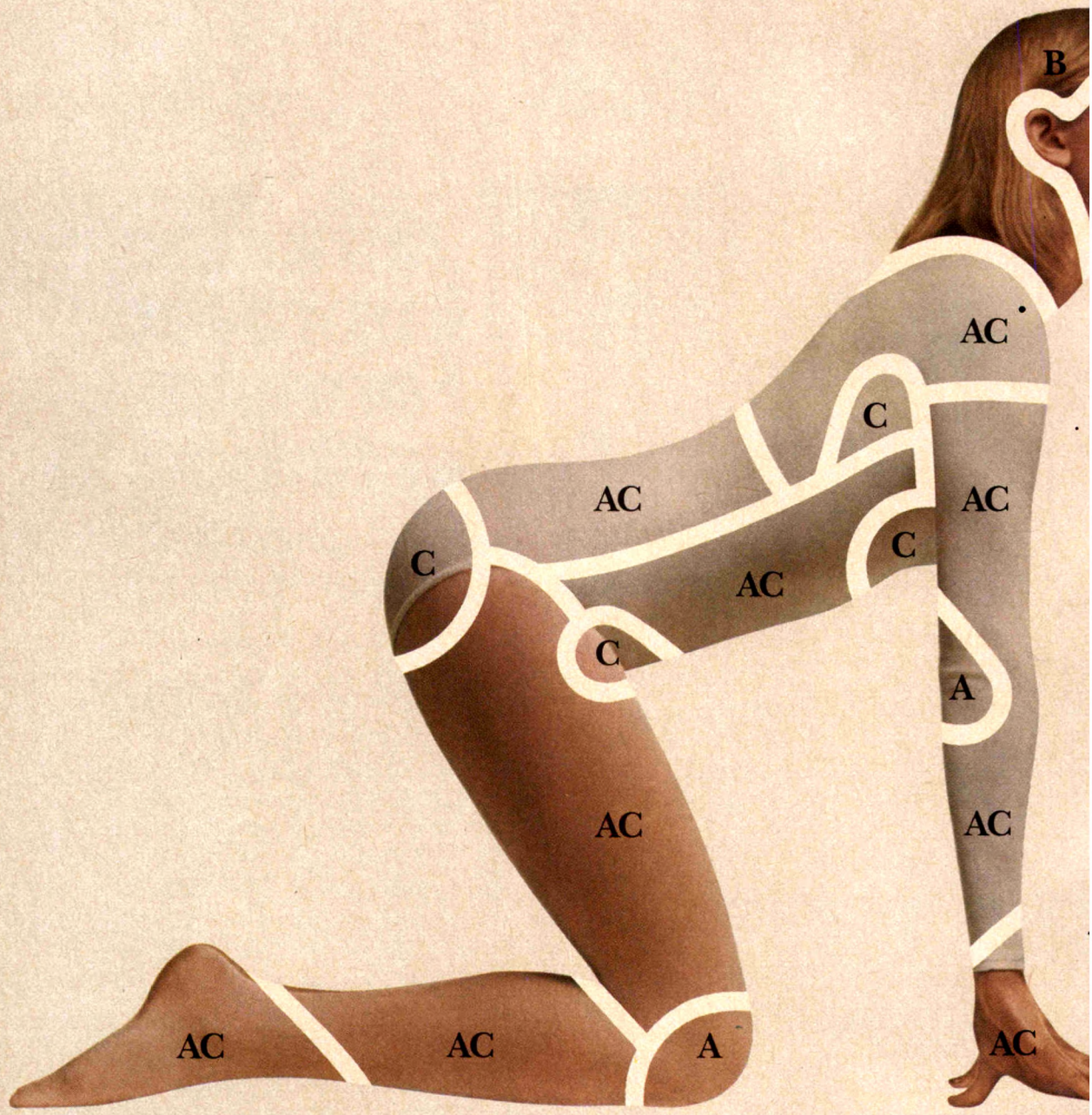

FOR THE

ZONES OF DERMATOSI

For dry areas/lesions

A New **Halog® Ointment 0.1%**

Halcinonide Ointment 0.1%

For scalp lesions

B New **Halog® Solution 0.1%**

Halcinonide Solution 0.1%

For moist areas/lesions

Full-strength

C **Halog® Cream 0.1%**

Halcinonide Cream 0.1%

'Maintenance formula'

Quarter-strength

New **Halog® Cream 0.025%**

Halcinonide Cream 0.025%

Clinical experience

A total of 984 psoriatic patients in US clinical studies were treated with either the Solution, the Creams, or the Ointment. After 2 weeks' therapy,* 151 (78%) of 194 patients improved with Halog Solution, 407 (92.5%) of 440 patients improved with full-strength (0.1%) Halog Cream, 132 (72%) of 184 patients improved with quarter-strength (0.025%) Halog Cream, and 145 (87%) of 166 patients improved with Halog Ointment.

In general, the preferred topical formulations for lesions in specific areas are: solutions for scalp lesions, creams for moist areas/lesions, and ointments for dry areas/lesions. The studies cited above, however, were not limited to lesions in these specific areas.

*Majority of patients evaluated after 2 weeks' therapy. Data on file at Squibb Institute for Medical Research.

See next page for brief summary.

©1977 E.R. Squibb & Sons, Inc. 357-508

HALOG®

HALCINONIDE

SQUIBB®

HALOG® (Halcinonide)
Cream/Ointment/Solution
Halog Cream 0.025% (Halcinonide Cream 0.025%) and Halog Cream 0.1% (Halcinonide Cream 0.1%) contain 0.25 mg. and 1 mg. halcinonide per gram, respectively, in a specially formulated cream base. Halog Ointment (Halcinonide Ointment 0.1%) contains 1 mg. halcinonide (0.1%) per gram in Plastibase® (Plasticized Hydrocarbon Gel), a polyethylene and mineral oil gel base. Halog Solution (Halcinonide Solution 0.1%) contains 1 mg. halcinonide (0.1%) per ml.
CONTRAINDICATIONS: Topical steroids are contraindicated in vaccinia, varicella, and in those patients with a history of hypersensitivity to any of the components of the preparations. These preparations are not for ophthalmic use.
PRECAUTIONS: *General*—If local infection exists, suitable concomitant antimicrobial or antifungal therapy should be administered. If a favorable response does not occur promptly, application of the corticosteroid should be discontinued until the infection is adequately controlled. If extensive areas are treated or if the occlusive technique is used, the possibility exists of increased systemic absorption of the corticosteroid and suitable precautions should be taken. If irritation or sensitization develops, the preparation should be discontinued and appropriate therapy instituted. Although topical steroids have not been reported to have an adverse effect on pregnancy, the safety of their use during pregnancy has not been absolutely established; therefore, they should not be used extensively on pregnant patients, in large amounts, or for prolonged periods of time.
Occlusive Dressing Technique—The use of occlusive dressing increases the percutaneous absorption of corticosteroids; their extensive use increases the possibility of systemic effects. For patients with extensive lesions it may be preferable to use a sequential approach, occluding one portion of the body at a time. The patient should be kept under close observation if treated with the occlusive technique over large areas and over a considerable period of time. Occasionally, a patient who has been on prolonged therapy, especially occlusive therapy, may develop symptoms of steroid withdrawal when the medication is stopped. Thermal homeostasis may be impaired if large areas of the body are covered. Use of the occlusive dressing should be discontinued if elevation of the body temperature occurs. Occasionally, a patient may develop a sensitivity reaction to a particular occlusive dressing material or adhesive and a substitute material may be necessary. If infection develops, discontinue the use of the occlusive dressing and institute appropriate antimicrobial therapy.
ADVERSE REACTIONS: The following local adverse reactions have been reported with topical corticosteroids: burning, itching, irritation, striae, skin atrophy, secondary infection, dryness, folliculitis, hypertrichosis, acneform eruptions, and hypopigmentation. The following may occur more frequently with occlusive dressings: maceration of the skin, secondary infection, skin atrophy, striae, and miliaria. Contact sensitivity to a particular dressing material or adhesive may occur occasionally (see PRECAUTIONS).
For full prescribing information, consult package insert.
HOW SUPPLIED: The 0.025% and 0.1% Cream and the 0.1% Ointment are supplied in tubes of 15 g. and 60 g., and in jars of 240 g. (8 oz.). The 0.1% Solution is supplied in plastic squeeze bottles of 20 ml. and 60 ml.

SQUIBB®

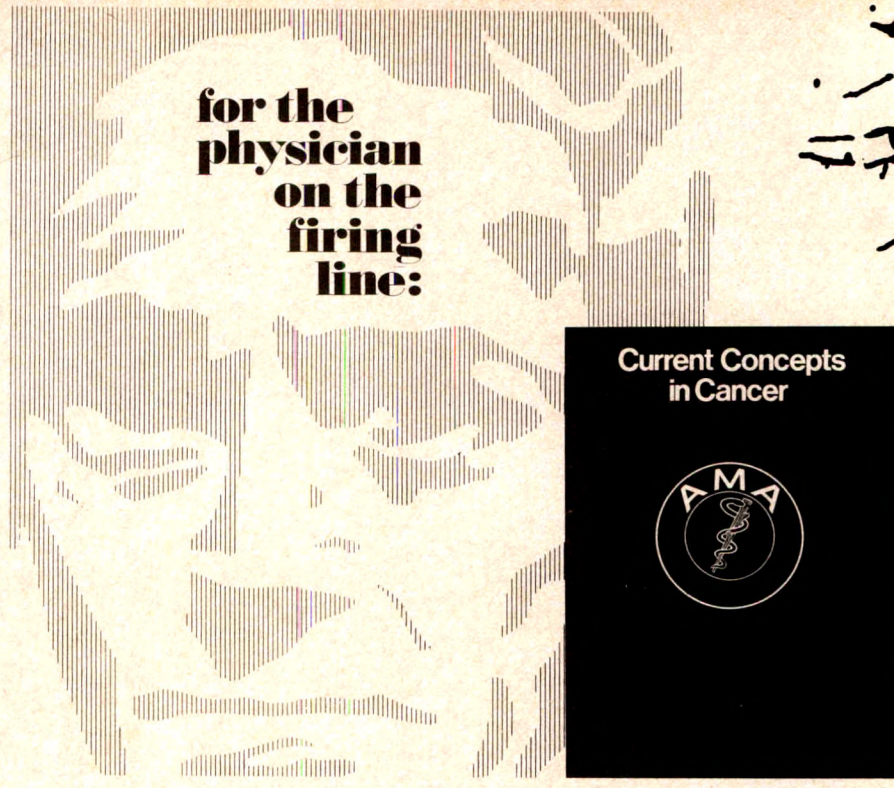

A valuable guide to diagnostic and therapeutic procedures for the cancer patient

Current Concepts in Cancer

While national attention focuses on cancer through specialized cancer centers, physicians are aware that the majority of cancer patients are treated in office practices. For most practicing physicians, cancer treatment is not a research objective, but a very practical problem in patient management.

Current Concepts in Cancer, a compilation of articles originally published in the *Journal of the American Medical Association,* is designed to be a guide for the practitioner in the choice of diagnostic and therapeutic procedures for many types of malignancies. It presents an objective interdisciplinary view by MDs outstanding in their respective fields, emphasizing principles of diagnosis and surgical, radiotherapeutic, and chemotherapeutic treatment.

Make this important resource a part of your reference file. Order your copy today.

American Medical Association
535 North Dearborn Street
Chicago, Illinois 60610

S/J

Please send me _____ copy(ies) of **Current Concepts in Cancer** (OP-281). Price is $10 per copy. Please enclose your remittance with order.

Please Print

Name _____

Address _____

City _____ State _____ Zip _____

The good news. The bad news.

American Medical News reports all the news you need to know!

Some of the news about medicine these days is pretty encouraging; some of it is frankly discouraging.

American Medical News prints both kinds of news—good and bad— because you need to know about those developments that could affect the way you practice medicine.

If you want to read just good news and praises of the profession, *American Medical News* isn't your kind of paper. It is a professional newspaper, not a house organ. The AMA Board of Trustees has ordered it to operate that way. That means that *American Medical News* prints both sides of a controversy; it prints what other people say about doctors; it asks discomforting questions; it prints a vast array of stimulating opinions from readers.

Give *American Medical News* just 30 minutes a week; it will give you all the news you need to know about what's happening in the practice of medicine.

Keeping your finger on the pulse of medicine

American Medical **NEWS**

An Informed Membership Is Our Greatest Strength

JANUARY 30, 1978

Carter's '79 budget: More aid for children, less money for schools

President Carter's budget for 1979 contains big increases in funding for child health, and Medicare and Medicaid programs, with substantial cuts in capitation grants for medical education. The increase in the total funding of the National Institutes of Health has been limited to 1.5%, which will not keep up with the rate of inflation in 1979, expected to be approximately 6%.

The Carter budget proposed for fiscal year 1979 (Oct. 1, 1978 to Sept. 30, 1979) contains these proposals:

- A $118-million increase in Medicaid for low-income pregnant women to provide pre-natal care and related ser-
- ...ded child health assess-
- ...million. The
- for health services for adolescents, with emphasis on prevention of unwanted pregnancy.
- A $34-million increase in funding for professional standards review organizations.

PSRO funding at $174 million for 1979 will be sufficient to blanket the country and review all Medicaid, Medicare, and child health procedures, HEW officials say. Instead, greater use of sampling techniques will allow the program to pick target areas, for review. Surgery will likely be the first target.

- A one-third reduction in capitation assistance to medical, osteopathic, and dental schools. Schools of public health will be funded at the 1978 level. Support for most nursing programs will end. HEW officials say the net effect will be
- ...medical school tuition and fun-
- ...the national health service corps and related scholarship programs.

The biggest money item in the health budget is Medicare and Medicaid, which together make up 23% of HEW's budget. This is a significant rise from 1973 when the two programs made up 18% of HEW's budget. Medicare hospital insurance payments will rise 15.3% in 1979 and Medicaid payments to physicians (not including the new programs in child health) will rise about 11%.

The Office of Management and Budget anticipates total outlays for these two programs to be $41.5 billion in 1979, if the Administration's hospital cost containment legislation is enacted by July 1.

"If these proposals are not enacted, the 1979 estimate will be $1.1 billion higher," say Health Care Financing Administration officials.

A modest increase was proposed in funding for health maintenance organizations. HEW proposed $5.3 million for 70 new HMO feasibility grants. HEW wants 172 HMOs operating by 1982, and anticipates there will be 5 million people enrolled in these plans by that time.

Funding for health planning agencies will basically keep pace with inflation. A $9-million increase will bring the planning budget to $152 million.

No major changes in the level of health services in the Veterans Administration were proposed. The VA's health budget will increase about 7% to cope with inflation.

Funds for clinical research in 1979 will be tighter. NIH's budget has leveled off and is shrinking slightly due to inflation. The only exception to this is the National Institute of Child Health and

(See Budget . . . , p. 13)

...trikes a possibility
...hospitals

Cleansing & Moisturizing

New Keri Facial Cleanser is formulated to slow moisture loss from the skin, emulsify oil, and remove dirt and debris as it leaves skin softer and smoother.

Cleansing without drying is a Keri tradition.

Patients who routinely use Alpha Keri® Bath Oil and Alpha Keri® Soap should welcome this new addition to the fine line of Keri skin care products.

New Keri® Facial Cleanser

In 4 oz. plastic bottles. Promoted to physicians only.

WESTWOOD
PHARMACEUTICALS INC.
Buffalo, New York 14213

© 1977 W.P. Inc.

Prognostic Index in Malignant Melanoma

Christian Schmoeckel, MD, Otto Braun-Falco, MD

• A retrospective study was undertaken of 146 surgically treated subjects with primary cutaneous melanoma of which 73 were disease-free for five to nine years and 73 developed later metastases. A prognostic factor was sought to determine patients with poor prognoses. The best overall method was shown to be the evaluation of the prognostic index defined as the product of tumor thickness and the number of mitoses per square millimeter. However, for establishing a group of patients with no incidence of metastases, the mitotic rate proved to be as good a factor as the prognostic index and better than tumor thickness or levels of invasion. The application of this prognostic index seems therefore to be useful in selecting for further treatment stage I melanoma patients with poor prognoses, eg, prophylactic lymph node dissection and immunochemotherapy.

(*Arch Dermatol* 114:871-873, 1978)

The five-year survival rate of patients with primary cutaneous malignant melanoma (MM) is particularly low as compared with other malignant neoplasms. It has been estimated at 58% for patients with no clinically suspect lymph nodes (stage I) and at 26% for patients with lymph node metastases (stage II).[1] An improvement of survival rates may be accomplished through further therapeutic procedures as follows in addition to the wide excision of the tumor: immunotherapy with bacillus Calmette-Guerin (BCG) vaccine,[2] immunochemotherapy with dimethyltriazeno imidazole DTIC and BCG vaccine,[3] and prophylactic lymph node dissection.[1,4-6] For obvious reasons, these measures should be restricted to patients with poor prognoses.

Many attempts have been made to determine the prognosis in primary cutaneous MM. It has been shown that several factors influence the clinical course of MM, such as sex,[6-8] site,[6-8] type of MM,[9] degree of cellular anaplasia,[10] and inflammatory reaction.[5,8,10,11] These factors have a statistical meaning only and cannot serve as guidelines in determining the prognosis for a given patient. The size of the tumor and its mitotic rate appear to be important as prognostic indicators. The size can be estimated through the level of invasion[9] or through direct measurement of the tumor thickness.[1,4-6,12] The mitotic rate varies considerably, and a correlation with mortality has been reported by several authors[13-17] but not confirmed by others.[8] Such factors as tumor cell types, epidermal changes, and structural aspects did not seem to have any bearing.[18]

In order to determine which patients with MM are likely to develop later metastases, an indicator is necessary that is both easy to use clinically and has a low rate of false negative and false positive results. As it was the purpose of this study to define such an indicator, an attempt was made to combine important criteria, especially tumor thickness and mitotic rates. The product of the two is considered the prognostic index.

MATERIAL AND METHODS

The 146 patients chosen had cutaneous primary MM and had been seen in the Dermatology Department, University of Munich, from 1967 to 1975. None had undergone previous biopsies nor x-ray treatment, and their histological slides were available. Treatment consisted of wide surgical excision of the malignant neoplasm; no immunochemotherapy or prophylactic lymph node dissections were performed. The first group included 73 patients (50 women and 23 men) who were free of metastases for a period of five or more years. The second group included 73 patients (40 women and 33 men) having entered stages II to III later on (up to seven years). The primary tumors were located both on the extremities (84 cases) and on the trunk and head (62 cases). An analysis according to site and sex is shown in the Table. Since 1971, a minor change of therapy was introduced consisting of a wider standardized excision (5 cm surface clearance and extending down to the fascia). In all microscopic slides the following determinations were made:

1. **Type.**—The type of MM, ie, lentigo MM, superficial spreading melanoma, and nodular melanoma, was determined according to the criteria of Clark et al.[9]
2. **Invasive Level.**—The level of invasion

Analysis of 146 Cases of Primary Cutaneous Malignant Melanoma

	No.	% of Metastatic Cases
Women*		
Extremities	60	43
Head and trunk	30	47
Total	**90**	44
Men*		
Extremities	24	50
Head and trunk	32	66
Total	**46**	59
Extremities	84	45
Head and trunk	62	56

*Ratio of women to men is 2:1. A slightly poorer prognosis for men was noted.

• Accepted for publication Nov 28, 1977.
• From the Department of Dermatology, University of Munich.
• Reprint requests to Department of Dermatology, University of Munich, Frauenlobstrasse 9, 8 Munich 2, West Germany (Dr Schmoeckel).

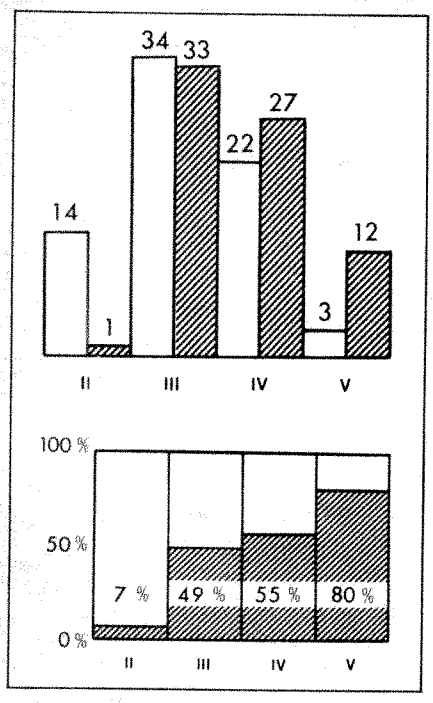

Fig 1.—Invasion levels in 146 cases of primary cutaneous malignant melanoma. White areas indicate cases without later metastases; shaded areas, cases with later metastases. Top, Absolute figures; bottom, percentages of metastatic cases.

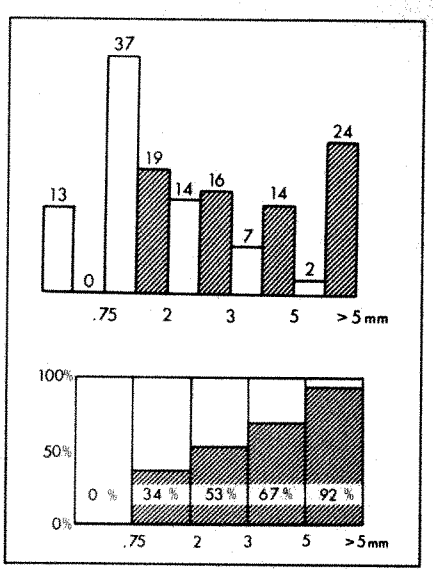

Fig 2.—Tumor thickness in 146 cases of primary cutaneous malignant melanoma. White areas indicate cases without later metastases; shaded areas, cases with later metastases. Top, Absolute figures; bottom, percentages of metastatic cases.

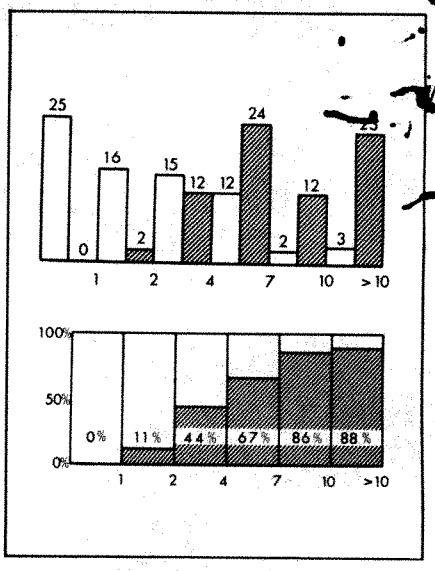

Fig 3.—Mitotic rates (number of mitoses) per square millimeter in 146 cases of primary cutaneous malignant melanoma. White areas indicate cases without later metastases; shaded areas, cases with later metastases. Top, Absolute figures; bottom, percentages of metastatic cases.

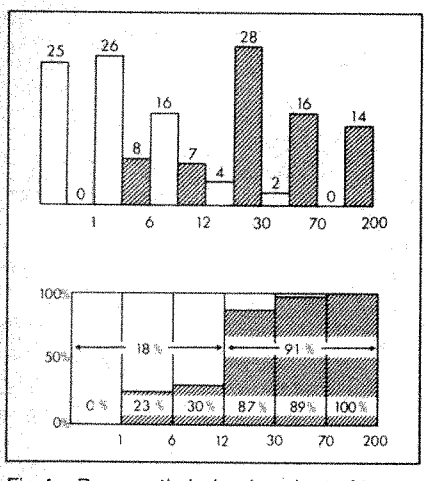

Fig 4.—Prognostic index (product of tumor thickness and mitotic rate, varying between 0 and 200) in 146 cases of primary cutaneous malignant melanoma. White areas indicate cases without later metastases; shaded areas, cases with later metastases. Top, Absolute figures; bottom, percentages of metastatic cases.

was determined according to Clark et al.[8]

3. **Intensity of Cellular Inflammatory Reaction.**—This was graded 0 when absent, 1 when very low, 2 when low, 3 when medium, and 4 when strong.

4. **Tumor Thickness.**—The highest vertical diameter of any section was selected and determined in millimeters by measuring the distance between the uppermost and lowest tumor cells. This definition was thought to be biologically more correct than the slightly different definition given by Breslow,[4] who measured from the top of the granular cell layer to the deepest point of invasion.

5. **Mitotic Rate.**—In at least 1.5 sq mm (using high power fields), the mitoses were counted and converted to 1.0 sq mm. The area of a high-power field was determined through πr^2. Necrotic areas were omitted, and areas with higher mitotic rates as seen with lower magnifications were used. In well-pigmented tumors it was generally possible to find areas with less melanization, but one patient had to be excluded from this study for that very reason. In small tumors, several sections were evaluated in order to reach at least 1.5 sq mm.

6. **The Prognostic Index.**—This was defined as the product of the tumor thickness and the mitotic rate.

7. **Qualitative Comparison.**—In order to compare the indicators qualitatively, two groups were established for each method—one with good prognoses, another with poor prognoses. The sum of false-negative cases (x) in the first group and of false-positive cases (y) in the second group was then considered as a percentage of the total sum (S) of MM patients ($x + y/S \times 100$).

RESULTS

Histologic Typing

In 146 cases, there were 9 lentigo MMs (none of which had metastases), 78 superficial spreading melanomas (38 with a metastatic development), and 59 nodular melanomas (35 with subsequent metastases).

Levels of Invasion

The results are shown in Fig 1. In the independent Student's t .test, t equaled 3.8316 and P was lower than 0.0005. The percentage of false-negative and false-positive cases determined as described above was 40%.

Intensity of the Cellular Inflammatory Reaction

The average intensity of the cellular infiltrate evaluated measured 2.4 for patients free of the disease for five or more years and 2.5 for patients with subsequent metastases; there is no statistically noticeable difference.

Tumor Thickness

The results are shown in Fig 2. In the independent Student's t test, t equaled 6.1581 and P was lower than 0.0005. The percentage of false-negative and false-positive cases was 29%.

Mitotic Rate

The results are listed in Fig 3. In the independent Student's t test, t equaled 7.1645 and P was lower than 0.0005. The percentage of false-negative and false-positive cases was 21%.

Prognostic Index

The results are listed in Fig 4. In the independent Student's t test, t equaled 7.007 and P was lower than 0.0005. The percentage of false negative and false positive results was 14%. The range from 0 to 6.0 is considered to be of low risk (13%), and the inter-

mediate range from 6.1 to 12.0 of a higher risk (30%) of development of metastases. For these combined ranges there is a risk of 18%. For indexes greater than 12.0, a very high risk of metastasis (91%) is noted.

COMMENT

Prophylactic lymph node dissection and immunochemotherapy with dimethyltriazeno imidazole and bacillus Calmette-Guerin may improve survival rates of melanoma patients.[1-6] Therefore, objective criteria are necessary to select stage I patients with poor prognoses to whom these prophylactic treatments should be applied. Site and sex proved to have a statistical bearing only (Table), and the intensity of the cellular inflammatory infiltrate was insignificant. The only useful measurements were levels of invasion, tumor thickness, mitotic rates, and the prognostic index. If it were decided to treat patients with levels III, IV, and V, as mentioned above, the number of false positive cases in this group would be high, ie, cases without metastases that would not require further treatment. By restricting this group to levels IV and V, the number of false positive cases would be smaller, but the number of false negative cases for levels II and III would increase. Confirming previous reports,[4,5] the direct measurement of tumor thickness results in a better prognosis because the sum of false negative and false positive cases (the dividing line being drawn at 2.0 mm) was lower (29% in this study) than for levels of invasion (40%). It was even better (21%) for the mitotic rate (separation at 4.0 mitoses/sq mm) and best (14%) for the prognostic index (separation at 12.0). The *prognostic index* was defined as the product of tumor thickness (in millimeters) and the mitotic rate (number of mitoses per square millimeter). Its determination can be made easily (within three to five minutes) so that clinical application is simple, and it seems to yield better results that the method proposed by Cochran,[19] even though no differentiation was made as to type or site of the primary tumor. The situation is slightly different when withholding prophylactic treatment from an MM patient who would actually need it, which is considered a grave and important shortcoming; treating patients unnecessarily would be more easily tolerated. Based on the results of this study, the prognostic index does not seem to be superior to the mitotic rate. For a mitotic rate lower than 1.1/sq mm, there were no cases of metastases similar to the prognostic index lower than 1.1, but in this respect the mitotic rate seems to be a better measurement than tumor thickness or levels of invasion because the number of patients included is higher.

Special attention was given to accounting for false positive and false negative results. A high prognostic index may be due to an underlying nevus, which causes a greater vertical diameter. It is also conceivable that in some instances micrometastases might have been destroyed through immunological factors, or might not have developed at all. In some cases the possibility of metastases still to develop cannot be excluded, since a five-year survival is not sufficient in MM to consider a patient cured.[20] False-negative results, on the other hand, often are probably due to technical problems, such as histological slides not showing the characteristic sections of the center of the tumor, or to their failure to contain suspected nodes that may have developed in the tumor. In most of these cases, the discrepancy between the clinically described size and elevation of the primary melanoma and its measurements on the slide was obvious.

There are few technical problems involved with determining the mitotic rate once the radius of a high power field of the microscope is known and if a calculator is at hand. Pyknotic nuclei and polymorphonuclear leukocytes can easily be distinguished from mitoses. Of course, the mitotic rate would be more exact if more than 1.5 sq mm were evaluated. Basically, it is probably sufficient to establish a low, medium, or high rate. The reason, however, for calculating the number of mitoses per square millimeter is twofold: the results will be less subjective, and they can be used to determine the prognostic index.

Helmut Bockelbrink, MS, and Anton Wunder, MS, Institute of Statistics (Technical University, Munich) gave assistance in statistical interpretation.

References

1. Tonak J, Hermanek P, Hornstein OP, et al: Therapie des malignen Melanoms der klinischen Stadien I und II. *Dtsch Med Wochenschr* 101:435-440, 1976.
2. Eilber FR, Morton DL, Holmes EC, et al: Adjuvant immunotherapy with BCG in treatment of regional lymph node metastases from malignant melanoma. *N Engl J Med* 294:237-240, 1976.
3. Gutterman JU, Mavlight G, Gottlieb JA, et al: Chemoimmunotherapy of disseminated malignant melanoma with dimethyl triazeno imidazole carboxamide and Bacillus Calmette-Guerin. *N Engl J Med* 291:592-597, 1974.
4. Breslow A: Tumor thickness, level of invasion and node dissection in stage I cutaneous melanoma. *Ann Surg* 182:572-575, 1975.
5. Wanebo HJ, Woodruff J, Fortner JG: Malignant melanoma of the extremities: A clinicopathologic study using levels of invasion (microstage). *Cancer* 35:666-676, 1975.
6. Weidner F, Hornstein OP, Hermanek P, et al: Early metastases in regional lymph nodes and prognosis of malignant melanoma: Histological and clinical examinations in 104 lymphadenectomized patients. *Arch Derm Res* 256:167-177, 1976.
7. Cochran AJ: Malignant melanoma: A review of ten years' experience in Glasgow, Scotland. *Cancer* 23:1190-1199, 1969.
8. Huvos AG, Shah JP, Miké V: Prognostic factors in cutaneous malignant melanoma: A comparative study of long term and short term survivors. *Hum Pathol* 5:347-357, 1974.
9. Clark WH Jr, From L, Bernardino EA, et al: The histogenesis and biologic behavior of primary human malignant melanomas of the skin. *Cancer Res* 29:705-726, 1969.
10. Gartmann H, Tritsch H: Bedeutung feingeweblicher Befunde für die Prognose des malignen Melanoms. *Dtsch Med Wochenschr* 97:857-859, 1972.
11. Kokoschka EM, Niebauer G: Zur histologischen Prognosestellung beim primären Melanom. *Wien Klin Wochenschr* 88:685-689, 1976.
12. Klostermann GF, Heite HJ: Das Tiefenwachstum des Melanoms in Relation zur Prognose. *Arch Derm Res* 244:214-217, 1972.
13. Cochran AJ: Histology and prognosis in malignant melanoma. *J Pathol* 97:459-468, 1969.
14. Williams WJ, Davies K, Jones WM, et al: Malignant melanoma of the skin: Prognostic value of histology in 89 cases. *Br J Cancer* 22:452-460, 1968.
15. Jourdain JC: Etude de critères cliniques et histologiques du prognostic des mélanomes malins primaires. *Ann Dermatol Syphiligr* (Paris) 101:171-178, 1974.
16. Little JH: Histology and prognosis in cutaneous malignant melanomas, in McCarthy WH (ed): *Melanoma and Skin Cancer*. Sydney, Australia VCN Blight, Government Printer, 1972, pp 107-119.
17. McGovern VJ: Melanoma: Growth patterns, multiplicity and regression, in McCarthy WH (ed): *Melanoma and Skin Cancer*. Sydney, Australia, VCN Blight, Government Printer, 1972, pp 95-106.
18. Christophers E, Braun-Falco O: Melanomalignom: Feingewebliche Untersuchungen und Prognose. *Arch Derm Res* 244:217-220, 1972.
19. Cochran AJ: Method of assessing prognosis in patients with malignant melanoma. *Lancet* 2:1062-1064, 1968.
20. Shah JP, Goldsmith HS: Prognosis of malignant melanomas in relation to clinical presentation. *Am J Surg* 123:286-288, 1972.

Psoriasis in an Unselected Series of Twins

Flemming Brandrup, MD; Mogens Hauge, MD; Klavs Henningsen, MD; Birthe Eriksen, MD

• The relative importance of genetic factors in the origin, age at onset, clinical type, course, and severity of psoriasis was evaluated on the basis of an unbiased sample of twins, ie, the Danish Twin Register, which covers the total population of twins born in Denmark. All verified and probable cases of psoriasis in twins, born 1891 through 1920, were ascertained. Results are presented of an examination of all members of index pairs in which both partners were alive on a certain date. Fourteen monozygotic and 22 dizygotic, like-sexed pairs were found to include at least one partner with unquestionable psoriasis. Zygosity determination was mainly based on extensive serological examinations. The analyses show that the manifestation of psoriasis depends almost exclusively on the presence of the specific genotype. The age at onset, clinical type, course, and severity are also mainly determined by the genetic constitution. Association with certain HLA antigens of the B series has been confirmed, but the fact that many of the twins (including several of the concordant monozygotic pairs) possess neither of these antigens shows the corresponding genes to be important, but not decisive, elements in the predisposition. We conclude that psoriasis is a genetically determined disorder that may, to a limited extent, be modified by environmental influences.

(*Arch Dermatol* 114:874-878, 1978)

Although psoriasis is one of the most common, chronic skin affections, its origin cannot yet be considered fully substantiated in spite of numerous attempts to provide the epidemiological, family, and twin data required for more penetrating and complete etiological analyses. Epidemiological studies provide the age-specific incidence and prevalence rates without which valid comparisons between and within populations cannot be made. Accumulation of cases within families of patients may suggest a hereditary background and possible modes of inheritance; however, when no simple, single gene model seems acceptable, twin analyses of the classical type form the tool that show whether common environment, common genetic factors, or both, cause the accumulation observed.

In Scandinavia, extensive population surveys have been made in the Faroe Islands and in Sweden. In the Faroe Islands, Lomholt[1] performed a complete census of all households in a delimited region, including about one third of the total Faroese population. The over-all prevalence of psoriasis in these persons was 2.8% with no sex difference. In Sweden, a sample of about 40,000 persons from various counties was interrogated by Hellgren[2] during a free, general health examination; Hellgren questioned the patients with regard to skin affections in general and psoriasis in particular. The prevalence of psoriasis among these persons was around 2% in the south and slightly higher in the north. A small random sample of Danes (about 4,000) was screened by Schwartz,[3] mainly by means of questionnaires; this sample showed a prevalence of psoriasis of 1.7%.

The number of family investigations published is high, but only a few fulfill the strict conditions for detailed and advanced analysis. One of the latest comprehensive studies of this type was performed by Watson et al,[4] who found it possible to exclude all simple, monogenic types of inheritance; these authors concluded that a multifactorial origin was more likely. Watson et al asked for "analyses of collections of less biased information from twin registries" to complete the picture. Recent, more refined, statistical methods have been applied to two earlier, very detailed reports of family studies made by Lomholt[1] and Hellgren[2]; the results[5,6] provided no strong arguments against the conclusion reached by Watson et al.[4] The polygenic hypothesis was already found most probable by Lomholt, but the mathematics of this model and the special statistical tests had not been worked out at the time he completed his analyses.

Twin studies based on cases ascer-

Accepted for publication Jan 24, 1978.

From the Department of Dermatology (Dr Brandrup), Odense University Hospital, Denmark; the University Institute of Clinical Genetics (Dr Hauge), Odense; and the Blood Group Department (Drs Henningsen and Eriksen), the University Institute of Forensic Medicine, Copenhagen.

Reprint requests to Department of Dermatology, Odense University Hospital, DK-5000 Odense, Denmark (Dr Brandrup).

tained in an unselected series of twins have not yet been published to our knowledge. This was emphasized by Farber et al[7] who reported their own twin sample, which is the largest ever collected. Farber and co-workers described the biases inherent in their sampling and stressed again that results from twin registers were urgently wanted. However, one could justifiably conclude from their study that genetic factors do contribute to the development of psoriasis; on the other hand, valid estimates of the relative importance of these factors or of heritability cannot be obtained from selected series or collections of case reports, because this approach almost invariably leads to an overrepresentation of monozygotic and concordant pairs.

Quite recently, contributions to the elucidation of the origin of psoriasis have come from new sources. A strong association between some HLA antigens and psoriasis vulgaris has been demonstrated,[8] supporting the assumption that more genes are involved in the predisposition to this disease; but etiological heterogeneity was also suggested in these studies. Less convincing evidence has been produced in favor of associations between some red cell and serum protein types and psoriasis.[9-11]

We herein attempt to meet the appeal for information from unbiased samples of twins with psoriasis. The material has been drawn from a nationwide register covering the total population of twins born in Denmark within a defined period.

SUBJECTS AND METHODS

The Danish Twin Register has been the source of the subjects for the present investigation. This Register intends to follow the total population of twins, born since 1870, from birth and throughout their lives, and to collect all relevant information on their morbidity and mortality.

The construction of the Register has been described in detail previously.[12] The collection of data is greatly facilitated by the existence of a national registration system, by full cooperation of all doctors and hospitals, and by the very positive attitude of the twins and their families; less than 2% of those registered refused cooperation. The primary approach of the Register to the twins is by a mailed questionnaire, but relevant medical data are verified and supplemented by information from such sources as hospitals and practitioners.

Since 1966, a question on the presence/absence of psoriasis has been included in the initial questionnaires sent to twins who were alive when traced, and also in the follow-up questionnaires that are distributed at intervals to all twins as long as they are alive.

For the present study, all twins in the Register who, before March 1, 1975, in their reply to a questionnaire had indicated presence of psoriasis were chosen. The investigation that is reported here concerns only same-sexed pairs born in the period 1891 through 1920, with both partners still living at the time of examination.

A total of 49 twins, belonging to 43 pairs, fulfilled the criteria given above. The attempt was made to visit all 86 individuals in their homes. No proband refused to accept the examiner (F.B.), but two of the partners would only permit an interview by telephone. A full medical history was obtained. If psoriasis was or had been present, the age at onset, morphology, distribution, course, and precipitating factors, if any, were recorded. A clinical examination was performed, and information was collected on psoriasis in all first-degree relatives. A blood sample was taken for the determination of zygosity and for a chromosomal analysis. One or both partners from four sets of twins refused a venipuncture. In some instances, HLA typing proved unsuccessful because the samples arrived in the laboratory in an unsatisfactory condition. All twins were seen within a period of ten months.

Clinical Diagnosis

The final clinical diagnosis was established according to the following criteria: if sharply demarcated, infiltrated, red, papular elements with characteristic scales, or eventually, a Bulkley membrane and Auspitz-sign were found at the examination, this was taken as evidence of psoriasis. If the skin was clear at the actual examination, the diagnosis had to be based on anamnestic data. If the twin had been seen by a doctor, inquiries were made about his or her diagnosis; in most cases, psoriasis had been verified by a dermatologist who had been consulted during previous attacks. If nothing but the scalp was involved, the lesions had to be typical before the diagnosis of psoriasis was accepted. Inverse psoriasis was only considered as fulfilling the present criteria if psoriatic lesions had been observed previously on sites of predilection or if the condition had been diagnosed by a dermatologist.

The condition of twins with pustular eruptions of palms or soles was classified neutrally as palmo-plantar pustulosis unless psoriatic lesions were found elsewhere at the actual examination, or were described in the history.

Isolated nail lesions were not considered sufficient for the diagnosis.

When the anamnestic data were highly suggestive, but when only slightly atypical eruptions were found at the time of examination, the diagnosis was supported by histopathological examination of a punch biopsy specimen.

Zygosity Diagnosis

The zygosity diagnosis was based on red cell, serum, and enzyme group determinations (a total of 15 systems), supplemented by HLA typing in most cases. Any difference between two partners with respect to one or more of these serological traits was taken as a proof of dizygosity; complete serological similarity was accepted as evidence of monozygosity, because this assumption under the present conditions has a probability of more than 99%. All serological tests were made before the identity of the blood samples was made known to the investigators. In cases where blood samples were unavailable, the principle generally used by the Danish Twin Register[12] was applied in the determination of the zygosity.

RESULTS

The examination of the 49 index cases that were chosen from the Register revealed that eight of these, belonging to eight different pairs (three male and five female), failed to fulfill the diagnostic criteria described. The diagnoses that were based on anamnestic information and the present clinical examination was, in six cases: stasis eczema (two cases), atopic dermatitis (one case), seborrheic dermatitis (one case), eczema (one case), and palmo-plantar pustulosis (one case). In the first three cases mentioned, the family doctor had suggested the presence of psoriasis; and in the last three cases mentioned, the twin believed the affection to be of a psoriatic nature, even if specialists who had been consulted found no support for this diagnosis. In two cases, the twins had mistakenly put their positive answer in a wrong place in the questionnaire, and there were actually no indications of psoriasis at any time in their history. Thus, 41 of the 49 twins were left with a fully established diagnosis of psoriasis and were considered probands in the present study. The examination of their partners revealed an additional five unquestionable cases of psoriasis in the monozygotic (MZ) group and two in the dizygotic (DZ) group. Three of these cases of psoriasis had manifested themselves after the twin had answered the latest questionnaire; in two instances, the follow-up questionnaire had not yet been returned at the time of the present examination. One twin had been given a different diagnosis when consulting the family doctor because of a skin eruption. Thus, only one false-negative reply was encountered. The clinical examination provided the diagnosis in 35 cases; eight of the remaining 13 cases that were diagnosed on the basis of the anamnestic data could be definitely substantiated by a dermatologist who had been consulted at the time of the eruption; in one instance, a

Composition of Subject Group*			
Group	No. of Pairs	No. of Pro-bands	No. of Secondary Psoriasis Cases
Monozygotic			
Males	6	9	3
Females	8	9	2
Total	**14**	**18**	**5**
Dizygotic			
Males	8	8	2
Females	14	15	0
Total	**22**	**23**	**2**

*Pairwise concordance rates: monozygotic pairs, 9/14 = 0.64; dizygotic pairs, 3/22 = 0.14. Probandwise concordance rates: monozygotic pairs, 13/18 = 0.72; dizygotic pairs, 4/23 = 0.17.

skin biopsy specimen supported the diagnosis.

In each of two pairs, one MZ and one DZ, typical psoriasis with a mild course had been present since the age of 17 in one member, whereas the partner had remained unaffected until the age of 67 and 65, respectively, when palmo-plantar pustulosis suddenly developed. These pairs were not counted as concordant in the numerical analyses. The break-down of subjects appears in the Table.

Etiological Aspects

Genetic Factors.—The so-called pairwise concordance rate, which gives the number of pairs in which both partners have psoriasis out of the total number in the group, was equal to 0.64 (9/14) in the MZ group and 0.14 (3/22) in the DZ group. This difference was highly significant ($P < .01$). No age correction was considered necessary, since the median age was 65 and 64, respectively, in the two groups.

The so-called probandwise concordance rate gives the proportion of independently ascertained probands who have a similarly affected partner. Eighteen MZ probands were ascertained independently, and 13 of these had a psoriatic co-twin; thus, the probandwise concordance rate was 0.72 (13/18) in MZ twins; the corresponding figure was 0.17 (4/23) in DZ twins. This implies that individuals who have a twin partner with psoriasis run a risk of around 70% of developing this affection (if they live long enough) when they belong to MZ pairs, and a risk of 15%-20% if they belong to DZ pairs. It should be noted that all male MZ pairs were concordant; this may, however, be due to chance.

HLA Types.—HLA typing was performed in 21 pairs. The most interesting findings concern the B13 and Bw17 antigens of the B series, which have previously been shown to have a close association with psoriasis vulgaris.[8] More than 50% of the affected twins had either B13 or Bw17, or both, antigens present. These two antigens have a frequency of 4.3% and 7.7%, respectively, in the Danish population. On the other hand, four of six psoriasis-concordant MZ pairs that were tested did not possess any of these antigens. In three DZ pairs in which the partners were discordant for psoriasis and with only one partner carrying B13 or Bw17, it was the affected partner who carried them. The present series contains too few cases of localized pustular psoriasis to be informative in this respect. Age at onset, severity, and course showed no striking differences between patients with and without B13 and/or Bw17 antigens.

Clinical Aspects

Age at Onset.—Figure 1 gives the age at manifestation of all affected individuals. The median age at manifestation was 19 years; the disease had developed before the age of 30 in 73% of the persons and before the age of 50 in 90%. The partners in whom psoriasis was first manifested and who were in doubly affected or concordant MZ pairs were found to have had the onset only slightly earlier than the affected partners in the MZ pairs with only one psoriatic member (mean ages, 18 and 20 years, respectively).

The interval between the ages of onset in the two partners of the nine concordant MZ pairs was six years or less in five pairs and 8, 14, 15, and 46 years, respectively, in the remaining four concordant MZ pairs. The three concordant DZ pairs had an interval of 11, 26, and 41 years, respectively, between the development of psoriasis in the two partners.

Course and Severity.—The attempt was made to rate the clinical picture in much the same way as used by Lomholt[1] in cases of psoriasis with a duration of more than four years. Four main categories were characterized as follows:

LR: Light recurring eruptions on the elbows and knees, but no symptoms for longer periods.

LC: Light, but rather constant symptoms, mainly on the elbows and knees, eventually also on the scalp, but not really disabling the patient.

MC: Moderate, almost constant, sometimes even severe symptoms, also on the trunk, but with minor spread.

SC: Severe, constant eruptions affecting the limbs, large parts of the trunk, and occasionally also the face and the dorsum of the hand.

The cases in which there were severe eruptions at an early age, but much milder symptoms later on, have been given the additional symbol ES in Fig 2 and 3.

The distribution of the course and severity of all cases of more than four years' duration is shown in Fig 2. The SC type is rare. Close to 50% of the total number of cases belong to the category with light, but rather constant symptoms (LC).

When comparisons with respect to course and severity were made between partners in pairs where psoriasis had been manifested for at least four years in both members, the results were as depicted in Fig 3. One of the concordant DZ pairs was disregarded in this context, because one of the members had his first eruption only two years prior to the present investigation. It is striking that only one of the nine doubly affected MZ pairs showed discrepancy with respect to course and severity, whereas the two psoriasis-concordant DZ pairs both showed intrapair differences.

The type of psoriasis that displays early, severe eruptions but milder symptoms later (ES) was rare, and was present in both members of one MZ and one DZ pair and in only one of two affected members in an MZ and in a DZ pair.

The morphology of the primary eruptions was the same in seven of the nine concordant MZ pairs: in six of these pairs, plaques appeared at the sites of predilection, and in one pair, guttate lesions were found in both partners. In the two remaining pairs, the partners had plaques and the guttate type of eruptions, respectively. In one of the concordant MZ pairs, typical plaques developed at the sites of predilection in one twin when aged 16; at the age of 31, minor plaques on the scalp and on the elbows and, in addition, mild inverse psoriasis and hyperkeratotic eczema of both hands developed in the partner.

Precipitating and Aggravating Factors

A careful search for possible exogenous influences of major importance in the development of psoriasis was made during the interviews with the twins.

There was a slight, but statistically insignificant, tendency in MZ pairs to have lived together for a longer time if they were concordant with respect to psoriasis rather than discordant.

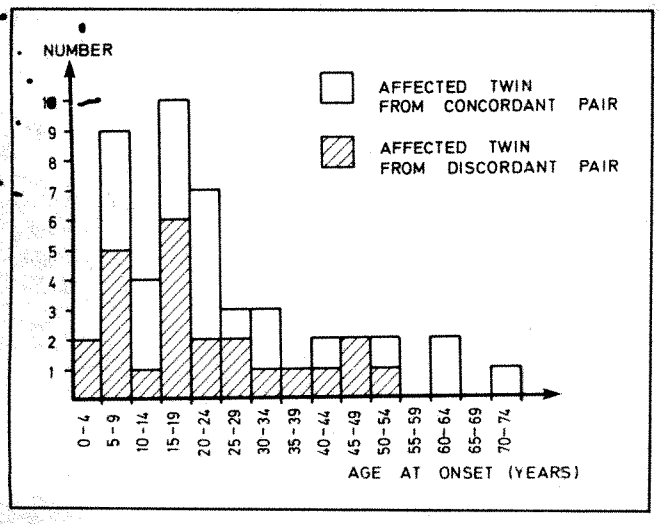

Fig 1.—Age at onset of psoriasis in 48 affected twins.

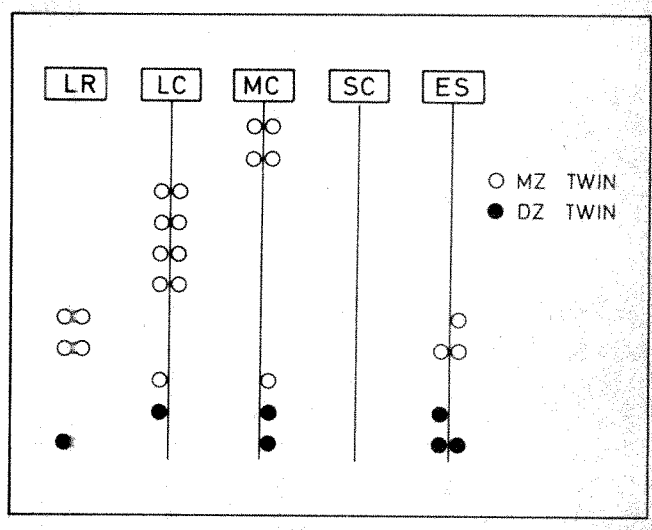

Fig 3.—Intrapair comparison of course and severity in nine monozygous (MZ) pairs and two dizygous (DZ) pairs showing concordance with respect to psoriasis (duration of affection > four years). See legend, Fig 2, for explanation of other abbreviations.

The medical history included no more frequent infections, especially those often caused by streptococci, in the twin with psoriasis than in the co-twin who escaped psoriasis. Chronic bronchitis and asthma were equally frequent in the two groups. Diabetes was diagnosed in three affected twins, but in only one of their unaffected co-twins.

Marital and social status, as well as occupation, seemed to have no relation to the presence of psoriasis in discordant pairs. A search for events that might have caused conflicts or prolonged stress at home or in the place of work did not reveal any indications of a heavier load in the affected than in the unaffected partner; admissions to psychiatric hospitals were, on the whole, extremely few.

Relation to Arthritis

Special attention was devoted to all possible signs of arthritis. This diagnosis was based on the interview, the examination, as well as on information from previous admissions to hospitals. Four cases of arthritis were found in twins with psoriasis. In one such twin, the results of serological rheumatoid factor tests (latex fixation test) had been positive, in one twin the results were negative, and in the remaining two twins, the serology was unknown. One seropositive value was observed in a nonpsoriatic partner from a DZ pair, and another seropositive value was observed in an MZ twin with palmo-plantar pustulosis only; the partner had typical psoriasis vulgaris, but no signs of arthritis.

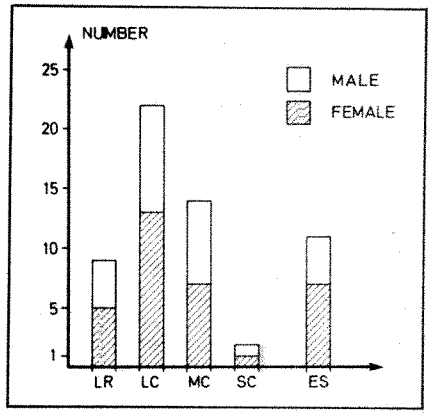

Fig 2.—Course and severity of psoriasis in 47 affected twins (duration of psoriasis > four years). LR, light recurring eruptions; LC, light, constant symptoms; MC, moderate, almost constant symptoms; SC, severe, constant symptoms; ES, severe eruptions early, mild symptoms later.

COMMENT

The main features of the present study are: First, the probands have been sampled from a population (of twins), and not from dermatological clinics or specialists; thus, ten of the 41 final probands had never been in touch with a dermatologist, but consulted a general practitioner only. Second, all twins and their partners were examined by one and the same investigator. Third, in pairs with only one affected partner, the minimal period of observation of the unaffected twin after psoriasis had developed in the other twin was 17 years in MZ and 29 years in DZ pairs. Furthermore, the mean age of the twins was 64 years at the time of the investigation, and they had all passed the age of 55. Fourth, the proportion of MZ pairs, which is 37% of the total sample, is in close agreement with expectation in this part of Scandinavia and with that observed in the total Twin Register.[12]

The present study permits a quantitative assessment of the relative importance of genetic factors in the development of psoriasis. However, such measures need not be generally valid; they apply in principle only to the population studied. The theoretical background has been worked out especially by Falconer[13] and was described in the ARCHIVES by Watson et al[4] in connection with their family analyses.

Heritability of Psoriasis

An estimtate of heritability, based on twin studies, can only be calculated if proband concordance rates are known. Based on the present material and an assumed population frequency of 2%, heritability is found to be about 90% according to the method given by Smith.[14] The population frequency used here is probably on the lower side of the true value because the mean age of the population from which the twins were derived is quite high; if a figure of 3% is used, the estimate comes closer to 100%. Although the standard errors are considerable, owing to the relatively limited material, it seems reasonable to accept the estimate as valid, especially because it is in very good agreement with that obtained through analogous methods

by Ananthakrishnan et al[6] on the basis of Lomholt's family material.[1] In the study by Ananthakrishnan et al, the heritability was found to be 91% when all first-degree relatives were combined. Lomholt's study stands out because of his personal examination of the vast majority of the family members.

A heritability of 90% implies that the variation observed between individuals with respect to presence or absence of psoriasis is due almost totally to their gene differences and only to a limited extent to the difference of the environmental factors experienced.

The only large twin series published previously, by Farber et al,[7] does not permit the use of this method of calculation. The information in this study was collected through inquiries to dermatologists all over the United States; the information was gathered almost exclusively through questionnaires; the study included an excess of MZ twins as anticipated with this type of approach; and the mean age was lower than that in our study. Since the gathering of data in the study of Farber et al was based primarily on questionnaire responses from patients outside the Stanford University Medical Center, the proband concordance rates could not be determined, because it was impossible for the investigators to designate an index case for each twin pair.

Environmental Effects

Environment may modify course, severity, and age at onset, but as demonstrated here, only to a rather modest extent. The high influence of genetic factors on course and severity is apparent from the observation that only one of nine concordant MZ pairs showed some difference in these respects, whereas two of three concordant DZ pairs exhibited dissimilarities. Morphology was also more alike in MZ twins. The same applied to age at onset. These findings confirm the similar observations made by Farber et al.[7]

Psoriasis Vulgaris vs Palmo-Plantar Pustulosis

The relation between psoriasis vulgaris and palmo-plantar pustulosis found no further elucidation in the present study. One MZ pair included one partner with the first-mentioned affection and one partner with the second. This is suggestive, but more similar cases are needed to support the assumption of a common gentic background.

HLA Types

The analysis of the distribution of HLA types confirmed the strong association with the antigens B13 and Bw17 of the B locus. It was, however, also apparent that psoriasis may develop if neither of these antigens are present. The observation reported by Beckman, Lidén, and co-workers[9-11] that the individuals heterozygous for the Ss factors of the MNSs blood group system were below expectation among psoriatic patients was not apparent in the present study. Not only were these factors more common than expected, but also, in six DZ pairs with only one psoriatic partner and one heterozygote, the heterozygote was always the one affected. Thus, the suggestion that heterozygosity for these factors protect against the development of psoriasis could not be supported by the present material. No signs were found of associations between continuous symptoms and the A blood group factor and the Fy(a+b−) phenotype, or between late onset and the same Duffy phenotype as described by Lidén, Beckman, and co-workers.[10,11]

External Factors

The search for external factors that influence the development of psoriasis was unsuccessful. Neither infections, nor conditions that might have caused stress or conflicts, nor longer stays in urban environments were observed more often in the affected than in the unaffected member of discordant pairs. Among MZ pairs with indentical genetic constitution, concordant pairs had stayed together for between 12 and 26 years (and only in one case for a longer period), and discordant pairs had stayed together for 14 to 25 years. Furthermore, the fact that the risk of developing psoriasis seemed to be much the same in the DZ twin-pairs that were observed here as the risk in ordinary siblings of affected probands,[1] suggests that the greater similarity of prenatal, infancy, and childhood environment experienced by pairs of DZ twins, compared with pairs of siblings in general, is of minor importance with respect to the development of psoriasis.

Conclusion

More extensive and comprehensive analyses, especially of discordant MZ pairs, would be of the greatest interest in attempting to identify possible external factors that may provoke or delay the manifestation of psoriasis. Such suggestions would be of great value in therapeutic and preventive efforts. Because information is continuously increasing in the Danish Twin Register where information on younger pairs (however still past 45 years) is being collected, a supplementary study of this type will appear in the future.

Financial support for this study has been given to F. Brandrup from the Hjalmar Westerdahl Research Foundation (Maleren Hjalmar Westerdahls Forskningslegat), and from the Regional Medical Research Foundation, Odense University Hospital (Det lokale forskningsfond ved Odense Sygehus).

M. Hauge received the Research Price award, donated by the Order of Odd-Fellows, Denmark (Odd-Fellow Ordenen i Danmark), which aided in the collection of the basic material.

References

1. Lomholt G: *Psoriasis, Prevalence, Spontaneous Course and Genetics: A Census Study on the Prevalence of Skin Diseases on the Faroe Islands.* Copenhagen, GEC Gad, 1963.

2. Hellgren L: *An Epidemiological Survey of Skin Diseases, Tattooing, and Rheumatic Diseases.* Stockholm, Almquist & Wiksell, 1967.

3. Schwartz M: *Heredity in Bronchial Asthma.* Copenhagen, Ejnar Munksgaard, 1952.

4. Watson W, Cann HM, Farber EM, et al: The genetics of psoriasis. *Arch Dermatol* 105:197-207, 1972.

5. Ananthakrishnan R, Eckes L, Walter H: On the genetics of psoriasis: An analysis of Hellgren's data for a model of multifactorial inheritance. *Arch Dermatol Forsch* 247:53-58, 1973.

6. Ananthakrishnan R, Eckes L, Walter H: On the genetics of psoriasis: An analysis of Lomholt's data from Faroe Islands for a multifactorial mode of inheritance. *J Genet* 61:142-146, 1974.

7. Farber EM, Nall ML, Watson W: Natural history of psoriasis in 61 twin pairs. *Arch Dermatol* 109:207-211, 1974.

8. Svejgaard A, Nielsen LS, Svejgaard E, et al: HL-A in psoriasis vulgaris and in pustular psoriasis: Population and family studies. *Br J Dermatol* 91:145-153, 1974.

9. Beckman L, Brönnestam R, Cedergren B, et al: HL-A antigens, blood groups, serum groups and red cell enzyme types in psoriasis. *Hum Hered* 24:496-506, 1974.

10. Lidén S, Beckman L, Bergdahl K, et al: Genetic markers in psoriasis, in Farber EM, Cox AJ (eds): *Psoriasis. Proceedings of the Second International Symposium.* New York, Yorke Medical Books, 1977, pp 127-133.

11. Beckman L, Bergdahl K, Cedergren B, et al: Genetic markers in psoriasis. *Acta Derm Venereol* 57:247-251, 1977.

12. Hauge M, Harvald B, Fischer M, et al: The Danish Twin Register. *Acta Genet Med Gemellol* 17:315-332, 1968.

13. Falconer DS: The inheritance of liability to certain diseases, estimated from the incidence among relatives. *Ann Hum Genet* 29:51-76, 1965.

14. Smith C: Concordance in twins: Methods and interpretation. *Am J Hum Genet* 26:454-466, 1974.

Chronic Urticaria-Like Lesions in Systemic Lupus Erythematosus

A Review of 12 Cases

Sean O'Loughlin, MD; Arnold L. Schroeter, MD; Robert E. Jordon, MD

• Twelve of 54 patients with systemic lupus erythematosus (SLE) had nonpurpuric, chronic urticaria-like lesions. Skin biopsy of the lesions was performed in 11 cases, and nine showed necrotizing vasculitis. The 54 patients, in general, had severe disease, and laboratory and clinical data suggested a positive relationship between the urticaria-like lesions and disease severity. There was no consistent relationship between the course of the urticaria-like lesions and the serologic findings and clinical activity of the SLE. The frequency and importance of urticaria-like lesions in SLE deserve further study.

(*Arch Dermatol* 114:879-883, 1978)

Chronic urticaria and its subcutaneous counterpart, angioedema, are common disorders that affect ⅕ of the population at some time.[1] In approximately 80% of the cases, no underlying cause is established, whereas in the remaining 20%, there is mainly allergic and nonspecific nonallergic urticaria.[2,3] Generally, in chronic urticaria, there is edema of the dermis with a polymorphous perivascular infiltrate,[4] and components of immunologic reactions are not found by immunofluorescence (IF) techniques[5] (this information has also been noted by the authors, unpublished data).

Mathews,[3] in 1974, stated that the precise incidence and circumstances under which urticaria occurs in systemic lupus erythematosus (SLE) have not been well documented. A recent review of seven series[6-12] revealed that the occurrence of urticaria in SLE varied from 0% to 50%.

We report the findings in 12 of 54 cases of SLE in which chronic urticaria-like lesions were a major cutaneous sign. The relationship of these lesions to SLE was studied by comparing serologic, histologic, and IF data with clinical findings. Hereafter, the urticaria-like lesions are referred to as urticaria for the sake of brevity.

• Accepted for publication Jan 20, 1978.

• From the Department of Dermatology, Mayo Clinic and Mayo Foundation, Rochester, Minn.

• Reprint requests to Section of Publications, Mayo Clinic, 200 First St SW, Rochester, MN 55901 (Dr O'Loughlin).

SUBJECTS AND METHODS

All 12 patients satisfied established criteria for a diagnosis of SLE[13]; all of the patients were women with negative personal and family histories for atopy. At initial examination, five patients had known SLE, and seven were seen for diagnosis. In all 12 patients, chronic pruritic urticaria was the predominant symptom, and an obvious cause had not been found despite detailed investigation. Various medications provided no relief. All 12 patients underwent physical examination, and a detailed history was obtained.

Laboratory Studies

The following investigations were performed in each case: hemoglobin, hematocrit, blood leukocyte and differential counts, ESR (Westergren), platelet count, LE clot test, antinuclear antibody, rheumatoid factor, automated reagin test (ART) for syphilis, serum bilirubin, serum glutamic-oxalacetic transaminase, lactic dehydrogenase, serum cryoglobulin, serum total thyroxine, direct Coombs' test, urinalysis, serum creatinine, creatinine clearance, chest roentgenogram, and electrocardiogram. Total serum complement was measured by an automated technique[14] in ten cases. Serum C3 was measured in six cases, and serum C4 was measured in nine cases by radial immunodiffusion.[15] Serum levels of IgG, IgA, and IgM were determined in ten patients. The C1 esterase inhibitor was measured in three cases by radial immunodiffusion[15]; hepatitis-associated antigen was measured in four cases; and serum salicylate level was measured in four cases.

Skin Biopsy

Punch biopsy specimens (4 mm) of active urticarial lesions (lesions present for less than eight hours) were taken from 11 patients after local anesthesia with 1% lidocaine hydrochloride without epinephrine. These specimens were fixed in 10% formaldehyde solution and stained with hematoxylin-eosin, resorcin-fuchsin-Giemsa, and Alcian blue-PAS. In addition, punch biopsy specimens were obtained from urticarial lesions of ten patients and from uninvolved sun-protected skin of eight patients, and these specimens were frozen in liquid nitrogen and stored at −70°C. Within one week, direct IF staining was performed by a standard procedure,[16] using fluorescein-conjugated antisera to IgG, IgA, IgM, C3, and fibrin. Fluorescein-to-protein ratios (F/P), units of antiserum, and use dilutions for these antisera conformed to previously determined standards.[16]

The presence of C1q, factor B, and properdin was determined by a modified indirect IF technique recently described by Provost and Tomasi[17] and Jordon et al.[18] Briefly, sections were treated with unlabeled rabbit anti-C1q or rabbit anti-factor B serum, followed by treatment with fluorescein-conjugated goat anti-rabbit IgG (F/P 4.4, use dilution 1:32). Likewise, sections treated with goat anti-properdin were treated with fluorescein-conjugated rabbit anti-goat IgG (F/P 3.5, use dilution 1:32). Antisera to C1q, factor B, and properdin were prepared as described previously.[18,19]

RESULTS

Clinical Data

All 12 patients were women whose ages when examined ranged from 23 to 57 years. The duration of urticaria ranged from four months to six years, and seven patients had lesions for more than one year. Four patients had associated angioedema of the face and lips; one of these patients also had angioedema of the limbs. Ten patients had generalized urticaria. In addition to having urticaria (which was the only cutaneous finding in five patients), three patients had livedo reticularis, two patients had purpura, one patient had discoid plaque lesions on the face, and one patient had scarring alopecia. The urticarial lesions were pruritic and nonpurpuric in all patients and did not differ clinically from "idiopathic" urticarial lesions; however, these lesions tended to be of longer duration. In five patients, urticarial episodes usually persisted for one to two days; in five patients, the episodes lasted two to three days; in one patient, they lasted four to five days; and one patient had transient lesions that lasted six to eight hours. Despite photosensitivity, which was

Table 1.—Histologic Findings in 11 Cases of SLE* With Urticaria

Findings	No. of Patients
Normal epidermis	6
Vacuolization of basal layer of epidermis	2
Focal edema and cavitation in epidermis	1
Hyperkeratosis and dermal-epidermal separation	1
Intraepidermal bulla formation	1
Necrotizing vasculitis with leukocytoclasis	9
Lymphohistiocytic proliferation and infarction	1
Diffuse perivascular polymorphonuclear leukocyte infiltrate	1
Prominent eosinophils	2

*SLE indicates systemic lupus erythematosus.

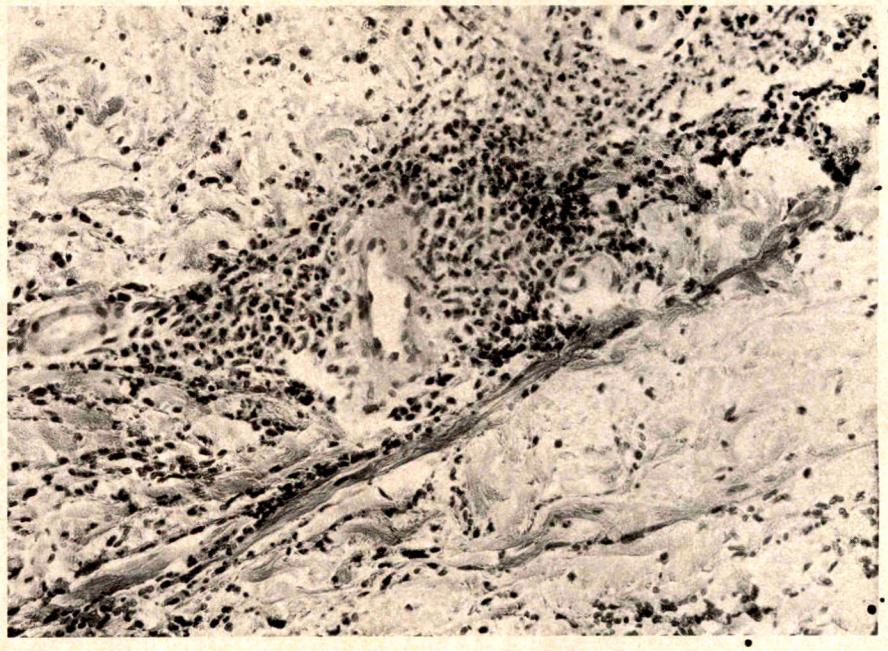

Fig 1.—Mid-dermal vessel showing endothelial cell swelling, degeneration of vessel wall, perivascular cellular infiltrate consisting predominantly of polymorphonuclear leukocytes, and nuclear dust (leukocytoclasis) (hematoxylin-eosin, ×200).

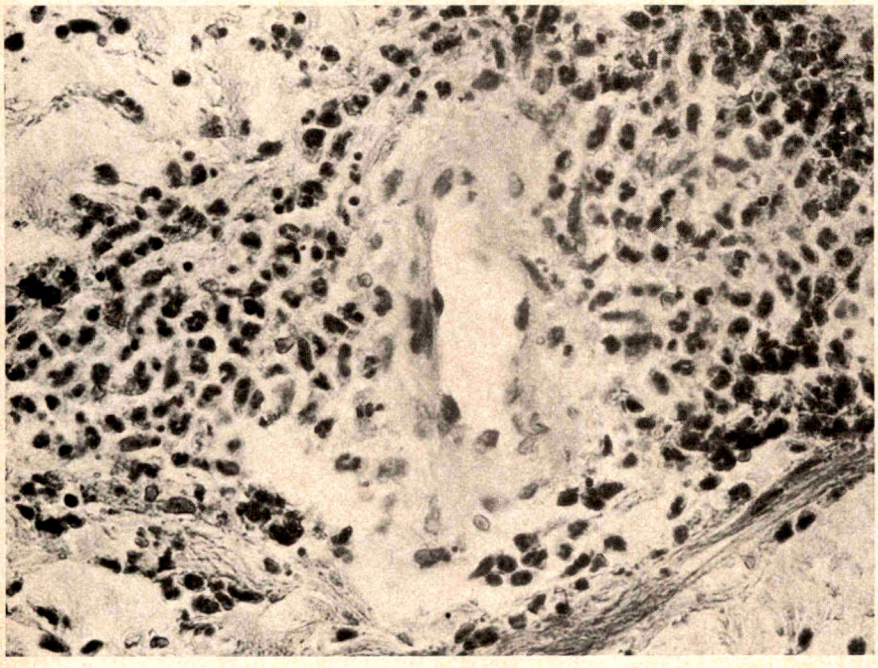

Fig 2.—Higher power view of changes seen in Fig 1 (hematoxylin-eosin, ×600).

Table 2.—Positive Direct Cutaneous Immunofluorescence in Cases of SLE* With Urticaria

	Findings Present/No. of Patients			
	Basement Membrane		Blood Vessels	
Antisera	Involved	Uninvolved	Involved	Uninvolved
IgG	7/10	3/8	1/10	0/8
IgA	1/5	1/6	0/5	0/6
IgM	10/10	8/8	6/10	1/8
C3	9/10	5/8	4/10	1/8
Clq	6/6	3/3	1/6	0/3
C3PA (factor B)	0/5	0/2	0/5	0/2
Properdin	3/5	1/2	0/5	0/2
C4	0/2	0/2	0/2	0/2
Fibrin	1/8	1/8	2/8	2/8

*SLE indicates systemic lupis erythematosus.

present in seven patients, sun-induced urticaria was not encountered. All patients had been taking oral antihistamine medication when examined, and five also were taking oral prednisone. Two patients had histories of transient urticaria after taking oral penicillin during childhood. One patient had a sister with proved SLE. One patient had myasthenia gravis for 26 years, but this was controlled by neostigmine (Prostigmin) bromide tablets (90 to 120 mg daily).

Seven patients had nondeforming synovitis of the hands, and four of these patients had generalized synovitis. Three other patients had generalized arthralgia. The one patient in whom the rheumatoid factor was positive (1:128) had a 20-year history of rheumatoid-type arthritis involving multiple joints.

Urinalysis, serum creatinine levels, creatinine clearance, and 24-hour urinary protein studies indicated that eight patients had notable renal disease. All eight of these patients had either many cellular casts or profuse proteinuria. Of these, five patients had histologic evidence of glomerulonephritis on renal biopsy.

One patient had lupus cerebritis with grand mal seizures and retinal cotton-wool exudates; results of retinal examination of the 11 other patients were unremarkable. One patient had a one-month history suggestive of pseudotumor cerebri.

Laboratory Data

Two patients had hemoglobin levels less than 10 g/dl; five had leukopenia; no patient had eosinophilia; and nine patients had elevated sedimentation rates (ESR greater than 20 mm in one hour), and eight of these patients had readings greater than 50 mm. One patient had thrombocytopenia with a platelet count of 38,000/cu mm. Nine patients had positive LE clot tests, and ten patients had positive antinuclear antibody titers; in eight of the ten, the titer was high (that is, greater than 1:256). Elevated serum anti-nDNA levels were found in the two patients studied. Of ten patients studied, three had elevated serum IgG levels, three had elevated serum IgA levels, and five had elevated serum IgM levels. Seven of the ten patients had low levels of total serum complement, and six of the seven had renal disease. Four of six patients studied showed low levels of serum C3 (two of the four had renal disease), and five of nine patients studied showed low levels of serum C4 (four of the five had renal disease). The ART for syphilis was reactive in two patients, and results of tests for cryoglobulin in the serum and the direct Coombs' test were negative in all patients. Results of liver function tests were normal.

The level of serum C1 esterase inhibitor was normal in the three patients tested. Hepatitis-associated antigen was negative in the four patients examined, and blood salicylate level was zero in the four patients tested.

Chest roentgenograms showed bilateral basal infiltration in two pa-

Table 3.—Treatment in 12 Cases of SLE With Urticaria*

Case/Treatment of SLE	Follow-up
1/Cyclophosphamide (150 mg, qd) and prednisone (50 mg, qd)	Urticaria subsided in two months. One year later, urticaria had not recurred on same treatment; generalized arthralgia persisted; ANA, 1:2,156; results of LE test showed nucleolysis; normal values for serum CH50, C3, and C4; serum creatinine value, 1.3 mg/dl; anti-nDNA, 3.27 μg/ml; leukocytes, 11.2 × 10^3/cu mm.
2/Prednisone (15 mg, qd)	Urticaria subsided in one month. Two years later, urticaria controlled on prednisone (15 mg); arthritis had subsided; results of LE test, negative; leukocytes, 5 × 10^3/cu mm; urine, normal.
3/Prednisone (20 mg, qd) and chloroquine (100 mg, qd)	Urticaria subsided in three months. Two years later, no recurrence on prednisone (5 mg, bid); asymptomatic; results of LE and ANA tests, negative.
4/Prednisone (20 mg, qd)	Urticaria subsided in two months. One year later, intermittent urticaria on prednisone (12 mg, qd); results of LE test, negative; ANA, 1:64; anti-nDNA, 0.4 μg/ml; CH50, 18 units; C4 < 10 ng/dl; two years later, urticaria when fatigued; on prednisone (10 mg, qd); ANA, negative; CH50, 11 units; leukocytes, 10 × 10^3/cu mm; serum creatinine value, 1 mg/dl; asymptomatic; urine, normal.
5/Prednisone (10 mg, qd)	Urticaria partially controlled, less severe and less frequent. One year later, no change on prednisone (10 mg, qd); asymptomatic; fever and arthritis subsided; results of LE test, negative; ESR, 14 mm in one hour; normal values for serum CH50 and C4; serum creatinine value, 1.1 mg/dl.
6/Hydroxyzine hydrochloride (25 mg, tid)	Urticaria minimally improved. Two years later, arthritis improved by ibuprofen; urticaria persisted while on hydroxyzine hydrochloride (25 mg, tid). Three years later, no change; repeat biopsy on urticarial lesion showed necrotizing vasculitis; results of ANA and LE tests, negative; leukocytes, 2.3 × 10^3/cu mm; ESR, 23 mm in one hour; CH50, 27 units; serum creatinine value, 1.1 mg/dl; urine, normal.
7/Prednisone (15 mg, bid)	Partial response to treatment when seen four months later.
8/Prednisone (20 mg, qd)	Urticaria subsided in two months. Two years later, no urticaria (patient not on treatment); leukocytes, 4.2 × 10^3/cu mm; ESR, 83 mm in one hour; urine, normal.
9/Chloroquine hydrochloride (125 mg, qd)	Urticaria subsided in two months. Two years later, asymptomatic on chloroquine (125 mg, qd); anti-nDNA, 3.2 μg/ml; ANA, 1:256; CH50, 14 units. Three years later, occasional urticaria on chloroquine (125 mg, qd); CH50, 24 units; leukocytes, 4.0 × 10^3/cu mm; urine, normal.
10/Azathioprine (125 mg, qd)	Urticaria subsided in three weeks. Two years later, no recurrence on prednisone (15 mg, qd) and chloroquine (250 mg, qd); Raynaud's phenomenon of hands and scarring scalp alopecia; arthritis subsided; anti-nDNA, 0.89 μg/ml; ESR, 46 mm in one hour; leukocytes, 4.3 × 10^3/cu mm.
11/Azathioprine (100 mg, qd)	Urticaria subsided in two weeks. Patient died four months later of renal and respiratory failure due to SLE.
12/Chloroquine hydrochloride (250 mg, qd)	Urticaria cleared in one month. One year later, no recurrence on prednisone (10 mg, qd); anti-nDNA, 0.75 μg/ml. Eighteen months later, easily fatigued; no urticaria; serum creatinine value, 1.1 mg/dl; leukocytes, 4.5 × 10^3/cu mm; results of LE test, negative; anti-nDNA, normal; urine, grade 2 proteinuria.

*SLE indicates systemic lupus erythematosus; qd, daily; bid, twice daily; tid, three times a day; ANA, antinuclear antibody.

Table 4.—Patients Having SLE and Urticaria Compared With Total Group of Patients Having SLE*

Findings	Percentage of Patients: Urticaria (12 Patients)	Percentage of Patients: Total Group (54 Patients)
Female	100	91
Photosensitivity	58	73
Fever	42	41
Pleurisy	17	24
Arthralgia	25	33
Arthritis	58	41
Raynaud's phenomenon	8.5	18
Anemia	17	35
Leukopenia (< 4,100/cu mm)	33	30
ESR > 20 mm in 1 hour	75	89
Positive LE test	75	65
Positive ANA	83	79
Renal involvement	67	52
Neurologic involvement	8.5	19
Increased serum IgG	30	32
Increased serum IgA	30	22
Increased serum IgM	50	49
Decreased serum CH50	70	54
Positive IF basement membrane		
Involved skin	100	97
Uninvolved skin	100	98
Positive IF dermal vessels		
Involved skin	60	40
Uninvolved skin	50	30

*SLE indicates systemic lupus erythematosus; ANA, antinuclear antibody titer; IF, immunofluorescence.

tients and a unilateral pleural effusion in another patient.

Skin Biopsy

Light microscopic examination of the biopsy specimen of the urticaria lesions revealed that nine of the 11 patients studied had necrotizing vasculitis as defined by Lever and Schaumburg-Lever[20] (Table 1). There was swelling of the endothelial cells of the vessels with fibrin deposition within and around the vessel walls (Fig 1). Cellular infiltrate was present predominantly around the blood vessels but also within the vessel walls; the infiltrates consisted mainly of polymorphonuclear leukocytes with some mononuclear cells. Nuclear fragments (leukocytoclasis) were present. Vessels at all levels of the dermis were involved, but those of the upper dermis were particularly involved. One patient had involvement of subcutaneous vessels. Only three of the nine patients with necrotizing vasculitis were taking medication other than oral antihistamines at the time of skin biopsy. Two patients were taking 20 mg of prednisone daily, and one patient was taking 40 mg of prednisone daily. The histologic patterns in these three patients did not differ substantially from those in the six other patients with necrotizing vasculitis. The ESR was elevated (more than 20 mm in one hour) in seven of the nine patients: five with more than 70 mm; one with 51 mm; and one with 31 mm. A similar pattern of marked elevation in ESR was seen in all 54 patients with SLE: 89% of the patients showed values more than 20 mm/hr; 65% showed values greater than 50 mm/hr; and 41% showed values greater than 75 mm/hr. The total serum complement level was low in five of the seven patients with necrotizing vasculitis who were studied; serum C3 level was decreased in all three patients studied, and serum C4 level was decreased in three of the six patients studied. Five of the nine patients with necrotizing vasculitis had substantial renal disease, and the total serum complement level was decreased in all five patients. Of the four patients without renal disease, the total serum complement level was normal in two; the level was decreased in one, and the level was not measured in one.

In two patients, necrotizing vasculitis was not seen on biopsy. One patient had a diffuse neutrophilic perivascular infiltrate thoughout the dermis, with a normal ESR, low total serum complement, and renal disease, and this patient was taking 15 mg of prednisone daily. The other patient had a diffuse perivascular lymphohistiocytic infiltrate with dermal infarction, an ESR of 97 mm, a low serum complement, and renal disease and was not receiving treatment.

The elastic tissue was destroyed in areas of vasculitis. Five patients had prominent epidermal changes secondary to vasculitis. Two patients had prominent eosinophils in the perivascular infiltrate.

IF Findings

Dermal-Epidermal Junction.—Immunoglobulins and complement fractions, when present at the dermal-epidermal junction, were of a granular band type that is characteristic of the usual pattern seen in SLE (Table 2 and Fig 2). The involved skin of all ten patients who were tested had IgM deposition, with nine of the ten having C3 staining and six of the six patients studied having C1q deposition. Seven of the ten patients examined had IgG deposition, while only one of five tested had IgA deposition. Three of four patients studied had properdin deposition, while none of the four patients had deposition of factor B. The dermal-epidermal junction of the uninvolved sun-protected skin showed a comparable pattern of positive staining consistent with our previous observations.[19]

Blood Vessels.—The superficial and mid-dermal vessels showed deposition of the various immunoglobulin and complement fractions in the skin lesions in more than half the patients studied (Fig 2). However, positive findings in the uninvolved skin were rare.

Course of Urticaria.—The urticarial reaction was completely controlled in five patients and partially controlled in six patients (Table 3) when corticosteroids, antimalarial drugs, or immunosuppressive medications were prescribed alone or in combination. In some patients, the urticaria was resistant to treatment, and rebiopsy of an urticarial lesion from one patient two years after onset of treatment showed the persistence of necrotizing vasculitis. There was no relationship between the course of urticaria and the other clinical and serologic factors of SLE activity.

COMMENT

There have been conflicting reports concerning the frequency and importance of urticaria in SLE. More than twenty-two years ago, Harvey et al[6] emphasized the frequent occurrence of transient urticaria and angioneu-

rotic edema in patients with SLE; these authors believed that such lesions often went unrecognized, and they reported that 7% of their 105 patients with SLE had urticaria and 4% had hives when initially seen. Scott and Rees[7] found that 15 of their 30 patients with SLE had urticaria; these investigators noted capillary dilatation and microinfarcts on biopsy of urticarial lesions, with some endothelial necrosis in patients who had purpura on initial clinical examination. In a recently reported series, 13% of 150 patients with SLE had recurring urticaria.[8] Of the larger series (520 cases) reported by Tuffanelli and Dubois,[9] 6.9% of patients had hives and angioedema, and urticaria was the first symptom in 4% of these. Of 28 patients with SLE reported by Hendrix,[10] four (14%) had urticaria. However, in other series of SLE patients, for instance, those of Haserick (275 patients)[11] and of Larson (200 patients),[12] urticaria was not seen in any patient.

Dubois[21] noted that urticaria and angioneurotic edema were not seen more frequently in patients with SLE than in allergic patients without SLE, but he contended that an exogenous antigen, such as food or medication, was responsible in both situations. However, in a controlled study, urticaria (including angioneurotic edema) was seen in 28% of 50 patients who had SLE compared with 10% of 100 control subjects; and other "allergic type diseases" were not more frequent in SLE.[22]

The 12 patients with urticaria in our series represent 23% of the 54 patients with SLE who were studied. Seven of the 12 patients had not had SLE diagnosed before our examination, although five of the seven had recurring urticaria for at least one year. Urticaria was a major cutaneous symptom in these 12 patients, and biopsy in 11 of these patients revealed necrotizing vasculitis with leukocytoclasis as the major histologic finding in nine patients. Examination of skin from urticarial lesions by direct IF showed immunoglobulin and complement deposition at the dermal-epidermal junction in ten patients and in the dermal blood vessels in six. A comparable incidence of positive reactivity was found in lesional skin of patients with SLE in the absence of urticaria (Table 4). The importance of cutaneous deposits of immunoglobulin and complement in the pathogenesis of SLE or SLE urticaria (or both) is questioned because of an approximately equal incidence of positive IF findings in uninvolved skin of both groups.

Jansen and Cormane[5] described a 32-year-old woman whom they had considered to have SLE and who had widespread urticarial lesions and edema of the upper lip. A biopsy specimen of the urticarial lesion revealed a perivascular infiltrate that consisted mainly of eosinophils, with some lymphocytes and histiocytes, and slight dermal edema. Immunofluorescence of the urticarial lesion demonstrated IgG and IgM staining of the dermal-epidermal junction. Uninvolved skin revealed IgM deposition at the dermal-epidermal junction.

Our patients with urticaria differ from those with vasculitis and hypocomplementemia described by McDuffie et al[23] in that all of our patients had definite SLE, none had hemorrhagic lesions, and many had severe renal disease. Sissons et al[24] described two patients who were similar to those described by McDuffie et al. In one of the patients of Sissons et al, the cutaneous histologic and IF findings resembled those seen in our series. However, the laboratory data were not consistent with SLE. The eight patients reported by Soter et al[25] were similar to ours in that nonpurpuric urticarial lesions showed leukocytoclastic vasculitis, but SLE was not present, and IF studies did not reveal consistent abnormalities.

In the series by Ballow et al,[26] none of the four patients with urticaria had SLE; two of the four patients had activation of the C1-bypass complement pathway.

The higher incidence of hypocomplementemia and renal disease in our urticarial patients suggests that urticaria lesions are seen more commonly in patients with severe SLE.

This investigation was supported in part by research grant AI-12049 from the National Institutes of Health, Public Health Service, and by a grant from the Minnesota chapter of the Arthritis Foundation.

Nonproprietary Names and Trademarks of Drugs

Azathioprine—*Imuran.*
Chloroquine hydrochloride—*Aralen Hydrochloride.*
Ibuprofen—*Motrin.*

References

1. Swinny B: The atopic factor in urticaria. *South Med J* 34:855-857, 1941.
2. Warin RP, Champion RH: Urticaria. *Major Probl Dermatol* 1:1-164, 1974.
3. Mathews KP: A current view of urticaria. *Med Clin North Am* 58:185-205, 1974.
4. Lever WF, Schaumburg-Lever G: *Histopathology of the Skin*, ed 5. Philadelphia, JB Lippincott Co, 1975, pp 133-156.
5. Jansen LH, Cormane RH: Urticaria bij lupus erythematodes. *Ned Tijdschr Geneeskd* 3:2160-2165, 1967.
6. Harvey AM, Shulman LE, Tumulty PA, et al: Systemic lupus erythematosus: Review of the literature and clinical analysis of 138 cases. *Medicine* 33:291-437, 1954.
7. Scott A, Rees EG: The relationship of systemic lupus erythematosus and discoid lupus erythematosus: A clinical and hematological study. *Arch Dermatol* 79:422-435, 1959.
8. Estes D, Christian CL: The natural history of systemic lupus erythematosus by prospective analysis. *Medicine* 50:85-95, 1971.
9. Tuffanelli DL, Dubois EL: Cutaneous manifestations of systemic lupus erythematosus. *Arch Dermatol* 90:377-386, 1964.
10. Hendrix R: Klinische Analytische Studie van 28 Gevallen van Lupus Erythematodus Disseminatus. *Acta Clin Belg* 28:69-91, 1973.
11. Haserick JR, cited by Dubois EL: Lupus Erythematosus: *A Review of the Current Status of Discoid and Systemic Lupus Erythematosus and Their Variants*, ed 2. Los Angeles, University of Southern California Press, 1974, p 294.
12. Larson DL: *Systemic Lupus Erythematosus.* Boston, Little Brown & Co, 1961, pp 38-41.
13. Cohen AS, Reynolds WE, Franklin EC, et al: Preliminary criteria for the classification of systemic lupus erythematosus. *Bull Rheum Dis* 21:643-648, 1971.
14. Olitzky I: Standardized, automated procedure for measurement of serum hemolytic complement activity. *Appl Microbiol* 16:1635-1639, 1968.
15. Mancini G, Carbonara AO, Heremans JF: Immunochemical quantitation of antigens by single radial immunodiffusion. *Immunochemistry* 2:235-254, 1965.
16. Beutner EH, Chorzelski TP, Jordon RE: Autosensitization in Pemphigus and Bullous Pemphigoid. Springfield, Ill, Charles C Thomas Publisher, 1970, pp 5-16.
17. Provost TT, Tomasi TB Jr: Evidence for complement activation via the alternate pathway in skin diseases: I. Herpes gestationis, systemic lupus erythematosus, and bullous pemphigoid. *J Clin Invest* 52:1779-1787, 1973.
18. Jordon RE, Schroeter AL, Good RA, et al: The complement system in bullous pemphigoid: II. Immunofluorescent evidence for both classical and alternate-pathway activation. *Clin Immunol Immunopathol* 3:307-314, 1975.
19. Jordon RE, Schroeter AL, Winkelmann RK: Dermal-epidermal deposition of complement components and properdin in systemic lupus erythematosus. *Br J Dermatol* 92:263-271, 1975.
20. Lever WF, Schaumburg-Lever G: *Histopathology of the Skin*, ed 5. Philadelphia, JB Lippincott Co, 1975, pp 160-163.
21. Dubois EL: *Lupus Erythematosus: A Review of the Current Status of Discoid and Systemic Lupus Erythematosus and Their Variants*, ed 2. Los Angeles, University of Southern California Press, 1974, p 294.
22. Becker LC: Allergy in systemic lupus erythematosus. *Johns Hopkins Med J* 133:38-44, 1973.
23. McDuffie FC, Sams WM Jr, Maldonado JE, et al: Hypocomplementemia with cutaneous vasculitis and arthritis. *Mayo Clin Proc* 48:340-348, 1973.
24. Sissons JGP, Williams DG, Peters DK, et al: Skin lesions; angio-oedema, and hypocomplementaemia. *Lancet* 2:1350-1352, 1974.
25. Soter NA, Austen KF, Gigli I: Urticaria and arthralgias as manifestations of necrotizing angiitis (vasculitis). *J Invest Dermatol* 63:485-490, 1974.
26. Ballow M, Ward GW Jr, Gershwin ME, et al: C1-bypass complement-activation pathway in patients with chronic urticaria and angio-oedema. *Lancet* 2:248-250, 1975.

Salabrasion of Tattoos

A Correlation of the Clinical and Histological Results

Walter A. Koerber, Jr, MD, Norman M. Price, MB, ChB

• Twenty-six tattoos were treated by salabrasion. The salt was left on the abraded surface from zero to 24 hours. The percentage of residual pigment varied from 50%, when the salt was removed immediately after salabrasion, to 5%, when the salt was left in place for over 12 hours. When the salt was left on for variable periods, some degree of scarring and hypopigmentation occurred in 79% and in 59% of the tattoos, respectively. When the salt was removed immediately after salabrasion, 29% of the tattoos showed scarring and 29% showed hypopigmentation. Our results show that the best method is to remove the salt immediately after salabrasion, but that this form of therapy should only be done on those lesions where the eventual cosmetic result is not important.

(*Arch Dermatol* 114:884-888, 1978)

Techniques for removing tattoos have been known for almost as long as the earliest recorded tattooing. One of the first recorded treatments for removing tattoos was by Scribonius Largus of 54 AD.[1-3] The Greek physician, Aetius, in 543 AD, was the first to use table salt in the removal of tattoos.[2-5] His method consisted of the application of an irritating mixture to the tattoo for several days, after which salt was imbued or inoculated into the tattoo.

More recently others have used salt to remove tattoos. In 1935 Klövekorn noted that tattoos could be removed by rubbing them with salt daily until the skin became red.[6] Crittenden, in 1971, coined the word "salabrasion" and reported on the successful removal of tattoos from five patients.[7] Manchester, in 1973 and 1974, reported on an additional 53 patients.[2,4]

Our report describes the results of salabrasion on 26 tattoos from ten patients.

Accepted for publication Jan 13, 1978.

From the Dermatology Service, Veterans Administration Hospital, Palo Alto, Calif, and the Department of Dermatology, Stanford (Calif) University Medical Center.

Reprint requests to Dermatology Service (151D), Veterans Administration Hospital, 3801 Miranda Ave, Palo Alto, CA 94304 (Dr Price).

MATERIALS AND METHODS

In all ten subjects, the hair was shaved over the area to be salabraded and the skin was cleaned with a providone-iodine solution. The area of the tattoo was anesthetized with 1% xylocaine without epinephrine. A few tattoos were salabraded without anesthesia. The tattoo was rubbed with a slightly moistened, sterile gauze dipped in table salt until the skin surface was removed, and a uniform, glistening erosion was present, at which point the epidermis should have been removed. The erosion produced in all cases was the same. Salt was then applied to the abraded area and was left on for differing periods of time, ranging from zero to 24 hours.

The treated lesions were either permitted to dry uncovered or were dressed with an antibiotic ointment and an occlusive gauze. The dressings were changed daily until the pigment ceased to appear on the dressings. Some of the tattoos were salabraded twice. Several patients developed superficial infection under the eschars and were given either erythromycin stearate, dicloxacillin sodium monohydrate, or tetracycline hydrochloride, depending on sensitivity test results.

Three-millimeter punch biopsy specimens were obtained from the tattoos prior to salabrasion and at various intervals after salabrasion (Table 1). The depth of tattoo pigment was measured from the specimens that were obtained prior to salabrasion, and the depth of necrosis was determined from the specimens that were taken after salabrasion. Tissue sections were stained with hematoxylin-eosin and trichrome.

The amount of scarring was graded as follows: 0, no perceptible scarring; 1, slightly perceptible scarring; 2, mild scarring of a part of the treated area; 3, moderate scarring of a part of the treated area; and 4, severe scarring including hypertrophic scars.

Photographs were obtained prior to salabrasion and at intervals following salabrasion. The percentage of residual pigment was estimated from the photographs.

RESULTS

The patients and the various indexes associated with their tattoos are summarized in Table 1. The depth of pigment in the dermis varied from 0.65 to 2.0 mm; the depth of necrosis after salabrasion varied from 0.2 to 2.2 mm.

There were ten professionally applied tattoos, which had an average depth of pigment of 1.17 mm and a range of 0.75 to 2.0 mm. There were nine amateur tattoos, which had an average depth of pigment of 0.88 mm and a range of 0.7 to 1.4 mm.

A graph of the variables, the depth of necrosis, and the amount of time that the salt was left in situ shows that the depth of necrosis reaches a maximum in a very short period of time and then remains constant (Fig. 1). This is further illustrated in Fig 2, which shows that necrosis occurs very rapidly and does not increase further in the days after salabrasion.

A graph of the percentage of residual pigment and the duration of time that the salt was allowed to remain on the abraded surface was plotted. The percentage of residual pigment decreased rapidly as the salt was left in place for longer periods of

Table 1.—Treatment Data

Patient	Tattoo	Location	Time Salt In Situ, hr	Depth of Pigment, mm	Depth of Necrosis, mm	Residual Pigment, %	Complications
1*	A	Right upper arm	24	2.0	2.0	0	Hypopigmentation; superficial infection; grade 4 scarring
2*	A	Right upper arm	24	1.1	1.0	15	Vitiligo
3*	A	Right upper arm	24	1.5	1.14	10	Hypopigmentation; superficial infection; grade 3 scarring
	B	Right upper arm	6	1.5	1.13	15	Hypopigmentation; grade 2 scarring; infection
	C	Left arm	0.75	0.9	0.7	10	Grade 3 scarring; hypopigmentation
	D	Left arm	1st 0‡	1.25	0.2	35	None
			2nd 0‡	...	...	25	Grade 1 scarring; hypopigmentation
	E	Right upper arm	0‡	...	...	35	Grade 2 scarring
4†	A	Right upper arm	24	0.8	2.0	0	Grade 4 scarring
	B	Right lower leg	24	0.8	2.2	0	Grade 3 scarring
	C	Left leg	24	0.65	1.4	0	Grade 3 scarring
5†	A	Chest	24	1.4	...	0	None
	B	Right dorsa fingers	24	1.0	...	15	Grade 2 scarring
	C	Left dorsa fingers	24	0.7	...	...	Grade 2 scarring
6*	A	Right upper arm	24	0.9	1.6	10	Hypopigmentation; grade 2 scarring
	B	Left upper arm	24	0.8	0.75	10	Hypopigmentation; grade 2 scarring
7*	A	Right forearm	12	0.75	0.76	0	Infection; grade 3 scarring; hypopigmentation
	B	Right forearm	2	1.0	1.0	5	Grade 3 scarring; hypopigmentation
8†	A	Right forearm	6	1.1	1.2	10	Infection; grade 2 scarring
9†	A	Chest	24	0.75	...	0	Hypopigmentation
	B	Left forearm	24	0.75	...	5	Grade 2 scarring; hypopigmentation
10*	A	Right forearm	1st 1.5	...	...	20	None
			2nd 0‡	...	...	15	Hypopigmentation
	B	Left upper arm	0‡	...	...	80	None
	C	Left ventral forearm	0‡	...	...	50	None
	D	Left ventral forearm	0‡	...	...	50	None

*Professional tattoo.
†Amateur tattoo.
‡Salt removed immediately after salabrasion.

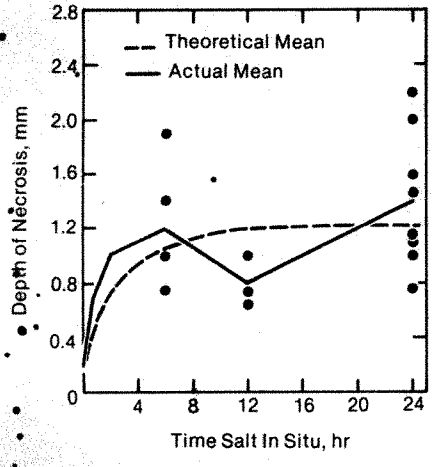

Fig 1.—Depth of necrosis vs time salt in situ.

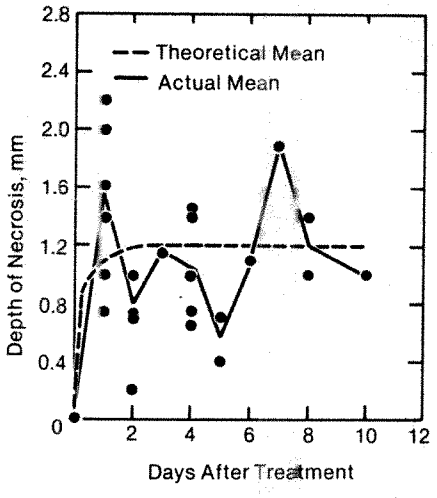

Fig 2.—Depth of necrosis vs number of days after treatment.

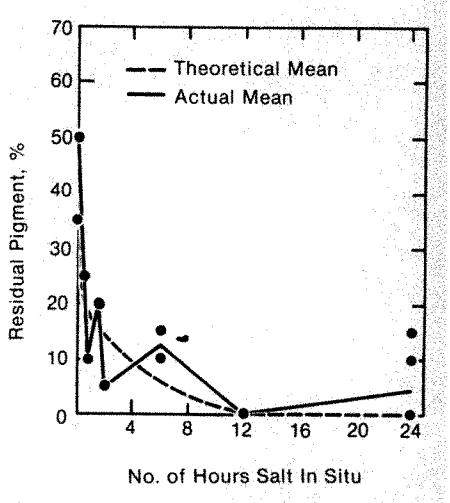

Fig 3.—Percentage of residual pigment vs number of hours salt in situ.

time. The range was from 50%, when the salt was removed immediately, to 5%, when the salt was left on for over 12 hours (Fig 3).

Figure 4 shows the curve for the variables percent residual pigment vs the depth of necrosis. As would be expected, as the average depth of necrosis increases, the percent residual pigment decreases.

HISTOPATHOLOGY

Observation of the surface of the specimens of biopsies from several patients taken immediately after salabrasion showed that there were a few islands of epidermis present on an apparently normal-appearing papillary dermis. No evidence of necrosis of the dermis was present from these specimens.

Observation of the specimens after salabrasion revealed that the exact boundary between necrotic and viable tissue was often difficult to determine. Initially, it seemed logical that one could observe the nuclei of fibroblasts, since they undergo dissolution at their death. However, it was found that the nuclei would often appear relatively normal in a wide zone of tissue beneath obviously nonviable tissue. Because of this, the exact depth of necrosis was sometimes difficult to determine. The trichrome stain was found to clearly delineate the boundary between necrotic and viable tissue. Several other stains were evaluated, but were considered unsuitable.

Biopsy specimens that were taken prior to salabrasion showed that the tattoo pigment was located primarily in macrophages and that only small amounts of pigment were free in the dermis. In sections taken 24 hours after salabrasion, there was an absence of the epidermis, while in the upper part of the dermis there was a large amount of nuclear fragmentation and usually an intense inflammatory infiltrate located in a wide band beneath the zone of necrosis. In a few sections, the specimen at 24 hours showed little or no inflammatory infiltrate. The infiltrate at 24 hours was composed of about 70% neutrophils and 30% mononuclear cells. The pigment at this time was scattered much more diffusely throughout the dermis and much of it was extracellular. There was a pale-staining amorphous layer, with yellowish amorphous material dispersed in aggregates throughout the upper part of the dermis.

After 48 hours, the infiltrate changed to predominantly mononuclear cells. In the viable dermis, much of the pigment again appeared to be in macrophages. Varying amounts of pigment were noted to be located extracellularly in the necrotic portion of the dermis.

The trichrome stain showed a bright red layer of necrotic tissue across the top of the specimens, and a brilliant green layer of viable tissue beneath. This corresponded closely with the necrotic and viable layers of the slides stained with hematoxylin-eosin. The trichrome stains delineated these layers more graphically than hematoxylin-eosin (Fig 5 and 6).

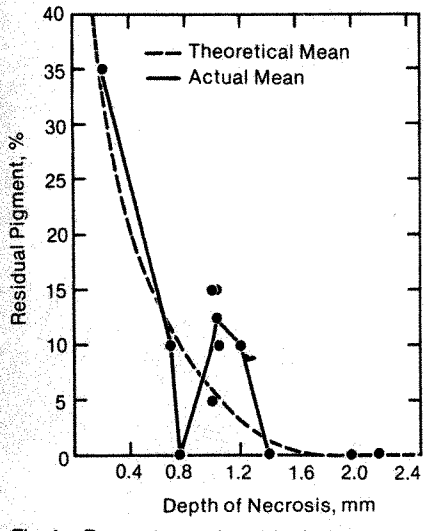

Fig 4.—Percentage of residual pigment vs depth of necrosis.

COMPLICATIONS

Several patients had very good or reasonably good results when the salt was left on for 24 hours, while others, in whom the salt was removed immediately, showed some scarring. Of 26 tattoos, there were 17 (65.3%) that manifested some degree of scarring. When the salt was left on for variable periods of time, scarring occurred in 79% (15/19) of the tattoos. When the salt was removed immediately after salabrasion, 29% (2/7) of the tattoos showed some scarring (Table 2). These inconsistencies are illustrated by the following examples from our patients:

One patient (case 5, A) with an amateur tattoo, in whom the salt was left on the abraded area for 24 hours, showed no scarring or pigmentary changes (Fig 7-9). Another patient (case 9, A) with a professional tattoo, in whom the salt was also left in place for 24 hours, showed slight hypopigmentation and virtually no scarring (Fig 10-12).

Fig 5.—Biopsy specimen taken two days after salabrasion. Salt left in situ 24 hours; necrosis, 1.0 mm (hematoxylin-eosin, magnification ×16).

Fig 6.—Same as Fig 5, using trichrome stain.

Fig 7.—Amateur tattoo on chest.

Fig 8.—Tattoo in Fig 7 immediately after salabrasion.

Fig 9.—Tattoo site in Fig 7 six months later. Salt in situ 24 hours.

Fig 10.—Professional tattoo on chest.

Fig 11.—Tattoo in Fig 10 24 hours after salabrasion.

Fig 12.—Tattoo in Fig 10 six months later. Salt in situ 24 hours.

Fig 13.—Tattoo right upper arm.

Fig 14.—Grade 4 scarring, same tattoo as Fig 13 one year later.

Fig 15.—Tattoo right forearm.

Fig 16.—Same tattoo as Fig 15, grade 3 scarring. Salt in situ on left half of tattoo for 12 hours and on right half of tattoo for two hours.

Fig 17.—Tattoo left forearm.

Fig 18.—Tattoo in Fig 17 three months later showing no scarring. Salt in situ zero hours.

Table 2.—Complication Data

Time In Situ, hr	Total Tattoos	Scarring Grades, No. (%) 0	1	2	3	4	Hypopigmentation
24.0	13	3	0	5	3	2	7
12.0	1	0	0	0	1	0	1
6.0	2	0	0	1	1	0	1
2.0	1	0	0	0	1	0	1
1.5	1	1	0	0	0	0	0
0.75	1	0	0	0	1	0	1
0.0	7	5	1	1	0	0	2
Total	**26**	**9**	**1**	**7**	**7**	**2**	**13**

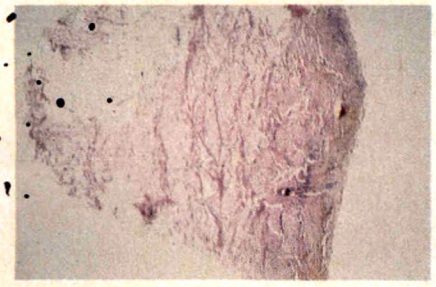

Fig 5

Fig 7

Fig 10

Fig 6

Fig 8

Fig 11

Fig 9

Fig 12

Fig 13

Fig 15

Fig 17

Fig 14

Fig 16

Fig 18

Several of the patients developed scarring. Grade 4 scarring developed in case 1, A, when the salt was left in place for 24 hours (Fig 13 and 14). Grade 3 scarring developed in case 7, A and B, irrespective of whether the salt was left on for 12 hours or two hours (Fig 15 and 16). When the salt was removed immediately, scarring was less likely to occur (cases 3, D, and 10, C) (Fig 17 and 18).

These examples illustrate that some of our patients showed results that conflicted with those we would have anticipated and with those found in the majority of our cases. The possible reasons for this are discussed in the following section.

There was some hypopigmentation of the treated sites, irrespective of the duration the salt was left on the abraded areas. Some degree of hypopigmentation developed in 58% (11/19) when the salt was left on for variable periods and in 29% (2/7) when the salt was removed immediately (Table 2).

Superficial infection occurred in five of the salabraded tattoos. All of these occurred when the salt was left on the salabrasions. In these patients, a thick, leather-like eschar formed that had a tendency to become elevated off the surface of the skin during muscular activity. Once an infection became established under these eschars, elimination was difficult even with the use of antibiotics. In subsequently treated tattoos, the salt was removed immediately after salabrasion and an antibiotic ointment was applied daily. Infection developed in none of these tattoos.

One patient (case 2,A) had a patch of vitiligo in his tattoo prior to salabrasion. After treatment, despite lack of scarring, the entire area showed depigmentation, which appeared clinically as vitiligo.

Most of the patients who had salabrasion without anesthesia experienced varying amounts of pain and were given local anesthesia during later salabrasions.

COMMENT

After salabrasion the necrosis of the epidermis and dermis is hypothesized to take place through an "osmotic shock" created by the hypertonic salt granules. A layer of the skin is probably destroyed within minutes. However, specimens taken immediately after salabrasion were normal, except for the absence of the epidermis, presumably because there was a lag between the injury and the histological appearance of necrosis.

The depth of necrosis increased rapidly as the salt was left on the treated area for longer periods, and after a few hours reached a plateau and did not increase further (Fig 1). This is further illustrated by Fig 2, which shows that maximum necrosis occurred quickly and did not increase in the days following salabrasion. A small increase in the amount of time that the salt is left on the treated area will lead to a relatively great increase in the depth of necrosis and hence scarring. It was virtually impossible to keep the salt off of one end of a tattoo while salabrasion was being performed on the other end, and scarring would sometimes develop at these sites.

The depth of necrosis could also be related to the tissue damage done by the abrasive technique itself. However, several biopsies done immediately after therapy showed the depth of trauma to extend only to the epidermodermal junction, without any immediate evidence of necrosis to the dermis.

Crittenden did not mention the incidence of scarring in his study.[7] Manchester initially commented that "there is occasional atrophic scarring of poor result."[2] Subsequently, he reported that scars developed in 19% of his series and that pigmentary changes developed in 8%.[4] Our results show higher rates of both scarring and pigmentary changes for those tattoos in which the salt was left in place for varying periods. When the salt was removed immediately, our percentage of scarring was slightly greater than Manchester's (29% vs 19%), and our percent pigment change was much greater (29% vs 8%).

It has been stated that a major difference between professionally done and self-inoculated tattoos was that the depth of the pigment was often greater and more variable in the latter.[7-10] In this study, both the average depth of pigment and the variability in depth were actually greater in the professionally done tattoos. It may be that the nonprofessionally done tattoos in this series were applied more carefully than usual.

As might be expected, most of the pigment in a tattoo is located in dermal macrophages. Immediately after salabrasion, a much greater proportion of the pigment is found extracellularly in the dermis. Larnder and Singh have suggested that the salt, being hypertonic, may cause crenation of the pigment-laden macrophages and thus free the pigment, which can be rephagocytized.[5] Indeed, biopsy specimens taken later than 24 hours after salabrasion showed the majority of the pigment to be either in the upper necrotic layer or rephagocytized in neutrophils and macrophages in smaller aggregates than before treatment.

Both Clabaugh and Boo-Chai have suggested that superficial dermabrasion of tattoos creates an inflammatory response that increases the removal of the tattoo pigment.[8,11] Some of the pigment passes to the surface in phagocytes and some is removed by the lymphatics. Larnder and Singh demonstrated with touch preparations that the cellular exudate at the surface of a salabraded tattoo contained abundant pigment.[5] A large amount of pigment is also removed when the necrotic portion of the tattoo heals.

We would hesitate to recommend salabrasion as a method of tattoo removal if the patient is concerned with the eventual cosmetic appearance. For the patient who does not care about scarring, salabrasion can remove the tattoo quickly, often with one treatment. For optimal results, salabrasion should be done only on small areas, and the salt should be removed immediately. When large areas are treated, the salt will sometimes be left on long enough to cause scarring.

Barbara Olsen, RN, provided nursing assistance and advice. Westwood Pharmaceuticals, Inc, paid for the color reproduction of the illustrations.

References

1. Roenigk HH Jr: Tattooing: History, techniques, complications, removal. *Cleve Clin Q* 32:179-186, 1971.
2. Manchester GH: Tattoo removal: A new simple technique. *Calif Med* 118:10-12, 1973.
3. Scutt RWB: The chemical removal of tattoos. *Br J Plast Surg* 25:189-194, 1972.
4. Manchester GH: The removal of commercial tattoos by abrasion with table salt. *Plast Reconstr Surg* 53:517-521, 1974.
5. Larnder DA, Singh J: The fate of the phagocyte in dermabrasion of tattoos with table salt. *Australas J Dermatol* 15:110-114, 1974.
6. Klövekorn GH: Eine einfache methode der Entfernung von Tätowierungen. *Dermat Wochenschr* 101:1271, 1935.
7. Crittenden FR Jr: Salabrasion: Removal of tattoos by superficial abrasion with table salt. *Cutis* 7:295-300, 1971.
8. Clabaugh W: Removal of tattoos by superficial dermabrasion. *Arch Dermatol* 98:515-521, 1968.
9. Wheeler ES, Miller TA: Tattoo removal by split-thickness tangential excision. *West J Med* 124:272-275, 1976.
10. Bailey BN: Treatment of tattoos. *Plast Reconstr Surg* 40:361-371, 1967.
11. Boo-Chai K: The decorative tattoo: Its removal by dermabrasion. *Plast Reconstr Surg* 32:559-563, 1963.

Successful Use of Cyclophosphamide and Prednisone for Initial Treatment of Pemphigus Vulgaris

Michael J. Fellner, MD; James M. Katz, MD; Jonathan B. McCabe

• Previous reports showed that cyclophosphamide used late in the treatment of patients with pemphigus vulgaris reduced the complications due to steroids. In this study, cyclophosphamide was used in the initial treatment of five patients with pemphigus vulgaris in combination with prednisone to avoid side-effects of prednisone. Two patients had no prior treatment with steroids for pemphigus. Results indicate that the initial combined program may be a highly effective treatment method for pemphigus vulgaris. Follow-up from one to four years after treatment shows all five patients in remission; four require no medication.

(*Arch Dermatol* 114:889-894, 1978)

Until 1969, corticosteroids were the only effective reported treatment for pemphigus. During that year the use of an immunosuppressant, in combination with corticosteroids, was reported by several innovators. Lever and Goldberg,[1] and Peck and Osserman[2] reported on their use of methotrexate sodium. Wolff and Schreiner[3] and Krakowski et al[4] reported on the use of azathioprine, and Ebringer and McKay[5] reported on the successful treatment of pemphigus vulgaris with cyclophosphamide.

The use of immunosuppressants by these investigators was prompted by evidence that pemphigus vulgaris involves an autoimmune phenomenon in which the level of autoantibody is correlated with the severity of the skin disease,[2,6,7] and by the serious side-effects of prolonged high-dose corticosteroid therapy. Combined treatment was usually initiated when severe side-effects of prolonged high-dose corticosteroid therapy were as threatening as the disease itself.

In this article we report the use of combined cyclophosphamide and prednisone therapy in the initial treatment for pemphigus vulgaris. By using cyclophosphamide early rather than after side-effects to steroids occurred, it was hoped that a tapering of the prednisone dosage could be achieved and side-effects could be avoided completely.

SUBJECTS, MATERIALS, AND METHODS

Five patients with pemphigus vulgaris were treated with large daily doses of prednisone (usually 200 mg) and 100 to 200 mg of cyclophosphamide (Cytoxan). Two had received no treatment for pemphigus vulgaris prior to our evaluations. The others had received prednisone in doses ranging from 40 to 240 mg/day.

After cyclophosphamide and prednisone therapy was started, our procedure was to taper the prednisone dosage first and then the cyclophosphamide, concordant with the clinical improvement. Only one patient showed adverse effects of prior prednisone treatment: moon facies and diabetes mellitus.

Diagnosis was confirmed by histologic study of hematoxylin-eosin-stained sections from all five patients and by immunofluorescent staining with antihuman IgG conjugated with fluorescein in four of five cases. The indirect test for circulating autoantibodies was done in all five cases. It consisted of blood sera that was layered on guinea pig esophagus as substrate and then was stained with antihuman IgG conjugated with fluorescein isothiocyanate.

REPORT OF CASES

Case 1.—A 66-year-old woman developed a sore throat in November 1974. Her family physician prescribed penicillin to be taken by mouth. Her condition became worse, with blistering of the mouth developing within a few days, and continued to worsen, with onset of fetor oris. She then sought consultation from a dermatologist in her community, who believed hospitalization was required; he referred her to one of us (M.J.F.) for therapy.

On admission to Flower and Fifth Avenue Hospital, she had a foul odor and severe generalized skin lesions with bullae, crusts, and secondary infection (Fig 1). Some lesions were hyperkeratotic and resembled pemphigus vegetans. Biopsy specimens were taken from three areas: a vegetative area on the abdomen, a bulla, and an area of normal-appearing skin. Examination of the vegetative area specimen showed hyperkeratosis, parakeratosis, considerable acanthosis, and elongation of the rete ridges. The subepidermal area showed severe edema, congestion, and infiltration with polymorphonuclear leuko-

Accepted for publication Dec 2, 1977.

From the Department of Dermatology, Bird S. Coler Hospital, Roosevelt Island, NY, and New York Medical College, Flower and Fifth Avenue Hospital.

Reprint requests to Department of Dermatology, Bird S. Coler Hospital, Roosevelt Island, NY 10044 (Dr Fellner).

cytes, including many eosinophils. A biopsy specimen from the bulla showed an intraepidermal cleft with intercellular edema. There was loss of intercellular bridges between cells in areas in the stratum germinativum and edema in the papillary dermis. The biopsy specimen from normal-appearing skin showed thin epidermis with intercellular edema and loss of intercellular bridges in some areas. There was edema of the dermis.

Direct immunofluorescent staining showed intercellular localization of IgG and C3 in involved areas. Indirect staining was positive in a titer of 1:320 during the acute phase.

A regimen of cyclophosphamide, 200 mg daily, and prednisone, 200 mg daily, were started in November 1974. She had received no corticosteroids or immunosuppressives up until this time. Dosages were tapered slowly as the skin cleared. Prednisone was tapered first. This took about three months. The WBC counts ranged from 8,000 to 5,000/cu mm. Several complications occurred, including thinning of the hair on the scalp, transient neutropenia, and guaiac-positive stools. All of the complications were reversible with adjustment of the medication. She was discharged from the hospital with clear skin and on no medication. Follow-up three years later showed that her skin was continually free of lesions.

Case 2.—Sores developed in the mouth of a 69-year-old woman, in February 1973. She sought advice from several physicians and took a variety of medications, including antibiotics, without beneficial effect. Lesions on the arm, legs, trunk, scalp, and genitalia developed within eight weeks, and the patient's mouth was so sore she could tolerate only bland liquids.

Medical history disclosed that the patient had always been in good health and had worked as a ballerina for a number of years. Several members of her family had had psoriasis and diabetes mellitus, including her father and sister.

Examination on admission showed multiple lesions over the back and on the body, with purulent, foul-smelling exudate and oral lesions (Fig 2). The vulva and labia majora and minora also were involved. A culture of pus from the skin demonstrated coagulase-positive *Staphylococcus aureus* sensitive to erythromycin.

A biopsy specimen was taken from a bullous lesion and showed a suprabasilar intraepidermal bulla with acantholytic cells. Direct staining of involved skin for IgG was positive, showing intercellular IgG. Indirect staining was also done on admission and showed an IgG titer for intercellular antibodies of 1:320 (Fig 3).

Therapy was started with 200 mg of prednisone and 150 mg of cyclophosphamide daily in divided doses. The WBC count ranged from 5,000 to 21,000/cu mm. In addition, she received the following drugs daily: erythromycin, 1 g; isoniazid, 300 mg; pyroxidine hydrochloride, 150 mg; a mixture of magnesium hydroxide and aluminum hydroxide gel (Maalox), 20 ml, four times daily; diazepam (Valium), 30 mg; and diphenhydramine hydrochloride (Benedryl), 100 mg. Meralluride sodium (Mercuhydrin), 2 ml intramuscularly, was given every other day. She did well on this regimen, but several penicillins (nafcillin sodium, ampicillin sodium, dicloxacillin sodium monohydrate) were also required to control infection. Diabetes mellitus was diagnosed and was well controlled with diet and 250 mg of tolbutamide given twice daily. The dosage of prednisone was gradually reduced while the cyclophosphamide dosage was maintained at 150 mg daily.

She was discharged approximately two months later in June 1973. Indirect immunofluorescence was negative at that time. The dose of cyclophosphamide was gradually reduced, and finally all medications were discontinued. She was seen on follow-up two years and one month later (July 1975) and was well and free of all lesions (Fig 4). Four years later she was seen again and was well and free of all skin lesions without medication.

Case 3.—A 44-year-old man was admitted to the hospital in March 1974. In January 1974, sores had developed in his mouth that caused him considerable pain and difficulty swallowing. The patient consulted numerous physicians and dentists and was given various medications without obtaining relief. The blistering became more intense and spread to the chest, back, buttocks, and other areas of the body. Medical history disclosed that the patient had had peptic ulcer disease. In addition, the patient reported exposure to many chemicals, such as insect sprays and repellents, associated with his hobby of gardening.

Physical examination showed extensive ulceration of the buccal mucosa and involvement on the chest, where the skin was crusting in many areas. A biopsy showed intraepidermal bulla with acantholytic cells. This patient was started on a regimen of 200 mg of prednisone and 150 mg of cyclophosphamide daily. He was also given a prophylactic ulcer regimen, including phenobarbital, a mixture of magnesium hydroxide and aluminum hydroxide gel, propantheline bromide (Probanthine), and diazepam. The WBC count was 13,000/cu mm and remained within normal range. The mouth lesions required intralesional therapy with triamcinolone acetonide (Kenalog) as well. The patient's skin cleared up and he was discharged six weeks later on maintenance doses of prednisone and cyclophosphamide that were tapered gradually. Five months after all therapy had been discontinued; he was free of lesions (July 1975).

Case 4.—A 60-year-old woman was admitted to Metropolitan Hospital on Nov 10, 1974. The patient had first noted blisters in the mouth four months prior to admission and sought treatment in Florida, where a local practitioner prescribed prednisone tablets to be taken orally for a week. One month prior to admission, blisters had developed that ulcerated on noninflamed bases in both axillae, over midchest, and on the legs. Secondary infection supervened. In addition, mouth lesions recurred, and she complained of a burning feeling in her mouth and throat.

Physical examination of the skin showed large, 5 × 5-cm, flaccid bullae with secondary infection in the axillary, presternal, and mammary regions (Fig 5). Other areas of involvement were the inner thighs and the lateral aspects of the right knee. In addition, multiple vesicles also were present, including several vesicles on the hard palate and lower lip. There was no involvement of the genital mucosa. Vital signs were normal.

Three intact vesicles from the abdomen were obtained. They showed intraepidermal bullae with acantholytic cells (Fig 5).

Direct immunofluorescent staining of biopsy sections showed intercellular deposition of IgG. Indirect staining was also positive. At the height of the eruption, the titer was 1:320; a week later, after treatment, it dropped to 1:40, and in two weeks it was down to 1:4.

The patient was started on a daily regimen of 200 mg of prednisone and 100 mg of cyclophosphamide. The WBC count during this time was initially 9,600/cu mm. It dropped and then returned to normal as medication was tapered. Within a few days she improved remarkably. Because of suspicion of gastrointestinal bleeding and positive stool guaiac test results, a barium enema was administered. Within 24 hours she developed a rigid abdomen and chemical peritonitis from seepage of barium through a damaged colon. She was given a temporary colostomy. Her skin continued to improve and cleared completely by the time she was discharged.

Case 5.—A 70-year-old woman first experienced pain in her mouth and throat ten months prior to admission. Her physician suspected an allergic reaction to indomethacin (Indocin), which she was taking for back pain. Her condition improved temporarily with steroid therapy, but soon she experienced exacerbation of the mouth lesions. She was admitted to the hospital for severe back pain, diagnosed as osteoarthritis, and on admission complained of difficulty swallowing. Examination showed multiple vesicles on the tongue. A tongue biopsy confirmed the diagnosis of pemphigus vulgaris. After admission, lesions developed on the chest and neck. Hematoxylin-eosin stain of the epidermis showed a suprabasilar bulla with acantholytic cells. Direct immunofluorescent stain showed intercellular deposits of IgG and C3. Indirect immunofluorescence also was positive for IgG.

The patient was started on a regimen of prednisone, 100 mg daily, but her condition failed to respond to this dosage. In addition, she began to experience symptoms of dyspepsia. As a result, the patient was given 100 mg of cyclophosphamide and 40 mg of prednisone daily. The WBC count ranged from 9,600 to 4,000/cu mm. The condition gradually improved, and now, 2½ years after onset of disease, she takes maintenance doses of 10 mg of prednisone daily. She has been taking this dose for the past two years and has remained free of the lesions for that time. She complains of pain in the mouth, but no oral lesions are discernible.

Fig 1.—Severe generalized pemph gus vulgaris.

Fig 2.—Pemphigus vulgaris with severe mouth involvement.

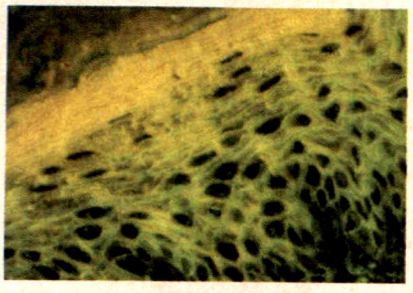

Fig 3.—Indirect test for circulating intercellular antibodies to IgG on guinea pig esophagus (original magnification ×160).

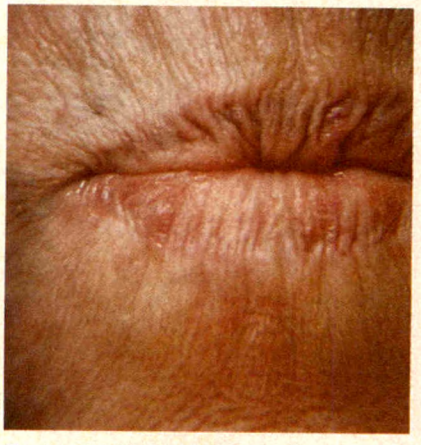

Fig 4.—Healed pemphigus vulgaris.

Fig 5.—Large bullae of mammary region.

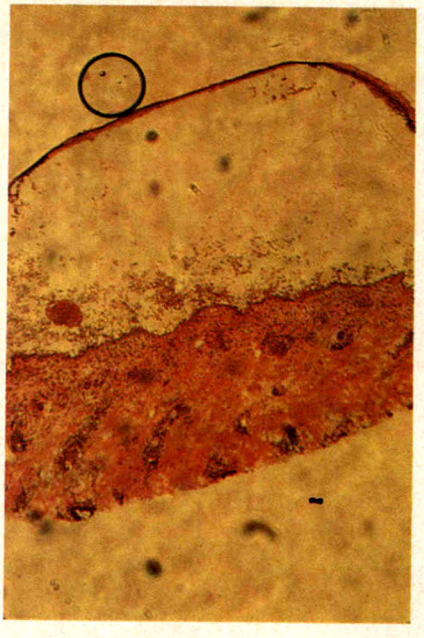

Fig 6.—Intraepidermal bullae with acantholytic cells (hematoxylin-eosin, original magnification ×40).

Table 1.—Summary of Previous Reports of Patients Treated With Cyclophosphamide

Source	Case/Age, yr/Sex	Severity/ Involvement	Initial Prednisone Therapy, mg/Day	Steroid Complications	Prednisone Dose With Cyclophosphamide, mg/Day
Ebringer and McKay[5] (1969)	1/49/F	Severe, generalized mouth	20 ↑ 40 ↑ **200**	Osteoporosis, gastrointestinal bleeding, cushingoid features, hypertension, myopathy, cataracts, mental depression, bony fractures	100 ↓ **10**
McKelvey and Hasegawa[11] (1971)	2/47/M	Explosive, severe body	**100** + 50 intramuscularly 3 times weekly	Diabetes mellitus, myopathy, osteoporosis, bony fractures, severe mental depression, peripheral edema	60 ↓ **10**
Krain et al[12] (1972)	3/61/M	Mouth and body	300 ↓ **120**	Potassium depletion, moon facies, hirsutism, muscle wasting, gastrointestinal bleeding, cataracts, diabetes mellitus, mental depression	120 ↓ 20 ↓ **15**
	4/12/F	Severe, generalized	**300**	Osteoporosis, diabetes mellitus, worsening of epilepsy, cataracts	300 ↓ **35**
	5/35/M	Generalized mouth	60 ↑ 100 ↓ 70 ↓ **25**	Moon facies, buffalo hump, hirsutism, rectal abscess	20 ↓ **125**
	6/67/F	Mucosal: nose, pharynx, vagina	120 ↓ 50 ↓ 20 alternate days 50 ↑ **20**	Osteoporosis, fractures, thrombophlebitis	65 ↓ alternating **25**
	7/27/M	Mouth	80 ↓ 10 ↑ **40**	Glaucoma, cataracts, cushingoid features	40 ↓ 40 alternating with **15**
	8/39/F	Trunk, back, groin	200 ↓ 75 ↓ **60**	Severe moon facies, hirsutism	60 ↓ 50 ↓ 10 ↑ **25**
	9/64/M	Trunk and groin	**60**	Diabetes mellitus and deep mental depression	60 ↓ 10 ↑ **30**
Medved and Maxwell[13] (1972)	10/51/M	Severe, generalized mouth	80 ↑ **100**	Failure to control pemphigus	100 ↓ **25**
	11/71/F	Severe, generalized mouth	**80**	Failure to control pemphigus	12 ↓ 1 dexamethasone
Glickman and Silvers[14] (1972)	12/50/F	Mouth and body	**60**	Cushingoid features, osteoporosis	80 alternate ↓ **0**

Table 2.—Summary of Treatment Schedule and Results of Initial Combined Therapy With Prednisone (P) and Cyclophosphamide (C) in Patients With Pemphigus

Case	Prior Treatment Pemphigus	Initial Dose, mg/Day P	Initial Dose, mg/Day C	Reasons for Combined Treatment	WBCs/ cu mm	Results*
1	None	200	200	Avoid steroid complications	8,000 to 5,000	Skin clear, no complications
2	None	200	150	Avoid steroid complications	5,000 to 21,000	Skin clear, no complications
3	Prednisone	200	150	Peptic ulcer, moon facies, diabetes mellitus	13,000 to normal	Skin clear, no complications
4	Prednisone	200	100	Avoid steroid complications	9,600-dropped, returned to normal	Skin clear, no complications
5*	Prednisone	100	100	Avoid steroid complications, lack of previous response to P alone	9,600-4,000	Skin clear, mouth clear, complains of mouth pain

* Only patient 5 required maintenance doses of 10 mg/day of prednisone. All others experienced remission without additional medication.

COMMENT

Review of Previous Treatment Modalities for Pemphigus With Cyclophosphamide and Other Drugs

The first reported use of cyclophosphamide for pemphigus was by Ebringer and McKay.[5] A woman with pemphigus vulgaris was treated with prednisolone for five years and developed osteoporosis, gastrointestinal bleeding, Cushingoid features, hypertension, myopathy, cataracts, bone fractures, and mental depression. The addition of 200 mg of cyclophosphamide daily permitted reduction of the prednisolone dose from 100 mg/day to a maintenance dose of 10 mg/day.

Jablonska et al[7] summarized the view in 1970, when they wrote that the chief indications for use of immunosuppressive drugs are patients who cannot tolerate large doses of corticosteroids, or in maintenance of patients in remission. Burton et al[8,9] reported using azathioprine with prednisone to control the pemphigus vulgaris of four patients. In two cases prednisone dose was tapered and finally discontinued and patients were maintained in remission with azathioprine alone. In the third case all medication was finally discontinued and the patient appeared to be in permanent remission four years later. In the fourth case, azathioprine was discontinued because of myalgia, vomiting, and a rash. That patient was maintained on 5 mg/day of prednisone with azathioprine. Van Dyck and van Velde[10] reported reduction and elimination of prednisone when azathioprine was used for two patients with pemphigus vulgaris.

Methotrexate also was used with prednisone to alleviate side-effects of prednisone in treating pemphigus vulgaris. In 1969, Lever and Goldberg[1] described three patients who received high doses of prednisone for treatment and maintenance. Their conditions responded well to methotrexate, tapering to low doses of prednisone or none at all. Peck and Osserman[2] were able to control two cases of pemphigus vulgaris with reduced doses of prednisone by using methotrexate.

Cyclophosphamide was also used to gain control and maintain patients with reduced doses of prednisone in 12 reported cases summarized in Table 1.

and Prednisone for Pemphigus Vulgaris

Initial Dose Cyclophosphamide, mg/Day	WBC Count During Cyclophosphamide Treatment	Result of Treatment	Maintenance Doses of Prednisone (P) and Cyclophosphamide (C), mg/Day
200	•	Skin clear, recurrences retreated	None
200	6,000-16,000	Skin clear, diabetes controlled, myopathy clear, ambulatory	10 P alternate days, 100 C
50	6,900-11,000	Skin clear, improved diabetes and depression	50 C and 15 P
100	3,000-4,500 and 1,270-2,600	Skin clear, cataracts	None
50 ↑ 100	6,000-9,000	Skin clear, all side-effects gone	50 C; 50 P alternate days
50 ↑ 100	5,100-9,900	Skin clear, improved diabetes	25 P alternate days; 100 C
50 ↑ 100	6,000-16,000	Skin clear	100 C; 40/15 P alternate days
125 ↑ 150	5,200-6,400, 3,400	Skin clear	20 P
50 ↑ 100	8,900-9,600	Skin clear, improved diabetes mellitus and depression	100 C, 30 P
80	...	Control	7 P, intermittent C
...	...	Clear	1 dexamethasone
150	...	Skin clear	50 C alternate days

As this Table shows, in ten of the 12 reported cases, (cases 1 to 9 and 12), steroid complications were severe at the time cyclophosphamide administration was begun. The two exceptions, reported by Medved and Maxwell,[13] represent failures to control the disease with high doses of prednisone. The average of doses of prednisone prior to combined treatment was 98 mg/day (Table 1, column 4, boldfaced numbers). The average of treatment doses after tapering with cyclophosphamide was 18 mg/day (Table 1, column 6). The average maintenance dose was 13 mg/day incuding three cases in which maintenance doses of prednisone were not given.

Pasricha et al[15] reported the use of cyclophosphamide alone to control active disease and its use in remission as a substitute for prednisone. The authors found that cyclophosphamide alone was ineffective in severe initial situations but was effective in preventing relapses in all four treated cases of pemphigus vulgaris. They concluded that pemphigus patients "should be treated with corticosteroids and once remission sets in, corticosteroids should be completely withdrawn and they should be maintained on oral cyclophosphamide."

Immunosuppressants have also been used alone as initial therapy to control disease. In their first reported series, Lever and Goldberg[1] successfully treated one case of early, localized pemphigus vulgaris with methotrexate alone. In his 1972 report of 36 patients treated with combinations of methotrexate and prednisone, Lever identified three groups of patients.[16] He found that, in the group of severely affected patients with a history of high dose prednisone therapy, use of methotrexate helped stabilize the condition and reduce prednisone dosage. The group already experiencing prednisone side-effects was treated with methotrexate as an alternative. The group of patients with early localized disease was treated with lower doses of prednisone initially in combination with methotrexate.

Roenigk and Deodhor[1] used azathioprine alone with good results. Their report in 1973 included four patients with early pemphigus vulgaris never treated with corticosteroids or not treated with them when azathioprine was initiated. Two of the four were treated successfully with azathioprine. The third required steroids for a flare up, but azathioprine controlled the disease after healing began, and the fourth patient showed mild improvement, but azathioprine was discontinued due to leukopenia and fatigue. Van Dyck and van Velde[10] treated one patient with severe pemphigus vulgaris with azathioprine alone.

Summary of Results of Initial Combined Treatment

Table 2 summarizes the results of initial combined treatment of our five patients. Two of the patients received combined treatment with prednisone and cyclophosphamide as initial therapy as soon as pemphigus was diagnosed. The other three had had some prednisone prior to starting this program of cyclophosphamide plus prednisone.

The lengths of remission range from one to four years, with no maintenance therapy in four of five patients. These patients appear to be in permanent remission. Our overall impression from evaluating the initial combined approach is that prednisone and cyclophosphamide are an effective means of obtaining excellent control, minimizing side-effects, and producing remission in patients with pemphigus vulgaris. Further experience will allow a more conclusive evaluation of this treatment program.

Rationale of Therapy and Pharmacology

Considering the side-effects of cyclophosphamide, Krain et al[12] commented that cyclophosphamide is more effective in immunosuppression and is less toxic than methotrexate or azathioprine; these same findings are also reported by others.[18-21] Infection represents the most likely serious complication of this treatment. Ten percent of patients on oral doses of cyclophosphamide develop cystitis.[19] Bleeding from inflamed bladder mucosa is common in these cases (estimated to occur in 1% to 4% of all patients undergoing cyclophosphamide treatment) and can be dangerous.[19] A high fluid intake and a daily urinalysis are recommended for patients taking cyclophosphamide. Alopecia has also been reported but is reversible.

Wall and Clausen[20] report strong evidence of the chemical carcinogenicity of cyclophosphamide when taken in high doses for prolonged periods of time. In their report, tumors of the urinary bladder occurred in patients who had high doses of cyclophosphamide one to ten years previously and in four of five patients who developed hemorrhagic cystitis. In these five patients, treatment lasted an average of four years and amounted to an average of 200 g/patient. For comparison with these data, it is notable that the total dose

maximum for our patients did not exceed 20 gm, or 10% of the average dose administered by Wall and Clausen.

The only adverse effects we encountered in our series were reversible neutropenia and reversible alopecia. In contrast, the morbidity from steroids included peptic ulcer lesions, diabetes mellitus, cushingoid appearance, and gastrointestinal bleeding.

Cyclophosphamide is chemically related to the mechlorethamine hydrochloride alkylating agents chlorambucil and triethylenemelamine. It cross links nucleic acids and proteins and interferes with DNA synthesis in the S phase of the cell cycle.[18] This chemical action is useful in killing neoplastic cells that have high mitotic rates, DNA synthesis, and proliferation. It has also been shown to have a strong immunosuppressant effect in man, both for humoral and cellular responses, although the effect for antibodies is more pronounced. Gershwin et al have reviewed the immunosuppressive properties of cyclophosphamide in detail.[21]

Rationale for the initial combined treatment we used is the presumption that the combination of cyclophosphamide and prednisone have a strong effect on suppressing the abnormal B cells that produce IgG and complex with skin to produce the disease. Improvement in the clinical picture is expected within ten days to three weeks, based on the known half-life of IgG, which is about 21 days. Recent reports have indicated a subgroup of IgG, IgG_3, with a shorter half-life of six or seven days. Further work is required to determine what is the spectrum of IgG involved in pemphigus and whether these differences affect prognosis.

Drugs, Chemicals and Pemphigus

Finally, it is interesting to note that several of the patients had considerable exposure to chemicals. This was either environmental, as in gardening, or in the form of exposure to penicillin before the onset of pemphigus symptoms. Krain et al,[22] indicating the importance of genetic factors in some patients, mention viruses, ultraviolet light, and drugs as potential inducers of pemphigus.

Since this manuscript was accepted for publication, Lever and Schaumburg-Lever[23] described their good experience using three immunosuppressants in combination with prednisone. Their protocol differed from ours since they used relatively low doses of prednisone (40 mg) and gave it on alternate days, while we used daily doses generally in the high range (more than 100 mg). Our results in patients free from lesions and off all medication indicate the advantage of the initial combination method of treatment for pemphigus. It seems logical to use initial combination treatment in severe cases to reduce the levels of obnoxious antibodies rather than to use high dose treatment with prednisone initially.[23]

This investigation was supported by a grant from the John A. Hartford Foundation, Inc.

Amelia Su-hui Chen performed the fluorescent laboratory stains.

Nonproprietary Names and Trademarks of Drugs

Ampicillin sodium—*Alpen-N, Amcill-S, Omnipen-N, Penbritin-S for Injection, Polycillin-N for Injection.*

Azathioprine—*Imuran.*

Cyclophosphamide—*Cytoxan.*

Dicloxacillin sodium monohydrate—*Dycill, Dynapen, Pathocil, Veracillin.*

References

1. Lever WF, Goldberg HS: Treatment of pemphigus vulgaris with methotrexate. *Arch Dermatol* 100:70-78, 1969.

2. Peck SM, Osserman KE: Studies in bullous diseases: Treatment of pemphigus vulgaris with methotrexate, two patients. *J Mt Sinai Hospital* 36:71-76, 1969.

3. Wolff K, Schreiner B: Immunosuppressant therapie bei pemphigus vulgaris. *Arch Klin Exp Dermatol* 235:63-77, 1969.

4. Krakowski A, Covo J, Rozanski Z: Pemphigus vulgaris. *Arch Dermatol* 100:117, 1969.

5. Ebringer A, McKay IR: Pemphigus vulgaris successfully treated with cyclophosphamide. *Ann Intern Med* 71:125-127, 1969.

6. Beutner EH, Jordan RE: Demonstration of skin antibodies in sera of pemphigus vulgaris patients by indirect immunofluorescence staining. *Proc Soc Exp Biol Med* 117:505-510, 1964.

7. Jablonska S, Chorzelski T, Blaszczyk M: Immunosuppressants in the treatment of pemphigus. *Br J Dermatol* 83:315-323, 1970.

8. Burton JH, Greaves MW, Marks JM, et al: Azathioprine in pemphigus vulgaris. *Br Med J* 3:84-86, 1970.

9. Burton JH, Greaves MW: Azathioprine for pemphigus and pemphigoid: A four-year follow-up. *Br J Dermatol* 91:103-109, 1974.

10. Van Dyck TJA, van Velde JH: Treatment of pemphigus and pemphigoid with azathioprine. *Dermatologica* 147:179-185, 1973.

11. McKelvey EM, Hasegawa J: Cyclophosphamide and pemphigus vulgaris. *Arch Dermatol* 103:198-200, 1971.

12. Krain LS, Landau JW, Newcomer VD: Cyclophosphamide in the treatment of pemphigus vulgaris and bullous pemphigoid. *Arch Dermatol* 106:657-661, 1972.

13. Medved A, Maxwell I: Intermittent cyclophosphamide in pemphigus vulgaris and bullous pemphigoid. *Can Med Assoc J* 111:245-250, 1974.

14. Glickman FS, Silvers SH: Pemphigus vulgaris treated with cyclophosphamide. *Arch Dermatol* 107:467-468, 1973.

15. Pasricha JS, Sood VD, Minocha Y: Treatment of pemphigus with cyclophosphamide. *Br J Dermatol* 93:573-576, 1975.

16. Lever WF: Methotrexate and prednisone in pemphigus vulgaris: Therapeutic results obtained in 36 patients between 1961 and 1970. *Arch Dermatol* 106:491-497, 1972.

17. Roenigk HH, Deodhor S: Pemphigus treatment with azathioprine: Clinical and immunological correlation. *Arch Dermatol* 107:353-357, 1973.

18. Grieco MH: Immunosuppressive drug therapy. *Drug Therapy* 1:9, 1971.

19. Pecker JL: Cytotoxic drugs in treatment of nonmalignant diseases. *Ann Intern Med* 76:619-642, 1972.

20. Wall RL, Clausen KP: Carcinoma of the urinary bladder in patients receiving cyclophosphamide. *N Engl J Med* 293:271-273, 1975.

21. Gershwin ME, Goetzl EJ, Steinberg AD: Cyclophosphamide use in practice. *Ann Intern Med* 80:531-537, 1974.

22. Krain LS, Terasaki PJ, Newcomer VD, et al: Increased frequency of HL-A10 in pemphigus vulgaris. *Arch Dermatol* 108:803-805, 1973.

23. Lever WF, Schaumburg-Lever G: Immunosuppressants and prednisone in pemphigus vulgaris. *Arch Dermatol* 113:1236-1241, 1977.

Speckled Lentiginous Nevus

Daniel M. Stewart, DO; Jules Altman, MD; Amir H. Mehregan, MD

• Speckled lentiginous nevus is, we feel, a distinctive nevocytic disorder and a clinical variety of nevus-cell nevus. The speckled areas show varying histological patterns that range from nevus incipiens to junctional and compound nevi. The background shows histological features of lentigo simplex. It is our contention that speckled lentiginous nevus should be separated from nevus spilus and nevus spilus tardus (Becker's), which we consider to be variants of epidermal nevus.

(*Arch Dermatol* 114:895-896, 1978)

We present the cases of six patients with a nevoid disorder that appears as small, dark hyperpigmented speckles superimposed on a tannish-brown background.

There is considerable confusion in the literature concerning the terms "nevus spilus," "speckled nevus spilus," and the recently described "zosteriform lentiginous nevus." The purpose of this paper is to define these terms and clarify the relationship between these entities and the one entity that we are describing as "speckled lentiginous nevus."

To classify these nevi and agree on the proper nomenclature, we shall clarify and separate various terms:

Lentigo simplex: These are well-defined, dark brown to black macular spots. Histologically, the lesion shows uniform epidermal hyperpigmentation together with a uniform increase in the number of junctional melanocytes.

Nevus incipiens: While some lentigines persist indefinitely in their macular form, many become clinically palpable, and that coincides with the appearance of nests of nevus cells at the junction. This nevus incipiens, in which features of lentigo and junction nevus are combined, gradually transforms into the common junction nevus, or the latter may arise de novo. One may encounter tumors in which all stages from lentigo to intradermal nest formation are present simultaneously.[1]

Nevus spilus: These are larger, well-defined, uniformly light to dark brown plaques. Histologically, there is an even thickening of the epidermis and epidermal hyperpigmentation with no obvious increase in the number of epidermal melanocytes or evidence of nevus-cell nest formation.

Accepted for publication Nov 4, 1977.

From the Department of Dermatology, Wayne State University School of Medicine, Detroit.

Reprint requests to Department of Dermatology and Syphilology, Wayne State University School of Medicine, Gordon H. Scott Hall of Basic Medical Sciences, 540 E Canfield Ave, Detroit, MI 48201 (Dr Stewart).

SUBJECTS

Pertinent clinical data on the six cases are summarized in the Table. The age of onset of the lesions, except in case 4, was at birth or in early infancy. Each lesion began as a macular, hyperpigmented light brown patch with the subsequent development of discrete flat or sightly elevated darkly pigmented speckles. Three female and three male subjects constitute the series. Cases 1 through 3 were seen initially with lesions on the trunk (Fig 1). In case 4, the lesion was located on the left breast. In case 5 (Fig 2), lesions followed a zosteriform distribution over the right mandible, auriculotemporal area, and scalp. In case 6, the lesion initially occurred on the right Achilles tendon.

HISTOPATHOLOGY

In general, the histological patterns of our cases showed similar features, but varied in degree. The tannish-brown background revealed changes consistent with lentigo simplex. The epidermis appeared slightly acanthotic, and the rete ridges were slightly elongated and showed diffuse hyperpigmentation. An increase in the number of pigment-forming melanocytes was also part of the picture in this area (Fig 3).

The biopsy specimen of the deeply pigmented speckled lesions showed histological variations. In some specimens, nests of pigmented nevus cells were present at the dermoepidermal junction (Fig 4). In other specimens, in addition to junctional nests, there were numerous nevus-cell nests in the underlying dermis (Fig 5). Areas of transition from lentigo simplex to junctional nevus with a definite increase in the number of junctional melanocytes and beginning nevus-cell nest formation in connection with the tips of rete ridges were also found. These areas were considered to be consistent with the nevus incipiens.

In summary, the histological findings of these nevi showed varied patterns that ranged from a tannish-brown background of lentigo simplex to nevus incipiens. The dark speckled areas showed varied patterns of junctional and compound nevus.

COMMENT

Nevus spilus was originally described by Bulkley,[2] Kaposi,[3] and Besnier et al[4] in the late 1800s as a uniform macular spot of hyperpigmentation. Pinkus and Mehregan, in their textbook,[5] state that nevus spilus does not differ histologically from ephelis (freckle) except for the facts that it covers a larger stretch of

Clinical Data for Patients With Speckled Lentiginous Nevus

Case No.	Sex	Age at Onset	Age at Evaluation, yr	Clinical Descriptions	Initial Clinical Diagnosis
1	F	Birth	11 mo	Cafe-au-lait spot on left lower portion of abdomen with many small macular, hyperpigmented lesions forming within one area	Junctional or compound nevus in cafe-au-lait spot
2	F	Infancy	11	6-cm cafe-au-lait spot on left lower portion of abdomen with freckles and moles scattered throughout	Speckled nevi over cafe-au-lait spot
3	M	Birth	15	Macular tannish-brown background superimposed by many darker speckled macules	Speckled nevus spilus
4	F	Birth	39	4 × 3-cm lesion on left medial aspect of breast consisting of light brown patch with brown papules and nodules interspersed throughout and elevated macular lesions	Speckled Nevus
5	M	4 yr	8	Multiple lentigines within patch of light brown background; areas involved are chin, right auriculotemporal area, and scalp	Zosteriform lentiginous nevus
6	M	Infancy	14	Lesion located on Achilles tendon on right foot measured 3 × 4 cm and consisted of background of light brown uniformly colored macule within which were numerous 2 to 3-mm, dome-shaped and slightly darker lesions	Speckled pigmented nevus

Fig 1.—Speckled darkly pigmented macules on tannish-brown background located on trunk.

Fig 2.—Left and right, Darkly pigmented speckles on tannish-brown background in zosteriform distribution on right side of cheek.

Fig 3.—Biopsy specimen of tannish-brown background showing epidermis slightly acanthotic with elongation of rete ridges along with diffuse hyperpigmentation and increase in number of pigment-forming melanocytes (silver stain, original magnification ×500).

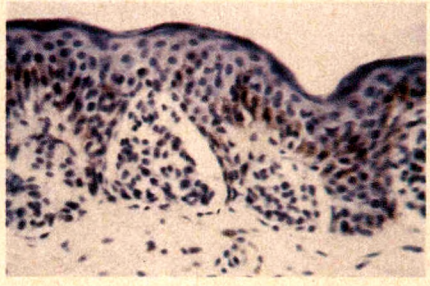

Fig 4.—Biopsy specimen of early, deeply pigmented speckled lesion showing nests of pigmented nevus cells at dermoepidermal junction (hematoxylin-eosin, original magnification ×500).

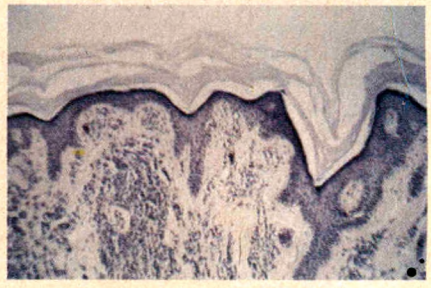

Fig 5.—Biopsy specimen of old pigmented speckled lesion showing junctional nests along with numerous nevus-cell nests free in underlying dermis (hematoxylin-eosin, original magnification ×100).

epidermis and that no nevus cells are present in nevus spilus.

In 1952, Ito and Hamada reported 21 cases of nevus spilus.[6] The authors, however, limited the term of nevus spilus to mean a pigmented macule containing dark pigmented speckles. Biopsy specimens obtained in four of the 21 cases showed no nevus cells. No mention, however, was made as to whether biopsies were performed on the pigmented background or speckled portions of the lesions.

In October 1970, Cohen et al reported on cases similar to Ito and Hamada.[7] They reported on 17 patients with patchy speckled melanotic lesions. In biopsy specimens that were obtained in five cases, nevus cells were present in the speckled and nonspeckled areas. On the basis of their biopsy findings, they concluded that nevus spilus represented a melanotic macular lesion that is dotted with darker speckles. Nevus cells were present both in the darker and lighter tan portions of the lesions.

In June 1973, Matsudo et al, reported on three cases of zosteriform lentiginous nevus.[8] The authors considered these cases to be a previously undescribed nevoid entity consisting of a giant pigmented linear band that is composed of multiple black speckles.

Biopsy specimens of the speckled areas showed regular epidermis with regular papillary projections. The basal layer showed an increase in numbers of melanocytes and an increased amount of pigment in the basal keratinocytes. Electron microscopy showed the theques to be composed of type B (Mishma) cells with electron-dense melanosomes and few premelanosomes.

We would prefer to retain the original clinical concept of nevus spilus as a flat macular patch without speckles that histologically shows mild acanthosis and papillomatosis, with an increase in melanin pigment but without an increase in the number of melanocytes and without nevus-cell nest formation.

We consider nevus spilus to be a variant of epidermal nevus. It would appear quite logical to consider nevus spilus tardus (Becker's nevus) to be closely related to nevus spilus and a variant of epidermal nevus since nevus spilus tardus shows similar histological findings of acanthosis and papillomatosis, with an increase in melanin pigment but without an increase in the number of melanocytes, including those of hyperplastic hair follicles and sebaceous glands.

Conversely, it is our concept that speckled lentiginous nevus and zosteriform lentiginous nevus are closely related to melanocytic or nevus-cell proliferation. Our biopsy specimens of the dark speckled areas showed either lentigo simplex, nevus incipiens, or frank junctional nevus, which makes it logical to interpret these lesions as a variant of nevus-cell nevus.

The question arises concerning the malignant potential because the lesion represents a localized group of melanocytic nevi. However, to our knowledge, no malignancy has been reported in speckled lentiginous nevus.

We feel that these lesions are not uncommon, however, and before the malignant potential is decided, the lesions should be observed during a long period of time.

This investigation was supported in part by a grant from Detroit General Hospital Research Corp.

The cost of color reproduction was paid by Westwood Pharmaceutical Co.

References

1. Pinkus H, Mehregan A: *A Guide to Dermatohistopathology*, ed 2. New York, Appleton-Century-Crofts, 1976, p 459.

2. Bulkley HD: Lecture on the classification and diagnosis of diseases of the skin. *NY Med Gazette* 2:97, 1842.

3. Kaposi M: *Hautkrankheiten*. Vienna, Urban and Schwartzenberg, 1887, p 583.

4. Besnier E, Brocq L, Jacquet L: *La pratique dermatologique*. Paris, Masson et Cie, 1902, p 565.

5. Pinkus H, Mehregan A: *A Guide to Dermatohistopathology*, ed 2. New York, Appleton-Century-Crofts, 1976, p 446.

6. Ito M, Hamada Y: Nevus spilus en Nappe. *Tohoku J Exp Med* 55:44, 1952.

7. Cohen HJ, Minkin W, Frank SB: Nevus spilus. *Arch Dermatol* 102:433-437, 1970.

8. Matsudo H, Reed WB, Homme D, et al: Zosteriform lentiginous nevus. *Arch Dermatol* 107:902-905, 1973.

Nosocomial Outbreak of Scabies

James J. Gooch, DPH; Stanley R. Strasius, MD; Betty Beamer, RN; Michael D. Reiter, PharmD; Gene W. Correll

• During the last quarter of 1976, a nosocomial outbreak of scabies occurred in a 558-bed community teaching hospital. There had been scattered reports of scabies throughout Michigan for nearly a year prior to this outbreak. The epidemic spread of scabies from a patient to 38 hospital employees and their families and associates was identified from historical, clinical, and microscopic skin preparation data.

(*Arch Dermatol* 114:897-898, 1978)

Scabies, a disease caused by infestation with the itchmite *Sarcoptes scabiei*, has once again become a major health problem. It is not a reportable disease and therefore only limited data on its past or present incidence in the United States are available. Within the past few years, an increase in its incidence in the United States has been suggested by several investigators,[1-7] by reports to the Center for Disease Control,[8-10] and by the Michigan Department of Public Health.[11] Infestations are seen in all socioeconomic groups and community settings, including in schools and in health care institutions. This report will describe an epidemic of scabies in 1976 that involved a 558-bed community teaching hospital in Michigan. The data for this report was collected by the hospital epidemiologist from private physicians, clinics, and clinical laboratories located in the hospital community.

SUBJECTS AND METHODS

The index of suspicion of a scabies outbreak began in October, when five nurses assigned to the same ward reported to the Employee Health Service with complaints of intensely pruritic papules on the abdomen, arms, waist, and axillary areas. A consultant dermatologist diagnosed scabies in all five cases, and the nurses had microscopic skin preparations positive for *S scabiei*.

On the basis of the clinical and laboratory findings, an epidemiologic investigation was initiated. A review of the patient-care assignment schedules for the five nurses identified several patients common to all five nurses. A skin preparation taken from one of these patients was found to be positive for *S scabiei*.

The patient was a 90-year-old woman who was admitted to the hospital Sept 26, 1976, with a generalized dermatitis (erythematous papular rash) of unknown etiology. The patient was reportedly well until two months prior to her admission, when she suddenly developed a generalized pruritic rash over her entire body. Because the patient was receiving medications for a chronic urinary tract infection, the rash was initially thought due to an allergic reaction to sulfa. The medication was discontinued and the patient was given a steroid burst, which seemed to help a little. Two weeks prior to admission, the rash became more severe and itching developed. On admission, the patient was seen by a dermatologist, who felt that the rash was largely due to either a neurodermatitis or an exfoliative dermatitis. On the 12th day of hospitalization, a skin scraping from the patient was found to be positive for *S scabiei*. The patient died Oct 15, 1976, of a medical problem unrelated to scabies.

A total of 86 hospital employees who had both direct and indirect contact with the scabietic patient were identified and examined. Scabies was diagnosed clinically in 38 cases (Figure): 30 hospital employees, seven family members and associates of infested hospital employees, and one funeral-home employee who had handled the remains of the scabietic patient. Twenty-five of the 38 cases of scabies were confirmed by historical, clinical, and microscopic skin preparation findings, while another 13 cases were diagnosed on the basis of historical and clinical findings only. As shown in the Figure, the first known cases of scabies occurred on Oct 7, some 12 days after the scabietic patient was admitted to the hospital. The incubation period (time from exposure to onset of symptoms), varied from short and precise in some cases to prolonged and uncertain in others. In general, the incubation period ranged from seven to 27 days, with an average of 12 days.

A massive treatment program was initiated on Oct 20, 1976. All cases of clinically diagnosed scabies were treated with 1% gamma benzene hexachloride lotion. Complete verbal and written counseling regarding the proper application of the lotion and cleaning of bedding and clothing was provided to each person. With respect to proper lotion application, each person was given the following instructions: (*a*) Take a hot soapy bath or shower; (*b*) After drying the skin, apply a thin layer of lotion over the entire skin surface, including the surrounding hair, leave on for 24 hours, and then wash off thoroughly; (*c*) Put on freshly laundered or dry-cleaned clothing.

Persons were told that itching might persist for several days after treatment and should not be regarded as a sign of reinfection. Therapy was not to be repeated unless the itching persisted for ten to 14 days, and then only if new lesions were developing.

All members of household in which one person had had a positive test were simultaneously treated with the lotion to avoid reinfection of treated individuals through contact with asymptomatic but infested household members. Many employees who reportedly had had direct contact with the scabietic patient and members of families with one positive case did not acquire the infestation and did not receive prophylactic treatment. Several additional cases of scabies occurred after the massive treatment program was initiated in October (Figure). However, all cases were successfully treated with the topical application of 1% gamma benzene hexachloride.

COMMENT

It was concluded that the nosocomial outbreak of scabies reflected the increasing prevalence of scabies in the hospital community. During the 16 months prior to this nosocomial outbreak, some 30 counties in Michigan had experienced similar outbreaks of scabies.[11] These outbreaks occurred in families, groups of schoolchildren, and persons working in medical-care facilities.

In this outbreak, transmission occurred primarily through intimate direct contact with a scabietic individual. The transmission of scabies did not occur in those persons who were exposed indirectly and inanimate objects were not implicated as a major transfer source of mites. The delay in diagnosing the case of the patient admitted with scabies was a major factor in the outbreak. In the judgment of the dermatologist, the patient did not have a classic textbook picture of a scabietic infestation. However, in retrospect, clues gleaned from the

Accepted for publication Feb 23, 1978.

From the Departments of Pathology (Dr Gooch), Internal Medicine (Dr Strasius), Personnel (Ms Beamer and Mr Correll), and Pharmacy (Dr Reiter), St Joseph Mercy Hospital, Ann Arbor, Mich. Dr Gooch is now with the Medical Division, E. I. du Pont de Nemours & Co, Inc, Wilmington, Del.

• Reprint requests to Medical Division, E. I. du Pont de Nemours & Co, Inc, Wilmington, DE 19898 (Dr Gooch).

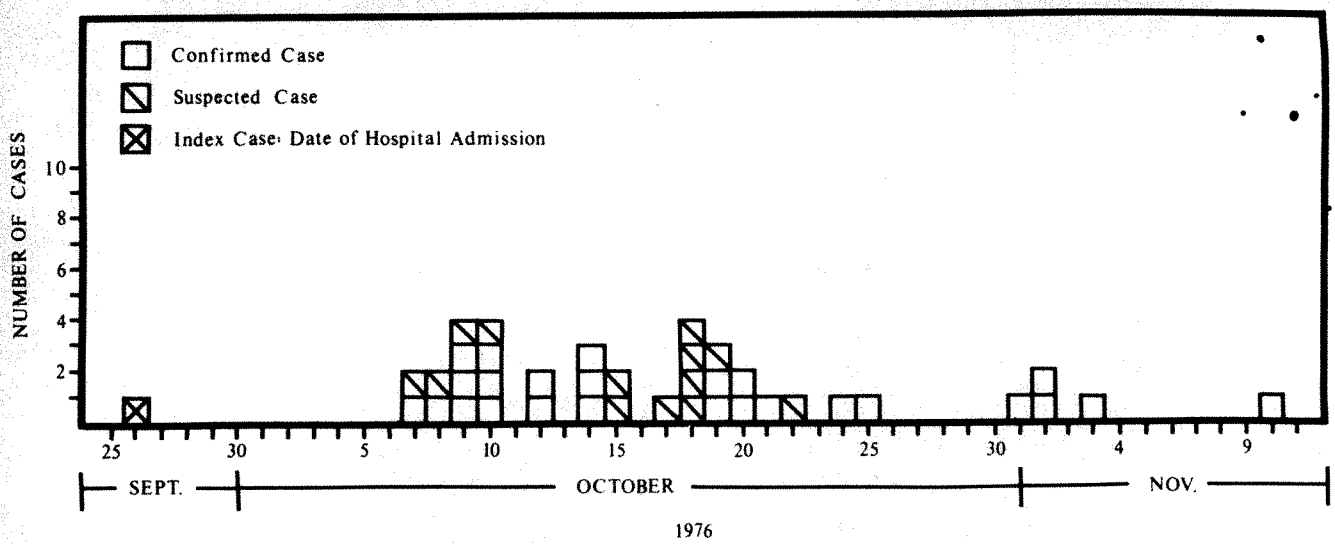

Cases of scabies by date of onset.

patient's history were indicative of scabies. Further, the high attack rate is suggestive of the highly contagious form, Norwegian (crusted) scabies.[12,13]

Norwegian scabies is usually characterized by vast numbers of mites in the exfoliating scales and delayed clinical diagnosis. No other cases of scabies in this epidemic in any way resembled Norwegian scabies. As with the index case in this outbreak, scabies are often mistakenly treated with local and sometimes systemic corticosteroids, which may cause amelioration of symptoms and signs while the infestation persists.[2,5] The resultant clinical picture is atypical and more difficult to diagnose while the infestation and transmissibility persists.[2,5]

As in other reported instances,[1,6,7] this outbreak is a further example of a patient with scabies who serves as a source for other cases of scabies. Nevertheless, the massive treatment program appeared to have been effective in terminating the epidemic. Although crowding and poverty have generally been associated with scabies, these factors were not important in this reported outbreak. The epidemic affected a population in which high levels of personal hygiene prevailed. Patients suspected or known to have scabies should be placed on wound and skin precautionary regimens to avoid direct contact transmission of scabies to hospital personnel and other patients.

When such an epidemic occurs in an institutional setting, an important issue is the concern of individuals who were in contact, or who felt they might have been in contact, with infected persons. In this instance, several measures were taken that counteracted on onset of panic.

(1) A dermatologist's advice as to prescribed and contraindicated treatment was sought by the pharmacist and reviewed with the employee health physician.

(2) Free supply of 1% gamma benzene hexachloride lotion was made available to employees and their families through the pharmacy on authorization from the employee health physician.

(3) An information sheet was developed and circulated to potentially exposed employees about scabies, its treatment, prophylactic treatment, any contraindications of the treatment and identifying the Employee Health Service as a source of treatment and furthur information.

(4) The epidemiologist sought out all possible contacts and had the necessary diagnostic work performed through Employee Health Service, which served as a control point. Pharmacy records also served as a secondary control point.

As a result, severe panic and dissatisfaction was prevented, a central source of information and control was established, and an effective proactive program of follow-up and treatment was secured. Of primary importance were the availability of highly competent professionals: the pharmacist, the employee health physician, the employee health nurse specialist, the administrative assistant for personnel, and the epidemiologist. Of primary importance was the consistent communication between and from these individuals.

The authors thank those individuals and clinics who provided data that led to the early discovery and irradication of this epidemic.

References

1. Heydon JR, Caplan RN: Epidemic scabies. *Arch Dermatol* 103:168-173, 1971.
2. Orkin M: Resurgence of scabies. *JAMA* 217:593-597, 1971.
3. Shaw PK, Jaranck DD: Recent trends in scabies in the United States. *J Infect Dis* 134:414-416, 1976.
4. Hurwitz S: Scabies in babies. *Am J Dis Child* 126:226-228, 1973.
5. Orkin M: Today's scabies. *JAMA* 233:882-885, 1975.
6. Bernstein B, Mihan R: Hospital epidemic of scabies. *J Pediatr* 83:1086-1087, 1973.
7. Biro L, Price E: An epidemic of scabies. *JAMA* 226:1568, 1973.
8. Scabies. *Morbidity Mortality Weekly Rep* 20:445, 1971.
9. Scabies. *Morbidity Mortality Weekly Rep* 24:118-123, 1975.
10. Current trends: Increased scabies incidence. *Morbidity Mortality Weekly Rep* 10-15, 1976.
11. *Scabies: Epidemiology and Management.* Weekly Surveillance Report, Michigan Department of Public Health, May 14, 1976.
12. George M: Norwegian scabies. *Arch Dermatol* 78:320-324, 1958.
13. Maguire HC Jr, Kligman AM: Norwegian scabies. *Arch Dermatol* 82:62-64, 1960.

Bullous Pemphigoid in Children

Maj J. Wendall Robison, MC, USA, Lt Col Richard B. Odom, MC, USA

• Bullous pemphigoid in children appears to be the same disease as its adult counterpart based on a case in a 3-year-old boy. Generalized tense bullae over the skin and oral mucosa, characteristic direct and indirect immunofluorescence, elevated IgE levels, blood eosinophilia, and therapeutic response to corticosteroids parallel the disease in adults. The long-term prognosis, however, is still unknown. A review of bullous pemphigoid in children is presented.

(*Arch Dermatol* 114:899-902, 1978)

Bullous pemphigoid is one of the chronic nonhereditary bullous diseases. Its incidence in children is unknown and believed to be rare. Bullous pemphigoid in children (BPC) appears to be not unlike the adult form in having characteristic clinical and histopathologic features, as well as diagnostic immunofluorescent findings. Tense, nongrouped bullae arise on normal and erythematous skin. Many lesions begin as urticarial plaques with irregular borders simulating erythema multiforme. Sites of predilection include the flexural areas—neck, axillae, groin, wrists, and antecubital and popliteal fossae—and, less frequently, the face, buttocks, and oral mucosa. Pruritus is an important but variable complaint. Histologic findings include a subepidermal bulla with variable numbers of eosinophils. Diagnostic direct immunofluorescence consists of linear deposition of IgG and complement (C3) at the basement membrane zone (BMZ), and indirect immunofluorescence also shows IgG at the BMZ.[1-4]

To our knowledge only 14 cases of immunofluorescent-positive BPC have been reported (Table).[5-11] Few of those reported cases provide a full description of the clinical course and treatment. The limited amount of clinical data regarding the immunofluorescent positive cases of BPC is too small to draw conclusions regarding the full clinical course, prognosis, or treatment of BPC. This report describes a case of BPC and reviews the literature.

REPORT OF A CASE

A 3-year-old boy was seen in our emergency room in December 1976 with an intensely pruritic, generalized skin eruption of three days' duration. He also had symptoms of an upper respiratory infection. Examination showed an afebrile child with excoriated papules and plaques over the buttocks, lower back area, ankles, and scrotum. There was an excoriated, papulovesicular eruption on the face, and submandibular lymphadenopathy was present. The diagnoses made by the attending physician included scabies of the trunk and extremities and herpes simplex of the face. Prescribed medications included an elixir containing brompheniramine maleate, phenylephrine hydrochloride, and phenylpropanolamine hydrochloride bacitracin, and gamma benzene hexachloride. His father had previously applied penicillin ointment to the lesions.

Two days following his first visit, the patient was given oral penicillin doses for impetigo. Because of a continually worsening course, he was admitted to the Pediatric Service on the third day with a rectal temperature of 38 °C. Examination disclosed impetiginized, pseudoumbilicated vesicles and pustules over the lips, nares, cheeks, chin, eyelids, penis, scrotum, buttocks, lower back, and axillae (Fig 1). Lesions extended onto the mucous membrane of the lower lip. Some of the bullous lesions assumed a rosette pattern. A diagnosis of bullous impetigo was made, and administration of dicloxacillin was begun. *Staphylococcus aureus* grew from the cultures of the skin lesions. The possibility of eczema herpeticum was also entertained. Bacterial and viral cultures of the throat, nasopharynx, and urine specimen showed no growth of organisms. Viral cultures of the bullae also showed no growth. Normal admission laboratory test results included hematocrit reading, serum electrolyte values, blood glucose level, and urinalysis. The WBC count was 12,000/cu mm, with a differential cell count of 37% neutrophils, 54% lymphocytes, 5% monocytes, 4% eosinophils, and 1% basophils.

The patient's condition improved during a five-day afebrile hospital course, and when he was discharged many areas were clearing. New lesions began developing while he was at home, and the patient was readmitted on the tenth day after discharge. There were multiple, large, tense, noninflamed bullae, especially on the face and neck. Nikolsky's sign was absent. Erythema-multiforme-like plaques on the trunk and generalized excoriations were noted. New bullae had developed on the genitalia, perineum, axillae, forearms and wrists, elbows and knees, and ankles and feet (Fig 2 and 3). Bullae also involved the buccal mucosa and the hard and soft palate. Ruptured bullae tended to coalesce and leave large, denuded areas that healed rapidly (Fig 4). A repeated WBC count showed 11,200/cu mm, with 33% neutrophils, 43% lymphocytes, and 24% eosinophils; the total eosinophil count was 2,688/cu mm. The IgE level was 2,234 units/ml (normal, 0 to 100 units/ml), and the antinuclear antibody test was negative.

Biopsy specimens of intact vesicles were taken for histologic study and submitted for direct immunofluorescence. Histopathologic findings showed a subepidermal bulla that contained numerous eosinophils. The overlying epidermal cells appeared intact without necrosis. A number of eosinophils were observed at the tips of papillae in the peripheral margins, and the overlying basal cells exhibited liquefactive changes. Beneath the bulla the dermis showed perivascular accumulations of eosinophils intermingled with some mononuclear cells and neutrophils.

Direct immunofluorescence demonstrated strongly positive deposition of IgG and complement at the BMZ (Fig 5). Immunoglobulin M and fibrinogen were present at the BMZ and in cells in the dermis. Staining for IgA was negative. Serum for indirect immunofluorescence was strongly positive at the BMZ, using monkey esophagus as a substrate, stained with mixed antihuman IgG-IgM-IgA.

A diagnosis of bullous pemphigoid was

Accepted for publication Sept 6, 1977.

From the Dermatology Service, Department of Medicine, Letterman Army Medical Center, Presidio of San Francisco.

The opinions or assertions contained herein are the private views of the authors and are not to be construed as official or as reflecting the views of the Department of the Army or the Department of Defense.

Reprint requests to Technical Publication Editor, Letterman Army Medical Center, Presidio of San Francisco, CA 94129.

Reported Cases of BPC With Positive Results of Immunofluorescent Studies							
			BMZ Immunofluorescence				
Source	Case/ Age, yr/ Sex	Mucous Membrane Involvement	Direct	Indirect	Blood Eosinophilia, %	IgE, Units/ml	Miscellaneous
Bean et al[5]	1/11/M	Present	...	1:1280	40	...	Ulcerative colitis
Fincher et al[6]	2/2½/M	Present	IgG,C′	Positive	...	...	Course complicated by staphylococcal septicemia
Jablonska et al[7]	3/4	...	IgG*	Negative†	...	...	...
	4/2	...	IgG,‡ IgA	Negative†	...	...	...
	5/13	...	IgG	1:320	...	...	...
Esterly et al[8]	6/12/F	Present	IgG,C′	1:1280	14	...	Normal serum complement, membranous glomerulonephropathy
Chorzelski et al[9]	7/6	...	IgG*	1:640	...	...	...
	8/4	...	IgG*	...	...	...	...
	9/7	...	IgG, IgA‡	...	...	...	...
	10/2	...	IgG, IgA‡	...	...	...	...
Skeete and Greaves[10]	11/12/F	...	IgG, IgM, C′	1:320	...	...	Elevated serum C3 and C7
Piamphongsant et al[11]	12/8/F	Present	IgG	1:10	...	...	...
	13/2/M	...	IgG, IgM, C′	1:20	...	...	Decreased C′ in blister fluid
	14/6/M	...	IgG, IgM, IgA, C′	1:10	...	...	Controlled on dapsone alone
Robison and Odom	15/3/M	Present	IgG, C′, IgM	Positive	24	2,234§	...

*Involved and uninvolved.
†No active disease at the time of testing.
‡Suggestive of mixed bullous disease.
§Normal, 0 to 100 units/ml.

Fig 1.—Pseudoumbilicated blisters. Lips and nares are involved.

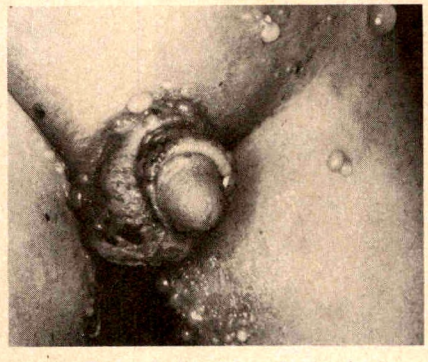

Fig 2.—Tense bullae in groin. Lesions on thigh are beginning to coalesce.

Fig 3.—Tense bullae on noninflamed base were present on soles of feet.

made. Dicloxacillin was discontinued, and the patient was observed for one week. New bullae continued to develop. Prednisone was then begun in doses of 60 mg every other day. After no improvement was noted during the first week, the prednisone dosage was increased to 100 mg on alternate days. The patient's condition slowly improved and was almost completely clear when he suddenly developed a generalized flare with new bullae developing at the margins of previously involved areas. These newer lesions were preceded by erythematous, urticarial plaques with irregular borders. The prednisone dosage was changed to a daily program of 70 mg each morning, and rapid clearing was noted within one week. Residual hypopigmentation and numerous milia were present diffusely. He is now free of disease and prednisone administration has been tapered. Duration of prednisone therapy was less than ten weeks. He has not had a recurrence of any skin lesions for the past seven months.

COMMENT

Bullous pemphigoid was first established as a distinct clinical and histopathologic entity by Lever in 1953.[12] The probability that a childhood form of the disease existed was first suggested by Kim and Winkelmann in 1961.[13] They believed that the bullous form of what was then called dermatitis herpetiformis (DH) of children was more closely related to bullous pemphigoid and suggested that the former cases be separated from the entity dermatitis herpetiformis and be named "bullous pemphigoid of childhood." With the advent of immunofluorescence some of those cases that were clinically compatible with childhood bullous pemphigoid were found to have negative direct immunofluorescence (three of six patients) and negative indirect immunofluorescence (six of six patients).[14] Jordon et al[14] introduced the term "benign chronic bullous dermatosis of childhood" for this group with immunologic negativity.

It was 1970 before the first case of bullous pemphigoid in a child, with positive immunofluorescent findings, was described.[5] Since that time, 14 cases of immunofluorescent-positive BPC have been reported (Table).[5-11] Prior to the widespread use of immunopathology, earlier cases of BPC were probably classified with DH of childhood.[7]

The pathogenesis of bullous pemphigoid is unknown. Some investigators support an immunologic basis.[3]

Fig 4.—Ruptured bullae coalesced, leaving large areas of denuded skin.

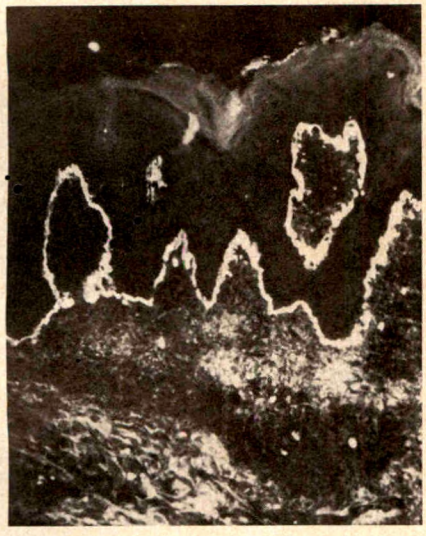

Fig 5.—Direct immunofluorescence of lesion stained positively for IgG in linear band along basement membrane.

Bean et al[5] proposed that nonspecific insults to the dermoepidermal junction might result in the formation of tissue-specific antibodies. This insult might initially follow drugs, chemicals, or ultraviolet light, or may accompany other systemic diseases,[4,8,15-25] such as alopecia areata,[4] ankylosing spondylitis,[4] benign and malignant neoplasms,[26] inflammatory bowel disease,[4] lichen planus,[19] membranous glomerulonephropathy,[8] multiple sclerosis,[4] pancreatitis,[27] pemphigus vulgaris,[23] polymyositis,[22] psoriasis,[25] rheumatoid arthritis,[20,21] sarcoidosis,[4] systemic lupus erythematosus,[16] and toxic goiter.[4] Antibody formation might perpetuate the reaction in an autoimmune manner. Bullous pemphigoid in children has been preceded by the administration of salicylazosulfapyridine, diphenoxylate hydrochloride, and atropine sulfate in one case,[5] penicillin and chloral hydrate in a second case,[6] and followed a sulfisoxazole-induced exfoliative dermatitis in another.[8] In addition, BPC has been reported in association with ulcerative colitis[5] and a membranous glomerulonephropathy[8] with immunoglobulin deposition in the kidney. The true meaning of these associations is unknown.

Our patient had no associated underlying disease and was in good health until the onset of the illness. Although a topical penicillin ointment and bacitracin were applied to early lesions, it is unlikely that those agents played a causative role. In all probability our patient's eruption was bullous pemphigoid from the onset, which, because of severe pruritus, became excoriated and developed a secondary staphylococcal infection that masked the clinical presentation. The possibility of a cicloxacillin-induced bullous pemphigoid eruption was considered. However, the patient's eruption continued and indeed worsened after discontinuation of the drug, making this theory less plausible.

That drugs may assume a more than coincidental role in the induction of bullous pemphigoid is illustrated by several recent reports. Wranicz and Czernielewski[18] reported on a 78-year-old woman who developed bullous pemphigoid following the topical application of benzyl benzoate. The diagnosis was supported by the presence of both in vivo and in vitro immunofluorescent staining. Bart and Bean[17] reported the development of bullous pemphigoid in an 84-year-old man following the topical application of fluorouracil. The patient had positive in vitro immunofluorescence when the serum and blister fluid were tested. Fellner and Katz[15] reported a case of bullous pemphigoid in a 78-year-old woman following furosemide therapy, and the eruption was reproduced by readministration of the drug.

Not all cases of BPC have characteristic findings initially. Our case was initially diagnosed as bullous impetigo, and eczema herpeticum with secondary impetiginization was strongly considered. The initial eruption may be mistaken for bullous erythema multiforme and may differ only in duration and immunofluorescent findings. Thus, certain acute blistering diseases of childhood should be considered in every differential—bullous impetigo and staphylococcal scalded skin syndrome, erythema multiforme, toxic epidermal necrolysis, bullous drug eruptions, bullous contact dermatitis, and herpesvirus infections. History and examination should eliminate the chronic hereditary blistering diseases, which include epidermolysis bullosa, incontinentia pigmenti, urticaria pigmentosa bullosa, and epidermolytic hyperkeratosis. The differential diagnosis should include all of the chronic nonhereditary blistering diseases in children.[28] These include pemphigus vulgaris and foliaceus, dermatitis herpetiformis, and chronic bullous dermatosis of childhood.

The clinical findings in BPC and benign chronic bullous dermatosis of childhood may overlap. Our patient manifested rosette-like bullous lesions similar to those described in chronic bullous dermatosis of childhood.[29] In addition, several of our adult cases of bullous pemphigoid have manifested a rosette pattern with polycyclic margins bordered by intact bullae. These observations suggest that this morphologic lesion is not specific for, although more predominant in, chronic bullous dermatosis of childhood. Jablonska et al[7] believed that there were no meaningful differences between their BPC cases and those childhood bullous cases with negative immunofluorescent findings.

Chorzelski et al[9] have recently shown that repeated immunofluorescent studies on any one case may eventually reveal positive findings. Thus, clinically characteristic but immunofluorescent-negative cases of BPC may exist but must await further final classification because immunologic negativity may be secondary to insufficient specimen testing[9] or interfering treatment programs (steroids) at the time of testing.[30]

There also exist cases that may overlap between BPC and DH of childhood.[31,32] Immunofluorescent findings may only confuse the picture, especially when both linear IgG and IgA are found.[7,9] Faber and Van Joost[33] reported such a case in which the staining for IgA was actually stronger than IgG, and the patient responded to sulfapyridine. The case was labeled juvenile pemphigoid by the authors, but Esterly et al[29] prefer to reclassify this patient under a subgroup of chronic bullous dermatosis of childhood characterized by IgA along the BMZ.

Katz et al[34,35] have recently reported finding HLA-B8 antigen in 85% of their dermatitis herpetiformis patients who had IgA deposits in the skin. In view of this finding, the determination of this HLA antigen in the chronic nonhereditary blistering diseases in children might provide valuable additional information in the overall assessment and classification of these children. Indeed future case evaluations may show a variety of

mixed bullous diseases in children, a concept that has recently been gaining recognition.[31,36]

Because of the variable findings on direct immunofluorescence in some cases of BPC, a positive indirect immunofluorescent pattern with IgG at the BMZ is probably the most specific finding in the diagnosis of BPC. On the other hand, the titer is not a sensitive indicator of disease activity or response to therapy.[37]

Corticosteroids appear to be the mainstay of treatment for BPC. Controlling doses are variable and can be combined with sulfapyridine and such immunosuppressive drugs as azathioprine.[38] Dapsone, with and without concomitant corticosteroids, has been reported to be effective in a few childhood cases.[11] Because of the success of commencing therapy with alternate-day corticosteroids in treating cases of pemphigus vulgaris,[39] and our success in maintaining our present adult bullous pemphigoid patients on alternate-day dosages, an attempt was made to control our present patient on alternate-day therapy. This was unsuccessful at maximum doses of 100 mg of prednisone (6 mg/kg) on alternate days. A higher alternate-day dose or longer alternate-day-treatment course might have been effective. Further alternate-day trials appear warranted.

Our present case of bullous pemphigoid closely mimics bullous pemphigoid in adults. In addition to similar morphological patterns, distribution of lesions, and histopathologic findings, our patient showed a rather strong blood eosinophilia and an elevated IgE level during the height of his disease. Blood eosinophilia was also reported in two other cases of BPC.[5,8] Immunoglobulin E has been shown to be elevated in 70% of adult cases of bullous pemphigoid.[40] This is the first reported IgE determination in a case of BPC as far as we know. Elevated IgE levels, blood eosinophilia, and the recent demonstration of an eosinophil chemotactic factor in the blister fluid[41] further support a possible immunopathogenetic mechanism in patients with bullous pemphigoid.

The chronic nonhereditary blistering diseases in children may be confusing from clinical, histopathological, therapeutic, and immunopathological points of view. In assessing this group of diseases, it is imperative to perform complete direct and indirect immunofluorescence, obtain certain HLA antigen determinations, survey for blood eosinophilia, determine immunoglobulin levels, and search for associated diseases. In certain instances, despite careful analysis, overlapping features may be encountered and separation of this group into specific entities may be difficult. However, with close scrutiny and utilization of newer immunological developments, it appears that many cases of the chronic nonhereditary blistering diseases in children parallel the adult forms of bullous diseases and can be categorized into specific disease entities.

Immunofluorescent studies were done by Denny L. Tuffanelli, MD. Carl Johnson, MD, assisted in the care of this patient.

Nonproprietary Names and Trademarks of Drugs

Azathioprine—*Imuran.*

Salicylazosulfapyridine—*Accurol, Azulfidine, Rorasul, SAS-500, Sulcolon, W-T SASP Oral.*

References

1. Jordon RE, Beutner EH, Witebsky E, et al: Basement zone antibodies in bullous pemphigoid. *JAMA* 200:751-756, 1967.
2. Beutner EH, Jordon RE, Chorzelski TP: The immunopathology of pemphigus and bullous pemphigoid. *J Invest Dermatol* 51:63-80, 1968.
3. Sams WM: Bullous pemphigoid: Is it an immunologic disease? *Arch Dermatol* 102:485-497, 1970.
4. Person JR, Rogers RS III: Bullous and cicatricial pemphigoid: Clinical, histopathologic, and immunopathologic correlations. *Mayo Clin Proc* 52:54-66, 1977.
5. Bean SF, Good RA, Windhorst DB: Bullous pemphigoid in an 11-year-old boy. *Arch Dermatol* 102:205-208, 1970.
6. Fincher DF, Dupree E, Bean SF: Bullous pemphigoid in childhood: Immunofluorescent studies. *Arch Dermatol* 103:88-90, 1971.
7. Jablonska S, Chorzelski T, Beutner EH, et al: Juvenile dermatitis herpetiformis in the light of immunofluorescence studies. *Br J Dermatol* 85:307-313, 1971.
8. Esterly NB, Gotoff SP, Lolekha S, et al: Bullous pemphigoid and membranous glomerulonephropathy in a child. *J Pediatr* 83:466-470, 1973.
9. Chorzelski TP, Jablonska S, Beutner EH, et al: Juvenile dermatitis herpetiformis versus "benign chronic bullous dermatosis of childhood": Are these immunologic diseases? *J Invest Dermatol* 65:447-450, 1975.
10. Skeete M, Greaves MW: Juvenile bullous pemphigoid. *Br J Dermatol* 95(suppl 14):23-25, 1976.
11. Piamphongsant T, Chaikittisilpa S, Kullavanijaya P: Bullous pemphigoid in childhood: Report of three cases and a review of literature. *Int J Dermatol* 16:126-133, 1977.
12. Lever WF: Pemphigus. *Medicine* 32:1-123, 1953.
13. Kim R, Winkelmann RK: Dermatitis herpetiformis in children: Relationship to bullous pemphigoid. *Arch Dermatol* 83:895-902, 1961.
14. Jordon RE, Bean SF, Triftshauser CT, et al: Childhood bullous dermatitis herpetiformis: Negative immunofluorescent tests. *Arch Dermatol* 101:629-634, 1970.
15. Fellner MJ, Katz JM: Occurrence of bullous pemphigoid after furosemide therapy. *Arch Dermatol* 112:75-77, 1976.
16. Jordon RE, Muller SA, Hale WL, et al: Bullous pemphigoid associated with systemic lupus erythematosus. *Arch Dermatol* 99:17-25, 1969.
17. Bart BJ, Bean SF: Bullous pemphigoid following the topical use of fluorouracil. *Arch Dermatol* 102:457-460, 1970.
18. Wranicz A, Czernielewski A: Pemphigoid induced by novoscabin. *Przegl Dermatol* 61:693-696, 1974.
19. Stingl G, Holubar K: Coexistence of lichen planus and bullous pemphigoid. *Br J Dermatol* 93:313-320, 1975.
20. Lillicrap DA: Rheumatoid arthritis and pemphigoid. *Proc R Soc Med* 56:921-922, 1963.
21. Salo OP, Räsänen JA: Pemphigoid and rheumatoid arthritis: A clinical and immunological study. *Ann Clin Res* 4:173-177, 1972.
22. Peck SM, Lefkovits AM: Bullous pemphigoid with polymyositis and coexisting contact dermatitis. *Arch Dermatol* 94:672-673, 1966.
23. Chorzelski TP, Maciejowski E, Jablonska S, et al: Coexistence of pemphigus and bullous pemphigoid. *Arch Dermatol* 109:849-853, 1974.
24. Cram DL, Fukuyama K: Immunohistochemistry of ultraviolet-induced pemphigus and pemphigoid lesions. *Arch Dermatol* 106:819-824, 1972.
25. Person JR, Rogers RS: Bullous pemphigoid and psoriasis: Does subclinical bullous pemphigoid exist? *Br J Dermatol* 95:535-540, 1976.
26. Stone SP, Schroeter AL: Bullous pemphigoid and associated malignant neoplasms. *Arch Dermatol* 111:991-994, 1975.
27. Smith GM: Prolonged spontaneous hypothermia: Report of a case associated with chronic pancreatitis and a pemphigoid eruption. *Ann Intern Med* 65:316-320, 1966.
28. Bean SF, Jordon RE: Chronic nonhereditary blistering disease in children. *Arch Dermatol* 110:941-944, 1974.
29. Esterly NB, Furey NL, Kirschner BS, et al: Chronic bullous dermatosis of childhood. *Arch Dermatol* 113:42-46, 1977.
30. McGuire J, Nordlund J: Bullous disease of childhood. *Arch Dermatol* 108:284-285, 1973.
31. Barranco VP: Mixed bullous disease. *Arch Dermatol* 110:221-224, 1974.
32. Cormane RH, Szabo E: Immunohistopathology of the skin in pemphigoid. *Br J Dermatol* 83:435-445, 1970.
33. Faber WR, Van Joost TH: Juvenile pemphigoid. *Br J Dermatol* 89:519-522, 1973.
34. Katz SI, Falchuk ZM, Dahl MV, et al: HL-A8: Genetic link between dermatitis herpetiformis and gluten-sensitive enteropathy. *J Clin Invest* 51:2977-2980, 1972.
35. Katz SI, Hertz KC, Rogentine GN, et al: HLA-B8 and dermatitis herpetiformis in patients with IgA deposits in skin. *Arch Dermatol* 113:155-156, 1977.
36. Honeyman JF, Honeyman A, Lobitz WC, et al: The enigma of bullous pemphigoid and dermatitis herpetiformis. *Arch Dermatol* 106:22-25, 1972.
37. Sams WM Jr, Jordon RE: Correlation of pemphigoid and pemphigus antibody titres with activity of disease. *Br J Dermatol* 84:7-13, 1971.
38. Burton JL, Greaves MW: Azathioprine for pemphigus and pemphigoid: A 4 year follow-up. *Br J Dermatol* 91:103-109, 1974.
39. Rabhan NB, Kopf AW: Alternate-day prednisone therapy for pemphigus vulgaris. *Arch Dermatol* 103:615-622, 1971.
40. Arbesman CE, Wypych JI, Reisman RE, et al: IgE levels in sera of patients with pemphigus or bullous pemphigoid. *Arch Dermatol* 110:378-381, 1974.
41. Baba T, Sonoyaki H, Seki K, et al: An eosinophil chemotactic factor present in blister fluids or bullous pemphigoid patients. *J Immunol* 116:112-117, 1976.

Bullous Pemphigoid and Ovarian Cystadenocarcinoma

Immunologic Studies

Mark V. Dahl, MD, Sandra Ristow, PhD

• A patient with bullous pemphigoid and papillary serous cystadenocarcinoma of the ovary was studied to determine if patient tumor cells would absorb antiepithelial basement membrane antibody present in patient serum. Absorption of patient serum with trypsinized tumor cells failed to decrease the titer of serum antibasement membrane antibodies. These studies present additional evidence that malignant neoplasms and bullous pemphigoid are not causatively related.

(*Arch Dermatol* 114:903-905, 1978)

The association of bullous pemphigoid and internal malignant neoplasms has been reported frequently.[1] Malignant tumors have included a variety of epithelial and mesothelial derived neoplasms arising in such diverse organs as lung,[2-5] kidney,[6,7] gallbladder,[3,8] bladder,[9,10] lymphatic tissue,[3] prostate,[9,10] breast, ovary,[11] colon,[12] rectum,[5,11,13] skin,[3,14] cervix,[15] blood vessels,[16] pancreas,[17] pharynx,[18] stomach,[11,19] larynx,[12] chorion,[20] and blood elements.[3,9,21] However, bullous pemphigoid is a chronic disease of the elderly, and chance occurrence of simultaneously developing cancer might be expected in some of these individuals. Thus, the pathophysiologic relationship of bullous pemphigoid to malignant neoplasms is still unclear.

Bullous pemphigoid is associated with circulating and fixed IgG antibody that binds to the basement membrane zone of various epithelial tissues.[22] These antibodies can fix complement and may induce tissue injury leading to formation of the tense bullae that characterize bullous pemphigoid.[23]

It is generally agreed that many persons with malignant tumors mount an immune response directed against tumor-specific antigens on malignant cells.[24] Antibodies that bind to tumor cells can be detected by immunofluorescence,[25] cytotoxicity assay,[26] or other methods.[27] In addition, patients often develop a lymphocyte-mediated, delayed hypersensitivity response against tumor antigens.[28,29]

If malignant neoplasms can produce bullous pemphigoid, an immunologic mechanism would seem likely. Antibody formed against tumor antigens might cross react with antigens in the basement membrane zone of squamous epithelium. These cross reacting antibodies might fix complement at the basement membrane and induce blister formation. Such a hypothesis would account for the circulating and skin-fixed antibasement membrane antibody observed in patients with bullous pemphigoid.

If, indeed, antibody formed against tumor cells could cross react with epithelial basement membrane, then it should be possible to absorb antibasement membrane antibodies with tumor cells. We recently studied a patient with the sudden onset of bullous pemphigoid and ovarian cystadenocarcinoma to investigate this possibility.

REPORT OF A CASE

A 65-year-old woman was admitted to the University of Minnesota Hospitals with a pruritic blistering dermatosis present for six weeks. The eruption began on the flexor surfaces of the forearms and spread to involve most of the cutaneous surface. She was otherwise in good health. There was no recent weight loss.

Physical examination showed a widespread vesiculobullous skin eruption. Tense bullae were present as nonscaling erythematous papules and plaques resembling urticaria. Extensive urticarial papules and plaques were present between bullae. Several bullae were hemorrhagic. Lesions were present over most of the cutaneous surface, but spared palms, soles, and face except for a single plaque on the right side of the forehead. Mucous membranes were not involved. Nikolsky sign was negative.

Pelvic examination demonstrated depression of the left vaginal wall by an extrinsic mass. Cervix and corpus uterii were anterior and distinctly separated from a 20-cm, firm, somewhat tender, irregular mass that extended across the midline to the right and to the sidewall on the left. This mass was best felt by rectovaginal examination. Smaller nodules were present in the right and left uterosacral ligaments, and inguinal lymph nodes were enlarged bilaterally. Results of the remainder of the examination were normal except for the presence of a grade 2/6 systolic early ejection heart murmur heard best at the left sternal border.

Biopsy specimens of skin showed subepidermal bullae containing numerous polymorphonuclear leukocytes and eosinophils. The basal layer and upper portion of the dermis were edematous and also contained numerous eosinophils. Direct immunofluorescence disclosed a bright linear band of C3 at the dermal-epidermal junction. No deposits of IgG, IgM, or IgA were observed. Indirect immunofluorescence demonstrated circulating antibasement membrane zone IgG antibody at a titer of 1:80.

Abnormal laboratory results included a hematocrit reading of 34%, mean corpuscular volume of 89 cuμ, mean corpuscular hemoglobin volume of 30 pg, mean corpuscular hemoglobin concentration of 34%, WBC count of 7,000/cu mm with 25% eosinophils. The ESR was 24 mm at 40 minutes. The total serum protein value was depressed at 5.6 g/dl, with an albumin value of 2.6 g/dl. The serum iron level was

Accepted for publication Sept 20, 1977.

From the Departments of Dermatology (Dr Dahl) and Surgery (Dr Ristow), University of Minnesota Medical School, Minneapolis.

Reprints not available.

32 μg/dl (19% saturation) and the lactic dehydrogenase (LDH) value was 436 IU/liter. Intravenous pyelograms showed two cystic lesions in the left kidney that were later established as benign renal cysts.

Normal laboratory measurements and results included sodium, potassium, bicarbonate, chloride, glucose, creatinine, BUN, uric acid, bilirubin, cholesterol, triglycerides, alkaline phosphatase, SGOT, urea-stable LDH, urinalysis, T_3, T_4, prothrombin time, platelets, thrombin time, ECG, Papanicolaou smear of the cervix, indirect Coombs' test, VDRL, chest x-ray film, and barium enema x-ray film. Other values were as follows: serum IgG, 660 mg/dl (normal, 372 to 1,356); IgM, 60 mg/dl (normal, 48 to 414); IgA, 128 mg/dl (normal 40 to 468); IgE, 18 mg/dl (normal, 12 to 444), total hemolytic complement, 42 units/ml (normal, 25 to 45).

Biopsy specimens of vaginal nodules showed ovarian adenocarcinoma, and an exploratory laparatomy, total abdominal hysterectomy, bilateral salpingo-oophorectomy, omentectomy, and biopsy of enlarged lymph nodes were performed. Histopathologic examination showed poorly differentiated papillary serous cystadenocarcinoma in myometrium, Fallopian tube, ovary, and lymph nodes.

Following surgery, all itching ceased for five days, then recurred. She was treated topically with 0.1% triamcinolone acetonide cream three times daily, hydroxazine hydrochloride, and she received 12 mg of melphalan daily for five days. Small vesicles continued to develop on an erythematous, edematous base, and these were generalized during her last examination three months after surgery.

METHODS

Preparation of Tumor Cells

Tumor was obtained under sterile conditions at the time of surgical resection and transported immediately to the laboratory. A portion of tumor was placed in a liquid nitrogen refrigerator for direct immunofluorescence testing. Tissue was minced by scalpel and placed in RPMI-1640 tissue culture medium containing 0.3% trypsin and incubated at room temperature with stirring for 20 minutes. Supernatant cells were removed (fraction 1), and new medium and trypsin were added. After a second 20-minute period, supernatant cells were again removed (fraction 2) and additional medium and trypsin added. This operation was repeated every 20 minutes to obtain fractions 3 and 4.

Supernatants were centrifuged at 160g for 10 minutes, washed three times with RPMI-1640 medium, resuspended in RPMI-1640 and incubated for four or five hours at 37°C to allow tumor antigens to regenerate on tumor cell surfaces. Following incubation, cells were centrifuged at 160g × 10 minutes.

Absorption Studies

Fractions 2 and 3 were combined. The viability of cells was greater than 95% as determined by trypan blue exclusion. The pellet of cells from the final wash was resuspended in an equal volume of patient sera, incubated with occasional gentle mixing at 37°C for 30 minutes, and centrifuged at 160g × 10 minutes. Supernate serum was removed and processed for indirect immunofluorescence. Tumor cells were kept at 4°C for 18 hours and processed for direct immunofluorescence. Similar absorption of patient serum was performed using autologous RBCs and patient myometrial tissue obtained at the time of surgery and processed in an identical manner to tumor.

Indirect Immunofluorescence

Indirect immunofluorescence was performed as previously described,[29] but using rabbit esophagus as substrate and fluorescein-labeled rabbit antihuman IgG. The specificity of the antisera was controlled by crossed immunoelectrophoresis, and the conjugated antigamma chains were tested on myeloma bone marrow cells. The antibody titer was 100, meaning that 100 μg of antigen must be added to 1 ml of antibody to obtain a supernatant containing neither free antigen nor antibody. The total protein concentration was 1.8 mg/ml, and the fluorescein-to-protein (F/P) ratio was 0.63 ± 0.03 (molar F/P, 2.3). Details of the microscope and filters have been described previously.[30]

Serial twofold dilution titers were obtained with patient serum, patient serum absorbed with tumor cells, patient serum absorbed with autologous RBCs, patient serum absorbed with patient normal autologous myometrial cells, and normal human serum. All slides were read in blind fashion as positive or negative without knowledge of dilution or serum pretreatment.

Direct Immunofluorescence and Blocking Experiments

Tumor tissue was processed for direct immunofluorescence as previously described.[31] In addition, tumor cells (80% viable) used in the serum absorption studies the previous day were incubated with either phosphate-buffered saline or unlabeled rabbit antihuman IgG (titer 600, protein concentration 9 mg/ml) for 30 minutes. Cell suspensions were washed twice in phosphate-buffered saline and incubated in suspension with the fluorescein-labeled antihuman IgG for 30 minutes. Cell suspensions were again washed twice in phosphate-buffered saline, and a drop of the final suspension of cells was placed on microscope slides for examination. Specimens were read as positive or negative without knowledge of treatment.

Tissue Culture

From cell fraction 4 10^6 tumor cells/ml were suspended in RPMI-1640 supplemented with 5%, 10% or 20% fetal calf serum or 5%, 10%, or 20% pooled human sera and incubated at 37°C in an atmosphere containing 5% carbon dioxide. Media were replaced as needed.

RESULTS

Absorption Studies

The titer of antibasement membrane antibody in tumor cell-absorbed serum was identical to the titer of antibody in unabsorbed serum, serum absorbed with autologous RBCs, and serum absorbed with patient normal myometrial tissue (1/80). No antibodies were detected in normal control serum.

Direct Immunofluorescence

No specific deposits of IgG, IgM, IgA, C3, or fibrinogen were observed on frozen tissue sections of tumors.

Immunoglobulin G could be detected on isolated tumor cells. Blocked cells were always distinguishable from unblocked cells.

Tissue Culture

Tumor cells attached well to tissue culture plates but failed to proliferate in tissue culture. Cultures were terminated after two weeks.

COMMENT

The relationship of bullous pemphigoid to internal malignant neoplasms is unclear. Despite numerous reports of simultaneous occurrence of bullous pemphigoid and malignant neoplasms, controlled studies have failed to show a meaningfully increased incidence of cancer among patients with bullous pemphigoid, except perhaps in patients with fixed, but not circulating, antibasement membrane antibody.[9,32,33]

Malignant neoplasms could produce bullous pemphigoid a number of ways. The tumor might secrete a hormone-like substance that could produce damage to the epithelial basement membrane zone. Antibody to the basement membrane area of skin might then be formed secondarily. Much less likely, a virus or other agent might induce cancer and simultaneous basement membrane zone damage. Alternatively, cancer might evoke production of an antibody capable of cross reacting with the basement membrane zone of skin to induce bullous pemphigoid.

Our studies dealt with this last hypothesis. We were unable to demonstrate cross reaction of antibasement membrane antibody with patient tumor cells. The titer of antibasement membrane antibodies in patient sera did not decrease following absorption with trypsinized patient tumor cells.

These studies by no means rule out the hypothesis that tumors can induce pemphigoid by immunologic cross

reaction between tumor-specific antigens and epithelial basement membrane. For example, the tumor antigen responsible might be present but not expressed at the cell surface. In this situation, intact living cells would not be expected to absorb pemphigoid antibody. Similarly, the antigenic tumor material might be stroma rather than tumor cell. It is also possible that some tumors coexisting with bullous pemphigoid can induce formation of antibasement membrane antibody, but other patients may develop tumor and skin disease independently.

Tumor cells regenerate tumor specific cell membrane antigens after trypsinization. Mouse sarcoma cells regenerate tumor antigens within two hours (P. Cleveland, PhD, oral communication, February 1977). We allowed four hours for our patient's tumor cell antigens to regenerate, but it is possible this was not sufficient time. Unfortunately, tissue culture of patient tumor cells was unsuccessful so we were unable to investigate this possibility. Similar studies in the future should attempt to establish antigenicity of tumor cells, perhaps by injection of tissue culture cells into species-unrelated recipients (such as New Zealand white female rabbits) followed by absorption with donor fibroblasts and examination of absorbed sera by immunofluorescence or cytotoxicity techniques. Neuraminidase treatment of cultured or isolated tumor cells might also be attempted in future studies to attempt to unmask antigen sites on tumor cells.[34,35]

We hope this report will stimulate researchers to investigate the relationship between bullous pemphigoid and malignant neoplasms as the opportunity arises. Previously we studied a patient with a meningioma and uncontrolled bullous pemphigoid (Dahl MV and Katz SI, unpublished data). We were unable to absorb the antibasement membrane antibody in patient serum by incubation with frozen tissue sections of patient tumor. In addition, rabbits inoculated with tumor homogenized in incomplete Freund's adjuvant failed to develop antibasement membrane antibodies as determined by direct and indirect immunofluorescence.

Numerous patients with bullous pemphigoid and coexisting malignant tumors have been reported.[1-21] Some of these patients may have had erythema multiforme bullosum rather than pemphigoid, since many were evaluated before immunofluorescence tests became available. In other patients, the simultaneous development of bullous pemphigoid and malignant neoplasms might be coincidental, as probably happened in our patient.

It seems prudent at present to regard bullous pemphigoid as a disease of elderly people that may, on some occasions, coexist with malignant (or benign) tumors. There is little evidence to suggest that the two diseases bear any causal relationship to each other, or that an intensive search for underlying malignant neoplasms is indicated in all patients.

This investigation was supported by Public Health Service grant 1-R01-CA-14815-01 and 5-T32AM07165.

William Lindroos and Nelson French gave technical assistance. R. Chris Diercks, MD, William C. Gentry Jr, MD, and James Rohrer, MD, referred this patient.

Nonproprietary Name and Trademark of Drug

Melphalan—*Alkeran.*

References

1. Bograw SL: Zur kasuistik der dermatitis herpetiformis Duhringi. *Arch Dermatol Syphiligr* 98:327-334, 1909.

2. Abadir R, Emery EW, Have PJ: Pemphigoid, bronchial neoplasm and radiotherapy. *Proc R Soc Med* 60:1271-1272, 1967.

3. Parsons RL, Savin JA: Pemphigoid and malignancy. *Br J Cancer* 22:669-672, 1968.

4. Rook AJ: A pemphigoid eruption associated with carcinoma of the bronchus. *Trans St Johns Hosp Dermatol Soc* 54:152-154, 1968.

5. Zinhsheim M, Gartmann H: Bulloses pemphigoid und figurierte erytheme als paraneoplastische hautreaktion bei einem bronchial-karzinom. *Z Hautkr* 49:215-218, 1974.

6. Morandi GA, Panerai A, Bongi G: Le sindromi paraneoplastiche: III. Contributo clinico alla conoscenza del pemfigoide paraneoplastico. *Riv Crit Clin Med* 64:498-508, 1964.

7. Paslin DA: Bullous pemphigoid and hypernephroma: A critical review of bullous pemphigoid and malignancy. *Cutis* 12:554-555, 1973.

8. Post B, Wilhelmi F, Ganner M: Bulloses pemphigoid als cutanes paraneoplastisches syndrom bei einem gallenblasencarcinom. *Hautarzt* 24:193-197, 1973.

9. Stone SP, Schroeter AL: Bullous pemphigoid and associated malignant neoplasms. *Arch Dermatol* 111:991-994, 1975.

10. Skog E: Cutaneous manifestations associated with internal malignant tumors with particular reference to vesicular and bullous lesions. *Acta Derm Venereol (Stockh)* 44:114-117, 1964.

11. Forman L: Pemphigoid occurring with carcinoma of the rectum. *Proc R Soc Med* 53:563, 1960.

12. Ebner H, Spangler E: Untersuchungen über die beziehung von bullosen pemphigoid und malignen allgemeinerkrankungen. *Wein Klin Wochenschr* 86:449-452, 1974.

13. Saikia NK, MacKie RM, McQueen A: A case of bullous pemphigoid and figurate erythema in association with metastatic spread of carcinoma. *Br J Dermatol* 88:331-334, 1973.

14. Marks JM, Gold SC: Pemphigoid and malignant melanoma. *Proc R Soc Med* 54:225-226, 1961.

15. Ive FA: Metastatic carcinoma of cervix with acanthosis nigricans, bullous pemphigoid and hypertrophic pulmonary osteoarthropathy. *Proc R Soc Med* 56:910, 1963.

16. Tye MJ: Bullous pemphigoid and Kaposi's sarcoma. *Arch Dermatol* 101:690, 1970.

17. Boyd RV: Pemphigoid and carcinoma of the pancreas. *Br Med J* 1:1092, 1964.

18. Cornia FE, Domonkos AN: Cutaneous reactions to internal malignancy. *Med Clin North Am* 49:655-680, 1965.

19. Braverman IM: *Skin Signs of Systemic Disease*, Philadelphia, WB Saunders, 1970.

20. Elliot JA: Bullous dermatoses of toxic origin: Report of a case involving an association with choriocarcinoma. *Arch Dermatol* 37:219, 1938.

21. Cuni LJ, Grünwald H, Rosner F: Bullous pemphigoid in chronic lymphocytic leukemia with the demonstration of antibasement membrane antibodies. *Am J Med* 57:987-992, 1974.

22. Jordon RE, Beutner EH, Witebsky E, et al: Basement zone antibodies in bullous pemphigoid. *JAMA* 200:751-756, 1967.

23. Jordon RE, Schroeter AL, Good RA, et al: The complement system in bullous pemphigoid: II. Immunofluorescent evidence for both classical and alternate-pathway activation. *Clin Immunol Immunopathol* 3:307-314, 1975.

24. Henney CS: Mechanisms of tumor cell destruction in Green I, Cohen S, McCluskey RT (eds): *Mechanisms of Tumor Immunity*. New York, John Wiley & Sons, 1977, pp 55-86.

25. Balcwin RW, Barker CR: Demonstration of tumour specific humoral antibody against amino azo dye induced rat hepatoma. *Br J Cancer* 21:793-800, 1967.

26. Cleveland PH, McKhann CF, Johnson K, et al: A microassay for humoral cytotoxicity demonstrating sublethal effects of antibody. *Int J Cancer* 14:417-426, 1974.

27. Faanes RB, Choi YS: Interaction of isoantibody and cytotoxic lymphocyte with allogeneic tumor cells. *J Immunol* 113:279-288, 1974.

28. Hellström KE, Hellström I: Lymphocyte-mediated cytotoxicity and blocking serum activity to tumor antigens. *Adv Immunol* 18:209-277, 1974.

29. Cerottini J, Brunner K, Brunner T: Cell-mediated cytotoxicity, allograft rejection, and tumor immunity. *Adv Immunol* 18:67-132, 1974.

30. Dahl MV, Katz SI, McGowen JH, et al: Pemphigus-like antibodies in sera of patients with thermal burns, gunshot wounds, and skin grafts. *Mil Med* 139:196-198, 1974.

31. Dahl MV, Ullman S, Goltz RW: Vasculitis in granuloma annulare: Histopathology and direct immunofluorescence. *Arch Dermatol* 113:463-467, 1977.

32. Person JR, Rogers RS: Bullous and cicatricial pemphigoid: Clinical, histopathologic and immunopathologic correlations. *Mayo Clin Proc* 52:54-66, 1977.

33. Ahmed AR, Chu TM, Provost TT: Bullous pemphigoid: Clinical and serologic evaluation for associated malignant neoplasms. *Arch Dermatol* 113:969, 1977.

34. Simmons RL, Rios A, Lundgren G, et al: Immunospecific regression of methylcholanthrene fibrosarcoma with the use of neuraminidase. *Surgery* 70:38-46, 1971.

35. Sedlacek HH, Seiler FR, Schwick HG: Neuraminidase and tumor immunotherapy. *Klin Wochenschr* 55:199-214, 1977.

Pyoderma Gangrenosum

Abnormal Monocyte Function Corrected In Vitro With Hydrocortisone

David A. Norris, MD; William L. Weston, MD; E. George Thorne, MD; James R. Humbert, MD

• A 34-year-old man with chronic active hepatitis and pyoderma gangrenosum demonstrated abnormalities in neutrophil and monocyte function. Monocytes from this man had diminished chemotaxis and bacterial phagocytosis. These functions were significantly improved in vitro after one hour of incubation of monocytes with 10^{-5} hydrocortisone. Neutrophil function was normal for bactericidal activity and phagocytosis, but neutrophil chemotaxis was diminished. A plasma inhibitor was not found to explain these phagocyte alterations.

(*Arch Dermatol* 114:906-911, 1978)

Pyoderma gangrenosum (PG) is a distinctive clinical lesion found in association with a variety of different diseases and several immunologic abnormalities. The clinical lesion is a necrotic ulcer with blue overhanging margins and a surrounding erythematous halo. The lesion may begin as erythema with a central papule, vesicle, or pustule and heals with an atrophic "cigarette-paper scar."[1] Pain is a prominent characteristic of the lesion, and association with trauma is seen in up to 40% of the cases.[2] Although classically described as a companion of chronic ulcerative colitis, in one large series only 50% of the cases were associated with this disease.[2] Regional enteritis,[3] rheumatoid arthritis,[4] pulmonary infection, diverticulosis,[2] leukemia,[5,6] Hodgkin's disease,[7] polycythemia vera,[8] myelofibrosis,[9] myeloma or paraproteinemia,[2] Behçet's disease,[10] and chronic active hepatitis[11] have also been associated with PG.

The histopathology of PG is nonspecific. The ulcer extends into the upper part of the dermis with an acute inflammatory infiltrate of polymorphonuclear leukocytes (PMNs) at the margin and a chronic inflammatory infiltrate in the center.[12] Most histopathologists believe that PG is not a vasculitis,[12-14] but there are still dissenters.[3,15-17] Cutaneous flora or contaminants grow in cultures of the lesions, and antibiotic therapy is not generally useful. Systemically administered corticosteroids produce substantial clinical response.[2]

The purpose of this article is to describe a patient with abnormalities of both neutrophil and monocyte function, which is another form of altered immunologic responsiveness in PG.

REPORT OF A CASE

A 34-year-old man complained of weight loss, jaundice, diarrhea, leg cramps, and painful nonhealing ulcers. Five months previously, the patient had seen his physician, at which time examination showed light mushy stools, dark urine, a tender liver, a bilirubin value of 5.4 mg/dl, and a SGOT level of 8,590 IU. He was treated with bed rest for "viral hepatitis." One week later, perianal ulcerations developed that were attributed to diarrhea and cutaneous irritation. Although he felt much better, skin lesions continued to develop "wherever I scratched myself." After three distinct clinical relapses, the patient was admitted to the Helena, Mont, Veterans Administration Hospital with light diarrhea, dark urine, a persistent bilirubin level of 5.0 mg/dl and a 5-g γ spike on serum protein electrophoresis. The VDRL test results, hepatitis B antigen, heterophile, and leptospiral antibody titers were all negative. Arthralgias, progressive cutaneous ulcers, and nightly spiking fever to 38° to 40°C developed, and he was transferred to the Denver Veterans Administration Hospital.

He arrived on Sept 15, 1975, and was a debilitated, icteric young man with spiking fever. Pertinent physical findings were cutaneous and scleral icterus, two aphthae on the oral mucosa, tender left knee and hip to passive motion, a superficial thrombophlebitis of the left leg, multiple petechial nonpalpable lesions on the buttocks and extremities, and several necrotic ulcers with surrounding erythema. The oldest of the lesions had dark overhanging borders with a necrotic, slightly purulent center (Fig 1). The earliest lesions had central papules or vesicopustules with surrounding nonpalpable erythema. All lesions were very tender. Biopsy of the lesions showed an ulcer with a lymphoid and mononuclear cell infiltrate. Immunofluorescent staining for complement or immunoglobulin was

Accepted for publication June 13, 1977.

From the Departments of Dermatology (Drs Norris, Weston, and Thorne) and Pediatrics (Dr Humbert), University of Colorado School of Medicine, Denver.

Reprints not available.

negative. Admission laboratory data showed the following: WBC count, 10,700/cu mm; hemoglobin level, 8 g/dl; hematocrit reading, 36%; differential cell count, slight shift to immature forms and numerous burr and target RBCs; bilirubin value (total/direct), 5.4/4.5 mg/dl; albumin concentration, 1.7 g/dl; prothrombin time, 18.5/10 sec; corrected sedimentation rate, 52 mm/hr; serum protein electrophoresis, a 5.7-g β-γ broad spike; IgG, 5 g; IgM and IgA, within normal limits; antinuclear antibody titer (ANA), 1:320 (diffuse pattern); anti-DNA, 41.5% (normal, < 12.5%); anti-extractable nuclear antigen (ENA), 19.5%; antimitochondrial, smooth muscle, and thyroid antibodies, and cryoglobulins, negative; rheumatoid factor, 1:160; C3, 18 mg/dl (normal, 48 to 92); C4, 8 mg/dl (normal, 18 to 40); Coombs' direct test results, positive; urinalysis, normal findings; and creatinine clearance, 125 ml/min. Barium studies of the entire gastrointestinal tract, proctoscopy, and rectal biopsy results were normal. After considerable discussion, the patient's condition was diagnosed as chronic active hepatitis and administration of prednisolone and mercaptopurine was begun. Tests of phagocytic cell function were performed early in his course of hospitalization before administration of antimetabolites or corticosteroids and before clinical evidence of infection developed.

The patient's liver functions continued to deteriorate in spite of treatment. Hepatic encephalopathy, bilateral pleural effusions, pericardial effusion with tamponade, progressive renal failure, and a bleeding diathesis developed, as well as a *Staphylococcus aureus* bacteremia that seemed to respond to a long course of nafcillin sodium. The pericardial and pleural effusions persisted, and on Oct 27 he suffered cardiac arrest and died.

Autopsy demonstrated postnecrotic cirrhosis typical of chronic active hepatitis. Mild proliferative glomerulonephritis, multiple autoantibodies, pericarditis and arthritis, and neuronal degeneration secondary to hepatic encephalopathy were also found and are consistent with chronic active hepatitis. The subclassification of this type of disease as "lupoid hepatitis," suggesting an association with systemic lupus erythematosus or an autoimmune variant of the disease, has provided no meaningful diagnostic, therapeutic, or etiologic differences between lupoid and nonlupoid groups.[18,19] The cause of death was believed to be infection secondary to immunosuppression; *Aspergillus* was found in the lungs and *S aureus* abscesses were found in the heart and pericardium.

METHOD

Separation of Cells

Heparinized venous blood (10 units of benzyl-alcohol-free heparin per milliliter of blood) from the patient was layered over 9% Ficoll-Hypaque and was centrifuged at 400 g for 40 minutes. The lymphocyte-monocyte rich layer was extracted and washed three times in RPMI (Roswell-Park Memorial Institute) tissue culture medium. Trypan blue exclusion and neutral red phagocytosis were performed to determine the percentage of phagocytic cells and their viability. The monocyte yield with this technique is usually between 20% and 40%; the remainder were lymphocytes. All results were adjusted for the percentage of mononuclear phagocytic cells in the final preparation.

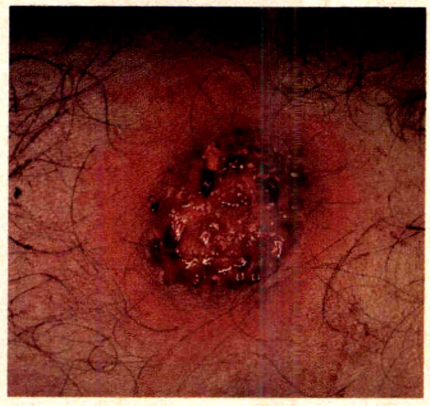

Fig 1.—Close-up of lesion on right leg shows central ulcer with blue overhanging border and ring of dusky erythema.

Polymorphonuclear phagocytes were obtained by layering heparinized venous blood over a 60% methylcellulose-Hypaque gradient for 30 minutes, separating the WBC-rich plasma, and centrifuging it for five minutes at 225 g. The cell pellet was resuspended in 0.5 ml of Hank's balanced salt solution with gel. Cell count and differential were then performed to determine the PMN yield, which was usually greater than 75% neutrophils.

Drug Incubation

Monocytes from the patient were incubated with hydrocortisone to see whether the functional defects could be corrected in vitro. Hydrocortisone sodium succinate was diluted in RPMI medium to 10^{-4} and 10^{-5}M concentration per liter. Monocytes were incubated with the drug and RPMI medium without drug as a control for one hour. The cells were then resuspended in fresh medium and functional assays performed. The cell preparations with and without drug contained the same number and percentage of monocytes.

A concurrent control of cells from a normal healthy donor was collected and separated at the same time as the patient's cells. Assays of cellular function were performed at the same time on patient and control.

Chemotaxis

Chemotaxis was performed by a modified Boyden chamber method[9] with acrylic plastic Swiss chambers and a sandwich of 8.0- and 0.45-μ filters (Millipore) separating the upper and lower chambers. Standard attractant was a 10% solution of human serum in tissue culture medium (RPMI for monocytes, Krebs without calcium for neutrophils) activated with *Escherichia coli* lipopolysaccharide endotoxin type 0111:B4 at 200 μg/ml. The same attractant was used for patient and controls and was added to the lower compartment of the chamber. To the upper chamber was added 0.250 ml of either a monocyte or neutrophil suspension containing 1×10^6 cells per milliliter. The monocyte-containing chambers were incubated for five hours at 37°C in a 5% carbon dioxide humidifier and the neutrophil chambers for one hour under the same conditions. The filters were removed, stained, dried, and mounted for reading. All assays were performed in triplicate. The cells on the upper surface of the 8-μ filter (nonmigrating) as well as those within the 8-μ filter, on the lower surface of the 8-μ filter, or on the surface of the 0.45-μ filter (migrating cells) were counted in ten high-power fields. The results were expressed as the percentage of monocytes or neutrophils migrating calculated by following formula:

$$\%M_m = M_m/(C_m + C_{nm})\ (M)$$

$$\%N_n = N_m/(C_m + C_{nm})\ (N)$$

where M_m indicates monocytes migrating, $C_m + C_{nm}$ indicates the total migrating and nonmigrating cells, M indicates the number of monocytes per 100 cells, N_m indicates the number of neutrophils migrating, and N indicates the number of neutrophils per 100 cells.

In the monocyte-containing filters, monocytes can be recognized by pseudopoda and size. Movement of lymphocytes into the filters is minimal. In the neutrophil assay, movement of contaminating monocytes is minimized by the short duration of the assay.

Bacterial Killing and Phagocytosis

With the lysostaphin technique of Tan et al,[21] killing is separated from phagocytosis in both neutrophils and monocytes.[20] With lysostaphin, a potent anti-staphylococcal agent that does not enter the cell, one can measure those organisms that have been engulfed but not yet killed.

A quantity of the drug-incubated cell suspension containing 10×10^6 monocytes or neutrophils was pelleted at 200 g and resuspended in 0.5 ml of 0.1% Hank's gel and 0.05 ml of heparin sodium. This was added to 0.5 ml of a 20% opsonization solution of AB negative serum in Hank's balanced salt solution and 0.1 ml of a bacterial suspension of *Staphylococcus aureus* 502, containing 10×10^6 bacteria, thus making a 1:1 monocyte-to-bacteria ratio or neutrophil-to-bacteria ratio. Dilutions of aliquots from the mixture were made in distilled water and were streaked over trypticase soy agar for baseline (zero hour) colony counts. The tubes were incubated on a tilt table for two hours at 37°C at 100% humidity. Appropriate dilutions in distilled water were performed at two hours, and the suspensions were streaked over agar for the two-hour colony count. Also, 0.2 ml of each two-hour sample was treated with 1 ml of 500 units/ml of lysostaphin, then neutralized with 0.1 ml 2.5% trypsin and streaked over agar after appropriate dilutions in distilled water. All

plates were incubated at 37°C for 24 hours, the number of colonies counted, and the counts corrected for differing dilutions. All assays were performed in duplicate.

Percent of total viable bacteria (%TVB) remaining after two hours' incubation was calculated from the following formula (parenthesis include dilutional corrections): % TVB equals the number of colonies after two hours incubation with cells (2.1×10^4) divided by the number of colonies at zero hours (1×10^5).

The percent of intracellular bacteria (%IB) was calculated from the following formula: % IB equals the number of colonies at two hours after lysostaphin (1.05×10^4) divided by the number of colonies at zero hour (1×10^5).

The percent extacellular bacteria (%EB) remaining represented the difference:

$$\%EB = \%TVB - \%IB$$

Intracellular bacteria (%IB) provide a measurement of bacteria ingested but not yet killed. Increase in %IB occurs when killing is diminished in the face of normal phagocytosis of viable bacteria. It is therefore an indirect indicator of killing. Percent extracellular bacteria (%EB) reflects phagocytosis of viable bacteria regardless of subsequent intracellular killing of the organisms. Increased %EB reflects diminished phagocytosis of organisms.

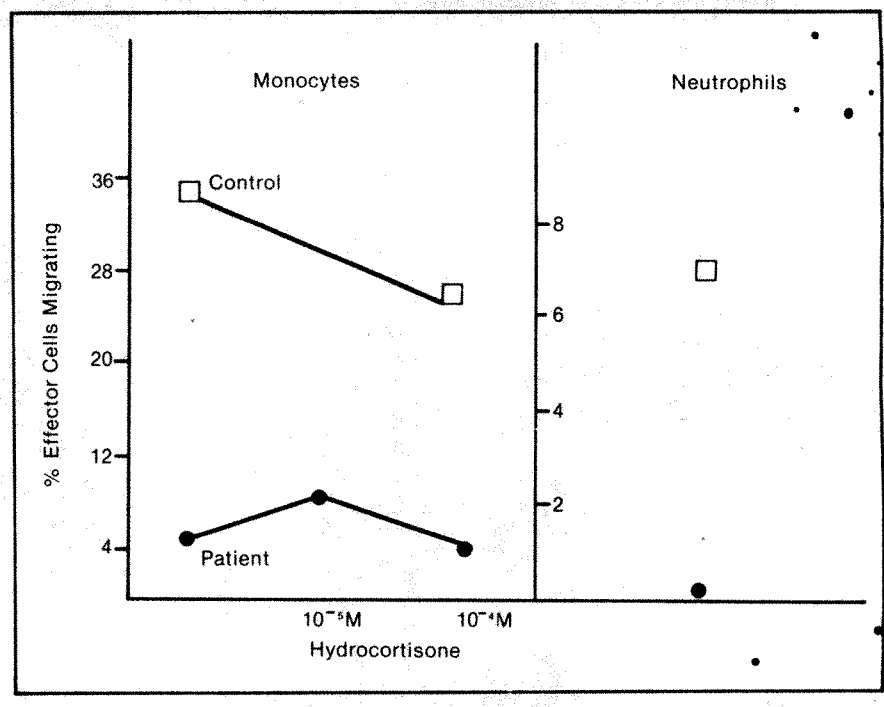

Fig. 2.—Chemotaxis of neutrophils and monocytes from patient (circles) and concurrent normal control (squares). Monocytes were also incubated in vitro with 10^{-5} and 10^{-4}M hydrocortisone. Data from control were well within laboratory range of normal. Points represent mean of triplicate assays.

Plasma Inhibitor Studies

Plasma from fresh heparinized blood of the patient and from a normal healthy control were added to the monocyte-rich cell suspension from a normal control and incubated for one hour to determine whether a plasma inhibitor of function was present in the patient's plasma. A 50:50 mixture of patient and control plasma was also studied to detect a correctable defect. The cells were then assayed for chemotaxis, bacterial killing, and phagocytosis and oil red O phagocytosis.

Oil Red O Phagocytosis

Oil red O phagocytosis was only used to evaluate the presence of inhibitor.

A mixture of paraffin oil and oil red O was prepared by a previously described method.[20] A suspension of 30 mg of *E coli* lipopolysaccharide 0111:B4 in 3 ml of Hank's balanced salt solution was placed in a 25-ml Erhlenmeyer flask and 1 ml of the paraffin oil containing oil red O was layered over it. This was placed in an ice-water bath and sonicated for 15 minutes using a sonicator set a 70 W. A mixture of 0.4 ml of this emulsion and 0.4 ml of fresh autologous serum was placed on a tilt table at 37°C for 15 minutes. Eight tenths of a milliliter of a suspension of cells (10^7 cells) preincubated with patient, control, or 50:50 plasma mixture were added to 0.2 ml of the opsonized oil particles and mixed in a water bath for five minutes. Six milliliters of ice cold, 1 mM N-ethylmaleimide was added, and the cells were pelleted at 500 g for 15 minutes. The supernatant containing uningested oil was discarded, and the cells were resuspended in 6 ml of 0.15M sodium chloride and centrifuged at 500 g for 15 minutes. The cellular button was resuspended in 3 ml of dioxane for 15 minutes at 85°C to release ingested paraffin-oil red O. The solutions were clarified at 1,000 g for 15 minutes and optical densities (OD) were read at 525 nm against a dioxane blank. Results were expressed as micrograms of paraffin ingested per 10^7 monocytes by the following formula:

$$[\,OD_{525} \times 50/(L \times M)\,] \times K$$

where L indicates the number of leukocytes per milliliter, M is the number of monocytes per 100 leukocytes, and K represents a constant for calculating the absorbance of oil red O at 525 nm into micrograms of paraffin oil ingested.

Statistics

Data were analyzed with the student's t test for significance.[22] Data from the patient were compared with the concurrent control for significance. There was no difference when significance was determined with the larger laboratory control population as opposed to the daily control.

RESULTS

Chemotaxis

Figure 2 shows the chemotaxis of neutrophils and monocytes for the patient and a concurrent control expressed as percent effector cells (monocytes or neutrophils) migrating over a five-hour (monocytes) or one-hour (neutrophils) incubation period. Migration of the patient's neutrophils and monocytes was significantly depressed ($P < .05$) when compared with the concurrent control and the normal laboratory range. Incubation of the patient's monocytes with hydrocortisone showed improvement from 4.26 to 8.03 at 10^{-5}M concentration ($P = .05$); but at 2 higher concentration, both the patient's and control's were diminished. However, even with hydrocortisone at 10^{-5}M, the patient's function was still below the 95% confidence limit of the standard laboratory range of normal controls. Chemotaxis of control cells in the presence of 10^{-5} hydrocortisone was not performed in this assay. Previous investigation in this laboratory and in others[23] showed inhibition of chemotaxis by 10^{-5}M hydrocortisone to be intermediate between that of 10^{-4}M and control.

Bacterial Phagocytosis and Killing

Figure 3 shows bacterial phagocytosis expressed as %EB surviving. An increase in %EB indicates impairment of phagocytosis. The patient's neutrophils showed no impairment of phagocytosis when compared with either the daily control or the laboratory normal range. The patient's monocyte phagocytosis was significantly impaired ($P = .05$) when compared with control. Hydrocortisone at 10^{-5}m concentration per liter significantly improved phagocytosis ($P = .05$), but the function was again diminished at 10^{-4}M concentration per liter. The decreased

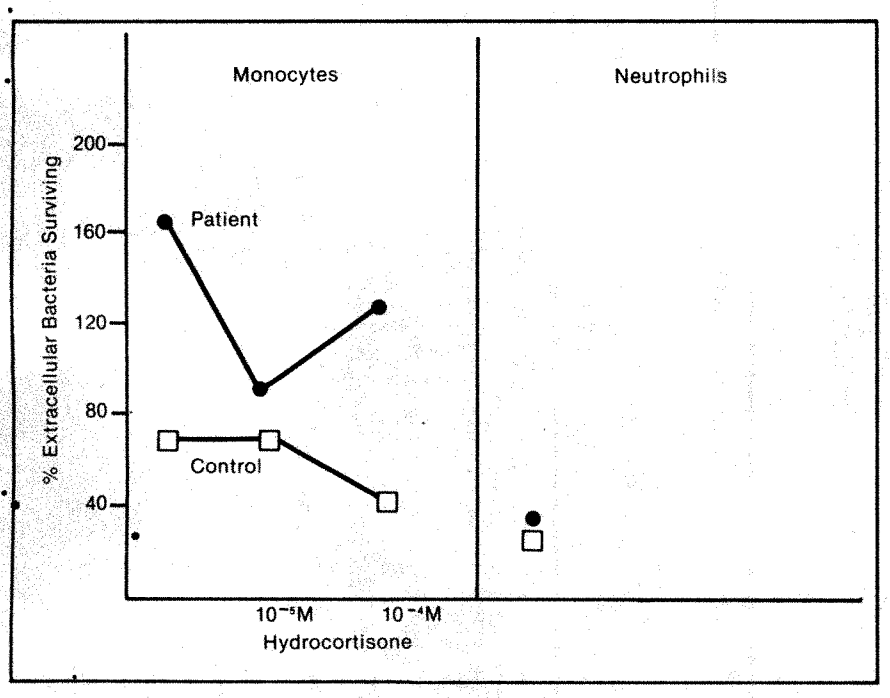

Fig 3.—Bacterial phagocytosis of neutrophils and monocytes from patient (circles) and concurrent normal control (squares). Monocytes were incubated in vitro with 10^{-5}M and 10^{-4}M hydrocortisone. Points represent mean of duplicate assays.

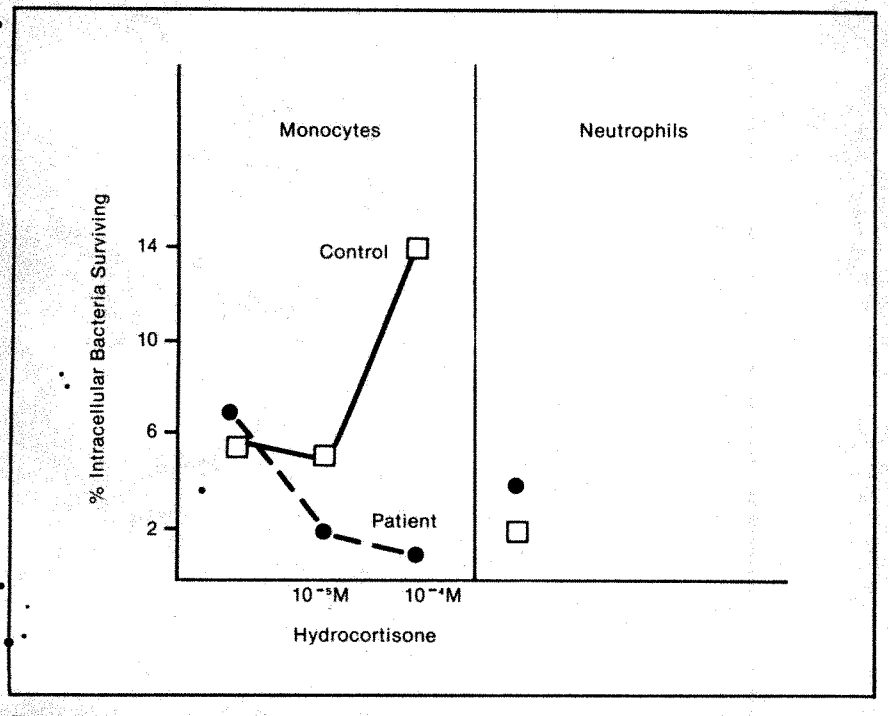

Fig 4.—Bacterial killing for monocytes and neutrophils from patient (circles) and normal control (squares). Data represent means of duplicate assays.

%EB seen with 10^{-4} hydrocortisone in the control was associated with a large increase in %IB described below.

Figure 4 shows %IB for monocytes and neutrophils. Increased %IB indicated diminished intracellular killing of phagocytized bacteria. Neither the baseline value for monocytes nor neutrophils was significantly elevated, but there was an interesting divergence of patient and control in the response of monocytes to hydrocortisone in vitro. The patient's intracellular killing was significantly improved by 10^{-4} and 10^{-5}M hydrocortisone ($P < .05$), while the control monocytes were significantly inhibited in killing at the higher concentrations.

Plasma Inhibitor Studies

The Table shows the comparative effect of incubating normal control cells in plasma from our patient with PG, a normal control, and in a 50:50 mixture of the two plasmas. The patient's plasma had no effect on either bacterial phagocytosis or killing by normal monocytes. It is important to note that, after incubation with the plasma, the cells in this assay system were resuspended in plasma free medium, thus removing any effect that would be created by a powerful opsonin in the patient's plasma. Chemotaxis is usually inhibited by the presence of normal plasma. The values obtained in the presence of normal and patient plasma were similar, but a 50:50 mixture produced significantly greater ($P = .02$) inhibition of chemotaxis. This suggests that the effects of the inhibitors were additive. This does not explain the inhibition of chemotaxis in our plasma-free experiments. Finally, oil red O phagocytosis was doubled when cells were incubated with plasma from a patient with PG. This suggests a powerful opsonin or potentiator of engulfment in the plasma of patients with PG.

Monocytes from this patient with PG showed diminished chemotaxis, and bacterial phagocytosis in vitro; these functions plus bacterial killing were significantly improved in vitro after one-hour incubation with 10^{-5}M hydrocortisone. Neutrophils from this patient showed diminished chemotaxis in vitro but normal killing and phagocytosis. In addition, the plasma from this patient augments paraffin oil phagocytosis by normal monocytes. Whether the defects described in this patient occur in all patients with PG must be verified by further investigation.

Plasma Inhibitor Studies			
Source of Plasma	**Patient**	**50:50**	**Control**
Bactericidal assay			
Phagocytosis, %EB*	138	122	118
Killing, %IB†	2	4	2
Chemotaxis, % monocytes migrating	19	10	15.6
Oil phagocytosis, μg oil/10^7 monocytes	0.1468	0.1258	0.0734

*EB, extracellular bacteria.
†IB, intracellular bacteria.

COMMENT

Distinct abnormalities in both humoral and cell-mediated immune response have been described in PG by many investigators. IgA, IgG, and IgM spikes in association with paraproteinemia or myeloma are often observed,[24,25] but immunofluorescent staining for immunoglobulins is usually negative in biopsy specimens from the clinical lesions. Lazarus et al[14] described four patients with PG and seronegative arthritis; cutaneous anergy to dinitrochlorobenzene, PPD, *Candida*, mumps, and streptokinase-streptodornase (SKSD); lack of migration inhibitory factor (MIF) release in vitro in response to PPD and SKSD, but positive response of lymphocytes in vitro to phytohemagglutinin (PHA). Phagocytic response was not measured per se, but nitro blue tetrazolium reduction was normal. Stolman et al described two patients with seropositive arthritis, cutaneous ulcerations, and similar cutaneous anergy, lack of MIF response in vitro, but normal PHA response.[15] Delescluse et al[26] reported depressed PHA response, cutaneous anergy, and a "dermonecrotic factor" in patients' sera that produced necrosis when injected into the patient's own skin. Long and Uesu[27] noted positive response to intradermal injection of the patient's own serum and rejection of skin autografts. Miller and Dooley described[28] two patients with depressed neutrophil random mobility and phagocytosis but with normal neutrophil chemotaxis. Shore[29] presented a patient with polycythemia rubra vera, PG, and defective neutrophil chemotaxis that was not corrected in vitro with control serum. The patient's serum had no effect on the function of normal neutrophils. Neutrophil phagocytosis and bactericidal activity were normal as was movement into a Rebuck skin window in vivo. Jacobs and Goetzl[30] demonstrated a "streaking leukocyte factor" found in the sera of patients with PG that enhanced the random mobility of both neutrophils and monocytes of normals without significantly increasing chemotaxis. This may be a potent chemokinetic factor that nondirectionally stimulates phagocyte movement. Finally, clofazimine,[31] a drug that enhances phagocytosis, has been found to produce clinical improvement in patients with PG.

The patient whose case we present had several abnormalities of immunologic responsiveness. He had a broad γ-β spike on serum protein electrophoresis and several specific autoantibodies (ANA, anti-n-DNA, anti-ENA, anti-IgG rheumatoid factor, and anti-RBC). Neutrophil chemotaxis was diminished in vitro, but phagocytosis and killing were normal. Monocyte chemotaxis, phagocytosis, and killing were all diminished in vitro and were significantly improved by hydrocortisone at 10^{-5}M in vitro. This concentration of hydrocortisone is one that can be achieved in vivo.[32] Higher concentrations of corticosteroids in vitro inhibit monocyte function.[33,34] It is unlikely that these findings (other than the autoantibodies) are simply related to chronic active hepatitis. The principle alterations in immunologic response in patients with chronic active hepatitis are increases in a variety of "autoantibody" levels[18,35] and production of lymphocytes that are cytotoxic to hepatocytes in vitro.[36] It is postulated that defective modulation of antibody production by suppressor T cells allows persistent hepatitis B antigenemia and the stimulation of killer lymphocytes that destroy hepatitis antigen containing hepatocytes. Opinions on therapy of chronic active hepatitis are divided between those who favor immunosuppressive therapy to ablate killer cell populations[19,37,38] and those who favor transfer factor[39] to increase helper T cell function, thus promoting anti-hepatitis B antibody production and efficient immune elimination of infected cells. To remove autoantibodies from our test systems, all cells were washed several times and resuspended in serum-free medium. Killer lymphocyte populations have not been shown to have any substantial effect on phagocyte function in vitro. The increase in phagocytic activity observed in normal cells incubated in the plasma of this patient with PG may have been related to the increased autoantibody levels or to the presence of increased opsonins (eg, C3b) in the plasma.

The wide variety of alterations in immunologic responsiveness in patients with PG and the variable, sometimes contradictory, results among different investigators force one to question whether there is a unifying immunologic mechanism in patients with PG or, indeed, if PG is a single disease or merely a clinical presentation with various different causes or pathomechanisms. This question cannot be resolved at this time. Certainly, the demonstration of deficiencies in lymphocyte, neutrophil, and monocyte function in patients with active lesions may be misleading. Pathologically, PG shows increased activity of effector cells of immunologic response with associated tissue destruction. Clinically, these patients react to minor trauma, skin grafts, or injection of autologous serum with increased immunologic responsiveness and tissue destruction. Although early postulates of Schwartzman's reaction[40] or other nonspecific destructive processes have generally been abandoned, it is reasonable to postulate that PG represents increased, misdirected effector cell responses against some factor in skin. The defects of peripheral blood effector cell function in vitro in these patients many reflect the release of immature cells into the peripheral blood in response to cutaneous stimuli as is seen in various chronic skin diseases,[41] "desensitization" of phagocytes as is seen in acute and chronic infection,[42,43] or altered responsiveness either as a cause or result of the PG process. Corticosteroids in vitro are potent suppressors of monocyte chemotaxis, phagocytosis, and killing in direct proportion to concentration.[23,33] The demonstration here of restoration of responsiveness in vitro after incubation of monocytes with hydrocortisone (which is therapeutically the most effective drug available in PG) suggests that altered monocyte responsiveness may be important in the pathomechanism of the disease and that the corrective mechanism of hydrocortisone may not be as immunosuppressant but as a restorer of *normal* responsiveness. The therapeutic effect of clofazimine may also be achieved by restoring altered phagocyte function to normal levels of

responsiveness. Careful investigation of effector function in vivo, characterization of tissue stimuli of effector cells, and the study of steroid effects on these responses may help relate the described alterations in lymphocyte, granulocyte, and monocyte function in PG to the progression and resolution of the lesions.

Since submission of this communication for publication, we have studied the monocyte function of two patients with PG and no associated disease. Monocyte chemotaxis was improved 88% and 90%, respectively, by incubation of the cells with 10^{-5}M concentration per liter of hydrocortisone.

The color cost for this article was paid by Westwood Pharmaceuticals, Inc.

Nonproprietary Name and Trademarks of Drug

Hydrocortisone—*Cort-Dome, Cortef, Cortifan, Cortril, Hycortole, Hydrocortone.*

References

1. Brunsting LA, Goerckerman WH, O'Leary PA: Pyoderma (ecthyma) gangrenosum: Clinical and experimental observations in five cases occurring in adults. *Arch Dermatol Syphilol* 22:665-680, 1930.
2. Perry HO: Pyoderma gangrenosum. *South Med J* 62:899-908, 1969.
3. Bishopric GA, Bracken JS: Pyoderma gangrenosum as the presenting sign of regional enteritis: Observations regarding the pathogenesis of the skin lesions. *South Med J* 57:675-678, 1964.
4. Ayres SA Jr, Ayres SA III: Pyoderma gangrenosum with the unusual syndrome of ulcers, vesicles and arthritis. *Arch Dermatol* 77:269-280, 1958.
5. Perry HO, Winkelmann RK: Bullous pyoderma gangrenosum and leukemia. *Arch Dermatol* 106:901-905, 1972.
6. Tay CH: Pyoderma gangrenosum and leukemia. *Arch Dermatol* 108:580-581, 1973.
7. Pyoderma gangrenosum, SOCIETY TRANSACTIONS. *Arch Dermatol* 109:269, 1974.
8. Feverman E, Potruch-Eisenkrafts: Pyoderma gangrenosum: Un cas de polycythemie vraie. *Bull Soc Fr Dermatol Syphil* 78:260-261, 1971.
9. Gopinath DK, Wolfe RD, Sabharwal K: Pyoderma gangrenosum with myelofibrosis. *J Ky Med Assoc* 72:548-550, 1974.
10. Moll JMH, Haslock I, MacCrae IF, et al: Association between ankylosing spondylitis, psoriatic arthritis, Reiter's disease, the intestinal arthropathies and Behcet's syndrome. *Medicine* 53:343-364, 1974.
11. Byrne JPH, Hewitt M, Summerly R: Pyoderma gangrenosum associated with active chronic hepatitis. *Arch Dermatol* 112:1297-1301, 1976.
12. Lever W, Lever GS: Bacterial diseases, in *Histopathology of the Skin*, ed 4. Philadelphia, JB Lippincott Co, 1967, p 273.
13. Braverman I: *Skin Signs of Systemic Disease.* Philadelphia, WB Saunders Co, 1970, p 309.
14. Lazarus GS, Goldsmith LA, Rocklin RE, et al: Pyoderma gangrenosum: Altered delayed hypersensitivity and polyarthritis. *Arch Dermatol* 105:46-51, 1972.
15. Stolman, LP, Rosenthal D, Yaworski R, et al: Pyoderma gangrenosum and rheumatoid arthritis. *Arch Dermatol* 111:1026, 1975.
16. Samitz MH: Cutaneous vasculitis in association with ulcerative colitis. *Cutis* 2:383-387, 1966.
17. Samitz MH, Dana AS, Rosenberg P: Cutaneous vascultitis in association with Crohn's disease. *Cutis* 6:51-56, 1970.
18. Read AE: Acute "juvenile" cirrhosis considered as part of a systemic disease and the effect of costicosteroid therapy. *Gut* 4:378, 1968.
19. Soloway RD, Summerskile WRJ, Baggenstross AH, et al: Clinical, biochemical and histological remission of severe chronic active liver disease: A controlled study of treatments and early prognosis. *Gastroenterology* 63:820-833, 1972.
20. Weston WL, Dustin RD, Hecht SK: Quantitative assays of human monocyte-macrophage function. *J Immunol Methods* 8:213-222, 1975.
21. Tan JS, Watanakunakorn C, Phair JP: A modified assay of neutrophil function: Use of lysostaphin to differentiate defective phagocytosis from impaired intracellular killing. *J Lab Clin Med* 78:315, 1971.
22. McCullough C, Van Aha L: *Statistical Concepts.* New York, McGraw Hill Book Co, 1963, p 241.
23. Rinehart, JJ, Balkerzak SP, Sagone AL, et al: Effect of costicosteroids on human monocyte function. *Clin Invest* 43:1337, 1975.
24. Ivis DS IV: Two cases of pyoderma gangrenosum associated with serum protein abnormalities (paraproteinemia). *Dermatologica* 132:409-433, 1968.
25. Cream JJ: Pyoderma gangrenosum with monoclonal IgM red cell agglomerating factor. *Br J Dermatol* 84:223-226, 1971.
26. Delescluse JD, de Bast C, Achten G: Pyoderma gangrenosum with altered cellular immunity and dermonecrotic factor. *Br J Dermatol* 87:529-532, 1972.
27. Long PI, Uesu CT: Pyoderma gangrenosum. *JAMA* 187:336-339, 1964.
28. Miller ME, Dooley R: Deficient random mobility, normal chemotaxis, and impaired phagocytosis: A new abnormality of neutrophil function. *Pediatr Res* 7:365, 1973.
29. Shore RN: Pyoderma gangrenosum, defective neutrophil chemotoxis, and leukemia. *Arch Dermatol* 112:1792-1793, 1976.
30. Jacobs JC, Goetzl EJ: "Streaking leukocyte factor," arthritis, and pyoderma gangrenosum. *Pediatrics* 56:570-578, 1975.
31. Michaelsson G, Molin L, Ohman S, et al: Clofazimine: A new agent for the treatment of pyoderma gangrenosum. *Arch Dermatol* 112:344, 1976.
32. King RJB: *Steroid-Cell Interactions.* Baltimore, University Park Press, 1974.
33. Norris DA, Weston WL, Sams WM: The effect of immunosuppressive and anti-inflammatory drugs on monocyte function in vitro. *J Lab Clin Med* 90:569-580, 1977.
34. Rinehart JJ, LoBuglio AS, Sayone AW, et al: Effect of corticosteroids on human monocyte function. *J Clin Invest* 54:1337-1343, 1975.
35. Read AE: Immunological liver disease. *J R Coll Physicians Lond* 8:31-36, 1973.
36. Eddleston ALWF, Williams R: Inadequate antibody response to HBAg or suppressor T-cell defect in development of active chronic hepatitis. *Lancet* 2:1543-1545, 1974.
37. Cook GC, Milligan R, Sherlock S: Controlled prospective trial of corticosteroid therapy in active chronic hepatitis. *Q J Med* 40:159-185, 1971.
38. Murray-Lyon IM, Stern RB, Williams R: Controlled trial of prednisone and azothioprine in active chronic hepatitis. *Lancet* 1:735-737, 1973.
39. Shulman S, Schulkind M, Ayoub E: Transfer factor treatment of chronic active hepatitis. *Lancet* 2:650, 1974.
40. Rostenberg A: The Shwartzman phenomenon: A review with a consideration of some possible dermatological manifestations. *Br J Dermatol* 65:389-409, 1953.
41. Meuret G, Schmitt E, Hagedorn M: Monocytopoeisis in chronic eczematous diseases: Psoriasis vulgaris and mycosis fungoides. *J Invest Dermatol* 66:22, 1976.
42. Mowat AG, Baum J: Polymorphonuclear leukocyte chemotaxis in patients with bacterial infections. *Br Med J* 3:617-619, 1971.
43. Keller HU, Hess MW, Cottier H: Inhibiting effects of human plasma and serum or neutrophil random migration and chemotaxis. *Blood* 44:843-848, 1974.

Sarcoidosis Associated With Mycosis Fungoides

Joseph P. McFarland, MD; Young C. Kauh, MD;
Herbert A. Luscombe, MD

• In November 1966, a 47-year-old black woman had a skin eruption and an abnormal chest roentgenogram that were found to be due to sarcoidosis. In September 1974, nodular lesions and subsequently generalized exfoliative dermatitis developed that were found to be due to mycosis fungoides. The concurrence of sarcoidosis and mycosis fungoides has been recorded only once in the literature. The depression of cell-mediated immunity found in this patient and other sarcoid patients suggests that impairment of the host's immunosurveillance system may predispose to the development of T-cell lymphomas.

(*Arch Dermatol* 114:912-915, 1978)

Concurrence of sarcoidosis and malignant lymphoma has been reported in the past,[1-7] but there is only one well-documented case of the development of mycosis fungoides in a patient with unquestionable sarcoidosis.[7]

The question of a relationship between sarcoidosis and the malignant reticuloendothelioses has been discussed at various times in the past. Three possible mechanisms have been postulated in reference to the coexistence of these two diseases. The first possible explanation is that the association of these two diseases is fortuitous.[3-5] Second, one may speculate that the granulomatous inflammation could be a local tissue reaction to an underlying malignant process rather than the occurrence of two separate disease processes.[1] Finally, one may hypothesize that malignant lymphoma may result from immunological deficiencies in patients with sarcoidosis.[2]

REPORT OF A CASE

A 47-year-old black woman was seen initially at the emergency room of a community hospital in November 1966 for complaints of a nonproductive cough, wheezing, dyspnea on exertion, and an asymptomatic erythematous skin lesion on the right forearm.

A chest roentgenogram demonstrated prominent hilar lymphadenopathy consistent with sarcoidosis. Following admission to the hospital, skin and scalene lymph node biopsies were done and both demonstrated noncaseating granulomatous foci with epithelioid, lymphoid, and giant cells (Fig 1). At discharge 10 mg daily of prednisone was prescribed.

In October 1969, she underwent a cholecystectomy for cholelithiasis, and an open liver biopsy showed noncaseating epithelioid granulomas.

In May 1971, her skin lesions became pruritic and more widespread, and she was admitted to the dermatology service of another hospital. Her skin showed disseminated, sharply marginated plaques and nodules. Some of the lesions were erythematous and smooth as on the forehead, whereas those on the trunk and thigh were hyperpigmented and scaly. A complete blood cell count, serum electrolytes, serum calcium concentration, and VDRL test results were within normal limits. Liver profile showed normal serum bilirubin and SGOT levels. However, the alkaline phosphatase and the lactic dehydrogenase values were 198 and 333 units/ml by automated analysis, respectively (respective normal ranges are 30 to 55 and 50 to 225 units/ml). Pulmonary function studies disclosed moderately severe lung restriction and mild airway obstruction. A chest x-ray film showed moderate infiltration of both lungs. Skin biopsy specimens indicated a granulomatous inflammation compatible with sarcoidosis (Fig 2). Chemotherapy was initiated on discharge: prednisone, 30 mg/day; chlorpropamide, 250 mg/day; and 0.1% triamcinolone acetonide cream applied three times daily.

She was admitted to Thomas Jefferson University Hospital for the first time in July 1973 for progression of her respiratory and dermatological problems. Skin and liver biopsies showed granulomas consistent with sarcoidosis. Special stains for fungal and acid-fast organisms were negative. The patient was discharged, on the following regimen: prednisone, 50 mg/day; trimeprazine tartrate, 2.5 mg orally four times daily; 0.1% triamcinolone acetonide cream; and sulfoxone sodium, 165 mg orally three times daily was added to alleviate the pruritus associated with the skin lesions. However, when her ankles became edematous and her blood glucose level rose to 385 mg/dl, the prednisone was discontinued and chlorpropamide, 250 mg daily, was prescribed to control her diabetes.

On Sept 26, 1974, she was readmitted following the development of nodular

Accepted for publication Sept 12, 1977.

From the Department of Dermatology, Thomas Jefferson University Hospital, Philadelphia.

Reprints not available.

lesions in the cervical area, right axilla, and right breast. On examination, the patient was dyspneic at rest. Inspiratory and expiratory wheezing as well as basilar rales were auscultated in both lung fields. Neither liver nor spleen were palpable. Dermatological examination disclosed generalized, beefy red, lichenified, desquamating patches and plaques with tumors, some of which were ulcerated (Fig 3). On admission, a hemogram was performed with the following results: hemoglobin level, 13.3 g/dl; hematocrit value, 38.4%; and WBC count, 13,700/cu mm, with 60% neutrophils, 9% lymphocytes, 5% mononuclear cells, and 4% eosinophils. The serum calcium level was 3.9 mEq/liter (normal, 4.4 to 5.4). Results of urinalysis were normal, except for the presence of 1 to 4 WBCs per high-power field and many bacteria. Serum protein electrophoresis yielded the following values: total protein 6.9 g/dl; albumin, 2.9 g/dl; α_1-globulin 0.2 g/dl; α_2-globulin, 0.3 g/dl; β-globulin, 1.3 g/dl; γ-globulin, 1.5 g/dl. Serum immunoelectrophoresis demonstrated an elevation in the IgA fraction. Blood gases were as follows: Po_2, 71 mm Hg; Pco_2, 33 mm Hg; pH, 7.43; oxygen saturation, 94%; Hco_3, 23 mEq/liter. Advanced fibrotic changes in both lung fields compatible with sarcoidosis were observed on a chest roentgenogram. Pulmonary function studies disclosed severe restrictive and minimal obstructive lung disease. No abnormality was detected in the ECG.

Skin biopsy specimens were obtained from two nodules on the anterior chest wall. Both specimens demonstrated acanthosis, spongiosis, elongation of the rete ridges, and Pautrier abscesses in the epidermis. In addition, a diffuse dermal infiltrate, composed of mycosis cells, lymphocytes, histiocytes, and plasma cells, was present. Both were interpreted as compatible with mycosis fungoides (Fig 4). A right axillary node biopsy disclosed atypical lymphoreticular hyperplasia and noncaseating granulomas. A buffy coat preparation of peripheral blood following PAS staining was negative for Sézary cells. Her hospitalization was complicated by an episode of generalized exfoliative dermatitis with the development of a superimposed pyoderma that was treated with prednisone (60 mg daily), cefazolin sodium (1 g) intramuscularly, oatmeal baths, and hydrophilic petrolatum. Prior to her discharge, electron-beam therapy was proposed as the therapeutic modality for her mycosis fungoides. Chlorpropamide (500 mg daily) was prescribed for her diabetes.

Although electron-beam therapy was initiated as an outpatient, the patient refused to continue the radiation therapy after a few appointments. On Feb 5, 1975, chlorambucil, 8 mg orally, was started in an effort to control her mycosis fungoides. Her condition improved substantially so that skin tests with intermediate PPD, mumps, *Candida* and streptokinase-streptodornase could be administered. At the same time Kveim tests with two antigens (Commonwealth serum lab lot 006 and Edinburgh lot 2A) were performed. All skin tests were nonreactive. The patient

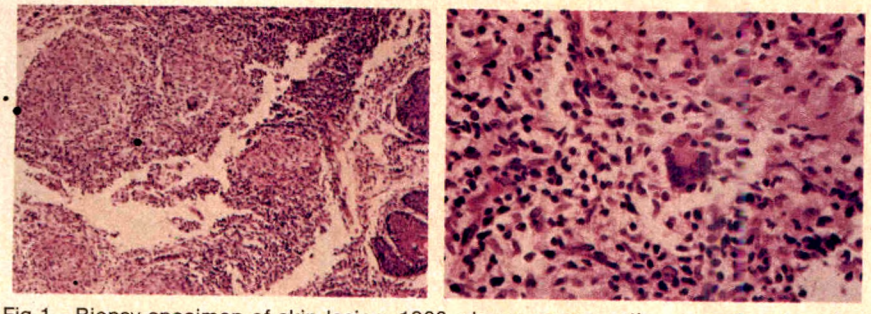

Fig 1.—Biopsy specimen of skin lesion, 1966, shows noncaseating granulomatous foci with epithelioid, lymphoid, and giant cells (original magnifications left, ×100; right, ×400).

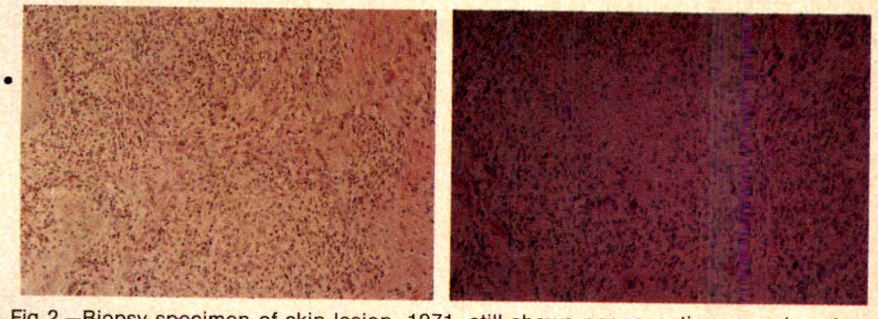

Fig 2.—Biopsy specimen of skin lesion, 1971, still shows noncaseating granulomatous infiltrations in dermis with dense epithelioid, lymphoid, and giant cells (original magnifications left, ×100; right, ×250).

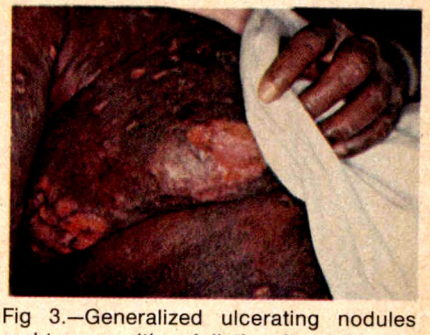

Fig 3.—Generalized ulcerating nodules and tumors with exfoliative dermatitis.

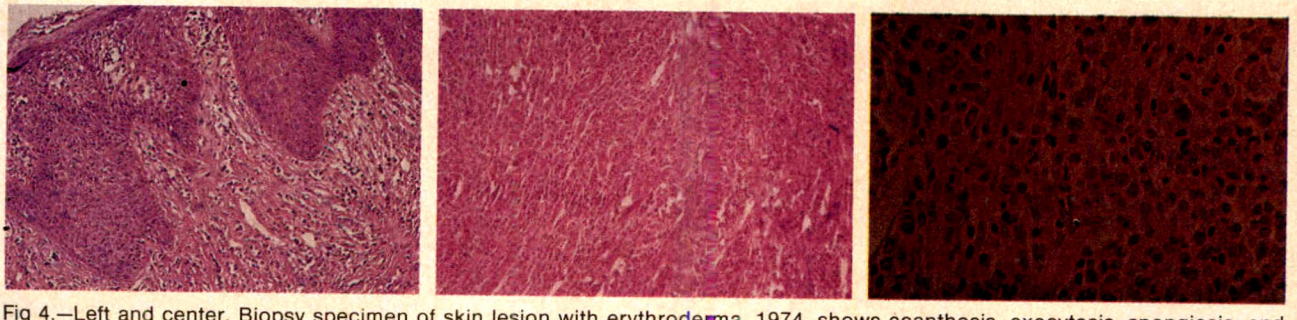

Fig 4.—Left and center, Biopsy specimen of skin lesion with erythroderma, 1974, shows acanthosis, exocytosis, spongiosis, and elongation of rete ridges with Pautrier abscesses in epidermis, diffuse monocytic infiltrations in dermis, and vasodilation (hematoxylin-eosin, original magnifications ×100). Right, Higher magnification of center micrograph shows dermis infiltrated mostly by mycosis cells, histiocytes, lymphocytes, plasma cells, and eosinophils (hematoxylin-eosin, original magnification ×400).

took the chlorambucil irregularly, and on Aug 8, 1975, she was readmitted to Jefferson with the plan of instituting topical mechlorethamine hydrochloride therapy. On the first day of admission, blood was drawn for both quantitative and qualitative lymphocyte studies. The WBC count was 7,900/cu mm with an absolute count of 798 lymphocytes. T lymphocytes, as determined by the E rosette assay, were 46% of the lymphocyte total (normal, 60% to 75%). B-lymphocytes, as detected by the EAC rosette assay, were 1% of the lymphocyte total; the remainder of the lymphocytes were unidentified. In vitro lymphocytic proliferative responses to phytohemagglutinin (PHA) and *Candida* antigens were performed using an isotope uptake by scintillation spectrometry.[8] The stimulation index for our patient's lymphocytes with exposure to PHA, 1:100 dilution, was 54.0 (normal = 50) and 4.0 to *Candida* (normal = 5.4 ± 1.4).

An attempt to induce tolerance to topical administration of mechlorethamine hydrochloride was made by administering 2 mg of the drug in 250 ml of saline intravenously over eight hours for 14 consecutive days. On the ninth day, a 10 mg vial of mechlorethamine hydrochloride was diluted in 50 ml of tap water and applied to her entire body surface except for the genitalia and intertriginous area. The topical application had to be curtailed for several days when the patient became leukopenic approximately two weeks following the completion of the intravenous mechlorethamine hydrochloride trial. When her blood cell count returned to normal, she was discharged and instructed to apply the mechlorethamine hydrochloride at the same dilution to her entire body surface every day.

Her condition showed little improvement, and in October 1975 more skin lesions began to develop; in addition, she complained of increasing fatigue and malaise. On examination her vital signs were within normal limits. Abnormal findings were limited to the lungs and skin. Auscultation of the lungs showed crackling rales at the left base and tubular breath sounds along the right sternal border. Infiltrated skin lesions ranging from plaques to tumor were detected over the entire body surface. Many lesions were ulcerated and purulent. Skin cultures from purulent ulcerated lesions demonstrated a mixed flora.

At this point systemic combined chemotherapy was initiated, consisting of doxorubicin hydrochloride, 82.5 mg intravenously once; cyclophosphamide, 990 mg intravenously once; vincristine sulfate, 1.98 mg intravenously once, and prednisone, 105 mg daily for five days. Chemotherapy at biweekly intervals was planned, but because of poor patient cooperation the chemotherapy was irregularly administered.

From January 1976 until the time of her death, she was readmitted to Jefferson on two other occasions for treatment of pyodermas that responded to both systemically and locally administered antibiotics.

On June 2, 1976, the patient lapsed into a comatose state. Chest x-ray film showed no change, and no definite cause for her deterioration was found. She died on June 3, 1976. Unfortunately, permission for necropsy was denied.

COMMENT

Prior to the epidemiological surveys Brincker conducted in Denmark, there was little evidence for a relationship between sarcoidosis and any of the malignant reticuloendothelioses. In his 1972 study, he found five cases of true sarcoidosis in about 1,500 cases of malignant lymphoma.[2] In a more extensive survey published in 1974, he found 48 patients who developed a malignant tumor among 2,544 patients with respiratory sarcoidosis registered in the Danish Institute of Clinical Epidemiology.[6] Only 33.8 malignant cases were expected if sarcoid patients had the same rates as the general population; the difference between the expected and observed number was considered statistically significant. Malignant lymphomas occurred 11 times more frequently than expected.

In reviewing these articles, one finds that in the first survey actually only two patients had unequivocal clinical and histological evidence of systemic sarcoidosis, one for 8 and one for 27 years, before malignant lymphoma was diagnosed. In one other case, the diagnosis of sarcoidosis was never confirmed histologically, but clinical findings such as fever, arthritis, erythema nodosum, nodal bilateral hilar node enlargement, and conjunctivitis were observed 14 years prior to the diagnosis of chronic lymphocytic leukemia. In the two other cases, sarcoidosis appeared many years after the diagnosis of Hodgkin's disease had been established.

In any event, the occurrence of two cases of sarcoidosis among 1,500 cases of malignant lymphoma is still high when compared with the incidence of four cases of sarcoidosis per 100,000 in the general population of Denmark.[9]

The accuracy of the second study may be questioned because of the existence of a reporting deficit of sarcoidosis cases diagnosed and treated in hospital departments other than the chest clinics and hence not reported to the central register. Although the magnitude of this reporting deficit is not known, this survey represents the only published attempt at estimating the incidence of lymphomas in a large series of sarcoidosis patients. Until another comparable survey is published, we will have to conclude that the coexistence of sarcoidosis and lymphoma is more than a fortuitous one.

Because of the numerous reports of sarcoid-like granulomas in a number of disease states, such as leprosy, tuberculosis, syphilis, brucellosis, leishmaniasis, fungus infections, and berylliosis, a distinction must be made as to whether the granulomatous inflammation was a tissue reaction to mycosis fungoides as opposed to the coincident development of two separate disease processes. Ackerman and Flaxman reported a case of mycosis fungoides in which the skin biopsy specimen demonstrated granulomatous features.[10] The granulomas were interpreted as a part of the mycosis fungoides rather than a manifestation of another disease because there was no clinical or laboratory evidence of sarcoidosis. To our knowledge this is only the third instance in which a lymphoma of the skin has followed cutaneous sarcoidosis.[1] In the first case, reported by Atwood et al a 49-year-old man developed asymptomatic extensive pigmented plaques and papules in 1954, and biopsies of these skin lesions revealed sarcoidosis. Kveim tests done on two separate occasions were positive. Roentgenographic examination showed bilateral hilar adenopathy with persistent infiltrates of both lower lobes. In 1960, another skin biopsy specimen was suggestive of both sarcoidosis and lymphoma, and a Kveim test was positive. When new infiltrated polycyclic skin lesions appeared in 1962, biopsies demonstrated mycosis fungoides.

Kahn et al described a 71-year-old woman who in 1969 had disseminated, circumscribed, elevated, erythematous plaques. Multiple biopsies of these lesions showed sarcoid-like granulomas. A Kveim test was not performed. Chest x-ray films showed a round shadow in the left lower lobe but no hilar lymphadenopathy. Bone marrow aspirations and liver biopsies did not show any signs of systemic sarcoidosis or lymphoma. A rapidly enlarging lesion above the left eye, which appeared three years later, proved to be a poorly differentiated tumor of the lymphocytic type.

It is uncertain whether Kahn and co-workers' patient had systemic sarcoidosis or a local tissue reaction to an underlying lymphoma. Atwood et al's case resembles our patient in that systemic sarcoidosis clearly preceded the development of mycosis fungoides. The presence of multiple organ involvement several years be-

fore the onset of mycosis fungoides in our patient is convincing evidence that the granulomatous lesions were indeed sarcoidosis as opposed to a nonspecific response to neoplasia.

In recent years it has become increasingly apparent that a defect in the host's immunological surveillance system may predispose to the development of malignancies. This observation has been reported with those patients receiving immunosuppressive therapy following transplantation,[11] in certain inherited disorders such as Louis-Bar, Chédiak-Steinbrinck-Higashi, and Aldrich's syndromes,[12] and with certain collagen vascular disorders, eg, dermatomyositis,[13] Sjögren's syndrome,[14] and systemic lupus erythematosus.[15]

As described in a recent review by James and coauthors, the cardinal immunological changes in sarcoidosis consist of hyperactive circulating antibody response, depression of delayed type hypersensitivity, and the Kveim-Siltzbach skin test phenomenon.[16] Except for the negative Kveim test results, our patient's immunological disturbances correspond closely to James et al's observations. Our patient's serum immunoelectrophoresis demonstrated an elevation of the IgA fraction. She had depression of delayed-type hypersensitivity both in vivo and in vitro. Skin tests for tuberculin, mumps, trichophyton, and streptokinase-streptodornase were nonreactive. The total number of lymphocytes and the percentage of both T- and B-lymphocytes were all decreased. However, the in vitro lymphocytic proliferative response to PHA was within normal limits. Unfortunately, those tests were conducted after the patient developed mycosis fungoides and was taking chlorambucil; they may be a result of either the malignant process or the immunosuppressive therapy.

Recently Lutzner et al have reported that both mycosis fungoides and Sézary's syndrome are cutaneous T-cell lymphomas.[17] When one combines those observations with the reported depressed cellular immunity observed in sarcoid patients, one must consider the possibility that the immunologic defect in sarcoidosis patients may predispose to the development of malignancies—particularly mycosis fungoides and Sézary's syndrome.

Schering Corporation assumed the cost of reproducing the color illustrations.

Lymphocyte studies were carried out in the laboratory of Burton Zweiman, MD, University of Pennsylvania School of Medicine.

Nonproprietary Names and Trademarks of Drugs

Cefazolin sodium—*Ancef.*
Doxorubicin hydrochloride—*Adriamycin.*
Vincristine sulfate—*Oncovin.*

References

1. Kahn LB, Gordon W, Camp R: Florid sarcoid reaction associated with lymphoma of the skin. *Cancer* 33:1117-1122, 1974.
2. Brincker H: Sarcoid reactions and sarcoidosis in Hodgkin's disease and other malignant lymphomata. *Br J Cancer* 26:120-128, 1972.
3. Goldfarb BL, Cohen SS: Coexistent disseminated sarcoidosis and Hodgkin's disease. *JAMA* 211:1525-1528, 1970.
4. Raben AC, Bogdanovich NK, Golochevakaya VS: A case of transformation of sarcoidosis into reticulosarcomatosis. *Probl Hematol* 6:763-769, 1961.
5. Silver NM, Nachnani G, Breslow A: Lymphosarcoma and sarcoidosis. *Am Rev Resp Dis* 96:290-295, 1967.
6. Brincker H, Wilbeck E: The incidence of malignant tumors in patients with respiratory sarcoidosis. *Br J Cancer* 29:247-251, 1974.
7. Atwood WG, Miller RC, Nelson CT: Sarcoidosis and the malignant lymphoreticular disorders. *Arch Dermatol* 94:144-151, 1966.
8. Zweiman B, Israel HL: Comparative in vitro reactivities of leucocytes from sarcoids and normals to different Kveim preparations. *NY Acad Sci* 278:700-710, 1976.
9. Brincker H, Wilbek E: The incidence of malignant tumors in patients with respiratory sarcoidosis. *Br J Cancer* 29:247-251, 1974.
10. Ackerman AB, Flaxman BA: Granulomatous mycosis fungoides. *Br J Dermatol* 82:397-401, 1970.
11. Penn, Starzl E: Malignant tumors arising de novo in immunosuppressed organ transplant recipients. *Transplantation* 14:407-417, 1972.
12. Lynch HJ: Skin, heredity, and cancer. *Cancer* 24:277, 1969.
13. Williams RC: Dermatomyositis and malignancy. *Ann Intern Med* 50:1174-1181, 1967.
14. Talal N, Sokoloff L, Barth WF: Extrasalivary lymphoid abnormalities in Sjogren's syndrome. *Am J Med* 43:50-65, 1967.
15. Nilsen LB, Missal ME, Condemi JC: Appearance of Hodgkin's disease in a patient with systemic lupus erythematosus. *Cancer* 20:1930-1933, 1967.
16. James GD, Neville E, Walker A: Immunology of sarcoidosis. *Am J Med* 59:388-394, 1975.
17. Lutzner M, Edelson R, Schein P, et al: Cell lymphoma: Sézary syndrome, mycosis fungoides, and related disorders. *Ann Intern Med* 83:534-552, 1975.

New Requirement for Authors

Congress recently passed *The Copyright Revision Act of 1976*, effective Jan 1, 1978, which affects the American Medical Association's procedure for reviewing manuscripts submitted for publication.

In view of this law, all transmittal letters accompanying manuscripts submitted for publication should contain the following language: "In consideration of the AMA taking action in reviewing and editing my submission, the author(s) undersigned hereby transfers, assigns, or otherwise conveys all copyright ownership to the AMA in the event that such work is published by the AMA."

Mycosis Fungoides Evolving to Myelomonocytic Leukemia

R. Kurt Lofgren, MD; John C. Wiltsie, MD; R. K. Winkelmann, MD, PhD

• Acute myelomonocytic leukemia, a type of leukemic conversion that may be a manifestation of mycosis fungoides, developed in two patients with fairly typical courses of mycosis fungoides. The cases of five other patients with myelogenous leukemia as the terminal event of mycosis fungoides have been reported in the literature. A relationship to therapy could not be established, although all patients had had irradiation or chemotherapy or both.

(*Arch Dermatol* 114:916-920, 1978)

Mycosis fungoides has been considered both as being a lymphoma in all its stages and as being a sequential inflammatory, proliferative, and malignant lymphoreticular disease of the skin. These two concepts differ principally in the approach to stage I and stage III diseases. Stage I mycosis fungoides is considered to be lymphoma according to the first view, even if the patient lives many years; the viscera show no changes, and a microscopic diagnosis of malignancy or even of mycosis fungoides at times cannot be made. The view of mycosis fungoides as always being a lymphoma also assumes that it does not transform into other reticuloendothelial or hematopoietic malignancies. The alternate view is that mycosis fungoides is a T-cell lymphoproliferative disorder that may transform into malignant lymphoma.[1] Many patients with stage III mycosis fungoides have variations in lymphoreticular malignancies and leukemia as the end stage. Although myelomonocytic leukemia is not common in mycosis fungoides, it has occurred. We present two cases to illustrate the relationship of long-standing mycosis fungoides to leukemia.

Accepted for publication Sept 16, 1977.

From the Departments of Dermatology (Drs Lofgren and Winkelmann) and Internal Medicine (Dr Wiltsie), and the Division of Hematology (Dr Wiltsie), Mayo Clinic and Mayo Foundation, Rochester, Minn.

Reprint requests to Section of Publications, Mayo Clinic, 200 First St SW, Rochester, MN 55901 (Dr Lofgren).

REPORT OF CASES

CASE 1.—In April 1970, a 57-year-old woman noted a nodule on her left thigh. The nodule had enlarged and became ulcerated. On her first visit in August 1970, examination showed poikiloderma, erythema, and some scaling of the trunk. The patient had cutaneous nodules on both lower extremities, a large ulcerated tumor on her left thigh (Fig 1, left), and keratoderma of her palms and soles. There was no substantial adenopathy, and results of the general physical examination were otherwise unremarkable.

At the initial visit, results of the

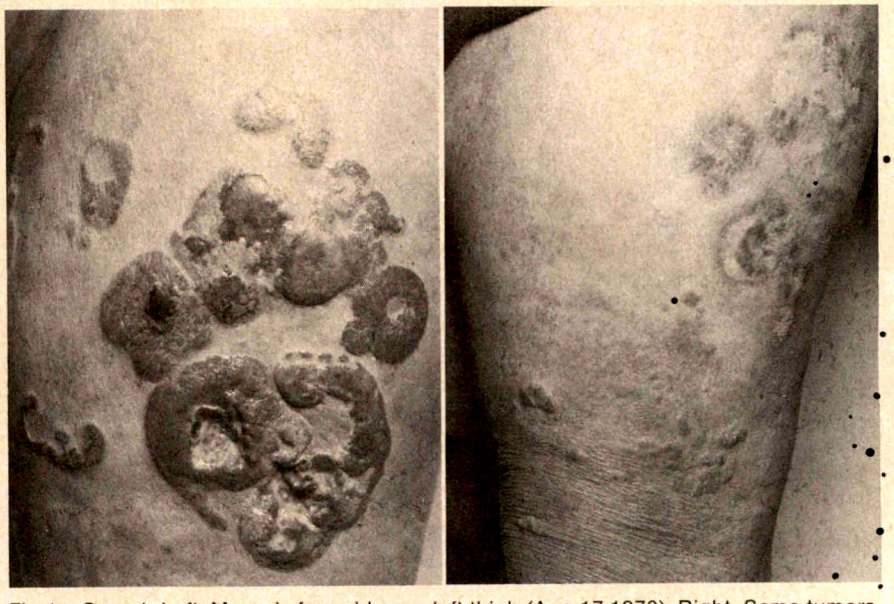

Fig 1.—Case 1. Left, Mycosis fungoides on left thigh (Aug 17,1970). Right, Same tumors after radiation therapy (March 22, 1971).

Fig 2.—Case 1. Top, Biopsy specimen of left thigh tumor (hematoxylin-eosin, original magnification ×66). Center, Peripheral smear demonstrating abnormal lymphocytes (July 2, 1976). Bottom, Bone marrow smear demonstrating myeloblast and promyelocytes with abnormal, coarse chromatin pattern and abnormal cytoplasmic granulation (Aug 2, 1976).

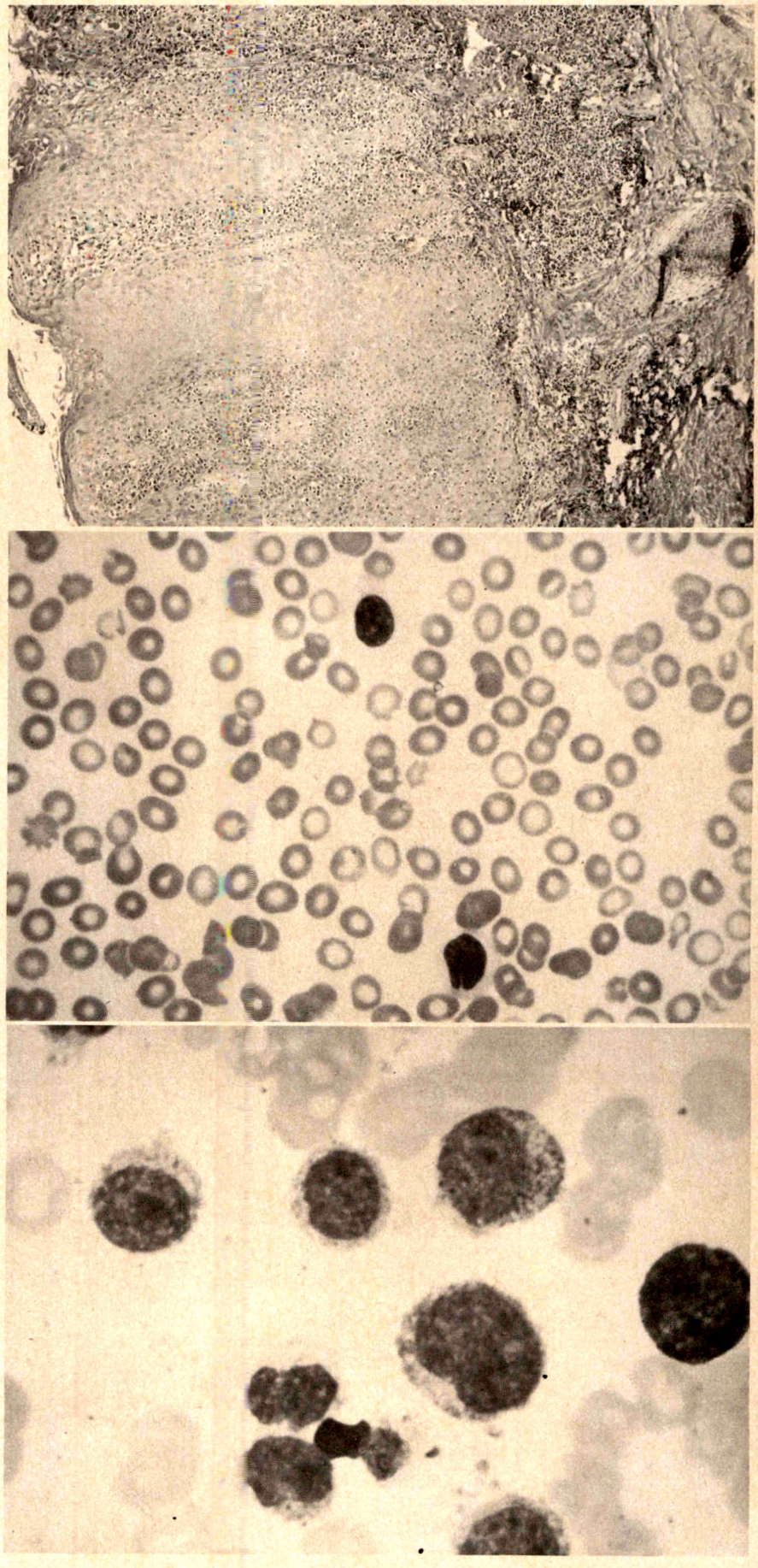

following tests were normal: urinalysis, hemogram, differential cell count, electrolyte levels, liver function tests, and ECG. A skin biopsy specimen demonstrated mycosis fungoides. A subsequent lymphangiogram and bone marrow examination showed no abnormalities. Initial therapy consisted of body bath radiation and focal radiation to the ulcerated left thigh lesion (Fig 1, right). Radiation therapy was repeated as needed until June 1971, when therapy with a topical nitrogen mustard, mechlorethamine hydrochloride, was started and continued as needed with occasional focal radiation every few months. Delayed hypersensitivity skin testing was done in January 1973, when the patient had an exacerbation that required hospitalization. At that time, one of the six antigens tested was positive. Reapplication in February 1974, when the patient was clinically much better, showed four positive reactions.

The patient returned in March 1975, with some improvement. She had recurrent infiltrated plaques on her left thigh and a new plaque on her left cheek. There were no palpable nodes; the liver and spleen were not enlarged. Results of urinalysis, hemogram, and the differential cell count were normal. Radiation therapy was prescribed. When the patient was seen again in November 1975, she had several infiltrated lesions on her right buttock, left cheek, and the front side of her left thigh. No laboratory work was done. A month of mechlorethamine was prescribed, but she did not use the medication until March 1976 because her symptoms were minimal.

On June 30, 1976, the patient was hospitalized after a febrile illness. There was no clinical evidence of mycosis fungoides, but her hemoglobin level was 7.8 gm/100 ml; hematocrit, 24.4%; platelet count, 120,000/cu mm; and leukocyte count, 2,000/cu mm, with a differential cell count of 5% polymorphonuclear leukocytes, 4% bands, 75% lymphocytes, 1% monocytes, 15% atypical lymphocytes (Fig 2, center), and 10% fragile cells. Results of the general physical examination were normal. There was no liver or spleen enlargement and no notable adenopathy. In spite of atypical lymphocytes in the peripheral blood, a bone marrow examination showed acute myelomonocytic leukemia (Fig 2, bottom). It was elected not to treat the leukemia immediately.

On Dec 15, a bone marrow examination demonstrated a hypercellular marrow with 80% blasts and promyelocytes; the numbers of lymphocytes, plasma cells, and megakaryocytes were decreased. The impression was that of acute myelomonocytic leukemia, and treatment was to begin on Dec 26.

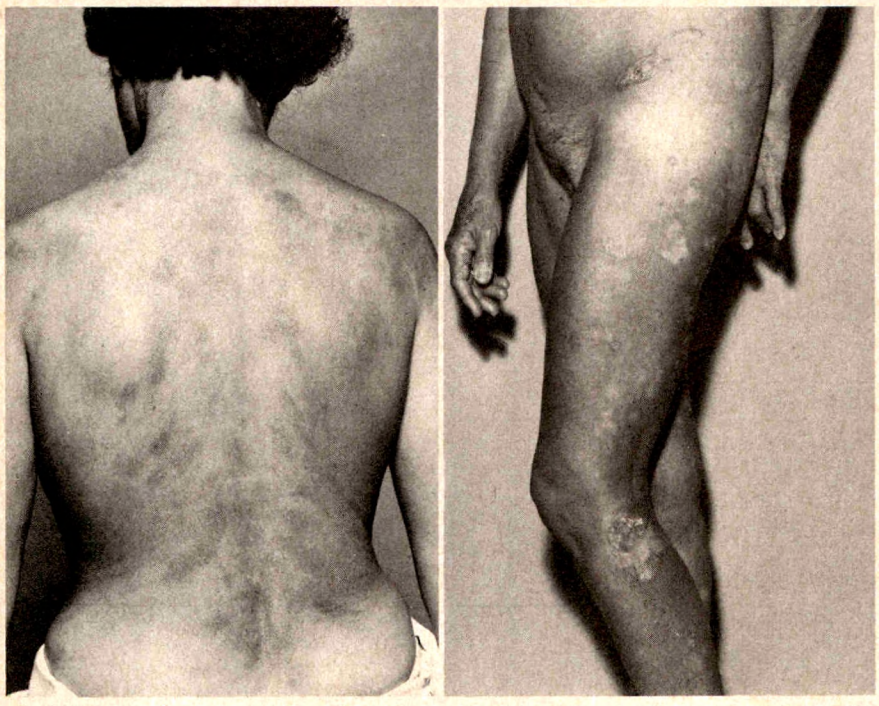

Fig 3.—Case 2. Left, Pruritic reddish-brown plaques (May 16, 1957). Right, Recurrent plaques of mycosis fungoides (Aug 22, 1966).

However, on Dec 22, the patient was hospitalized with a leukocyte count of 206,000/cu mm, with 98% blasts, a hemoglobin level of 4 gm/100 ml, and a platelet count of 23,000/cu mm. Despite aggressive cranial radiation therapy, 8 gm of hydroxyurea given intravenously, and leukapheresis, she died the following evening.

Case 2.—A 50-year-old woman was first seen at our clinic in May 1957 because of pruritic lesions on her back and shoulders (Fig 3, left). The lesions had been present for one year. Severe pruritus preceded the lesions, which were reddish-brown, oval plaques. The lesions persisted during the previous year, with none completely clearing (Fig 3, right). Results of the general physical examination were normal. Urinalysis, hemogram, differential cell count, chest roentgenogram, oral cholecystogram, upper gastrointestinal tract film series, and barium enema showed no abnormalities. The peripheral smear had an occasional myelocyte. A skin biopsy specimen demonstrated mycosis fungoides (Fig 4, top). A bone marrow study showed no abnormality. Initial treatment was radiation therapy.

For 15 years she received repeated focal radiation therapy and topical mechlorethamine for repeated recurrence of skin lesions and for several skin and mucous membrane nodules that were diagnosed as mycosis fungoides or lymphoma or both. She also received chlorambucil (2 mg/day for five months) between February and September 1969. Therapy was stopped because the leukocyte count was 2,800/cu mm and the differential cell count showed 55% polymorphonuclear leukocytes, 10.5% bands, 22% lymphocytes, 11% monocytes, 1% basophils, and 0.5% metamyelocytes.

In May 1972, when her condition was being treated with radiation therapy, her leukocyte count was 2,800/cu mm, with metamyelocytes, myelocytes, and blasts noted on the smear (Fig 4, center). In June the leukopenia was still present. Her skin had slightly sclerotic, hypopigmented plaques and her mouth had a small ulcer on the hard palate. Otherwise, results of the physical examination were normal. There was no enlargement of her liver or spleen, and there was no adenopathy. Her urine was normal. The hemoglobin level was 10.8 gm/100 ml; erythrocyte count, 4.03×10^6/cu mm; hematocrit value, 33.1%; platelet count, 303,000/cu mm; and leukocyte count, 2,800/cu mm, with 30.5% polymorphonuclear leukocytes, 5.5% bands, 42% lymphocytes, 12% monocytes, 0.5% eosinophils, 1% basophils, 0.5% metamyelocytes, 2% myelocytes, 1.5% promyelocytes, and 4.5% blasts. Results of a Coombs' test, electrolyte study, barium enema test, and liver scan were all negative or normal. Delayed hypersensitivity skin tests were positive for three of six antigens tested. A bone marrow smear showed increased erythropoiesis with distinct nuclear abnormalities, decreased maturation beyond the myelocyte level with hybrid granulation, and increased megakaryocytes with qualitative nuclear abnormalities diagnostic of evolving myelomonocytic leukemia (Fig 4, bottom). Her condition was not treated until December, when she received chemotherapy elsewhere. She died in January 1973, with disseminated aspergillosis and myelomonocytic leukemia confirmed at autopsy.

COMMENT

While generally, throughout its course, mycosis fungoides is limited to the skin, in some patients internal organs become involved and the disease may evolve into lymphoma or develop a leukemic phase. In 1966, on the basis of 165 cases of mycosis fungoides, Cyr et al[2] reported that 36 (34%) of 106 deceased patients had had a transition to lymphoma or leukemia. Fourteen patients had reticulum cell sarcoma, 15 had lymphosarcoma, and seven had Hodgkin's disease. In three patients with reticulum cell sarcoma, monocytic leukemia developed; and in four patients with lymphosarcoma, a leukemic phase developed prior to death. In that series of 165 patients, no patient had myeloid or granulocytic leukemia. Similarly, in Epstein and co-workers' study[3] of 144 patients with mycosis fungoides at the National Cancer Institute, no patients had terminal myeloid or granulocytic leukemia.

Only a few well-documented case reports of mycosis fungoides terminating in myelogenous leukemia exist in the literature (Table). In 1954, LeDonne[4] described a 46-year-old man who was originally seen with a generalized pruritic eruption of 20 years' duration and red, raised lesions that had been present for six months. A biopsy specimen demonstrated mycosis fungoides. Treatment included a total of 35 months of irradiation, urethan (1 to 2 gm/day for five months), two courses of intravenously administered mechlorethamine, and two courses of corticotropin. After five years of treatment, the patient became progressively ill and early myelogenous leukemia was diagnosed on bone marrow examination. At autopsy, the diagnoses of mycosis fungoides and chronic myelogenous leukemia were confirmed. In 1968, Sandbank and Katzenellenbogen[5] described a patient who, at the age of 18 years, had noted a red, smooth, gradually spreading eruption on her arms and legs. When she was 35 years old, mycosis fungoides was diagnosed by biopsy. Her treatment was intermittent and involved grenz ray and roentgen rays until the age of 53 years, 35 years after the onset of her eruption, when she complained of extreme weakness. A bone marrow smear showed acute myeloblastic leukemia.

There are a few case reports with important similarities but less documentation. In 1928, Hudelo and associates[6] reported the case of a 48-year-old woman who had a generalized pruritic eruption of 18 months' duration. Her eyebrows and ears were infiltrated. The spleen and the sub-

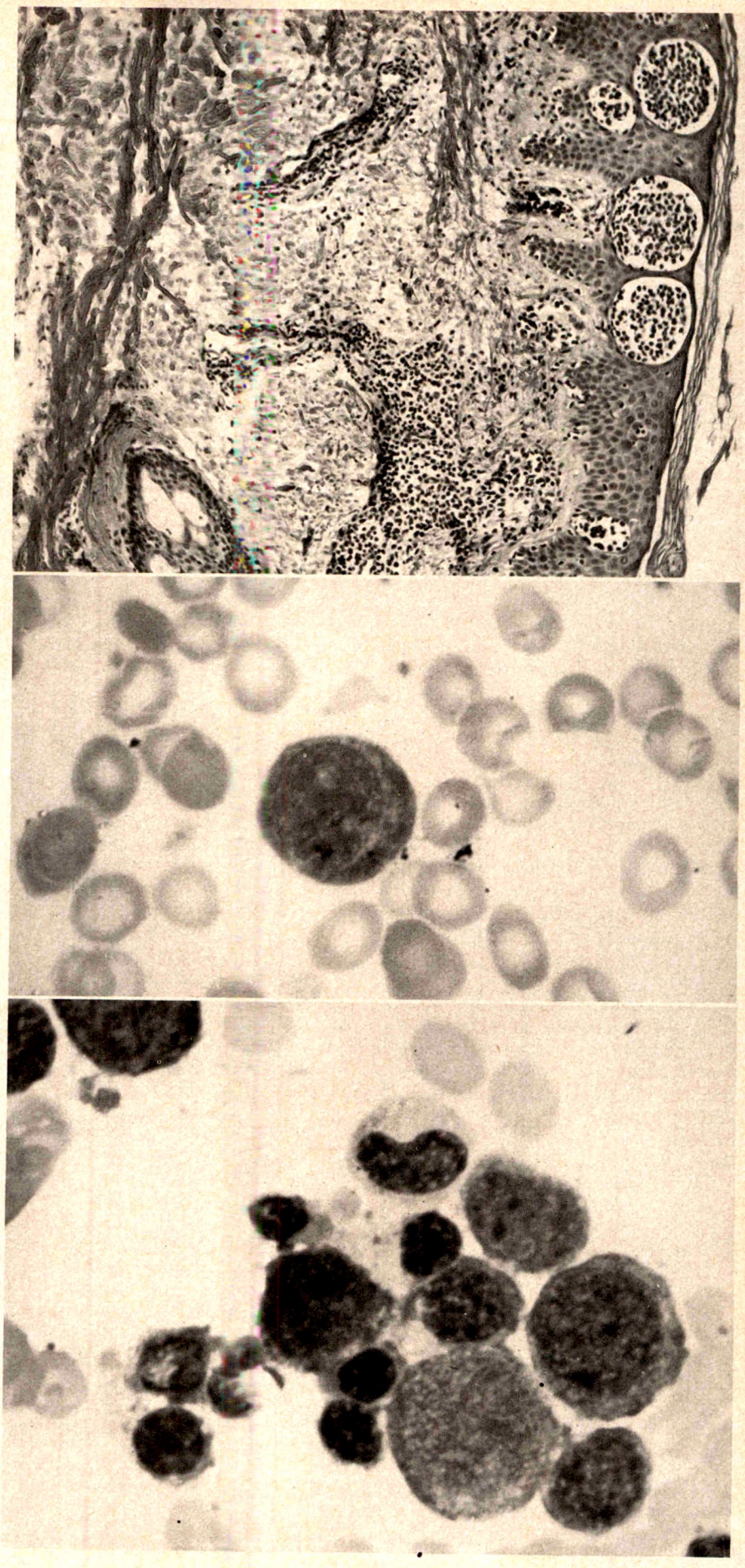

Fig 4.—Case 2. Top, Biopsy specimen of reddish-brown plaque (hematoxylin-eosin, original magnification ×100). Center, Peripheral smear demonstrating circulating malignant blast (June 8, 1972). Bottom, Bone marrow smear showing megaloblastoid erythropoiesis (June 4, 1972).

maxillary and axillary nodes were palpable. The peripheral smear showed a leukocyte count of 83,000/cu mm, with 48% myelocytes. A skin biopsy specimen revealed vacuoles in the epidermis, with lymphocytes and plasma cells. The dermis had a reticular type of cellular infiltrate, primarily with myelocytes, mast, plasma, and connective tissue cells, and frequent mitotic figures. The infiltrate was considered to be inflammatory and not neoplastic. A biopsy specimen had some features of mycosis fungoides, ie, Pautrier's abscess-type epidermal vacuoles and a mixed cellular infiltrate. There was clinical evidence of mycosis fungoides; the condition began as pruritus that developed into tumors, and the patient's general health was maintained despite two to three years of losing weight. The authors questioned whether this was primary leukemia with early skin involvement or mycosis fungoides with secondary leukemia.

In 1967, Feuerstein[7] described a 50-year-old woman whose condition was diagnosed as mycosis fungoides in 1952. Treatment consisted of intravenously administered mechlorethamine, cyclophosphamide, and grenz rays. In November 1963, her leukocyte count was 20,000/cu mm, with a differential cell count of 15% polymorphonuclear leukocytes, 3% lymphocytes, 4% monocytes, 4% eosinophils, 1% basophils, 4% blasts, 10% promyelocytes, 15% myelocytes, and 16% metamyelocytes. This was interpreted as either chronic granulocytic leukemia or leukemoid reaction.

Degos et al[8] reported the case of a 61-year-old woman who had had psoriasis for 30 years without pruritus and whose condition was treated with standard therapy. In 1947, she noted pruritus, and the clinical and histological diagnosis of mycosis fungoides was made. Irradiation had little effect on the confluent erythematous plaques and keratosis; however, the pruritus improved. In September 1955, when Degos and associates saw the patient, a biopsy specimen taken from the left flank tumor demonstrated mycosis fungoides. Bone marrow examination showed myeloid leukemia with many eosinophils.

All of the patients had received

Seven Patients With Mycosis Fungoides Evolving to Acute Myelomonocytic Leukemia

Author	Duration of Mycosis Fungoides, yr	Treatment	Status
Present study, case 1	5	X-rays; topical mechlorethamine	Acute myelomonocytic leukemia
Present study, case 2	15	X-rays; topical mechlorethamine; chlorambucil	Acute myelomonocytic leukemia
LeDonne[4]	5	X-rays; intravenous mechlorethamine; urethan; corticotropin	Chronic myelogenous leukemia
Sandbank & Katzenellenbogen[5]	18	X-rays; grenz rays	Acute myeloblastic leukemia
Hudelo et al[6]	2-3	. . .	Myeloid leukemia
Feuerstein[7]	11	Intravenous mechlorethamine; cyclophosphamide; grenz rays	Chronic granulocytic leukemia or leukemoid reaction
Degos et al[8]	7	X-rays	Myeloid leukemia with eosinophils

therapy that may have been part of the cause of the leukemia. Ionizing radiation is leukemogenic in experimental animals and humans.[9] Chronic lymphocytic leukemia is the only leukemia without evidence of being caused by radiation. Chronic granulocytic leukemia is more often associated with a single intense exposure, whereas multiple smaller exposures are associated with acute leukemia, especially nonlymphocytic.[10] Originally, the radiation used in treating mycosis fungoides in some patients was penetrating and was associated with leukopenia. In none of the presently reported cases can radiation be considered a definite etiologic factor in the development of leukemia and no radiation-associated leukopenia was noted.

Many of the patients in this report were given a topical nitrogen mustard, mechlorethamine, and some received intravenous mechlorethamine. Only the intravenous mechlorethamine has been associated with leukopenia. However, the question of the effect of topically absorbed mechlorethamine remains. Because mechlorethamine is considered to be radiomimetic, the toxic effects of radiation and mechlorethamine could be additive. Many patients received both radiation and mechlorethamine. The patients with myelomonocytic leukemia described herein had received urethan, cyclophosphamide, mechlorethamine, and chlorambucil. Systemic chemotherapy was related to myelomonocytic leukemia in patients with Wegener's granulomatosis whose conditions were treated with chlorambucil[11] and patients with renal disease whose conditions were treated with cyclophosphamide.[12] Our first patient had only topical mechlorethamine therapy and roentgen-ray therapy. The patients of Sandbank and Katzenellenbogen[5] and Degos and associates[8] had roentgen-ray therapy only. Because three patients in the group had no systemic chemotherapy, the relationship to myelomonocytic leukemia was not established.

A recent hypothesis of the cause of leukemia concerns the concept of an immune surveillance system that is constantly destroying newly transformed leukemic cells. Many of the modalities used to treat mycosis fungoides (such as radiation therapy) and certain chemotherapeutic agents (such as alkylating agents) also have been used successfully to depress the immune system in patients undergoing renal transplantation. This suggests the possibility that, by depressing the immune surveillance system, the therapy for the patient with mycosis fungoides may participate in the development of leukemia.

The development of leukemia in the two cases reported herein may be the coincidence of two independent malignancies, a complication of therapy, a manifestation of some predisposing factor common to acute myelomonocytic leukemia and mycosis fungoides, or the direct evolution of mycosis fungoides. A coincidence is unlikely, however, because both diseases are rare, but the other possibilities all raise intriguing questions about the etiology and treatment of mycosis fungoides. The recent demonstration of acute myelomonocytic leukemia occurring in a patient with nonHodgkin's lymphoma[13] indicates that these possibilities are current problems in malignant lymphocytic disease and that the relationship may be important in understanding the nature of such disease, including mycosis fungoides, and in planning safe, effective therapy.

Nonproprietary Names and Trademarks of Drugs

Corticotropin—*Acthar, Cortrophin, Cortrophin Zinc.*
Hydroxyurea—*Hydrea.*

References

1. Brehmer-Andersson E: Mycosis fungoides and its relation to Sézary's syndrome, lymphomatoid papulosis, and primary cutaneous Hodgkin's disease: A clinical, histopathologic and cytologic study of fourteen cases and a critical review of the literature. *Acta Derm Venereol* 56(suppl 75):71-21, 42, 1976.
2. Cyr DP, Geokas MC, Worsley GH: Mycosis fungoides: Hematologic findings and terminal course. *Arch Dermatol* 94:558-573, 1966.
3. Epstein EH Jr, Levin DL, Croft JD Jr, et al: Mycosis fungoides: Survival, prognostic features, response to therapy, and autopsy findings. *Medicine* 51:61-72, 1972.
4. LeDonne JE: Mycosis fungoides: Report of a case terminating in myelogenous leukemia. *N Engl J Med* 250:240-242, 1954.
5. Sandbank M, Katzenellenbogen I: Mycosis fungoides of prolonged duration in siblings. *Arch Dermatol* 98:620-627, 1968.
6. Hudelo L, Cailliau F, Chène: Leucémie myeloïde avec éruptions polymorphes et infiltrations tumorales (rapports avec le mycosis fongoide). *Bull Soc Fr Dermatol Syphilol* 35:193-204, 1928.
7. Feuerstein W: Mykosis fungoides mit terminaler myeloisch-leukämoider Reaktion. *Dermatol Wochenschr* 153:524-535, 1967.
8. Degos R, Delort J, Ossipowski B, et al: Leucose myeloïde terminant l'évolution d'un mycosis fongoïde; précession d'un psoriasis (6e cas)? *Bull Soc Fr Dermatol Syphilol* 62:476-478, 1955.
9. Gunz F, Baikie AG: *Leukemia*, ed 3. New York, Grune & Stratton Inc, 1974, p 98.
10. Linman JW: *Hematology: Physiologic, Pathophysiologic, and Clinical Principles.* New York, Macmillan Co, 1975, pp 540-544.
11. Westberg NG, Swolin B: Acute myeloid leukaemia appearing in two patients after prolonged continuous chlorambucil treatment for Wegener's granulomatosis. *Acta Med Scand* 199:373-377, 1976.
12. Roberts MM: Acute leukaemia after immunosuppressive therapy. *Lancet* 2:768-770, 1976.
13. Ligorsky RD, Axelrod AR, Mandell GH, et al: Acute myelomonocytic leukemia in a patient with macroglobulinemia and malignant lymphoma. *Cancer* 39:1156-1162, 1977.

α_1-Antitrypsin Deficiency Associated With Persistent Cutaneous Vasculitis

Occurrence in a Child With Liver Disease

Flemming Brandrup, MD, Poul Aa. Østergaard, MD

• α_1-Antitrypsin (α_1-AT) deficiency is an autosomal recessive inherited disease. The serum concentration of the protease inhibitor (Pi) α_1-AT is controlled by a set of codominant allelic genes, constituting the so-called Pi system. Abnormal conditions reported in connection with severe α_1-AT deficiency of the PiZZ type have been, in the newborn, cholestasis and progressive juvenile cirrhosis, and in adults, panacinar pulmonary emphysema and liver disease. Skin changes have not been described previously in connection with this disease picture.

The case is persistent cutaneous vasculitis in a 2-year-old child with α_1-AT deficiency of the PiZZ type, heterozygosity for the Duarte variant of galactose-1-phosphate uridyl transferase, and neonatal liver disease. A pathogenetic relationship may exist between the biochemical defects and both the skin and liver diseases.

(*Arch Dermatol* 114:921-924, 1978)

α_1-Antitrypsin (α_1-AT) is a glycoprotein that is formed in the liver and secreted into the plasma, where it occurs as the most important protease inhibitor (Pi).

Starch gel electrophoresis has demonstrated that α_1-AT shows genetic polymorphism.[1] The electrophoretic mobility and the serum concentration are controlled by a set of codominant allelic genes that constitute the so-called Pi system.[1] The Pi system contains more than 20 different allelic genes, designated by letters in relation to their electrophoretic mobility. The phenotype PiMM occurs most frequently, and corresponds to a normal serum concentration of α_1-AT. The phenotype PiZZ occurs in Scandinavia in the proportion of one per 1,500 individuals,[2,3] and corresponds to an α_1-AT concentration of 10% to 15% of the normal value.

α_1-Antitrypsin deficiency appears to have an autosomal recessive mode of inheritance,[1,4-6] in which the separate genes have complete penetrance, so that the concentration of α_1-AT in the individual depends on the additive effect of the two allelic genes.

A number of the patients with severe α_1-AT deficiency of the PiZZ type contract severe, panacinar emphysema, which often leads to death before the age of 50 years.[2] The heterozygote has an intermediate concentration of α_1-AT, and the question of whether these subjects have an increased prevalence of lung disease still does not appear to be settled.[7]

Sharp et al, in 1969, reported a number of cases of severe and rapidly progressive cirrhosis of the liver in children with α_1-AT deficiency.[6] Subsequent histological, histochemical, and electron microscopic studies revealed characteristic changes.[8] Within the hepatocytes were found globules of homogeneous material staining strongly red with PAS, and immunofluorescence showed that this material was a glycoprotein resembling α_1-AT.[8,9]

A number of reports have appeared in recent years describing similar changes in the liver cells in adults with severe α_1-AT deficiency and lung disease.[10-14] Some of these patients had clinical signs of cirrhosis of the liver and increased occurrence of carcinoma of the liver.[10] An electrophoretic study of the α_1-AT-like material accumulated in the liver cells showed that, in contrast to the genuine protein, this material lacke sialic acid,[15] and it is possible that the disease is determined by a defect in secretion due to reduced sialyl-transferase activity.[16]

A case was reported recently[17] of neonatal jaundice and cirrhosis in a child with phenotype PiZZ who was, at the same time, homozygous for the Duarte variant of galactose-1-phosphate uridyl transferase. The authors suggested that the Duarte variant might be specifically associated with the development of liver disease in phenotype PiZZ subjects.

Specific skin changes have not been described previously in association with α_1-AT deficiency and liver disease in children. We therefore find it of some interest to report a case of chronic papular eruption with histological vasculitis in a 2-year-old child with congenital disease of the liver and α_1-AT deficiency.

REPORT OF A CASE

A 2-year-old girl was observed in the dermatology department from birth because of a therapy-resistant, nonpruritic rash.

There was no family history of the condition. The child was the second of two children. Her sister, aged 6, was healthy. At the age of 16 years, her mother underwent treatment for pulmonary tuberculosis, and, during the last two months of pregnancy, she received prophylaxis with isoniazid. Pregnancy was otherwise without complications.

The delivery was normal. Birth weight was 4,080 g, length was 53 cm. The infant

Accepted for publication Sept 14, 1977.

From the Departments of Dermatology (Dr Brandrup) and Pediatrics (Dr Østergaard), Odense (Denmark) University Hospital. Dr Brandrup is now with the Department of Dermatology, Gentofte Hospital, Hellerup, Denmark.

Reprint requests to the Department of Dermatology, Gentofte Hospital, Niels Andersensvej 65, DK-2900, Hellerup, Denmark (Dr Brandrup).

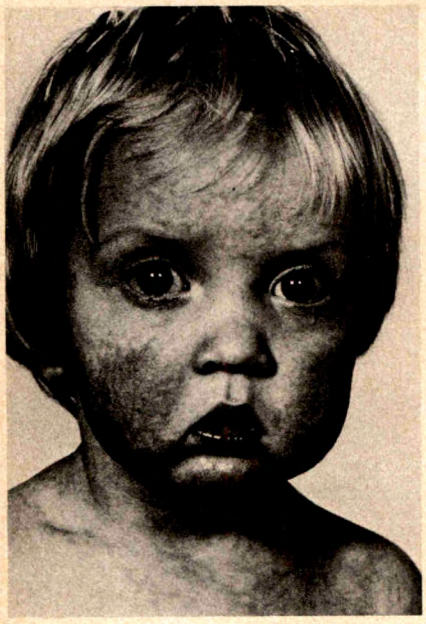

Fig 1.—Child at 14 months. Papular, infiltrated, red, nonpruritic skin eruption on face and shoulders.

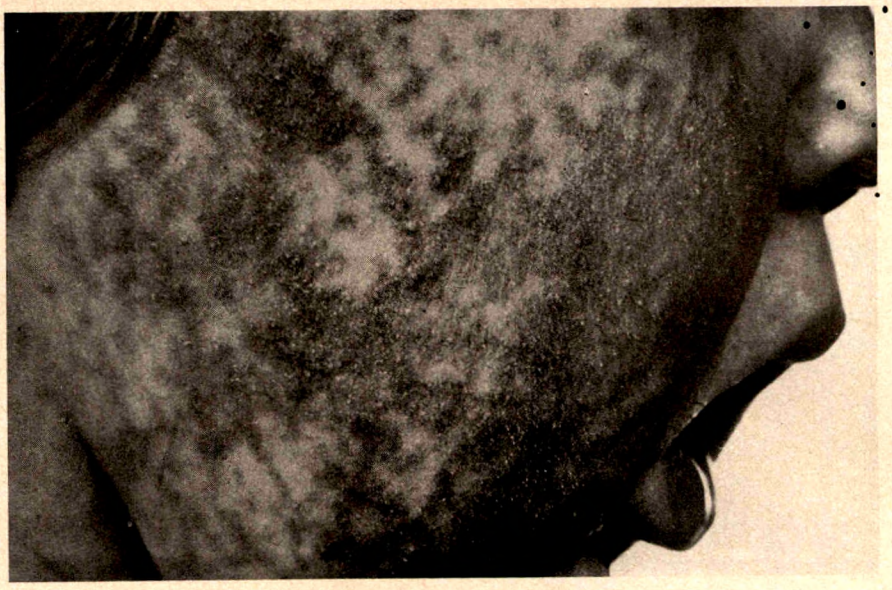

Fig 2.—Close-up of right cheek.

had protracted neonatal jaundice, persisting for about 2½ months and accompanied by feeding problems, with attacks of vomiting and failure to thrive normally. The infant was therefore admitted at the age of 4 months to the pediatric department, where the jaundice was found to have disappeared, but the liver was enlarged, extended 3 to 4 cm below the costal margin, and was blunt-edged and firm. During this period the patient's condition was characterized by recurrent upper respiratory tract infection and gastroenteritis.

Values for SGOT, SGPT, and serum lactic dehydrogenase were found to be elevated, but the serum bilirubin value was normal. There was no serological evidence of toxoplasmosis or cytomegalovirus infection, and hepatitis-associated antigen was not demonstrated. Reduced α_1-AT concentration was found in the serum, values of 32 and 55 arbitrary units being found (normal, 61 to 145), and starch gel electrophoresis showed α_1-AT reduced to 25% of normal and of type PiZZ. Relative leukopenia was found during the first 1½ years of life, and at the age of 14 months there was a leukocyte count of 9,000/μl and 94% lymphocytes in a differential count. Bone marrow aspiration from the crista showed, at that stage, normoplasia with an increased number of lymphocytic cells, while the peripheral blood showed granulocytopenia and relative lymphocytosis.

On examination the galactose-1-phosphate uridyl transferase activity was found to be reduced (0.269 μmole/min/g hemoglobin), and on electrophoresis the phenotype Gt 2-1 was found, corresponding to the heterozygous state for the Duarte variant.

The child has been thriving normally and showing normal psychomotor development. An attack of chicken pox has had a normal course. At 2½ years of age, she was hospitalized because of pneumonia and otitis, after an attack of measles. The liver is still enlarged, 3 cm below the costal margin, and SGOT and SGPT levels are elevated. The blood picture has since normalized spontaneously. Throughout the course of the disease the hemoglobin concentration, erythrocyte count, and the thrombocyte count have been normal. There has been no proteinuria or hematuria, and serum creatinine clearance was normal. The ESR was normal or slightly elevated. Normal concentrations of IgG, IgA, and IgM were found in the serum.

FINDINGS

Skin

Since birth the child has had a generalized, nonpruritic rash. At the age of 24 hours, there was a finely macular exanthema, most pronounced on the limbs and the face. At the age of four months, there was an almost generalized, papular, strongly red rash, particularly dense on the face and the extensor aspect of the limbs. The skin was generally grayish and mottled. While a patient of the dermatology department, at the age of 14 months, no change was found in the papular, strongly red rash on the face (Fig 1 and 2), extensor aspect of the arms, and back of the hands. There was a more papular, scattered rash on the trunk and thighs. Trunk, buttocks, and lower limbs showed pronounced cutis marmorata (Fig 3). No purpura or petechiae were found.

Histology

Punch biopsy specimens from affected skin showed slightly acanthotic epidermis. The upper half of the corium showed a number of rather

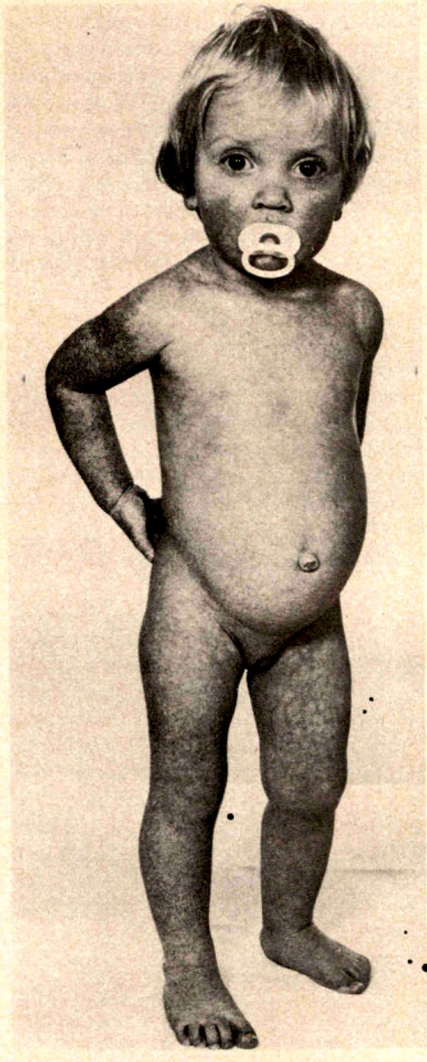

Fig 3.—Child at 14 months. Papular eruption on face, shoulders, and at extensor aspects of arms. Livedo reticularris on lower limbs.

Fig 4.—Blood vessel localized superficially in corium, showing endothelial proliferation, edema of vascular wall, and infiltration with mainly polymorphonuclear leukocytes (hematoxylin-eosin, original magnification ×140).

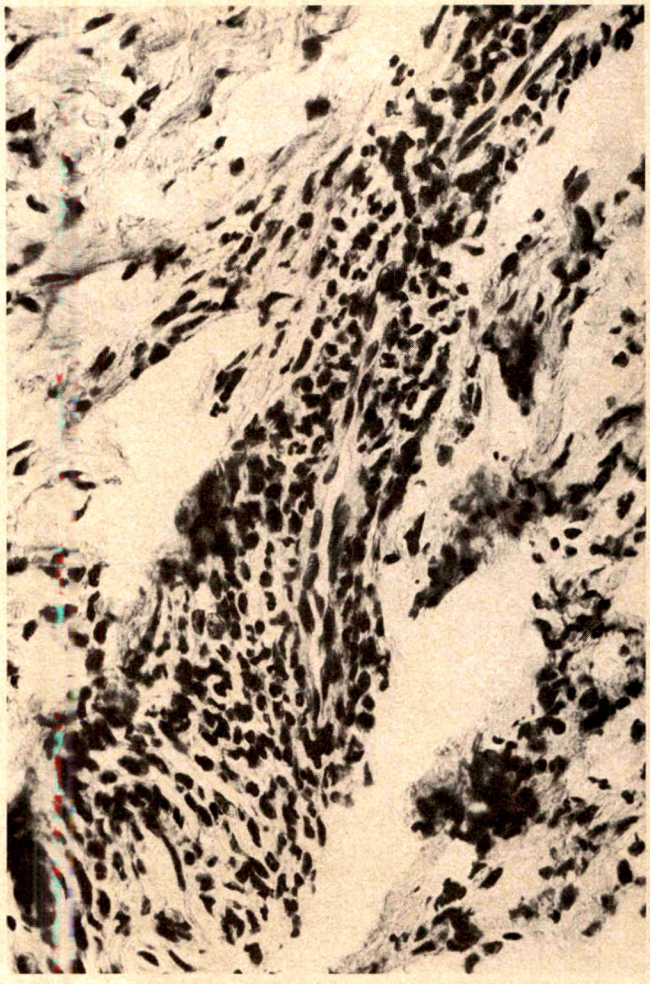

Fig 5.—Part of blood vessel showing infiltration with sleeve of lymphocytes and granulocytes (hematoxylin-eosin, original magnification ×350).

thick-walled vessels with infiltration in the vessel walls, consisting mainly of granulocytes, a number of them eosinophilic (Fig 4). The vessels were also found to be surrounded by a sleeve of lymphocytes and granulocytes (Fig 5). There was no extravasation of erythrocytes. No epithelioid cell granulomas or xanthoma cells were found. The vessel walls contained no fibrinoid necrosis. Small basophilic particles resembling "nuclear dust" were seen scattered throughout the corium. The microscopic diagnosis was vasculitis.

Immunofluorescence Studies

A 4-mm punch biopsy specimen was obtained from the hip region after local freezing. The biopsy specimen was frozen instantaneously in liquid nitrogen and stored at −80 °C until investigation. The immunofluorescent study was made using a method described previously.[18] Sections of a thickness of 6 μM were washed in buffered saline phosphate, pH 7.2 for ten minutes and incubated with fluorescein-conjugated antihuman IgG, IgA, IgM, antifibrinogen, anticomplement C3 and anti-α_1-AT. After incubation for thirty minutes, the sections were washed three times in buffered saline phosphate for five minutes. The sections were examined for the presence of in vivo bound antibody. Microscopy was performed with a dark-field microscope with a mercury (HBO 200 W) light source. An exciter filter (BC 12/3) and a (Zeiss) barrier filter were used.

Conjugates

Fluorescein-conjugated rabbit antihuman IgG (FITC) was used. The molar fluorescein-protein ratio was 1.4. By immunoelectrophoresis, only one precipitation band was found in the IgG region. The conjugate was diluted to 1:32 before use. The plateau end point titer was 1:128. The fluorescein-conjugated anti-IgA and anti-IgM were diluted to 1:20, the fluorescein-conjugated antifibrinogen and anti-C3 to 1:16, and the fluorescein-conjugated anti-α_1-AT to 1:32. The dilution ratios of all the conjugates were chosen to produce the clearest fluorescence.

With anti-IgG diffuse fluorescence was found in the dermis, while no fluorescence was found with anti-IgA and anti-IgM. After incubation with anti-C3, granular fluorescence was found in some papilla tips. After incubation with antifibrinogen, considerable fluorescence was found in the dermis, mainly localized to the dermal vessels. The changes are compatible with vasculitis. After incubation with antiserum to α_1-AT, scattered true fluorescence was found in the dermis. The fluorescence seemed to be localized mostly to vascular walls and the perivascular area.

Cellular Immunity

An examination of cellular immunity showed normal conditions in lymphocyte transformation tests. The following tests were performed: (1)

mitogen stimulation with phytohemagglutinin and poke weed mitogen; (2) specific antigen stimulation with PPD, and (3) mixed lymphocyte culture with a pool of allogenic cells. Rosette formation tests showed a normal percentage of T-lymphocytes, whereas the percentage of B-lymphocytes was reduced slightly (10%). The methods used for the examinations have been described previously.[19,20]

COMMENT

In the present case there were signs of prolonged neonatal cholestasis and persistent affection of the liver, but, since liver biopsy was not attempted, it is not possible to decide whether this is a case of progressive juvenile cirrhosis. The clinical picture corresponds to the findings in other cases of α_1-AT deficiency and liver disease.[5,21-23] This defect is not an uncommon cause of neonatal cholestasis and progressive cirrhosis. Among 424 children with liver disease, 20 were found with α_1-AT deficiency of type PiZZ,[22] and a screening of 200,000 newborn infants[23] revealed 120 PiZZ phenotype infants, 22 of whom developed clinical signs of liver disease. The prognosis for this disease appears to be a variable one.[22-23]

Skin changes have not been described previously in connection with this disease, but pathophysiological considerations would suggest that the skin as an organ could also be affected. α_1-Antitrypsin deactivates numerous proteolytic enzymes, such as proteases released from granulocytes (collagenase, elastase), pancreatic trypsin, and collagenase in the skin and synovial membrane.[24] It has, therefore, been postulated that the cause of the development of pulmonary emphysema in adults could be an early reduction in pulmonary elasticity due to autodigestion after release of granulocyte proteases that are not inhibited in the normal manner.

Our patient had pronounced histological changes in the skin with severe infiltration of granulocytes and lymphocytes in and around the vessel walls. The inflammatory skin changes were not found to be localized particularly to the lower trunk and lower limbs, as is otherwise found in vasculitis. Release of granulocyte proteases appears to be a central process in the inflammatory reaction in vasculitis,[25] and this could explain the strong inflammatory reaction in a patient with reduced protease-inhibitor activity, but it is uncertain whether this defect can also initiate the development of vasculitis.

Moroz et al[26] have demonstrated subendothelial deposits of AT, complement, and immunoglobulins along the glomerular basement membrane in three children with AT deficiency of the PiZZ type who died of cirrhosis. These authors suggested that the abnormal Z protein serves as an antigen in the formation of immune complexes that may have caused the renal lesions observed in these children. In our patient, C3, AT, and immunoglobulins were found along the vascular beds of the skin, which, likewise, may be due to the formation of immune complexes by AT in the circulation of the child. This hypothesis could explain the unusual persistence of cutaneous vasculitis in this patient.

Since not all children with α_1-AT deficiency of the PiZZ type develop liver disease, there must be other genetic or environmental factors of importance. Lieberman et al,[27] for instance, postulated that the storage of AT within the hepatocytes made them particularly vulnerable to damage from infectious diseases. The reduced levels of galactose-1-phosphate uridyl transferase observed in our patient may be an additional load on the liver, resulting in damage to the hepatocytes, followed subsequently by release of the abnormal AT into the circulation.

We wish to thank the following colleagues for assistance in the investigations: H. E. Christensen, MD, Institute of Pathology, Odense University Hospital (Histology); G. Heydenreich, MD, Department of Dermatology, Odense University Hospital (Immunofluorescence Studies); S. A. Birkeland, MD, Tissue Culture Laboratory, Institute of Pathology, Odense University Hospital (Cellular Immunity); T. Sveger, MD, Department of Clinical Chemistry, Malmö General Hospital, Sweden (Pi-typing); R. Bütler, MD, Red Cross Laboratory, Bern, Schweiz (Gt-typing).

All conjugates were obtained from Behringwerke AG.

References

1. Fagerhol MK, Laurell CB: The Pi-system: Inherited variants of serum alpha$_1$-antitrypsin. *Prog Med Genet* 7:96-111, 1970.

2. Eriksson S: Studies in alpha-1-antitrypsin deficiency. *Acta Med Scand* 177(suppl 432):1-85, 1965.

3. Laurell CB, Sveger T: Mass screening of newborn Swedish infants for alpha$_1$-antitrypsin deficiency. *Am J Hum Genet* 27:213-217, 1975.

4. Østergaard PAA: Hereditary alpha$_1$-antitrypsin deficiency and liver cirrhosis in children. *Dan Med Bull* 20:96-101, 1973.

5. Asarian J, Archibald RWR, Lieberman J: Childhood cirrhosis associated with alpha-1-antitrypsin deficiency. *J Pediatr* 86:844-850, 1975.

6. Sharp HL, Bridges RA, Krivit W, et al: Cirrhosis associated with alpha-1-antitrypsin deficiency: A previously unrecognized inherited disorder. *J Lab Clin Med* 73:934-939, 1969.

7. Kueppers F, Dönhardt A: Obstructive lung disease in heterozygotes for alpha-1-antitrypsin deficiency. *Ann Intern Med* 80:209-212, 1974.

8. Sharp HL: Alpha-1-antitrypsin deficiency. *Hosp Pract* 6:89-96, 1971.

9. Aagenaes Ø, Matlary A, Elgjo K, et al: Neonatal cholestasis in alpha-1-antitrypsin deficient children. *Acta Paediatr Scand* 61:632-642, 1972.

10. Berg NO, Eriksson S: Liver disease in adults with alpha$_1$-antitrypsin deficiency. *N Engl J Med* 287:1264-1267, 1972.

11. Campra JL, Craig JR, Peters RL, et al: Cirrhosis associated with partial deficiency of alpha-1-antitrypsin in an adult. *Ann Intern Med* 78:233-238, 1973.

12. Cohen KL, Rubin PE, Echevarria RA, et al: Alpha-1-antitrypsin deficiency, emphysema, and cirrhosis in an adult. *Ann Intern Med* 78:227-232, 1973.

13. DeLellis RA, Balogh K, Merk FB, et al: Distinctive hepatic cell globules in adult alpha-1-antitrypsin deficiency. *Arch Pathol* 94:308-316, 1972.

14. Gordon HW, Dixon J, Rogers JC, et al: Alpha$_1$-antitrypsin accumulation in livers of emphysematous patients with A$_1$-AT deficiency. *Hum Pathol* 3:361-370, 1972.

15. Eriksson S, Larsson C: Purification and partial characterization of PAS-positive inclusion bodies from the liver in alpha$_1$-antitrypsin deficiency. *N Engl J Med* 292:176-180, 1975.

16. Weiser MM, Lamont JT, Walker WA: Alpha$_1$-antitrypsin deficiency: A defect of secretion. *N Engl J Med* 292:205-206, 1975.

17. Weitkamp LR, Sayre JW, Schwartz RH, et al: 'Duarte variant with clinical signs' has alpha$_1$-antitrypsin genotype ZZ. *J Med Genet* 13:46-48, 1976.

18. Heydenreich G, From E, Diederichsen H: Some unusual findings obtained by the immunofluorescence method in bullous pemphigoid and benign mucous membrane pemphigoid. *Acta Derm Venereol* 52:201-204, 1972.

19. Birkeland SA: The immunological capacity of peripheral lymphocytes in a blast-transformation system using frozen-stored cells. *Cryobiology* 13:433-441, 1976.

20. Birkeland SA: Rosette formation tests for T and B lymphocytes using frozen-stored cells. *Acta Pathol Microbiol Scand C* 83:298-302, 1975.

21. Ward AM, Underwood JCE: Alpha$_1$-antitrypsin deficiency and liver disease in childhood: Genetic, immunochemical, histological, and ultrastructural diagnosis. *J Clin Pathol* 27:467-472, 1974.

22. Odievre M, Martin IP, Hadchouel M, et al: Alpha$_1$-antitrypsin deficiency and liver disease in children: Phenotypes, manifestations, and prognosis. *Pediatrics* 57:226-231, 1976.

23. Sveger T: Liver disease in alpha$_1$-antitrypsin deficiency detected by screening of 200,000 infants. *N Engl J Med* 294:1316-1321, 1976.

24. Tokoro Y, Eisen AZ, Jeffrey JJ: Characterization of a collagenase from rat skin. *Biochim Biophys Acta* 258:289-302, 1972.

25. Sams WM, Thorne EG, Small P, et al: Leukocytoclastic vasculitis. *Arch Dermatol* 112:219-226, 1976.

26. Moroz SP, Cutz E, Balfe JW, et al: Membranoproliferative glomerulonephritis in childhood cirrhosis associated with alpha$_1$-antitrypsin deficiency. *Pediatrics* 57:232-238, 1976.

27. Lieberman J, Mittman C, Gordon HW: Alpha$_1$-antitrypsin in the livers of patients with emphysema. *Science* 175:63-65, 1972.

Columnar Epidermal Necrosis

A Special Form of Toxic Epidermal Reaction?

Hachiro Tagami, MD; Kozo Uragami, MD; Mizuho Yamada, MD; Tadahiro Aoshima, MD

• A bizzare erythematosquamous, partially verrucose, crusty or eroded eruption developed in a 6-year-old boy one week after his first measles vaccination. The eruption regressed completely after a two-year clinical course. Histologically, the epidermis showed unique columnar eosinophilic degeneration. There was a dense, mononuclear cell infiltration in the upper part of the dermis. To our knowledge these clinical and histologic features have not been reported in the literature, although they resemble, in some aspects, Kyrle's disease, Mucha-Haberman's disease, or lichen planus verrucosus.

Regarding the pathomechanisms underlying the development of this unique epidermal change, a postulate was made that it represented a special form of toxic epidermal reaction, probably resulting from autoaggressive lymphoid cell response to epidermal cells. Furthermore, relationship of measles vaccination to this special response is suggested.

(*Arch Dermatol* 114:925-928, 1978)

Focal degeneration or necrosis throughout the whole thickness of the epidermis is observed under a variety of clinical conditions. On the basis of their pathomechanisms, they can be classified into the following three large categories.

1. An accumulated horny mass at a localized area causes thinning and necrosis of the underlying epidermis. When the horny mass penetrates into the dermis, it causes a foreign body reaction. We find such changes in Kyrle's disease,[1] clavus, and hyperkératose en bouchons d'origine mécanique.[2] In the epithelium of the skin appendages, similar changes occur more frequently, eg, in acne, perforating folliculitis,[3] cystically dilated hair follicles, and epidermoid cysts.

2. Degenerative tissue components or metabolites in the dermis cause necrosis of the overlying epidermis and then are discarded through the channel of necrotic epidermis, ie, epidermal necrosis associated with transepidermal elimination.[4] It is found in such dermatoses as elastosis perforans serpiginosa, reactive perforating collagenosis, calcinonis cutis, osteoma perforans, perforating granuloma annulare, and necrobiosis lipoidica.

In these two situations, a foreign body granulomatous reaction accompanying a neutrophilic infiltration may occur in the dermis together with transepidermal elimination of resultant basophilically stained tissue debris.

3. In contrast to these two conditions, in the third category, focal epidermal necrosis develops directly, without any precedent accumulation of a horny mass or degenerative tissue components or metabolites. In a very mild case, there may be only a few dyskeratotic cells or necrotic cells in the epidermis. However, when the epidermal damage is severe, eg, in severe cases of contact dermatitis, erythema multiforme, fixed drug eruption, epidermal necrosis due to systemic administration of antimetabolites, lichen planus, and Darier's disease, total necrosis of the focal epidermis may occur. In this case the foreign body granulomatous reaction to dyskeratotic or eosinophilic-stained epidermal cells is not remarkable.

In this article we describe a child in whom an unusual scaly erythematous eruption developed that histologically showed numerous areas of characteristic columnar epidermal necrosis associated with a dense mononuclear cell infiltration in the dermis. The histologic feature suggests that this unique dermatosis developed through a pathomechanism similar to that of the third category.

REPORT OF A CASE

A 6-year-old boy was first seen in August 1973 because of an asymptomatic, scaly, erythematous eruption of four months' duration. In April 1973, one week after he received his first measles vaccination (a live attenuated virus vaccine), a mild fever and thrush-like stomatitis developed that were followed by the appearance of nonpruritic, erythematous patches on the limbs and buttocks. Under a diagnosis of hand-foot-mouth disease, he was treated by a local pediatrician who performed transfusion of 200 ml of his mother's blood because of severe anorexia. All of the symptoms appeared to resolve in June but recurred in a few weeks in a much more extensive fashion.

When first seen by us, he had numerous, discrete or confluent, scaly, partially crusty or eroded, erythematous plaques of various sizes on the limbs and trunk. They were particularly dense on the knees, elbows, buttocks, and dorsa of hands and feet, forming polycyclic verrucose lesions by coalescence (Fig 1 and 2). Much smaller, discrete, solid, scaly erythematous patches 0.5 to 2 cm in diameter were also present on the trunk and limbs, studded with fine, scattered, brownish, crusty dots (Fig 3). On removal of thick scales and crusts, the underlying skin had a raw surface. The palms and soles showed fine vesiculation and brownish dots (Fig 4). However, the visible mucous membranes, nails, and hairy portion of the scalp were not affected.

Laboratory evaluation demonstrated an initial WBC count of 3,650/cu mm with a

Accepted for publication Aug 17, 1977.

*From the Department of Dermatology, Hamamatsu University School of Medicine (Drs Tagami, Yamada, and Aoshima), and the Department of Dermatology, Kansai Medical College (Dr Uragami), Japan.

Reprint requests to Department of Dermatology, Hamamatsu University School of Medicine, Handacho, Hamamatsu, Shizuoka 431-31, Japan (Dr Tagami).

normal differential cell count, elevated ESR of 38 mm/hr, and C-reactive protein (2+). Later complete blood cell counts, urinalysis results, chest x-ray films, results of blood chemistry studies and serologic tests for syphylis, and serum immunoglobulin levels were all within normal limits throughout the following two years. He had been nonresponsive to intradermally administered PPD tests and remained so during the observation period.

Fig 1.—Scaly, partially crusted, polycyclic, erythematous eruption on legs.

Clinical Course

Each lesion started as an erythematous papule about 0.5 to 1 cm in diameter, progressed into a scaly-crusty plaque, and after several weeks gradually regressed leaving a hyperpigmented area. The following various therapeutic measures were carried out with little benefits: daily oral administration of 25,000 units of vitamin A, 250 mg of tetracycline hydrochloride, 250 mg of micronized griseofulvin, or 50 mg of dapsone for at least a period of two weeks. Only daily 1-mg oral doses of betamethasone appeared to reduce the intensity and amount of rash. Nevertheless, it was still not effective enough to suppress the lesions completely but rather caused the development of moon face, even in a few months.

In general, the skin condition seemed to worsen during summer and improve during winter. However, in the summer of 1975, two years after the onset and at the time of exacerbation, the child went sea bathing and became sunburned. Thereafter, the skin lesions began to subside rapidly and within two months the whole skin became free of the lesions. There has been no relapse in the subsequent two years.

All of the following tests on uninvolved skin from the midportion of his back failed to produce his lesions artificially: (1) five minimal erythema doses of ultraviolet light from a bank of five fluorescent sun lamps; (2) application of 5% thurfyl nicotinate; and (3) a six-hour occlusive patch test with 100% croton oil.

Histopathological Findings

Four biopsy specimens were obtained from lesions in various stages. They were prepared in the routine way, serially sectioned, and stained with hematoxylin-eosin, Weigert, and van Gieson stains.

The specimen from a solid erythematous patch of an early stage on the back showed a diffusely scattered mononuclear cell infiltrate in the upper dermis that focally invaded the lower portion of the acanthotic epidermis, causing liquefaction of the basal cells, spongiosis, and formation of round eosinophilic bodies and pigmentary incontinence (Fig 5).

A scaly erythematous lesion studded with fine brownish dots, representing a lesion of a more advanced stage on the extensor surface of the legs, demonstrated focal columnar eosinophilic degeneration of the whole thickness of the epidermis with pyknotic nuclei that appeared as a parakeratotic column, resembling cornoid lamella noted in porokeratosis (Fig 6). The base of the column and the lower portion of the surrounding epidermis were disintegrated with formation of a cleft containing eosinophilically stained degenerated epidermal cells and infiltrating mononuclear cells. Corresponding to the clinical severity of crusty verrucose changes, the area of the columnar necrotic portion became more

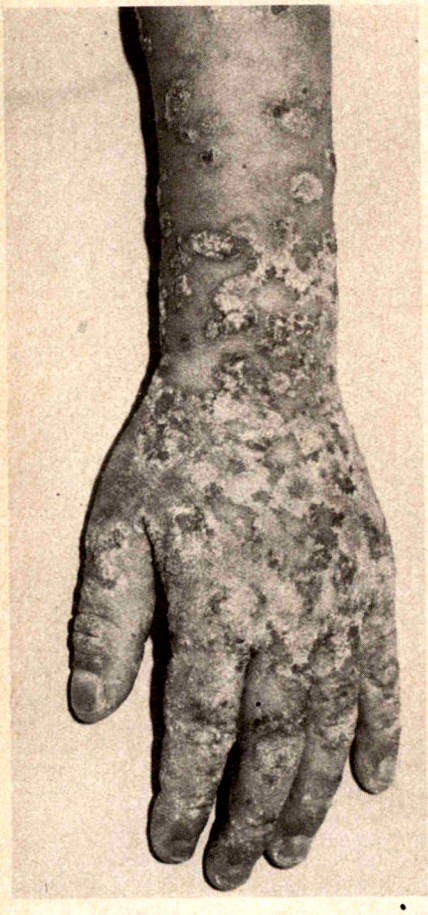

Fig 2.—Dorsum of left hand densely covered by coalesced erythematosquamous lesions.

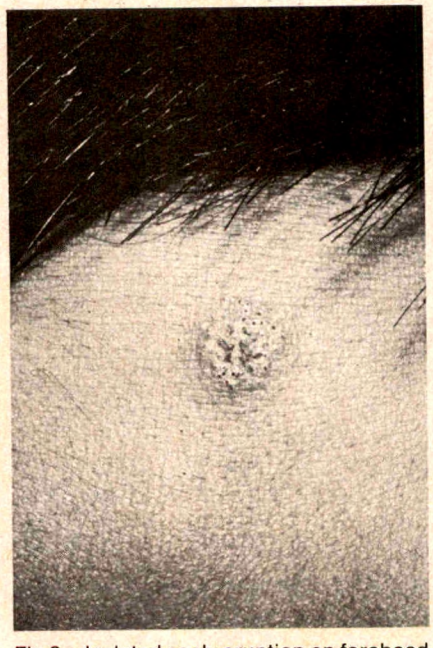

Fig 3.—Isolated scaly eruption on forehead studded with tiny, brownish, crusty spots.

Fig 4.—Vesicular eruption on palm studded with spots of brownish discoloration.

prominent (Fig 7 and 8). The neighboring epidermal cells were hypertrophic and palely stained. The dermoepidermal junction in such regions were hard to delineate because of prominent disorganization brought about by dense cellular invasion.

The involvement of the hair follicles was not clear in any of the biopsy specimens. The intraepidermal eccrine sweat duct was not involved in the columnar epidermal necrosis (Fig 7). The Weigert staining demonstrated no specific abnormalities in elastic fibers in the upper dermis.

COMMENT

This case presented unique clinical and histologic features. A search in the literature disclosed no reports of similar cases in the past. Clinically the lesions consisted of asymptomatic red infiltrated papules or patches that later became scaly, crusty, verrucous or eroded. The main histologic event noted in early, slightly elevated erythematous papules seemed to be a mononuclear cell infiltration in the upper dermis and invasion of the epidermis, which showed basal spongiosis and scattered individual cell necrosis. Later, the whole thickness of the affected area of the epidermis fell into eosinophilic degeneration resembling somewhat the cornoid lamella noted in porokeratosis Mibelli; while in the latter, the epidermal cells underlying the parakeratotic column are never completely degenerated, in the columnar epidermal necrosis of this case, localized parakeratosis involved even the basal cells. Macroscopically, these degenerative portions appeared to correspond to fine brownish, crusty dots scattered over an erythematous base. Further advanced lesions showed a much more extensive eosinophilic degeneration in the epidermis, which was noted clinically to be a firmly adherent brownish crust, removal of which resulted in a bleeding raw surface.

There was great difficulty in diagnosing the condition because of the unique clinical and histologic features.

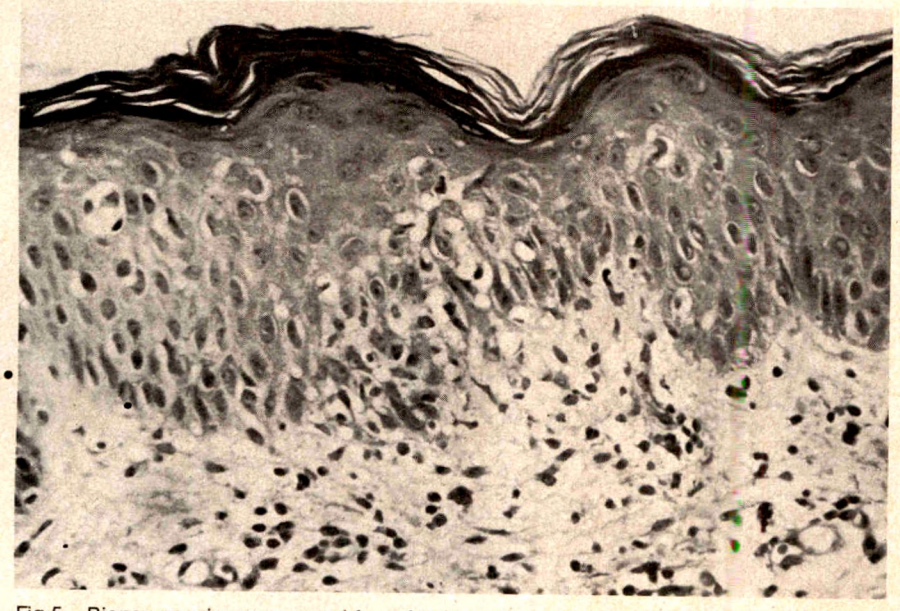

Fig 5.—Biopsy specimen removed from fresh, erythematous lesion on back shows focal spongiosis of lower epidermis with exocytosis (hematoxylin-eosin, original magnification ×400).

Fig 6.—Biopsy specimen obtained from scaly erythematous lesion studded with fine, brownish, crusty dots demonstrating thin parakeratotic column throughout whole thickness of epidermis, whose lower portion is disintegrated to form cleft containing eosinophilic-stained necrotic epidermal cells and infiltrating cells (hematoxylin-eosin, original magnification ×400).

Fig 7.—Sections from verrucose lesions on knee show thick dense parakeratotic column. Note sparing of intraepidermal portion of eccrine sweat duct (hematoxylin-eosin, original magnification ×200).

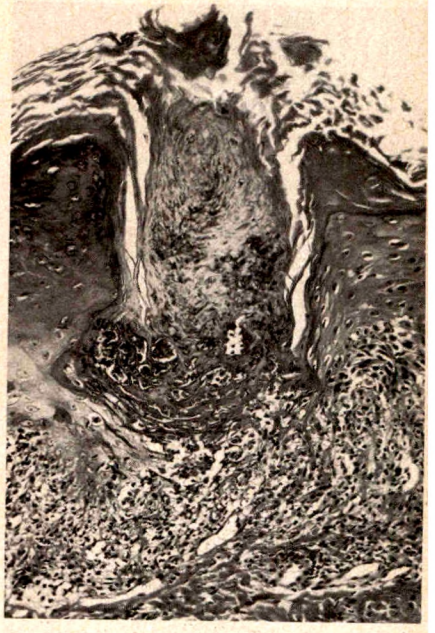

Fig 8.—Sections from same lesion as in Fig 7 shows more advanced stage of columnar epidermal necrosis with disorganization at base of column (hematoxylin-eosin, original magnification ×200).

The following three dermatoses were particularly problematic when making a differential diagnosis:

Kyrle's Disease (Hyperkeratosis Follicularis et Parafollicularis in Cutem Penetrans

The clinical aspects of our case, consisting of asymptomatic, chronic, hyperkeratotic plaques, resembled those reported by Kyrle.[1] Our case particularly bears resemblance to those reported by Tappeiner et al.[5] In the past, many cases, particularly those with perforating folliculitis, were described as an abortive type or a variant of Kyrle's disease because of the similarity of clinical or histologic findings. These descriptions caused great confusion in the clinical entity of Kyrle's disease until Carter and Constantine[6,7] and Tappeiner et al[5] introduced strict guidelines for its diagnosis. These criteria preclude a diagnosis of a variant of Kyrle's disease in the present case for the following reasons:

1. In Kyrle's disease the initial lesions are scattered discrete papules with cone-shaped central keratotic plugs somewhat resembling those of keratosis follicularis pilaris, while those of our case were slightly raised erythematous patches 5 to 10 mm in diameter. Furthermore, clinically and histologically, the involvement of hair follicles was not apparent in our case.

2. The lack of palmoplantar lesions is cited as a criterion for Kyrle's disease. Although there have been a few case reports of exceptional cases of Kyrle's disease associated with palmoplantar lesions,[5,8] all lesions were described as skin-colored papules with horny plugs reminiscent of punctate keratoderma. The vesiculated lesions in our case are definitely different from these changes.

3. Except for the cases reported by Tappeiner et al,[5] all the reported cases of Kyrle's disease were in adults.

4. Thus far, no reports of resolution have been made in Kyrle's disease, while a complete involution occurred in our case after two years.

5. As mentioned before, the histologic findings of our case are distinct from those of Kyrle's disease.

Pityriasis Lichenoides et Varioliformis Acuta (Mucha-Haberman's Disease)

The asymptomatic infiltrated papules or patches that later evolved into scaly, crusty, or eroded lesions and histologic changes consisting of a dense mononuclear cell infiltrate in the upper dermis and focal disintegration of the epidermis seem to suggest Mucha-Haberman's disease. Furthermore, our patient was a child, and spontaneous regression occurred after two years. On the other hand, massive hyperkeratotic crusted or erosive lesions of the fully developed stage, palmoplantar vesiculation, and rather sparse distribution of the lesions on the trunk are the features far different from those of typical Mucha-Haberman's disease. In addition, the lack of vascular involvement, which is observed in the latter, ie, endothelial proliferation, diapedesis of RBCs, invasion of the vessel walls by mononuclear cells, and eventual vascular occlusion[9] argues against such a diagnosis.

Lichen Planus Verrucosus

The clinical aspect of our case, chronic verrucose lesions chiefly noted on the extremities and histologic features of the initial lesion, are similar to those seen in lichen planus. However, rather rapid evolution of each lesion, lack of oral as well as nail lesions, and presence of the unique histological columnar epidermal necrosis are not the features found in lichen planus.[10]

In addition to the above mentioned dermatoses, such diseases as Darier's disease, erythema elevatum diutinum, multiple keratoacanthoma, and porokeratosis Mibelli were also considered but were ruled out on the basis of the clinical manifestations, course, and/or histologic features.

In regard to the pathogenesis of this unique columnar epidermal necrosis, the absence of a neutrophilic infiltration beneath the parakeratotic columns suggests that it developed through the pathomechanisms similar to those of the third category mentioned initially, focal epidermal necrosis. The fact that his family history showed no keratinization disorders and that this dermatosis affected him only during a certain period of time seem to militate against the possibility of hereditary or congenital keratinization disorders. Rather, it is logical to speculate that the densely infiltrating mononuclear cells might be related to the development of the necrotic columns of the epidermis, probably by releasing a cytotoxic factor(s).

The skin lesions developed one week after receiving his first measles vaccination. In the skin lesions of measles, there develops a focal necrotic change of the epidermis somewhat resembling that observed in our case.[11] Furthermore, toxic epidermal necrolysis, a much more extensive necrotic epidermal change, has been reported to occur during the course of measles.[12] Meanwhile, toxic epidermal necrolysis[13] or lichen planus-like eruption[14,15] have been reported in graft vs host reaction, most possibly developing based on the following pathomechanisms: the host's own epidermal cells appear foreign to its self-recognition apparatus and become a target of aggressor lymphocytes. Therefore, it is of interest to speculate that attenuated measles virus in some way induced an autoaggressive cytotoxic reaction of our patient's lymphoid cells against his own epidermal cells, although no clear-cut explanation can be presented for the unique localizing tendency of the epidermal damage. Moreover, no specific immunological studies were carried out in this case to verify such hypothesis.

Shigeo Ofuji, MD; Stefania Jablonska, MD; Martin C. Mihm Jr, MD; and John W. Petrozzi, MD, gave helpful criticism and advice.

References

1. Kyrle J: Kyperkeratosis follicularis et parafollicularis in cutem penetrans. *Arch Dermatol Syphilol* 123:466-493, 1916.
2. Tapernoux B, Delacrétaz J: Hyperkératose en bouchon d'origine mécanique. *Dermatologica* 143:201-208, 1971.
3. Mehregan AH, Coskey RJ: Perforating folliculitis. *Arch Dermatol* 97:394-399, 1967.
4. Mehregan AH: Transepidermal elimination, in Mali JWH (ed): *Current Problems in Dermatology*. Basel, Switzerland, S Karger, 1970, vol 3.
5. Tappeiner J, Wolff K, Schreiner E: Morbus Kyrle. *Hautarzt* 20:296-310, 1969.
6. Carter VH, Constantine VS: Kyrle's disease: I. Clinical findings in five cases and review of literature. *Arch Dermatol* 97:624-632, 1968.
7. Constantine VS, Carter VH: Kyrle's disease: II. Histopathologic findings in five cases and review of the literature. *Arch Dermatol* 97:633-639, 1967.
8. Helmke R: Über eine abortiven Fall um Hyperkeratosis follicularis et parafollicularis in cutem penetrans. *Dermatol Wsch* 120:74-77, 1949.
9. Szymanski FJ: Parapsoriasis and pityriasis lichenoides et varioliformis acuta, in Graham JH, Johnson WC, Helwig EB (eds): *Dermal Pathology*. Hagerstown, Md, Harper & Row Publishers, 1972.
10. Chapman RS: Lichen verrucosus and reticularis. *Dermatologica* 142:363-373, 1971.
11. Ackerman AB, Suringa DWR: Multinucleate epidermal cells in measles. *Arch Dermatol* 103:180-184, 1971.
12. Lyell A: A review of toxic epidermal necrolysis. *Br J Dermatol* 79:662-671, 1967.
13. Peck GL, Herzig GP, Elias PM: Toxic epidermal necrolysis in patients with graft versus host reaction. *Arch Dermatol* 105:561-569, 1972.
14. Touraine R, Revuz J, Dreyfus B, et al: Graft versus host reaction and lichen planus. *Br J Dermatol* 92:589, 1975.
15. Saurat JH, Didier-Jean L, Gluckman B, et al: Graft versus host reaction and lichen planus-like eruption in man. *Br J Dermatol* 92:591-592, 1975.

Cutaneous Manifestations of Noonan's Syndrome

Lt Comdr H. W. Wyre, Jr, MC, USNR

• Noonan's syndrome is a multisystem syndrome that has received little attention in the dermatologic literature, although there are numerous cutaneous manifestations that have been described. A typical case of Noonan's syndrome is presented. Clinical findings in this patient included short stature, curly scalp hair, prominent ears, hypertelorism, webbing of the neck, cubitus valgus, pigmented nevi, stasis dermatitis, and plantar hyperkeratosis. The latter two findings have not been previously reported in Noonan's syndrome. We urge that dermatologists become more aware of this syndrome to document the spectrum of changes that may occur in Noonan's syndrome.

(*Arch Dermatol* 114:929-930, 1978)

Numerous different defects have been described in patients with Noonan's syndrome. However, the cutaneous manifestations have received little attention.[1-5] A patient with this syndrome is described and the skin manifestations are reviewed.

REPORT OF A CASE

A 37-year-old man was first seen in the Dermatology Clinic at the National Naval Medical Center, Bethesda, Md, in 1976. Chief complaints were chronic dermatitis of the lower extremities since the age of 18 years and thickened skin on the soles of his feet since the age of 13 years. Pruritic areas of brown discoloration on the legs had been noted by the patient for several years. The foot lesions had been asymptomatic. Since early adulthood, there had been bilateral swelling of the lower extremities. There was no history of thrombophlebitis.

Surgical history included repair of pyloric stenosis at the age of 6 weeks, right orchiectomy for an undescended testicle at the age of 12 years, pinning of the right femur secondary to fracture at the age of 19 years, and repair of atrophic maxillae and left inguinal herniorrhaphy at the age of 32 years. The result of a karyotype study that was done in 1971 was normal (46 XY). He had always been short in stature. According to the history obtained from the patient, his mother who is now 76 years old has short stature, small hands, a chronic dermatitis of the legs, swelling of the legs, varicose veins, and mild thickening of the skin on the soles. His grandmother, now deceased, had short stature, small hands, swelling of the legs but no chronic dermatitis or abnormalities of the feet. There were no reported similar abnormalities in the patient's sister, maternal aunt and uncle, maternal great aunts, father, and paternal relatives.

Results of physical examination showed the following characteristics (Fig 1): short stature (height, 162.56 cm), curly scalp hair, prominent ears, hypertelorism, webbing of the neck, cubitus valgus, normal left testicle with absence of the right testicle, bilateral inguinal scars, small hands and feet, extensive brown discoloration of the lower extremities with erythema and scaling, superficial small varicosities at the ankles (Fig 2), moderate pretibial and ankle-pitting edema, and extensive plantar hyperkeratosis which was most prominent over the metatarsal heads (Fig 3). A few pigmented nevi and small hemangiomas were present on the trunk. The nail plates were normal.

Roentgenograms of the hands and feet revealed small but well-formed bones. Chest roentgenogram was normal.

COMMENT

Patients with Noonan's syndrome may be male or female, but because of the phenotypic similarity between Turner's and Noonan's syndromes, they have been confused in the female patient.[6] The discovery by Ford et al[7] of the X-chromosomal abnormality in patients with Turner's syndrome has helped to differentiate these syndromes, since patients with Noonan's syndrome have normal chromosome numbers. Various modes of inheritance have been proposed, but direct transmission suggests an autosomal dominant mode of inheritance.[6,8]

Numerous different defects, most of them minor, have been described in this syndrome.[6,9-11] Nora et al[6] presented the following major clinical findings in 81 patients:

Clinical Features	Percent
Characteristic facies	100
Short stature	83
Abnormal ears	78
Undescended testis	72 (of male)
Eye problems	58
Low posterior neck hairline	57
Cardiovascular anomalies	55
Cubitus valgus	54
Webbed neck	48

Cardiovascular anomalies may shorten the life expectancy of these patients, and the most common lesion noted is pulmonary stenosis.

The cutaneous manifestations of

Fig 1.—Full frontal view. Note presence of hypertelorism, prominent, low-set ears, and cubitus valgus.

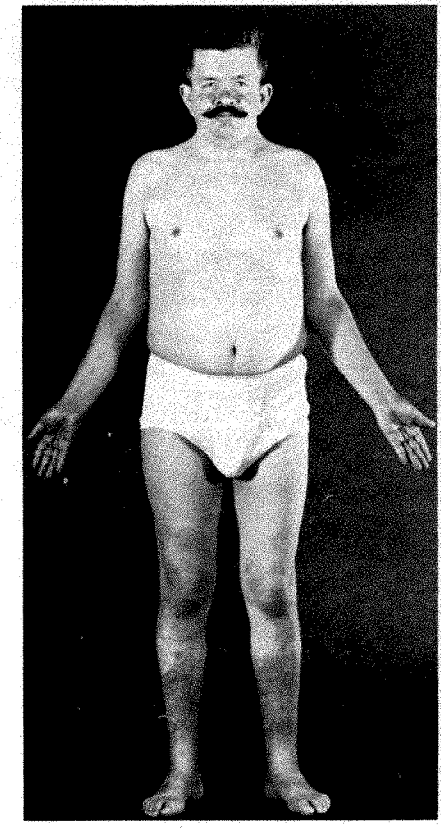

Accepted for publication Sept 14, 1977.

From the Department of Dermatology, National Naval Medical Center, Bethesda, Md.

The opinions expressed in this article are those of the author and are not necessarily those of the Department of the Navy or the Department of Defense.

Reprints not available.

Fig 2.—Lower legs. Note prominent stasis dermatitis and small varicosities over ankle.

Fig 3.—Plantar aspect of feet. Note hyperkeratosis, which is greater over metatarsal heads.

Cutaneous Manifestations in Noonan's Syndrome
Lymphedema
Transient lymphedema of dorsum of hands and feet in infancy
Stationary or progressive lymphedema into adulthood
Hair
Low posterior neck hairline
Curly hair
Pubic and axillary hair often scanty in the male
Female escutcheon in the male
Beard growth poor in the male
Hirsutism
Nails
Dystrophic nails which are short and wide
Nevi
Pigmented nevi are frequent
Dermatoglyphics
Distal axial triradius
Tissue Reaction
Keloid formation
Skin Texture
Soft skin
Elastic skin

Noonan's syndrome are presented in the Table. Lymphedema was found in many patients.[5,6,12-14] This lymphedema may be transiently present in the infant,[6] or it may persist into adulthood.[5] Abnormalities of hair include low posterior neck hairline,[6,9,12] coarse curly hair,[11,13,15] scanty pubic and axillary hair, female escutcheon and poor beard growth in the male,[14] and hirsutism of the cheeks of women and extensor surface of the forearms in both sexes.[13] Short and wide dystrophic nails may be found.[6,12,13] Pigmented nevi are frequent.[6] While some dermatoglyphic studies have shown a distal axial triradius,[6] Collins and Turner[9] did not find a characteristic dermatoglyphic pattern. A tendency toward keloid formation has been noted.[6,14] This must be taken into consideration before recommending surgical correction of webbed neck or ptosis.[6] The skin may be soft and hyperelastic.[8,16] Skin biospy specimens have demonstrated no specific abnormalities[8]; however, in one patient, pulmonary and femoral arteries showed degeneration of the media with relative excess of acid mucopolysaccharides. The elastic fibers in these vessels were fragmented, reduced in numbers, and lacked orderly arrangement. Because of the skin characteristics and the observed vascular alterations, a basic defect in connective tissue has been proposed. Single cases of dry ichthyotic skin,[9] nevus flammeus on the forehead,[11] cavernous hemangioma on the forehead,[11] freckles on the shoulder,[13] alopecia,[14] cutis laxa,[14] and diffuse hyperpigmentation[17] have been reported. No reported cases have had stasis dermatitis or plantar hyperkeratosis.

Syndromes to be considered in the differential diagnosis of Noonan's syndrome include the following[6]: Turner's, Aarskog's, Klippel-Feil's, Forney's syndromes, familial telecanthus, pulmonary valvular dysplasia (cardiofacial syndrome), and the leopard syndrome. Nora et al[6] suggested that Noonan's, Aarskog's,[18] leopard[19] syndromes, and pulmonary valvular dysplasia (cardiofacial syndrome)[20] are a single syndrome. Each of these has many common features, but, in the literature, emphasis has been placed on distinctive features of each syndrome. While emphasis is placed on a distinct scrotal configuration (the scrotum overrides the base of the penis) in Aarskog's syndrome, these patients also have shortness of stature, hypertelorism, abnormal ears, and cryptorchidism. In the leopard syndrome, emphasis is placed on the multiple lentigenes, but these patients also have ocular hypertelorism, pulmonary stenosis, abnormalities of the genitalia, retardation of growth, and deafness. The features seen in pulmonary valvular dysplasia (cardiofacial syndrome) are pulmonary valvular stenosis, small stature, unusual facies, and mental retardation. All of the features, except the scrotal configuration seen in Aarskog's syndrome, may be seen in Noonan's syndrome.

The diagnosis of Noonan's syndrome should be considered during the examination of patients who have the skin conditions that are listed in the Table. With more detailed cutaneous examination of patients with this syndrome, knowledge of the specific skin manifestations can be further expanded.

References

1. Carter DM, O'Keefe EJ: Hereditary cutaneous disorders, in Moschella SL, Pillsbury DM, Hurley HJ (eds): *Dermatology*. Philadelphia, WB Saunders Co, 1975, vol 2, pp 1044-1045.
2. Goltz RW: Bonnevie-Ullrich-Turner syndrome, in Fitzpatrick TB, Arndt KA, Clark WH, et al (eds): *Dermatology in General Medicine*. New York, McGraw-Hill Book Co, 1971, pp 1466-1471.
3. Rook A: Genetics in dermatology, in Rook A, Wilkinson DS, Ebling FJG (eds): *Textbook of Dermatology*, ed 2. Oxford, England, Blackwell Scientific Publications, 1972, vol 1, pp 97-98.
4. Freedberg IM: Turner's syndrome, in Demis DJ, Dobson RL, McGuire J (eds): *Clinical Dermatology*. Maryland, Harper & Row Publishers Inc, vol 2, pp 1-2.
5. Minkin W, Frank SB, Wolman SR, et al: Lymphedema in Noonan's syndrome. *Int J Dermatol* 13:179-183, 1974.
6. Nora JJ, Nora AH, Sinha AK, et al: The Ullrich-Noonan syndrome (Turner phenotype). *Am J Dis Child* 127:48-55, 1974.
7. Ford CE, Jones KW, Polani PE, et al: A sex-chromosome anomaly in a case of gonadal dysgenesis (Turner's syndrome). *Lancet* 1:711-713, 1959.
8. Bolton MR, Pugh DM, Mattioli LF, et al: The Noonan syndrome: A family study. *Ann Intern Med* 80:626-629, 1974.
9. Collins E, Turner G: The Noonan syndrome—a review of the clinical and genetic features of 27 cases. *J Pediatr* 83:941-950, 1973.
10. Noonan JA, Ehmke DA: Associated noncardiac malformations in children with congenital heart disease, abstracted. *J Pediatr* 63:468-470, 1963.
11. Noonan, JA: Hypertelorism with Turner phenotype: A new syndrome with associated congenital heart disease. *Am J Dis Child* 116:373-380, 1968.
12. Nora JJ, Sinha AK: Direct familial transmission of the Turner phenotype. *Am J Dis Child* 116:343-350, 1968.
13. Kaplan MS, Optiz JM, Gosset FR: Noonan's syndrome: A case with elevated serum alkaline phosphatase levels and malignant Schwannoma of the left forearm. *Am J Dis Child* 116:359-366, 1968.
14. Heller RH: The Turner phenotype in the male. *J Pediatr* 66:48-63, 1965.
15. Karpouzas J, Papaioannou AC: Noonan syndrome in twins. *J Pediatr* 85:84-86, 1974.
16. Towne WD, Fabian JS, Rosen KM, et al: Systolic prolapse of mitral valve in Noonan's syndrome. *Am Heart J* 90:499-502, 1975.
17. Bamrah VS, Hughes CV, Ajlouni K, et al: Aortic regurgitation and pigmentation—unusual features of Noonan syndrome. *Am J Med Sci* 271:211-214, 1976.
18. Furukawa CT, Hall BD, Smith DW: The Aarskog syndrome. *J Pediatr* 81:1117-1122, 1972.
19. Gorlin RJ, Anderson RC, Blaw M: Multiple lenginenes syndrome. *Am J Dis Child* 118:652-662, 1969.
20. Linde LM, Turner SW, Sparkes RS: Pulmonary valvular dysplasia: A cardiofacial syndrome. *Br Heart J* 35:301-304, 1973.

Hereditary Congenital Hypopigmented and Hyperpigmented Macules

Wiete Westerhof, MD; Frits A. Beemer, MD; Rudi H. Cormane, MD;
Jan W. Delleman, MD; William R. Faber, MD; Joop G. Y. de Jong, MD; Wouter W. van der Schaar, PhD

• Congenital hypomelanotic and hypermelanotic macules traced in three generations of a family suggested autosomal dominant inheritance. Some affected members also showed retarded growth and mental deficiency.

Light microscopic findings of "split-dopa" preparations of lesional and normal skin were comparable, except that background staining of keratinocytes in dark macules was higher than in control skin. In light macules it was lower.

Ultrastructurally, hypomelanotic skin showed small melanosomes (0.3 μ) that occurred in keratinocytes in melanosome complexes. Hypermelanotic skin revealed large melanosomes (0.6 μ) that were singly distributed in keratinocytes. Melanosome size in normal skin averaged 0.4 μ; distribution pattern was mixed. Melanin granules inside keratinocytes were fully melanized. Hyperpigmented, normal and hypopigmented skin of one person had histological features of black oriental and white skin. This clinical picture could well represent a new neurocutaneous syndrome different from tuberous sclerosis.

(*Arch Dermatol* 114:931-936, 1978)

*Accepted for publication Aug 17, 1977.

From the Departments of Dermatology (Drs Westerhof, Cormane, Faber, and van der Schaar) and Pediatrics (Dr Beemer), University of Amsterdam, and the Department of Ophthalmogenetics, Netherlands Ophthalmic Research Institute, Amsterdam (Drs Delleman and de Jong).

Reprint requests to Department of Dermatology, Binnengasthuis, Amsterdam (Dr Westerhof).

When light and dark macules occur since birth in members of a family, one should be suspicious of tuberous sclerosis.[1,2] Light macules,[3] especially leaf-shaped,[4] represent a major symptom in tuberous sclerosis, often heralding other symptoms such as shagreen skin, subungual fibromas, sebaceous adenoma, and other skin tumors, as well as seizures, muscular spasms, and mental retardation. The difficulty in such early cases is to confirm the diagnosis.

It appears that examination of the skin (light macules) at the ultrastructural level shows characteristic features. There is a decrease in melanization and size of melanosomes. In the keratinocytes these small sized, immature melanosomes occur in so-called melanosome complexes.

No electron microscopic data of dark macules prevalent in patients with tuberous sclerosis have been reported so far.

We were in the position to examine several members of a family who have had dark and light patches on the skin since birth. Other than this, they exhibit no skin lesions.

In order to study this phenomenon, we used dihydroxyphenylalanine (DOPA)-stained epidermal split sections to determine the number of melanocytes and their characteristics and electron microscopy for the evaluation of the size and distribution of melanosomes in the keratinocytes.

REPORT OF CASES

The family is of Hindustani origin with the following pedigree:

Not all members of the third generation could be traced; only patients III-2 and III-4 (Fig 1) have been examined physically. They are all married and have children. Members of the fourth generation have all been examined physically. Patients IV-3 and IV-6 were admitted to the hospital for dermatologic, internal, ophthalmologic, neurologic, and psychological assessment.

The clinical and electron microscopic findings of the patients under study were compared with features of tuberous sclerosis, Recklinghausen's disease (neurofibromatosis), Albright's disease, nevus pigmentosus, and piebaldness[5] (Table 1).

Case 1.—A 39-year-old woman (Fig 1, III-4) is married and has eight children; three are described below. She is 162 cm tall and has a relatively light complexion, showing a light macule on the right side of her chest and a faint dark macule on her left shoulder.

Case 2.—A 21-year-old boy (Fig 1, IV-3) has a dark complexion. There are six dark and 12 light macules on his arms, legs, and trunk (Fig 2). These are well defined, asymmetrical, and not confined to any dermatome. No pigmentary changes were noted on the mucous membranes. He is 160 cm tall.

Results of liver and kidney function studies were normal. Amino acid chromatography of the urine showed normal findings. Skeletal x-ray films demonstrated no abnormalities.

Ophthalmologic examination showed some lens opacities but otherwise normal eyes.

Neurological examination showed nor-

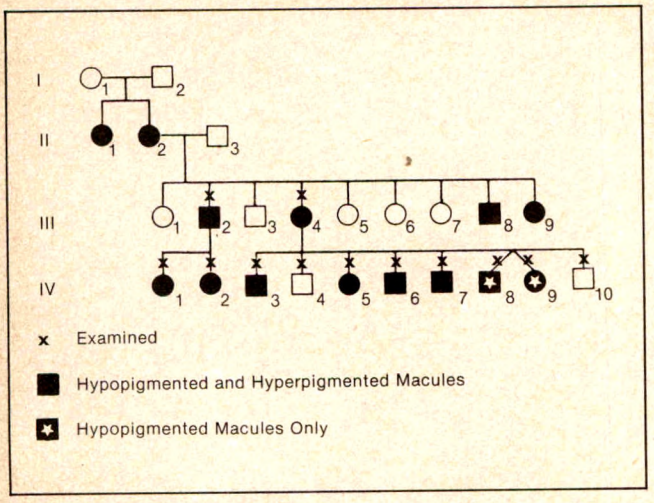

Fig 1.—Pedigree of Hindustani family.

Table 1

Characteristic	Tuberous Sclerosis
Skin	Café au lait & hypopigmented patches; sebaceous adenomas; shagreen skin, periungual fibromas
DOPA activity	Decreased
Electron microscopy	Small melanosomes with low electron density in keratinocytes
Skeleton	Thickened calvaria
CNS	Glial proliferations in brain, epilepsy, mental retardation, muscular spasm
Hormonal status	
Internal organs	Renal tumors, rhabdomyoma of heart, interstitial fibrosis of lungs
Eye	Retinal hamartomas, optic disc hamartomas, cataract
Inheritance	Autosomal dominant

Fig 2.—Left, Hypopigmented and hyperpigmented macule on right thigh of patient IV-3 (case 2). Right, Same patient. Light and dark lesions lie in apposition.

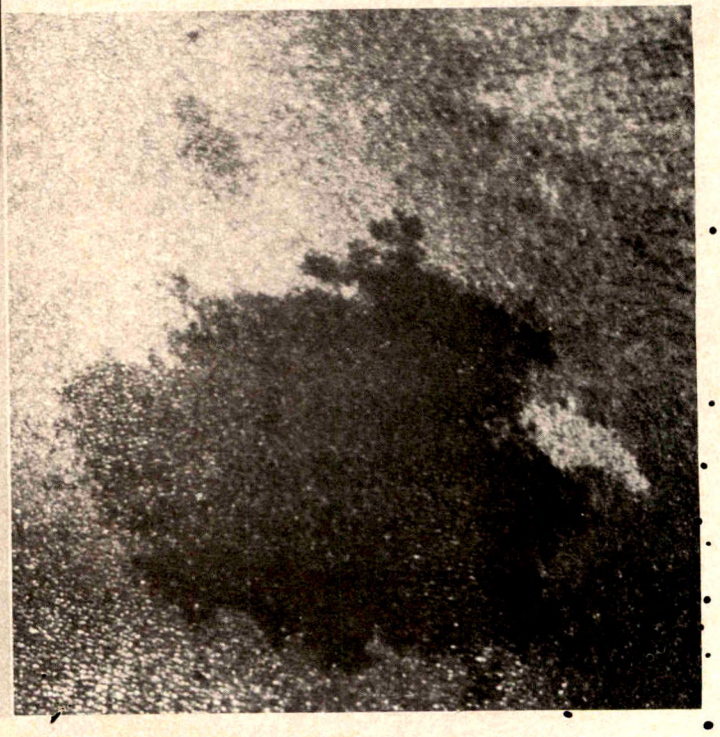

—Comparison of Characteristics of Five Similar Diseases and Patients Studied

Recklinghausen's Disease	Albright's Disease	Nevus Pigmentosus[5]	Piebaldiness[5]	Patients Under Study (eg IV-6)
Café au lait spots, cutaneous neurofibromas, axillary freckling.	Café au lait spots	Hypopigmented macules	Hyperpigmented spots within hypomelanotic lesions not containing functional melanocytes	Hypopigmented & hyperpigmented macules
Normal	Normal	Decreased or normal	Increased	Normal
Giant melanosomes (+++) in melanocytes & keratinocytes	Giant melanosomes (+) in melanocytes & keratinocytes	Melanosome aggregation in melanocytes	Abnormal (spherical & granular) and normal (ellipssoidal & lamellar) melanosomes in hypermelanotic areas	Big melanosomes, single distribution; small melanosomes, complex distribution
Spina bifida, kyphosis, scoliosis, subperiostal hyperostosis	Polyostotic cysts (fibrous dysplasia)	...	...	Cervical rib, small skull, small sella turcica
Neurilemoma of nerve stem, epilepsy, oligophrenia, oligophrenia epilepsia	...	...	...	Mental retardation
Associated with Addison's hyperparathyroidism, pheochromocytoma	Precocious puberty	...	...	...
Gastrointestinal tumors	...	...	...	...
Optic nerve glioma, hyperpigmented spots in iris and choroid, exophthalmos, glaucoma	Unilateral exophthalmos, papilledema, optic nerve atrophy, visual field defect	...	...	...
Autosomal dominant	Autosomal dominant	...	...	Autosomal dominant

Table 2.—Average Number of Melanocytes per Square Millimeter ± SD Mean Compared With Normal Values*

Case/Biopsy Site	Hyperpigmented Skin	Control Skin	Hypopigmented Skin	Control Skin	Staricco and Pinkus	Szabo
2/abdomen	1,157 ± 17	1,178 ± 16	1,252 ± 32	1,199 ± 33	754	890 ± 70
3/thigh	829 ± 9	966 ± 11	828 ± 7	976 ± 14	1,031	1,000 ± 70
4/thigh	1,103 ± 13	1,114 ± 8	1,029 ± 21	1,029 ± 23	1,031	1,000 ± 70
5/abdomen/buttock	1,230 ± 25	1,093 ± 24	1,252 ± 13	1,103 ± 20	754	890 ± 70

* Determined by Staricco and Pinkus in 1957[6] and Szabo in 1959[8].

Fig 3.—DOPA-stained epidermal sheets (basal layer up). Melanosomes are bipolar and stellate. DOPA activity of melanocytes in lesional and control skin is normal. Left, background staining (melanin content) in hypermelanotic macule is very heavy, whereas it is very slight in hypomelanotic macule (right) as compared with normal control skin (center) (original magnification ×320).

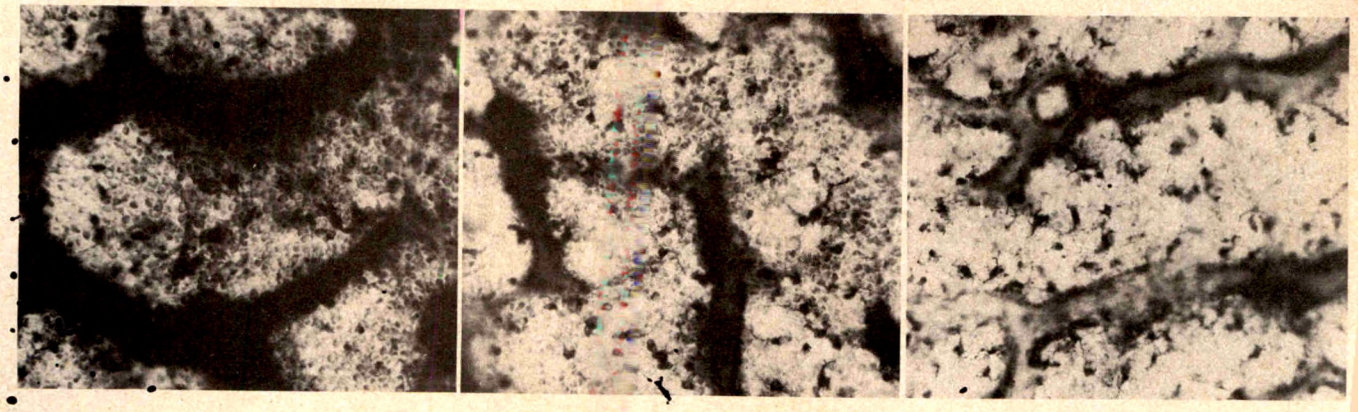

mal results, except for the presence of Wartenberg's symptom in the left arm.

The subject's IQ was 74 on the Wechsler Adult Intelligence Test. In comparison, his younger brother (Fig 1, IV-4) has no stigmas, is 175 cm tall (within the normal range), and has an average IQ (98).

Case 3.—A 17-year-old girl (Fig 1, IV-5) has a dark complexion. On her right thigh she has a light macule and on her left thigh a very small but distinct dark macule. She is 159 cm tall.

Results of liver and kidney function studies were normal as were amino acid chromatography of the urine, excretion pattern, and sexual development.

Case 4.—A 16-year-old boy (Fig 1, IV-6) showed retarded growth (height 154 cm) and a dark complexion. He was born prematurely and weighed 1,275 g at birth.

Multiple skin lesions were present on his body. There were more than ten light macules, some of which were large (15 cm in diameter), pronouncedly hypopigmented, and well demarcated, while others were small and hardly noticeable.

The number of hyperpigmented macules also exceeded ten and ranged in size from 1 to 10 cm in diameter. They were spread all over the body and one lesion was present on the chin. No pigmentary changes or tumors were seen on mucous membranes.

Results of liver and kidney function studies were normal (taking into account the serum values of a growing child). The lactic dehydrogenase level was 388 units/liter; fraction III, 23.8% (normal, 7% to 15%); and fraction IV, 9.9% (normal, 0.5% to 4%). Amino acid chromatography of the urine indicated an increase in 1-methylhistidine (? diet). Results of a feces benzidine test were negative, and an ECG was normal.

X-ray films showed the following: skull, a small sella turcica and a veiled right sinus maxillaris; skeleton, one cervical rib on the right, but no abnormal calcification of cysts; thorax, normal.

Pathologic examination of a wart on his scalp showed a hyperkeratotic papilloma. On the nose a few skin colored papules could be seen, but they were not diagnostically distinctive histologically. The bridge of the nose was broad.

The patient complained of seeing things unclearly. Visual acuity OU was 4/5 without correction. There were hypesthesia of the corneas and subcapsular opacities of the lenses, but fundi were normal. The visual field showed fluctuating findings, but electroretinography and visually evoked responses demonstrated no abnormalities.

The circumference of the skull was 46.5 cm. Neurologically, there were no abnormalities and an EEG was normal.

The boy's IQ was ±65 and his performance is suggestive of organic brain disease resulting in a certain degree of sensory aphasia.

MATERIALS AND METHODS

Using Thiersch's method, four biopsy specimens each, 2 sq cm large, were taken from patients IV-3, IV-5, IV-6, and IV-7. One specimen was taken from the center of a hyperpigmented macule, one from the center of a hypopigmented macule, and one from normal skin taken 5 cm from the hyperpigmented or hypopigmented macule to serve as a control. Each specimen was divided in two pieces. One was used for the "split DOPA" technique and the other was prepared for electron microscopy.

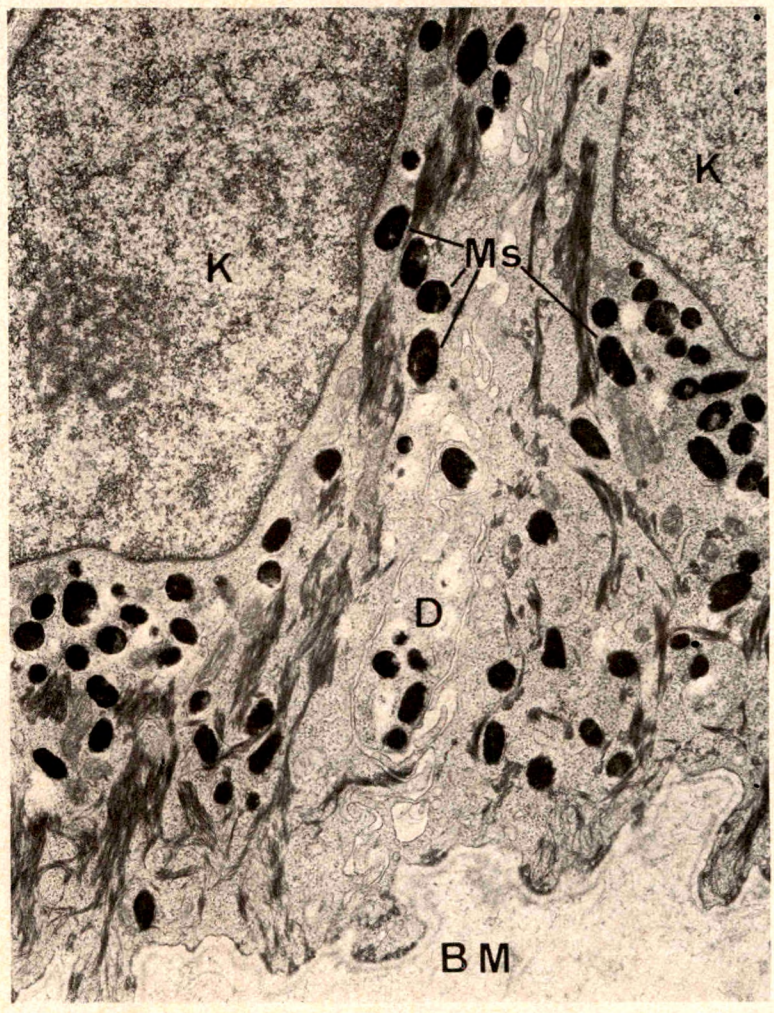

Fig 4.—Hypermelanotic macule. Big melanosomes (average transverse diameter 0.6 μm) are singly distributed in keratinocytes (K). D indicates dendrite of melanocyte; BM, basement membrane; Ms, nonaggregated melanosome (original magnification ×24,000).

Split Dihydroxyphenylalanine Technique

The skin splitting and DOPA staining technique were performed as originally described by Staricco and Pinkus.[6] The specimens were washed in normal saline and immersed in 2N sodium bromide solution at room temperature for four to five hours. Thereafter, the epidermis could be removed easily and washed in isotonic saline for one minute.

The epidermal sheets were then incubated in 0.1% levodopa (L-DOPA) (3.4 dihydroxyphenylalanine dissolved in 0.1M sodium phosphate buffer, pH 7.4) for one hour at 37 °C, after which the solution was changed; then the sheets were incuba for seven hours. The specimens were fi in a 10% solution of formaldehyde for hours, subsequently dehydrated in alc and xylol, and mounted in resin betw slide and coverglass with the basal la up.

Melanocyte counts were made with standard light microscope at a magnif tion of 400 diameters. In each specimen square fields with a side length of 37 were examined. The number of mela cytes per square millimeter was calcula by conversion.

From each specimen photographs (m nification ×315) were taken for a comp ative study of the melanocyte size morphology (nucleus, perinuclear cy plasm, and dendrites) as well as pigment uptake by keratinocytes.

Electron Microscopy

The specimens for electron microsc were immediately fixed in a 1:1 dilutio Karnovsky's paraformaldehyde-gluta dehyde fixative for five hours at r temperature and were rinsed in 0.1M c

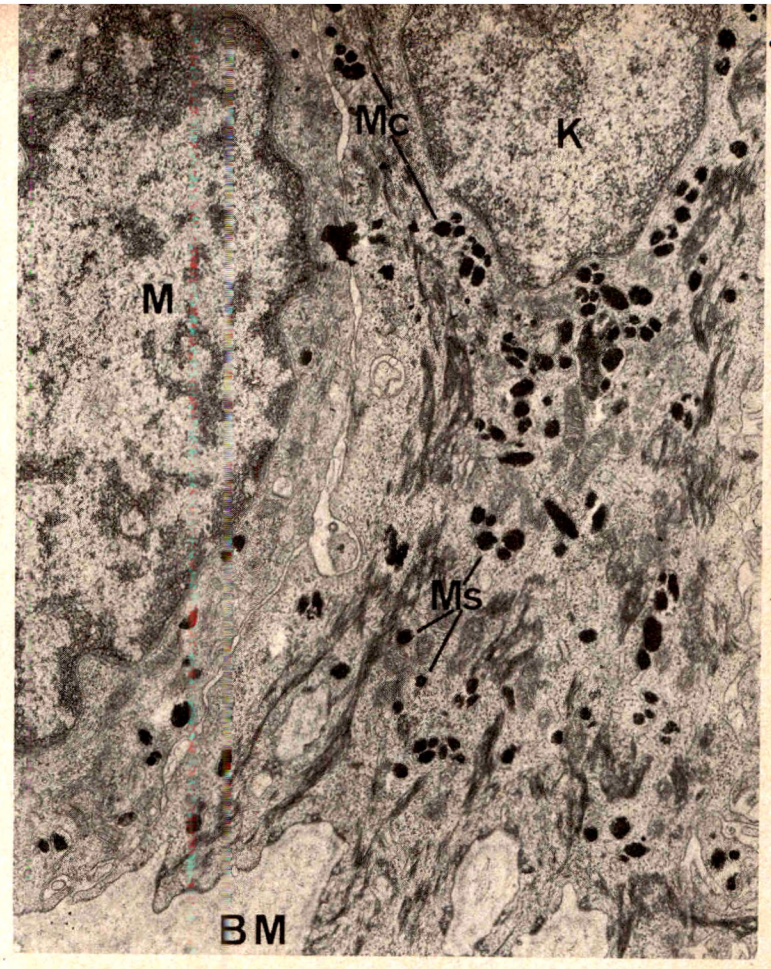

Fig 5.—Hypomelanotic macule (same patient as Fig 4). Small melanosomes (average transverse diameter 0.3 μm) occur in keratinocytes (K) mostly in aggregated form (melanosome complexes). M indicates melanocyte; BM, basement membrane; Mc, melanosome complex; Ms, nonaggregated melanosome (original magnification ×24,000).

dylate buffer pH 7.4 and stored in the same buffer at 4 °C.

Postfixation was carried out with 3% osmic acid in distilled water for 1.5 hours at 4 °C, followed by staining en block with 0.5% uranyl acetate in 0.1M barbital (Veronal) acetate buffer, pH 7.2, for two hours at room temperature. All specimens were rapidly dehydrated in a graded series of alcohols and were embedded in Epon 812. Ultrathin sections were cut with diamond knives on ultramicrotomes, picked up on uncoated copper grids, stained with lead citrate, and examined with an electron microscope.

In determining the melanosome size of each specimen, two electron micrographs (×24,000) were taken randomly on which the transverse diameters of the five largest melanosomes were measured, not taking the enveloping double membrane into account (simplification of a method described by Konrad and Wolff[7]).

RESULTS

Melanocyte Counts

There was no substantial difference between the number of DOPA positive cells found in hypopigmented and hyperpigmented macules and that found in the normal skin.

See Table 2 in which are given the average number of melanocytes per square millimeter in comparable areas, as determined by Szabo[8] and Staricco and Pinkus.[6]

In the dark and light patches, as well as in normal skin, the melanocytes were of comparable size and were mixed bipolar and stellate in appearance (Fig 3) with well-developed branching dendrities. No giant melanosomes were encountered.

The DOPA reaction was equally intense in normal and pathologically affected skin (Fig 3). In hyperpigmented macules the background staining (of keratinocytes) was very pronounced. In normal control skin it was moderate, whereas in hypopig-

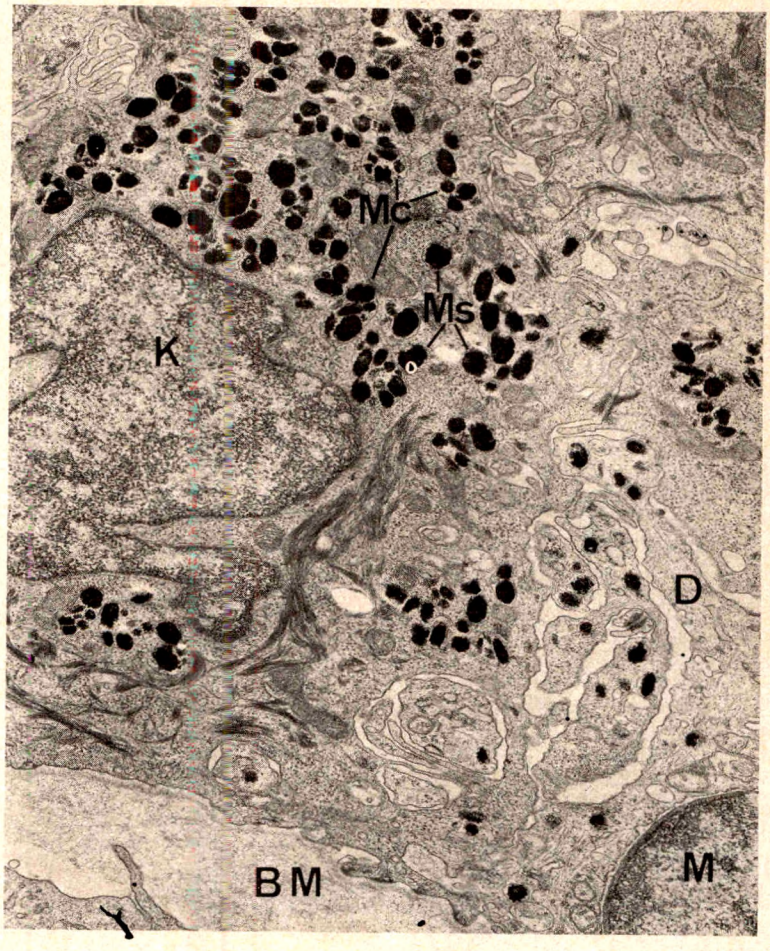

Fig 6.—Normal skin (same patient as Fig 4). Melanosomes (average transverse diameter 0.4 μm) are distributed in keratinocytes (K) as single units and as complexes. D indicates dendrite of melanocyte; M, melanocyte; BM, basement membrane; Mc, melanosome complex; Ms, nonaggregated melanosome (original magnification ×24,000).

mented macules it was negligible (Fig 4).

Electron Microscopy

No degenerative changes were seen in the normal control skin or in the hyperpigmented and hypopigmented macules. There were neither signs of inflammation in the epidermis nor in the dermis. A few melanophages were present in all specimens.

The melanocytes bulged towards the dermis and contained premelanosomes and melanosomes of stage 1 to 4. No melanosome aggregation was observed inside the melanocytes. The melanosomes were ellipsoidal and lamellar.

The dispersion of melanosomes in the cytoplasm of the melanocytes (perinuclear and dendrites) was equal. The transfer of melanosomes from the melanocytes to the keratinocytes in abnormal and normal skin was not disturbed judging by the number of melanosomes inside the keratinocytes.

Melanosomes occurring in melanocytes and keratinocytes of hyperpigmented macules were large (average transverse diameter 0.6 μ). The melanosomes were distributed exclusively as single units in the keratinocytes (Fig 4). On the other hand, the melanosomes in melanocytes and keratinocytes of hypopigmented macules were about twice as small (average transverse diameter 0.3 μ) as compared with the hyperpigmented areas, and their distribution pattern inside the keratinocytes was mostly in complexes (Fig 5).

In normal skin the average transverse diameter of the melanosomes was 0.4 μ, whereas the melanosomes were distributed in keratinocytes singly as well as in complexes (Fig 6).

There was no difference in electron density between melanosomes of normal skin and that of hyperpigmented and hypopigmented macules.

COMMENT

As compared with average regional frequence distribution numbers given by Szabo[8] and by Staricco and Pinkus,[6] the density of melanosomes on the lower abdomen and buttocks is slightly higher in cases 2 and 5. It is known, however, that individual variation can be considerable.[9] In this case there may be a hereditary tendency towards such a melanocyte distribution.

The remarks about the melanocyte morphology are only impressions, since measurements are difficult as is clearly demonstrated by the irregular shape of the melanocyte-bodies clenched between the surrounding keratinocytes and of the winding dendrities creeping between the Malpighian cells.

Our light and electron microscopic findings regarding the hypomelanotic macules differ to a certain extent from those made by Fitzpatrick et al[4] (Table I). They found a decreased DOPA activity and melanocytes with a narrow perikaryon in DOPA-stained sections. Furthermore, they described a decrease in the size of melanosomes often showing their internal structure, indicating that the melanin deposition is incomplete. In keratinocytes the small and immature melanosomes tended to be aggregated into melanosome complexes.

Changes in hypermelanotic macules of patients with definite symptoms of tuberous sclerosis have so far not been described at the ultrastructural level.

It is of interest that the differences in melanosome size and distribution pattern in keratinocytes of hypomelanotic macules, normal control skin, and hypermelanotic macules occurring here in a single member of the family under study resemble those typical for, respectively, white, oriental, and black skin.

These results support the findings of Wolff and Konrad[10] that the size of melanosomes determines the distribution in the keratinocytes as singles or as complexes.

The patients described here do not demonstrate major symptoms of tuberous sclerosis. Only a few minor symptoms (small skull, mental deficiency, and retarded growth), which is prevalent in many other neurocutaneous syndromes, are present. It is therefore better to consider this clinical picture, of which the most striking symptoms are hypomelanotic and hypermelanotic macules, as a separate entity.

Studying the pedigree (Fig 1) suggests that this disease is most likely inherited in an autosomal dominant way.

Patient 1 (the mother) has discrete lesions of which she was hardly aware. In contrast, the majority of her children have skin lesions. Some children have experienced difficulties in learning, and one was severely mentally handicapped. Therefore, genetic counseling is indicated.

Electron microscopy was carried out in the Department of Dermatology I, University of Vienna, under the guidance of Klaus Konrad, MD.

Technical assistance was given by Susan Csegezi, Lotte Polasek, and Bab Vrees.

Els Jansen-van den Bosch typed the manuscript.

References

1. Butterworth T, Wilson McC Jr: Dermatologic aspects of tuberous sclerosis. *Arch Dermatol* 43:1-41, 1941.

2. Chao DH-C: Congenital neurocutaneous syndromes in childhood. *J Pediatr* 55:447-459, 1959.

3. Gold AA, Freeman JM: Depigmented nevi: The earliest sign of tuberous sclerosis. *Pediatrics* 35:1003-1005, 1965.

4. Fitzpatrick TB, Szabo G, Hori Y, et al: White leaf-shaped macules: Earliest visible sign of tuberous sclerosis. *Arch Dermatol* 98:1-6, 1968.

5. Jimbow K, Fitzpatrick TB, Szabo G, et al: Congenital circumscribed hypomelanosis: A characterization based on electronmicroscopic study of tuberous sclerosis, nevus depigmentosus and piebaldism. *J Invest Dermatol* 64:50-62, 1975.

6. Staricco RJ, Pinkus H: Quantitative and qualitative data on the pigment cells of adult human epidermis. *J Invest Dermatol* 28:33-45, 1957.

7. Konrad K, Wolff K: Hyperpigmentation, melanosome size, and distribution patterns of melanosomes. *Arch Dermatol* 107:853-860, 1973.

8. Szabo G: Quantitative histological investigations on the melanocyte system of the human epidermis, in Gordon M (ed): *Pigment Cell Biology*. New York, Academic Press, 1959, pp 549-561.

9. Szabo G, Gerald AB, Pathak MA, et al: Racial differences in the fate of melanosomes in human epidermis. *Nature* 222:1081-1088, 1969.

10. Wolff K, Konrad K: Melanin pigmentation: An in vivo model for studies of melanosome kinetics within keratinocytes. *Science* 174:1034-1035, 1971.

Acrodermatitis and Acquired Zinc Deficiency

Richard I. Ecker, MD, Arnold L. Schroeter, MD

• A 42-year-old woman had an acquired zinc deficiency. The patient was malnourished, secondary to chronic alcohol (ethanol) abuse and cirrhosis, with associated low serum and urinary levels of zinc. Her acrodermatitis was unresponsive to topically applied triamcinolone acetonide but cleared after oral zinc sulfate therapy.
(*Arch Dermatol* 114:937-939, 1978)

Recently, therapeutic advances have been made in the understanding of zinc deficiency as related to acrodermatitis enteropathica,[1] and the adult form has been seen with total parenteral nutrition.[2] We describe a case of adult acrodermatitis that responded to oral zinc therapy.

REPORT OF A CASE

A 42-year-old woman had a ten-day history of a progressive pruritic rash. She had first noticed the rash on the hands and had noted its proximal spread to the forearms. Its initial appearance was papulovesicular, but this changed rapidly to a scaly, reddened, reticulated rash. The patient used various topical medicines, which had been previously prescribed for her recurrent neurodermatitis. These included a lubricating cream, haloprogin cream, and a mild soap. Approximately five days after the initial lesion began, a similar rash appeared on the thighs, lower legs, and ankles. Because the rash began to develop on the chest area, the patient sought relief.

Accepted for publication Sept 16, 1977.
From the Mayo Clinic and Mayo Foundation, Rochester, Minn.
Reprint requests to Section of Publications, Mayo Clinic, 200 First St SW, Rochester, MN 55901 (Dr Ecker).

The patient had had a single hospital admission for neurodermatitis nine years previously. Important medical history included 20 years of alcohol (ethanol) abuse and early cirrhosis documented by liver biopsy in 1967. The patient, a tavern owner, admitted to continued alcohol intake of two to three beers per day and consumption of a maximum of one meal per day. The patient denied any recent trauma, insect bites, illicit drug injection, recent illness, contact allergies, atopic disease, or previous skin problems other than those previously noted. The patient refused admission to the hospital and was evaluated initially as an outpatient and then later during a ten-day hospital stay. Medicines at admission included one folic acid tablet daily, a topically applied triamcinolone acetonide cream, and a daily multivitamin.

On physical examination at hospitalization, the patient was thin, pale, uncooperative, sullen, emotionally labile, and somewhat slow to orient herself to the hospital. The pulse rate was 84 beats per minute, oral temperature was 36.6° C, and blood pressure was 98/60 mm Hg. The skin had a reticulated, crusting maculopapular rash that involved the distal aspects of the upper and lower extremities, thighs, chest, and shoulders. A single annular lesion of the occipital scalp with central clearing was observed. Also prominent were erythematous, crusted, and fissured lesions confined to the knuckles and in the finger webs (Fig 1). Oral examination showed a reddened, nontender oral mucosa and a smooth, atrophic tongue. The liver by percussion was of normal size, with the edge 4 cm below the right costal margin and with a firm, smooth, nontender border. Moderate ankle edema was present. There were no deficiencies of taste or smell.

The hemoglobin level was 11.9 g/dl; hematocrit reading, 37%; mean corpuscular volume, 107 cuμ; mean corpuscular hemoglobin value, 356 pg with 768,000 platelets; and WBC count, 8,300/cu mm with 76% neutrophils, 19% lymphocytes, 2% monocytes, and 2% eosinophils. Laboratory studies gave the following values: ESR, 36 mm/

Fig 1.—Acrodermatitis of hand, with erythematous lesions over bony prominences.

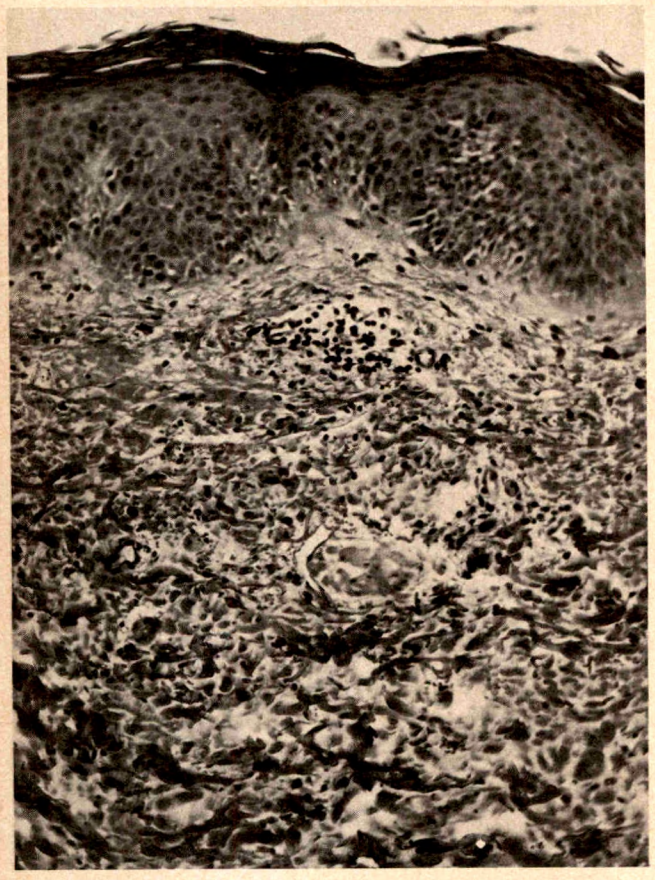

Fig 2.—Biopsy specimen from forearm showing parakeratosis, acanthosis, and lymphocytic perivascular infiltrate (hematoxylin-eosin, original magnification ×160).

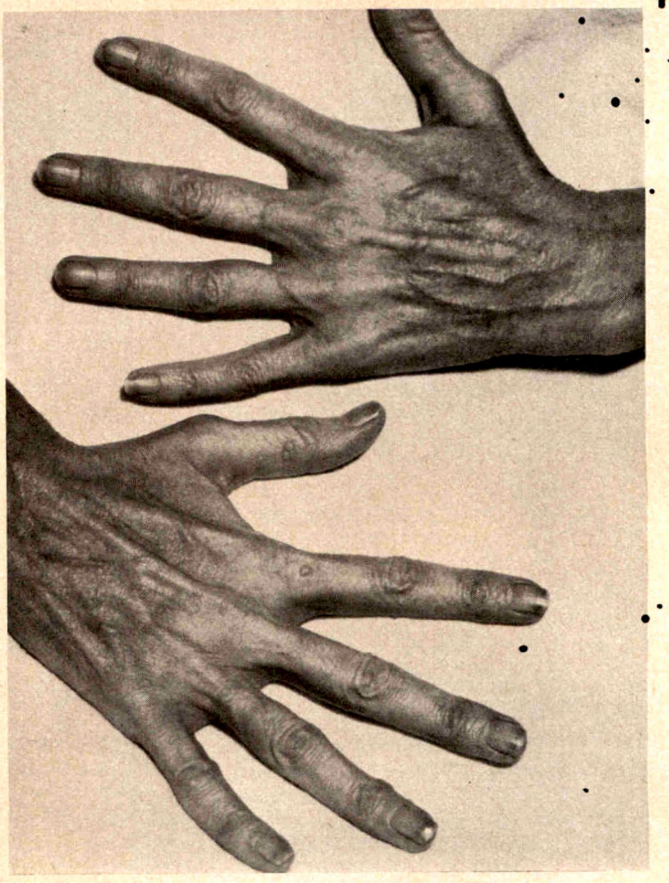

Fig 3.—Acrodermatitis of hand. Clearing of lesions after four days of zinc therapy.

hr; fasting glucose, 106 mg/dl; potassium, 3.1 mEq/liter; calcium, 7.4 mEq/liter; total protein, 5.7 g/dl; albumin, 2.85 g/dl; SGOT, 23 units/liter; SGPT, 16 units/liter; alkaline phosphatase, 434 units/liter; creatinine, 1.0 mg/dl; and uric acid, 7.7 mg/dl. The free fatty acid concentration was 770 μEq/liter (normal, 239 to 843 μEq/liter). There was 1+ proteinuria. Serum cholesterol and triglyceride values were 115 and 125 mg/dl, respectively. Antinuclear antibody and lupus erythematosus clot tests were negative.

A three-hour glucose tolerance test showed the following values: at 30 minutes, 98 mg/dl; at 1 hour, 158 mg/dl; at 2 hours, 114 mg/dl; and at 3 hours, 102 mg/dl. A liver and spleen scan was normal. The fluorescent treponemal antibody test was negative. Additional laboratory values were as follows: serum iron, 112 μg/dl; total iron-binding capacity, 198 μg/dl (with 57% saturation); vitamin B_{12}, 775 pg/ml; folate, 12 ng/ml; serum carotene, 6 μg/dl; magnesium, 1.11 mg/dl; prothrombin time, 11.9 seconds, urine sodium, 65 mg/liter; total thyroxine, 3.5 μg/dl; free thyroxine, 0.9 μg/dl; and thyroid-stimulating hormone, 9 μU/ml. The concentration of serum zinc was 54 μg/dl (normal, 75 to 140 μg/dl) and of urine zinc was 176 μg/24 hr (normal, 300 to 700 μg/24 hr). Both zinc determinations were done by the atomic absorption method. The hair zinc content was 231 μg/g (normal, 100 to 200 μg/g).[3] A roentgenogram of the chest showed old healing rib fractures of previous trauma.

A scabies preparation was negative, and the KOH test was negative on preparations from the scalp and a lesion on the right thigh. Subsequent cultures for bacteria and fungi were negative. A skin biopsy specimen showed hyperkeratosis, parakeratosis, acanthosis, and a perivascular infiltrate in the upper part of the dermis (Fig 2). Direct immunofluorescence showed scattered C3 at the basement membrane. Therapy was begun initially with topical wet dressings and 0.05% triamcinolone acetonide cream (every three hours), ultramicronized griseofulvin (125 mg twice a day), miconazole nitrate cream (twice a day), and multivitamins. In four days the rash cleared completely from the chest, shoulders, and upper arms and was eventually confined to the distal aspects of the extremities.

During this period, the patient refused to eat, was uncooperative and tremulous, and had occasional auditory hallucinatory episodes at night. A possible diagnosis of delirium tremens was considered; however, the patient failed to exhibit facial congestion, dilated pupils, tachycardia, moist skin, hyperreflexia, garbled speech, visual hallucinations, or clouding of consciousness. Because of the lack of clinical response to our initial therapy for a nonspecific dermatitis and tinea corporis, a zinc-deficiency dermatosis was considered. The antifungal and topical steroid regimens were stopped, and zinc sulfate therapy, 300 mg/day, was begun. After four days of this therapy, the rash cleared from the extremities (Fig 3), papillas began on the tongue, and the patient's mental status was markedly improved. The calorie intake also increased from between 200 and 300 to between 1,500 and 2,000 per day. Patch test series done at this time demonstrated no positive results in an area not previously treated with triamcinolone cream. The patient was dismissed and was given instructions regarding a proper diet and general skin care, as well as a regimen of furosemide, 20 mg/day as needed for her ankle edema, and the continuation of zinc and multivitamin therapy. The serum zinc level at dismissal was 86 μg/dl.

When contacted three months after dismissal, the patient reported that her skin was free of lesions and that she had maintained her improved mental status. After six weeks of oral zinc therapy, she was eating a minimum of two balanced meals per day in place of mineral supplements. The serum zinc level at this time was 159 μg/dl.

COMMENT

The patient was seen initially with a crusted vesicular rash confined to

the extremities and chest and a single lesion on the scalp. At initial examination, the dermatitis appeared to be one of the following: contact dermatitis, autosensitization to infection, neurodermatitis, or tinea corporis. When the usual modes of therapy were applied, the rash responded promptly in all but the acral areas, which remained resistant to intensive topical steroid therapy. At this time, the patient's nutritional status and distribution of the rash was similar to that recently described in a case of acquired zinc deficiency and acrodermatitis-enteropathica-like skin lesions associated with trace metal deficiency of total parenteral nutrition.[2] With the baseline results of mineral studies[4] and knowledge of zinc deficiency associated with alcoholic cirrhosis,[5-8] we attempted a therapeutic trial of oral zinc. The rash cleared completely during a four-day period, without specialized dermatologic therapy. Two other changes were also noted. The tongue reverted to an almost normal form, and the patient underwent a noticeable personality change. She became cooperative, cheerful, and attentive to her personal hygiene and medical care.

From the well-accepted cause-effect relationship of a zinc-deficiency state and acrodermatitis enteropathica in infants and children, as well as possible adult forms, we would add to the symptom complex the associated mental changes apparent in this case. Whereas an overall, in-depth psychiatric assessment to document depressive symptoms was not attempted in our case, at admission this patient had several of the symptoms associated with depression: insomnia, anorexia, lethargy, low spirits, and lack of self-interest. At dismissal, her mother remarked that she seemed "more like her old self again," since all of the above mental problems were at least partially alleviated. This has been previously noted in other instances of zinc deficiency.[9,10]

The cause of the zinc deficiency in this case was believed to be related to generalized malnutrition and alcoholic cirrhosis of the liver. Results of the patient's physical examination, her nutritional history, previous diagnosis of early alcoholic cirrhosis, and probably continued high alcohol intake support this diagnosis. The association between the low serum zinc level and the high urine zinc concentration has been discussed.[8] Our patient had low serum and urine zinc concentrations. We are unable to resolve this discrepancy, except to hypothesize that, for this individual, the low urine zinc level followed a previous high urinary zinc stage of alcoholic cirrhosis, and this perhaps represents a conservation measure of long-term zinc deficiency.

The relatively high zinc content in hair despite low serum and urine zinc levels is paradoxical. Cosmetic preparations that contain zinc can result in elevated levels in hair.[3] Present technology does not allow removal of all nonbiologic zinc (J. T. McCall, PhD, oral communication, July 1977). The conspicuous hair coloring and curling treatment used by our patient seemed to account for this inconsistency. An alternative explanation is that an interpretation of hair zinc content depends on a normal hair growth rate. Therefore, a decreased growth rate can account for higher zinc concentration than would otherwise be expected.

The skin biopsy done prior to commencement of zinc therapy also demonstrated a histologic diagnosis compatible with acrodermatitis enteropathica. Whereas the biopsy findings were considered to be nonspecific in this disorder, the characteristic hyperkeratosis, parakeratosis, acanthosis, and chronic inflammatory reaction of the upper part of the dermis that are frequently seen in acrodermatitis enteropathica were all present in our case.[11] The immunofluorescence study demonstration was apparently a nonspecific finding in this patient, because we know of no previously reported similar findings in acrodermatitis enteropathica.[11]

The possibility of adult zinc deficiency should be considered in alcohol abusers, in the malnourished, and in those with acrodermatitis unresponsive to the usual modes of therapy.

Nonproprietary Names and Trademarks of Drugs

Haloprogin—*Halotex*.
Miconazole nitrate—*Micatin*, *Monostat*.

References

1. Neldner KH, Hambidge KM: Zinc therapy of acrodermatitis enteropathica. *N Engl J Med* 292:879-882, 1975.
2. Tucker SB, Schroeter AL, Brown PW Jr, et al: Acquired zinc deficiency. *JAMA* 235:2399-2402, 1976.
3. Petering HG, Yeager DW, Witherup SO: Trace metal content of hair: I. Zinc and copper content of human hair in relation to age and sex. *Arch Environ Health* 23:202-207, 1971.
4. Halsted JA, Smith JC Jr: Plasma-zinc in health and disease. *Lancet* 1:322-324, 1970.
5. Goodhart RS, Shils ME: *Modern Nutrition in Health and Disease: Dietotherapy*, ed 5. Philadelphia, Lea & Febiger Publishers, 1973, pp 382-388.
6. Sunderman FW Jr: Current status of zinc deficiency in the pathogenesis of neurological, dermatological and musculoskeletal disorders. *Ann Clin Lab Sci* 5:132-145, 1975.
7. Sandstead HH: Zinc nutrition in the United States. *Am J Clin Nutr* 26:1251-1260, 1973.
8. Allan JG, Fell GS, Russell RI: Urinary zinc in hepatic cirrhosis. *Scott Med J* 20:109-111, 1975.
9. Moynahan EJ: Zinc deficiency and disturbances of mood and visual behaviour. *Lancet* 1:91, 1976.
10. Tasman-Jones C, Kay RG: Zinc deficiency and skin lesions. *N Engl J Med* 293:830, 1975.
11. Rayhanzadeh S, Dantzig P: Acrodermatitis enteropathica, with pathologic findings in jejunum and skin. *Pediatrics* 54:77-80, 1974.

Monosymptomatic Hypochondriacal Psychosis Manifesting as Delusions of Parasitosis

A Description of Four Cases Successfully Treated With Pimozide

Alistair Munro, MD

• A recent article in the ARCHIVES described the severe problems encountered in trying to treat patients with delusions of parasitosis. The present article describes four such cases, which fall into the larger category of monosymptomatic hypochondriacal psychoses, conditions that appear to be related to the paranoid disorders. Evidence is accumulating that such cases may respond very specifically to treatment with pimozide, a relatively new psychotropic medication. This drug keeps the symptoms in remission but does not effect a cure; nevertheless, it may represent a highly important advance in therapy in a condition traditionally regarded as virtually untreatable.

(*Arch Dermatol* 114:940-943, 1978)

The article entitled "Delusions of Parasitosis" by Gould and Gragg[1] has engendered interest in the psychiatric literature since its publication in the ARCHIVES in December 1976. A resume was published in the *Digest of Neurology and Psychiatry*,[2] and an editorial in the *British Medical Journal*[3] was inspired by it. Gould and Gragg have made several worthwhile points about a condition that causes distress to patient and therapist alike and that tends to have a very poor prognosis. They stress that there must be no doubt that the complaint is delusional in nature, and clearly, when a patient comes to a psychiatrist complaining of a parasitic infestation that is not obvious, the psychiatrist should certainly obtain a dermatological opinion. In fact, the process is usually reversed, since these patients are often seen first by a dermatologist who cannot find evidence of infestation and who may then ask for a psychiatric consultation.

Another point well made by Gould and Gragg is the need to establish rapport with the patient. Their two case histories clearly demonstrate how suspicious and defensive these patients are, and how conflicting are the attitudes and advice of the physicians they see. These people usually make their way from physician to physician demanding help and rarely feeling satisfied, since the disorder often is progressive and, until now, there has been no specific treatment. Usually they react with indignation and hostility to any suggestion that their condition may be psychogenic, and their behavior strongly suggests that delusional parasitosis is closely related to paranoia.

In addition, it is necessary to differentiate between psychotic and neurotic disorders. In a recent letter and article, Riding and I[4,5] differentiate those cases in which there is a persistent neurotic fear of parasitic infestation (which can be classed as a type of phobia) and those in which the belief of infestation is truly delusional, and the illness therefore a psychotic one, probably with affinities to paranoia. In the German and Scandinavian psychiatric literature, this second group is included in the disorders known as monosymptomatic hypochondriacal psychoses. These are characterized by the patient's unshakeable belief that some aspect of his anatomy, physiology, or health status is abnormal, despite all evidence to the contrary, and should not be diagnosed in the presence of any meaningful degree of organic brain syndrome, depressive illness, or schizophrenia. In the phobic type of case, psychotherapy, behavior therapy, and tranquilizing drugs may be indicated, and success is likely to be related to the specificity of the phobia, limited duration of the symptoms, and the stability of the underlying personality. In general, long-established cases do badly, as do cases with multiple symptoms.[6] In the delusional cases the

Accepted for publication Sept 22, 1977.

From the Department of Psychiatry, Toronto General Hospital, Toronto, Ontario, Canada.

Reprint requests to Department of Psychiatry, Toronto General Hospital, 101 College St, Toronto, Ontario, Canada M5G 1L7 (Dr Munro).

results are traditionally very poor and, until recently, discussion of therapy has tended to be mostly academic. Riding and I[4,5] describe the apparently successful treatment of three cases of monosymptomatic hypochondriacal psychosis, partial success in a fourth, and success in a case with similar symptoms that we hesitated to describe as an outright monosymptomatic psychosis. These results were obtained with pimozide, an antipsychotic medication. Two of the patients who had delusions of insect infestation were the first to be treated successfully with this drug. Following our report, two other workers (Reilly[7] and Reilly and Beard[8]) have indicated that they are obtaining similar results with pimozide. Recently, there has been a report of another single patient who appeared to respond to a monoamine oxidase inhibitor,[9] although the case may have been of depressive origin. It therefore appears that more specific help may now be available for some of these unfortunate people.

The patients whom Riding and I treated were seen in England, but since coming to Toronto in 1975, I have been asked to examine seven patients with monosymptomatic hypochondriacal psychosis, four of whom have had delusions of insect infestation. Three of the latter continue under my care at present; the fourth patient refused to see me again, but his condition is supervised by another psychiatrist who provides information on progress. All four patients have responded strikingly to pimozide, as did two of the other patients; the seventh patient refused to accept treatment from a psychiatrist.

Pimozide is a neuroleptic substance and the first clinically available representative of the diphenylbutylpiperidines, a group of drugs closely allied to the butyrophenones (one of which is haloperidol). It has been available for several years in Europe and Great Britain and, during the past two years, in Canada. It is likely to become available in the United States in early 1978. Until lately, its main use has been in the treatment of schizophrenia, especially in patients who show severe apathy and inertia. It is given in relatively low dosage compared with most neuroleptics, and it is relatively free of serious side-effects, though over-alerting (or paradoxically in some cases, inertia) and mild Parkinson's symptoms have been encountered. It is best given in a single dose in the morning to minimize effects on sleep.

REPORT OF CASES

Case 1.—A 60-year-old woman complained of insects crawling over her head and body She was referred by a dermatologist who had found absolutely no evidence of parasitic infestation. The patient's general health was good and she made no other complaints. Two years previously, she found some maggots in flour in her kitchen. Since then, she had become progressively more convinced that she was infested by mites, and she was very upset that no physician could confirm their presence. She told no one else, lest they would shun her, and she washed herself, her clothes, and her bedclothes incessantly, but without relief. She slept little as she sometimes arose at night to wash and change her nightclothes.

The patient admits to having always been somewhat obsessional, but there was no previous history of psychiatric disorder. She married as a young woman, but marriage was unsuccessful and eventually ended. She has a daughter living in South Africa whom she greatly misses. Her main social contacts are with relatives whom she sees only occasionally. Apart from her brother who had "nervous troubles of middle age," which cleared up, there is no known family history of psychiatric illness.

At her first interview, the patient appeared to be a pleasant, cooperative, but anxious woman who looked younger than her chronological age. Her sensorium was clear and intelligence above average. Her belief in the parasitosis was absolute, and she pointed out marks on her skin that she insisted were actual insects or their eggs. She had mild ideas of reference; these related entirely to fears that people would learn of her infestation. Otherwise, the personality was perfectly well-retained, and there was no evidence of a schizophrenic process or of a depressive illness.

The patient was unwilling to accept a psychiatric explanation of her condition and no attempt was made to argue with her. A diagnosis of monosymptomatic hypochondriacal psychosis/infestation psychosis was made. Despite her antipsychiatric bias, the patient was desperate for help and agreed to take pimozide. Therefore, administration of 2 mg orally per day was begun.

After a week, she reported a slight lessening in her preoccupation with the infestation and a slight reduction in anxiety. At that point the pimozide dosage was increased to 4 mg daily. Three weeks after her original visit, she reported that she was feeling much more cheerful and optimistic and was going out more because of a lessening fear of contamination.

Four weeks from the commencement of medication administration, she said that, during the previous week, she had developed a considerable feeling of well-being. She had visited her relatives for three days without taking special precautions, and she was now washing herself at a normal frequency. Unfortunately, for a short time thereafter, her symptoms partly returned. More than 4 mg of pimozide daily had made her feel restless, and she reduced the dosage herself for a short period, which coincided with the return of symptoms. On stabilizing the dosage of 4 mg, improvement and well-being returned. More recently, the pimozide was reduced to 2 mg daily and has continued at this maintenance level with total remission of symptoms.

The patient found a job and has made friends with a lady of similar age with whom she is beginning to exchange visits. She visits her family more frequently than before, and she is reasonably content, though she admits her life is rather lonely.

At no time has she ever admitted her complaint was psychiatric in nature and she refers to it simply and euphemistically as her "problem," but her attitude toward visiting me is now positive. I see her at intervals of three months in order to review her medication; she will mention her "problem" only if asked.

Case 2.—This 70-year-old man was referred by a dermatologist who could find no cause for his complaint of flea infestation for a year. He said the fleas were originally from a pet canary.

The patient lives alone, but says that he had plenty of friends until the infestation began, when he withdrew completely from company. He retired from work only two years previously, following a sudden, severe, myocardial infarction. He made an excellent recovery from this and resumed an active life, but missed his work. He admitted to only a moderate degree of alcohol drinking.

He was very indignant that the dermatologist had been unable to confirm the presence of fleas. He showed me "flea-bites," which were actually Campbell-de Morgan spots and small moles. He was angry at being sent to a psychiatrist and said all he wanted was effective insecticides. He had already spent a good deal of money on these in an attempt to rid his house of fleas. He washed himself and his clothes almost incessantly but said the fleas immediately jumped back on him.

At the first interview, he appeared much younger than his stated age and intelligence was average. He insisted his complaint was physical and could not be persuaded otherwise. His sensorium was clear, memory and orientation were normal, and personality was excellently preserved. He was not suffering from depressive illness, schizophrenia, or dementia. A diagnosis of monosymptomatic hypochondriacal psychosis/infestation psychosis was made.

With great reluctance, the patient agreed to take pimozide and was given 2 mg orally per day, which was increased to 4 mg five days later. Seventeen days later, although his complaints about fleas were essentially unchanged, he appeared much less agitated and reported a weight gain of 2.7 kg. He was persuaded to increase the pimozide to 6 mg daily and, two weeks later, reported great improvement. There were far fewer fleas in the house and he was much less bothered by them. Although

he still washed his clothes daily, he said that this was now a precaution rather than a necessity. By now he had become very compliant about treatment and attendance.

A week later he complained of extreme lethargy and, in view of his cardiac history, he was hospitalized briefly for observation. There it was discovered that he was so impressed by the efficacy of pimozide, he raised the dose of his own accord until he was consuming approximately 24 mg/day, which was grossly excessive. In the hospital, he was given dosages ranging from 6 mg daily (at which level some fleas "reappeared") to 12 mg daily, when his symptoms were in full remission. He was discharged and is again seen as an outpatient. Pimozide dosage is currently at a maintenance level of 4 mg daily.

He exchanges visits with friends and is no longer interested in having his house fumigated. He is embarrassingly positive about the results of treatment but has never admitted that his symptoms were psychological.

Case 3.—When first seen, this 56-year-old unmarried woman complained of insect infestation for five months. She said that sewer-digging was being done outside her house, and a mouse had entered the house from the sewer. Thereafter, she had increasing skin irritation and a growing conviction that she was infested by insects. She claimed to see black bugs and white eggs on her skin and had taken "specimens" to her family doctor and to a dermatologist, who found them to be flakes of skin. She got little sleep because of the insects and because she repeatedly washed herself, her clothes, and her bed linen.

The patient is an overweight diabetic who is treated by diet; she also receives methyldopa (Aldomet) for hypertension. She lives alone and has never had any close friends. She nursed her aged parents through their last illnesses, although she worked steadily as a clerk until two years ago. She attends a psychiatrist, mainly to discuss her loneliness, and on one occasion was given a tricyclic antidepressant, but quickly stopped it because it made her overactive.

At her first interview, the woman was noted to be restless and anxious. Intelligence was average and memory normal. She gave the impression of having a somewhat eccentric personality, but there was no evidence of schizophrenia. She was not suffering from a depressive illness, and there were no symptoms of organic brain syndrome. A diagnosis of monosymptomatic hypochondriacal psychosis/infestation psychosis was made. She was disbelieving about any help a psychiatrist might be able to give her. I did not argue but merely asked her to take pimozide, to which she eventually agreed. To start, she was given 2 mg daily for one week, increasing to 4 mg daily thereafter. After two weeks of taking medication she reported slight improvement, especially noticeable since raising the daily dose of pimozide to 4 mg, but said her life was still seriously disrupted by the presence of so many insects. Two weeks after this, she agreed that her daytime symptoms were noticeably better, but her pruritus was still bad at night. Pimozide was increased further to 6 mg daily and at that stage, the patient's delusion virtually disappeared. A short time later, she developed influenza and for no very good reason thought she should discontinue the medication. On 6 mg/day she had noticed some degree of lethargy, which disappeared on the day following discontinuation; three days later the delusions returned in full force. She was persuaded to resume taking pimozide, 6 mg daily, and she is currently on this dosage. Her lethargy has responded well to antiparkinsonian medication. She is now quite positive toward her medication but does not admit that her illness was psychological. She is getting out and about reasonably freely, and she is no longer trying to have the authorities fumigate her house.

Case 4.—About four months before being referred to me, this 29-year-old unmarried man probably had a genuine attack of pubic lice, which was treated successfully. However, a month or two later, he developed itching all over his body and started using the anti-infestation shampoo in widespread fashion. Despite the fact that several doctors had been unable to confirm the presence of insects, he had become convinced he was infested everywhere, and he interpreted white skin flakes as evidence of ova. He had shaved off all his body hair and had bought a microscope to study the insects. Although he had looked at numerous specimens, he could never quite focus sufficiently to identify one unmistakably.

He was very angry that the various doctors, whom he thought incompetent, could not identify the insects. He intended to visit as many doctors as was necessary, until he found one who could confirm his illness. He was extremely irate at being asked by a dermatologist to see me. He told me that he already saw a psychiatrist from time to time and had been treated on occasion for "depression," but currently he felt very well emotionally, he was working steadily, and he had no serious stresses in his life.

Several times during the interview he displayed overt anger, mainly because he insisted his symptoms were physical. I did not disagree with this assertion. Intelligence was high average, and the personality was well-preserved, though by the patient's description, his idée fixe was taking over his everyday life. His conviction about infestation was delusional in intensity.

The patient was most unwilling to accept medication from me but agreed to discuss the situation with his own psychiatrist. I spoke to the latter, who told me that he considered the patient to be suffering from a borderline personality disorder with periodic decompensation into schizoaffective illness, from which he always recovered. There was no previous history of infestation psychosis.

The patient has refused to see me but did accept pimozide, 2 mg daily, from his psychiatrist, with rapid and marked improvement in the delusional symptom. He rationalized this by saying that the drug was having a direct effect on the insects. The delusion disappeared altogether and the patient stopped taking the medication about two months after starting it, because it was over-stimulating him. To date, the infestation has not recurred.

COMMENT

If one compares the two cases reported by Gould and Gragg with the four cases reported above, it can be seen how remarkably similar are the complaints made by patients with infestation psychosis. This tends to be true of most cases of monosymptomatic hypochondriacal psychosis, whatever the nature of the delusion. These people are totally convinced of the presence of parasites (or a bad smell, or an abnormal appearance of some kind) and are very angry that no doctor will believe them. Typical individuals with infestation psychosis arrive carrying an envelope or a pill bottle containing flakes of skin that they insist are the insects or their ova. They indignantly refuse any psychiatric explanation and yet, as Gould and Gragg demonstrate, they may accept psychiatric intervention if it is tactfully proffered, perhaps because they are so desperate to persuade someone of the truth of their complaints. Usually, they have taken these complaints to many doctors and they report in great detail the inefficiency and negligence that they consider they have experienced with all of them.

Another factor that seems to stand out among these patients is their tendency to be "loners." Despite a wide age range, and representation from both sexes, the patients I have seen have a very great tendency to be unmarried or separated from their spouses. In no case was this noted to be a precipitating circumstance, and there is a strong impression that there must be factors in these individuals' premorbid personalities that make them unsatisfactory marriage partners. The overall similarity of the clinical phenomena, and the remarkably consistent response to pimozide, suggest that delusions of parasitosis are simply one form within the wider group of disorders known as the monosymptomatic hypochondriacal psychoses. All of them have, until now, been regarded as well-nigh hopeless therapeutically and prognostically.

The term "monosymptomatic hypochondriacal psychosis" is little used in

the English language literature, psychiatric or otherwise; even in Scandinavia, where the concept is better known, the number of subjects seen by psychiatrists is small. Retterstøl[10] reports that only 0.4% of a total psychiatric admission in Oslo, Norway, consisted of patients with paranoid psychoses with hypochondriasis as the main delusional content. However, many such cases do not come to a psychiatrist, partly because the dermatologist or other physician is disinclined to refer a patient who is so antagonistic to medicine in general and psychiatry in particular, but also because the psychiatrist has usually offered very little of therapeutic value until now.

Pimozide is no magic cure. It is an antipsychotic substance whose main role has been in the treatment of inert chronic schizophrenic patients. Its application to cases of monosymptomatic psychosis was fortuitous in the first instance,[4,5] but experience in Canada as well as in England convinces me that it is a highly specific treatment in cases of monosymptomatic delusion, *provided the diagnosis is carefully made.* It does not appear to work in the dysmorphobic type of patient whose origins are neurotic rather than psychotic; indeed, it may make these patients worse.[4,5] Therefore, it is important to have a psychiatric opinion in these cases. Reilly and Beard[8] report preliminary confirmatory findings, and both these workers and myself are trying to initiate controlled clinical trials comparing pimozide with other psychoactive drugs. Unfortunately, in my own case, I find the patients initially so hostile and uncooperative, yet so demanding of help, that I have been unable to persuade any of them to enter a properly constituted investigation at the outset of treatment.

Pimozide produces remission, not cure, and in several of my cases the patient has spontaneously stopped taking the medication and has had a rapid return of symptoms. Increasingly it seems that a clinical trial will have to be based on a correlation of remission or exacerbation of symptoms with administration or withdrawal of the drug. At present, I can say that I have seen 11 patients with monosymptomatic hypochondriacal psychosis, six of whom have had delusions of parasitosis, improved markedly with pimozide and, in one case, remain well for a period of three years until I lost contact with the patient. All of these improvements have been confirmed by colleagues and have occurred in a type of case still regarded by many as hopeless.

I would suggest that all cases confirmed as delusions of parasitosis of the type described are worthy of a clinical trial with pimozide. The optimum dosage has to be found experimentally for each patient, but usually lies between 2 mg and 8 mg daily. Rarely must one go above this level and then only for a temporary period.

Robin Brooks-Hill, MD, assisted in the assessment of cases 2 and 3. Lawrence L. Ballon, MD, supplied follow-up information on case 4. Anita Jarvis, MD, staff dermatologist, referred the patients.

References

1. Gould WM, Gragg TM: Delusions of parasitosis: An approach to the problem. *Arch Dermatol* 112:1745-1748, 1976.
2. *Digest of Neurology and Psychiatry.* Series 45, Feb 15, 1977.
3. Delusions of parasitosis, editorial. *Br Med J* 1:790-791, 1977.
4. Riding J, Munro A: Pimozide in the treatment of monosymptomatic hypochondriacal psychosis. *Lancet* 1:400, 1975.
5. Riding J, Munro A: Pimozide in the treatment of monosymptomatic hypochondriacal psychosis. *Acta Psychiatr Scand* 52:23-30, 1975.
6. Kenyon FE: Hypochondriacal states. *Br J Psychiatr* 129:1-14, 1976.
7. Reilly TM: Pimozide in monosymptomatic psychosis. *Lancet* 1:1385, 1975.
8. Reilly TM, Beard AW: Monosymptomatic hypochondriasis. *Br J Psychiatr* 129:191, 1976.
9. Roberts J, Roberts R: Delusions of parasitosis. *Br Med J* 2:1219, 1977.
10. Retterstøl N: Paranoid psychoses with hypochondriacal delusions as the main delusion. *Acta Psychiatr Scand* 44:334-353, 1968.

CORRECTION

Incorrect Stage Numbers.—In the article entitled, "Selective Immunological Evaluation of Mycosis Fungoides," published in the February ARCHIVES (114:207-212, 1978), the stage numbers that appear in the second and third sentences of the first paragraph on p 209 are incorrect. In the second sentence, which begins: "However, in the case of . . . ," the stage number should be IIIa. In the following sentence, the stage numbers should be IIa and IIIa, respectively. (The latter number is correct as it stands in the text.)

Giant Cell Tumor of the Tendon Sheath Involving Skin

Donald T. King, MD; Arlen J. Millman, MD; Arnold W. Gurevitch, MD; Frank M. Hirose, MD

• Giant cell tumor of the tendon sheath is the second most common tumor of the fingers and hands but is only rarely mentioned in the dermatologic literature. Although its pathogenesis has been debated, it is probably a type of fibrous histiocytoma. This tumor is almost always benign but may locally invade the overlying dermis and be confused with a malignant neoplasm. It often extends to the synovium of the adjacent joint space and necessitates total excision to prevent local recurrence. Therefore, excision should be undertaken by a physician who is surgically qualified for such procedure. We report a case that illustrates the clinical and pathologic aspects of this lesion.

(*Arch Dermatol* 114:944-946, 1978)

The differential diagnosis of tumors on the fingers is extensive and includes lesions that arise within the epidermis, such as the eccrine poroma, as well as those that originate in the dermis and subcutaneous tissue. Among the many nodular lesions that arise in the latter two sites are the epidermal inclusion cyst, digital mucous cyst, rheumatoid nodule, angioma, acquired digital fibroma, cutaneous cartilaginous tumor,[1] and metastatic neoplasm.[2,3] In addition, tumors, such as ganglion, giant cell tumor of tendon sheath, xanthoma tendinosum, synovial sarcoma, chondrosarcoma, osteosarcoma, epithelioid sarcoma,[4] clear cell sarcoma,[5] and fibroma of tendon sheath,[6] may develop from underlying skeletal structures and their surrounding soft tissues.

The giant cell tumor of the tendon sheath is second in frequency only to ganglia among the tumorous conditions of the hand and finger[7] and is known by a variety of terms, including fibrous histiocytoma of the tendon sheath, xanthogranuloma, myeloplaxoma, nodular tenosynovitis, and benign synovioma.[8]

Despite its frequent occurrence and possible clinical and pathologic confusion with other lesions that occur in the skin and subcutis, the giant cell tumor of the tendon sheath has been described rarely in the dermatologic literature.[9,10] This report illustrates the clinical and pathologic features of a giant cell tumor of tendon sheath, which infiltrated the overlying dermis. Therefore, this entity must be considered in the differential diagnosis of dermal nodules on the fingers.

REPORT OF A CASE

A 51-year-old man appeared at the Dermatology Clinic of UCLA-Harbor General Hospital with a one-year history of a slowly growing tumor over the distal interphalangeal joint of the left index finger (Fig 1). He claimed the growth began shortly after he struck his finger against a table. The lesion was asymptomatic and did not impair joint mobility. Examination showed a firm and rubbery 1.5 × 2.5-cm, lobulated, nonmovable tumor over the dorsum of the index finger. There was an associated dystrophy and discoloration of the nail plate. Initial differential diagnosis included rheumatoid nodule, acquired digital fibrokeratoma, foreign body granuloma, fibroma, myxoid cyst, eccrine poroma, and cutaneous cartilaginous tumor. Roentgenograms showed a soft tissue mass without evidence of calcification or destruction of underlying bone. A 3-mm punch biopsy specimen of the skin was of insufficient depth to include the tumor and revealed only skin with hyperkeratosis and mild acanthosis.

The patient was referred to the Plastic Surgery Service where the tumor and overlying skin, nail, and nail matrix were excised under local anesthesia. At surgery, the mass seemed to extend to the synovium but did not protrude into the joint cavity itself. Grossly, the lesion consisted of multiple, firm white pseudoencapsulated lobules surrounded by dense fibrous tissue. Microscopically, there were nodules of relatively large polygonal, histiocytic cells with scanty cytoplasm and medium-sized vesicular nuclei that displayed eosinophilic nucleoli. In focal areas, these cells contained intracytoplasmic hemosiderin. Numerous multinucleated, foreign body giant cells were admixed with the histiocytic cells. In some regions, there were clusters of foamy macrophages. These cellular elements were enmeshed in a dense hyalinized connective tissue stroma (Fig 2). A

Accepted for publication Sept 20, 1977.

From the Department of Pathology (Drs King and Hirose), and the Division of Dermatology, Department of Medicine (Drs Millman and Gurevitch), Harbor General Hospital, UCLA School of Medicine, Torrance, Calif.

Reprint requests to Department of Pathology, Harbor General Hospital, 1000 W Carson St, Torrance, CA 90509 (Dr King).

Fig 1.—Giant cell tumor of tendon sheath of index finger, with site of punch biopsy in center.

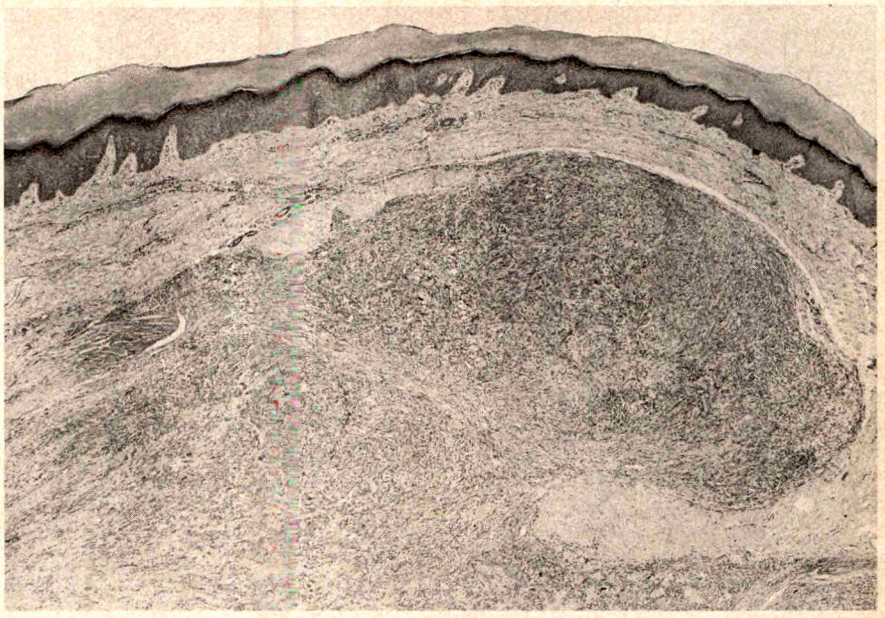

Fig 2.—Surgical specimen showing lobules of giant cell tumor of tendon sheath extending into middle of dermis (hematoxylin-eosin, original magnification ×26).

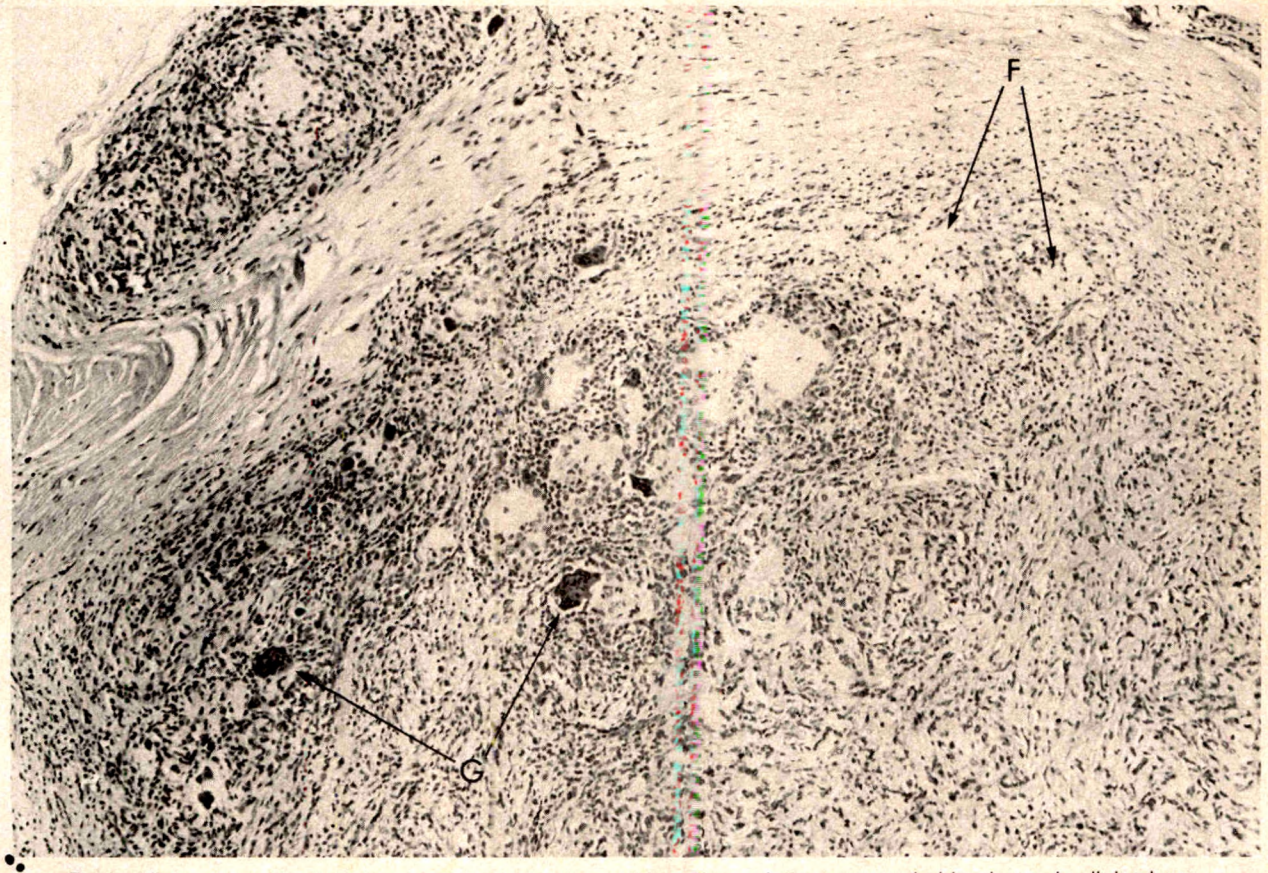

Fig 3.—Higher magnification showing lobu e of polymorphic cell population surrounded by dense, hyalinized connective tissue. Giant cells (G) and foam cells (F) are shown (hematoxylin-eosin, original magnification ×70).

few, narrow clefts or slit-like cavities lined by flattened cells were also present. The tumor nodules extended up into the middle of the dermis of the overlying skin and fingernail bed (Fig 3). No mitoses were seen.

Postoperatively, the patient has done well with no evidence of recurrence.

COMMENT

Giant cell tumor of tendon sheath arises predominantly on the fingers and less commonly on the knee, hand, wrist, foot, and hip. Although the most frequent single location is adjacent to the distal interphalangeal joint, as in this case, the anatomic site may sometimes bear no immediate relationship to a joint.[11] In addition, these tumors may occur on the volar and dorsal, as well as on the medial and lateral, surfaces of the fingers. The right and left hands appear to be affected equally and, rarely, a patient man have one lesion on each hand.[7] Typically, it appears as a painless, slowly growing mass on the finger, which produces disability only when the tumor becomes so large that it interferes mechanically with motion of the joint. The skin is usually freely movable over a lesion located proximally on the fingers but is frequently adherent to those tumors that are located distally.[11] Roentgenograms often show pressure erosion of the adjacent bone without evidence of invasion. Although these tumors are almost always benign, on extremely rare occasions they may become malignant and metastasize.[12]

The usual treatment is careful total excision. At surgery, the tumors are found to be adherent to a tendon sheath, joint capsule, or to the synovial joint surface itself, which requires the joint cavity to be opened to excise the tumor.[13] Because of the lobulated nature of the lesion, attempts to totally remove the tumor are often unsuccessful, and local recurrences are common. In these situations, local excision should again be performed rather than amputation or other radical procedures. Roentgen therapy is ineffective.[7]

There have been numerous hypotheses regarding the pathogenesis of this tumor. The variety of names applied to this entity are reflective of some of those theories. Suggested origins include inflammation, neoplasia, disturbance of lipid metabolism, trauma, and hemorrhage.[14] The most widely accepted thesis, first proposed by Jaffe and co-workers,[15] is that the giant cell tumor of tendon sheath (nodular tenosynovitis) is a reactive hyperplastic inflammatory lesion that is closely related, if not identical, to pigmented villonodular synovitis. These entities are believed to represent the same process, whether they involve the synovial membrane of a joint, bursa, or tendon sheath. All are histologically characterized by fibrous stroma, hemosiderin deposition, histiocytic infiltrate, and multinucleated giant cells. Unfortunately, the inciting cause of the inflammatory process is unknown. Results of electron microscopical study have supported this concept and indicate that the polymorphic cell population of lipid-laden foam cells, multinucleated giant cells, and round or polygonal stromal cells are all derived from type A (macrophage-like) and type B (fibrocyte-like) cells that are normally present in the human synovial membrane.[16] These findings, together with comparative histologic studies,[11] indicate that these growths are variants of the fibrous histiocytoma.[17]

Although the giant cell tumor of the tendon sheath has a fairly characteristic histologic appearance, there is enough variability to cause occasional confusion with other benign, as well as malignant, lesions. For example, the tumor may be very fibrotic and sparsely cellular and resemble a fibroma,[7] or it may contain myxomatous areas in which polyhedral spindle cells or stellate-shaped cells are surrounded by a mucinous matrix,[7] and thus, suggest a myxoma. If the lesion is large and extremely cellular, with numerous mitoses, it could be mistaken for a fibrosarcoma.[8,18] Similarly, in those instances in which it is locally infiltrative, especially into the overlying skin,[13] and incorrect diagnosis of malignancy might be entertained.

It is important for both the clinical dermatologist and the pathologist to be familiar with this lesion. Because of its frequent extension to joint and adjacent structures and its common recurrence following subtotal excision, removal should obviously be attempted only by a surgically qualified physician. In addition, the pathologist must be familiar with this lesion and its histologic spectrum to ensure precise diagnosis and avoid confusion with more ominous and aggressive neoplasms.

References

1. Holmes HS, Bovenmeyer DA: Cutaneous cartilaginous tumor. *Arch Dermatol* 112:839-840, 1976.
2. Boyes JH: *Burrell's Surgery of the Hand.* Philadelphia, JB Lippincott Co, 1970, chap 19.
3. King DT, Gurevitch AW, Hirose FM: Multiple cutaneous metastases of a scapular chondrosarcoma. *Arch Dermatol,* to be published.
4. Enzinger FM: Epithelioid sarcoma: A sarcoma simulating a granuloma or a carcinoma. *Cancer* 26:1029-1041, 1970.
5. Enzinger FM: Clear-cell sarcoma of tendons and aponeuroses: An analysis of 21 cases. *Cancer* 18:1163-1174, 1965.
6. Chung EB, Enzinger FM: Fibromas of tendon sheath. *Lab Invest* 36:333-334, 1977.
7. Phalen GS, McCormack LJ, Gazale WJ: Giant-cell tumor of tendon sheath (benign synovioma) in the hand: Evaluation of 56 cases. *Clin Orthop* 15:140-151, 1959.
8. Ackerman LV, Rosai J: *Surgical Pathology.* St Louis, CV Mosby Co, 1974, p 1084.
9. Allen AC: *The Skin: A Clinicopathological Treatise.* New York, Grune & Stratton Inc, 1967, pp 1026-1027.
10. Fort SL, Rodman OG: Erythema elevatum diutinum: Response to dapsone. *Arch Dermatol* 113:819-822, 1977.
11. Jones FE, Soule EH, Coventry MB: Fibrous xanthoma of synovium (giant-cell tumor of tendon sheath, pigmented nodular synovitis): A study of 118 cases. *J Bone Joint Surg Am* 51(pt A):76-86, 1969.
12. Kahn LB: Malignant giant cell tumor of the tendon sheath. *Arch Pathol* 95:203-208, 1973.
13. Wright CJE: Benign giant-cell synovioma: An investigation of 85 cases. *Br J Surg* 38:257-271, 1951.
14. Granowitz SP, D'Antonio JD, Mankin HL: The pathogenesis and long-term end results of pigmented villonodular synovitis. *Clin Orthop* 114:335-351, 1976.
15. Jaffe HL, Lichtenstein L, Sutro CJ: Pigmented villonodular synovitis, bursitis, and tenosynovitis: A discussion of the synovial and bursal equivalents of the tenosynovial lesion commonly denoted as xanthoma, xanthogranuloma, giant cell tumor or myeloplaxoma of the tendon sheath with some consideration of this tendon sheath lesion itself. *Arch Pathol* 31:731-765, 1941.
16. Eisenstein R: Giant-cell tumor of tendon sheath: Its histogenesis as studied by the electron microscope. *J Bone Joint Surg Am* 50(pt A):476-486, 1968.
17. Stout AP, Lattes R: *Tumors of the Soft Tissues.* Atlas of Tumor Pathology, Armed Forces Institute of Pathology, 1967, pt 1, pp 38-52.
18. Ackerman LV, del Regato JA: *Cancer: Diagnosis, Treatment, and Prognosis.* St Louis, CV Mosby Co, 1970, p 948.

Dapsone-Induced Jaundice

Stephen P. Stone, MD, Robert M. Goodwin, MD

Enthusiasm in the use of dapsone for acne conglobata and other severe acne has created an increase in the use of this drug by dermatologists. We describe three patients in whom jaundice developed during dapsone therapy of 3 to 36 weeks' duration. Jaundice was due to cholestasis in two cases and to hemolysis in the third. These significant side effects call for careful observation by the physician if dapsone is to be used with safety.

(*Arch Dermatol* 114:947, 1978)

Reports of successful treatment of severe acne with dapsone appear to have led to an increase in the use of this drug by dermatologists. In spite of a recent report of deaths associated with dapsone,[1,2] dermatologists seem to prefer its use. The most recent (third) edition of *AMA Drug Evaluations* describes adverse reactions produced by the sulfones as mild and "observed only rarely with therapeutic doses."[3] It is well to remember that the therapeutic doses referred to in this article range up to 100 mg daily, while most dermatologists prescribe as much as 200 or even 300 mg of dapsone daily for the treatment of severe acne.

We describe herein three patients who were recently treated with dapsone in doses that ranged from 50 to 200 mg daily and in whom icterus and abnormal liver functions developed. This represents 50% of the patients who have been so treated in our practice within an eight-month period.

Accepted for publication Oct 31, 1977.

From the Department of Medicine, Southern Illinois University School of Medicine, Springfield (Dr Stone) and the Dermatology Center, Ltd, Springfield, Ill (Drs Stone and Goodwin).

Reprint requests to Dermatology Center, Ltd, 630 N First St, Springfield, IL 62702 (Dr Stone).

REPORT OF CASES

Case 1.—An 18-year-old man was treated for severe cystic and conglobate acne with the usual topical preparations, including sulfurated lime solution (Vleminckx's solution), tretinoin (vitamin A acid), and benzoyl (Persa-Gel) peroxide gel, in addition to tetracycline hydrochloride (to 2 gm daily), erythromycin, minocycline (Vectrin) hydrochloride, and topical clindamycin (Cleocin) hydrochloride. After 1½ years of therapy, his condition had failed to show significant improvement; therefore, dapsone therapy (100 mg twice each day) was started. His condition improved somewhat, but initially we were unable to reduce the dose to 150 mg each day because of his skin's tendency to flare. Thirty-six weeks after dapsone therapy was started, he was first noted to be icteric, and results of liver function tests (Table) were found to be considerably abnormal. A consultant thought that the findings from the liver function tests were consistent with cholestatic jaundice and advised against liver biopsy. Dapsone therapy was immediately discontinued, and liver function values returned to normal within nine days.

Case 2.—A 16-year-old boy with acne conglobata was first treated with tetracycline and erythromycin, but after three months of little improvement, dapsone therapy was started. Improvement was prompt, but two weeks after institution of dapsone therapy, results of liver function tests were noted to be mildly elevated, and jaundice was apparent. Dapsone therapy was discontinued, and the results of liver function tests returned to normal.

Case 3.—A 20-year-old woman was treated since the age of 18 years for severe nodular and cystic acne. After minimal improvement with tetracycline, her skin continued to flare, and she was treated with erythromycin and subsequently minocycline, without significant improvement. Dapsone therapy (50 mg twice daily) was started, which was increased to 50 mg three times each day. Within three weeks of the institution of therapy, she was visibly jaundiced, and dapsone therapy was discontinued. Results of liver function tests, other than serum bilirubin and lactic dehydrogenase levels, were normal: a 2-gm drop in the hemoglobin level suggested that jaundice was probably hemolytic in origin.

Results of Liver Function Tests in Three Patients With Jaundice*

Patient	Age, yr/Sex	Onset of Jaundice After Dapsone Therapy, wk	Daily Dose of Dapsone, mg	Serum Level: Bilirubin, mg/100 ml	Serum Level: Alkaline Phosphatase, units/100 ml	Serum Level: LDH,† units	Serum Level: Cholesterol, mg/100 ml
1	18/M	36	200	7.6	206	481	121
2	16/M	2	200	2.8	141	363	180
3	20/F	3	75	3.7	55	351	135
Normal Value	...	...	...	<1	25-125	100-225	150-300

*Before dapsone therapy results of liver function tests were normal.

COMMENT

The abnormal results of the liver function tests, which were noted in the first two patients, were thought to be due to cholestasis: no liver biopsies were performed. The results of liver function tests were noted to return to normal usually within 10 to 14 days of cessation of dapsone therapy.

The most dangerous side effect of dapsone in patients without a glucose-6-phosphate dehydrogenase deficiency would appear to be agranulocytosis.[1,2] Hemolytic anemia and methemoglobinemia are relatively more common,[3,4] while polyneuropathy has received much recent attention.[5,6]

Although Millikan and Harrell[7] first recognized cholestatic hepatitis as a side effect of dapsone therapy, to our knowledge, little of this problem has been mentioned in the recent literature since their report.[8]

Our experience with dapsone suggests that jaundice, due to hemolysis, cholestatic hepatitis, or a combination of the two, may be more common than previously recognized. For this reason we would urge that liver function tests, as well as complete blood cell counts, should be routinely monitored in persons who are treated with dapsone. Although the abnormal results of liver function tests appear to be completely reversible, the occurrence of overt jaundice in a patient being treated for acne can be a frightening, or at best, a disconcerting experience, not only for the physician but for the patient and his family.

Nonproprietary Name and Trademark of Drug

Dapsone—*Avlosulfon.*

References

1. Ognibene AJ: Agranulocytosis due to sone. *Ann Intern Med* 72:521-524, 1970.
2. Catalano PM: Dapsone agranulocy *Arch Dermatol* 104:675, 1971.
3. AMA Department of Drugs: *AMA Evaluations*, ed 3. Littleton, Mass, Publ Sciences Group, Inc, 1977, p 819.
4. Shelley WB, Goldwein ML: High dapsone toxicity. *Br J Dermatol* 95:79-82,
5. Fredericks EJ, Kugelman TP, Kir Dapsone-induced motor polyneuropathy: plication of prolonged treatment of sub pustular dermatosis. *Arch Dermatol* 1 1160, 1976.
6. Gehlmann LK, Koller WC, Malkins Dapsone-induced neuropathy. *Arch D* 113:845-846, 1977.
7. Millikan LE, Harrell ER: Drug rea the sulfones. *Arch Dermatol* 102:220-224
8. Graham WR Jr: Adverse effects of *Int J Dermatol* 14:494-500, 1975.

Edited by Philip M. Catalano, MD*

Mucocutaneous Lymph Node Syndrome (Kawasaki's Disease)

A New Disease Remaking Its Debut

Guinter Kahn, MD

The mucocutaneous lymph node syndrome (MLNS) was first described in the English literature by Kawasaki in 1974.[1] Around 1961 he noticed a constellation of findings: (1) fever lasting more than seven days; (2) conjunctival injection; (3) erythema of the oropharynx; (4) indurated edema and erythema of the hands, followed by desquamation of the fingertips; (5) nonpurulent cervical lymphadenopathy of 1.5 cm or more in diameter; and (6) an erythematous polymorphous rash. He reported the cases of 50 patients in 1967[2] and later detailed the Japanese experience of more than 6,000 cases in the first English publication cited above. MLNS is now called Kawasaki's disease.

By the end of 1974, case reports began to appear from places other than Japan and in people other than Orientals.[3] By January 1975, the first case in the continental United States was documented.[4] By the end of 1975, reports came from Greece,[5] Canada,[6] Korea,[7] and many areas of the United States.[8,9] In 1976 and 1977 cases appeared in Australia[10] and West Germany.[11] It is now clear that MLNS crosses racial, geographic, social, economic, and seasonal barriers. Kawasaki disease was first mentioned in the dermatologic literature in 1977.[12]

The disease is of special importance in that 1% to 2% of children suddenly die of it, usually after the acute phase. MLNS has been described only in children less than 10 years of age, most commonly between 1 and 2 years, and without familial occurrence.

DIAGNOSIS

Signs and Symptoms

The principal symptoms and signs are present in over 90% of cases, except that the edematous hands and enlarged nodes occur perhaps just a bit less frequently (around 75%). A spiking-patterned fever of 38.3 to 40 C precedes other symptoms by one to four days and lasts from five to 20 days (most fevers last more than seven days). Erythema of the oropharynx is accompanied by dryness, fissuring of the lips, and protuberance of the papillae of the tongue (strawberry tongue). The exanthem may be morbilliform, scarlatiniform, or multiform with iris lesions. It begins on the palms and soles and spreads centripetally. A firm edema of the palms and soles develops and eventuates into the characteristic singular fingertip and toetip desquamation, which begins at the junction of the nails and skin. This exfoliation indicates the end of the acute phase and heralds the spread of desquamation over the remainder of the body. Large cervical nodes (often single) develop. These may be unilateral and are nonpurulent and 1.5 cm or larger in diameter. Occasional symptoms (5% to 40%) include diarrhea, vomiting, arthralgia, arthritis, mild hepatitis with jaundice, and mild aseptic meningitis.

Laboratory Findings

Laboratory findings are characteristic but not diagnostic of MLNS. Elevated are the WBC count (a polymorphonuclear leukocytosis), platelet count, and C-reactive protein level. IgE has been reported as elevated,[13] although this has not been a consistent finding.[14,15] Urine samples are sterile, but many demonstrate WBCs and small amounts of protein. Urethral inflammation appears to be the source of these changes, and small meatal ulcers have been reported.[15] Important normal laboratory findings

*Department of Dermatology, University of Miami, Miami, Fla.

include cultures of urine, stool, CSF, and throat scrapings. The antibody titers for streptococci (antistreptolysin O, antistreptohyaluronidase, streptozyme, DNase B) are also normal.

Electrocardiographic changes were present in as many as 70% of cases.[16] Coronary arteriograms revealed abnormalities in 12 of 14 cases, and seven showed aneurysms of the coronary vessels.[17]

Differential Diagnosis

Differential diagnosis includes a number of childhood eruptions:

Scarlet Fever.—Scarlet fever exhibits elevated titers for streptococcal products and responds to antibiotic therapy. The exanthem here is finely papular and begins in the groin, axillae, and around the neck. Spread is then to the trunk and extremities. If the face is involved, perioral pallor is evident. The eruption can be blanched on diascopy, except in flexural creases (Pastia's lines). Desquamation may peel in sheets, especially from the palms and soles.

Erythema Multiforme.—Erythema multiforme (and Steven-Johnson syndrome) has characteristic cutaneous changes in most cases, including bullous lesions and purulent mucosal exudate. Although iris lesions can occur in MLNS, they are less frequent and are not yet described as bullous or conforming to classic "target" lesions of erythema multiforme. Moreover, the typical fingertip peeling is unique to MLNS and is a very useful diagnostic sign, and contrasts with the substantial exfoliation of Stevens-Johnson syndrome.

Measles.—Atypical measles is generally seen in older children (aged more than 8 years), in whom MLNS is rare. The eruption ranges from that of an aborted minimal, otherwise typical measles to petechiae, urticaria, and vesicles. These latter and more aberrant changes usually begin on the feet and extend upward, and generally are more severe on the extremities. Most often they are accompanied by high fever and toxic conditions. Again, the desquamation is a key differential point.

Juvenile Rheumatoid Arthritis.—Juvenile rheumatoid arthritis has a more evanescent rash that is not nearly so impressive as in MLNS. The eruption, which may be recurrent, is characterized by pink, maculopapular lesions that range from a few millimeters to 1 cm in diameter. Central pallor may be present in larger lesions, and coalescence may occur. The trunk and proximal extremities are chiefly involved, and an isomorphic response may develop.[18] Although fusiform digital swelling may occur in juvenile rheumatoid arthritis, the firm induration and magenta discoloration of the palms and soles are absent.

Systemic Lupus Erythematosus.—Systemic lupus erythematosus exhibits antinuclear antibodies, leukopenia, and will often show evidence of even more multisystem involvement than MLNS.

Acrodynia and Other Conditions.—Acrodynia (pink disease) exhibits many features of autonomic disturbance related to mercury toxicity. Pruritus is usually a major feature, and symptoms of polyneuritis occur. Other conditions that may be confused with MLNS include herpetic stomatitis, viral exanthems, drug reactions, staphylococcal scalded-skin syndrome (and other bacterial septicemias), and rickettsial diseases.

Mortality

Although initially considered nonfatal, further reports began to substantiate a mortality of 1% to 2%. Death was most common in boys less than 1 year old, and usually occurred in the third or fourth week of illness. Deaths also occurred during convalescence. Autopsy of the infants has shown arteritis as the dominant histologic change.[19] Coronary arteritis may lead to coronary aneurysm. Interestingly, these changes are the same as those seen in infantile periarteritis nodosa (IPA).[20-23] The MLNS Research Committee (under the Japanese Ministry of Health) by 1973 had evaluated more than 3,000 cases, 67 of which were fatal.[19] The coronary arteries were affected with an arteritis no different from that found in IPA. Kawasaki correlated death with a prolonged acute phase in which the temperature was elevated more than the average length of time (ten days). In addition, the sedimentation rate was greatly elevated.[24]

MLNS: WHAT IS IT?

The similarity of IPA and MLNS in both clinical and pathological changes is more than superficial. In 44 cases of IPA, Tanaka was able to demonstrate retrospectively that 66% of incompletely recorded cases included the major symptoms and signs of MLNS.[19-23]

Heretofore, IPA has been an enigmatic disease. Diagnosis generally had been made retrospectively, and most authors had experience with but few cases. Rarely is the diagnosis considered before death.[25-27] Tanaka's thorough review confirmed the inability to diagnose IPA in vivo. A series at Mayo Clinic described children aged less than 1 year; the longest survival (1973) was nine months. Complete remission in an older boy has been achieved with prednisone and azathioprine.[28]

Interest stirred by an old-new disease (IPA-MLNS) yielded two unexpected details that further substantiate their similarity: (1) IgE levels are elevated during the acute phase of both diseases; and (2) aneurysms associated with both may regress gradually or disappear.[18,29] Both findings thus have been reported independently in both conditions since 1974, which strengthens the concept of the two diseases being overlapping, if not identical.

Additionally, IPA must not be confused with adult periarteritis nodosa (APA). The two conditions differ in their clinical presentations, pathological manifestations, and laboratory findings. Decreased complement levels, abnormal muscle biopsy specimens, and elevated Australia antigen levels, all of which are often found in APA.[26-30] Moreover, the principal symptoms of IPA (or of MLNS) are not found in APA. More complete comparative studies are now underway.[19]

The cause of MLNS has not been forthcoming, in spite of the organized and diligent search of the Japanese. A clue that the disease might be infectious is that rickettsia-like bodies have been demonstrated in the involved skin and lymph nodes[31] by electron microscopy and yolk-sac culture.[32] Unfortunately, results of other investigations have not confirmed these findings.[33] Also, the disease does not respond to antibiotic therapy.

Another investigator pointed out the similarity of MLNS to acrodynia (pink disease) and claimed that both could be a manifestation of mercury poisoning. In response to an editorial,[34] Kawasaki pointed out that acrodynia is rare in Japan because pediatric mercury-containing products (teething powders and lotions) are not used and that mercury levels attained from vaccines, contraceptive creams, and contaminated foods are minimal.[35] Notwithstanding is the Japanese mercury-fish-poisoning epidemic that killed 115 people by 1975.[36] After Kawasaki charted the clinical difference between MLNS and pink disease, the only common denominator found was the red edematous distal extremities.

WHERE DO WE GO FROM HERE?

Clinicians and research investigators are now searching for the solutions to this problem. Is the IgE elevation significant? MLNS is the only acute febrile disease in which the increase in the serum IgE level correlates with the acute phase.[13] Are only individuals who are genetically programmed for a brisk IgE response affected by an MLNS-related immunogen? Should the thrombocytosis be treated?

No uniformly successful treatment has been reported. Aspirin has not been effective,[24] and the effects of corticosteroids have not been impressive. A case has been reported in which depressed complement levels (not a common finding) rose during therapy.[30] The patient survived nine months after the acute phase of MLNS in spite of coronary and brachial aneurysms.

With increased awareness, reports are beginning to appear in the dermatologic literature.[12] Let us hope that the needed answers are not far behind.

As a further note, the Center for Disease Control, Atlanta, has begun a registry for cases of MLNS in the United States. Physicians aware of cases are requested to inform them of such.

References

1. Kawasaki T, Kosaki F, Okawa S, et al: A new infantile acute febrile mucocutaneous lymph node syndrome (MLNS) prevailing in Japan. *Pediatrics* 54:271-276, 1974.
2. Kawasaki T: MCLS: Clinical observations of 50 cases. *Jpn J Allerg* 16:178, 1967.
3. Melish ME, Hicks RM, Larson E: Mucocutaneous lymph node syndrome (MLNS) in the US, abstracted. *Pediatr Res* 8:427, 1974.
4. Nix WL, Clark E, Montgomery JR, et al: A case of mucocutaneous lymph node syndrome in the continental United States?, abstracted. *Clin Res* 23:70, 1975.
5. Valaes T: Mucocutaneous lymph node syndrome (MLNS) in Athens, Greece. *Pediatrics* 55:295, 1975.
6. Russell AS, Zaragoza AJ, Shea R: Mucocutaneous lymph node syndrome in Canada. *Can Med Assoc J* 112:1210-1211, 1975.
7. Kim J, Yeo Y, Lee DB: Mucocutaneous lymph node syndrome: Clinical observation of eight cases. *Korea New Med J* 16:1157, 1973.
8. Brown JS, Bulmeier GJ, Cox F, et al: Mucocutaneous lymph node syndrome in the continental US. *J Pediatr* 88:81-83, 1976.
9. Dennis MK, Ayoub EM, Graham T, et al: Mucocutaneous lymph node syndrome in Florida. *J Fla Med Assoc* 64:21-26, 1977.
10. Carter RF, Haynes ME, Morton J: Rickettsia-like bodies and splenitis in Kawasaki disease. *Lancet* 2:1254-1255, 1976.
11. Stephenson SR: Kawasaki disease in Europe. *Lancet* 1:373-374, 1977.
12. Odom RB, Olson EG: Mucocutaneous lymph node syndrome. *Arch Dermatol* 113:339-340, 1977.
13. Kusakawa S, Heiner DC: Elevated levels of immunoglobulin E in the acute febrile mucocutaneous lymph node syndrome. *Pediatr Res* 10:108-111, 1976.
14. Laver B, Bruhn F, Todd J, et al: Mucocutaneous lymph node syndrome in Denver: *Am J Dis Child* 130:610-612, 1976.
15. Melish M, Hicks R, Larson E: MLNS in the United States. *Am J Dis Child* 130:599-607, 1976.
16. Asai T, Kiguchi H, Nagai Y, et al: Analysis of cardiac involvement in 29 cases with MCLS. *Jpn J Pediatr* 26:824, 1973.
17. Kato H, Koike S, Yamanoto M, et al: Coronary aneurysm in infants and young children with acute febrile mucocutaneous lymph node syndrome. *J Pediatr* 86:892-898, 1975.
18. Vaughan V, McKay R (eds): *Nelson Textbook of Pediatrics*, ed 10. Philadelphia, WB Saunders Co, 1975, pp 522-523.
19. Tanaka N, Sekimoto K, Naoe S: Kawasaki disease: Relationship with infantile periarteritis nodosa. *Arch Pathol Lab Med* 100:81-86, 1976.
20. Benyo RB: Periarteritis nodosa in infancy. *Am J Dis Child* 116:539-544, 1968.
21. Crocker DW, Sobin S, Thomas WC: Aneurysms of the coronary arteries: Report of three cases in infants and review of the literature. *Am J Pathol* 33:819-843, 1957.
22. Monro-Faure H: Necrotizing arteritis of the coronary vessels in infancy. Pediatrics 23:914-926, 1959.
23. Roberts FB, Fetterman GH: Periarteritis nodosa in infancy. *J Pediatr* 63:519-529, 1953.
24. Kawasaki T, quoted by Melish ME, Hicks RE, Larson EJ: Mucocutaneous lymph node syndrome in the United States. *Am J Dis Child* 130:605, 1976.
25. Fetterman GH, Hashida Y: Mucocutaneous lymph node syndrome (MLNS): A disease widespread in Japan which demands our attention. *Pediatrics* 54:268-270, 1974.
26. Gillespie DN, Burke EC, Holley KE: Periarteritis nodosa in infancy: A diagnostic enigma. *Mayo Clin Proc* 48:773-775, 1973.
27. Chamberlain JL III, Perry LW: Infantile periarteritis nodosa with coronary and brachial aneurysms: A case diagnosed during life. *J Pediatr* 78:1039-1042, 1971.
28. Melam H, Patterson R: Periarteritis nodosa: A remission achieved with combined prednisone and azathioprine therapy. *Am J Dis Child* 121:424-427, 1971.
29. Glanz S, Bittner SJ, Berman MA et al: Regression of coronary-artery aneurysms in infantile polyarteritis nodosa. *N Engl J Med* 284:939-940, 1976.
30. Krous HF, Clausen CR, Ray CG: Elevated immunoglobulin E in infantile polyarteritis nodosa. *J Pediatr* 84:841-845, 1974.
31. Hamashima Y, Kishi K, Tasaka K: Rickettsia-like bodies in infantile acute febrile mucocutaneous lymph node syndrome. *Lancet* 2:42, 1973.
32. Hamashima Y, Kishi K, Tasaka K: Discovery and isolation of rickettsia-like bodies from MCLS patients. *Prog Med* 87:189, 1973.
33. Shishido A, Adachi Y: in *Progress of Research on Kawasaki Disease*. (MCLS), Kawasaki T, Kusskawa S, Shigematsu I. Tokyo, 1976.
34. Cheek DB: Comment on MCLS: Could it be heavy metal poisoning? *Pediatrics* 56:335-336, 1975.
35. Kawasaki T: Dr. Kawasaki replies. *Pediatrics* 56:336, 1975.
36. Mercury in the environment, editorial. *Lancet* 2:344, 1977.

P. acnes come out in the Wash

A recent research study showed Desquam-X® Wash (4% BENZOYL PEROXIDE) can reduce P. acnes 87.7% in 1 day*

Purpose of the *in vivo* study was to generate data showing the reduction of anaerobic facial bacteria (P. acnes).

Desquam-X Wash was applied b.i.d. No other acne therapy was administered.

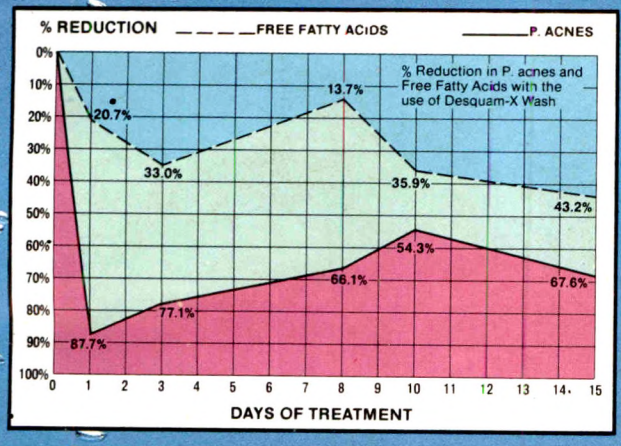

The first benzoyl peroxide cleanser, available only on your Rx.

Desquam-X® Wash (4% Benzoyl Peroxide) THERAPEUTIC CLEANSER

NDC 0072-6900-05

CONTENTS: DESQUAM-X® WASH contains 4% benzoyl peroxide, sodium octoxynol-3-sulfonate, water, sodium dioctyl sulfo-succinate, sodium lauryl sulfoacetate, magnesium aluminum silicate, methocel A4M, EDTA.

INDICATIONS: May be used topically alone for mild to moderate acne vulgaris. In severe, complicated acne Desquam-X Wash may be used as an adjunct to therapeutic regimens which might include antibiotics, retinoic acid products, and/or sulfur and salicylic acid containing preparations.

ACTION: Provides drying and desquamation desirable in the topical treatment of acne. Desquam-X Wash has demonstrated antibacterial activity against Propionibacterium acnes. Desquam-X Wash has also been shown to reduce the concentration of free fatty acids in the sebum.

DIRECTIONS FOR USE: Wash vigorously with Desquam-X Wash once or twice daily, avoiding contact with eyes or mucous membranes. Drying and peeling may be modified by adjusting the dosage schedule.

CONTRAINDICATIONS: Not to be used in patients known to be sensitive to benzoyl peroxide or other ingredients.

PRECAUTIONS: Avoid contact with eyes and mucous membranes. To prevent bleaching, avoid contact with hair. Keep this and all drugs out of the reach of children. For external use only.

NOTE: May bleach colored fabrics. Store below 77°F.

HOW SUPPLIED: Plastic bottles 5 oz. (141.8 g.)

CAUTION: Federal law prohibits dispensing without a prescription.

*Data on file, Westwood Pharmaceuticals.

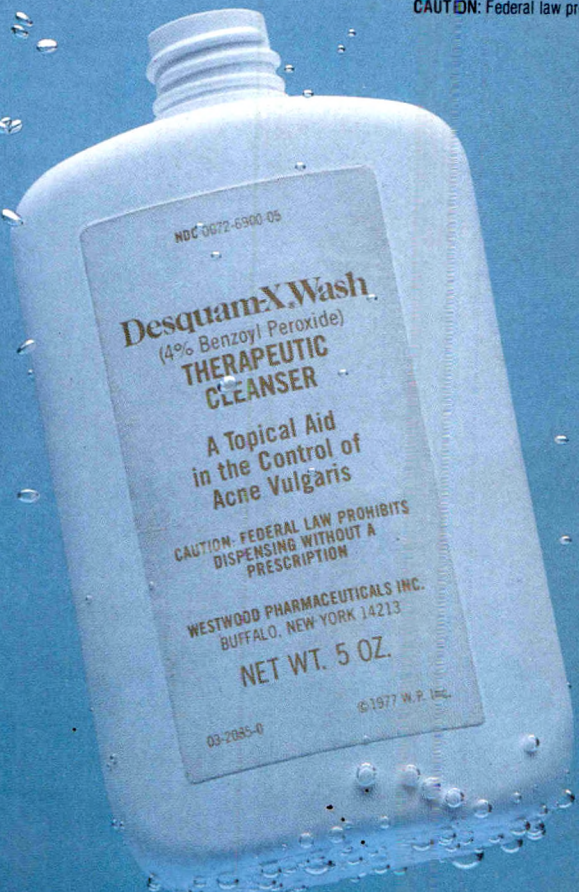

WESTWOOD
PHARMACEUTICALS INC.
Buffalo, New York 14213

©1978, W.P. Inc.

New Desquam-X®

(5 OR 10% BENZOYL PEROXIDE, 6% LAURETH-4)

water base gel is not watered down.

Clinically as effective as the alcohol formulation and even more cosmetically acceptable than before.

One study shows Desquam-X10®
(10% BENZOYL PEROXIDE, 6% LAURETH-4)
reduced P. acnes 99.9% in 3 days*

Purpose of the *in vivo* study was to generate data showing the reduction of anaerobic facial bacteria (P. acnes).

Desquam-X 10 was applied b.i.d. No other acne therapy was administered.

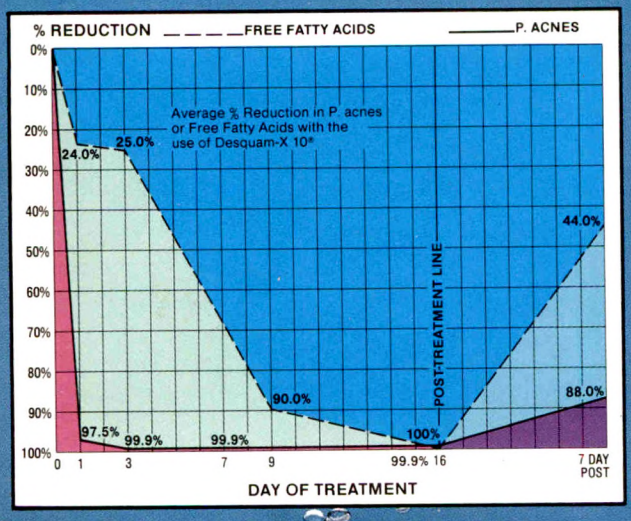

- **Large new 3 oz. tube for patient economy and convenience**
- **Eliminates alcohol sting**

Desquam-X5®	Desquam-X10®
NDC 0072—6621-01—1.5 oz.	NDC 0072—6721-01—1.5 oz.
NDC 0072—6621-03—3 oz.	NDC 0072—6721-03—3 oz.

CONTENTS: Desquam-X5 contains 5% Benzoyl Peroxide, 6% laureth-4, carbomer 940, di-isopropanolamine, disodium edetate and water.

Desquam-X10 contains 10% Benzoyl Peroxide, 6% laureth-4, carbomer 940, di-isopropanolamine, disodium edetate and water.

INDICATIONS: May be used topically alone for mild to moderate acne vulgaris and as an adjunct in therapeutic regimens for severe, complicated acne which might include systemic antibiotics, retinoic acid products and/or sulfur and salicylic acid containing preparations.

ACTION: Provides the desirable drying and desquamation needed in the topical treatment of acne. Desquam-X has been demonstrated to have anti-bacterial effects, especially against Propionbacterium acnes.

DIRECTIONS FOR USE: After washing as instructed, rub Desquam-X into affected areas twice daily. In fair skinned individuals or under excessively dry atmospheric conditions it is suggested that therapy be initiated with one application daily.

The desired degree of drying and peeling can be obtained by modification of the dosage schedule.

CONTRAINDICATIONS: Not to be used in patients known to be sensitive to any ingredient of Desquam-X.

PRECAUTIONS: Avoid contact with eyes and mucous membranes. For external use only. Keep this and all drugs out of the reach of children.

Store below 75°F.

NOTE: May bleach colored fabrics.

HOW SUPPLIED: Plastic tubes 1.5 oz. (42.5g); 3 oz. (85 g).

CAUTION: Federal law prohibits dispensing without prescription.

*Data on file, Westwood Pharmaceuticals.



WESTWOOD
PHARMACEUTICALS INC.
Buffalo, New York 14213

©1978, W.P. Inc.

Glaucoma Induced by Application of Corticosteroids to the Periorbital Region

Niels V. Nielsen, MD, Per N. Sørensen, MD

Reports of ocular complications from local and systemic corticosteroid therapy have been published[1]; two reports[2,3] document glaucoma provoked from the application of corticosteroid ointment to the periorbital region. This serious complication, which develops insidiously, has been noted in a recent article in the ARCHIVES.[4] We report two more such cases.

Report of Cases

CASE 1.—A 68-year-old woman had her intraocular pressure (IOP) routinely measured in 1972 because of mild diabetes mellitus. Her IOP was 30 mm Hg in the right and 32 mm Hg in the left eye by Goldmann's applanation tonometry. For two years she had applied prednisolone ointment, 5 mg/g of ointment on both eyelids several times daily for a periorbital eczema. She had no history of glaucoma, and her IOP in 1969 was 20 mm Hg in the right and 18 mm Hg in the left eye. The corrected visual acuity was 20/20 in both eyes. The visual field and results of slit-lamp examination and gonioscopy were normal. The optic discs had no glaucomatous changes. The corticosteroid therapy was discontinued, and in 14 days the IOP fell to 26 mm Hg on both sides. After three months of treatment for the glaucoma, the pressure in both eyes was corrected. Repeated examinations during the next four years showed normal ocular tension without further therapy, and the visual field and optic discs were normal.

CASE 2.—An 80-year-old woman was admitted to the hospital in June 1976 because of bilateral decreased visual acuity. For three years the patient had treated a bilateral periorbital dermatosis with triamcinolone acetonide ointment (0.1%) applied three times daily. The IOP was elevated to 46 mm Hg in the right and 32 mm Hg in the left eye, as measured by Goldmann's applanation tonometry. The corrected visual acuity was less than 20/200 on the right and 20/40 on the left side. Perimetry disclosed a distinct nasal defect in the visual field of the right eye (Figure). Results of slit-lamp examination, including gonioscopy, were normal. The right optic disc was moderately pathologically excavated. On both sides the periorbital skin showed severe atrophy from the corticosteroid therapy. Treatment with corticosteroid ointment was discontinued, and three months later the IOP was 16 mm Hg in both eyes. Therapy for the glaucoma was administered only for the first 14 days. However, the decreased visual acuity and the visual field defect persisted.

Comment

It is generally accepted that corticosteroids applied to the conjunctiva may give rise to glaucoma. In our patients, the corticosteroid ointment

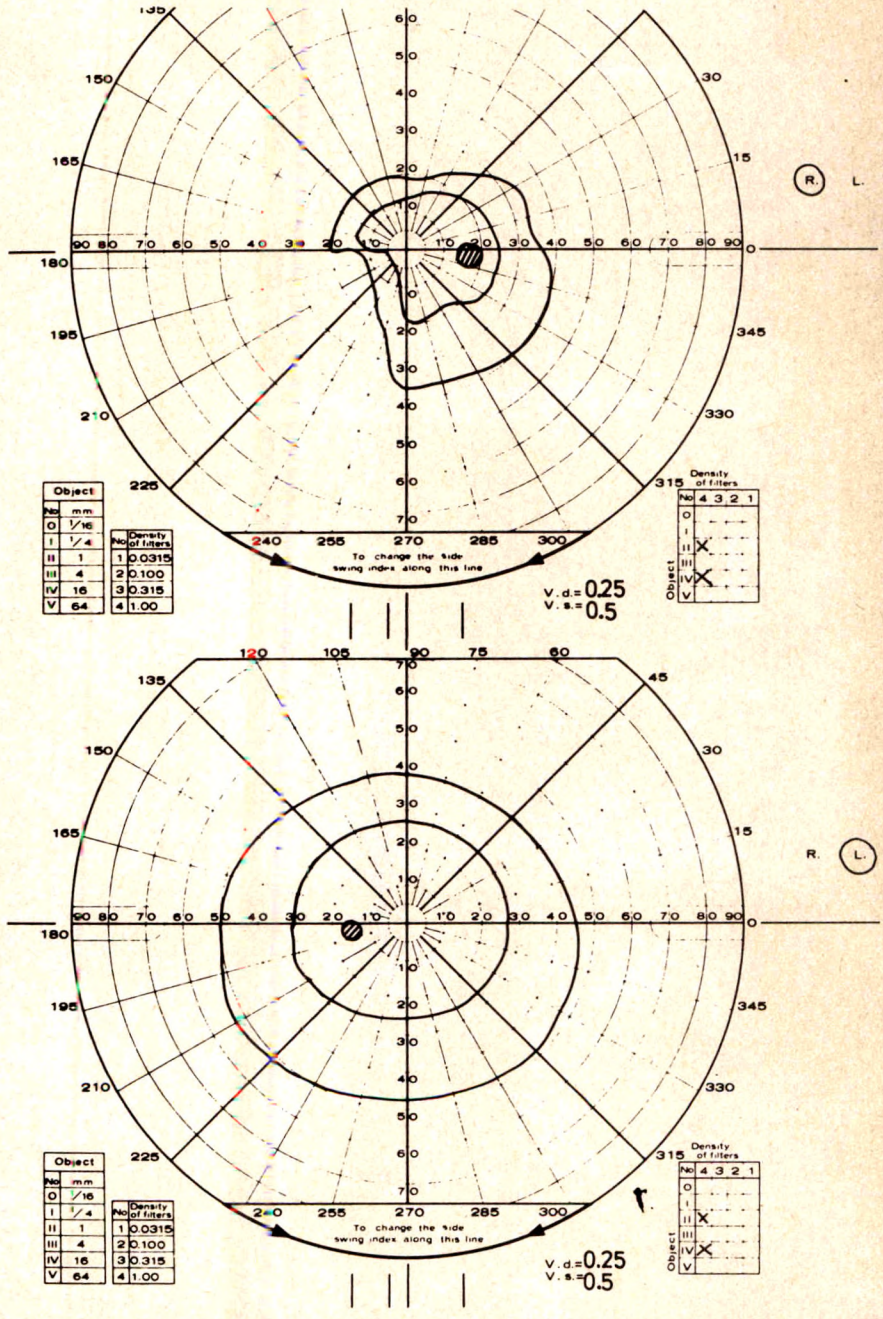

Visual field of patient in case 2. On left side, great nasal defect and concentric restriction have developed. Top half of Figure represents right eye and bottom half, left eye. Illumination is 31.5 apostilb. Object 1 and 16 sq mm, intensity is 1,000 apostilb.

From the Department of Ophthalmology, Central Hospital, Nykøbing Falster, Denmark.

Reprint requests to Department of Ophthalmology, Central Hospital, 4800 Nykøbing Falster, Denmark (Dr Nielsen).

had been applied extraocularly. The most probable explanation for the development of the ocular hypertension seems to be a direct conjunctival contamination, but a penetration through the lids cannot be excluded.[5] Despite the fact that the thin and richly vascularized facial skin is known to absorb corticosteroid ointment to an extremely high degree, a systemic adverse effect on the eyes appears to be less likely than topical adverse influences.[1] Nevertheless, Armaly[6] has observed a rise of IOP in the opposite eye when corticosteroid drops have been applied monocularly. However, this finding has not been observed by others. From the information presented, it seems reasonable to suggest that any prolonged use of topical corticosteroids in the periorbital region should be instituted with the cooperation of an ophthalmologist.

References

1. Grant WM: *Corticosteroids: Toxicology of the Eye.* Springfield, Ill, Charles C Thomas Publisher, 1974, pp 320-327.
2. Hales RH: Glaucoma induced by careless use of steroids. *J Pediatr Ophthalmol* 10:206-207, 1973.
3. Brubaker R, Halpin J: Open-angle glaucoma associated with topical administration of flurandrenolide to the eye. *Mayo Clin Proc* 50:322-326, 1975.
4. Howell JB: Eye diseases induced by topically applied steroids: The thin edge of the wedge. *Arch Dermatol* 112:1529-1530, 1976.
5. Duke Elder S, Wybar KC: *The Anatomy of the Visual System: System of Ophthalmology.* London, Henry Kimpton Medical Publisher & Bookseller, 1961, vol 2, pp 527-533.
6. Armaly MF: Dexamethasone ocular hypertension in the clinically normal eye. *Arch Ophthalmol* 75:766-782, 1966.

Aggressive Chondroid Syringoma

Report of a Case in an Unusual Location and With Local Recurrence

Jan B. C. Botha, MB, ChB, MMed(Anat Path), FF Path (SA), Leonard B. Kahn, MB, BCh, MMed(Path), MRC Path

Chondroid syringoma is a cutaneous mixed tumor of salivary-gland-type usually located in the head and neck region. It usually has a prominent chondroid component. Hirsch and Helwig[1] and Stout and Gorman[2] have reported the largest series of cases, 188 and 134 respectively. Aggressive or frankly malignant behavior is rare and has been observed in only five instances.[1,3-6] The presence of satellite nodules adjacent to the main mass and of cellular atypism and mitotic activity has been used as criterion of malignancy.

Report of a Case

A 15-year-old girl had a nodule in her left external auditory meatus that was excised but recurred three years later. She is now 21 years old and has no evidence of residual disease. Histologically, both the original lesion and the recurrence showed features of a chondroid syringoma (Fig 1, left and right), except for a moderate degree of pleomorphism and occasional mitoses (Fig 2, left and right). Several satellite tumor nodules were present adjacent to the main nodule in the primary lesion. The cytoplasm of many of the large cells had a physaliferous appearance (Fig 2, left and right).

Comment

The chondroid syringoma in our case was not typical, in that it recurred three years after excision and showed focal areas of severe atypism and some mitotic activity. Three of the five previously reported malignant lesions metastasized, and both the primary lesion and metastases showed atypism and mitotic activity.[4-6] The interval from surgical removal to local recurrence or metastatic spread has varied from less than 1 to 4 years. All six cases of chondroid syringoma that exhibited aggressive behavior occurred in female patients, whereas the benign variant is more frequent in male patients.

The rarity of this lesion and its chondroid or chordomatous appearance may result in misdiagnosis. The location of the lesion in our patient, as well as the presence of cells resembling physaliferous cells, raised the possibility of a chordoma extending from the basisphenoid region. However, there was no clinical evidence of a chordoma and the ductal elements in the tumor were incompat-

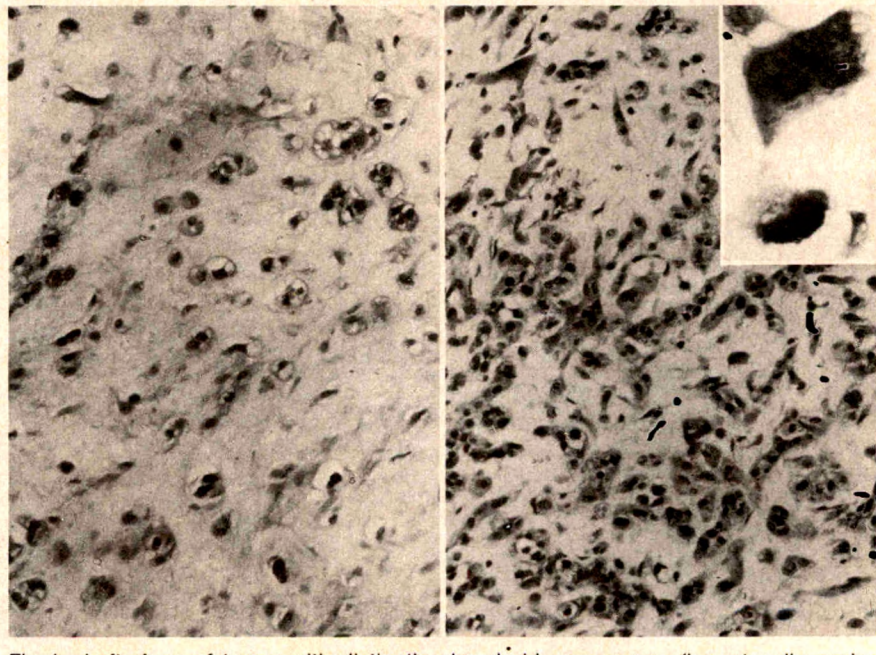

Fig 1.—Left, Area of tumor with distinctly chondroid appearance (hematoxylin-eosin, original magnification ×100). Right, Area of tumor composed of cells arranged in cords and poorly formed tubules. Inset, Detail of cellular atypia and single mitotic figure (hematoxylin-eosin, original magnification ×100; inset, original magnification ×400).

Accepted for publication Aug 10, 1977.

From the Department of Pathology, University of Cape Town (South Africa) Medical School. Dr Kahn is now with the Department of Pathology, University of North Carolina School of Medicine, Chapel Hill.

Reprints not available.

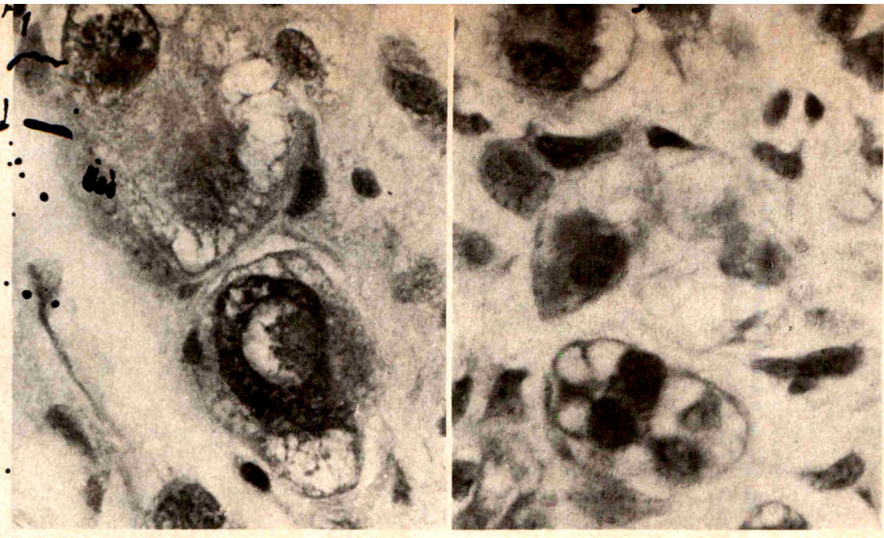

Fig 2.—Left, Cellular atypia. Right, physaliferous cell types (hematoxylin-eosin, original magnification ×400).

ible with this diagnosis. Physaliferous cells are not confined to chordomas, but have been described in other conditions, such as colonic adenocarcinomas.[7]

It is possible that the lesion originated from the ceruminous glands of the external auditory canal. These glands are modified sweat glands, and the tumors arising therefrom, so-called ceruminomas, are usually benign and have a distinct glandular pattern. Less commonly, they resemble the mixed tumors of sweat gland origin found elsewhere. The rare malignant ceruminomas generally take the form of adenoid cystic carcinomas and not malignant mixed tumors.[8]

References

1. Hirsch P, Helwig EB: Chondroid syringoma: Mixed tumor of skin, salivary gland type. *Arch Dermatol* 84:177-189, 1961.
2. Stout AP, Gorman JG: Mixed tumors of the skin of the salivary gland type. *Cancer* 12:537-543, 1959.
3. Sharvill DE: Mixed salivary-type tumour of the skin with malignant recurrence. *Br J Dermatol* 74:103-104, 1962.
4. Rosborough D: Malignant mixed tumours of the skin. *Br J Surg* 50:697-699, 1963.
5. Matz LR, McCully DJ, Stokes BAR: Metastasizing chondroid syringoma. *Pathol* 1:77-81, 1969.
6. Hilton JMN, Blackwell JB: Metastasizing chondroid syringoma. *J Pathol* 109:167-170, 1972.
7. Hellstrom HR, Fisher ER: Physaliferous variant of carcinoma of colon. *Cancer* 17:259-263, 1964.
8. Cankar V, Crowley H: Tumors of ceruminous glands. *Cancer* 17:67-75, 1964.

Recurrent Aphthous Stomatitis

An Immunofluorescence Study

Susanne Ullman, MD, Robert J. Gorlin, DDS

Cell-mediated immunity to oral mucosa has been demonstrated in patients with recurrent aphthous stomatitis (RAS).[1] Lymphocytes from patients with RAS are toxic to normal oral epithelial cells in tissue culture.[2,3] Humoral antibodies to oral mucosa have been demonstrated in the serum as well as fixed in vivo in the cytoplasm of oral epithelial cells.[4,5]

In this study, aphthae from patients with RAS were examined for deposits of immunoglobulins and complement by immunofluorescence microscopy.

From the Division of Oral Pathology (Dr Gorlin) and the Department of Dermatology, University Hospitals, University of Minnesota, Minneapolis.

Reprint requests to Division of Oral Pathology, University of Minnesota, Minneapolis, MN 55455 (Dr Gorlin).

Materials and Methods

Biopsy specimens of aphthae were obtained from ten consecutive patients with RAS. Eight patients had the simple form of RAS that heals without leaving scars, while two had the cicatricial form of RAS. Biopsy specimens from uninvolved oral mucosa were obtained from four patients.

The biopsy specimens were examined for deposits of IgG, IgM, IgA, complement C3, and fibrinogen by direct immunofluorescence microscopy.

Fig 1.—Deposits of complement C3 in vessel wall in aphtha (original magnification ×192).

Fig 2.—Granular deposits of complement C3 (arrows) in subepithelial zone of aphtha (original magnification ×192).

Immunoglobulins, Complement C3, and Fibrinogen in Recurrent Aphthous Stomatitis*

Type	No. of Patients	Vessel Walls C3	Vessel Walls IgM	Vessel Walls IgA	Vessel Walls F	Subepithelial Zone C3	Subepithelial Zone F
Simple	8	8	4	2	2	4	1
Cicatricial	2	2	2	0	2	1	0
Total	10	10	6	2	4	5	1

*F indicates fibrinogen.

Results

As stated in the Table, granular deposits of C3 were found in the vessel walls of all ten aphthae (Fig 1) and in the subepithelial zone of five (Fig 2). Deposits of IgM and IgA were seen in the vessel walls of six and two aphthae, respectively. Deposits of IgG were not seen.

No deposits were noted in three of the biopsy specimens from uninvolved oral mucosa. One specimen that was taken adjacent to an aphthous lesion showed small amounts of IgM in the vessel walls.

Comment

Histopathologic studies of aphthous lesions have shown vasculitis with perivascular mononuclear infiltrates, endothelial edema, and sometimes thrombosis.[5] The demonstration of immunoglobulins and complement C3 in the vessel walls suggests that the vasculitis may be caused by deposition of immune complexes.

This investigation was supported by a grant from the Diabetes Research Fund of the American Diabetes Association, Minnesota Affiliate, and Public Health Service program grant DE-1770 in Oral Pathology.

References

1. Lehner T: Stimulation of lymphocyte transformation by tissue homogenates in recurrent oral ulceration. *Immunology* 13:159-166, 1967.
2. Dolby AE: Recurrent aphthous ulceration. *Immunology* 17:709-714, 1969.
3. Rogers RS III, Sams WM Jr, Shorter RG: Lymphocytotoxicity in recurrent aphthous stomatitis: Lymphocytotoxicity for oral epithelial cells in recurrent aphthous stomatitis and Behçet syndrome. *Arch Dermatol* 109:361-363, 1974.
4. Donatsky O, Dabelsteen E: An immunofluorescence study on the humoral immunity to adult human oral mucosa in recurrent aphthous stomatitis. *Acta Allergol* 29:308-318, 1974.
5. Lehner T: Pathology of recurrent oral ulceration and oral ulceration in Behçet's syndrome. Light, electron and fluorescence microscopy. *J Pathol* 97:481-494, 1969.

Usual Scabies With Nail Infestation

Takao Saruta, MD, Yoshio Nakamizo, MD

In recent years, the prevalence of scabies has greatly increased and unusual forms of the disease have been observed.[1,2] We present a case of usual scabies with nail infestation. This diagnosis was made by detection of *Sarcoptes scabiei* from the scales of the involved nail and through histological studies.

Report of a Case

A 51-year-old woman was seen in January 1976 with a papulovesicular eruption that was accompanied by scaling and scratch marks on the axillae, the lower portion of the abdomen, and the buttocks. The dorsal aspect of the foot showed thick scaling. The nail of the left first toe was elevated by large accumulations of hyperkeratotic debris (Fig 1). Innumerable mites *(Sarcoptes scabies)* and eggs were detected from scales of the nail (Fig 2). Furthermore, histological findings from the mass, which was stripped of the hyperkeratotic scale of the nail, showed numerous mites and eggs to be present in the horny layer (Fig 3).

There was no history of scabies in her family. Physical examination showed that she had diabetes mellitus, hypertension, anemia (RBC, 236 × 10^4; hemoglobin, 8.5 g/dl), leukocytosis, hypoalbuminemia (2.9 g/dl), rheumatoid arthritis, and pyelonephritis. After three months of treatment with crotamiton, the scales of the nail and other eruptions disappeared.

Fig 1.—Clinical aspects of nail infestation of scabies. Nail of toe was elevated by large accumulations of hyperkeratotic debris.

Fig 2.—Mite from nail (original magnification ×400).

Comment

Nail changes have been described in Norwegian scabies by several authors. Ormsby and Montgomery[3] observed distortion and destruction of the nail, and Kurtin and Leider[4] and Haydon and Caplan[5] reported hyperkeratotic changes. Zaias[6] found mites in the nails of patients with Norwegian scabies that eventually resulted in nail-plate dystrophy.

In usual scabies, however, nails are not ordinarily involved and, as far as we know, there is no report of findings of mites in the affected nail. Our

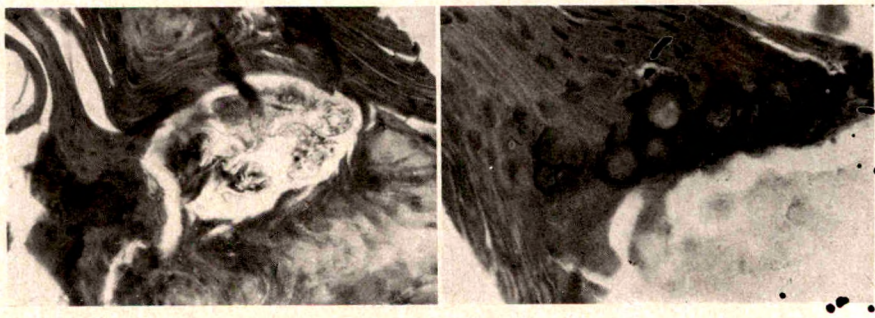

Fig 3.—Left, Mite and eggs (right) in the horny layer (hematoxylin-eosin, original magnification ×400).

From the Department of Dermatology, The Institute of Balneotherapeutics, Kyushu University, Beppu, Japan.

Reprint requests to Department of Dermatology, Institute of Balneotherapeutics, Kyushu University, Beppu, Japan (Dr Saruta).

case seems to represent another unusual manifestation of usual scabies that has been recently observed. In the present case, the patients systemic illness, including diabetes, anemia, and hypoalbuminemia, may well be responsible for the development of the nail changes.

Nonproprietary Name and Trademark of Drug

Crotamiton—*Eurax Cream.*

References

1. Hellier FF: Incidence of scabies. *Arch Dermatol* 93:634, 1966.
2. Orkin M: Today's scabies. *Arch Dermatol* 111:1431-1432, 1975.
3. Ormsby OS, Montgomery H: *Diseases of the Skin.* Philadelphia, Lea & Febiger Publishers, 1948, pp 1224-1233.
4. Kurtin SB, Leider M: Norwegian scabies. *N Engl J Med* 278:1099-1100, 1968.
5. Haydon JR Jr, Caplan RM: Epidemic scabies. *Arch Dermatol* 103:168-173, 1971.
6. Zaias N: *Clinical Dermatology.* London, Harper & Row Publishers, vol 11, 1975.

Idiopathic Calcinosis of the Scrotum

Benjamin K. Fisher, MD, Israel Dvoretzky, MD

Idiopathic calcinosis of the scrotum, which is a rarely reported condition of unknown etiology, may be easily misdiagnosed as epidermal or pilar cysts. Histologically, the diagnosis is easy and quite typical.

Report of a Case

A 24-year-old man was admitted to The Chaim Sheba Medical Center in November 1975 for removal of several asymptomatic scrotal cysts of several years' duration.

Examination showed several firm, nontender nodules of various sizes on the scrotum; the larger nodules were apparently formed from several smaller ones joined together (Fig 1). The diagnosis of epidermal cysts was made and all visible lesions were surgically removed. During surgery, some of the lesions were found to contain a viscous, thick, white-yellowish fluid. None contained an obvious sac.

Postoperative recovery was uneventful. Results of the following laboratory tests were found to be either within normal limits or negative: complete blood count, ESR, routine urinalysis, VDRL, blood glucose, blood urea, serum electrolytes, serum calcium, serum phosphorus, total proteins, serum electrophoresis, uric acid, serum creatinine, serum lipids, and stools for ova and parasites.

Histological examination of all lesions showed a similar picture. Present in the dermis were small and large calcified masses. In several places the calcium was missing; it was apparently lost during the histological preparation and empty spaces resulted. In most places, these calcium deposits did not elicit any inflammatory reaction, while in a few places slight-to-moderate inflammatory infiltrates were seen. Rare foci of foreign body reaction with giant cells were observed. The von Kossa stain was strongly positive (Fig 2). No evidence of epidermal inclusion cysts or pilar cysts was seen in the many sections that were examined. In some sections, bundles of smooth muscle were seen in the lower dermis.

From the Department of Dermatology, The Chaim Sheba Medical Center, Tel-Hashomer, Israel. Dr Fisher is now with The Wellesley Hospital, Toronto. Dr Dvoretzky is now with Yale University, New Haven Conn.

Reprints not available.

Fig 1.—Several smooth nodules on scrotum, indistinguishable clinically from epidermal or pilar cysts.

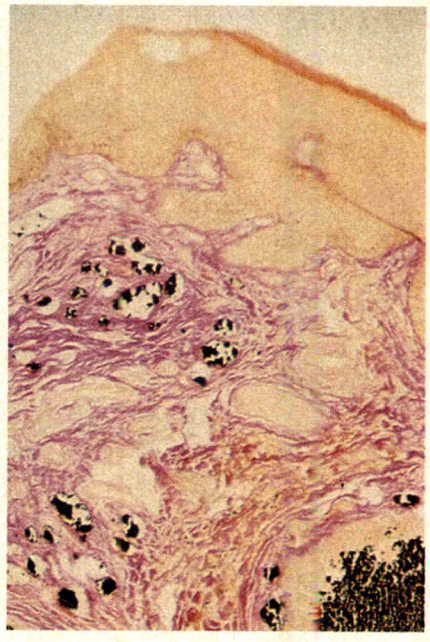

Fig 2.—Several black calcified masses in dermis. Empty spaces had contained calcium that was lost during histological preparation (van Gieson-von Kossa combined stain, original magnification ×100).

Comment

Idiopathic calcinosis of the scrotum was recently reviewed by Shapiro et al,[1] who reported 13 new cases in addition to nine proved cases that were collected from the literature. Veress and Malik[2] reported six cases from the Sudan. The condition does not seem to be related to calcinosis cutis of either the dystrophic or the metastatic types.[1]

Histologically, the picture is fairly typical with amorphous calcium deposits in the dermis, the occasional presence of a foreign body reaction, and the presence of smooth dartoic muscles.

Although calcium deposits in the scrotum could be diagnosed roentgenographically, this procedure is inadvisable because of possible medicolegal implications. The condition seems to be entirely benign, and therapy should be limited to the removal of bothersome lesions.

This investigation was supported by Canadian Friends of Hospital Tel-Hashomer, Calgary, Alberta, Canada.

References

1. Shapiro L, Platt N, Torres-Rodriguez VM: Idiopathic calcinosis of the scrotum. *Arch Dermatol* 102:199-204, 1970.
2. Veress B, Malik MOA: Idiopathic scrotal calcinosis. *East Afr Med J* 52:705-710, 1975.

Why prescribe two?

(Shown actual size)

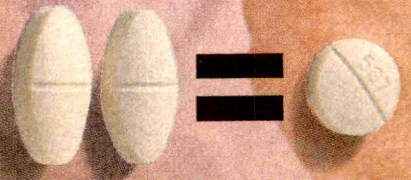

Other Ultramicrosize griseofulvin 125 mg. tablet

New Ultramicrosize FULVICIN P/G 250 mg. tablet

One tablet/once a day for enhanced patient compliance

The new one-a-day convenience of improved, ultramicrosize FULVICIN P/G helps maintain treatment and prevent missed doses.

One-half the dose

Therapeutic effectiveness—enhanced G.I. absorption makes it possible for 250 mg. of FULVICIN P/G to effectively replace 500 mg. of microsize griseofulvin. This is due to a special process by which ultramicrosize griseofulvin crystals, dissolved in P/G (polyethylene glycol), are dispersed throughout the tablet.

Easy-to-swallow tablets

Compare the size of the new 250 mg. tablet of FULVICIN P/G with the two-a-day 125 mg. tablet of the other ultramicrosize griseofulvin.

Significant savings to patients

New, improved FULVICIN P/G is up to 35 per cent less expensive per dose than all microsize griseofulvin formulations.*

Unique dosage flexibility

New, improved FULVICIN P/G is the only ultramicrosize griseofulvin to offer two strengths—125 mg. and 250 mg. tablets—for easy dose titration. And for added flexibility, the tablets are scored.

*Based on list-price comparisons.

Schering
Now, one will do.
Introducing the NEW 250 mg. tablet
FULVICIN® P/G
brand of GRISEOFULVIN ULTRAMICROSIZE
Because we believe your patient would prefer to take one tablet once a day.
COPYRIGHT © 1978, SCHERING CORPORATION. ALL RIGHTS RESERVED SLS-217
See Clinical Considerations section on following page.

FULVICIN P/G

GRISEOFULVIN ULTRAMICROSIZE

Tablets

Clinical Considerations: **INDICATIONS** FULVICIN P/G Tablets are indicated for the treatment of ringworm infections of the skin, hair, and nails, namely: tinea corporis, tinea pedis, tinea cruris, tinea barbae, tinea capitis, tinea unguium (onychomycosis) when caused by one or more of the following genera of fungi: *Trichophyton rubrum, Trichophyton tonsurans, Trichophyton mentagrophytes, Trichophyton interdigitale, Trichophyton verrucosum, Trichophyton megninii, Trichophyton gallinae, Trichophyton crateriforme, Trichophyton sulphureum, Trichophyton schoenleinii, Microsporum audouinii, Microsporum canis, Microsporum gypseum,* and *Epidermophyton floccosum.* Note: Prior to therapy, the type of fungi responsible for the infection should be identified. The use of this drug is not justified in minor or trivial infections which will respond to topical agents alone. Griseofulvin is not effective in the following: bacterial infections, candidiasis (moniliasis), histoplasmosis, actinomycosis, sporotrichosis, chromoblastomycosis, coccidioidomycosis, North American blastomycosis, cryptococcosis (torulosis), tinea versicolor, and nocardiosis. **CONTRAINDICATIONS** This drug is contraindicated in patients with porphyria, hepatocellular failure, and in individuals with a history of sensitivity to griseofulvin. **WARNINGS** *Prophylactic Usage:* Safety and efficacy of griseofulvin for prophylaxis of fungal infections have not been established. *Animal Toxicology:* Chronic feeding of griseofulvin, at levels ranging from 0.5-2.5% of the diet resulted in the development of liver tumors in several strains of mice, particularly in males. Smaller particle sizes result in an enhanced effect. Lower oral dosage levels have not been tested. Subcutaneous administration of relatively small doses of griseofulvin once a week during the first three weeks of life has also been reported to induce hepatomata in mice. Although studies in other animal species have not yielded evidence of tumorogenicity, these studies were not of adequate design to form a basis for conclusions in this regard. In subacute toxicity studies, orally administered griseofulvin produced hepatocellular necrosis in mice, but this has not been seen in other species. Disturbances in porphyrin metabolism have been reported in griseofulvin-treated laboratory animals. Griseofulvin has been reported to have a colchicine-like effect on mitosis and cocarcinogenicity with methylcholanthrene in cutaneous tumor induction in laboratory animals. *Usage in Pregnancy:* The safety of this drug during pregnancy has not been established. *Animal Reproduction Studies:* It has been reported in the literature that griseofulvin was found to be embryotoxic and teratogenic on oral administration to pregnant rats. Pups with abnormalities have been reported in the litters of a few bitches treated with griseofulvin. Additional animal reproduction studies are in progress. Suppression of spermatogenesis has been reported to occur in rats, but investigation in man failed to confirm this. **PRECAUTIONS** Patients on prolonged therapy with any potent medication should be under close observation. Periodic monitoring of organ system function, including renal, hepatic, and hematopoietic, should be done. Since griseofulvin is derived from species of *Penicillium,* the possibility of cross sensitivity with penicillin exists; however, known penicillin-sensitive patients have been treated without difficulty. Since a photosensitivity reaction is occasionally associated with griseofulvin therapy, patients should be warned to avoid exposure to intense natural or artificial sunlight. Should a photosensitivity reaction occur, lupus erythematosus may be aggravated. Griseofulvin decreases the activity of warfarin-type anticoagulants so that patients receiving these drugs concomitantly may require dosage adjustment of the anticoagulant during and after griseofulvin therapy. Barbiturates usually depress griseofulvin activity, and concomitant administration may require a dosage adjustment of the antifungal agent. **ADVERSE REACTIONS** When adverse reactions occur, they are most commonly of the hypersensitivity type, such as skin rashes, urticaria, and rarely, angioneurotic edema, and may necessitate withdrawal of therapy and appropriate countermeasures. Paresthesias of the hands and feet have been reported rarely after extended therapy. Other side effects reported occasionally are oral thrush, nausea, vomiting, epigastric distress, diarrhea, headache, fatigue, dizziness, insomnia, mental confusion, and impairment of performance of routine activities. Proteinuria and leukopenia have been reported rarely. Administration of the drug should be discontinued if granulocytopenia occurs. When rare, serious reactions occur with griseofulvin, they are usually associated with high dosages, long periods of therapy, or both. **HOW SUPPLIED** FULVICIN P/G Tablets, 125 mg., white, compressed, scored tablets impressed with the Schering trademark and product identification numbers, 228; bottle of 100. FULVICIN P/G Tablets, 250 mg., white, compressed, scored tablets impressed with the Schering trademark and product identification numbers, 507; bottle of 100. **Store at controlled room temperature 59°F to 86°F (15°C to 30°C).**

10705266 JANUARY 1978

For more complete details, consult package insert or Schering literature available from your Schering Representative or Professional Services Department, Schering Corporation, Kenilworth, New Jersey 07033.

Send us this coupon today and we'll send you a w[illegible] to slash your claims reporting costs and tim[illegible]

Return Order Blank To:
American Medical Association
535 North Dearborn
Chicago, Illinois 60610
(312) 751-6000

Type of form		Quantity—in orders of:	Price Including Handling and Postage
☐ Single Form (One page pads of a hundred)	OP-407	1,000 ☐	$ 18.50
		5,000 ☐	78.00
		10,000 ☐	138.00
☐ Two Forms (Original and one carbon)	OP-408	1,000 ☐	28.00
		5,000 ☐	112.00
		10,000 ☐	210.00
☐ Continuous Form (Original and one carbon) (For Computer Printers)	OP-409	1,000 ☐	28.00
		5,000 ☐	112.00
		10,000 ☐	210.00

TOTAL _____

Name _____

Street Address _____

City _____ State _____ Zip _____

Check or money order must accompany this order and be made payable to the American Medical Association.

The Official AMA Uniform Health Insurance Claim Form

Accepted by Medicare, Commercial Carriers, many Blue Shield Plans, and many states for Medicaid.

Developed by the AMA in cooperation with carriers, government agencies, and other groups, this form is the most current and most widely used claim reporting form available. It significantly reduces the time and cost of claims reporting. **Note:** A number of private firms are marketing an outdated, more expensive version of this form. To be certain you are using the most current and acceptable form to third party insurers, we encourage you to use the official AMA form. Order today.

to the Editor

Readers are advised that in view of The Copyright Revision Act of 1976, *all Letters to the Editor submitted for publication must contain on the transmittal letter the following language: "The person(s) undersigned hereby grant the American Medical Association permission to publish this Letter and in addition, hereby assigns all copyright ownership therein to the AMA."*

Dermatologists for the Nation: Perspectives

To the Editor.—The recent article in the ARCHIVES by Krasner and associates (113:1367-1371, 1977) provides us at last with a scientific evaluation of the problem of dermatologic manpower. Their classic paper is beautifully thought out and covers almost every aspect of the problem.

It is clear from their data that the number of dermatologists in the United States will double between now and the year 2010. One must add that the estimate of 8,800 dermatologists in the year 2010 is based on the assumption that no new residency positions will be added over the next 35 years. Actually, the number of residents in training has been increasing. When I last reported on this subject in 1971, the number of new dermatologists entering practice each year was estimated at 200[1]; now a figure of 250 is used. With no residency programs at 40-odd medical schools,[2] the pressure to add more training programs in the future may well be irresistable. If each of the 42 medical schools that do not have dermatology residencies now were to graduate two trained dermatologists a year, the number of dermatologists produced each year would increase from 250 to 334, and the ultimate number of dermatologists in practice at the equilibrium date 35 years later would increase from 8,800 to 334 × 35, or (theoretically) 11,690.

The question is, are we going to need all the dermatologists we are going to train? There is no doubt that there is an enormous number of dermatologic problems to be treated. Surveys show that some 31% of the population have skin disease, a large, but unknown amount of which is not being treated by anyone.[3] Only about a third of the visits now being made to physicians for dermatologic complaints are made to dermatologists.[4] Health Maintenance Organization data shows need for about three dermatologists per 100,000 population (in contrast to the present ratio of about two) and the Soviet Union has an even higher ratio.[5]

Reflecting this pent-up demand, many established dermatologists (especially in small towns) complain of overwork and are seeking partners.

It may be that there is so much skin disease to treat that we cannot possibly satiate the demand for dermatologists. However, we hear allegations that the present market is becoming saturated. Third-year residents complain that there are very few "open" cities left, and the number of dermatologists who find it necessary to maintain two or more offices to keep busy appears to be on the increase. These considerations indicate that the gap between demand and supply of dermatologists is shrinking, but give us no idea how wide that gap still is or how many more dermatologists could be absorbed.

There are so many unknown factors in the prediction of dermatologic manpower needs, that it is much like the interpretation of ink blots—any conclusions reflect primarily the anxieties of the viewer.

However, the fact that England manages to get by with only about 300 dermatologists (1/250,000 population) demonstrates that we cannot lightly assume that in the United States in the next 35 years 8,800 (or perhaps 11,690) dermatologists will be needed. That may be the case only if the following assumptions are met:

1. Money will be available through increasing prosperity or Universal health insurance to pay for virtually unlimited medical care for Dermatologic problems.
2. Dermatologists will not be displaced by other physician specialists or generalists in supplying this care.
3. Physicians (rather than paramedical personnel) will supply the bulk of this care.

Assumption 1 is a matter of much current debate. It seems quite likely that the national health insurance scheme that evolves in this country will attempt to control costs by co-pay and deductible features, and may specifically exclude many forms of cosmetic medicine and surgery. Such restrictions might actually shrink the economic demand for dermatologists. The mere fact that we double the number of dermatologists does not mean that the public will be willing to pay twice as much for their services.

Assumption 2 is difficult to evaluate, but it is obvious that the present shortage of primary care physicians will become less acute. The yearly number of medical school graduates has virtually doubled in the last ten years and is still expanding.[6] If 50% of these graduates are to enter primary care, the possibility of an oversupply of family doctors and other primary care physicians must be considered. Many of these underemployed physicians may develop an interest in dermatology. As HMOs develop captive populations, they are likely to employ family physicians to assist and replace dermatologists. Should new legislation or HMO regulations require written referral for a patient to see a specialist (as in England and some Canadian provinces now), the dermatologist would be at a disadvantage in attracting patients with dermatologic problems away from the primary physician.

Assumption 3 is also impossible to predict. In the military services, physicians' assistants and corpsmen are used extensively to extend dermatologists' services, but their true impact has not been evaluated. As HMOs attempt to cut costs, it is reasonable to expect them to employ "acne technicians," "wart technicians," and other lay assistants to decrease the number of trained dermatologists on their payrolls. Health spa and cosmetic salon chains, with efficient management techniques, using physicians only to sign periodic prescriptions for oral medication, may be able to take over much of the treatment of acne and psoriasis.

On the other hand, principles of economics may work in our favor. It may work out that the private dermatologist's office, using his own trained assistants, but with no union labor, no hospital bureaucracy, and no central record room will continue to be the most cost-efficient way to treat common dermatologic problems, and the

by one mechanism or another, most of the patients will eventually find their way to such offices.

If the assumptions described herein should not be met, we may eventually face a period during which dermatologists are in oversupply. A number of adjustments might then come into play:

If more dermatologists were trained than were needed, they would tend to raise fees and to look harder, or even advertise, for work to be done. Labor-intensive treatment methods might be emphasized, as they attempted to give more service to each patient ("more care per cure"). As physicians in all other specialties might be doing the same thing at the same time, total medical costs would be likely to rise with the physician population. Indeed, medical care might become so expensive that the fee-for-service system would be abandoned in an effort to control costs. However, even dermatologists who are on salary would not be immune to the temptation to expand services in order to increase the size of the organizations they control.

Another consequence of an increase in the supply of dermatologists would be that the salaries of those who were employed by institutions would fall. However, as dermatologists became cheaper, they would be more widely employed. Large groups would have no incentive to hire family physicians or physicians' assistants to practice dermatology if board-certified dermatologists cost no more. In any event, any moderate excess of dermatologists who may be trained will create forces which will bring about its own employment. We will use what we train.

Although we may be faced with an oversupply of dermatologists in the future, organized dermatology has little ability to decrease the number of residents in training. Should the board or any other organization attempt to do so, it might be accused of monopolistic practices. Individual residency programs, however, might do a variety of things to decrease their output. They can accept more foreign physicians committed to return to their homelands. Family medicine and internal medicine residents rotating through dermatology can be used to do some work now done by dermatology residents. The scope of dermatologic training can be broadened to include more plastic surgery, allergy, rheumatology, and physical therapy. In the extreme case, trained dermatologists could become as cheap as residents, and teaching centers could eliminate residency positions as more full-time faculty were hired at the same price.

Governmental regulation of the number of specialists trained has been suggested, and actually came close to passage a few years ago. Perhaps a governmental agency could make rational decisions in this very complicated area. On the other hand, such an agency might deliberately create an oversupply of dermatologists in order to drive down incomes (but not the total cost) of dermatologists and deprive them of their independence. Or it might cut back the supply of dermatologists, to cut down on the total expense of dermatologic care, or it might vacillate from one approach to the other. However, federal regulation of the supply of dermatologists may be better than none at all, and perhaps we should begin to think positively in this direction.

Certainly, we must continue to monitor the problem by continuation of research such as that of Krasner et al, with the hope of providing facts that will guide the acts of both governmental and professional decision-making bodies in the future.

To recapitulate, we cannot predict the financing and organization of health care in the future, and therefore we cannot predict what the need for dermatologists will be. If we train relatively few dermatologists, they will serve as ethical consultants in a traditional medical capacity; if we train too many, they will find employment at one level or another, by one way or another. We will learn to live with whatever happens, and there is not much we are going to do about it. But we must certainly make every attempt to keep abreast of the situation.

EDMUND D. LOWNEY, MD
Columbus, Ohio

1. Lowney ED: The ecology of dermatologists. *Arch Dermatol* 104:113-116, 1971.
2. Everett MA: Academic manpower in dermatology. *Arch Dermatol* 113:1365-1366, 1977.
3. Johnson, MLT, Roberts J: Prevalence of dermatologic disease among persons age 1-74: United States: *Advance Data From Vital and Health Statistics*, National Center for Health Statistics, No. 4, Jan 26, 1977, Health Resources Administrations, US Department of Health, Education, and Welfare, Washington, DC.
4. Stern RS, Johnson ML, DeLozier J: Utilization of physician services for Dermatological complaints. *Arch Dermatol* 113:1062-1068, 1977.
5. Bogatyrev ID(ed): *Zabolevaemost' Gorodskovo Naselenie i Normatyvy Lechebno-profilakticheskoi Pomoshchi*. Moscow, Meditsina, 1967.
6. Cooper JAD: Medical education: Past, present and future. *N Engl J Med* 297:941-943, 1977.

Diagnosis and Prognosis of New World Leishmanias

To the Editor.—Although w[illegible] with Price and Silvers' statem[illegible] "New World Leishmaniasis: S[illegible] Aids to Diagnosis," which appe[illegible] the October ARCHIVES (113:141[illegible] 1977), we wish to call attention t[illegible] points that were not stressed and that may be of importance to physicians in nonendemic areas who are confronted with possible cases of cutaneous leishmaniasis.

Price and Silvers mention the Montenegro or intradermal test for leishmaniasis, but perhaps unduly minimize the utility of this reaction. Though antigens for the Montenegro test may not be commercially available from US manufacturers, they are available from at least one South American manufacturer (Instituto Adolfo Lutz, São Paulo, Brazil) and one European manufacturer (Burroughs Wellcome, England). The test is no more difficult to administer or interpret than a PPD reaction and gives results in 48 hours. In cutaneous leishmaniasis, as in leprosy, there is an inverse relationship between the cellular immune response of the host and the parasite load in the tissues. Therefore, if the Montenegro test is negative, results of a biopsy (or even direct smear of the lesion) will generally be positive, and vice versa. (Though positive intradermal reactions due to past subclinical or extinct infections may cause us problems of interpretation in endemic areas, this should be less so in returning travelers.) Finally, it has been established that a cellular immune response is necessary, if not sufficient, for effective control of the parasite by the host, whereas no studies to date have determined a relation between humoral responses to parasite antigens and resistance. Therefore, the development of the Montenegro reaction in the patient may provide information of greater relevance concerning his defenses than would serological responses.

Our second point is concerned with treatment and relapse. Price and Silvers mention the mutilating secondary mucocutaneous lesions of American leishmaniasis (espundia), but do not make clear that such relapses can occur up to 25 years after apparent clinical cure of the primary lesion, if natural stress[1] or immunosuppressive therapy[2] tip the balance in favor of the parasite. Though the only effective therapeutic agents are

not.

forbiddingly toxic, we therefore utilize a more vigorous therapeutic regimen (at least two ten-day series of antimonials, separated by a ten-day rest period) if the patient's general state permits, since our local strain of *Leishmania* is known to produce espundia. In any case, the diagnosis of American leishmaniasis should be given prominent attention in the patient's permanent medical record, since serious sequelae can occur after many years and can be provoked by therapeutic measures for unrelated conditions.

PAMELA L. MORIEARTY, PHD
CANDIDO PEREIRA, MD
Salvador, Brazil

1. Walton BC, Chinel LV, Eguia y Eguia O: Onset of espundia after many years of occult infection with *Leishmania brasiliensis*. *Am J Trop Med Hyg* 22:696-698, 1973.
2. Shaw PK, Quigg LT, Allain DS, et al: Autochthonous dermal leishmaniasis in Texas. *Am J Trop Med Hyg* 25:788-796, 1976.

Treatment of Hallopeau's Acrodermatitis With Triamcinolone Acetonide

To the Editor.—Notowicz et al's report in the January ARCHIVES (114:129, 1978) of the successful use of topical mechlorethamine hydrochloride in Hallopeau's acrodermatitis prompts me to suggest that intramuscular triamcinolone acetonide should always be tried in this disorder. It is highly effective against all the manifestations of inverse psoriasis, including this one. A single dose of 60 mg, deep into the buttock, may be safely followed by a second injection within a week or two if the response is disappointing; a third treatment is unlikely to be needed. Relapses, mysteriously, are not common, at least in lesions that involve only one digit. Side effects, barring disturbances of the menstrual cycle, are virtually nil, as one would expect from such a small total dose.

HARRY L. ARNOLD, JR, MD
Honolulu

Nonproprietary Name and Trademark of Drug

Triamcinolone acetonide—*Kenalog 40.*

Woronoff's Ring in Goeckerman Treatment of Psoriasis

To the Editor.—Recently, Woronoff's ring of psoriasis has been shown to be an area in which prostaglandins (PG) are absent or are synthesized in very low concentrations, perhaps as the result of an inhibitor of PG synthesis.[1] It is also well established that ultraviolet (UV)-B damage to skin is mediated by PG activity as PG inhibitors, such as indomethacin and acetyl salicylic acid, inhibit the UV-B-induced erythema.[2,3] We have observed the absence of sunburn in Woronoff's ring in psoriatic patients undergoing the modified Goeckerman treatment for psoriasis. Figure 1 demonstrates this phenomenon in a 50-year-old man with psoriasis who received a sunburn reaction during the Goeckerman treatment program. The psoriatic plaque involuted rapidly, as did Woronoff's ring, but the sunburn reaction resolved more slowly. Figure 2 demonstrates Woronoff's ring surrounding a psoriatic plaque in a 28-year-old woman. This is, in turn, surrounded by the "pink" skin induced by the Goeckerman treatment.

Fig 1.—Sunburn reaction in 50-year-old psoriatic man during Goeckerman treatment.

Fig 2.—Woronoff's ring surrounding psoriatic plaque which, in turn is surrounded by "pink" skin induced by Goeckerman treatment.

It might be anticipated that the addition of salicylic acid to the crude coal tar in petrolatum might inhibit the PG-mediated, UV-light-induced erythema outside Woronoff's ring. I submit these figures for their pictorial value and to demonstrate that 2% crude coal tar in petrolatum (Fig 2) or the addition of 3% salicylic acid to the 2% crude coal tar in petrolatum (Fig 1) does not alter the erythema outside or the pallor of Woronoff's ring.

ROY S. ROGERS III, MD
Rochester, Minn

1. Pennys N, Ziboh V, Simon P, et al: Pathogenesis of Woronoff ring in psoriasis. *Arch Dermatol* 112:955-957, 1976.
2. Synder DS, Eaglestein WH: Intradermal anti-prostaglandin agents and sunburn. *J Invest Dermatol* 62:47-50, 1974.
3. Synder DS, Eaglestein WH: Topical indomethacin and sunburn. *Br J Dermatol* 90:91-93, 1974.

Fixed Drug Eruption Owing to Sulfamethoxazole

To the Editor.—A 59-year-old woman came to my clinic in late 1977 with a two-year history of a recurrent eruption. Lesions, which always totaled four, consisted of red, blistered areas that lasted about five days before settling down and often leaving pigmentation. They always appeared in the same sites, and attacks occurred every few months.

Report of a Case.—On examination, she showed well-defined, resolving erythematous patches over the right supraclavicular fossa, over the right calf, and above the right lateral malleolus. She was seen in a further attack one month later, and her history disclosed that she had been taking a mixture of trimethoprim and sulfamethoxazole (co-trimoxazole; Septrim [British]; Bactrim, comparable US product) tablets when the attack occurred. She then disclosed that she had had courses of the trimethoprim-sulfamethoxazole mixture for urinary symptoms at times since 1971, but she had taken the tablets regularly every few months during the last three years.

With the patient's agreement, it was decided to reproduce the eruption. She was exposed first to trimethoprim in a dosage equivalent to the contents of four trimethoprim-sulfamethoxazole tablets (80 mg ×4) on each of two successive days, but there was no recurrence of her rash. She was then exposed to sulfamethoxazole, again in a dosage equivalent to the contents of four trimethoprim-sulfamethoxazole tablets (400 mg ×4), on two separate occasions. The drug was taken for two successive days the first time and on one day the second time. On the first occasion, sore red patches appeared at the

four sites three hours after the first dose; one the second occasion, soreness occurred within two hours of the first dose, and there also was slight blister formation. She was also exposed to sulfamethazine (sulfadimidine), 1 g one day and 2 g three weeks later, with no recurrence of the eruption.

Comment.—This case is interesting in that a fixed drug eruption owing to sulfamethoxazole had clearly been developed, and, although this was reproducible, the patient could take sulfamethazine with no side effect. Welsh noted that a fixed drug eruption can develop with one sulfonamide but not necessarily with other sulfonamides.[1] This patient had also taken sulfamethoxazole for many years before the drug sensitivity developed. Although fixed drug eruption owing to sulfonamides is well known, Savin did not find them among the most common causes in his series.[2]

JULIAN VERBOV, MD, MRCP
Liverpool, England

P.G.W. Jones, principal pharmacist, Sefton General Hospital, Liverpool, England, prepared separate capsules of trimethoprim and sulfamethoxazole from powder supplied by Burroughs Wellcome & Co.

Nonproprietary Names and Trademarks of Drugs

Sulfamethoxazole—*Ganatol.*
Trimethoprim—*Syraprim.*

1. Welsh AL: *The Fixed Drug Eruption.* Springfield, Ill, Charles C Thomas Publisher, 1961, p 141.
2. Savin JA: Current causes of fixed drug eruptions. *Br J Dermatol* 83:546, 1970.

Congenital Pigment Formation

To the Editor.—In the July 1977 issue of the ARCHIVES (113:987), Grange S. Coffin presents a case report entitled "Congenital Pigment Formation," in which a pattern of pigment in the shape of a deer track, which seems to be outlined by a pale, ventral median stripe, is described. Dr Coffin has no explanation of this congenital anomaly.

We think that this mark enters into the group of "pigmentary demarcation lines," as defined by Selmanowitz and Krivo (*Br J Dermatol* 93:371, 1975), and can be identified with the group C, type 2 of the Miura's classification system (*Tohoku J Exp Med* 54:135-140, 1951). We have recently studied this curious type of pigmentation to individualize a new type of lineral dermatoses, which we named "axial dermatoses" (*Ann Derm Vénéréol* 104:304-308, 1977) because such dermoid patterns electively follow the linear course of Sherrington's axial lines.

ANDRÉ DUPRÉ, PHD
Toulouse, France

In Reply.—Occasionally I see a child who has a puzzling cutaneous pigment pattern in the shape of a deer track overlying the sternum; in July, the ARCHIVES published a clear photograph of such a pattern. Now we are indebted to Professor Dupré for comments that may solve the puzzle. His letter advises that the outlines of these deer tracks may be classified as pigmentary demarcation lines. The references show that demarcation lines have been described and studied since 1913, and that a creditable embryologic explanation for them is being considered. We are grateful for this information.

GRANGE S. COFFIN, MD
Berkeley, Calif

Coexistence of Malignancies With Bullous Pemphigoid

To the Editor.—The relationship of bullous pemphigoid to malignancy is still a controversial problem in spite of multiple reported cases. Some authors regard the association as a real one,[1,2] and others regard it as merely a fortuitous coexistence,[3,5] while still others point to a significantly higher incidence of malignancies in cases of pemphigoid in which the patients have low titers or no detectable serum antibody to the basement membrane zone.[6]

Therefore, we have made an analysis of cases of bullous pemphigoid seen in our department during the period of 1968 to 1977. Malignant tumors were found in 12 of 110 (11%) cases of bullous pemphigoid, with six in 54 women and six in 56 men. These tumors included four breast cancers, two cancers of the prostate, two lymphoreticular malignancies, and one malignant tumor of each of the following tissues: lung, thyroid, larynx, and skin. In addition to these, eight patients, six men and two women, were suspected of having malignant tumors. These included two cases of hypertrophy of the prostate, three cases of suspected carcinoma of the stomach, and one case each of suspected carcinoma of the colon, of the thyroid in a patient with struma nodosa toxicum, and of the stomach in a patient with a tentative diagnosis of Hodgkin's disease (patient lost to follow-up). Since malignancy has as yet been confirmed in these cases, they were not included in the statistical analysis.

The 1968 to 1974 mean incidence of malignant disease was calculated for the population of Poland with consideration of the age and sex of the patients suffering from malignancies, using the Poisson equation as applied to rare cases with known probabilities. The expected incidence of malignancy in the 56 men was 0.537, as compared with the six proved cases observed. In the group of 54 women, the incidence of tumors would have been 0.293, as compared with the six cases found. As compared with the expectancy of cancer in the Polish population in a corresponding age and sex group, the recorded incidence was highly significant ($P < .001$). The true incidence of malignant tumors in bullous pemphigoid would be even higher if eight cases suspected of malignancy could be followed for a longer period.

Although the problem of a causal relationship between bullous pemphigoid and malignancy is still controversial, from the practical point of view the thorough examination of patients with bullous pemphigoid for internal malignancy should be strongly recommended as a routine procedure.

T. P. CHORZELSKI, MD
S. JABLONSKA, MD
E. MACIEJOWSKA, MD
Warsaw, Poland
ERNST H. BEUTNER, PHD
Buffalo, NY
L. WRONKOWSKI
Warsaw, Poland

1. Rook AJ: A pemphigoid eruption associated with carcinoma of the bronchus. *Trans St John Hosp Derm Soc* 54:152-154, 1968.
2. Jablonska S, Chorzelski TP: Autoimmunologische Hautveränderungen bei malignen tumoren der inneren organe. *Z Haut Geschlechtskr* 46:548-552, 1971.
3. Parsons RL, Savin JA: Pemphigoid and malignancy. *Br J Cancer* 22:669-672, 1968.
4. Paslin DA: Bullous pemphigoid and hypernephroma: A critical review of the association of bullous pemphigoid and malignancy. *Cutis* 12:554-555, 1973.
5. Stone SP, Schroeter AL: Bullous pemphigoid and associated malignant neoplasms. *Arch Dermatol* 111:991-994, 1975.
6. Person JR, Rogers RS: Bullous and cicatricial pemphigoid. *Mayo Clin Proc* 52:54-66, 1977.

Lichen Striatus With Nail Dystrophy

To the Editor.—Lichen striatus is not a common clinical entity. When it is found in conjunction with nail involvement, it is even rarer. We would like to report such a case, which was recently seen in our clinic.

Left thumbnail showing longitudinal splitting and shredding.

Report of a Case.—A 2-year-old boy was seen in our clinic in March 1977, because of the appearance of an asymptomatic, hypopigmented, coalescing, linear, papular eruption on the left forearm that had been present for about six months. On closer inspection, the papules were noted to extend to the posterior nail fold of the left thumb. The child's mother had noted gradual changes in the appearance of the left thumbnail during the previous six months, and when we examined the child, the entire nail plate revealed longitudinal splitting and shredding (Figure). A potassium hydroxide preparation of nail scrapings was negative. A skin biopsy specimen from one of the papules showed minimal perivascular infiltration composed of lymphocytes and histiocytes. The epidermis showed areas of edema and focal exocytosis.

Comment.—Linear lichen planus might enter into the differential diagnosis of a lesion such as this one, although the physician can usually differentiate it from lichen striatus rather easily. Whereas lichen planus is almost always quite pruritic, lichen striatus usually does not itch.[1] Characteristically, lichen planus shows destruction of the basal layer and considerable hyperkeratosis, in contrast with lichen striatus, which shows little of either of these features. Pinkus[2] notes that the infiltrate in lichen striatus may vary from extremely heavy to sparse, even within the same biopsy specimen. The gross lesion described in this report is quite similar to those reported by Owens,[3] Kaufman,[4] and Senear and Caro,[5] with longitudinal splitting or ridging of the nail plate found in all cases.

MARK MEYERS, MD
WILLIAM STORINO, MD
SIDNEY BARSKY, MD
Chicago

1. Lever WF: *Histopathology of the Skin*, ed 5. Philadelphia, JB Lippincott, 1975.
2. Pinkus H: *A Guide to Dermatohistopathology*, New York, Appleton-Century-Crofts, 1976.
3. Owens DW: Lichen striatus with onychodystrophy. *Arch Dermatol* 105:457-458, 1972.
4. Kaufman JP: Lichen striatus with nail dystrophy. *Cutis* 14:232-234, 1974.
5. Senear FE, Caro MR: Lichen striatus. *Arch Dermatol* 43:116-133, 1941.

Red Poster Paint Tattoo Granuloma

To the Editor.—In Danish prisons, tattoo colors and instruments are forbidden. However, some prisoners constructed tattooing instruments by mounting steel needles on electric shavers. Owing to the lack of standard pigments, the prisoners improvised, viz, they used a paint that is used for posters, for hobby crafts and for decoration.

The poster paint is available in scarlet and dark green, and is used for hobby work in the prison. The scarlet paint contains color index (CI) pigments 3, 4, and 95, all of which are monoazopigments, whereas the dark green paint contains CI yellow 1, which is a monoazopigment, CI 7, and CI blue 15, both of which are phthalocyanine pigments. Both poster paints contain chalk, dolomite, and casein as binders, and the preservative 0.4% chlormetacresol.

In 1973, seven prisoners were referred to the Department of Dermatology, Odense University Hospital, Odense, Denmark, for treatment of ulcerating, itching skin tumors that were located specifically at the sites where the red tattoo had been made and the scarlet paint had been inserted in the skin. A common feature in all patients was that two to four weeks after the tattooing procedure, the patients felt intense itching and they noticed cutaneous swelling at the location of the red color (Figure). The inconvenience and discomfort were so pronounced that before referral to the dermatological department, the patients attempted to remove the itching areas with razor blades or by burning out the tumor area with cigarettes.

Potent corticosteroids were without benefit. In two patients, intralesional corticosteroids had a slight effect. Only after excision of the tumor were the symptoms relieved, so that surgical treatment became the treatment of choice.

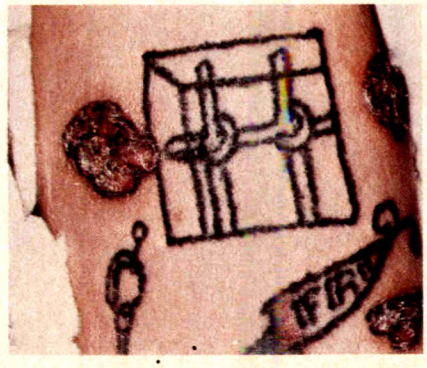

Tumor lesion at site of red tattoo.

Patch-testing with the paint alone was negative in all patients.

By light microscopy, a papillomatous bulging from the surface of the skin, with severe hyperkeratosis and deep horny invagination, was seen. In some patients, parakeratosis was observed. The underlying stratified squamous epithelium was highly hyperplastic and papillomatous, but generally showed well-differentiated cells. In smaller areas, there was a rather severe infiltration of the epithelium with leukocytes, and epithelial downgrowths with deeply located horny cysts were observed often. The basal cell layer was poorly differentiated, and often, epidermolysis was present.

The corium was remarkably thickened and heavily infiltrated with inflammatory cells. Plasma cells, lymphocytes, and histiocytes were present in large accumulations, sometimes as perivascular "cuffing" without inflammatory cells present in the vessel walls.

Many cells in the infiltrate were large polygonal cells with faintly staining cytoplasm, which was often finely granulated. The nucleus in each of these cells was large, oval- or bean-shaped, with a vesicular appearance, and often with a distinct nuclear membrane and a large, round nucleus. Such epithelioid cells were found singly between lymphocytes, plasma cells, and histiocytes, and also in clusters that resembled epithelioid cell granulomas. Large multinucleated cells of the Langhans' type were present. The cells occasionally contained a sparse amount of the tattoo pigment.

Scattered throughout the tissue, the cells that contained tattoo pigment were recognized as large macrophages of stellate shape.

Many mast cells were observed, but obviously without relation to the pigment-containing "tattoo cells"[1] or to the epithelioid cells.

The ultrastructure of the granulomatous lesions revealed a variegated picture. The cells showed various degrees of differentiation towards plasmocellular forms, and such cells did not contain tattoo pigment.

Another cell type was characterized by large size and stellate form, with many villous cell protrusions from the outer cell membrane. The cytoplasm often exhibited many empty vesicles of various sizes, together with many dense bodies or lysosomes and mitochondrion. These epithelioid cells contained only minimal amounts of tattoo pigment, or none at all.

However, tattoo cells as described by Christensen and Schmidt[1] were present in considerable amount. In these membrane-limited cells, dense collections of pigment filled out the whole cytoplasm.

From the present material, we cannot determine how often poster paint produces granulomatous tumors, since we have seen only seven such cases. However, in these cases, the prisoners had known that everyone tattooed with the red paint would develop an itching tumor.

Sneddon[2] described beryllium granuloma, and Loewenthal[3] reported granuloma in tattoo marks owing to chromium allergy from a green tattoo. However, Beerman and Lane[4] recorded that foreign-body reactions to pigment, as such, had never been observed.

From the morphological point of view, the changes of the granulomatous type that are recorded herein should be compared to those changes seen in Boeck's sarcoid[5] and in granulomatous hypersensitivity.[6]

HENNING SCHMIDT, MD
H. E. CHRISTENSEN, MD
Odense, Denmark

1. Christensen HE, Schmidt H: The ultrastructure of tattoo marks. *Acta Pathol Microbiol Scand* (A) 80:573, 1972.
2. Sneddon IB: Berylliosis: A case report. *Br Med J* 1:1448, 1955.
3. Loewenthal LJA: Reaction in green tattoos: The significance of valence state of chromium. *Arch Dermatol* 82:237-243, 1960.
4. Beerman H, Lane RAC: Tattoo: A survey of some of the literature concerning the medical complications of tattooing. *Am J Med Sci* 227:444, 1954.
5. Wanstrup J, Christensen HE: Sarcoidosis: I. Ultrastructural investigations on epithelioid cell granulomas. *Acta Pathol Microbiol Scand* 66:169, 1966.
6. Epstein WL: Granulomatous Hypersensitivity. *Prog Allergy* 2:36, 1967.

Mycobacterium marinum Infections

To the Editor.—I read with interest the article "*Mycobacterium marinum* Infections Treated With Tetracycline" (113:1067-1068, 1977). The authors state that "based on our correlated in vitro antimicrobial studies, we believe that this [clinical effectiveness] is a direct antimicrobial effect." The five isolates in their study demonstrated in vitro sensitivity to tetracycline at the 25 to 50 μg/ml level. On their suggested oral treatment regimen of 2 g of tetracycline daily, peak blood levels of 3 to 6 μg/ml are achieved.[1,2] This would only be 5% to 10% of the quantity of tetracycline necessary for the in vitro inhibition of *M marinum*. Although tetracycline concentrates in certain tissue sites, I am unaware of data showing tenfold to 20-fold concentration in skin or soft tissues, as compared with serum levels.

I agree with Izumi et al that "the results of chemotherapy have been difficult to evaluate because of the natural tendency of this infection to spontaneously heal, usually within one to two years." Although difficult to accomplish, only a double-blind controlled study will satisfactorily answer whether the use of tetracycline is effective therapy for *M marinum* infections. However, even if the use of this antibiotic is shown to be efficacious in *M marinum* infections, it is probably not explained by direct antimicrobial effect.

FRANCIS D. PIEN, MD
Honolulu

1. Weinstein L: Tetracycline and chloramphenicol, in Goodman LS, Gilman A (eds): *The Pharmacological Basis of Therapeutics*, New York, Macmillan Co, 1975, p 1185.
2. Hoeprich PD: Antimicrobics and anthelmintics for systemic therapy, in Hoeprich PD (ed): *Infectious Diseases*, Hagerstown, Md, Harper & Row Publishers Inc, 1977, p 155.

Treatment of Psoriasis With Dialysis

To the Editor.—With Dr Karl Nolph, our director of nephrology, I have been observing two patients with very extensive, disabling psoriasis that had persisted without improvement for many years despite treatment with repeated trials of Goeckerman therapy and folic acid antagonists. These patients, who have no renal disease, were the first to undertake dialysis for psoriasis, and both have enjoyed prompt and total healing of the skin, which has been sustained without further treatment since April 1977. These initial cases were managed by Dr Nolph's renal fellow, Dr Z. J. Twardowski, who, I believe, is the first physician to perform dialysis specifically for psoriasis.

At the University of Missouri Medical Center, Columbia, we are evaluating cases of psoriasis for dialysis and will continue preliminary evaluations of efficacy, particularly in regard to the possible benefit for early and severe, psoriatic arthritis. The exact treatment of the first three patients who had dialysis for psoriasis is described in an article now awaiting publication in the *Annals of Internal Medicine*. Originally, our interest was drawn to this experiment by several reports of impressive resolution of severe psoriasis in patients with renal disease at the time of their dialysis. We are following up two groups of patients: one group whose psoriasis did clear with dialysis but whose dialysis program was determined by their renal disease; and a more interesting, second group with normal renal functions on whom dialysis was performed for psoriasis alone.

Because this preliminary information is intriguing, it has traveled quickly to many dialysis centers both here and in Europe. I wish dermatologists to be aware of our interests and our concerns. We urge medical caution, all proper procedures in human experimentation, documentation over the years by dermatologists, and informed expertise in dialysis. The dialysis procedure is a special one for psoriasis, and some unique pitfalls have been recognized. We wish to correlate as much medical experience as possible with either standard hemodialysis or peritoneal dialysis of patients who incidentally have psoriasis. Dialysis does not appear helpful for pustular psoriasis, for example, and other examples of failure are known. One patient without renal disease but with severe, pustular, erythrodermic psoriasis had dialysis done here wihout any benefit. I would like to hear from persons concerned with dialysis who undertake the care of a patient with psoriasis.

Obviously, hypotheses regarding the mechanism of *possible* benefits of dialysis on psoriatic skin come to mind. We have done measurements on blood and on dialysates concerning folic acid, serum-bound zinc, and vitamin A, in addition to the routine measurements to determine the thoroughness of dialysis and the effects on normal renal functions. Assistance in gathering observations on dialysis and psoriasis toward a cautious and rational evaluation would be appreciated.

PHILLIP C. ANDERSON, MD
Columbia, Mo

The Lady and the Flea

To the Editor.—In the latter part of the 19th century, a small book was printed privately in Cincinnati by Henry F. Farny, the famous painter of Indians, and was presented to Richard H. Wald. This book has current interest in the clinical features of the bites of fleas. The pictures of takeoffs of various periods of art show the uncomfortable woman and the bemused gentleman observing but evidently not bitten. In the family group, women show bite reaction usually more than other members,

"THE LADY AND THE FLEA."
A TALE OF A TALE.

Fig 1.—"The Lady and the Flea," front page.

PUBLISHED BY THE SOCIETY FOR THE DISSEMINATION OF USELESS KNOWLEDGE AND THE LEAGUE FOR THE PROPAGATION OF THE CASTANEA VULGARIS.

Plate G.

From the Jocund Tales of Augsburg (Nuremburg, Mathias Kopurger, 1487). The original was engraved by Hermann Fogel or Vogel, 1453-1526, pupil of Albert Durer. Fogel is best known by his series of illustrations entitled "Hahnenschwänze"—now very rare—but of which an admirable copy is preserved in the Lenox Library of New York.

Fig 2.—Top right, Middle Ages. Bottom left, Japanese period. Bottom right, Colonial period.

Plate A.

From an ancient Kakemono of the reign of Jimnu Tenno, commonly attributed to Hirokama Shuhito. Now preserved in the Imperial Library of Tokio.

Plate J.

Early woodcut, from Kingston *Gazette*, Jan. 14th, 1800.

even though they may not be insect-bite reactors. The location of bites, chiefly on the lower extremities, is also characteristic. Recent studies in England by Miriam Rothschild, long interested in fleas, suggests, at least for the European rabbit flea, that reproductive hormones of the rabbit have a role in the breeding cycle of the flea.[1] The first picture in the book of "The Lady and the Flea" shows dogs. So, the flea of interest may be *Ctenocephalides canis*, the dog flea, rather than *Pulex irritans*, the flea of man. In the old literature, women often wore flea traps. Paintings of the Renaissance do show women, not men, looking for fleas. So, this entertaining and rare little volume by a famed painter has clinical value.

LEON GOLDMAN, MD
BETTY STIX
Cincinnati

1. Rothschild M: Fleas. *Endeavour* 24:162-168, 1965.

Peculiar Pruritus

To the Editor.—A towering mountain of medical literature makes it increasingly difficult for an author to ascertain that a disease strange to him has not been hitherto observed. The "peculiar persistent pruritic affection of the skin" is reported by Schamberg in the July 1977 ARCHIVES (113:986) too late. This disorder was described and named (also alliteratively) "puncta pruritica" by Toomey, 55 years ago (*Arch Dermatol* 5:744-747, 1922). Independent discovery is nonetheless commendable, and to Schamberg, the discovery he himself made should be a source of satisfaction.

MORRIS WAISMAN, MD
Tampa, Fla

In Reply.—I appreciate Dr Waisman's interest in my letter. My chief reaction is amazement and admiration for his instant recall of a paper published 55 years ago. He wrote to me: "Puncta pruritica was a paragraph in fine print in Ormsby's text. As a resident the description fascinated me because so curious and unique. I looked forward to spotting some cases, but never in all the years have I encountered one. I envy your experience with this rarity and am glad that you reported."

Comparison of puncta pruritica and the entity described by me shows many similarities. In both disorders the itching is discontinuous; one or more small discrete points are affected; examination of the skin reveals no evidence of dermatitis; fingernail pressure or pinching suffices and scratching is not needed to relieve the itch; and treatment is ineffective. There are a few differences in the descriptions of the disorder: Toomey stated the itch is of ten to 60 minutes duration, while I find it much more brief, often being simply momentary. Toomey found the itching to be most often localized over bony prominences; I was not impressed by this. I found lesions usually centripetal; he did not. Despite these differences, it appears we are looking at essentially the same entity.

I am grateful to Dr Alexander A. Fisher for sending me a reprint of the "PPPP syndrome."[1] And, lo and behold, the seventh P-alliterative title in the dermatologic stable[2] crossed my desk just the other day.

IRA LEO SCHAMBERG, MD
Elkins Park, Pa

1. Fisher AA: Allergic petechial and purpuric rubber dermatitis: The PPPP syndrome. *Cutis* 14:25, 1974.
2. Persistent Pigmented Pruritic Posterior Plaques. *The Schoch Letter*, 27, no 7, item 53, 1977, p 14.

Balance Beam Alopecia

To the Editor.—Six months ago I saw a young woman who complained of hair loss. She had obvious hair loss from the frontal scalp to the occiput in a linear distribution along either side of the vertex.

Examination of the hairs showed no microscopic abnormality, and the scalp appeared entirely normal. The hair was parted through the central portion of the involved area, and I felt that traction might have been involved in the hair loss pattern. The patient denied traction, and stated that she brushed infrequently. I again saw this patient four months later for a different problem. I asked her how her hair was doing, and she stated, "it is growing back now that I have stopped using the balance beam."

The balance beam is an apparatus used by gymnasts. During practice, head stands and rollovers are performed repeatedly. One can imagine the amount of traction applied to the vertex of the scalp.

Since I have become aware of this phenomenon, I have seen three similar cases, and in each case the patient was a young woman who practiced gymnastics. As gymnastics becomes more and more popular, this entity will be seen with greater frequency.

P. HAINES ELY, MD
Roseville, Calif

SYNALAR®
(fluocinolone acetonide)
CREAM 0.025%
CREAM 0.01%
OINTMENT 0.025%
SOLUTION 0.01%

Description Synalar (fluocinolone acetonide) has the chemical name 9α-difluoro-16α-hydroxyprednisolone 17-acetonide.

The cream contains fluocinolone acetonide 0.25 mg./g. or 0.1 mg./g. in a water-washable aqueous base of stearic acid, propylene glycol, sorbitan monostearate and monooleate, polysorbate 60, purified water and citric acid with methylparaben and propylparaben as preservatives.

The ointment contains fluocinolone acetonide 0.25 mg./g. in a white petrolatum U.S.P. vehicle.

The solution contains fluocinolone acetonide 0.1 mg./g. in a water-washable base of propylene glycol with citric acid.

Indications For relief of the inflammatory manifestations of corticosteroid-responsive dermatoses.

Contraindications Topical steroids are contraindicated in vaccinia and varicella.

Topical steroids are contraindicated in those patients with a history of hypersensitivity to any of the components of the preparation.

Precautions If irritation develops, the product should be discontinued and appropriate therapy instituted.

In the presence of an infection the use of an appropriate antifungal or antibacterial agent should be instituted. If a favorable response does not occur promptly, the corticosteroid should be discontinued until the infection has been adequately controlled.

If extensive areas are treated or if the occlusive technique is used, the possibility exists of increased systemic absorption of the corticosteroid and suitable precautions should be taken.

Although topical steroids have not been reported to have an adverse effect on pregnancy, the safety of their use in pregnant females has not absolutely been established. Therefore, they should not be used extensively on pregnant patients, in large amounts, or for prolonged periods of time.

Synalar products are not for ophthalmic use.

Adverse reactions The following local adverse reactions have been reported with topical corticosteroids: burning, itching, irritation, dryness, folliculitis, hypertrichosis, acneform eruptions, hypopigmentation.

The following may occur more frequently with occlusive dressings than without such therapy: maceration of the skin, secondary infection, skin atrophy, striae, miliaria.

How Supplied
Synalar (fluocinolone acetonide)
Cream 0.025% — 15 and 60g. tubes and 120 and 425g. jars.
Cream 0.01% — 15, 45 and 60g. tubes and 120 and 425g. jars.
Ointment 0.025% — 15 and 60g. tubes and 425g. jars.
Solution 0.01% — 20cc. and 60cc. plastic squeeze bottles.

Also Available
Synalar-HP® (fluocinolone acetonide) Cream 0.2% 5g. and 12g. tubes.

SYNTEX
SYNTEX LABORATORIES, INC.

ES USEFUL TODAY AS THE
AY IT WAS INTRODUCED

SYNALAR
(FLUOCINOLONE
ACETONIDE)

See preceding page for sum
of prescribing information

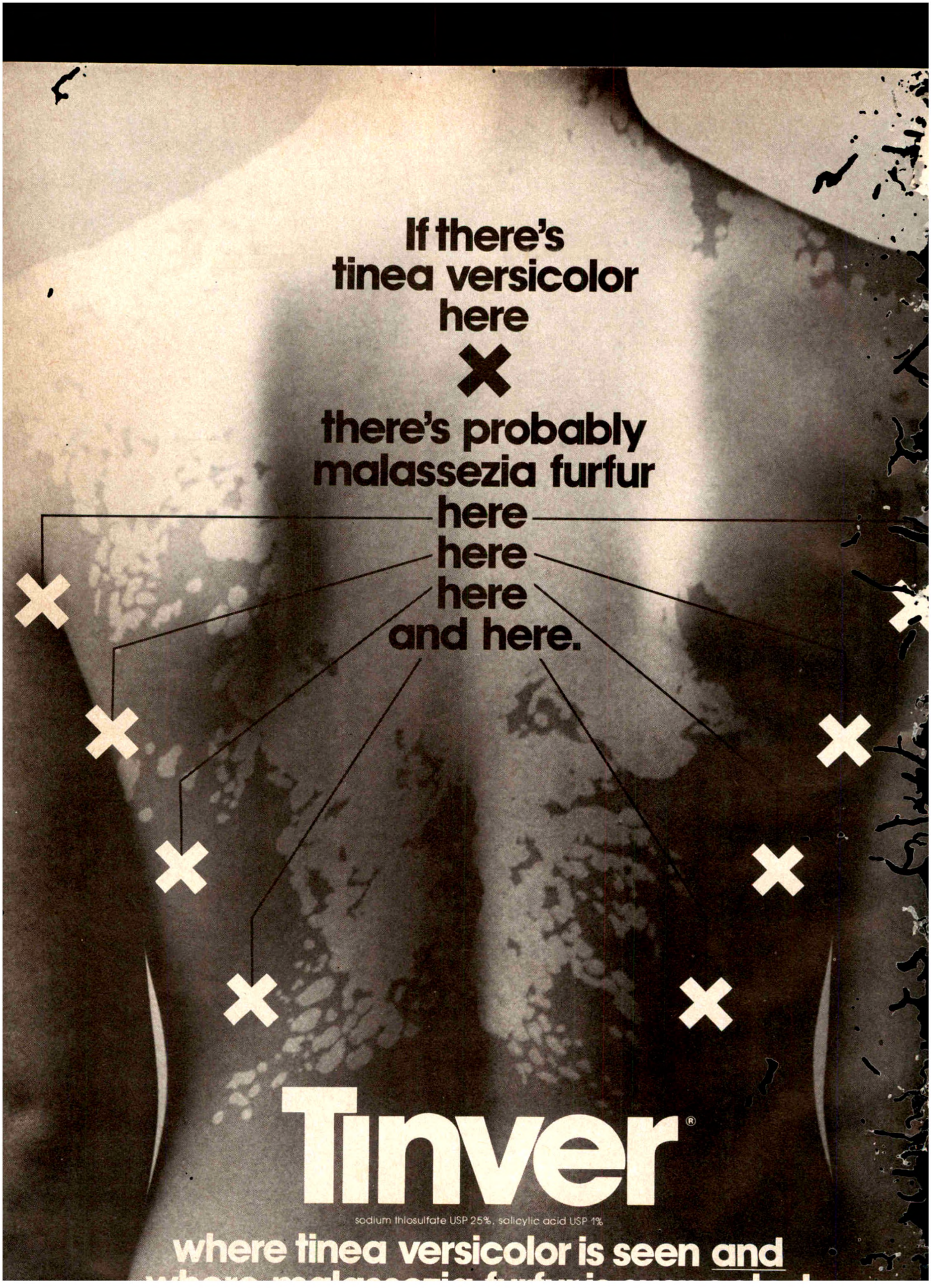
If there's
tinea versicolor
here
there's probably
malassezia furfur
here
here
here
and here.
Tinver®
sodium thiosulfate USP 25%, salicylic acid USP 1%
where tinea versicolor is seen and

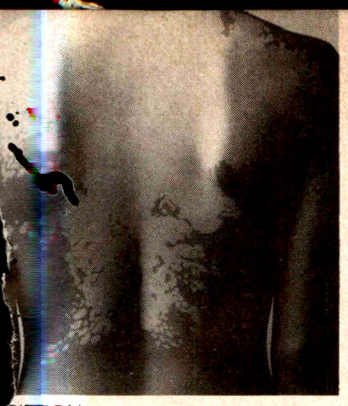

RIPTION:
um thiosulfate 25%, salicylic acid
sopropyl alcohol NF 10%,
ylene glycol USP, menthol USP,
um edetate, colloidal alumina,
rified water.

ONS:
l use in the treatment of tinea
(Malassezia furfur infection).

NS:
ation or sensitivity develop,
se. Do not use on or about

N:
n, rinse and dry the
before application of
ly a thin film of lotion
reas and other
s twice a day.
stic evidence of the
appear in a few days,
continue treatment
er period. Clothing
d to prevent reinfection.

dispenser bottles.

w prohibits dispensing
ption.

Hind Pharmaceuticals, Inc.
ter Road
vale, California 94086

nver®

thiosulfate USP 25%, salicylic acid USP 1%

News and Notes

Pediatric Dermatology Symposium.—This four-day symposium, which is to be held at Stanford University on Aug 9 through 12, 1978, will focus on recent advances in neonatal dermatoses, genodermatoses, and practical skin therapies. It is an American Medical Association-accredited postgraduate seminar. For information, contact Paul H. Jacobs, MD, Department of Dermatology, Stanford University School of Medicine, Stanford, CA 94305, or phone (415) 497-6101.

Advances in Dermatology.—The Department of Dermatology of Northwestern University Medical School, Chicago, announces a postgraduate course, "Advances in Dermatology." The course will be held Oct 19-20, 1978, at the Alumni Center of Northwestern University. Guest speakers include Drs Robert Goltz, Denny Tuffanelli, and Stephen Webster. The faculty includes Drs Henry H. Roenigk, Jr, William Caro, Ruth Freinkel, Nancy Esterly, and Nancy Furey. Topics will include: psoriasis; PUVA; pediatric dermatology; connective tissue disorders; acne and bullous diseases.

The Chicago Dermatological Society will hold its three-day clinical meeting immediately after the postgraduate course, Oct 20-22, 1978, at the Ritz-Carlton Hotel (two blocks from Northwestern University). Guest speakers will be announced later. For information contact Dr Henry H. Roenigk, Jr, Department of Dermatology, Northwestern University Medical School, 303 E Chicago Ave, Chicago, IL 60611.

American Dermatological Association Election.—Newly elected officers and directors of the American Dermatological Association are Anthony N. Domonkos, MD, President; James B. Howell, MD, vice-president; and Milton Orkin, MD, board of directors.

Tropical Dermatology.—The Fourth World Congress of Tropical Dermatology (International Society of Tropical Dermatology) will take place Sept 23-26, 1979 at the Marriott Hotel in New Orleans. For information contact Ted Driscoll, 7109 Masters Dr, Pótomac, MD 20854; telephone, (310) 299-

Ultrasound, Sound, Microwaves, Laser, and Ultraviolet.—A course entitled "Ultrasound, Sound, Microwaves, Laser, and Ultraviolet: Biophysical and Biological Basis, Hazards, and Applications in Medicine and Industry" will be held at Massachusetts Institute of Technology, Cambridge, from July 24 to 28, 1978.

The course will emphasize practical considerations in safe and effective use of these modalities in medical and industrial practice, eg, methods and instrumentation for power measurement, calibration, and dosimetry, and compliance with federal and state regulations.

For further information, please contact Director of Summer Sessions, Room E19-356, Massachusetts Institute of Technology, Cambridge, MA 02139.

Scholarship Program for Dermatologic Surgery.—The American Society for Dermatologic Surgery announces its fourth annual scholarship program to emphasize the scope and importance of surgery in dermatology and to disseminate surgical knowledge and training in our specialty. A number of grants of variable amounts and for variable periods of time will be awarded to defray some or all of the expenses of such training. Applicants must be in an approved dermatology residency training program and finish the surgical elective at least six months before the completion of the residency; or be a full-time faculty member in an approved dermatology program; or be actively involved in a dermatology training program in some other capacity. Surgical training in teaching institutions and private practices are acceptable. Other proposals for obtaining training suggested by the candidates will be considered.

Applications, subject to the approval of the training director, should be submitted by Oct 15, 1978.

Scholarship awards will be announced at the American Society for Dermatologic Surgery meeting at the American Academy of Dermatology in December. For further information and applications, write to Edward A. Krull, MD, chairman, scholarship committee, Henry Ford Hospital, Department of Dermatology, Detroit, MI

INDEX TO ADVERTISERS

A

Abbott Laboratories 816-817

B

Barnes-Hind Pharmaceuticals 970-971
Burroughs Wellcome Company 815

C

Campbell Laboratories, Inc. 844
Cooper Laboratories, Inc. 819

D

Dermik Laboratories 853, 972-973
Doak Pharmacal Company 847
Dome Laboratories 830-831, 858-859

G

General Foods 829
General Medical Company 822

H

Herbert, G.S., Laboratories, Division of Allergan Pharmaceuticals 828
Hoechst-Roussel Pharmaceuticals 836-838

I

International Light Inc. 838

J

Johnson & Johnson 850-851, 863

L

Lederle Laboratories, Division of American Cyanamid Company 845-846, 854-855

O

Owen Laboratories, Inc. ..... 3rd Cover

P

Parke-Davis & Company 974-975
Pharmacia Diagnostics 852
Plough Advertising 865
Procter & Gamble Company 813, 828A-828B, 862A-862F
Purdue Frederick Company 827

R

Reed & Carnrick 834-835
Riker Laboratories Inc. 826
Roche Laboratories, Division of Hoffmann-LaRoche, Inc. 840-841
Roerig, J.B., Company Division of Pfizer, Inc. 832-833

S

Saunders, W.B., Company 839
Schering Corporation 848-849, 958-960
Squibb, E.R., & Sons, Inc. 866-868
Stiefel Laboratories, Inc. 823, 856
Stuart Pharmaceuticals Div. of ICI Americas Inc. 825
Syntex Laboratories, Inc. 820-822, 860-862, 968-969

T

Texas Pharmacal Company 864

U

University of Pittsburgh 838

W

Westwood Pharmaceuticals, Inc. ..... 2nd Cover, 842-844, 857, 870, 951-952, 4th Cover

While every precaution is taken to insure accuracy, we cannot guarantee against the possibility of an occasional change or omission in the preparation of this index.

HYTONE® Cream
(hydrocortisone)

Description: Hydrocortisone ½%, 1% or 2½% in a water-washable cream co purified water, propylene glycol, glyceryl monostearate, cholesterol and related isopropyl myristate, polysorbate 60, cetyl alcohol, sorbitan monostearate, poly stearate and sorbic acid.

Action: Topical steroids are primarily effective because of their anti-inflamma antipruritic and vasoconstrictive actions.

Indications: For relief of the inflammatory manifestations of corticosteroid-r dermatoses.

Contraindications: Topical steroids are contraindicated in those patients w of hypersensitivity to any of the components of the preparation.

Precautions: If irritation develops, the product should be discontinued and a therapy instituted.

In the presence of an infection the use of an appropriate antifungal or antibacte should be instituted. If a favorable response does not occur promptly, the corti should be discontinued until the infection has been adequately controlled.

If extensive areas are treated or if the occlusive technique is used there will systemic absorption of the corticosteroid and suitable precautions should particularly in children and infants.

Although topical steroids have not been reported to have an adverse effe pregnancy, the safety of their use in pregnant women has not absolutely In laboratory animals, increases in incidence of fetal abnormalities hav with exposure of gestating females to topical corticosteroids, in some low dosage levels. Therefore, drugs of this class should not be used ext patients, in large amounts, or for prolonged periods of time.

The product is not for ophthalmic use.

Adverse Reactions: The following local adverse reactions have topical corticosteroids, especially under occlusive dressings: bur dryness, folliculitis, hypertrichosis, acneform eruptions, hypopig dermatitis, allergic contact dermatitis, maceration of the skin, s atrophy, striae, miliaria.

Dosage and Administration: Apply to affected areas 3 or 4

How supplied: 2½% – Tube 1 oz.; 1% and ½% – Tube 1 oz.

Caution: Federal law prohibits dispensing without prescriptio

VYTONE® Crean
(diiodohydroxyquin 1%, hydrocortisone 1

Description: Vytone Cream contains hydrocortisone 0.5% c 1% in a greaseless cream of purified water, propylene glycol cholesterol and related sterols, isopropyl myristate, polysorba sorbitan monostearate, polyoxyl 40 stearate and sorbic acid.

Actions: Combines the antifungal and antibacterial actions anti-inflammatory and antipruritic effects of hydrocortisone, p broader control of various acute and chronic dermatological d

Indications: Based on a review of a related drug by the Council and subsequent FDA classification for that drug, t follows:

"Possibly" Effective: Contact or atopic dermatitis; impetigi nummular eczema; infantile eczema; endogeneous chronic stasis dermatitis; pyoderma; nuchal eczema and chronic ec externa; acne urticata; localized or disseminated neuroderm chronicus; anogenital pruritis (vulvae, scroti, ani); folliculitis, toses; mycotic dermatoses such as tinea (capitis, cruris, corpo monilliasis; intertrigo. Final classification of the less-than-effec requires further investigation.

Contraindications: Topical steroids are contraindicated in viral diseases as varicella and vaccinia and in individuals when circulation is markedly i Cream is contraindicated in those patients with a history of hypersensitivi components of the preparation.

Warnings – Usage in Pregnancy: Although topical steroids have not bee have an adverse effect on the fetus, the safety of their use on pregnant pati been absolutely established. Therefore, they should not be used extensively, amounts or for prolonged periods of time on pregnant patients.

Precautions: For external use only. Keep away from eyes. If irritation develo product should be discontinued and appropriate therapy instituted. If extensiv treated or if the occlusive technique is used, the possibility exists of increas absorption of the corticosteroid and suitable precautions should be taken. Ma skin, hair, or fabrics. Diiodohydroxyquin may be absorbed through the skin and with thyroid function tests. If such tests are contemplated, wait at least one m discontinuance of therapy to perform these tests. The ferric chloride test for ph ketonuria (PKU) can yield a false positive result if diiodo droxyquin is present diaper or urine.

Prolonged use may result in overgrowth of nonsusceptib organisms requiring appropri therapy. Keep out of the reach of children.

Adverse Reactions: The following adverse reactions have been reported with top al steroids, either with or without occlusive dressings: burning sensations, itching, irrita dryness, folliculitis, secondary infection, skin atrophy, striae, hypertrichosis, acnef eruption, and hypopigmentation.

Dosage and Administration: Apply to affected areas 3 or 4 times daily in accor with physician's directions.

How Supplied: Tubes, 1 oz.

Caution: Federal law prohibits dispensing without prescription.

For Patient Starters Call Toll-Free (800) 523-6674

Dermik

Dermik Laboratories, Inc., Fort Washington, Pa. U.S.A. 1903

Front Runner



HYTONE® 2½% Cream

(hydrocortisone)

for rapid control of the majority of inflammatory dermatoses seen in office practice—a logical alternative to the fluorinated steroids.

Followed by HYTONE® 1% or 1/2% Cream, for maintenance therapy and ultimate control.

VYTONE® 1% or ½% Cream (diiodohydroxyquin 1%, hydrocortisone 1% or 1/2%)

for broader control of various acute and chronic dermatoses— hydrocortisone plus the antibacterial/antifungal actions of diiodohydroxyquin.

(Vytone has been evaluated as possibly effective for these indications; see adjoining prescribing information.)

Vectrin® Capsules

(minocycline hydrochloride capsules, USP)

50 and 100 mg

effective adjunctive treatment in severe acne

Before Treatment | After Treatment

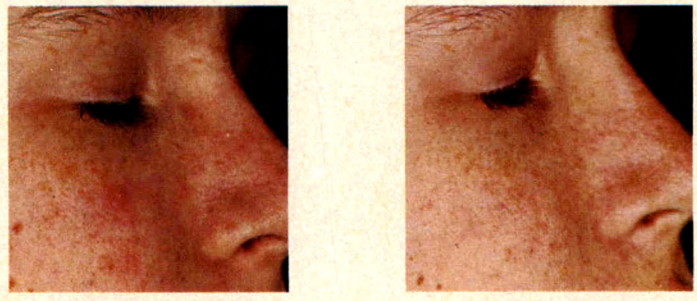

84 DAYS
Vectrin, 50 mg, twice daily

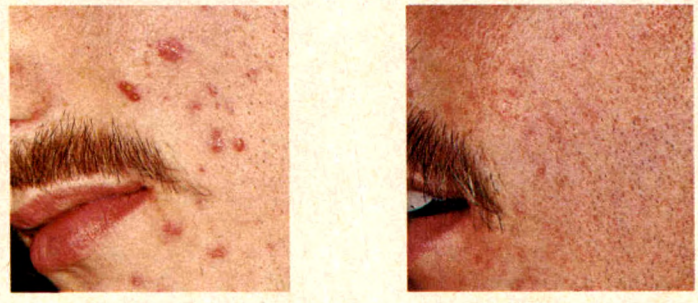

91 DAYS
Vectrin, 50 mg, twice daily

40 DAYS
Vectrin, 100 mg, once daily

84 DAYS
Vectrin, 100 mg, once daily

PARKE-DAVIS

See following page for brief summary of prescribing information.

HN Capsules, 50 and 100 mg
cycline HCl capsules, USP)
Summary Prescribing Information
d in severe acne as adjunctive therapy. Consult ge insert for complete prescribing information.
indication: Hypersensitivity to any tetracycline.
ngs: When need for intensive treatment outweighs tial dangers, perform renal and liver function tests and during therapy; also follow serum concen- ns. In renal impairment, usual doses may lead to si accumulation and liver toxicity. Under such tions, use lower total doses, and, in prolonged y, determine serum levels. The use of tetracyclines tooth development (last half of pregnancy, y, and childhood to the age of 8 years) may cause anent discoloration of the teeth (yellow-gray- This is more common during long-term use s been observed following repeated short-term es. Enamel hypoplasia has also been reported. cyclines, therefore, should not be used in this age unless other drugs are not likely to be effective contraindicated. Photosensitivity manifested by aggerated sunburn reaction has been observed ne individuals taking tetracyclines. Advise patients be exposed to direct sunlight or ultraviolet light uch reaction can occur, and discontinue treatment evidence of skin erythema. Studies with cycline HCl indicated that photosensitivity did ccur. However, reports have been received. ients with significantly impaired renal function, ntiabolic action of tetracycline may cause crease in BUN leading to azotemia, hyperphos- mia, and acidosis. **CNS side effects:** (light- edness, dizziness, vertigo) have been reported, disappear during therapy, and always disappear when drug is discontinued. Caution patients who ience these symptoms about driving vehicles or hazardous machinery while taking this drug. **nancy:** In animal studies, tetracyclines cross the nta, are found in fetal tissues, and can have toxic s on the developing fetus (often related to retar- n of skeletal development). Embryotoxicity has noted in animals treated early in pregnancy. The of minocycline HCl for use during pregnancy ot been established. **Newborns, infants, and ren:** All tetracyclines form a stable calcium plex in any bone-forming tissue. Prematures, oral doses of 25 mg/kg every six hours, demon- d a decrease in fibula growth rate, reversible when was discontinued. Tetracyclines are present in ilk of lactating women who are taking a drug in lass.
autions: Use may result in overgrowth of non- eptible organisms, including fungi. If superinfection rs, antibiotics should be discontinued and appro- therapy instituted. In venereal diseases when istent syphilis is suspected, darkfield examination ld be done before treatment is started and blood ogy repeated monthly for at least four months. nts on anticoagulant therapy may require down- adjustment of such dosage. Test for organ system nction (eg, renal, hepatic, and hemopoietic) in term use. Treat all group A beta-hemolytic tococcal infections for at least 10 days. Avoid g tetracycline in conjunction with penicillin.
erse Reactions: GI: Anorexia, nausea, vomiting, hea, glossitis, dysphagia, enterocolitis, inflam- ry lesions (with monilial overgrowth) in anogenital n. **Skin:** Maculopapular and erythematous rashes. ative dermatitis (uncommon). Photosensitivity is ssed above. (See Warnings.) **Renal toxicity:** Rise N, dose-related. (See Warnings.) **Hypersensitivity tions:** Urticaria, angioneurotic edema, anaphylaxis, hylactoid purpura, pericarditis, exacerbation of mic lupus erythematosus. In young infants, bulging els have been reported following full therapeutic ge, disappearing rapidly when drug was ntinued. **Blood:** Hemolytic anemia, thrombo- enia, neutropenia, eosinophilia. **CNS:** (See ngs.) When given over prolonged periods, cyclines may produce brown-black microscopic loration of thyroid glands; no abnormalities of d function studies are known to occur.
E: Concomitant therapy: Antacids containing inum, calcium, or magnesium impair absorption; ot give to patients taking oral tetracycline. Studies ate indicate that absorption of VECTRIN (mino- ine hydrochloride) is not notably influenced by s and dairy products.
prescribing information available upon request.
DAVIS & COMPANY
MI 48232
DA-2378-1-P (2-78)

Society Transactions

The Society Proceedings are edited by Dr Harry L. Arnold, Jr, Straub Clinic, Honolulu, HI 96813. Transactions and photographs should be sent, in duplicate, directly to him.

PHILADELPHIA DERMATOLOGICAL SOCIETY

Nov 21, 1975

Waine C. Johnson, MD, Recorder

Acrodermatitis Enteropathica. Presented by JAMES J. LEYDEN, MD, and JOHN J. LASKAS JR, MD

An erythematous, scaling, pustular eruption over the hands, feet, arms, legs, and face developed at 3 weeks of age in a 29-year-old man. This has persisted throughout his life and alopecia and contractures of the fingers and legs gradually developed. Numerous topical medications have been used without notable improvement. Physical examination at this time shows an almost total alopecia of the scalp, an erythematous scaling eruption of the face, and thick scales and plaques on the palms, soles, and digits. Results of numerous laboratory studies have been normal and the serum zinc level was 0.05 mg/dl (normal, 0.05 to 0.15 mg/dl). A biopsy specimen in 1973 showed a psoriasiform reaction. Treatment recently with oral zinc sulfate (200 mg four times a day) has resulted in considerable improvement.

Discussion

ALBERT M. KLIGMAN, MD: I saw this patient many years ago and considered the possibility of moniliasis and ichthyosiform erythroderma, but the features were not distinct or clear-cut. As I recall, he did not respond well to diiodohydroxyquin (Diodoquin) and diarrhea was not a prominent feature. There has been considerable improvement in this patient's condition since zinc sulfate therapy was begun.

RAUL FLEISCHMAJER, MD: I remember an entity that occurs in pigs and is known as porokeratosis. This is true zinc deficiency that results in diffuse scaling, alopecia, and hyperkeratosis of the esophageal mucosa and that histologically resembles psoriasis. I wonder whether zinc may not be a cofactor for an enzyme in the process of keratinization.

DR PAUL GROSS: There was a letter to the editor in *Lancet* from a Danish group that proposed that the mechanism in acrodermatitis enteropathica was failure of gut transportation of zinc, and the reason diiodohydroxyquin was sometimes effective was that it served to carry the zinc molecule across the membrane for absorption.

DR KLIGMAN: Since this patient's serum level is at the lower limit of normal and if it is accurate, one has to raise the question as to whether this patient actually has acrodermatitis enteropathica and whether there are other diseases that zinc sulfate may improve.

May 21, 1976

Waine C. Johnson, MD, Recorder

Hyperlipidemia. Presented by JOSEPH K. CORSON, MD

This 66-year-old woman had an unrelated skin lesion on one forearm. It was noted that she had yellow nodules on the elbows and yellowing of the palmar creases. The lesions had been present for several years. She had had substernal pain recently, but an ECG was normal. In 1970 her cholesterol level was 500 mg/dl and triglyceride level was 135 mg/dl. In 1975 results from a lipoprotein electrophoresis showed a broad β band, and in 1976 they showed a heavy pre-β band.

Discussion

RAUL FLEISCHMAJER, MD: The patient has tuberous xanthomas. The lipid profile in 1970 suggests a type II pattern. At a later date the same studies showed an increase in cholesterol and triglyceride levels, which suggested a type III pattern. Later on a type IV pattern emerged. Thus, the lipoprotein pattern is not consistent and does not appear to identify a specific genotype. The latest genetic classification of hyperlipidemias is that of Goldstein et al (*J Clin Invest* 52:1544, 1973), and it is based on whether there is an increase in cholesterol, triglycerides, or both. I think this patient has a type II-B pattern, which explains also the increase in triglycerides.

Although the disease is transmitted as a single dominant gene, the hyperlipidemia does not seem to be an important factor in the incidence of arteriosclerosis in this family.

ALBERT KLIGMAN, MD: What about the clinical classification of this case?

DR FLEISCHMAJER: Clinically I would say that this is a type II or, what used to be called, essential familial hypercholesterolemia. Type I is extremely rare and type IV is usually associated with diabetes. Type V is probably a variant of type IV. Types IV and V are usually associated with eruptive xanthomas. One cannot rule out type III, although some authors have questioned the existence of this pattern.

DR KLIGMAN: Will a low-fat diet help this patient?

DR FLEISCHMAJER: Type II usually does not respond well to a diet. Since this case appears to be a type II-B, she should be placed on a low-cholesterol, low-carbohydrate diet. If there is no response, then I would suggest treatment with clofibrate (Atromid-S), with a dosage of 500 mg four times a day.

Michigan Dermatological Society

Feb 11, 1976

Amir H. Mehregan, MD, Recorder

Cerebriform Nevus. Presented by EDWARD A. KRULL, MD, AND M. D. SIEGEL, MD.

A 19-year-old woman has had a large growth on her scalp since birth. The lesion

has gradually increased in size proportionally to her total body growth without much concern to her or to her parents. There are no physical or mental abnormalities.

Physical examination shows a large, hairless, unreddened, cerebriform plaque covering much of the occipital portion of the scalp. On the surface of the lesion are numerous irregularly shaped nodules, some firm and others with rubbery consistency. The patient also has many small pigmented nevi on her trunk.

A portion of the growth was surgically excised. A deep-seated, well-defined, jet black nodule was found under the lesion. This nodule was also removed. Histologic examination of the growth shows a papillomatous pigmented nevus with numerous nests of nevus cells in the dermis. Some of the deep nevus cell nests show neuroid structures. The covering epidermis shows papillomatous hyperplasia and hyperpigmentation. There are no areas of junctional activity. The deep-seated black nodule consisted of dense proliferation of heavily pigmented, dendritic dermal melanocytes that formed intersecting bundles. There are also large numbers of macrophages containing melanin granules. Histologic diagnosis is cerebriform pigmented nevus with an underlying blue nevus.

Discussion

DR KRULL: An excellent review of cerebriform nevus was made by Dr Milton Orkin and his colleagues[1] in 1974. Clinically, cerebriform nevus is present at birth and shows either a gradual increase in size or a rapid growth from the ages of 5 to 10 years. Frequently, a third to half of the scalp, especially the occipital region, is involved. One common manifestation is progressive alopecia, which was so obvious in this case. A musty odor frequently emanates from the lesion, and occasionally there may be itching, pain, or burning sensation. Recurrent infection is not uncommon. The enlarged lymph node, present on one side of this patient's neck, is most likely secondary to this complication. Two instances of malignant melanoma have been reported developing in such nevi, and this accounts for 4% of the cases reported. However, this does not indicate true incidence of malignancy, which is probably much lower, since not all the uncomplicated cerebriform nevi are reported. In contrast to the giant or bathing trunk type of nevi, the cerebriform nevi show no associated epilepsy or other mental or neurologic disorders. An x-ray film of the lesion may show soft tissue calcification. The only effective treatment is surgical excision and plastic repair.

What about the blue nevus observed in this case? This deep seated lesion was movable and in surgery appeared as a well-defined black color nodule. We do not know what the incidence of blue nevus is in cerebriform nevi. However, in giant nevi in the series reported by W. B. Reed and his colleagues,[2] 11 of 55 cases showed associated blue nevi. Interestingly, in three of their cases with malignant melanoma in giant nevi, the blue nevus was associated with the melanoma, but it could not be determined if it was the source of melanoma.

Cutaneous Leishmaniasis. Presented by ALEJANDRO MORALES, MD, AND M. W. SHAPIRO, MD.

The patient is a 38-year-old white man who visited Iraq for six months in 1975. Three months prior to his return, an eruption developed on his hands and feet. The lesions were diagnosed as cutaneous leishmaniasis and were treated with 13 injections of stibophen (Fuadin) for a total course of 50 ml two months, without any response.

Multiple well-defined plaques were present over the dorsa of the hands and feet (Figure). Some lesions were annular, with rolled infiltrated border and central crust. Other lesions were elevated nodules with fungating crusted surface.

Histologic examination showed a very heavy dermal infiltrate of lymphocytes, histiocytes, and plasma cells. Many of the histiocytes contained Leishman's bodies.

Discussion

DR SHAPIRO: Cutaneous leishmaniasis is an endemic disease in Asia, Asia Minor, North Africa, the Mediterranean coast, Central and South America. The organism is from the family of Trypanosomidae, and there are at least four species: *Leishmania tropica* is exemplified by this case; *L braziliensis*, which causes mucocutar leishmaniasis; *L donovani*, the organis kala azar; and *L mexicana*, which ca chiclero's ulcer. Most likely, *L tropic* two different strains. In its mamm host, it exists as an organism (length, μ; width, 1 to 1.5 μ) with a poster located 1-μ round nucleus and parani or kinetoplast, and extending surface, is a sheet within which is flagellum. When the organism is ing by the *Phlebotomus* fly, it converts int leptomonad form that is 15 to 20 μ long this is also the form that grows in culture.

The cultural and morphologic chara istics of all four types of *Leishmania* identical. They cannot be identified ex by the clinical disease that they proc However, by electron microscopy *L tro* shows absence of rough endoplasmic r ulum and has greater pinocytic act than *L donovani*. The organism is cult in Novy-Neal-Nicolle's medium at 2 35°C. Reservoirs for the organism ar dog, cat, and various rodents. In m incubation period is ten days to sev months, generally around two or t weeks.

There are classically two clinical pre tations. The wet or early ulcerative f occurs in rural areas. The lesion is infl matory and may be associated lymphangitis. Secondary nodules may velop along the inflamed lymph chan The lesion grows for two or three mo and usually resolves within three to months. The dry or urban variety or late ulcerative form tends to grow n slowly, for two to six months, and res within one year. The lesion appears red to purplish papule or nodule, w tends to enlarge. It may or may ulcerate and leaves a stellate depres scar.

Intradermal Montenegro's test is p tive in 80% to 95% of cases. It may negative in the early stage of infection is usually negative in the anergic vari Since the lesions are self-healing, tr ment may not be necessary. Small lesi may be treated by cryotherapy or surg excision. Large or multiple lesions treated by various antimonial preparati intramuscularly or by amphotericin B. patient is now receiving medication w metronidazole.

Circular lesion with infiltrated border of leg (top) and elevated nodular lesion over dorsum of hand (bottom).

Nonproprietary Names and Trademarks of Drugs

Amphotericin B–*Fungizone*.
Metronidazole–*Flagyl*.

References

1. Orkin M, Frichot BC III, Zelickson Cerebriform intradermal nevus: A cause of c vercitis gyrata. *Arch Dermatol* 110:575- 1974.

2. Reed WB, Becker SW, Becker SW Jr, e Giant pigmented nevi, melanoma, and lept ningeal melanocytosis. *Arch Dermatol* 91: 119, 1965.

for psoriasis/eczema
psoriGel™
a tar concentrate in an emollient gel
NET WT. 4 OZ.
Tar therapy has progressed one step further.
psoriGel™: a proven effective tar concentrate in an emollient vehicle for the treatment of psoriasis, eczema, and other tar responsive dermatoses.
Owen
Owen Laboratories, Dallas, Texas 75234
Division of Alcon Laboratories, Inc.

You've made PreSun® (5% PABA) number one*

Now, a major clinical sunscreen study confirms PreSun's premier sunscreen position.

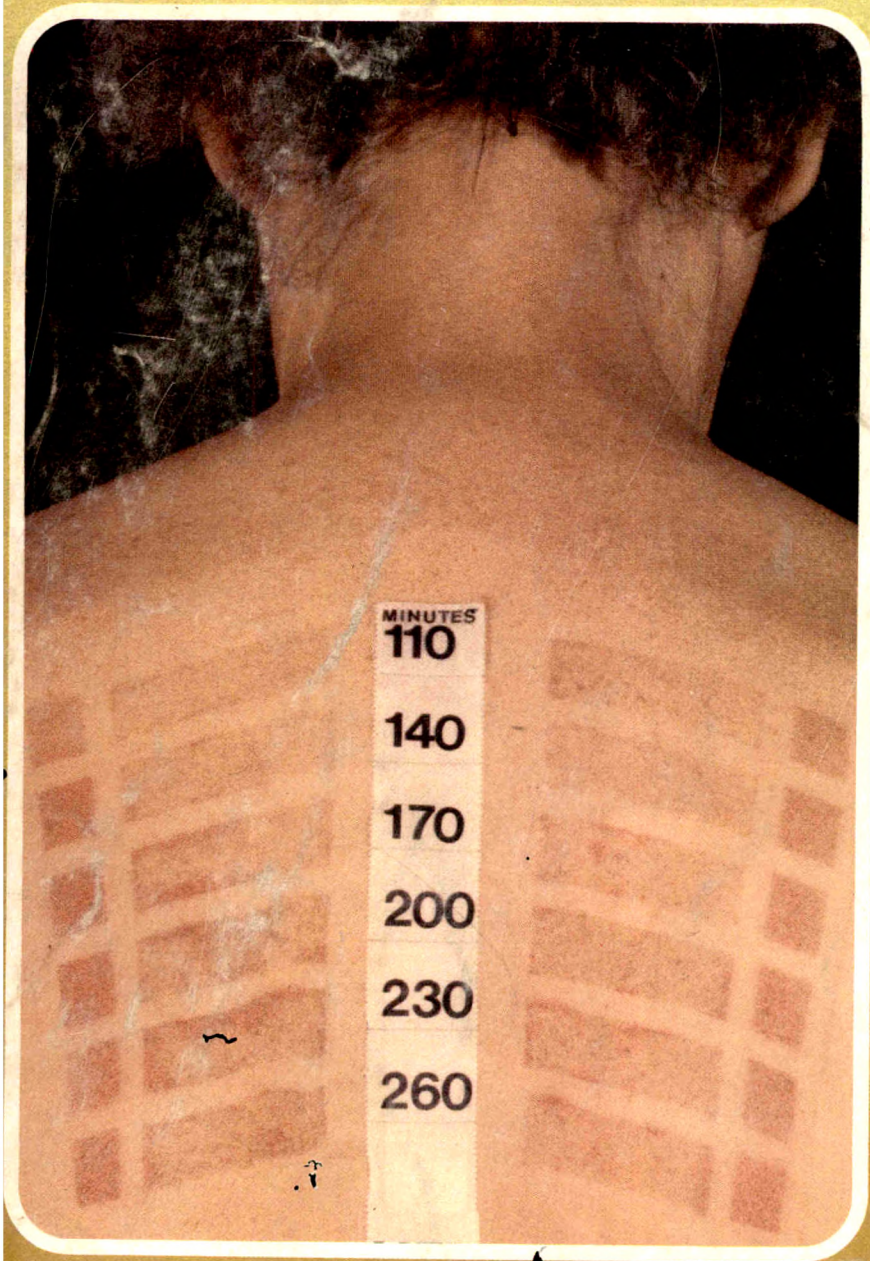

Unretouched photo of subject's back, PreSun® applied (right) and another sunscreen product (left).

Westwood designed its most rigidly controlled sunscreen study to date; 68 sun-sensitive volunteers were exposed to increasing amounts of southern California sunlight up to 4 hours. This complex investigation demonstrated important differences between the degree of protection that sunscreen products afford. PreSun® was shown to afford maximum sunscreen protection. On an average, PreSun allowed the sun-sensitive individual to withstand the sun *over eight times longer* before acquiring a slight, painless reddening, than he could unprotected.** PRESUN CONTINUES TO SET THE SUNSCREEN STANDARD. DON'T JEOPARDIZE THE SKIN OF YOUR SUN-SENSITIVE PATIENTS WITH JUST ANY FORMULA.

PreSun® may also help prevent premature aging and skin cancer caused by the sun.

*Based on retail sales of ethically promoted sunscreens.

**Information on file at Westwood Pharmaceuticals

WESTWOOD
PHARMACEUTICALS INC.
Buffalo, New York 14213
In Canada, Belleville, Ontario K8N 5E9